COUNTWAY LIBRARY
HC 4WUX %

Medical Library

BOSTON
MEDICAL LIBRARY
8 THE FENWAY

Date

Digitized by the Internet Archive
in 2025

https://archive.org/details/treatiseonorthop0000roya

A TREATISE

ON

ORTHOPAEDIC SURGERY

BY

ROYAL WHITMAN, M.D., M.R.C.S., F.A.C.S.

CONSULTANT TO THE HOSPITAL FOR THE RUPTURED AND CRIPPLED, TO ST. GILES AND ST. JOHN'S GUILD HOSPITALS, TO THE NEW YORK AND DARRACH HOMES FOR CRIPPLED CHILDREN, TO THE POLYCLINIC HOSPITAL, TO ST. AGNES'S HOSPITAL, WESTCHESTER AND TO THE SHRINERS' HOSPITAL AT MONTREAL, TO THE NEW YORK STATE BOARD OF HEALTH AND TO THE STATE DEPARTMENT OF LABOR; MEMBER OF THE NEW YORK SURGICAL SOCIETY, MEMBER OF THE AMERICAN, BRITISH, FRENCH, ITALIAN AND RUSSIAN ORTHOPAEDIC ASSOCIATIONS.

NINTH EDITION, THOROUGHLY REVISED

ILLUSTRATED WITH 981 ENGRAVINGS

18 P. 4
9th ed.

LEA & FEBIGER
PHILADELPHIA
1930

MEDICAL LIBRARY
OF THE
BOSTON

COPYRIGHT
LEA & FEBIGER
1930



18P78

PRINTED IN U. S. A.

DEDICATION OF THE FIRST EDITION

TO

VIRGIL P. GIBNEY, M.D., LL.D.

THIS VOLUME IS INSCRIBED

AS A TOKEN OF FRIENDSHIP ASSURED BY LONG ASSOCIATION

AND OF APPRECIATION OF HIS EFFORTS

FOR THE ADVANCEMENT OF

ORTHOPAEDIC SURGERY

MEDICAL LIBRARY
OF THE
BOSTON CITY HOSPITAL

PREFACE.

ORTHOPAEDIC Surgery is concerned with bodily mechanics, with the prevention and correction of deformity and with the conservation of the locomotive function.

It has become a specialty because of the time-absorbing character of the work and because of the technical difficulties that it involves, and its scope is determined by the aptitude and opportunity of those who practise it.

From this standpoint the selection of subjects and the space allotted to each have been determined primarily by their relative importance, numerical or otherwise, in a hospital service unhampered by any artificial restrictions.

This material, drawn from every department of medicine, composed of groups unrelated in etiology and pathology is ill adapted to conventional classification.

The only common basis is mechanical disability. The subject has been presented, therefore, as far as practicable from a functional standpoint and in a manner that has proved acceptable in clinical teaching. Thus, mindful that the majority of the deforming diseases are first cared for by the general practitioner, the writer has been at some pains to demonstrate methods of systematic physical examination that lead to early diagnosis and so to explain the relation of causes to consequences as to indicate in natural sequence the principles of preventive treatment.

This ninth edition has been thoroughly revised and by comparison with the first, which appeared in 1901, demonstrates clearly the great advance both in scope and method of this branch of surgery during the present century.

It pleases the author to assume, that since his book represents a continuity of personal experience, it has gained in interest and authority with each succeeding issue.

R. W.

NEW YORK CITY.

CONTENTS.

CHAPTER I.

TUBERCULOUS DISEASE OF THE SPINE.

Description — Pathology — Etiology — Statistics — General prognosis —Symptoms—Physical examination—Contour and flexibility of the spine—Divisions of the spine—Landmarks—The differential diagnosis of disease in the lower, middle, and upper regions of the spine——Treatment by horizontal fixation, by convex stretcher frame, by ambulatory supports, by plaster jackets, by Calot jacket, the plaster corset, by braces, by other means—The selection and adaptation of treatment for disease of the different regions of the spine—The complications of tuberculous disease of the spine—Abscess, course, symptoms, treatment—Paralysis—course, symptoms, treatment—Operative treatment—Recurrence of disease—Secondary deformities 17–113

CHAPTER II.

NON-TUBERCULOUS AFFECTIONS OF THE SPINE.

Syphilis — Malignant disease — Osteomyelitis, acute and chronic—Actinomycosis — Injury — Traumatic spondylitis — Typhoid spine —Gonorrheal arthritis of the spine — Arthritis — Spondylitis deformans, varieties—Kyphosis of adolescents—Rhachitic spine—Osteitis deformans—Tabetic deformity—Spondylolisthesis—Pain in the back—Deformity secondary to sciatica—Sciatic scoliosis—Disease and injury at the sacro-iliac articulation—Coccygodynia . 114–147

CHAPTER III.

LATERAL CURVATURE OF THE SPINE.

Description—habitual and fixed deformity, rotation and lateral-deviation—Pathology — Etiology — Statistics —Varieties — Distribution and effects of deformity — Symptoms — Diagnosis — Prognosis — Prevention of deformity—Desks, chairs—Principles of treatment—Treatment—by posture and exercises, general exercises, heavy exercises, special exercises — Supports. Forcible correction of deformity—Adjuncts in treatment—The Abbott treatment—Operative treatment—Supplemental treatment—Duration of treatment. 148–232

CHAPTER IV.

DEFORMITIES OF THE SPINE (CONTINUED). DEFORMITIES OF THE CHEST. THE FUNCTIONAL PATHOGENESIS OF DEFORMITY.

Variation in contour of the spine—Vertebral epiphysitis—Anterior-posterior deformities of the spine—Kyphosis—Lordosis—Congenital elevation of the scapula—Paralytic elevation of the scapula—Deficiency and malformation of vertebra—Abnormalities of ribs—Cervical ribs—Absence of ribs—Malformation of pectoral muscle—Abnormality of clavicle—Flat chest—Pigeon chest—Funnel chest—Minor Deformities—Snapping neck—Snapping jaw—Scapular crepitus —Acquired luxation or subluxation of the clavicle—Displacement of the acromio-clavicular articulation—Arthritis of the acromio-clavicular joint—Asymmetrical development—Functional pathogenesis of deformity—(Wolff's law)—Atrophy of bone—Hypertrophy of bone—Tables of height, weight, and circumference of the chest 233–257

CHAPTER V.

TUBERCULOUS DISEASE OF THE BONES AND JOINTS.

Predisposition—Mode of infection—Latent tuberculosis—Local predisposition—Statistics—distribution of disease, location, side affected, sex, age—Pathology—Varieties of disease—synovial—arborescent synovial form—rice bodies—caries sicca—Tuberculous rheumatism—Septic infection—Progress and method of repair—Prognosis—Diagnosis—Treatment—direct sunlight—operative and mechanical—by drugs—local applications—Iodoform filling—Cabot's fluids—Beck's preparation—X-ray—Active and passive congestion—venous stasis (Bier's treatment) 258–278

CHAPTER VI.

NON-TUBERCULOUS DISEASES OF THE JOINTS.

Syphilitic disease of joints—Gonococcal arthritis—Other forms of infectious arthritis—Acute osteomyelitis—Chronic sclerosing osteitis—Brodie's abscess—Hemorrhagic osteomyelitis—Arthritis deformans—Osteo-arthritis and rheumatoid arthritis—Varieties—Treatment—Still's disease—Gout—Rheumatism—Hemophilia—Hemarthrosis—Scorbutus—Charcot's disease—Other forms of arthropathy—Anchylosis—Treatment—Myositis ossificans—Malignant disease of bone 279–326

CHAPTER VII.

TUBERCULOUS DISEASE OF THE HIP-JOINT.

Pathology—Etiology—Statistics—Symptoms—Physical signs, stiffness, distortion, apparent lengthening, apparent shortening—Changes in contour—Atrophy—Causes of actual shortening—Measurements—Lovett's table—Kingsley's table—Explanation of physical signs—Differential diagnosis—Principles of treatment—The traction hip brace—Traction plasters—The Thomas brace—The plaster bandage—Various methods of reducing deformity—Comparison of methods of treatment—The long hip splint—The hip splint and the plaster spica—Other forms of apparatus—Bilateral hip disease—Hip disease in infancy—Hip disease in adult life—Arthrodesis—Abscess—statistics — sinuses — treatment — Operative treatment — exploration—excision—amputation—reduction of resistant deformity—Prognosis, mortality, functional results—Secondary deformities of hip disease—Treatment—Final results 327–417

CHAPTER VIII.

NON-TUBERCULOUS AFFECTIONS OF THE HIP-JOINT.

Statistics—Traumatisms at the hip—Acute infectious arthritis—Acute epiphysitis—Subacute arthritis—Gonococcal arthritis—Spontaneous dislocation—Extra-articular disease—Bursitis—Malignant disease at the hip-joint—Cysts of the femur—Osteitis fibrosa—Arthritis deformans—Osteochondritis-deformans coxæ juvenilis—Osteochondritis ischiopubica 418–434

CHAPTER IX.

TUBERCULOUS DISEASE OF THE KNEE-JOINT.

Pathology—Etiology—Statistics—Symptoms, primary and secondary distortions—Shortening and lengthening—Diagnosis—Differential diagnosis—Treatment—Reduction of deformity—Forms of braces—Accessories in treatment — Extra-articular disease — Abscess — Synovial tuberculosis—Operative treatment—arthrectomy, excision, amputation — Prognosis — mortality—functional results — General conclusions 435–460

CHAPTER X.

Non-tuberculous Affections and Deformities of the Knee-joint.

Injury in childhood—Acute synovitis—Chronic and recurrent synovitis—Intermittent synovitis—"Quiet effusion"—Injury to cartilage—Internal derangement of knee-joint—Displacement of a semilunar cartilage—Loose bodies in knee-joint—Osteochondritis desiccans—Osteochondromatosis—Cysts of the external semilunar cartilage—Rupture of the ligaments—Hyperplasia—Prepatellar bursitis—Pretibial bursitis—Enlargement of superficial pretibial bursa—Bursæ and cysts in the popliteal region—Injury of tibial tubercle—Chondromalacia of the patella—Acquired genu recurvatum—Congenital genu recurvatum—Rudimentary or absent patella—Patella biparta—Congenital and acquired displacement of patella—Slipping patella—Elongation of the ligamentum patellæ—Snapping knee—Congenital contraction at the knee—General contractions 461–487

CHAPTER XI.

Diseases and Injuries of the Ankle- and Tarsal-Joints.

Tuberculous disease—Pathology—Etiology—Statistics—Symptoms—Diagnosis—Treatment—Prognosis—Tuberculous disease of the tarsus—Statistics—Treatment—Köhler's disease—Köhler's disease of the head of a metatarsal bone—Sprain of the ankle—Chronic sprain—Fracture of tarsal bones—Tenosynovitis—Tuberculous tenosynovitis—Tumors of tendon sheaths—Swelling about the ankles 488–505

CHAPTER XII.

Diseases and Injuries of the Articulations of the Upper Extremity.

Tuberculous disease of the shoulder-joint—Pathology—Statistics—Symptoms—Treatment—Prognosis—Tuberculous disease of the elbow-joint—Pathology—Statistics—Symptoms—Treatment—Prognosis—Tuberculous disease of the wrist-joint—Symptoms—Treatment—Prognosis—Spina ventosa—Periarthritis of the shoulder—Snapping shoulder—Chronic bursitis at the shoulder—Epicondylitis, tennis elbow—Sprain of the wrist—Fracture of carpal bones—Kienbock's disease—Acute and chronic tenosynovitis at the wrist 506–524

CHAPTER XIII.

Deformities of the Upper Extremity.

Congenital dislocation of the shoulder—Obstetrical paralysis and dislocation—Treatment—Operation on brachial plexus—Recurrent dislocation of the shoulder—Congenital deformities of the elbow—Congenital pronation of the forearm—Cubitus valgus—Cubitus varus—Subluxation of the wrist—Congenital deformities at the wrist—Club-hand—Varieties—Treatment—Club-hand associated with defective development—Contractions and distortions of the fingers—Webbed fingers—Congenital displacement of phalanges—Trigger-finger—Snapping thumb—Ganglion—Mallet-finger—Baseball-finger—Dupuytren's contraction—Ischemic paralysis and contraction . . 525–552

CHAPTER XIV.

Congenital and Acquired Affections Leading to General Distortions.

Rhachitis—Etiology—Pathology—Symptoms, deformities—Prognosis—Treatment—"Late rickets"—Renal rickets—Infantile scorbutus—Chondrodystrophia—Dyschondroplasia—Multiple cartilaginous exostoses—Osteitis fibrosa—Multiple myeloma—Fragilitas ossium—Osteosclerosis—Marmorknochen—Fragilis generalisata—Osteomalacia—Senile osteomalacia—Hunger osteomalacia—Local osteomalacia—Osteitis deformans—Secondary hypertrophic osteo-arthropathy—Acromegalia 553–576

CHAPTER XV.

Congenital Dislocation of the Hip and Coxa Vara.

Congenital dislocation of the hip-joint—Statistics—Pathology—Etiology—Symptoms, unilateral, bilateral, anterior dislocations, Supracotyloid displacement—Diagnosis—Differential diagnosis—Treatment—the Lorenz operation—Preliminary traction—Reduction in two sittings—Prognosis—Operative treatment—Treatment of older subjects—Osteoplastic buttress—Lorenz bifurcation operation—Review of treatment—Palliative treatment—Congenital subluxation of the hip—Snapping hip—Hypermobility of the joints—Coxa vara—Pathology—Etiology—Statistics—Symptoms, unilateral, bilateral—Diagnosis—Treatment—Forcible abduction—Osteotomy, linear, cuneiform—Fracture of the neck of the femur in childhood—Traumatic coxa vara—Simple fracture—Epiphyseal fracture—Fracture in adult life—The author's treatment for complete, for impacted—Coxa valga 577–635

CHAPTER XVI.

Deformities of the Bones of the Lower Extremity.

Bow-leg—Knock-knee—Statistics—Etiology—The outgrowth of deformity—Genu valgum—Description—Attitudes—Secondary deformities—Gait—Unilateral deformity—Pathology—Treatment—expectant, mechanical, operative—Genu varum—Symptoms—Treatment—expectant, mechanical, operative—Anterior bow-leg—Congenital anterior curvature of the tibia and pseudo-arthrosis—General rhachitic distortions 636–661

CHAPTER XVII.

Diseases of the Nervous System.

Acute anterior poliomyelitis—Pathology—Etiology—Statistics—Symptoms—Diagnosis—Differential diagnosis—Prognosis—Causes of Deformity—Deformity in various regions—Subluxation—Retardation of growth—Principles of treatment—Treatment, mechanical, operative—Tendon and muscle transplantation—Arthrodesis—Nerve grafting—Recapitulation 662–710

CHAPTER XVIII.

Diseases of the Nervous System (Continued).

Cerebral paralysis of childhood—Description—Distribution—Etiology—Pathology—Symptoms—Congenital weakness and paralysis—Acquired paralysis—Hemiplegia—Paraplegia—Treatment, mechanical, operative—Prognosis—Spastic spinal paraplegia—Dystonia lenticularis, Dystonia musculorum deformans—Amytonia congenita—Progressive muscular atrophy—Myelopathic paralysis or atrophy—Myopathic paralysis or muscular dystrophy—Pseudohypertrophic muscular paralysis—Peroneal atrophy—Hereditary ataxia—Multiple neuritis—Neuritis—Subacute combined sclerosis—Hysterical and functional affections of the joints—Neurotic spine—Hysterical spine—"Hysterical scoliosis"—"Hysterical hip"—"Hysterical talipes"—"Neurotic joints"—Camptocormia, Bent-back 711–732

CHAPTER XIX.

Congenital and Acquired Torticollis.

Description—Statistics—Congenital torticollis—Etiology—Hematoma of the sternomastoid muscle—Acquired torticollis—Varieties—Acute torticollis — Etiology — Symptoms — Diagnosis — Treatment of chronic torticollis—mechanical, operative—Treatment of acute torticollis — Spasmodic torticollis — Etiology — Pathology — Treatment—Exceptional forms of torticollis—paralytic, diphtheritic, cervical opisthotonos, rhachitic, ocular, psychical 733–755

CHAPTER XX.

Disabilities and Deformities of the Foot.

General description of the foot and of its functions—The arches, the foot as a passive support, in activity, improper postures, movements—Function of the muscles—Strength of the muscles—The foot as a mechanism—The weak foot or so-called flat-foot—Description—Anatomy —Etiology —Statistics —Pathology —Symptoms —Diagnosis — Varieties — Weak foot in childhood — Exceptional forms—Treatment — Preventive — Exercises — Support — Construction of brace—Plaster cast—The brace—The rigid weak foot—Forcible correction of deformity—Functional use in the overcorrected attitude—Systematic manipulation—Subsequent treatment—Adjuncts in treatment—Operative treatment 756–802

CHAPTER XXI.

Disabilities and Deformities of the Foot (Continued).

The hollow or contracted foot—Varieties and treatment—Anterior metatarsalgia — Morton's neuralgia — Etiology — Treatment — Painful warts—Achillobursitis — Apophysitis — Achillobursitis posterior—Strain of the tendo Achillis—Tendinitis ossificans—Rupture of the tendo Achillis—Painful heel—Plantar neuralgia—Vasomotor trophic neuroses—Angioneurotic edema, acroparesthesia, erythromelalgia, Raynaud's disease—Trench foot—Dysbasia angiosclerotica (Intermittent limp)—Thrombo-angiitis obliterans—Periarterial sympathectomy—Sympathetic ganglionectomy—Injection treatment of varicose veins—Hallux rigidus (Painful great toe)—Injury of the sesamoid bones—Hallus varus—Pigeon-toe—Metatarsus varus—Hallux valgus—Bunion — Hammer-toe—Ingrown toe-nail — Over-lapping toes—Exostosis of the foot—Fracture of metatarsus—Köhler's disease of a metatarsal head—Supernumerary bones—Displacement of the peronei tendons—Shoes, effects of improper shoes—Demonstration of the proper shoe—Socks 803–845

CHAPTER XXII.

Deformities of the Foot.

Talipes—Description—Varieties—Statistics of talipes, congenital and acquired—Relative frequency of the different varieties—Congenital talipes — Etiology — Anatomy — Symptoms — Treatment — Principles of treatment of infantile club-foot—First stage of treatment, rectification of deformity, preliminary manipulation, mechanical, by plaster bandage, by braces, restoration of function, supervision, treatment in older subjects, tenotomy—Second stage of treatment, support and restoration of function, retention by adhesive plaster, by brace, manual correction—Third stage of treatment, supervision —Treatment of neglected club-foot, age influencing, rapid correction of deformity—Forcible manual correction—Wolff's treatment, reduction of deformity by wrenches—Ober's operation—Malleotomy —Tenotomy—Division of tendo Achillis—Open method—Phelps' operation—Operations on the bones—Astragalectomy—Osteotomy —Hoke's multiple osteotomy—Mechanical treatment—Treatment of club-foot in adult—Other varieties of congenital talipes, varus, equinus, calcaneus, valgus, equinovalgus, calcaneovalgus, calcaneovarus, equinocavus, valgocavus—Congenital deformities of foot, associated with defective development, with absence of fibula, with absence of tibia, with congenital deficiency and hypertrophy—Constricting bands—Congenital hypertrophy—Congenital edema—Spina bifida and talipes 846–900

CHAPTER XXIII.

Deformities of the Foot (Continued).

Acquired talipes — Etiology — Diagnosis — Talipes equinus — Etiology — Symptoms — Treatment — mechanical, operative — Talipes equinovarus — Treatment — Talipes equinovalgus — Simple talipes valgus — Talipes calcaneus — Description — Development of deformity — Symptoms — Treatment — mechanical, operative — Willett's operation — The author's operation — Talipes calcaneovalgus and calcaneovarus—Tendon transplantation in the treatment of paralytic talipes—Tendon transplantation and arthrodesis—Review of the operative procedures for the relief of paralytic deformities of the foot 901–948

CHAPTER XXIV.

Collateral Orthopaedic Surgery.

Spine—Sacro-iliac and lumbosacral joints—Scapulæ—The extremities—Schedule of ratings for amputations, fractures, and their sequelæ—Fractures—The abduction treatment of fractures of the neck of the femur—Fracture at the shoulder—The Reconstruction operation—The Reconstruction operation for other conditions—Central fracture of the acetabulum with penetration of the femoral head—Bone grafts—Dislocation of the cervical vertebræ—Amputations and artificial limbs—Preparation of stump—Vanghetti's operation —Injury to nerves—Surgery of peripheral nerve injuries—Operations on individual nerves—Brachial nerves—Palmar nerves—Nerves of the leg—Trick movements—Tendon transplantation—Attitudes of election—Suspension and extension frames—Braces—Splints—Reconstructive treatment 949–1052

MEDICAL LIBRARY
OF THE
HOSPITAL

ORTHOPAEDIC SURGERY.

CHAPTER I.

TUBERCULOUS DISEASE OF THE SPINE.

Synonym.—Pott's disease.

Pott's disease is a chronic destructive process of the bodies of the vertebræ. The disintegration of the weight-supporting portion of the spine, throws into relief one or more of the spinous processes, thus an angular posterior projection is formed. It is called Pott's disease because such deformity, accompanied by pain and oftentimes by paralysis, was first described in English by Percivall Pott in 1779. Angular deformity is simply the evidence of local weakness. Thus it might be the result of fracture, or of the erosion of an aneurism, or of malignant disease, or syphilis, or other pathological process; but deformity from such causes is not now included under Potts' disease. In the modern sense it signifies tuberculous disease of the bodies of the vertebræ, of which the early symptoms may be detected and of which the deforming effects may be checked and even prevented by timely treatment. The degree of the deformity and its effects are determined primarily by the extent and location of disease. If one vertebral body is destroyed the projection will be sharp; if several are implicated it will be less angular, and if one side of a body breaks down before the other there may be lateral as well as posterior distortion. If the disease is at either extremity of the spine the angular projection is slight because the area of the spine directly involved in the deformity is small compared to that which is free from disease (Fig. 5). But if the center of the spine is affected the opportunity for deformity is great, because the entire column may enter into the formation of the angular kyphosis. In such cases the capacity of the chest is lessened and the internal organs are compressed (Fig. 23).

Pott's disease, as contrasted with tuberculosis of other bones and joints, is peculiar in its inaccessibility; in its proximity to important parts, the vital organs in front and the spinal cord behind. Finally, in that the effects of disease and deformity influence in much greater degree the entire mechanism of the body.

Pathology.—The minute changes that characterize tuberculosis of bone in general are described in Chapter V.

The first indication of the disease is usually found in the anterior part of a vertebral body just beneath the fibroperiosteal layer of the anterior longitudinal ligament. From this point the granulation tissue advances along the front of the spine, and following the course of the bloodvessels it invades the underlying bone. In other instances the process may begin in the interior of a vertebral body, most often in several minute foci near the upper or lower epiphysis. These coalescing, gradually enlarge, forming a cavity, enclosed by cortical substance, which finally collapses under the pressure of the superincumbent weight. Occasionally the disease advances beneath the anterior ligament without implicating deeply the substance of the bone—a form of tuberculous periostitis, "spondylitis superficialis." Cases of this type in its mildest form have been described by Froelich[1] as similar to so-called tuberculous rheumatism, in which recovery without deformity is the rule.

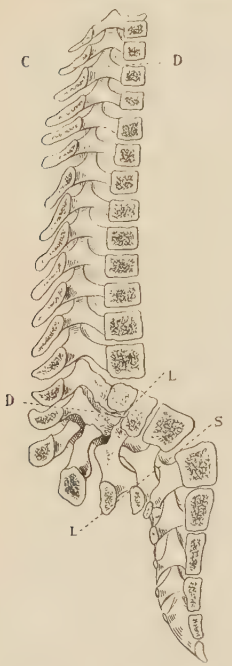

FIG. 1.—Destruction of the bodies of the first, second, and third lumbar vertebræ—with the resulting deformity. (Ménard.)

The intervertebral disks appear to offer some resistance to the extension of the disease from one vertebra to another, but when the bone is destroyed on either side they quickly disintegrate and disappear. The posterior part of the spinal column usually remains free from disease, with the exception of the pedicles and articulations that may be in direct contact with it. In rare instances the process may begin in a lamina or spinous process or in one of the small joints; but such forms of local tuberculosis could hardly be classed as Pott's disease.

The course and outcome of the disease depend upon its type. In one instance the area of primary infection is small and the local resistance is sufficient to check its further progress, so that cure without deformity may follow. In another the disease is inactive and the granulation tissue undergoes a fibroid transformation or becomes ossified. In such cases deformity may appear and slowly increase, practically without symptoms. In most instances, however, the infected granulations advance more rapidly, destroying the bone or other tissue with which they come in contact. There is the usual retrograde metamorphosis to cheesy degeneration, and very frequently liquefaction and abscess formation follow.

In cases of moderate severity that come to autopsy during the progressive stage of the disease, one finds, usually, on dividing the

[1] Rév. d'Orthop., September, 1914.

thickened tissues in front of the spine, a cavity the walls of which are lined with granulation tissue in various stages of degeneration, containing puriform fluid and "bone sand." The adjoining vertebral bodies present a worm-eaten appearance. One or more of them is partially destroyed, and occasionally sequestra of considerable size are present.

FIG. 2.—Pott's disease.

If the disease begins in the interior of a vertebral body it may extend backward as well as forward, and forcing its way into the vertebral canal it may involve the coverings of the spinal cord and cause pressure paralysis even before the deformity attracts attention. Less often pressure on the cord may be due to the presence of an abscess or to displacement of bone. The caliber of the spinal canal may be constricted somewhat by pressure incidental to progressive deformity upon the

softened and thickened tissues at the seat of disease, but, as a rule, its capacity is not directly lessened by the angular distortion, nor does the degree of deformity directly influence the frequency of paralysis.

Although the disease may begin in multiple foci throughout an extended area, or in two or more distinct regions of the spine simultaneously, yet clinical observation indicates that it is, in most instances, originally confined to one or to two adjacent bodies. From this central point it may extend indefinitely in either direction, but in ordinary cases the final area of deformity and rigidity shows that from three to six bodies are more or less involved before cure is established.

If the disease is limited in extent, the eroded surfaces of the adjoining vertebræ may come into direct contact; but if several vertebral bodies have been destroyed, the upper portion of the spine as it sinks downward is often displaced backward, so that the anterior part of one or more of the upper segments may be apposed to the superior surface of the first body of the lower section (Fig. 3). Less often there may be forward displacement of the upper part upon the lower (Fig. 1).

At all stages of the disease resistance to its progress is evident in the affected parts.

Repair is accomplished occasionally by contact and solid union of the adjoining surfaces of softened bone; but usually the anchylosis is in part fibrous, in part cartilaginous, and in part bony, and this union may be further strengthened by a callous formation from the thickened tissues about the seat of the disease. In cases of long standing the articular processes, the pedicles, and laminæ may become anchylosed before repair has advanced appreciably in the anterior portion of the column.

Cure may be absolute, as when no vestige of the disease remains; it may be practically assured, as when the diseased products undergo calcareous degeneration and are shut in by a layer of solid bone. In other instances the disease becomes quiescent or but slowly advances, showing its presence by exacerbations of pain or by the formation of an abscess long after active symptoms have ceased.

Etiology.—The etiology of tuberculosis of the spine does not differ from that of tuberculosis of other bones; the subject is considered in Chapter V.

Relative Frequency.—Tuberculosis of the spinal column is more common than of any other single bone or joint. This is illustrated by the statistics of tuberculous disease treated in the out-patient department of the Hospital for Ruptured and Crippled during a period of twenty years.

	Cases.
Tuberculosis of the spine	4,299
Tuberculosis of the hip	3,329
Tuberculosis of other joints inclusive	3,222
Total	10,850

Of 1996 autopsies on subjects with tuberculous disease of bones and joints the spine was involved in 702—35.2 per cent.[1]

[1] Billroth-Menzel: Handb. der orthop. Chir., Joachimsthal, S. 1304.

Age.—Pott's disease, although far more common in the middle period of childhood, from the third to the tenth year, may appear in earliest infancy or extreme age.

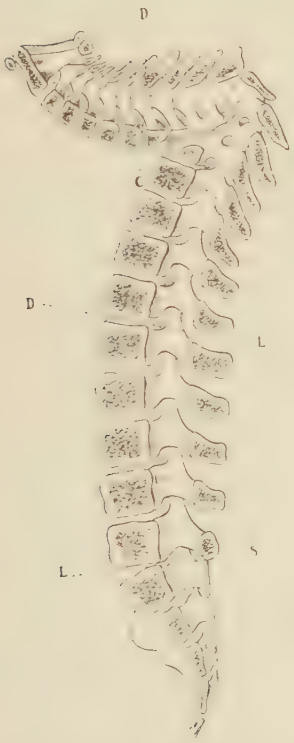

FIG. 3.—Destruction of the bodies of the third, fourth, fifth, sixth, and seventh dorsal vertebræ; partial destruction of three others. (Ménard.)

FIG. 4.—The deformity corrected, showing the area of the destructive process. (Ménard.)

In a series of 1259 consecutive cases of tuberculosis of the spine collected from the records of the outdoor department of the Hospital for Ruptured and Crippled, the ages of the patients at the supposed time of onset of the disease appeared to be as follows:

		Per cent.
Less than 1 year	38	= 3.1
Between 1 and 2 years	176	= 14.2
Between 3 and 5 years	627	= 50.2
Between 6 and 10 years	234	= 18.3
Between 11 and 20 years	89	= 7.2
Between 21 and 30 years	43	= 3.5
Between 31 and 50 years	31	= 2.6
Over 50 years	11	= 0.8

The youngest patient was two months old, the oldest seventy-one years.

Sex.—Sex exercises comparatively little influence on the liability to disease of this region. Of 10,753 cases, 5741 were in males (52.2 per cent.) and 5012 in females (47.8 per cent.).

The Situation of the Disease.—The dorsolumbar section of the spine is most often affected. Cervical disease is comparatively infrequent.

In the series of 1355 cases from the records of the Hospital for Ruptured and Crippled, the attempt was made to locate the origin of the disease by the most prominent spinous process in the tracing. The following are the conclusions:

	Cervical.	Dorsal.	Lumbar.	Lumbosacral.
First	3	26	94	13
Second	3	43	96	..
Third	15	42	64	..
Fourth	20	46	57	..
Fifth	13	49	6	..
Sixth	22	76	..	..
Seventh	24	82	..	..
Eighth	..	97	..	..
Ninth	..	92	..	..
Tenth	..	110	..	..
Eleventh	..	71	..	..
Twelfth	..	120	..	..
Total	100	854	317	13

No deformity, cervical	2
No deformity, dorsal	31
No deformity, lumbar	22
	55
Disease in two regions of the spine	16

Of 694 autopsies on subjects with tuberculosis of the spine:

The cervical region was involved in 185	26.5 per cent.
The dorsal region was involved in 310	44.6 per cent.
The lumbar region was involved in 265	44.3 per cent.[1]

The proportionate length of the different sections of the spine at the age of five years is, according to Disse:[2]

Cervical	20.2
Dorsal	45.6
Lumbar	34.2
	100.0

Of 3110 cases, in approximately 8 per cent. the disease was in the cervical region; 64 per cent in the dorsal and 28 per cent in the lumbar region. It appears, therefore, that the frequency of the disease in the different regions of the spine does not correspond to the area, as has been suggested, but that it is proportionately much less common in the cervical and much more common in the dorsal region.

[1] Billroth-Menzel: Loc. cit.

[2] Skeletlehre, 1896.

This may be explained apparently by the greater strain to which the middle and lower parts of the spine are subjected, as well as by the relative proportion of cancellous tissue which offers the opportunity for infection.

It may be noted in this connection that the proportionate length of the sections of the spine changes somewhat with the age, as is illustrated by the following table, the scale being 1000:[1]

	Cervical.	Thoracic.	Lumbar.
At birth	240	490	260
Three years	214	479	306
Five years	206	486	308
Eleven years	209	500	290
Fourteen years	216	500	284
Adult	195	482	323

Prognosis.—The prognosis in tuberculous disease is discussed in Chapter V. Pott's disease is the most dangerous of the tuberculous affections of the bones or joints, because of the relative importance of the structure affected and of the parts lying in contact with it.

It is evident also that the degree of deformity and its situation have a direct influence on the prognosis. In disease of either extremity of the spine the direct deformity is insignificant and the secondary effect upon the trunk is slight.

In the typical "hump-back" deformity, however, the contents of the thorax and abdomen are compressed; the bloodvessels are distorted, and the caliber of the aorta, which is more directly affected, is often much diminished; respiration is made difficult, and the circulation is impeded; as a consequence the heart is usually hypertrophied and valvular insufficiency is not infrequent. Thus the vital functions which are carried on at a disadvantage at all times may be overtaxed by the strain of unfavorable surroundings, overwork, or disease. It is a matter of common observation that few of those who are markedly deformed reach old age. On the other hand, it may be assumed that slight deformities, or those which do not as directly interfere with the vital functions, exercise but little influence upon the future well-being of the patient. Seemann[2] has reported on the later results in 182 cases treated in Garré's Clinic. Of those in the first ten years of life after a period of twelve years, 40 per cent. were dead, 50 per cent. cured, disease still active in 10 per cent. Of the older cases 50 per cent. were dead, and in 25 per cent. the disease was still present. In a total of 517 patients under sixteen years of age treated at the New York Orthopaedic Hospital between 1895 and 1910, 271 could be traced. Of these 112 were dead in 1916 (38.6 per cent.).

Although the absolute mortality of Pott's disease cannot be accurately estimated, it may be stated that at least 20 per cent. of all patients die during the progress of the disease, and within a few years

[1] Moser: Handb. der orthop. Chir., Joachimsthal, 1905, p. 521.
[2] Beitr. z. klin. Chir., vol. **87**, Heft 1.

after its onset, from causes directly or indirectly dependent upon the local lesion. Some of these die from general dissemination of the tuberculous infection and tuberculous meningitis; some from exhaustion following septic infection and persistent suppuration, or from amyloid degeneration of the internal organs; some from tuberculosis of the lungs, and many from intercurrent affections that are fatal because of the devitalizing influence of the disease and its complications.

Symptoms.—The most obvious sign of Pott's disease is deformity. At an early stage of the process there may be but a slight irregularity in the contour of the spine, and if several adjacent vertebral bodies are affected the projection may be somewhat rounded in outline; but as compared with other deformities of the spine, that of Pott's disease is characteristically angular, and as its cause is loss of substance, its formation is accompanied by and must have been preceded by the symptoms of bone disease.

Deformity is thus the evidence of a destructive process that may have existed for months and only by its early recognition can the ideal result be attained. The spine which, although weak, is still straight may be held straight; but when the deformity is present, it can be remedied only in part, and it may be difficult even to check its progress. For as the upper segment of the spine sinks forward and downward, the influences of compression and attrition increase the activity of the local process and aggravate its effects.

Formerly angular deformity was thought to be the essential sign of Pott's disease, and even now the fact is not generally recognized that the detection of the disease in its inception is both possible and easy if one will apply the same methods that serve for the diagnosis of other affections not attended by a symptom so obvious as external deformity. It is to such application of the principles of differential diagnosis that attention is called.

The spine is the chief support of the body, possessing a free mobility that accommodates it to every movement of the body. It is evident, therefore, that the symptoms of a destructive disease must be pain, weakness, and impairment of normal motion. Motion and support are not, however, the only functions of the spine; it contains the spinal cord, from which branch the nerves that supply the organs and members of the body. This may be implicated at an early stage of the affection, and the sudden onset of paralysis may overshadow the symptoms of the original disease. In other instances the tumor of an abscess—one of the common accompaniments of tuberculous disease—may interfere with the functions of important parts lying in the neighborhood of the spine, and peculiar symptoms, due to this cause, may attract attention before the primary disease is suspected. Such symptoms may be misleading, and it is well, therefore, to consider them apart from those that indicate the primary effect of the disease upon the spine. These direct symptoms usually precede and always accompany the secondary or complicating symptoms, and upon them the diagnosis depends.

MEDICAL LIBRARY ... CITY HOSPITAL

The primary and diagnostic symptoms of Pott's disease may be classified as follows:

(*a*) Pain.
(*b*) Stiffness.
(*c*) Weakness.
(*d*) Awkwardness.
(*e*) Deformity.

(*a*) **Pain.**—At first thought one might expect the pain of Pott's disease to be localized at the affected vertebræ, and to be accompanied by sensitiveness to pressure or even by infiltration and swelling of the neighboring tissues; but it will be remembered that the bodies of the vertebræ are in the interior of the trunk, practically speaking, as near to its anterior as to its posterior surface (Fig. 9), and that the products of the disease pass downward and forward, rarely backward. Thus sensitiveness to pressure on the projecting spinous processes is unusual, and palpation, except in the cervical region, is of comparatively little diagnostic value.

The pain of Pott's disease is not localized in the neighborhood of the disease, because the filaments that supply the bodies of the vertebræ are insignificant parts of nerves that are distributed to distant points—to the head, to the limbs, and to the front and sides of the trunk—and to these parts the pain is referred; thus "earache," or "stomachache," or "sciatica" may be symptomatic of Pott's disease. The pain is by no means constant; it is induced by jars or by sudden or unguarded movements. It is often worse at night, when, after the relaxation of the muscular tension that has protected the part, the unconscious movements during sleep cause discomfort, and the child moans in its sleep, or is restless, and sometimes it wakes with a cry—"night cry."

(*b*) **Impairment of Function or Loss of Normal Mobility: Stiffness.**—Stiffness is in part voluntary, in the sense that the patient adapts his movements and attitudes to the sensitive spine, but the essential stiffness of Pott's disease is caused by the involuntary muscular tension and contraction of the muscles. This reflex muscular spasm varies in degree, with the state of the underlying disease. It may fix the spine or it may check only the extremes of motion, but it is always present, preceding deformity and accompanying it until cure is established; thus it is the most important of the diagnostic symptoms of Pott's disease.

(*c*) **Weakness.**—As the disease affects the most important support of the body, it is a direct as well as an indirect cause of weakness, and the more vulnerable the spine, the more pronounced is this symptom; thus in a young child, "loss of walk," the refusal to stand, and the instinctive desire for support are the symptoms that first call attention to the local disease.

(*d*) **Change in Attitude: Awkwardness.**—This really sums up the effects of the preceding symptoms, since it is evident that pain, weakness, and stiffness must cause a change in appearance and in the habitual attitudes of the patient. Such symptomatic attitudes may be almost diagnostic of the disease and of the part of the spine involved.

(*e*) **Change in the Contour of the Spine: Deformity.**—The deformities of Pott's disease may be classified as:

1. Bony deformity.
2. Muscular deformity.
3. Compensatory deformity.

The characteristic angular projection caused by destruction of bone has been described on a previous page.

Muscular deformity is the distortion due to muscular spasm or contraction. Of this the wry-neck, symptomatic of cervical disease, and psoas contraction in the lower region of the spine are the most familiar examples.

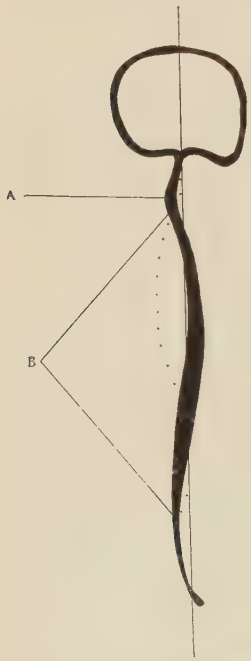

FIG. 5.—*A*, direct deformity; *B*, compensatory deformity. The dotted line indicates the normal contour of the spine.

Compensatory deformity signifies the more general effect of the local disease and local distortion upon the spine as a whole (Fig. 5). Thus an angular projection must be balanced by a compensatory incurvation, and lateral distortion in one direction by lateral distortion in another.

These three deformities are, of course, nearly related, and they are usually combined, although muscular distortion may precede the stage of bone destruction, while the compensatory changes are not immediately apparent. On the other hand, the secondary changes in the contour of the spine may catch the eye before the primary local deformity is detected.

Lateral deviation of the spine is not infrequent; it may be a direct distortion at the seat of the disease, caused by the destruction of the side of a vertebral body (Fig. 22), but more often it is a secondary effect of such irregular erosion at one or the other extremity of the spine, or the effect of muscular contraction, or it may be due to simple weakness, in which case it is a transient symptom.

Finally, even in incipient cases, there is almost always a slight change in the outline of the spine due to local rigidity; the spine no longer forms a long, regular curve when the body is bent forward, but the outline is broken at or near the seat of the disease (Fig. 7).

Secondary or Complicating Symptoms.—(*a*) **Abscess.**—This may, by its size or situation, cause peculiar symptoms. In the retropharyngeal space it may interfere with respiration and deglutition. In the thoracic region it might be mistaken for pleurisy or empyema, and when it forms a tumor in the iliac fossa it may interfere with locomotion.

(*b*) **Paralysis.**—This is usually a late symptom, but if the disease begins in the center or posterior part of a vertebral body, it may implicate the spinal cord before deformity is apparent.

Abscess and paralysis are symptoms that may be explained by Pott's disease, but other than by calling attention to disease of the spine as a possible cause of the complication, they do not aid one in

Fig. 6.—Normal contour and flexibility of the spine.

Fig. 7.—Incipient Pott's disease. Showing the break in the contour of the spine of which the normal flexibility is but slightly impaired.

determining the diagnosis; for this reason they are classed as secondary symptoms.

General Symptoms.—Especial stress is laid by certain writers upon the diagnostic value of a slight but constant elevation of the temperature. This is usually present if the disease is active or when an abscess is approaching the surface, but the positive value of the symptom in early or quiescent cases is doubtful. It may be assumed also that a patient suffering from tuberculous disease of the spine will present some evidence of a painful and depressing affection, or of inherited or acquired weakness; yet it must be remembered that the absence of such general symptoms would not exclude Pott's disease.

The Contour and Flexibility of the Spine.—In the enumeration of the early symptoms of Pott's disease, two have been noted as of especial importance—the impairment of normal mobility and the effect of the disease upon the contour of the spine and upon the attitudes of the patient. Therefore in the study of the normal spine the standard with which that suspected of disease must be compared, mobility and contour, at different ages and under different conditions, should receive especial consideration.

The spine as a whole is a flexible column presenting certain constant curves, forward in the upper, backward in the middle, and forward again in the lower region. These curves are essentially the effect of the force of gravity and of the action of the muscles in balancing the weight of the body in the upright attitude. In the adult they are practically fixed; in early childhood they can be nearly obliterated by traction in the horizontal position; and in infancy they do not exist. If the newborn infant is placed in a sitting posture the head falls forward and the spine bends in one long backward curve, characteristic of weakness. If when it lies on the back the legs are drawn down from their habitual attitude of semiflexion, it will be noticed that the range of extension is somewhat limited because of the absence of the lumbar curve and the inclination of the pelvis. When the gain in muscular power is sufficient to enable the infant to raise and to control the head, the curve of the neck appears. Later, when the child stands, the erector spinæ muscles hold the body upright against the resistance of the iliopsoas group and of the ligaments of the hip-joints; thus the lumbar curve and the inclination of the pelvis result, and the normal contour of the spine is established.

If from the odontoid process of the axis of a normal individual in the erect posture a line be dropped to the ground, this perpendicular or weight line, about which the weight of the body is balanced, will indicate the curves of the spine and divide it into sections that correspond sufficiently well to function. The cervical curve ends at the second dorsal vertebra, the thoracic curve at the twelfth dorsal, and the lumbar curve at the sacro-vertebral angle (Fig. 8).

What has been spoken of as the normal contour of the spine varies considerably in the adult. It is affected by the occupation and by many other circumstances; of this, the round shoulders of the cobbler

or the weaver, the stoop of weakness, of old age, and the like are familiar examples; but in childhood distinct variations from the normal contour almost always have a clearly defined pathological cause. As the normal contour is the effect of the balancing of the body in the upright posture, it is evident that if the outline of one part is permanently changed compensation for this change must be made in another part. Thus when deformity is well marked, the normal curves of the spine are often completely reversed (Fig. 5), and even in early cases the abnormal contour may attract attention before local deformity is noticeable.

Divisions of the Spine.—Although the spine is a flexible column whose outline changes with every movement and posture yet the range and character of this motion vary greatly in different parts. In the cervical and lumbar regions the range is extensive, because of the relatively large proportion of elastic intervertebral substance, because of the direction of the articular surfaces, and because the spine is near the center of the body. Motion is very limited in the thoracic region, because the intervertebral disks are thin, because of the overlapping spinous processes, and because it forms a part of the rigid thorax. Where free motion is essential to the habitual attitudes, interference with normal motion, and the other attendant symptoms of disease will be apparent earliest. Thus one more often has the opportunity for early diagnosis in disease of the lumbar and cervical regions because in the one the motions necessary in stooping, sitting, and standing are constrained, and in the other the neck is stiff, or the head is turned or drawn from the normal line. In the thoracic region early diagnosis is less often made, because in this section motion is so unimportant that its restraint may escape the attention of the patient or parent. In considering diagnosis, therefore, and, in fact, treatment and prognosis, one should divide the spine into three sections to correspond with function:

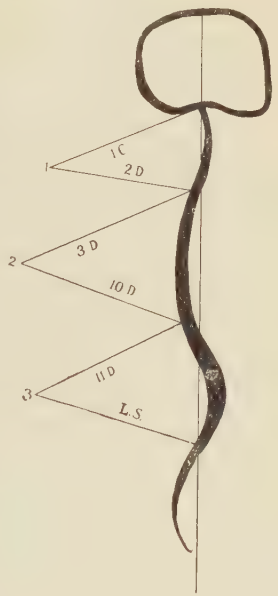

FIG. 8.—The divisions of the spine.

1. The neck part, that permits free motion of the head, ending at the third dorsal vertebra.

2. The rigid thoracic part, which includes the third and the tenth dorsal vertebræ.

3. The lower part, made up of the lower two dorsal and the lumbar vertebræ, in which the principal movements of the trunk are carried out (Fig. 8).

One must bear in mind the distribution of the nerves, because the

characteristic pain is referred to their terminations, also the parts in relation to the spine at different levels that may be implicated in the disease. Thus remembering that the symptoms of Pott's disease are,

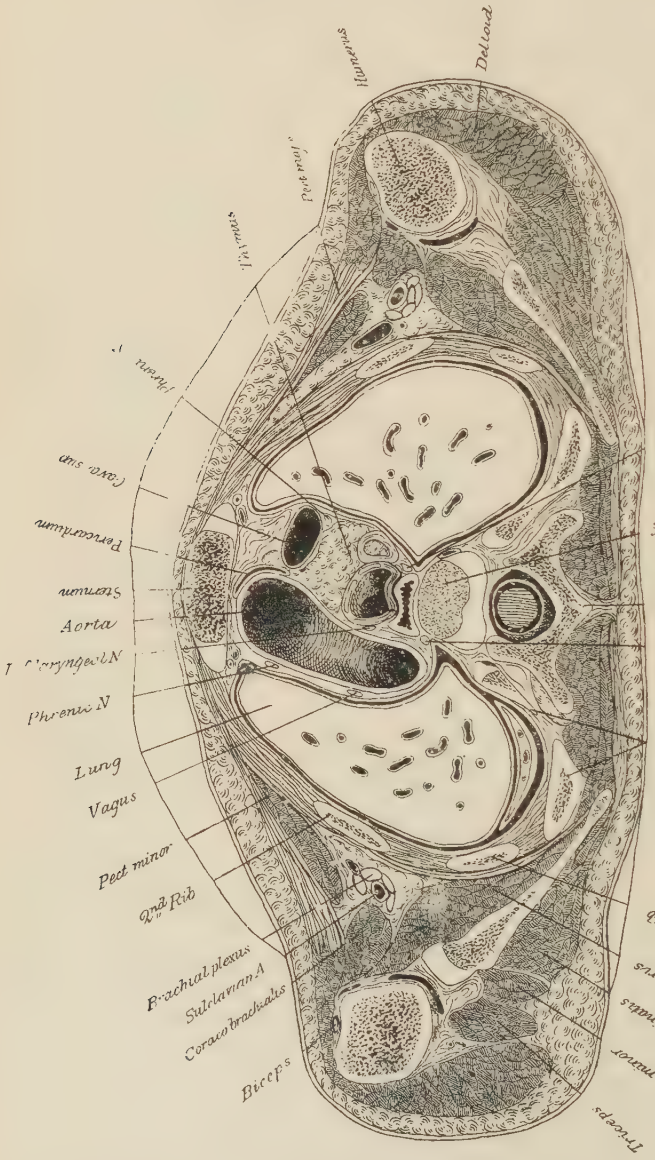

Fig. 9.—Cross-section of the body of a child at the third dorsal vertebra. (Dwight.)

in general, stiffness, weakness, pain, and deformity, one will always apply these symptoms to a particular region of the spine, and will picture to himself the effect of such stiffness, weakness, and deformity at this or at that vertebra; the effect of an abscess in this or that

situation, and the area of paralysis that might be caused by pressure on the cord at one or another level.

Landmarks.—The atlas is on a line with the hard palate.

The axis is on a line with the free edge of the upper teeth.

The transverse process of the atlas is just below and in front of the tip of the mastoid process.

The hyoid bone is opposite the fourth cervical vertebra.

The cricoid cartilage is on a line with the sixth cervical vertebra.

The upper margin of the sternum is opposite the disk, between the second and third dorsal vertebræ. The junction of the first and second sections of the sternum is opposite the fourth dorsal vertebra.

The tip of the ensiform cartilage is opposite the lower part of the body of the tenth dorsal vertebra.

The anterior extremity of the first rib is on a line with the fourth rib at the spine, the second with the sixth, the fifth with the ninth, and the seventh with the eleventh.

The scapula overlaps the second and the seventh ribs, its lower angle being opposite the center of the eighth dorsal vertebra.

The root of the spine of the scapula, the glenoid cavity, and the interval between the second and third dorsal spines are in the same plane.

The most constant landmark from which to count is the spinous process of the fourth lumbar vertebra, which is on a line with the highest point of the crest of the ilium. The umbilicus is near the same plane.

The Inclination of the Pelvis.—In the erect attitude the plane of the brim forms an angle of 50 degrees to 60 degrees with the horizon.[1]

The tip of the coccyx is opposite the lower border of the symphysis pubis.

Length of the Spinal Cord.—In the adult the spinal cord terminates at the lower margin of the first lumbar vertebra. At birth it extends to the third lumbar vertebra and its membranes to the second division of the sacrum.

The Intervertebral Disks.—In the adult the intervertebral disks form 41.9 per cent. of the cervical, 26.4 per cent. of the dorsal, and 44.6 per cent. of the lumbar regions of the spine (Dwight).

The character of the disease, its manifestations, and its effects upon the spine having been outlined, the student is now brought, as it were, into actual contact with the patient and his family; and as Pott's disease is the most important of the chronic affections of childhood, it will serve as a type to illustrate methods of examination and of treatment as applied in orthopaedic practice.

The Rational Signs.—The symptoms of Pott's disease vary decidedly, not only with the region of the spine involved, but also with the age and surroundings of the patient. Like other forms of tuberculous disease it is an insidious chronic affection, and its early symptoms may

[1] Men, 54.17; women, 51.72. Prochvnik: Archiv. f. Gynec., 1882, **19**, 1. This inclination is increased when the thighs are abducted to the full limit as in the abduction treatment for fracture of the neck of the femur.

fail to attract attention, because they are irregular or intermittent. It is often after a fall or violent play that the evidences of pain or weakness can no longer be overlooked, so that injury is likely to occupy a prominent place in the history.

History.[1]—The account of the disease given by the parent is usually indefinite and misleading. Certain points, however, of relative importance may be ascertained by the following questions:

One asks if the immediate relatives of the child have suffered from phthisis or other form of tuberculosis, as this might indicate a predisposition to disease, and thus affect the prognosis.

One asks if the child has been robust or the reverse and if recovery from the ordinary ailments of childhood was prompt or tedious, in order that one may judge of the quality of the patient.

One next asks, not "How long has the child been ill?" for this is usually understood to refer to the duration of the more decided symptoms, but "When was the child last perfectly well?" One asks particularly as to the onset of the first symptoms whether it was sharp and decided, or gradual and ill-defined; if the symptoms were preceded by contagious disease. This latter is an important question, because measles, for example, predisposes to tuberculous infection or at least to its local outbreak, and diphtheria is often followed by paralysis or by weakness that may simulate certain symptoms of Pott's disease. The character of the injury that almost every patient is supposed to have received is then investigated. It should be made clear whether the injury was the direct cause of the symptoms, or if it may have simply aggravated or brought to light the dormant disease, or if, as is often the case, there is simply an indefinite remembrance of an injury which has no connection with the symptoms.

To establish injury as the direct cause of symptoms, the patient must have been well at the time of the accident, the symptoms must have followed immediately and must have persisted since; and finally, the symptoms must be of a nature to be explained by a definite injury.

By careful questioning one may usually determine whether the symptoms of which the patient complains are acute or chronic. This is of importance because tuberculosis is a chronic disease—one of the few chronic diseases of childhood—although its exacerbations may resemble the symptoms of acute disease or even injury.

However important a correct history may be, it is upon the physical examination that the diagnosis practically depends.

Physical Signs.—The physical examination begins with inspection when one notes the general condition and the actions and postures of the patient.

Voluntary actions and attitudes are important, because they show

[1] When the first edition of this book was prepared tuberculous disease of the bones and joints was the most important division of orthopaedic surgery and Pott's disease was the most important disease of the group. Consequently this was made the keynote chapter as indicating the method of conducting a physical examination. This will explain what may seem an over elaboration of the subject.

MEDICAL LIBRARY BOSTON

the adaptation of the body to the disease, the conscious and unconscious efforts of the patient to guard the weak part from strain and from motions that caused discomfort and pain. Direct inspection, palpation, and the tests of voluntary and passive motion are of still greater importance, because by such means one may demonstrate the presence of disease and localize it with accuracy.

The examination must be purposeful. When one asks the patient to pick up a coin from the floor, it is to test the lower region of the spine for the symptoms of weakness and stiffness. The ability to perform the act with ease by no means excludes disease of the spine in the regions not directly involved in the movements of stooping or turning the body, although this would appear to be the general belief.

Such tests must not only be purposeful, but they must be adapted to the age and intelligence of the patient. The child that refuses to pick up a coin will often gather up its garments, because it wishes to be clothed again. If it will not stoop, it will rise usually if placed in the recumbent or sitting posture—an equally useful test. A child will walk toward its mother if placed at a distance from her. It will always turn its head toward her; thus voluntary motion of the cervical region may be tested by changing the mother's position, while the child is held by the examiner. Young children that struggle when placed on the table may submit quietly when in the mother's arms.

Various simple and effective tests will suggest themselves to the examiner who has a definite purpose in view, but much patience may be required in early cases, and several examinations may be necessary before the presence or absence of disease can be definitely determined. It is important to remember that in childhood, at least, abnormal symptoms always have a cause; therefore a patient should be kept under observation until the cause is discovered.

Of all the early signs of Pott's disease restriction of motion due to reflex muscular contraction is the most important, since it precedes deformity and accompanies it until cure is finally established. This muscular resistance limits motion in all directions; thus it may be distinguished from the spasm or contraction of certain groups of muscles caused by irritation or inflammation not connected with the spine, for in such instances motion is limited only in the directions directly opposed by the muscular contraction. True reflex muscular spasm is quite independent of the will, and thus it may be distinguished from simple voluntary resistance on the part of the patient.

The muscular resistance is most marked in the neighborhood of the disease, but it extends to a greater or less distance according to the acuteness of the local process and the susceptibility of the patient.

Even in early cases the situation of the disease is usually shown by a slight irregularity of the spine in the center of the area where motion is restrained by muscular spasm as well as by the change of contour. This change in outline and in flexibility may be demonstrated by bending the patient forward. If the spine forms a long, even, regular curve, and if there is no evidence of pain or stiffness when such an

attitude is assumed, Pott's disease is extremely improbable. If, on the other hand, the outline of the curve is broken; if the motion of one section of the spine is restrained, disease may be suspected; and if other evidence of tuberculous ostitis is present, the diagnosis may be made with certainty (Figs. 6 and 7).

By a careful physical examination one may usually detect Pott's disease at its inception and fix upon its location, or at least upon the point suspected of disease. One will then ask oneself if tuberculous disease of the bodies of the vertebræ of this particular region will satisfactorily explain all the symptoms; if, for example, the pain corresponds to the distribution of the nerves; if restraint of function will explain the attitudes of the patient, and if the change in contour is significant of a destructive process.

As has been stated the symptoms and the effects of the disease differ according to the function of the part of the spine involved, and the further examination should be conducted, therefore, from this stand-point.

1. **Regional Examination. The Lower Region.**—Considering the regions of the spine in the order of liability to disease one begins with the lower section, comprising the lumbar and the two lower dorsal vertebræ, that more nearly correspond in shape and function to the lumbar than to the thoracic division.

This is the region of free and extensive motion; thus the painful stiffness, characteristic of the disease, is usually evident long before the stage of bone destruction.

The characteristic attitude of the patient is one of what might be called overerectness, and in many instances there is an increased *hollowness* of the back (lordosis, Figs. 10 and 12); thus the prominent abdomen may first attract attention. The gait is constrained, and a peculiar tiptoeing step, the feet being slightly inverted to avoid the jar of striking the heels, is often observed, an evidence that the spine is sensitive to slight jars. More characteristic of lumbar disease is a peculiar swagger explained in part by the exaggerated lordosis, and in part by the loss of the accommodative, balancing motion of the lumbar spine, as the weight falls alternately on each limb in walking.

The exaggerated lumbar lordosis, so characteristic of the early stage of the disease, is partly voluntary, as bending the trunk forward increases pressure upon the diseased vertebral bodies, so bending it backward relieves this pressure. It is partly involuntary, caused by the contraction of the muscles on the posterior aspect of the spine; and it is in part compensatory, as the slight psoas contraction which is often present has a tendency to tilt the pelvis forward, necessitating a greater backward inclination of the body.

As the disease progresses the lumbar section becomes straighter, and finally it may project backward in the characteristic angular deformity. Yet even after the lordosis has been lost, the backward inclination of the body still persists as a compensation for the change in balance which the transformation of the forward curve to a posterior deformity has necessitated (Fig. 11). Thus overerectness or backward

inclination of the body characterizes the disease of this region from its beginning to its end in uncomplicated cases.

Slight psoas contraction as a part of the general muscular spasm about the diseased area simply increases the lordosis; but if the contraction is greater, when for example an abscess is present which involves the substance of the psoas muscles or forms a painful tumor in the pelvis, the erect attitude is no longer possible. The thighs are drawn toward the trunk, and the trunk is inclined forward to relax the tension. As

FIG. 10.—Disease of the upper lumbar region before the stage of deformity, showing abnormal lordosis.

FIG. 11.—The same patient (Fig. 10) five years later, showing deformity.

this greater contraction is commonly unilateral, the patient "favors" the flexed limb, and the resulting limp is often mistaken for a sign of hip disease. Unilateral psoas contraction is, in fact, so often present when the patient is first brought for treatment that a limp and the accompanying inclination of the body may be considered as characteristic of disease of the lumbar region at a somewhat advanced stage (Fig. 13).

The location of the pain depends upon the distribution of the nerves that supply the diseased vertebræ or that pass in their vicinity; it

may radiate over the inguinal region or backward to the loins or buttocks or down the front or back of the thighs to the knees. *Painful "cramp"* is sometimes a prominent symptom; the limb is spasmodically drawn toward the body and the patient, seizing it with both hands, shrieks with pain.

FIG. 12.—Disease of the lumbar region. First symptom, pain in the knees.

FIG. 13.—Disease of the lumbar region with right iliopsoas abscess and psoas contraction. See Fig. 80.

Lateral inclination of the body is often present particularly when the disease is at the lumbo-sacral articulation. It is usually a symptom of unilateral psoas contraction and abscess; it may be due also to unilateral contraction of the trunk muscles, or at a later stage it may indicate collapse or destruction of one side of a vertebral body. In other instances it is not a fixed attitude, but is simply a voluntary adaptation to weakness or pain; thus one may find a large abscess in one pelvic fossa unaccompanied by psoas contraction, while the

body is inclined toward the opposite side, apparently because the weight is supported habitually on this limb.

The stiffness, weakness, and pain characteristic of disease in this region are exemplified in many ways; for example, the child may be unable to turn in bed; it is slow and awkward in rising in the morning or in changing from an attitude of rest to one of activity. It often prefers to stand rather than to sit, because in the latter position more weight is thrown upon the sensitive vertebral bodies. When seated, particularly when riding in a carriage or street car, the patient often sits upright, the hands resting instinctively on the seat to steady and support the spine.

Fig. 14.—Lumbar disease. The manner of picking up an object.

Stooping, a posture that increases the pressure on the diseased vertebral bodies and which necessitates muscular tension and strain in regaining the erect position, is always avoided by the patient if the disease is at all acute. For example, when the child is asked to pick up an object from the floor, it either refuses or it squats on the heels or drops upon the knees (Fig. 14) instead of flexing the spine as in health. The erect attitude is then regained by pushing the body up by the pressure of the hands on the

Fig. 15.—Showing the rigidity of the spine before appearance of deformity.

thighs. If the child who refuses to stoop is placed upon the floor, it will, if possible, seize the mother's skirts or it will crawl to a chair or other object upon which the body may be drawn up by the arms, so that the discomfort caused by contraction of the back muscles may be avoided.

After the inspection of the movements and attitudes of the patient the direct examination of the range of passive motion is made. The patient is placed at full length, face downward, on a table, and the range of extension and of lateral motion is tested by lifting the legs and swaying the body gently from side to side (Fig. 15). The spine is so flexible in childhood that rigidity even in the upper dorsal region may be demonstrated by this method, and in testing the lumbar region the thorax should be fixed by the hand. One should then examine for

FIG. 16.—Test for psoas contraction.

psoas contraction. The pelvis is pressed firmly against the table with one hand, while the leg, held in the line of the body, is gently lifted by the other (Fig. 16). The normal range of hyperextension at the hip-joint should permit raising the knee two or three inches from the table. Restriction of extension of both thighs, indicating a slight degree of psoas contraction, is very common in lumbar Pott's disease; but when the restriction is marked, and especially if it is unilateral, a deep abscess may be suspected. Such unilateral psoas contraction may be demonstrated by placing the child on the back, allowing the limbs to hang over the edge of the table, when the unaffected thigh will drop below its fellow (Fig. 17).

As a rule, flexion of the spine is much more restricted in the early stage of the disease than is extension; this may be demonstrated by placing the child on its hands and knees and lifting it from the floor, when the

body, instead of bending over the supporting hands, retains almost its original contour (Fig. 18).

FIG. 17.—A method of demonstrating psoas contraction.

FIG. 18.—Disease of the lumbar region before the stage of deformity. A test for rigidity.

As has been stated, even in early cases one may detect often a slight fulness about the spinous processes or a slight irregularity in their line,

about which the muscular spasm is most marked; this indicates the exact seat of the disease. Pressure on the spinous processes may cause discomfort, and sometimes greater elasticity at this point may be demonstrated. Except in the hands of an expert, it is, however, a test of comparatively little value; and again it may be mentioned that local pain and local sensitiveness to pressure on the spinous processes are not characteristic signs of Pott's disease.

Finally, one should examine for *pelvic abscess*. This may be suspected as an accompaniment of unilateral psoas contraction, although psoas contraction may be present without abscess, and abscess may be present without psoas contraction if the substance of the muscle is not involved.

The typical psoas abscess, as pictured and described, is a fluctuating tumor that suddenly appears on the inner side of the thigh, although it may have been many months in sinking to this position from its original site. Demonstrable abscess is present at some time in at least 50 per cent. of the cases of lumbar disease, and its detection is a matter of importance, since its subsequent behavior will often materially influence the treatment. The child is placed on the side, the thigh is flexed, and the hand is pressed gently down into the loin and iliac fossa. Sometimes the examination will be made easier by extending the limb and thus bending the spine forward toward the hand. Often in this manner one can make out a peculiar sausage-like thickening on one or the other side of the spine, or a larger, rounded tumor in the iliac fossa, the presence of which would not otherwise have been suspected.

Diagnosis.—If a careful physical examination were made in all suspicious cases, by one at all familiar with the ordinary symptoms of Pott's disease, the field for differential diagnosis would be small indeed; but it would appear that such examinations are not made usually by the physician who is first consulted. One may learn, for example, that the child has been circumcised because of pain about the genitals, or because of weakness of the limbs, supposed to be due to "reflex irritation;" or if the patient is an adult, that he has been treated for sciatica, rheumatism or strain, long after the deformity even, would have been apparent had the back been inspected.

Pott's disease in this region is most often mistaken for some one of the following affections:

Lumbago.—This may simulate some of the symptoms of Pott's disease of this region, but it is of sudden onset, usually accompanied by local pain and sensitiveness of the muscles themselves.

Strain of the Back.—This is often accompanied by stiffness and pain on motion, but, like lumbago, its onset is sudden and its cause is known. The pain is usually localized at the point of injury; it is relieved by rest, and the restriction of motion is in great degree voluntary. In Pott's disease the pain is neuralgic; it is often worse at night and the rigidity is due to reflex spasm.

Sciatica.—The pain of sciatica is most often unilateral; it is usually confined to the distribution of this nerve, which is often sensitive to

MEDICAL LIBRARY

pressure. The pain of Pott's disease, if it is referred to the limbs, is usually bilateral and the nerve trunks are not often sensitive to pressure. In sciatica, movements of the limbs that cause tension on the nerve are often painful, while motion of the spine is free, or but slightly restricted, the reverse of the symptoms of Pott's disease. It is true that lateral deviation and even rigidity of the lumbar spine are sometimes observed in cases of lumbo-sciatic neuralgia of long standing, but if the latter symptom is marked the diagnosis may be regarded as open to question.

Spondylitis Deformans.—This disease is practically confined to adult life and is far more often mistaken for lumbago than for tuberculous disease. It is described in detail in Chapter II.

Spondylolisthesis.—This is a very uncommon affection in early life. It may simulate disease at the lumbo-sacral articulation. A description of its peculiarities will be found in Chapter II.

Sacro-iliac Disease.—Sacro-iliac disease is far more likely to be mistaken for disease of the hip-joint than of the spine; the pain and sensitiveness are usually localized about the seat of disease and the movements of the spine are not restricted, except in cases of long standing.

Lumbago, sciatica, and sacro-iliac disease are extremely uncommon in childhood, and if supposed strains or injuries of the spine cause persistent symptoms, the appropriate treatment would be similar to that of Pott's disease; that is to say, the suspected part should be supported until the cause of the symptoms is made clear.

The attitude characteristic of Pott's disease of this region, the hollow back, the prominent abdomen, and the swaying gait, may be simulated by *bilateral congenital dislocation of the hip*, in which the pelvis is suspended at a point behind its normal position; but in this instance the gait and attitude have existed since the child began to walk, and the symptoms of the disease are absent. A similar attitude is sometimes caused by weakness or paralysis of the muscles of the back, as, for example, in the *muscular dystrophies*. In such affections there may be also a disinclination to stoop, and there may be limitation of motion, symptoms that bear a superficial resemblance to Pott's disease; but as there are no other signs of disease of the spine, it may be readily excluded.

When psoas contraction is present the resulting limp, often accompanied by pain in the limb, is almost invariably mistaken for a symptom of *hip disease*.

Although flexion of the thigh caused by psoas contraction is a common accompaniment of Pott's disease, it is not usually an early symptom; thus the history will probably call attention to symptoms referable to the spine, that have preceded it. Again, the limp of Pott's disease is caused simply by flexion of the limb, and if the tension of the contracted iliopsoas muscle is relieved by flexing the thigh still further, the other movements at the hip, abduction, adduction, rotation, and flexion, are free and painless. Thus, hip disease, in which all

movements are restrained in nearly equal degree by muscular spasm, may be excluded readily, except, perhaps, in infancy.

Hip Disease in Infancy.—At this susceptible age sympathetic spasm of the lumbar muscles may accompany acute affections of the hip, and similar spasm of the hip muscles may be present in Pott's disease of the lower part of the spine.

Several examinations may be necessary before the exact location of the disease can be determined, and in doubtful cases the application of a temporary support to the back and thigh, such as a plaster spica to relieve the sympathetic spasm, is useful as an aid in diagnosis.

It has been stated that extension of the thigh only is restrained by psoas contraction. It should be evident, however, that the presence of a large and painful abscess in the pelvis or thigh may limit motion in other directions as well; but even in such cases at least one movement is unrestrained; thus disease of the joint may be excluded.

Secondary Hip Disease.—In Pott's disease of long standing, complicated by abscess, in which the tissues about the joint are infiltrated or traversed by discharging sinuses, secondary infection of the hip-joint is not an unusual complication. In such cases, when the limb is distorted and when motion at the hip is limited by the sensitive and contracted tissues, it is not easy to determine the presence or absence of joint disease. Doubtful cases of this class should be treated symptomatically.

Pelvic Abscess.—As abscess is such a common complication of Pott's disease, it will be necessary to consider abscesses of other origin, that may cause occasionally symptoms resembling somewhat those of disease of the spine. Such are the *perinephritic abscess* in direct communication with the kidney or the *paranephritic* in the fatty tissue separated from the kidney by a layer of fascia, and, more rarely, that of *appendicitis*. They differ from the abscess of Pott's disease in that they are, as a rule, acute in their onset and are accompanied by constitutional symptoms and by local pain and sensitiveness. In such cases the motions of the spine may be restrained, but the restraint is in great degree voluntary, quite different from the rigidity due to disease of its substance. It is true that the pelvic abscess of Pott's disease which has become infected may cause constitutional symptoms, but the history of the disability and discomfort that must have preceded the abscess, together with the probable presence of deformity, will make the diagnosis clear. Chronic abscess in the pelvis of other than spinal origin may be the result of disease of the pelvic bones, or of the sacro-iliac articulation, or of the hip-joint. It may be caused by the breaking down of retroperitoneal lymph glands, or it may have its origin in inflammation about the uterine appendages, and cases of so-called idiopathic inflammation and suppuration of the iliopsoas muscle have been described. In childhood, chronic abscesses in this locality are almost always tuberculous in character, and are caused by disease of bone, either of the spine or of the pelvis. Disease of the spine can be determined usually by the methods already indicated, but if

the abscess is of other origin its exact cause can be decided in many instances only by an operative exploration. Abscesses of this character, of slow and apparently painless formation, may finally cause a swelling in the inguinal region or about the saphenous opening that in the adult is not infrequently mistaken for *hernia*. In practically all cases, however, the tumor of the abscess may be made out on palpation within the pelvis, and, although the contents of the external sac may be in part forced back into the larger reservoir, its reduction is very different in feeling from that of a true hernia.

Peculiarities of Lumbar Pott's Disease in Infancy.—Attention has been called repeatedly to the great importance of careful observation of the postures and movements of the patient, to the change in the contour of the spine, and particularly to the abnormal lordosis and peculiar attitude of overerectness in the early stage of disease. But the description of attitudes of standing and walking, and of the contour of the spine which is the result of the erect posture, does not apply to the infant in arms, nor can the spine be divided into contrasting sections for the purpose of differential diagnosis. In Pott's disease of infancy the muscular spasm is usually more intense and its extent is greater; the child screams when it is moved or when the diapers are changed. Slight irregularity of the spinous processes indicating the position of the destructive process is often evident and abscess is not unusual. There is usually no difficulty in determining the presence of disease even in very early cases, but, it is sometimes difficult to decide whether the lumbar spine or one of the hip-joints is involved.

Pott's disease of infancy may be mistaken for *acute rhachitis* or *scurvy*. The symptoms of such affections are, however, not limited to the spine, but involve to a greater or less degree the limbs and joints, indicating that the discomfort and pain are due to a general, not to a local, disease.

The Rhachitic Spine.—The deformity of the spine, caused by rhachitis, is not infrequently mistaken for that of Pott's disease.

It has been stated that when in early infancy the child is placed in the sitting posture the spine bends in a long, posterior curve, indicative of the weakness normal at this age. Such a curvature is characteristic also of acquired weakness and particularly that caused by rhachitis in early childhood. The weak child that has never walked or that has "lost its walk" sits much of the time in its chair, or is carried about on its mother's arms. In this posture the spine is habitually bent backward. Soon a slight projection persists, even when the child is recumbent. This usually increases in size and becomes more resistant, forming a somewhat rounded and posterior curvature of the dorsolumbar portion of the spine.

The diagnosis from Pott's disease should be made without difficulty, because the evidences of general rhachitis being present, the deformity is almost as much to be expected as would be distortions of the legs were the child walking. If the patient is placed in its habitual sitting posture it will be seen that the deformity is simply an exaggeration of a

normal attitude. In this attitude the patient remains contentedly for an indefinite time, whereas if Pott's disease were present the child would lie on its back or abdomen. The projection is rounded, not angular, and if the patient is placed in the prone posture the projection may be reduced, in part, by raising the thighs while gentle pressure is exerted upon the kyphosis. Finally, although such extension and pressure may cause discomfort, there is complete absence of the muscular spasm characteristic of Pott's disease.

It may be stated, then, that the rhachitic deformity is a rounded curvature of the lower part of the spine. Its cause is weakness and habitual posture. The stiffness corresponds to the duration of the deformity. The pain, if the rhachitis is acute, is general and is explained by the sensitive condition of the bones and joints. It is true that rhachitis and tuberculous disease of the spine may be combined, but in such rare instances the symptoms of the more serious local disease will make themselves evident as distinct from those of the general weakness.

Summary.—The more characteristic symptoms of disease of the dorso-lumbar region are:

Increased lordosis or overerectness and a prominent abdomen; a cautious, constrained, or waddling gait; less often a lateral inclination of the body or a limp caused by psoas contraction.

Stiffness of the spine, which makes bending or turning the body difficult.

Pain referred to the back, to the inguinal region, or to the thighs, and in more advanced cases the characteristic deformity.

Disease of the Thoracic Region of the Spine.—The normal movement of this section of the spine, which includes the third and tenth vertebræ, is as compared with those above and below it, slight; thus, disease of this region may not interfere to a noticeable degree with the general functions of the spine.

As this part of the column curves backward, the deformity, often unattended by severe symptoms, is not infrequently mistaken for round shoulders (Fig. 20). It seems probable, also, because of the normal backward curve, and because of the leverage exerted by the weight of the head and arms, that deformity quickly follows disease. At all events, patients are not often seen before it is present, so that the diagnosis is usually evident on inspection of the patient.

The *attitudes* are not especially significant. If the lower part of the region is involved, and if the disease is at all acute, they are similar to those of disease of the lower region, viz., erectness, the peculiar, cautious, in-toeing step, and the disinclination to bend the body forward (Fig. 19).

If, on the other hand, the upper part is affected, the attitude is often, particularly in young children, one of weakness; there is a slight forward inclination of the body, the head being tilted backward or inclined toward one side, and a peculiar shrugging, squareness, and elevation of the shoulders is often noticeable (Fig. 21). In many instances the

apparent elevation of the shoulders is in reality caused by the deformity, which shortens the neck and lowers the head (Fig. 23).

In this connection it should be mentioned that one of the secondary effects of the disease, the so-called *pigeon chest*, may first attract the attention of the parent. The forward inclination of the spine causes a flattening of the upper part of the chest, while the sternum sinks downward and becomes prominent; thus the anterior-posterior diameter of the thorax is increased, and it is compressed from side to side, resem-

Fig. 19.—Disease of the lower dorsal region. The earliest indication of deformity.

bling very closely the deformity of rhachitis. As the pigeon chest of Pott's disease is always secondary to the spinal deformity, its cause, of course, becomes apparent on examining the back.

Of the early symptoms of disease of the thoracic region, pain and labored or "grunting" respiration are the most characteristic. *Pain* referred to the abdomen and to the front and sides of the chest is usually an early and often a constant symptom; thus persistent "stomach-ache" in a child should always lead to an examination of the spine.

A "spasm of pain" is sometimes excited by lateral compression of the chest, as when the child is lifted suddenly by the parent.

Of much greater importance, however, is the *labored* or *grunting respiration*, which, indeed, is almost pathognomonic of Pott's disease. This "grunting" is caused by the interference with respiration, more particularly with the normal rhythmical movements of the ribs. The restraint is, in part, due to muscular spasm and to deformity and in part to the voluntary effort of the patient. The inspiration is quick

FIG. 20.—Pott's disease of the middle dorsal region at an early stage, showing slight increase of the dorsal kyphosis, without noticeable change in the attitude. Contrast with Fig. 21.

FIG. 21.—Disease of the upper dorsal region. Characteristic attitude.

and shallow, in great degree diaphragmatic, and expiration is accompanied by a sigh or grunt. This is caused apparently by a momentary closure of the larynx to resist the escape of air and thus sudden motion of the chest walls. Grunting respiration is, of course, an evidence of the more acute type of disease, but even in mild cases will be noticed when the patient is fatigued or during play.

An *aimless cough* may be symptomatic of disease of the upper dorsal region, and spasmodic attacks resembling asthma are not uncommon.

In most instances the characteristic deformity is present on examination, and in the exceptional cases in which it is absent a slight change in contour will be apparent when the trunk is flexed. In place of the long, regular curve of the normal spine a point where two distinct outlines unite will be observed—one of which may be curved, while the other is practically straight (Fig. 7).

Muscular spasm is apparent on sudden movement of the spine and it may be demonstrated in children by raising the legs and swaying the body from side to side (Fig. 15). The change in the rhythm of respiration has been mentioned. Although the respiratory movement of the entire thorax is lessened in range, the restraint does not affect all the ribs equally; those that articulate with the diseased vertebræ are often nearly motionless, while the movement of those at a distance from the disease may approach the normal.

In tracing the neuralgic pain to its source the sharp, downward inclination of the ribs must be borne in mind; thus the cause of pain in the "stomach" must be looked for between the shoulder-blades.

As in the lumbar region, slight *lateral deviation* of the spine is not uncommon, and it may be accompanied by a noticeable twist or rotation so that the ribs on one side project slightly backward (Fig. 22).

In this region the *spinal cord* is more often involved than in disease of other sections; thus an awkward, stumbling gait and finally "loss of walk" may first attract attention. The paralysis of Pott's disease and its differential diagnosis are considered in more detail elsewhere.

Abscess as a complication of disease of the thoracic region cannot be demonstrated by palpation unless it has found an outlet between the ribs, but percussion will often demonstrate an area of dulness or flatness extending from the diseased vertebræ toward the lateral aspect of the chest. This is due in part, however, to the inflammatory thickening of the tissues in the neighborhood. In rare instances the abscess may press directly upon the trachea or bronchi and cause spasmodic attacks of dyspnea resembling asthma.

Diagnosis.—It is hardly necessary to mention the list of affections that may cause pain in the chest or abdomen; it is sufficient to state that such symptoms always require a physical examination. The same statement applies to irregular respiration, to cough, and to so-called asthma.

Occasionally tuberculous disease of the thoracic section in adolescence is practically painless, and the resulting deformity is rather rounded than angular, so that it may be mistaken for round shoulders. "*Round shoulders*" is, however, as a rule, of long duration. The exciting cause or causes of postural deformity in occupation or otherwise are indicated often by the history. The rigidity is less marked than in Pott's disease, and neuralgic pain is absent.

Vertebral Epiphysitis of Adolescence.—This is a posterior curvature characterized by pain in the dorsal region and by sensitiveness to pressure over the spinous processes. The pain is, however, not referred, as in Potts' disease, nor is the limitation of motion as marked.

The contour of the rhachitic kyphosis has been described. It should be evident that a more or less angular projection in the upper part of the spine cannot be rhachitic; and yet because of the absence of pain this diagnosis is made not infrequently, and as a consequence the activity of the tuberculous disease may be increased by massage and exercises.

Lateral deviation of the spine as a symptom of disease hardly could be mistaken for the ordinary *rotary-lateral curvature,* in which pain and muscular spasm are absent. Tumors involving the spinal cord may induce radiating pain, the diagnostic points being disturbances of sensation and eventual paralysis.



Fig. 22.—Marked lateral deviation of the spine with rotation. Deformity at the eighth dorsal vertebra.

Acute affections within the chest, *pleurisy, pneumonia,* and *empyema,* are sometimes accompanied by lateral deviation of the spine, but the sudden onset and the constitutional and local symptoms that accompany such affections should make the cause of the deformity and pain evident. It is because these cases are sometimes sent to orthopaedic clinics for braces that they seem worthy of mention.

The abscesses in this region, as has been mentioned, cause usually dulness or flatness on percussion of the chest, and within this area friction sounds and rales may be heard. The tuberculous fluid may remain indefinitely in the posterior mediastinum and the area of flatness may extend beyond the axillary line, yet it may give rise to no symptoms. If the diagnosis of Pott's disease had not been made or if the presence of the abscess had not been determined by the previous physical examination, it might be mistaken, during an acute exacerbation of the disease or constitutional disturbance from other cause, for pleurisy or empyema or even for phthisis. In all cases, therefore, a careful examination of the chest should be made from time to time in order that the presence or absence of abscess may be recorded.

Summary.—Pott's disease of the thoracic region is often insidious in its onset, causing no positive symptoms before the stage of deformity.

Its most characteristic symptoms are pain referred to the front and sides of the body and the grunting respiration.

If the disease is progressive, weakness and stiffness are present. The

MEDICAL LIBRARY

attitude, when the disease is in the lower thoracic region, resembles that of lumbar disease; if the upper part is affected the head is tilted somewhat backward and the shoulders appear to be elevated.

2. **Disease of the Upper Region.**—The upper region of the spine, which includes the cervical and two of the dorsal vertebræ, corresponds in freedom of movement and in its contour to the lumbar region. From the functional stand-point it may be divided into two parts. Of these the superior or occipito-axoid section is peculiar in that it contains no vertebral body nor intervertebral cartilage, and in that the movements of the head are carried out in special joints and are con-

FIG. 23.—Bilateral psoas contraction of an extreme degree and paralysis. The arms used as supports.

trolled by special muscles. Occipito-axoid disease is relatively more frequent in adult life than in childhood and it is as compared to disease of other regions of the spine more dangerous because of the proximity of the vital centers which may be injured by pressure or by sudden displacement of the weakened vertebræ.

Symptoms.—In a typical case the symptoms are *neuralgic pain* radiating over the back and sides of the head, following the distribution of the auricular and occipital nerves. *The neck is stiff* and the

head may be fixed in the median line, the chin being somewhat depressed; or more often it is tilted to one side, simulating the attitude of torticollis (Fig. 24).

The attitude and appearance of the patient, when normal movement of the neck is restrained by a painful disease, is characteristic; the eyes follow one, or the body is turned, when the attention of the patient is attracted. The patient moves carefully, in order to avoid jar; often the chin is instinctively supported by the hand, and a favorite attitude is one in which the patient sits with elbows on the table, the hands

AUG 17 1954
MEDICAL LIBRARY

Fig. 24.—Cervical disease with abscess. Characteristic attitude.

supporting the head (Fig. 25). If the attempt is made to raise the chin, or to rotate the head, the patient seizes the hands of the examiner, and, it may be, screams in apprehension. There may be slight *bulging* or *infiltration* of the tisues about the seat of disease. The affected vertebræ are usually sensitive to direct pressure, and not infrequently deep fluctuation in the suboccipital triangle can be made out.

The atlo-axoid junction lies just behind the posterior wall of the pharynx, on a line with the upper teeth. Here *abscess* may appear early in the course of the disease, causing symptoms of obstruction, such as snoring, change in the quality of the voice, difficulty in swallowing,

or spasmodic attacks of so-called croup. If abscess is present or if the disease is at all acute, the reclining posture sometimes aggravates the symptoms, so that "getting the child to bed" is often a tedious and difficult task.

In certain instances the location of the disease, whether of the occipito-atloid or of the atlo-axoid articulation, may be determined, but as both joints are to a great extent controlled by the same muscles, this is often impossible.

FIG. 25.—Cervical disease. A characteristic attitude.

The uppermost joint, that between the atlas and occiput, permits the nodding movement of the head, or flexion and extension on the spine, the range being about 50 degrees, 20 degrees forward and 30 degrees backward, while the atlo-axoid joint permits rotation of the atlas about the axis through a range of about 60 degrees.

If the disease be in the upper joint the nodding movements should be more restricted than those of rotation, and *vice versa*. To make the test one must grasp the neck firmly in order to restrain movement except in the joint under examination. Because of free motion in the cervical region, fixation of the upper articulations is often overlooked when the disease is of the subacute type.

The Lower Cervical Region.—The symptoms of disease of the lower cervical section, although similar in character, are often less marked than those of the upper region. The cervical spine becomes straighter, and often a slight backward projection or thickening indicates the position of the disease. The head is usually turned to one side by contraction of the lateral muscles in an attitude of wry-neck (Fig. 26). The pain is referred to the neck, to the sternal region, or down the arms, following the distribution of the brachial plexus.

In the more advanced cases one's attention may be attracted to the cervical region, because the neck seems short and because the head is tilted backward. The entire back shows a compensatory flattening, yet no deformity is apparent until the occiput is raised and drawn forward, when a shelf-like projection may be felt at what appears to be the extremity of the spine, but which is really an angular deformity at the third or fourth vertebra.

FIG. 26.—Disease of the middle cervical region at an early stage.

This emphasizes the importance of careful observation of the contour of the spine and explaining to oneself every change from the normal that may be noticed.

Disease at the cervico-dorsal junction resembles in its symptoms that of the upper dorsal region. The head is usually tilted backward (Fig. 21) or it may be turned to one side. Disease at this point is often subacute in character, and paralysis from pressure on the spinal cord sometimes appears before deformity is apparent. Occasionally irregularity of the pupils is present because of sympathetic involvement.

The spinous process of the seventh cervical or first dorsal vertebra is often prominent (vertebra prominens) in normal individuals, and it may be mistaken for the deformity of disease, especially when pain is referred to this region, as in hysterical or hyperesthetic subjects. If such projection is symptomatic of disease there is almost always a slight compensatory flattening of the spine below the point and a certain degree of rigidity of the surrounding muscles.

Diagnosis.—As stiffness and distortion of the neck are the most prominent symptoms of disease of this region, one must consider first the forms of *torticollis* for which it might be mistaken. In typical torticollis the distortion of the head is caused almost invariably by contraction of the muscles supplied in part by the spinal accessory nerve, the sternomastoid, and trapezius, thus the chin is slightly elevated and turned away from the contracted muscle.

Congenital torticollis, which has existed from birth, is not accompanied by pain and it could hardly be mistaken for a symptom of disease.

Acute "rheumatic" torticollis, "stiff neck," is a common affection. It is of sudden onset, "in a single night;" the affected muscles are sensitive to pressure; the course of the affection is short and it is of comparative insignificance.

A more persistent form of acute *torticollis*, characterized by muscular spasm and by local sensitiveness, sometimes accompanies enlarged or suppurating cervical glands; it may follow "earache," "tonsillitis," "sore throat," or any form of irritation about the pharynx. This

FIG. 27.—Deformity at the cervical vertebra indicated by the wrinkle in the neck. The attitude of the head and the compensatory projection in the lumbar region are characteristic.

form of wry-neck is not only very painful, but it may persist indefinitely, and permanent deformity may result. The onset is usually sudden; the pain and sensitiveness are local and are confined, as a rule, to the contracted part. The sternomastoid and trapezius muscles are most often involved; thus, the wry-neck is typical. If the tension be relaxed by inclining the head toward the contracted muscles, motion of the spine itself will be found to be free and painless; but if traction is made on the contracted muscles it causes discomfort, and it is usually resisted by the patient.

In disease of the occipito-axoid region the distortion of the head is by no means typical of sternomastoid contraction; it may be tilted up

or down or laterally to an exaggerated degree. In other words, the wry-neck of Pott's disease is an irregular distortion, because it is not dependent on the contraction of a particular muscle or muscular group. "In torticollis the chin is turned away from the contracted muscle, while in Pott's disease it is turned toward the contracted muscle." This is an axiomatic expression of the fact that the distortion of the head symptomatic of atlo-axoid disease depends, in great degree, upon the spasm of the small muscles that directly control these joints, the recti and obliqui, not upon the contraction of the sternomastoid muscle, as in the ordinary form of wry-neck. Again, the contraction, symptomatic of Pott's disease, of this or other region, is the result of muscular spasm that checks painful motion. If the head be grasped firmly by the hands and if gentle traction is made, the distortion may often be overcome without discomfort to the patient. If similar traction is made upon the contracted muscles of acute wry-neck the pain is increased and the patient protests.

In disease of the middle cervical region, however, the distortion may resemble closely that of acute torticollis; for if the latter is caused by the irritation of inflamed or suppurating glands there is often sensitiveness to manipulation, with more or less general muscular spasm. In such cases the diagnosis may be impossible until apparatus has been applied to rest the part and to correct the deformity.

As has been stated, the head may be tilted backward to compensate for deformity in the middle cervical region, and in some instances it may be drawn backward by spasm of the posterior muscles. Such a case might be mistaken for *cervical opisthotonos*, or posterior torticollis, which is sometimes seen in young infants suffering from exhausting diseases, basilar meningitis and the like. In such conditions, however, the characteristic symptoms of Pott's disease are, of course, absent.

The opposite attitude, viz., a forward droop of the head due to weakness of the extensor muscles, is not uncommon as a sequence of *diphtheria* or other forms of contagious disease.[1] This droop may be accompanied, also, by contraction of one of the sternomastoid muscles and by pain. In such cases the history of the preceding affection, the weakness or paralysis of other parts, as of the soft palate, of accommodation of the eyes and the like, together with the general bodily weakness, should make the diagnosis clear.

Injury of the upper segment of the spine, strain, contusion, or fracture, unless efficiently treated, may cause symptoms resembling very closely those of tuberculous disease; for example, pain radiating over the back of the head, rigidity and deformity of the neck, and even infiltration and local tenderness about the injured part. Such cases, when seen several weeks or months after the accident, are puzzling, because one may be in doubt whether the symptoms were caused by a

[1] In a series of 1313 cases of diphtheria 6 per cent. were paralyzed; of these 77 per cent. recovered. In two-thirds of the cases the soft palate was alone involved. A. Lowe: Glasgow Med. Jour., October, 1911.

simple injury or whether tuberculous infection may have followed or preceded it. In such cases a positive diagnosis cannot be made until the effect of rest and protection has been observed—that is to say, suspicious cases should be treated as one would treat actual disease. If the case is simply one of injury, recovery may be rapid and complete, while if disease is present the symptoms only will be relieved.

The occipito-axoid articulations may be involved in *acute* or *chronic arthritis* and the like. If the manifestations are general in character the diagnosis is, of course, easily made; but occasionally the infection is limited to the joints at the upper extremity of the spine and it may be attended by fever and constitutional disturbance. The sudden onset and rapid recovery if proper treatment is applied are the diagnostic points.

Abscess in the cervical region is a secondary symptom, and although the change in the voice and the difficulty in breathing or swallowing may be the most noticeable symptoms, yet they are always accompanied by some of the characteristic signs of Pott's disease. Whenever the diagnosis of cervical disease is made one should examine the throat, and whenever a chronic retropharyngeal abscess is present one should look for the symptoms of Pott's disease. The diagnosis of the retropharyngeal abscess can be made only by inspection and palpation; therefore one need only mention the fact that symptoms of obstruction in the throat, similar to those of abscess, may be caused by adenoid growths and by enlarged tonsils.

Retropharyngeal abscess by no means always indicates Pott's disease. It may be one of the sequelæ of contagious disease or a complication of pharyngitis. It is then rapid in its onset and is not accompanied by the symptoms of Pott's disease.

Summary.—If the disease is of the upper or occipito-axoid region the head is usually fixed in an attitude of deformity, which may be slight or extreme. If the disease is of the middle region, the attitude more often resembles that of ordinary torticollis. In the lower region marked spasm of muscles is unusual, but the head inclines backward or toward one shoulder.

The contour of the cervical spine changes as the disease progresses; the normal anterior curvature is obliterated; thus, the head is pushed forward while the dorsal section of the spine becomes flat or even incurvated in compensation. The seat of the disease is often shown by an area of thickening or local sensitiveness to deep pressure.

Diagnosis in General.—Weakness and the so-called "loss of walk" are well-known symptoms of Pott's disease, and on this account children suffering from various types of weakness or paralysis are often brought to orthopaedic clinics for the treatment of "spine disease."

Certain forms of paralysis bear a superficial resemblance to some of the symptoms of Pott's disease; for example, *pseudohypertrophic muscular dystrophy* to the attitude caused by disease of the lumbar region and *diphtheritic paralysis* to that of the dorsal region. *Spastic paralysis* of cerebral origin resembles somewhat the paralysis of

Pott's disease, but it may be differentiated by the absence of pain, by the history, and by what is apparent in most cases, the mental impairment.

Primary spastic spinal paraplegia resembles the paralysis of Pott's disease more closely, but the essential symptoms of a destructive disease of the spine are absent. The contractions combined with the weakness and pain that sometimes follow *cerebrospinal meningitis* may be mistaken for the symptoms of bone disease, but they are readily explained by the history of the case.

Forms of organic disease of the spine other than tuberculosis, as, for example, malignant disease, syphilis, spondylitis deformans and the like, in which the question in differential diagnosis is not of the presence or absence of disease but rather of its nature, are described in Chapter II.

The list of affections that has been considered in the differential diagnosis is a long one, but it has been made up from actual experience. Mistakes in diagnosis must be accounted for usually by carelessness or ignorance, or because of insufficient opportunity for examination; but in the earliest stages of the disease repeated examinations and even tentative treatment may be necessary before the diagnosis is assured.

The Roentgen-ray Photography as a Means of Diagnosis.—Roentgen pictures are of comparatively little importance from the stand-point of early diagnosis of Pott's disease in childhood, because the symptoms usually precede the destructive changes in the bone. They are of value as a means of determining the exact extent of the disease. If the negative is well-defined the diseased vertebræ are seen to be irregular in outline, or they may be lost in a peculiar blur. By counting from above and below the boundaries of the disease may be made out, but inferences as to its character and quality must be made from the rational and physical signs (Fig. 36). The tuberculin test is considered in Chapter V.

The Record of the Case.—The history and the results of the examination of the patient should be recorded somewhat in the following order:

1. The family and the personal history.

2. The history of the disease, with especial reference to its mode of onset, its probable duration, to the noticeable symptoms, and to previous treatment.

3. The physical examination. This should include the general condition of the patient, the height and weight, the attitude, the character of the disease, whether progressive, as indicated by muscular spasm and pain on motion, or quiescent, the presence of abscess or paralysis as a complication, and, finally, the position and extent of the disease. This is best shown by a tracing made by means of a strip of lead or pure tin of such thickness that it may be readily molded on the spine and yet hold its shape when removed (Fig. 28).

The tracing should be of the entire spine, made while the patient lies extended in the prone position, and the exact location of the most

BOSTON CITY HOSPITAL

prominent spinous process should be marked upon it. In determining the position of the disease it is well to count the spinous processes from below upward, beginning with that of the fourth lumbar vertebra, which lies on a line drawn between the highest points of the iliac crests. There are other landmarks that are approximately correct. Sometimes the last rib may be traced to its origin; the scapula covers the second and seventh ribs, the root of the spine of the scapula and the middle point of the glenoid cavity being on a line with the third, and its inferior angle opposite the tip of the seventh dorsal spinous process. The upper margin of the sternum is opposite the interval between the second and third dorsal vertebræ. In many instances the vertebra prominens and the spinous process of the axis can be identified. Such landmarks are, of course, somewhat displaced if the deformity is extreme, but they are always sufficiently correct to check errors in counting the spinous processes.



FIG. 28.—Tracings of the spine, illustrating recession of deformity under treatment by the convex frame.

The history furnishes a foundation on which treatment is conducted and from which its results may be determined. It should present, therefore, the condition of the patient when treatment is begun, and in it the complications and incidents and the changes in the treatment should be noted at regular intervals while the patient is under observation.

Treatment.—The general treatment of tuberculous disease is considered in Chapter V. Pott's disease is the most serious of the tuberculous affections of the bones, and the importance of hygienic surroundings, nourishing food, sunlight, and, above all, open air both day and night, if possible, can hardly be exaggerated.

The General Principles of Mechanical Treatment.—Under normal conditions the weight of the head and of the thoracic and abdominal organs tends to bend the spine forward and downward—a tendency that is resisted by the action of the muscles of the back. If the resistance is weakened, as in Pott's disease, by the direct destruction of the weight-bearing portion of the spine, this tendency toward deformity is, of course, greatly increased. Thus the pressure of the superincumbent weight upon the weakened part and the strain of motion are, from the mechanical stand-point, the most important factors in the production of deformity.

When the trunk is inclined forward, the intervertebral disks are compressed and the pressure upon the vertebral bodies is increased. When it is held erect or is inclined backward this pressure is lessened and a part of the weight is transferred to the posterior parts of the column. The object of a brace or other support is to hold the spine in the extended position, so that direct pressure on the diseased vertebræ may be relieved. One aims to splint the spine as effectively as if it were broken, in order to relieve the discomfort and pain, so depressing to the patient, and to assure the rest that is essential to repair.

The effectiveness of a particular splint or support, whether applied to a broken bone or to a diseased spine, depends upon the area that it covers on either side of the part to be supported and upon the accuracy of its adjustment, as well as upon the damage that the part has already sustained, and the strain to which it still may be subjected.

From this stand-point it is evident that it is difficult to apply effective support to the trunk because of its size, shape, and contents, and it is apparent also that the mechanical conditions are more favorable in some parts than in others. For example, the splint should be effective when the disease is of the lower dorsal region, because its two extremities, attached to the pelvis and to the shoulders, are equidistant from the point to be supported. The conditions are unfavorable in disease of the upper thoracic region, because the weight of the head and of the arms tends to increase the deformity, and because of the insufficient leverage that can be secured for the supporting appliance. The pelvis is the base of support for all forms of splints, and if it is smaller than the abdomen, as in infancy, ambulatory appliances are far less effective than in older subjects.

In actual practice the treatment of Pott's disease is determined by the age of the patient, the situation of the disease, the duration of the deformity, and by many other circumstances, but the relative efficiency of braces or other appliances may be estimated on purely mechanical grounds. Thus, as the ultimate deformity of Pott's disease is, in great degree, caused by the *force of gravity acting on a weakened spine*, the most effective treatment must be fixation in the horizontal position, for in this position the strain of use and the pressure of superincumbent weight can be removed completely.

Horizontal Fixation.—Apparatus for this treatment should be quite independent of the bed on which it may be placed, and of such appliances several forms are in use.

The reclinationgypsbettes of Lorenz[1] is simply a posterior case of plaster of Paris enclosing the head and body.

The Phelps bed is somewhat similar. A thin board is cut in the outline of the child's body and extended legs. It is padded with wadding and covered with cotton cloth; the patient is then placed upon it and plaster bandages are applied to enclose the body and the legs.

[1] Hoffa: Lehrbuch der Orthop. Chir., 3d ed., p. 324

The front is then cut away, so that the patient may be removed from the bed for an occasional bath and change of clothing.[1]

The wire cuirasse has been popularized by Sayre;[2] it is somewhat more cumbersome and expensive than the last appliance, for which it served as a model.

The most effective and convenient form of this type of simple horizontal support is the frame introduced by Bradford. This is a rectangular frame of gas-pipe a few inches longer and slightly wider than the patient's body. Over the frame covers of strong canvas are drawn tightly by means of corset lacings or straps on its under surface, leaving an interval beneath the buttocks for the use of the bedpan (Fig. 29).



FIG. 29.—The original Bradford bed frame. (Bradford and Lovett.)

THE CONVEX STRETCHER FRAME.

The stretcher frame[3] is a modification of that of Bradford, designed to assure correction of deformity in some degree with more direct and constant corrective support and less interference with the clothing. It is made of ordinary galvanized gas-pipe or steel tubing of a small diameter. It should be about 4 inches longer than the child and about fourth-fifths as wide, the lateral bars corresponding to the articulating surfaces of the four extremities with the trunk. The ordinary dimensions are $7\frac{1}{2}$ by 38 inches, or the width to length about as 1 to 5.

At first thought it would seem that the side bars might cause uncomfortable pressure on the overhanging shoulders, but as the arms are set upon the middle of the lateral aspect of the trunk, and thus on a considerably higher plane than the dorsum, there is but bare contact when the cover is fairly rigid. Before applying the cover one may with advantage wind bandages tightly about the frame at the point which is to support the trunk in order to make the support as unyielding as possible (Fig. 30). The cover should be of strong canvas suitably protected in the center by rubber cloth. This is applied and is drawn tight by means of corset lacings and straps. Upon this two thick pads of felt are sewed; these should be about seven inches in length and about an inch in thickness, placed on either side of the spinous processes

[1] The Phelps Plaster-of-Paris Bed: Tr. Am. Orthop. Assn., 1891, **4**, 83.
[2] Redard: La gouttiere de Bonnet, Chir. Orthop., p. 243.
[3] Whitman: Tr. Am. Orthop. Assn., 1901.

at the seat of the disease, thus protecting them from pressure, fixing the part more firmly, and increasing the leverage of the apparatus. The child, wearing only an undershirt, stockings, and diaper, is placed upon the frame and is fixed there usually by a front piece or apron similar to that used with the spinal brace. As soon as the patient has become accustomed to the restraint one begins to overextend the spine by bending the bars from time to time, with the aim, as has been stated, of actually separating the diseased vertebral bodies and obliterating all the physiological curves of the spine, so that the trunk shall be finally



FIG. 30.—The modified frame with the bandage.

bent backward to form the segment of a circle. The greatest convexity is at the seat of the disease, and as the head and lower extremities are on a much lower level, an element of gravity traction is present in some instances, while the support of the spine, as a whole, is much more comprehensive than when the body lies upon a plane surface (Fig. 32). The gradual overextension of the spine by bending the frame in this manner is so definite and simple that it may be easily carried out by the physician, and it may be exaggerated slightly, to compensate for the sagging of the cover. Thus, it is far more effective than any form of padding placed on a flat surface, or other form of support with which I am familiar. Upon this frame the child lies constantly, its clothing



FIG. 31.—The stretcher frame, showing the canvas cover and apron.

being made sufficiently large to include the apparatus, thus assuring additional fixation. In exposing the back at regular intervals to sunlight, the frame may be reversed so that the patient lies prone in its concavity thus assuring the proper attitude. It is, of course, desirable to have two equipped frames, but this is by no means essential.

The effect of the persistent attitude is not merely to change the contour of the spine, but of the entire trunk as well; to flatten and broaden the thorax. This increase of the lateral at the expense of the anteroposterior diameter is the reverse of the natural tendency of the

deformity, and it is therefore a favorable rather than an unfavorable effect of the treatment. The same tendency in the abdominal region may be checked by the use of a flannel binder, such as is ordinarily worn by infants.

FIG. 32.—The frame bent to assure overextension of the spine. The rapid recession of deformity in this case is shown by the tracings. The advantage of the appliance for sunlight treatment are apparent. Fig. 28.

The method of attaching the patient to the frame varies somewhat according to the situation and character of the disease. In ordinary cases, as has been stated, a canvas apron, similar to that used with the back brace (Fig. 64), is applied, and is buckled to the sides of the frame. If advisable the shoulders may be held down by bands crossing the chest or by axillary straps connected by a chest band. If still more effective fixation is desired, as in disease of the upper dorsal region, the anterior shoulder brace, as used with the back brace (Fig. 69), may be



FIG. 33.—The modified stretcher frame showing overextension of the spine, with traction for the head and limbs as applied for Pott's paraplegia, caused by disease in the upper dorsal region.

attached to the axillary straps. In disease of the upper and middle regions of the spine restraint of the legs is not necessary, but in lumbar disease a broad swathe should be passed across the thighs, and if psoas spasm is present traction may be employed.

If the disease is of the upper region and if the patient's head is of the long type, it is advisable to make a right angular downward bend of the side bars, so that the occiput, being on a lower level, the proper pressure at the seat of disease may be assured.

In disease of the upper region of the spine traction is desirable to aid in the reduction of deformity and to prevent the patient from raising

FIG. 34.—The upper part of the frame bent backward to permit hyperextension of the head.

the head. This traction is usually applied by means of the halter as used with the jury-mast. The straps are attached to a crossbar at the

FIG. 35.—A perfect cure obtained by the stretcher treatment. The situation of the disease is shown in the *x*-ray picture, Fig. 36.

upper extremity of the frame, and traction may be made by simply tightening them; or if the upper part of the frame is somewhat elevated,

the weight of the patient's body makes the proper counter-traction. This position has the advantage, also, of allowing the patient a better opportunity to see what is going on about him (Fig. 33).

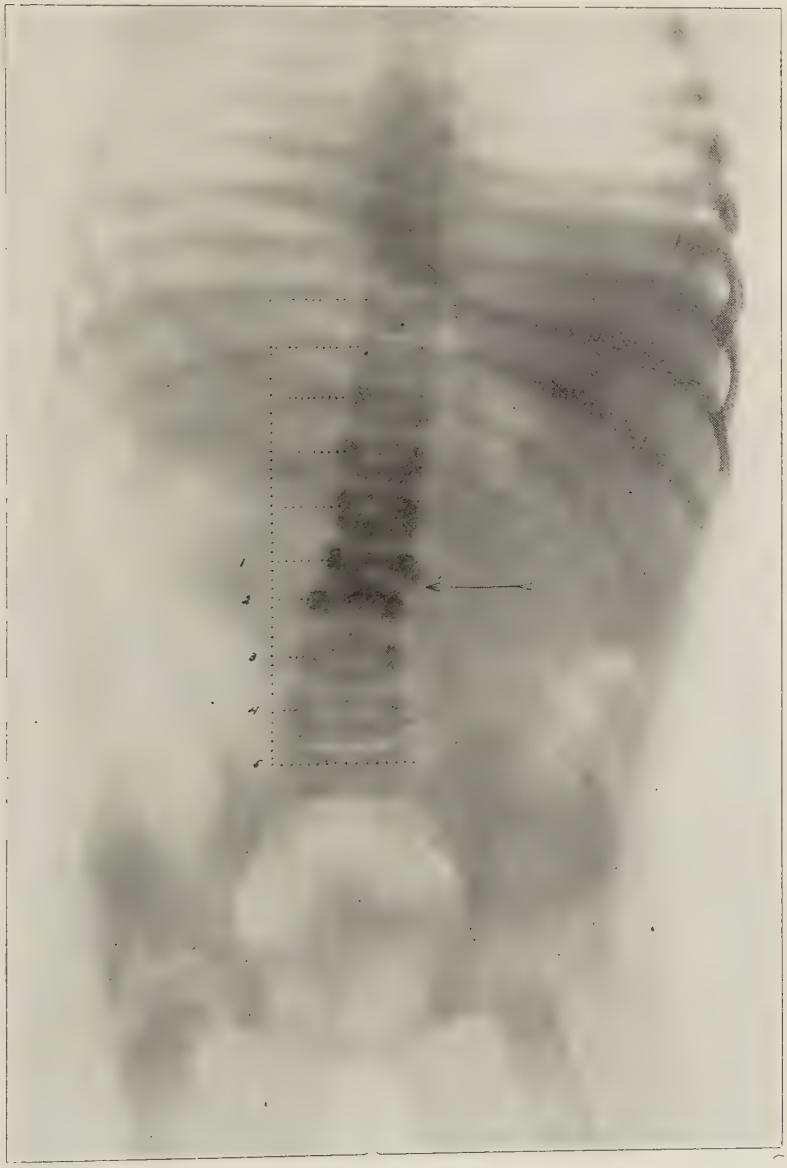

FIG. 36.—A roentgen-ray picture of the case (Fig. 35) before treatment. The situation of the disease at the junction of the first and second lumbar vertebræ is indicated by the lateral deviation and by the approximation of the dotted lines *1* and *2* as compared to the others.

In disease of the cervical region traction is usually of service and restraint of the head is always indicated in addition when the occipito-axoid region is involved.

Direct fixation of the spine may be desirable in cases of more acute disease. This may be attained by the use of a light back brace, or a plaster jacket, in connection with the frame. Such support should not be applied, however, until the recession of deformity, which is to be expected under treatment by the horizontal fixation and overextension, has been obtained (Fig. 28).

As this frame is simply a horizontal brace the child may spend as much time in the open air as would be practicable were any other appliance used.

FIG. 37.—The baby carriage as used in hospital practice for patients on the stretcher frame.

I have never seen other than favorable results from this method of treatment. Pain and discomfort are, as a rule, relieved almost immediately, and there is a corresponding improvement in the general condition of the patient. Meanwhile the growth of the trunk, which is so often checked by the disease and by the deformity, appears to progress normally, so that the apparatus may be actually outgrown before the termination of this part of the treatment. Horizontal fixation is, of course, a treatment not complete in itself, since it must be supplemented by the usual supports when the erect attitude is again assumed. Its duration varies from six months to two years. The indications for its discontinuance are the correction of deformity, the apparent quiescence or cure of the local disease as indicated by the physical signs, and by the behavior of the patient, who, as repair advances, becomes restless when removed from the frame, evidently desiring to sit and to stand.

MEDICAL LIBRARY BOSTON HOSPITAL

It is well to apply the ambulatory support some time before the patient is released from the frame, permitting little by little the changes in attitude and habits. If the plaster jacket is to be used it may be

FIG. 38.—Pott's disease of the middle dorsal region, a type of disease in which horizontal fixation is always indicated. H. S., aged fourteen months.

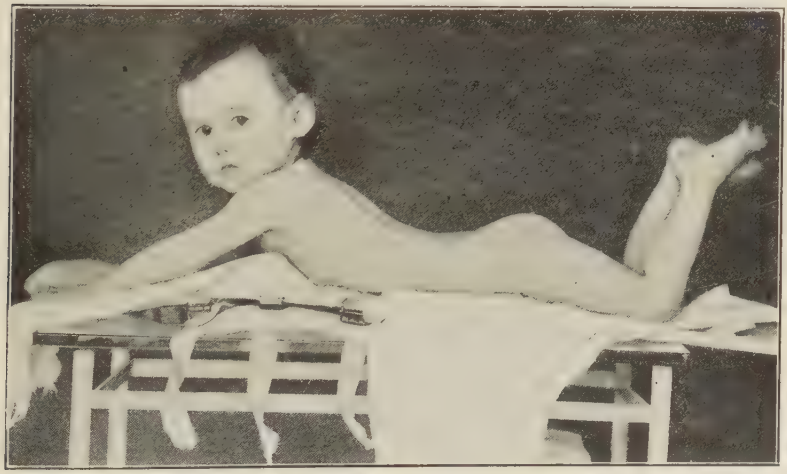

FIG. 39.—H. S., after fixation for fourteen months on the stretcher frame, shows the recession of deformity. Compare with Fig. 38.

applied during longitudinal suspension or otherwise, after which the child is immediately replaced upon the frame; thus it holds the spine in an attitude to which it has become accustomed (Fig. 58).

Ambulatory Supports.—The two types of ambulatory supports are the plaster jacket and the steel brace. The first of these has the great advantage in that the service of a skilled mechanic is not essential and in that the patient is more under the control of the physician than when removable apparatus is used.

The Plaster Jacket.—It was claimed at one time that a plaster jacket applied while the body was partially suspended would actually relieve the weakened area of superincumbent weight by holding the diseased surfaces apart. This is not the fact. The jacket supports the spine by holding it in the erect or extended position and thus transferring the weight in part from the diseased vertebral bodies to the lateral and posterior portion of the column.

Its efficiency depends upon the accuracy of its adjustment to the contour of the trunk and upon the leverage that it exerts above and below the weakened part. It should be applied while the body is held in the best possible position; its inner surface should be smooth, and the bony prominences that are exposed to friction and pressure should be protected.

A seamless shirt fitting the body closely and long enough to reach the knees should be worn. These are made in several sizes and are sold by the yard at a low price. A band of linen, China silk, or other material, about three inches in width and three feet in length, should be placed beneath the shirt on the front and back. These bands, or, as Lorenz calls them, "scratchers," are for the purpose of keeping the skin clean. The patient is then placed upon a stool and the halter of the suspension apparatus is carefully adjusted; the arms are extended over the head and the hands clasp the straps or rings; thus, the chest is expanded to its full limit. Sufficient tension is made upon the rope to partially suspend the body and to draw the spine into the best possible attitude; in most instances the heels should be slightly lifted from the stool.

Dr. Sayre, to whom we are indebted for the exposition of this valuable means of treatment, insisted that the sensations of the patient should be the guide and that traction should be made only to the point of comfort. This is a valuable indication in the treatment of the adult, but it is not often of service in childhood.

Before applying the plaster bandages, pieces of piano felting or similar material of sufficient thickness are placed about the anterior pelvic spines, over the upper part of the sternum, and a thin strip is sometimes used to cover the spinous processes. Finally, long pads of saddler's felt, or of other material of sufficient thickness, are applied on either side of the prominent spinous processes to protect them from friction and to provide greater pressure and fixation at the seat of disease. In the treatment of adolescent or adult females the breasts should be covered with a layer of cotton, which may be removed later, if necessary, to prevent pressure. The "dinner pad" is now not often used,

except in the treatment of adults and in certain cases in which the abdomen is retracted. In childhood the abdomen is usually prominent, and extra space is not often required. Occasionally, however, one is told that the patient complains of discomfort after meals, evidently due to constriction, and in such cases proper allowance must be made. The

FIG. 40.—The plaster jacket, illustrating the arrangement of the shirt.

FIG. 41.—The plaster jacket supporting the abdomen. The cleansing bandages are not shown.

pad, which is supposed to represent the space necessary after a full meal, is made by folding a small towel into the shape of a sandwich; this is attached to a bandage and is placed beneath the shirt just below the ensiform cartilage; when the jacket is completed it may be drawn out by means of the hanging bandage, leaving the additional space for emergencies.

The materials for the jacket should be of the best. Fresh dental plaster should be rubbed by hand into strips of crinoline, free from glue. The bandages should be from three to five inches in width and six yards in length, from three to six being required for a jacket, according to the size of the child. They should be placed on end, in a pail of warm water, one at a time as they are used. No salt or alum should be used to hasten the setting of the plaster; in fact, if such aid is necessary it is unfit for use. When the bubbles have ceased to rise the bandage is squeezed gently until no water drips from it, and the loose threads are removed from the ends.

Fig. 42.—The jury-mast and the anterior support.

One person should sit behind the patient and one in front, while the third may hold the rope and check the swaying of the body. The one who sits behind the patient may clasp the child's legs between his knees and thus assure better fixation of the pelvis. The pads are held in position until they are fixed by the plaster bandages, which should be applied with a slight and even tension.

As a rule the jacket should be of uniform thickness throughout. This thickness need not exceed one-eighth to one-fourth of an inch, and it may even be lighter in certain cases. It is well to begin by figure-of-eight turns about the waist and pelvis with sufficient tension to bring into relief the pelvic crests, since the pelvis is the base of support; and, as the most important point for counter-pressure is the upper part of the chest, the appliance should be made especially strong and resistant at this point.

During the application of the jacket it should be rubbed constantly in order that the different layers of bandage may adhere to one another, and that it may fit the projections of the pelvis and body closely. Meanwhile the attitude of the patient should be carefully watched, in order to prevent lateral inclination of the body. It is often possible while the patient is suspended to correct the deformity still further by backward traction on the shoulders and forward pressure on the trunk while the jacket is hardening.

When the jacket is nearly firm it should be trimmed. In many instances this may be done while the patient is in the swing, but if he is fatigued, he may be placed in the recumbent posture.

As a rule the front of the jacket should reach from the upper margin of the sternum to the pubes; behind, from about the midline of the scapulæ to the gluteal fold; laterally, it should be cut away sufficiently

Fig. 43.—The jury-mast.

to prevent chafing of the arms; and on either side of the pubes an oval section is cut out, to allow for the flexion of the thighs in the sitting posture. Particular attention is called to the importance of making the jacket as long as possible, so that the abdomen may be contained within it instead of being forced out beneath its lower border (Fig. 41). After the application of the jacket the patient should remain in the recumbent posture for at least half an hour or longer, as it does not become absolutely firm for several hours. The shirt is then drawn up over the jacket and is sewed to the neck portion; this adds much to neatness and cleanliness. The shirt must be drawn tightly about the neck, in order to guard the body from the crumbs or other objects that may fall beneath the jacket, and in many instances a special protector in the form of a wide collar bib may be used with advantage.

The upper and lower ends of the cleansing bandages are joined to one another with tape, and with them the skin is carefully rubbed twice daily. When soiled they may be replaced.

It may be mentioned in this connection that even the slightest excori-

Fig. 44.—Illustrating fixation of head in the overextended attitude.

ation or irritation of the skin beneath the jacket can be detected by the peculiar odor. Of this parents should be informed, so that it may be cut down and the source of the irritation removed at once. With ordinary care "sores," the bugbear of the plaster jacket, may be avoided or so quickly detected that they are of little consequence. From the mechanical stand-point the plaster support is most satisfactory in the treatment of disease of the dorsolumbar region, its efficiency lessening with the distance from this central point.

If the disease is above the tenth dorsal vertebra it is well to carry the plaster bandages about the neck and in front of the shoulders as in the Calot jacket, or direct backward traction on the shoulders may be made by means of the anterior shoulder brace described in connection

Fig. 45.—A fixation support for the head. This may be used with the brace or with the jacket.

Fig. 46.—Front view of the same patient.

with the spinal brace (Fig. 42); this may be attached to buckles incorporated in the plaster or by tapes crossed behind the shoulders. Traction applied in this manner is an additional fixation for the spine and assures better expansion of the chest. In default of this appliance the shoulders may be included in the plaster support.

In many instances a head support is required, and it is, of course, always indicated in disease of the upper dorsal and cervical regions. For this purpose the head may be included in the plaster support, or a

jury-mast or a posterior splint may be employed. The jury-mast should be of tempered steel, strong enough to hold its shape under the tension of the halter (Fig. 43). Its base should be incorporated firmly in the jacket below the seat of the disease; it should be long enough to reach well above the head, and the crossbar should be placed directly over the ears (Fig. 47).

The halter should be applied with as much tension as can be borne comfortably by the patient, so that the weight of the head may be at least partly supported. The straps should be adjusted to tilt the chin slightly upward, the aim being to draw the head backward and thus to

FIG. 47.—The jacket and jury-mast applied. The same patient is shown in Fig. 33.

extend the spine. In disease of the cervical region the crossbar should be fixed to check lateral motion of the head, but this is unnecessary when it is at a lower level.

If fixation of the head is desired, or if the jury-mast is ineffective, an appliance similar to that shown in Fig. 45 may be used. This consists of two light steel bars, incorporated like the jury-mast in the jacket, and adjusted to the neck and back of the head. Their upper extremities are joined by a band of light steel of U-shape, long enough to reach from ear to ear, the circumference being completed by a band of tape across the forehead. In certain instances additional straps may be placed beneath the chin and the occiput, as in Figs. 45 and 46. In this

connection it may be stated that the support provided by the jury-mast is only effective when it is carefully adjusted and constantly watched. In most instances, therefore, a rigid apparatus, though less comfortable, is to be preferred.

If the jacket is carefully fitted to the pelvis it may be a fairly efficient support even for disease of the lower lumbar region. If, however, the symptoms are acute, with accompanying spasm of the flexors of the thigh, it should be extended to one or both knees as a single or double spica, according to the indications.

FIG. 48.—The Calot jacket, showing application to the neck and shoulders.

FIG. 49.—The Calot jacket, showing the pad and hooks.

The Calot Jacket.—Calot was at one time an advocate of the immediate correction of the deformity of Pott's disease, a treatment described in previous editions of this book. Although the method is no longer used, it served a purpose in calling attention to the importance of more effective preventive treatment, and it has further been demonstrated that the deformity may be corrected to the same degree, so far as the final result is concerned, by milder methods. One of these is the

MEDICAL LIBRARY

convex stretcher frame or similar appliance in recumbency, and another is the Calot jacket in ambulatory treatment.

The essentials of the Calot support are fixation of the neck and shoulders as well as of the pelvis, and direct pressure over the kyphosis, the front of the jacket having been cut away so that the trunk may be forced forward, thus straightening the spine as a whole, and in some degree the local deformity.

FIG. 50.—The Calot jacket, showing the thick block of wood used for pressure over the felt pads. For this detail in the pressure appliance I am indebted to Dr. G. E. Bennett.

In applying the support the patient is partly suspended in the ordinary manner. If the head is to be included a special sling must be used. This may be improvised from bandage material, but preferably it is made of canvas. It should be about five or six feet in length and two and a half inches in width, the ends are sewed together, making when it is passed over the crossbar two loops, of which one is placed about the chin and the other beneath the occiput. These are attached to one another by safety pins above the ears. To the posterior loop a similar band about three and a half feet in length is sewed. This when carried behind the occiput and attached to the crossbar holds the head

firmly in the desired position if it is to be included in the support. A close-fitting shirt with a high neck and sleeves is worn. The protecting pads are then applied in the usual manner and a band of felt is placed about the neck. In addition the front of the thorax is covered with a layer of cotton batting about one inch in thickness. The arms are supported at a right angle to the trunk and the jacket is constructed, if the disease is of the lower dorsal region, to include the neck and shoulders. As a part is to be cut away it must be made much thicker

FIG. 51.—The Calot jacket, showing the head support and hooks.

than the ordinary jacket, especially over the shoulders, on the lateral borders of the chest and about the deformity. Calot constructs the jacket with layers of crinoline previously cut in patterns, which are then saturated with liquid plaster mixture, but those accustomed to the roller bandages will prefer them, strengthening the jacket by reverses in the usual manner.

When the jacket is sufficiently firm the patient is placed upon the back and a small triangular opening is cut over the chest through which the thoracic pad is removed, so that respiration may not be constrained.

The following day, or when the jacket is thoroughly dry, the front is cut away as illustrated in the pictures. Another opening is made in the back to thoroughly expose the area of the disease. Vaseline is then applied to the skin and pads of cotton, one after the other, are forced into the opening to the point of toleration, with the aim of pressing the trunk forward and flattening the projection. These pads are held in place by turns of plaster bandage or by adhesive plaster. The procedure is repeated at intervals of several weeks, the pressure if possible being increased.

A more accurate adjustment of the corrective force and one that permits inspection of the spine and thus lessens the danger of pressure sores is as follows: The pads are made of thick felt arranged to press on either side of the spinous processes. Over them is placed a thick piece of wood of the exact size of the opening. Pressure is made by two firm bands of tape buckled to metal hooks fixed to the lateral margins of the jacket. Fig. 49.

If the disease is of the upper third of the spine the head should be supported. The sling is adjusted to hold the head in a position of slight extension. The shirting is drawn over the head, an opening having been cut for the face. The neck, chin and occiput are protected with felt or cotton and the plaster is applied about the head; the sling is then removed and the support cut to the shape shown in the illustration (Fig. 51). The shirting is afterward sewed in the usual manner.

The Calot jacket is difficult to adjust, but it is far more effective than any other form of ambulatory support.

The Application of the Jacket in the Recumbent Posture.—The jacket may be applied, while the patient lies extended in the prone posture, by the *hammock* method suggested by Davy, of London.

A long narrow strip of cotton cloth is passed under the shirt and is drawn tight enough, by means of a pulley or by manual traction, to support the trunk in the proper attitude, preferably, of course, in overextension. An opening is cut for the face, and if advisable, traction may be made on the arms and legs of the patient. The bandages are then applied in the ordinary manner, after which the cloth may be cut short at one end and removed.

This method is of service in the treatment of weak or paralyzed patients, but the adjustment is somewhat less satisfactory than by the ordinary method in that the fixation of the thorax is less accurate. The jacket may be applied in the supine posture by means of the *Goldthwait* apparatus. This may be employed also in the routine application of the plaster jacket.

It consists essentially of a support (Fig. 52) carrying on its upper extremities two thin strips of perforated metal. To these strips felt is attached, forming pads similar to those used on the back brace. The patient is then placed with his back resting on the pads at the seat of the disease. The buttocks and the head are allowed to sink downward to the point of toleration; thus an extending force is exerted on the spine. The plaster bandages are then applied in the usual manner about the

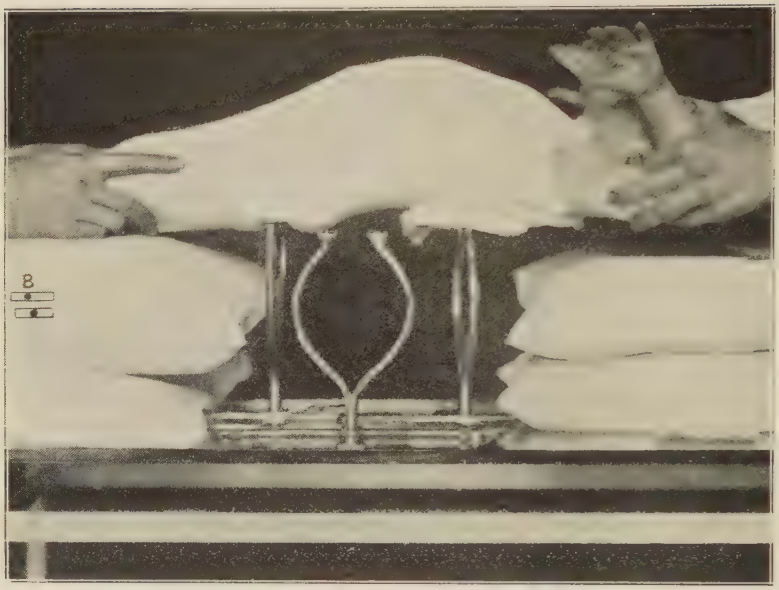

FIG. 52.—The application of the jacket in the recumbent posture by means of the Goldthwait appliance: *A*, the support, similar to that upon which the patient is lying; *B*, two thin bands of steel, similar to those used in the Taylor brace.

FIG. 53.—R. Tunstall Taylor's apparatus for the application of the plaster jacket in the recumbent posture, consisting of an adjustable back support and pelvic rest, connected by a sliding bar. (See Fig. 54.)

FIG. 54.—The Taylor appliance in use, showing the hyperextension of the spine. The plaster jacket having been applied, the back rest is removed by pressing the bandages from side to side or by enlarging the opening. If desirable the defect is then concealed by a turn of plaster bandage.

body on either side of the support. When it is completed the patient is lifted from the support, the pads being included, of course, in the jacket. An opening remains at this point that may be closed by an additional bandage.



FIG. 55.—Goldthwait's portable frame for applying the plaster jacket.

Other supports of a similar nature are in use, but as they do not differ from it in principle a detailed description is unnecessary (Figs. 53 and 54).

If the deformity is of recent origin it may be actually corrected by the leverage exerted, but in many instances the effect is to hyper-

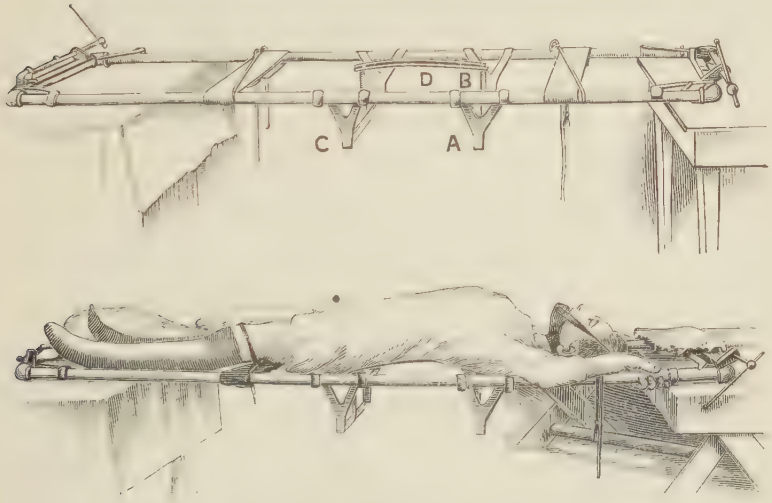

FIG. 56.—The plaster jacket applied in supine posture by means of the Metzger-Goldthwait apparatus.

extend the unaffected parts of the spine, particularly in the lumbar region. Thus the correction is apparent rather than actual. In order to prevent this and to exert more effective leverage on the deformity, Goldthwait uses the apparatus illustrated in Fig. 55.

The patient lies on two malleable steel bars fitted to the lumbar region, reaching only to the apex of the deformity. The plaster bandages forming the lower part of the jacket having been applied, the upper portion of the trunk is allowed to sink downward to the point of toleration and the jacket is then completed. The steel bars, which have prevented the upward arching of the lumbar region of the spine, are then withdrawn. The Metzger apparatus, of which that last described is an adaptation, which permits longitudinal traction as well as direct leverage, is shown in Fig. 56.

The Application of the Jacket to Patients Who Have Been Treated on the Stretcher Frame.—A satisfactory method of applying a plaster jacket to young subjects, when the deformity has been corrected in whole or in part by recumbency on the frame in the overextended position, is the following: The patient is suspended face downward in the horizontal position by two assistants, one holding the arms and the other the thighs; thus, a certain amount of traction is exerted, while the weight of the body tends to overextend the spine.



FIG. 57.—The stretcher frame on which the patient is replaced while the jacket is hardening.

In this attitude a jacket is quickly applied and the child is at once replaced upon the frame, which has been protected by a rubber sheet (Fig. 57). The plaster jacket, during the hardening process, must conform to the habitual posture of recumbency. The pressure pads of the frame indent the bandage on either side of the spinous processes (Fig. 58) and thus afford better support and fixation. This is a very satisfactory method of applying the jacket in this class of cases because it is not necessary to retain the child in an uncomfortable position while the support is hardening, and because accuracy or adjustment in the best possible attitude is assured.

For the routine application of the plaster jacket vertical suspension is to be preferred, because in this more natural attitude the support may be more accurately and comfortably adjusted. The hammock method and that just described are of particular service in the treatment of young subjects. The supine posture may be selected with advantage when the spine is sufficiently flexible at the seat of disease to permit a certain degree of correction or if the patient is weak or timid or paralyzed.

As a rule a jacket may be worn for two months, although not infrequently it may remain for six months, or even longer, and yet be fairly efficient. Usually one jacket is removed and another applied on the same day, but if the skin is at all sensitive it is well, after the washing and powdering, to reapply the old jacket, closing it with adhesive plaster and allow an interval of a few days before applying the permanent one.

FIG. 58.—Jacket applied by the stretcher method, showing the depressions on either side caused by the frame pads.

The Plaster Corset.—In the stage of recovery the jacket may be replaced by a corset. A jacket, made and trimmed as already described, is cut down the center and removed from the body. It is carefully readjusted to its former shape, bandaged with the cut surfaces in close apposition, and is thoroughly dried or baked.

All wrinkles are then cut away from the inner surface and extra padding is applied if necessary; the shirt is drawn tightly about the borders of the jacket and strips of leather provided with hooks are sewed in front so that it may be laced like an ordinary corset. It may be removed from time to time to allow for bathing, but it should always be removed and reapplied while the patient is suspended or in the recumbent position.

The corset is sometimes used in place of the jacket during the active stage of the disease, but it is less effective, since the repeated stretching during removal and reapplication weakens the appliance and impairs the accuracy of adjustment. In addition, one of the strongest argu-

FIG. 59.—The Ghormley bivalve corset high in front supporting the shoulders—low behind.

FIG. 60.—The bivalve jacket-corset as used for sunlight treatment.

FIG. 61.—Exposure of the back for sunlight treatment.

ments in favor of the use of plaster of Paris, that treatment is under control of the surgeon, is nullified. A disadvantage of the plaster jacket is that it does not permit direct exposure to the sun.

Ghormley, of Boston, constructs a bivalve corset. It is applied in the recumbent posture, then cut into an anterior and posterior section. The back part reaches only to the level of the disease, but the front encloses the neck and shoulders, thus assuring hyperextension. The method of exposure is shown in the photographs furnished by Dr. Ghormley (Figs. 59 to 61, p. 80).

Corsets of Other Material than Plaster of Paris.—Corsets of wood, leather, paper, poroplastic felt, celluloid or aluminum are sometimes used. These are constructed on a plaster cast of the body, an accurately fitting jacket being used as a mold.

Such corsets have certain advantages of durability and elegance, but none of them has the accuracy of fit of the plaster of Paris corset which is molded directly on the body. Corsets of this class are usually somewhat expensive, and on that account are often worn after they are outgrown or when they no longer fit the patient. Their use is practically limited to the stage of recovery or for other affections than Pott's disease.

The Back Brace.—The spinal brace, or spinal assistant, as the original appliance of Dr. C. F. Taylor was called, consists essentially of two steel bars that are applied on either side of the

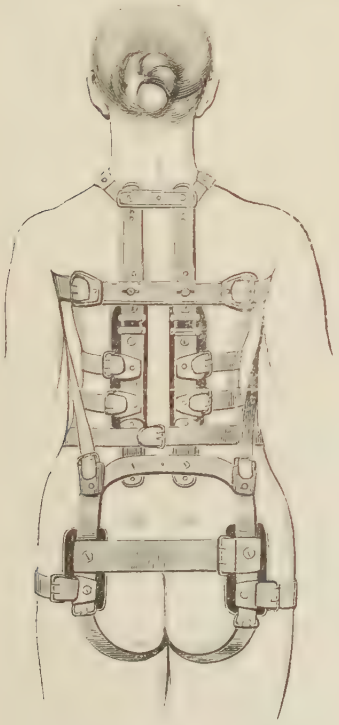

FIG. 62.—The Taylor back brace. (H. L. Taylor.)

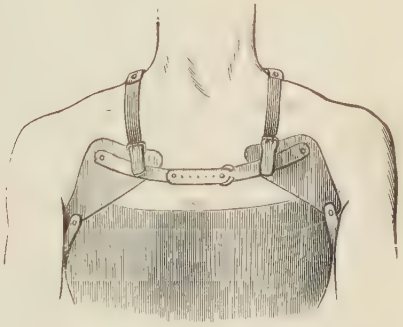

FIG. 63.—The Taylor chest-piece. Two triangular pads of hard rubber connected by a bar.

spinous processes from the top to the base of the spine. At the seat of the disease pads are placed to provide for greater pressure and fixation, and to form a fulcrum over which the spine may be straightened or held erect, when the two extremities of the brace

are firmly attached to the pelvis and to the shoulders. The attachment at the lower end is made by means of a pelvic band of sheet steel (gauge 18) from one and a half to two inches in width, long enough to reach from one iliac spine to the other; it is placed as low as possible on the pelvis; in other words, just above the upper extremities of the trochanters. To this the uprights are firmly attached at an interval of from one and a quarter to one and three-quarter inches from one another, so that the spinous processes may pass between them, while pressure is made on the lateral masses of the vertebræ. The uprights are made of varying strength, according to the age of the patient, usually about one-half an inch in width (of gauge 8 to

FIG. 64.—Backward traction on the shoulder fixes the upper dorsal region.

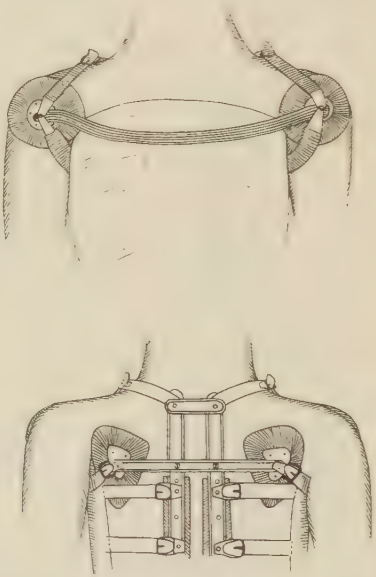

FIG. 65.—The anterior shoulder brace and its attachment.

12) and of such quality of steel that, although unyielding to the strain of use, it may be readily bent by wrenches, and thus accurately adjusted to the back. The uprights reach to the root of the neck, or to about the level of the second dorsal vertebræ; from this point two short arms of metal project forward and outward on either side of the neck, reaching to about the middle of the clavicles. To these padded shoulder straps are attached which pass through the axillæ to a crossbar on the back brace; thus downward pressure on the shoulders is avoided and increased leverage is assured (Fig. 66).

Opposite the area of disease two strips of thin steel about three inches in length are fixed; these are slightly wider than the uprights and are perforated for the attachment of the pressure pads, which may be made

of layers of canton flannel or felt, or unyielding material, such as leather or hard rubber, may be used instead. The pads should project from a quarter- to a half-inch in front of the uprights in order that firm and constant pressure, to the degree that the skin will tolerate, may be made at the seat of disease (Fig. 59).

In measuring for this brace the patient is placed in the prone posture and a tracing of the outline of the back is made by means of the lead tape. This outline may be cut in cardboard and fitted to the back; in fact, if the mechanic is unfamiliar with the work, each part of the

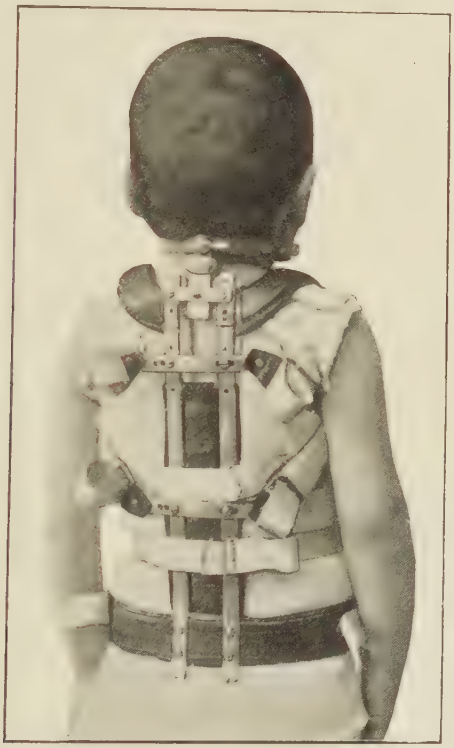

FIG. 66.—The Taylor brace and head support applied for disease of the upper dorsal region.

brace, uprights, pelvic band, etc., may be cut in cardboard and attached to one another to serve as a model. Before the brace is finished it should be applied to the back and should be adjusted carefully by means of wrenches. The pelvic band and the parts that come into direct contact with the skin are usually covered with leather, or, in the treatment of young children, with rubber plaster and canton flannel to prevent rusting.

If the brace is applied before the stage of deformity it should follow the exact shape of the spine, but if deformity is present, particularly

in disease of the thoracic region, it should be made somewhat straighter, in order to permit a gradual correction of the compensatory lordosis in the lumbar region, and for increased leverage above the deformity. As has been stated, a certain degree of recession of deformity may be obtained by rest in the horizontal position, and if practicable this improved contour should be attained before the brace is applied. The

FIG. 67.—The Taylor brace and head support applied to the patient shown in Fig. 73 illustrating the correction of the deformity.

FIG. 68.—The Taylor brace with jury-mast.

apparatus is held in place by an "apron" (Fig. 67), which covers the chest and abdomen, to which straps are attached. Ordinarily this is made of strong linen or cotton cloth, but a canvas front, shaped accurately to the body and strengthened with whalebone is a more comfortable and efficient support. In applying the brace the pelvic band is first attached to the apron, then the straps in order, from below upward, and, finally, the shoulder straps. Each strap is tightened until the brace is firmly fixed in proper position. If the brace is accurately

adjusted it holds its place by friction, but when the disease of the lower lumbar region, or if the brace has a tendency to upward displacement, perineal straps should be used to hold the pelvic band firmly in its place (Fig. 59). At first the brace is removed once a day in order to wash and powder the back, the same care being observed in moving the child as in the treatment by the frame; but after the skin has become accustomed to the pressure the brace should be removed only at infrequent intervals, and thus, preferably, only under the supervision of the surgeon.

FIG. 69.—The Taylor back brace and head support combined with the Whitman anterior support.

This description indicates the essential qualities of the back brace. It has been modified in various ways; for example, Dr. Taylor eventually discarded the straight pelvic band in favor of one of a U-shape (Fig. 59). This makes the brace somewhat lighter and relieves the sacrum from pressure, but it does not add to its effectiveness. The efficiency may be increased, however, by modifying the upper attachment, as is illustrated in Fig. 63, in which two triangular pads of hard rubber connected by a metal bar are employed.

This is an improvement on the simple shoulder straps of the original brace, but it does not provide the quality of support and fixation that is desirable when the disease is of the upper or middle segment of the thoracic region. In such cases the upper part of the chest is flattened, the inclination of the ribs is increased, and the shoulders droop forward, carrying with them the scapulæ. Thus the weight and the strain of the motion and use of the arms tend to increase the deformity.

In health direct forward or reaching movements of the arms are always accompanied by an increase in the posterior curvature of the dorsal spine. On the other hand, if the shoulders are drawn backward and held in this attitude the curvature of the spine is lessened and the chest is elevated and expanded (Fig. 64).

FIG. 70.—The anterior shoulder brace.

FIG. 71.—The scapular pads.

In the treatment of disease of the upper dorsal region it should be the aim, in the application of a brace, to follow this indication and to apply pressure directly upon the extremities of the shoulders to assure the greatest possible fixation of the spine and to restrain the movements of the arms that tend to increase the deformity.

The diagrams illustrated in Fig. 65 show how such support may be applied. Two saucer-shaped plates of hard rubber or padded metal (Fig. 69) cover the heads of the humeri and are joined by a rigid bar of steel, which passes across but does not touch the chest. On the back brace are placed two triangular pads of similar construction, which cover and press upon the scapulæ. These pads are, however, not essential and are often omitted. The back brace is applied, the shoulders are then drawn backward and the shoulder-cups are firmly attached by

straps to the neck bars of the brace above and by axillary bands below, in the usual manner. By this means the thorax is elevated and the spine is more effectively fixed, while direct movement of the arms forward is checked. It would seem that such restraint would be irksome to the patient, but in an extended use of the apparatus this has never caused complaint. In many instances, even when the disease is as low as the tenth dorsal vertebra, it may be used with advantage, but it is especially indicated when the disease is in the neighborhood of the seventh dorsal vertebra. In connection with the shoulder brace it is usually advisable to apply a support beneath the chin to prevent the forward inclination of the neck and to tilt the head somewhat backward. A very simple and inoffensive support of this character is a loop of steel surrounding the neck and attached by screws to a back bar on the brace (Fig. 72). If a more efficient brace is required, as when the disease is of the upper dorsal or cervical regions, the Taylor head support should be used. This is an oval ring of steel which may be clasped about the neck by means of a lateral hinge. On the front a cup of hard rubber supports the chin and behind the ring fits upon an upright pivot that may be raised or lowered upon a crossbar on the upper part of the brace; free lateral motion is allowed, or it may be checked by means of a screw (Fig. 66).

FIG. 72.—The loop head support.

FIG. 73.—Disease of the middle cervical region, showing the deformity and attitude. This patient had been paralyzed for one year before treatment was begun. (See Fig. 67.)

If fixation of the head is indicated, as in disease at or near the occipito-axoid region, two steel uprights may be attached to the back of the ring; these are bent to fit the posterior and lateral aspect of the head closely, and a band of webbing is passed from one upright to the other and about the forehead.

In applying the support the chin should always be tilted slightly upward in order to throw the weight of the head backward (Fig. 67). The adjustment of the head support is made easier if the pivot is attached to the upright by means of a ball-and-socket joint (Shaffer—Fig. 63) that may be regulated by a screw and key.

When the Taylor head support or similar appliance is used the greater part of the pressure is sustained by the chin, which may, after a time, undergo an unsightly recession. It may be of advantage, therefore, in such cases, and particularly when restraint of the motion of the neck is desirable, to transfer this pressure to the forehead and occiput by extending the back bars upward over the back of the head (Fig. 78).

A jury-seat may be used to support the head also, as described in connection with the plaster jacket (Fig. 68).

Comparison of the Two Forms of Ambulatory Support.—The most severe criticisms of the jacket have been made, by those unfamiliar with its use, on theoretical grounds rather than from actual observation. While it is apparent that there are certain objections to the support, experience has shown that when it is properly applied it is in suitable cases a thoroughly reliable, efficient, and often indispensable means of treatment. Indeed, it may be stated that by means of the various forms of support that may be constructed of plaster of Paris it is possible to treat successfully nearly every case of Pott's disease without the aid of the professional brace-maker.

It is evident that under certain conditions a fixed support must be inferior to the adjustable brace, in early childhood for example, when the pelvis is undeveloped. Again, when the disease is low down, at or near the lumbo-sacral junction, the lower border of the jacket does not hold the pelvis with sufficient security to provide the proper support. In the upper dorsal region the attachments for accurate fixation may be adjusted more readily to the brace, and in disease of the cervical region the metallic head support is to be preferred to the halter of the jury-mast, for the reason that it cannot be removed by the patient. The traction of the jury-mast is very effective when properly used, and particularly so when painful distortion of the neck is present; but the tension on the strap is rarely constant, and thus it loses in efficiency. A rigid support is, of course, preferable in the disease of the atlo-axoid region. The Calot support, though cumbersome and somewhat difficult of adjustment, is perhaps the most efficient means of treatment of disease of the upper region of the spine. It is, of course, least satisfactory during the warm months.

The jacket is most serviceable in the region from the tenth dorsal to the second lumbar vertebra. It is not only effective, but it is often a more comfortable support than the spinal brace. It is more satis-

BOSTON CITY HOSPITAL

factory when lateral deviation of the spine is present, and from the clinical stand-point it is often more efficacious in relieving pain in this region when the disease is at all acute. One may conclude, then, that each form of support may be used according to the indications. The absolute control of the treatment, assured by the use of the plaster jacket, will often overbalance the claims of the brace.

Other Forms of Support.—In certain cases of disease of the lower lumbar region it may be advisable to restrain the movements of the thighs, although ordinarily, when this is necessary, ambulation should be discontinued. Such restraint may be attained by making the back bars of the brace stronger and extending them down the thighs to the knees like a double Thomas hip brace.

If the jacket is used it may be extended to a single or double spica for the same purpose as has been mentioned. Such appliances are useful when psoas spasm and "cramp" are troublesome symptoms.

In disease of the cervical region a certain degree of support and fixation may be obtained by collars of poroplastic felt, plaster of Paris, or other material. The *Thomas collar* (Figs. 75 and 76) is the best of this type of support, but none of them is thoroughly efficient unless used with a brace to control the larger movements of the spine. They are useful in emergencies, but they are not often required when proper braces can be obtained.

Fig. 74.—A light support of steel and celluloid for disease of the cervical region. (Baeyer.)

In the final stage of treatment the Knight brace, a light steel frame with corset front, may be used (Fig. 78) or a long corset similar to that ordinarily worn by women, but strengthened by the insertion of light steel bars, may be sufficient.

Many other forms of apparatus of greater or less merit might be described, but space has permitted only a detailed account of three forms representing the essential principles involved in the treatment of Pott's disease.

The Principles of Treatment in Their Practical Application.—The effect of treatment must be estimated not simply by its relief of the symptoms of the disease, since deformity may increase in spite of the apparent well-being of the patient, but it must be selected and continued or changed with the aim of combating ultimate deformity, and on this standard success or failure must be determined.

Indications for Treatment by Recumbency.—As has been stated already, the most important influence toward deformity is the force of gravity; therefore horizontal fixation in overextension is the most efficient means of preventing deformity and of assuring the rest that favors repair.

It is indicated as the routine treatment in infancy and in early childhood up to the age of four years at least.

In many instances absolute recumbency may not be required, but the period of activity must be carefully regulated, and must be dis-

FIG. 75.—The Thomas collar of leather stuffed with cotton. (Ridlon and Jones.)

FIG. 76.—The Thomas collar for permanent use. A piece of thin sheet metal is cut wide enough to reach from the sternum to the chin, and from the back of the neck to the base of the occiput. The edges are turned out and the whole properly covered with felt and fitted. (Ridlon and Jones.)

FIG. 77.—The Thomas collar applied. (Ridlon and Jones.)

FIG. 78.—The Knight brace with the back bars prolonged to support the head.

continued when there is evidence of discomfort or weakness or pain. If the period of activity must be short, it should be passed in the open

air. The passive attitude of sitting, although less strain is thrown upon the spine than during activity, favors deformity; thus the reclining or semireclining posture should be assumed, as a rule, when the child is in the house, at least during the active stage of the disease. Even if the spine appears to be perfectly supported, the time spent in bed should be long, and a period of rest in the middle of the day should be enforced.

FIG. 79.—The final result of extreme bilateral psoas contraction. The direct bone deformity being comparatively slight.

FIG. 80.—Final result of lumbar disease; spontaneous absorption of abscess and but slight deformity. (See Fig. 13.)

The arguments in favor of horizontal fixation in early childhood do not apply to disease in the adult. At this age the structure of the spine is resistant and deformity is little to be feared, while such confinement would be irksome and impracticable; thus local support, supervision, and, if possible, a change of climate must be the treatment of selection for the adolescent or adult.

In the middle period of childhood, from the fifth to the tenth year,

horizontal fixation is the treatment for emergencies; for paralysis, for abscess, for dangerous disease of the atlo-axoid region, for progressive deformity, and for pain that cannot be relieved by the ordinary means.

Special Indications for Treatment of Diseases of the Different Regions of the Spine.—In the selection of treatment and in the general management of Pott's disease each region of the spine must be judged by itself, since in each there are special difficulties to be met, and complications to be feared that may influence the prognosis and lead to modifications of the routine of treatment.

The Lower Region.—The prognosis is good in disease of the lower region, and one may, as a rule, predict recovery without noticeable deformity; at most but a slight shortening and broadening of the trunk and a peculiar erectness of attitude.

The brace is the better support when the disease is near the sacrum, while the jacket is often more comfortable and more effective than the brace when the middle or upper lumbar region is diseased, particularly when lateral deviation of the spine is present.

The most troublesome complications of this region are psoas contraction and the abscess with which it is often combined.

As has been stated, psoas contraction changes the attitude of over-erectness, favorable to repair, to a forward stoop that increases the pressure and friction at the seat of disease. If this attitude persists and if it becomes fixed by permanent changes, such as are likely to follow the burrowing of a pelvic abscess, most disastrous deformity may result; the body and the thighs are approximated and the erect attitude is made impossible. In neglected cases of this character, division of the contracted tissues and forcible correction or even subtrochanteric osteotomy may be necessary to overcome the secondary deformity. In ordinary cases of psoas contraction, and when one limb only is flexed, the patient may be allowed to go about with crutches, using a high shoe on the unaffected side, so that the flexed limb need not affect the attitude. If, however, the contraction persists, it is well to place the patient on a frame and to reduce the flexion by traction in the line of deformity, or it may be directly reduced under anesthesia, fixation in the extended position being assured by a spica jacket, as will be described in the treatment of disease of the hip-joint. Persistent psoas contraction is almost always a symptom of abscess about the origin or in the substance of the muscle, and when it is accompanied by pain it is always an evidence of progressive disease.

Abscess may be expected as a complication in at least 50 per cent. of the cases of disease of this region, but it is by no means always accompanied by psoas contraction, nor is psoas contraction always symptomatic of abscess. Abscess unaccompanied by contraction usually has its origin above the lumbar region and does not involve, therefore, the substance of the psoas muscle. The treatment of abscess is considered elsewhere.

Disease of the Middle and Upper Dorsal Region.—This is, from the stand-point of prevention of deformity, the most difficult region of

the spine to treat, although the symptoms of the disease may be readily relieved.

Deformity is present in nearly all cases when the patient is brought for treatment, and it is difficult to check its progress for the reasons that have been stated already.

The final result in the majority of cases is what appears to be exaggerated round shoulders; the neck is shortened and projects forward, the chest is flat, and the shoulders are high.

In all cases of disease above the ninth vertebra, the shoulders should be restrained to secure greater fixation of the spine; and in all cases above the seventh or eighth vertebra a head or chin support is indicated in addition. It is in the treatment of disease of this region that the Calot jacket is particularly indicated.

Paralysis is a frequent complication of disease in this region. When it appears after treatment is begun, it usually indicates inefficient fixation of the spine or of failure to regulate the strain to which the diseased part is subjected. Its symptoms and its treatment will be considered later.

Disease of the Upper Dorsal and Middle Cervical Region.—This is the most favorable region of the spine for treatment. The disease is usually not extensive because of the small size and compact structure of the vertebræ, and the mobility of the cervical region is so great that it readily compensates for the local rigidity. Under efficient treatment one may predict recovery without noticeable deformity, and in the less successful cases it is not, as a rule, offensive. The shoulders appear high, the neck is short, the head inclines forward, while the back is abnormally flat in compensation for the change in contour of the part above.

When the case of cervical disease is first brought for treatment a *wry-neck* deformity, often made more persistent by the infiltration of an abscess or by enlarged cervical glands, is almost always present. As a means of correcting this distortion, the jury-mast and traction halter is a very efficient and comfortable support. Under its constant tension the deformity may be corrected with ease, but as a permanent treatment more exact fixation by means of metallic support or the Calot jacket is preferable.

Disease of the Occipito-axoid Region.—Under efficient treatment the prognosis is good, and recovery without deformity should be the rule. The course of the disease, although it is often accompanied by acute symptoms, is usually short, as compared with that of other regions of the spine. It may be assumed that, in many cases, it is primary arthritis, or, at least, that the primary focus in the atlas or axis is very small. The disease at this point is, however, in close proximity to the vital centers, and sudden death from displacement and pressure on the cord is not uncommon. Abscess is frequent, and it is often a troublesome and dangerous complication.

If wry-neck deformity is present it should be reduced by traction either in bed or by means of the jury-mast. The head should then be

fixed in an attitude of slight extension by an efficient head brace or by the Calot or similar support. Recumbency is indicated during acute phases of the disease.

Abscess Complicating Pott's Disease.—A limited collection of tuberculous fluid is present at some time during the course of Pott's disease in practically all cases, an assumption usually confirmed by roentgen-ray examination; but unless it appears as a palpable tumor above or below the thorax or upon the surface of the body, its presence is not often detected.

In a total of 1779 cases of Pott's disease examined with reference to the occurrence of abscess as a complication, it was detected in 334, or 18.7 per cent.

In 354 autopsies by Mohr, Nebel, Bouvier, and Lannelongue abscess was found in 281, or nearly 80 per cent.

Although cases of Pott's disease that come to autopsy may be supposed to represent a severe type of disease, yet it is evident, by contrasting the statistics, that a large proportion of the abscesses escape detection in the living. One may conclude, then, that abscess may be expected as a more or less serious complication in 25 per cent. of all cases of Pott's disease, and in at least half of those in which the lower region of the spine is affected. The greater frequency here is explained by the large size and less resistant structure of the vertebral bodies as compared with those of the upper regions.

The tuberculous abscess is separated from the neighboring parts by a limiting wall varying in thickness according to its age, the outer layers of which are of fibrous and cellular tissue, the inner of granulation tissue covered with yellowish-gray or pinkish-gray necrotic membrane, which is easily separated from the underlying parts. The fluid of the abscess is usually of a whitish or whey-like color, composed of serum, leukocytes and emulsified caseous material and fibrin. Floating in it are masses of cheesy necrotic tissue and sometimes minute fragments of bone, which settle to the bottom of the glass. Certain of the smaller quiescent abscesses contain only this whitish semisolid material. The fluid of abscesses in process of resolution is often clear, like serum; but if secondary infection has taken place the pus is of a greenish-yellow color and is of uniform consistency. At any stage of its progress the abscess may become stationary and its contents may be absorbed; in fact, such an outcome is not unusual. The fluid of the abscess is usually sterile, and secondary infection, before a communication with the exterior of the body is established, is uncommon.

Abscess is a symptom of disease, and it is in some degree an evidence of its character. If it appears early and increases in size rapidly it usually indicates a destructive and rapidly advancing process. On the other hand the slowly enlarging or quiescent abscess has but little significance. The abscess may cause no symptoms whatever, or it may be a source of inconvenience simply because of its size or situation. In many instances, however, a period of malaise or discomfort or pain is followed and explained by the appearance of an abscess, but whether

the symptoms are caused by the tension of the abscess or by a more acute phase of the disease itself is not always clear.

Large abscesses that are increasing in size and approaching the surface are usually accompanied by pain and by elevation of temperature. This may indicate a slight degree of secondary infection, but the ordinary deep abscess appears to have no other effect than to add, doubtless, to the susceptibility of the patient.

The Course and Peculiarities of Abscess in the Different Regions of the Spine.—The tuberculous abscess may remain as a small collection of fluid in the neighborhood of the diseased area. As a rule, however, it slowly increases in size, and under the influences of the force of gravity and the tension of its contents it finds its way down the spine or toward the exterior of the body, following the path of least resistance. The abscesses that have passed below the diaphragm or that have originated below this point may follow various paths. Some enter the sheath of the psoas muscle and finally make their appearance on the inner aspect of the thigh, *psoas abscess*. Others perforate the sheath of the quadratus lumborum muscle and form a *lumbar abscess*, projecting between the twelfth rib and the crest of the ilium at the triangle of Pétit. Those abscesses that escape from the fascia of the psoas muscle or that pass downward on the surface of the iliac fascia, the so-called *iliac abscesses*, may appear as a tumor over the outer extremity of Poupart's ligament at the junction of the transversalis and iliac fasciæ, or the fluid may follow the course of the iliac artery to the thigh, or, escaping from the greater sacrosciatic foramen, form a *gluteal abscess*. The iliac or psoas abscess is most often confined to one side, but it may be bilateral, the two sacs communicating with one another by a larger or smaller channel.

FIG. 81.—Bilateral lumbar abscess.

In the *thoracic region* the abscess may remain indefinitely in the posterior mediastinum, where, if large, its presence may be demonstrated by an area of dulness extending toward the lateral region of the thorax, or it may perforate the intercostal muscles and appear on the posterior or lateral aspect of the chest, or it may pass downward through the aortic opening in the diaphragm and become an iliac abscess.

Abscess caused by disease of the *occipito-axoid* region may force its way forward between the recti muscles and appear behind the pharynx as the retropharyngeal abscess, or the fluid may take the opposite direction and distend the suboccipital triangle and then pass forward to the region of the mastoid process. In other instances the abscess may dissect its way about the base of the skull or pass upward through the foramen magnum or downward into the spinal canal.

Abscesses from the *middle cervical region* usually pass outward between the scaleni and longus colli muscles to the interval between the trapezius and sterno-cleido-mastoid, perforating the skin about the middle of the lateral aspect of the neck near the anterior border of the latter muscle.

These are the paths usually followed by the tuberculous fluid, but occasionally it may enter the spinal canal or break into the pleural cavity or lung or intestine or by the side of the rectum or elsewhere.

Treatment of Abscess.—Abscess is by far the most serious complication of Pott's disease. It may interfere with proper mechanical treatment, and it is often a cause of permanent deformity. It prolongs the course of the disease by extending its boundaries, and, although it is not often an immediate cause of death, yet many patients die because of the exhaustion of long-continued suppuration and of the amyloid degeneration that may finally result.

A large abscess is always a source of danger because of the possibility of secondary infection of its contents before it finds an outlet, and because of the probability of infection when a communication with the exterior has been established. Abscess is, however, a symptom and result of disease, and in properly treated cases it is, as a rule, a complication of comparatively slight consequence. If it is not present when treatment is begun, one may hope to prevent it by effective protection of the spine; and if it is present this protection should be all the more rigidly enforced. An abscess often exists for months before its presence is detected, and after its discovery it may remain quiescent for a long time and finally disappear.

In a large proportion of cases the abscess causes no symptoms, but slowly finds its way to the surface of the body. Meanwhile it may be assumed that the disease of the spine, of which the abscess is a result, is in process of cure; so that when the fluid finds an outlet the source of supply will be shut off, and thus the patient is spared the danger and discomfort of discharging sinuses, that so often persist after early operation.

The so-called radical treatment of the abscess of spinal disease is usually unsatisfactory, because it is impossible to remove the disease of which the abscess is a symptom.

As the abscess is a symptom of disease, so, as a rule, its treatment should be symptomatic. The *retropharyngeal abscess* demands prompt evacuation, because it is likely to obstruct breathing and swallowing, because its sudden rupture may cause death, and because an abscess in

MEDICAL LIBRARY

such close proximity to the vital centers is always a source of danger. In cases of emergency the abscess may be evacuated by an incision in the middle line of the pharynx but preferably the opening should be from the exterior. An incision is made along the posterior aspect of the sternomastoid muscle in its upper third. The abscess tumor is easily reached by careful dissection, and drainage is established which has evident advantages over that into the throat.

Abscesses from the *middle cervical region* usually point in the lateral region of the neck and cause but little inconvenience. Abscesses in the *upper thoracic region* may, in rare instances, cause dangerous pressure on the trachea or bronchi, as shown by spasmodic attacks of inspiratory dyspnea, "asthmatic attacks." In some instances an area of dulness near the seat of disease demonstrates the position of the abscess, but if it lies in the median line it cannot be detected either by auscultation or percussion. If the inspiratory dyspnea is well-marked the symptom may be fairly attributed to this cause, and if the spasmodic attacks are frequent and severe the operation of *costotransversectomy* is indicated. An incision is made, preferably on the right side, to expose the articulation between the transverse process and the rib, and one or two of these joints is resected; the finger is then inserted and passed along the surface of the adjacent vertebral body until the abscess sac is reached. This is usually directly in front of the spine at or about the fifth dorsal vertebra. After incision a drainage tube should be inserted (Fig. 9). The same procedure should be considered whenever abscess and paraplegia are combined, as it is quite possible that the paralysis is dependent on the pressure of the abscess.

At the Rizzoli Institute of Bologna abscesses in this region are evacuated by a trocar at least 3 mm. in diameter. This is inserted in an intercostal space, starting at a point about two-fingers' breadth from the spinous process and in a direction from without inward, following the margin of the body of the vertebra, keeping in contact with the superior margin of the rib below. As a rule, the puncture is made at the right of the spine, as there is less danger of puncturing the aorta, even if it is embedded in the wall of the abscess. The depth of the abscess from the skin is about 7 cm. From practical experience, it is concluded that all mediastinal abscesses in which there are indications of involvement of the cord should be evacuated in this manner.

In the lower region of the spine intervention may be indicated because there is evidence of *secondary infection*. In this event, if the abscess distends the lumbar region or forms a sac on either side of the spine an opening in the loin on one or both sides of the spine is necessary. This is made, as in operations on the kidney, by an incision on the outer side of the erector spinæ muscle between the last rib and the crest of the ilium along the outer border of the erector spinæ muscles. The dense fascia is divided, exposing the quadratus lumborum, which is split longitudinally to the outer side of the transverse processes, care being taken to avoid the lumbar arteries. In certain cases it is possible to expose the spine and to remove fragments of necrosed bone along

with the contents of the abscess. As a rule the complete removal of the lining membrane of the abscess is not practicable, and one must be content to evacuate the solid and semisolid contents by flushing with hot water, together with as much of the abscess membrane as may be removed by swabbing with gauze. The most important point in the operation is to provide efficient and complete drainage of the cavity. Two or more counter-openings are usually necessary when the lumbar incision has been made, one just in front of the anterior-superior spine and another in the thigh, if the abscess is of the psoas variety. Long drainage tubes are inserted, and should remain until a proper channel for the escape of pus has been established.

If the abscess is of one side only, not extending into the thigh, and if evacuation seems advisable because of its size or tension, it may be opened by an anterior incision below Poupart's ligament just to the inner side of the sartorius muscle. After expression of its contents a drainage tube may be inserted long enough to reach to the seat of disease if it be of the lumbar region.

The dressing should be of dry sterile gauze, and great attention should be paid to absolute cleanliness and to effective drainage. As soon as it is possible, if the discharge has become slight and if the spine can be properly supported, the patient is allowed to walk about and to go into the open air. In ordinary cases a slight discharge persists for several months or longer, depending on the condition of the disease.

In the symptomatic treatment of abscess, *aspiration* is sometimes of service, for by this means it may be prevented from increasing in size; and if the disease is quiescent the cure of the abscess may follow the removal of its contents which allows the collapse of its walls. When aspiration is employed it should be repeated systematically as often as the abscess cavity refills. After each evacuation pressure should be applied to favor the adhesion of the apposed walls.

If the contents are of such a nature that aspiration is ineffective an *incision* may be made, through which the semisolid substance may be removed. The opening is then closed by several layers of sutures, and pressure is applied with the aim of obtaining primary union. This operation may be repeated several times if necessary. Often a sinus eventually forms at one or other of the openings.

The *injection of antituberculous remedies*, although they may have no direct influence on the disease, may diminish the infective quality of the fluid and solid contents of the abscess and stimulate the reparative processes that check its progress. An emulsion of iodoform in sterilized oil or glycerin (10 to 20 per cent.) is often used, from 4 to 30 grams being injected at intervals of from two to four weeks after evacuation of the contents, the amount and the frequency of the injection depending upon the age of the patient and upon the effect of the treatment. If used with caution as to asepsis, and to the toleration of the patient for iodoform, no harm will follow, even if the treatment proves to be of little practical value.

Calot favors frequent aspirations usually at intervals of a week or more and injection of a fluid composed of:

	Grams.
Sterilized oil	70
Ether	30
Creosote	6
Iodoform	10

Two to 12 grams are injected, according to the age of the child.

The abscess is aspirated as often as pus accumulates and the average number of injections is 10 to 12. When the fluid withdrawn becomes serous in character the injections are discontinued.

As the abscess approaches the surface the skin becomes red and thin, and there is usually some local sensitiveness and pain. Whenever spontaneous evacuation of the abscess is probable the mother should be instructed as to the necessity of absolute cleanliness and the proper dressings should be provided. In such an event the patient should remain in bed for several days or until the discharge has become small in amount.

In the symptomatic treatment of the abscesses of Pott's disease one may conclude, then, that operation will be indicated in the treatment of the retropharyngeal abscess and in the rare instances when dangerous pressure is exerted by an abscess in the posterior mediastinum. It is indicated, of course, when there is evidence of mixed infection or when the rapidly enlarging abscess causes discomfort or interferes with effective support. It is usually indicated when the abscess is of large size if proper care can be provided. The operative treatment is practically free from danger if cleanliness and efficient drainage can be assured. Aspiration is free from danger; it is often of service in preventing the enlargement of the abscess and it may hasten its absorption. An incision for the complete removal of the contents, followed by immediate closure of the wound, is in many instances the operation of selection.

If the abscess cavity after the removal of its contents is not large it may be filled with Beck's mixture of bismuth and vaseline 1 to 3, injected at a temperature of 110°. This treatment is described in Chapter V. In all cases of this type constitutional treatment, particularly exposure to the direct rays of the sun, is of the greatest importance.

Paralysis Complicating Pott's Disease ("Pott's Paraplegia").—The tuberculous process in the vertebral bodies may extend backward, and breaking through the posterior ligament it may enter the epidural space and press upon the spinal cord; then follows paresis or paralysis of the parts below the constriction.

The caliber of the spinal canal is not usually lessened by the characteristic angular distortion of the spine, although the weight and forward inclination of the trunk may force the softened tissues backward against the cord and thus increase the direct pressure. In fact,

paralysis is much more often associated with a slight or moderate kyphosis than with extreme deformity.

In rare instances the pressure may be due to a fragrant of necrosed (Fig. 82) bone or to solidification of the tissues in and about the canal during the process of repair. It may be caused, in part, at least, by the pressure of a neighboring abscess, but it is usually the result of the slow advance of the tuberculous disease. When this has forced an

FIG. 82.—Pressure on the cauda equina by a fragment of the second lumbar vertebra. (Sorrel.)

entrance into the spinal canal it sets up a resistant inflammatory thickening of the coverings of the cord—first a peripachymeningitis and then a pachymeningitis. In addition to the direct pressure there may be an interference with blood supply and the lymphatic circulation, with resulting local edema of the cord. An increase in the interstitial connective tissue of its substance and a corresponding atrophy of the nervous elements may follow, and as a sequence an ascending and descending degeneration that, in prolonged cases, may terminate

in partial or complete sclerosis. The dura mater is a resistant structure and direct destruction of the cord by the tuberculous disease is uncommon. In fact, as a rule, but little permanent damage results, even from long-continued pressure and paralysis, for the cord seems in these cases to possess the power of repair and regeneration to a remarkable degree.

Frequency.—In 1670 cases of Pott's disease recorded at the New York Orthopaedic Dispensary, paralysis occurred in 218,[1] and in 445 cases in the private practice of Dr. C. F. Taylor,[2] 59 cases of paralysis were observed. Thus, in a total of 2015 cases of Pott's disease there were 279 cases of paralysis, or 13.7 per cent.

This proportion is much larger than the normal, however, for many of the patients were taken to the special hospital because of the paralysis, as in 40 of Taylor's and in 133 of the dispensary cases. If these be excluded, the percentage of paralysis occurring in those actually under treatment is reduced to 5.6 per cent. This percentage corresponds very closely to that of Dollinger,[3] viz., 41 cases of paralysis in 700 cases of Pott's disease under treatment (5.8 per cent.), and it may be accepted as representing the average liability to paralysis among those who have received treatment for Pott's disease, the percentage being much higher in neglected cases. In 241 cases of Pott's disease in adolescents and adults treated by Painter[4] there were 33 cases (13 per cent.), a higher proportion than in childhood.

The Liability to Paralysis in Disease of the Different Regions of the Spine.—The liability to paralysis is very much greater in disease of certain regions of the spine than in others.

Thus, 105 of the 209 cases in Myers's list, in which the situation of the disease was recorded, complicated disease of the dorsal region above the eighth vertebra. Of the remainder, in 16 the disease was of the cervical region; in 12 of the cervicodorsal, and in 59 of the lower dorsal and dorso-lumbar regions.

Thirty-seven of Taylor's 59 cases were caused by disease of the dorsal region; 8 occurred in the cervical and cervico-dorsal and 11 in the dorso-lumbar and lumbar regions.

Twenty-six of the total of 41 cases recorded by Dollinger were caused by disease of the third to the seventh dorsal vertebræ, inclusive, or about 23 per cent. of the cases in which this region was involved.

Of 132 cases of paraplegia reported by Gibney[5] not one complicated lumbar disease; nearly all were caused by compression in the middle or upper thoracic region.

These statistics show that the upper and middle dorsal section is the point of greatest liability to paralysis—a fact that is explained possibly by the smaller size of the canal at this point, and by the difficulty of assuring complete fixation at the seat of disease. It may be estimated

[1] Myers: Tr. Am. Orthop. Assn., 1891, **3**, 209.
[2] Taylor and Lovett: New York Med. Rec., June 19, 1896.
[3] Loc. cit.
[4] Am. Jour. Orthop. Surg., November, 1910.
[5] Jour. Nerv. and Ment. Dis., January 5, 1897.

that in 15 per cent. of the cases of Pott's disease of this region paralysis will appear before cure is established.

Time of Onset.—In exceptional instances the paralysis may precede deformity, and it may be the first symptom that attracts attention to the disease. In 14 of 74 cases reported by Gibney the paralysis was present before the bone disease was recognized, and it is probable that the primary disease had existed for several months before the appearance of the paralysis. Usually it is a comparatively late symptom, appearing after the stage of deformity and more often six to twelve months after the recognition of the disease, but its appearance may be deferred until long after apparent cure.

Duration.—In exceptional cases the paralysis appears to be caused simply by disturbance of the circulation of the cord, due possibly to the pressure of the superincumbent weight upon the softened and diseased tissues, as it disappears almost immediately when the spine is straightened and supported. Usually the paralysis persists for several months, not infrequently it lasts a year, and partial or even complete recovery is possible after a much longer time, in one instance after five years.[1] Recovery from the paralysis depends upon the course of the disease of which it is a symptom, upon the absorption and organization of the tuberculous granulations that press upon the cord, and upon the regenerative changes in its structure, if it has been implicated in the disease.

Symptoms.—The most marked effect of the pressure on the cord is the interference with its conductivity. The reflex centers situated below the point of constriction, relieved from the inhibition of the brain, become overactive, while control of the parts below the constriction is lessened or lost. The pressure of the diseased products is more directly upon the anterolateral columns, so that motion is much more often primarily affected than is sensation.

The early symptoms of Pott's paraplegia are weakness, awkwardness, and a stumbling, shambling gait. The symptoms usually increase rapidly until paralysis of motion is complete. At this stage the patella tendon reflex is increased and ankle-clonus is often present. As a rule both limbs are affected in equal degree, but occasionally paralysis of one may be more complete or may precede that of the other, and in the stage of recovery power may return more rapidly on one side than on the other. The limbs in the early stage of the paralysis may appear limp and powerless, but when the patient is moved or when the reflexes are stimulated the peculiar spastic rigidity or stiffness appears.

As a rule the stiffness increases with the duration of the disease, and spastic contractions are often present; thus, the thighs may be apposed, the knees flexed, and the feet extended. Persistent contractions indicate, as a rule, permanent damage to the cord, and in such cases complete recovery is unusual.

Sensation is not affected ordinarily, but in the more severe or

[1] Goldthwait: Am. Jour. Orthop. Surg., April, 1915.

prolonged cases it may be impaired or lost. Sensation was retained throughout in 24 of the 40 cases reported by Shaffer.

In the cases of partial paralysis control of the bladder may be retained, but usually there is incontinence. As the bladder fills the reflex center is excited, and it empties itself.

The control of the sphincter ani is less often or less noticeably affected.

As the paralysis is the result in many instances of active or of advancing disease its onset may be preceded by discomfort or pain. Thus, noticeable discomfort attended by an exaggeration of the patella tendon reflex may be considered as an indication for enforced rest of the individual, although increased activity of the reflexes is not uncommon during the progressive stage of the disease without apparent involvement of the spinal cord. When paralysis occurs in patients who are under treatment for Pott's disease the onset is not attended, as a rule, by noticeable or unusual pain; nor is pain usually complained of after the paralysis has developed.

FIG. 83.—Pott's paraplegia before the stage of deformity. The apparatus used in the treatment of this case is shown in Fig. 45.

The extent of the paralysis depends upon the situation of the disease. In exceptional cases, in which the cervical enlargement, from the fifth cervical to the first dorsal is involved, there may be flaccid paralysis of the arms with spastic paralysis of the lower extremities. This occurred in 7 of the cases reported by Myers. As a rule, however, the paralysis is a complication of disease of the dorsal region above the reflex centers in the lumbar enlargement of the cord but below the nerve supply of the upper extremities. If the disease is at a lower point, for example, in the dorso-lumbar section so that these reflex centers themselves are directly implicated, reflex activity is not increased, and intermittent incontinence is replaced by constant dribbling of urine. If the cauda equina alone is implicated in disease of the lumbo-sacral region the symptoms are those of neuritis, pain, numbness, and weakness in the area supplied by the affected nerves. Such weakness with accompanying muscular atrophy may be present in the upper extremities when the disease is in the neighborhood of the origin of the brachial

plexus, while in the lower limbs the characteristic spastic condition is evident. In characteristic cases the nutrition of the limbs is not greatly affected, nor do the contractions become permanent; but when the paralysis is prolonged, and particularly when sensation is lost, the muscles waste, the circulation is impaired, and fixed distortions usually appear. Even in the more prolonged and severe forms of paralysis occurring in childhood, bed-sores are rarely seen.

Prognosis.—In properly treated cases the prognosis is very favorable, as is illustrated by the final results of 47 of the 59 cases of paraplegia in Taylor's practice. Of these 39 recovered completely, 5 died of intercurrent disease while apparently recovering, and in 3 the recovery was partial.

Of the hospital cases recorded by Myers, 3 per cent. died of intercurrent disease. The final results could be ascertained in but 55 per cent. of the patients. All of these recovered.

Of 74 cases of paraplegia treated by Gibney,[1] 45 were cured, 12 improved, 8 unimproved, and 9 died. Thus, 77 per cent. were cured or improved. In a similar series of 40 cases reported by Shaffer, 80 per cent. were cured and but 10 per cent. of the remainder were considered as hopeless cases.

In a total of 975 cases "abandoned to medical treatment," collected from various sources by Rozoy,[2] there were 429 cures. Of the remainder 16 were improved, 130 were unimproved, and there were 244 deaths. The contrast in the results reported would appear to show the advantage of thorough mechanical treatment.

Recurrence of paralysis after recovery is not infrequent: in 18 cases such recurrences from one to four times are recorded by Myers, and seven successive attacks of paralysis were observed in a patient under treatment at the Hospital for Ruptured and Crippled.

The relapses are due apparently to the renewed activity of the disease, and in many instances this may be explained by the neglect of protective treatment.

Treatment.—The treatment of the paralysis is included in the treatment of the disease of which it is a symptom, except that even greater care should be exercised to assure fixation of the spine.

Rest in the position of hyperextension on the stretcher frame is indicated. Direct traction by the weight and pulley may be used if the disease is in the upper dorsal or cervical regions. For bed-ridden patients a convenient method of assuring extension of the spine in connection with head traction is to suspend the trunk on a sling of canvas drawn transversely beneath the seat of disease and attached to bars on the sides of the bed after the Rauchfuss method. The back brace or the plaster jacket assures additional fixation, and such support should be employed in connection with recurrency whenever practicable. The Calot jacket with the greater fixation assured by the pressure over the kyphosis should be employed in preference to other supports of this

[1] Jour. Nerv. and Ment. Dis., January 5, 1897.

[2] Mal. de Pott, Paris, 1901.

character. If, however, the brace has been worn as an ambulatory support, its shape must be modified to accommodate the change in the outline of the spine, induced by recumbency and extension.

Manipulation or massage of the limbs is contra-indicated because it simulates the reflexes. If persistent contractions of the muscles are present the deformity may be reduced by traction applied in the ordinary manner (Fig. 33), or a fixation brace may be worn. A long double spica plaster support, of which the upper part is cut away to permit inspection, is a satisfactory treatment if the contractions are spasmodic and painful.

Counter-irritation at the seat of disease was by Pott considered of the greatest value, and the application of the actual cautery from time to time, about the kyphosis, seems in certain cases to exert a favorable influence on the underlying disease.

Electricity, particularly galvanism, has been used, and it is of some service in preserving the nutrition of the limbs. Its value in a case must be judged by its effect.

Internal remedies are of little value, with the possible exception of iodide of potassium, which is supposed to act upon the tuberculous granulation tissue as upon the products of syphilitic disease. A convenient method of administration is a solution of which one drop represents one grain of the drug. This is given in milk or in Vichy water, beginning with five drops three times daily and increasing the dose a drop each day until the point of toleration is reached.

The first indication of improvement is usually lessening of the muscular spasm; then the ability to move a toe may be regained, after which recovery follows quickly. At this stage massage of the limbs may be employed with advantage. The exaggerated reflexes may persist long after recovery; in fact, as has been stated, this symptom is not uncommon among patients suffering from dorsal Pott's disease who have never been paralyzed.

Aspiration.—In some instances paralysis may be caused by the pressure of the abscess. If this may be demonstrated by roentgen examination and percussion it should be aspirated in the manner described on p. 97.

Laminectomy.—The operation of laminectomy was at one time in favor, but it has now been practically abandoned, as a treatment of routine at least, for the paraplegia of Pott's disease, because it has been demonstrated that recovery, if somewhat long deferred, is the rule without operation, while the direct death-rate of the operation is large. Of 132 operations reported by Menne,[1] 56 per cent. of the patients were cured or improved.

In 134 cases collected by Rhein[2] the immediate mortality (those dying within a month after the operation) was 36 per cent.

Lloyd[3] has collected 128 "reliable" cases of Pott's disease in which

[1] Ztschr. f. Orthop. Chir., 1912, vol. 4.
[2] Willard: Jour. Nerv. and Ment. Dis., May, 1897.
[3] Philadelphia Med. Jour., February 22, 1902.

laminectomy was performed. The deaths due directly to the operation were 21 (16.45 per cent.); subsequent deaths, 36 (28.20 per cent.); total deaths, 57 (44.55 per cent.); recoveries, 37 (28 per cent.); improved, 16 (12.5 per cent.); unimproved, 18 (14.06 per cent.).

Laminectomy is an incomplete operation in the sense that the disease of the bone is not removed, thus recurrence of paralysis from extension of the disease is not infrequent after a successful immediate result. It should be reserved for those cases in which after a thorough and prolonged trial of ordinary methods the condition does not improve. Eighteen months has been suggested as the proper time in which to test conservative treatment. The operation may be indicated also if the symptoms, in spite of treatment, increase in severity, particularly when the cervical region is involved or when there is evidence that the integrity of the cord is threatened, or when the paralysis is of sudden onset, or when displacement of bone or pressure from an abscess seems probable as the exciting cause, although in the latter instance the direct evacuation of the abscess by costotransversectomy, as advocated by Ménard, or by aspiration, should precede laminectomy. Occasionally the operation is indicated as a forlorn hope in adults suffering from cystitis and bed-sores.

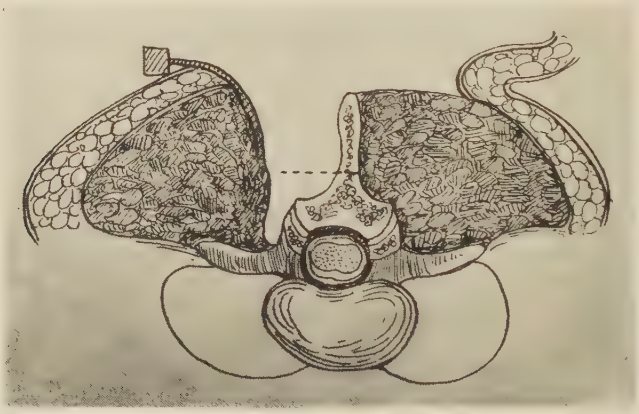

Fig. 84.—Diagram showing preservation of spinous processes. (Cross-section.) (Mixter.)

The usual method in operating is as follows:[1] A long incision is made parallel to and close by the side of the spinous processes. The muscles are drawn to one side, the spinous processes are cut through and drawn with the attached muscles to the opposite side (Fig. 84). The laminæ at the seat of disease are then removed with the cutting forceps, exposing the dura mater. The tuberculous tissue is usually

[1] It should be borne in mind that the segments of the cord do not correspond to the spinous processes of the same number. Thus, in the cervical region the affected segment is one vertebra higher. In the upper dorsal region two higher. From the sixth to eleventh dorsal three higher. The three lower lumbar and sacral segments are to be found opposite the eleventh and twelfth dorsal spines. (Chipault.)

found upon the front or lateral surfaces of the canal, and its complete removal is often impossible and the operation is usually conducted with the purpose of simply relieving pressure. The shock of the operation is often marked, so that it should be as rapid as possible, and loss of blood should be carefully guarded against. As a rule the wound may be closed without drainage. After the operation the spine should be supported by a brace or jacket until the disease is cured.

In several instances forcible correction of the spine (Calot's operation) relieved the pressure on the cord and rapid recovery followed. This indicates the importance of assuring overextension of the spine whenever it is possible, but this should be attained preferably by gradual postural correction rather than by force.

Fortunately the great majority of cases of paraplegia from Pott's disease occur in childhood, and, as has been mentioned, the complications of later life, bed-sores, cystitis and the like are rarely troublesome. Such paralysis in the adult is more serious from every point of view. The principles of treatment are the same, but their application is more difficult and the prognosis is more doubtful.

Local Paralysis Complicating Pott's Disease.—In certain cases the extension of the disease may involve the nerve roots near their exit from the spine. Actual compression at the intervertebral foramina is unusual, since the nerves are embedded in fat and occupy but one-third of the space. Local paralysis may occur independently of the involvement of the cord. The symptoms are those of neuritis in the affected nerves. In extremely rare instances the pressure on the cord may cause hemiplegia.

The Operative Treatment of Pott's Disease.—It has long been known that the cure of Pott's disease is often aided by the fusion of the posterior or unaffected part of the spine, and that anchylosis here sometimes precedes that at the seat of the disease.

From time to time attempts have been made to induce such fixation by operation, one of the earliest being that of Hadra by wiring of the spinous processes.[1] Calot[2] also performed what was essentially the fusion operation in 1897.

In 1910 F. Lange[3] reported a case in which cure was hastened by the insertion of metal rods beneath the muscles on either side of the spinous processes at the seat of the disease. He suggested also the transplantation of bone for the same purpose. Since 1920 he has used celluloid splints in 52 cases. These he considers superior to bone. The splints are inserted on either side of the spinous processes upon the laminæ. They are made of the proper length and strength and are accurately moulded to the deformity. He states that celluloid causes no irritation and that in but 5 instances was removal necessary.

The first of the effective operations for inducing anchylosis was that of R. A. Hibbs,[4] by removal of the periosteum from the spines and

[1] Tr. Am. Orthop. Assn., 1891, vol. 4.
[2] Compt. rend. d. congrès d. Chirurg., 1897.
[3] Jahreskurse f. ärtz. Fortb., September, 1910.
[4] New York Med. Jour., May 27, 1911.

laminæ and breaking down the spinous processes. This operation is described by Hibbs as follows:[1]

"A longitudinal incision is made directly over the spinous processes, through the skin, supraspinous ligament and periosteum to the tips of the spinous processes. The periosteum is split over both the upper and lower borders of the spinous processes and the laminæ, and stripped back from them to the base of the transverse processes with a periosteal elevator, bleeding being checked by packing with gauze. The lateral articulations at the base of the transverse processes are then curetted. The spinous processes are then transposed after partial fracture, so that they make contact with fresh bone, the base of each with its own base and the tips with the base of the next below (Fig. 85). The adjacent edges of the laminæ being absolutely free from periosteum, a small piece of bone is elevated from the edge of each lamina and turned down to overlap the one below. The lateral walls of periosteum and the split supraspinous ligament are brought together over these processes by interrupted chromic catgut sutures. The skin wound is closed and a steel brace applied, with the space between the uprights increased somewhat at the site of the wound, so as not to make pressure on it. In some cases the gaps in the periosteum removed from the spinous processes and laminæ have been closed by suture, thus establishing at once a continuous periosteal wall, but this is of doubtful utility.

"The number of vertebræ in each instance included in the operation is determined by the extent of the disease. It is necessary always to be sure of attaching the diseased vertebræ at either end of the involved area to healthy ones above and below.

"Rest in bed is absolute for from eight to ten weeks. During the next four weeks, sitting up is permitted. At the end of the twelfth week, walking is allowed. The brace is continued for another month, when it is removed for a part of each day until gradually left off entirely. With children under five it should be worn for six months."

The alternative operation, one of bone transplantation, was described by F. H. Albee[2] in September of the same year. This has been slightly modified since and is now essentially as follows: A lateral incision is made by the side of the spinous processes, extending above and below the seat of disease. The flap is retracted, exposing the spinous processes over which an incision is made dividing the interspinous ligament in the middle line. With a thin chisel the spinous processes are split, including two of those of the healthy vertebræ above and below, if the disease is of the thoracic region, or but one if in the lumbar; the halves on one side are separated laterally, leaving a trough, into which a section of the crest of the tibia of sufficient length, the endosteal side apposed to the median halves of the spines, is inserted and fixed in place by strong sutures of kangaroo tendon passed through the interspinous ligament. The other tissues are then closed in layers. A plaster

[1] Jour. Am. Med. Assn., August 10, 1912.
[2] Ibid., September 8, 1911.

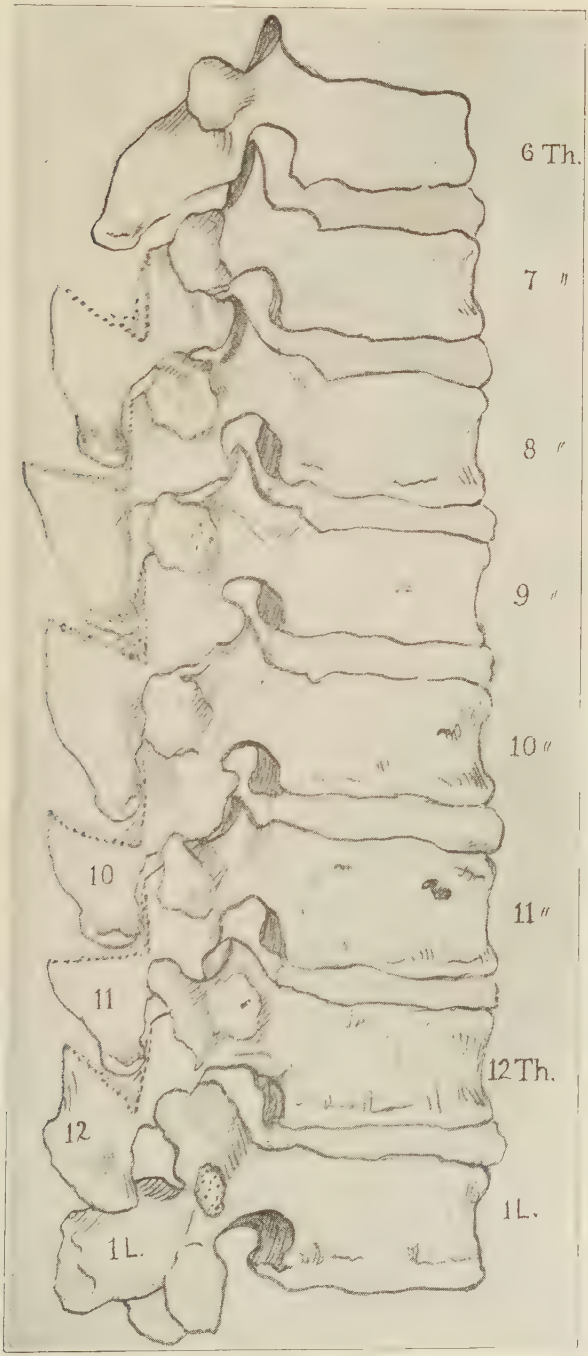

Fig. 85.—Spinous processes partially fractured and used for bridging the gap between the vertebræ. (Hibbs.)

splint or jacket may be applied, or the patient may be placed on a stretcher frame, or in suitable cases, simply confined to the bed. According to Albee, consolidation is often complete in six to eight weeks when ambulation may be tentatively resumed, and in favorable cases no support is applied because a certain strain is supposed to strengthen the graft.

In most instances the transplant must be adjusted to a more or less angular deformity, either by making multiple cuts with the saw on its under surface, so that it may be bent as a carpenter bends a board. Or, by cutting a section from the inner side of the tibia corresponding to the contour of the curve. In cases of extreme deformity the graft may be divided into several overlapping sections which eventually become fused in the process of repair.

Various modifications of these operations are employed. Beef bone is often used for the graft. It has the advantage of accuracy of adjustment and is fairly satisfactory.

The fusion operation is sometimes supplemented by osteoperiosteal grafts from the tibia or by beef bone grafts as in the operative treatment of scoliosis.

Assuming that these operations are equally effective, that of Hibbs has the advantage that it does not involve other injury, that it reduces in some degree the angularity of the projection and that it is more applicable to cases of extreme deformity. On the other hand, it is a tedious operation, involving more local disturbance of the tissues and more shock to the patient.

Bone transplantation has the advantage of providing direct support with possibly greater immediate assurance of security with very little local injury. In a number of cases, however, the graft has been broken after consolidation was apparently complete with return of the symptoms. One may conclude therefore that as a permanent support it is less stable than fusion.

In the one instance, the transplanted bone and the resulting fusion of the spinous processes form a bony ridge or crest. In the other, the area of fixation is more diffused, simulating more closely the natural process of repair. Both Hibbs and Albee advocate operative fixation in practically all cases of tuberculosis of the spine.

The former has reported on the final results of the fusion operation in 286 consecutive cases (1915–1920[1]), 40 per cent of the patients being less than five years of age. There were 3 operative deaths; 74.6 per cent. of the patients were cured; 3.1 per cent. were not improved. There were 67 deaths, 10 of them from causes other than tuberculosis. The average stay of the patients in the convalescent hospital was nineteen months.

Henderson[2] has reported on final results in 264 cases, but 16 of the patients being less than ten years of age. In 90 per cent. bone grafts were employed and in 10 per cent. fusion. The results were excellent in

[1] Jour. Bone and Joint Surg., October, 1928.
[2] Jour. Am. Med. Assn., June 5, 1929.

33 per cent., good in 18.1 per cent., fair in 15 per cent., poor in 12.1 per cent. The mortality was 20.4 per cent.

Henderson's results correspond fairly with those reported by Koenig[1] of 46 operations after an interval of five or more years. The results were satisfactory in 63 per cent., unsatisfactory in 37 per cent., death-rate 24 per cent. Neither abscess nor paralysis were favorably influenced by the operation. The deformity was not lessened and not infrequently it increased somewhat after the operation.

Albee has reported on the more immediate results in a much larger number of patients treated by himself and others. It is stated that the disease was arrested in 84.4 per cent. of the cases and that the mortality was less than 3 per cent.[2]

It seems fair to conclude that these operations simply assure more efficient splinting for the weakened spine than can be attained by apparatus and that operative treatment, although of the greatest value in selected cases, particularly in the adolescent or adult class, is not to be undertaken as a routine or exclusive measure in the treatment of Pott's disease, but that it is distinctly supplementary to conservative treatment.

It is more often indicated in the thoracic region where motion is comparatively limited than in the lumbar segment where it is so important, while the cervical spine is hardly amenable to operative treatment. Operations of this character are more likely to be successful in the curative sense in the adolescent or adult class than in early childhood. Furthermore, since cure is attained at the expense of movement the functional results of conservative treatment in favorable cases are better in this respect than when four to eight vertebræ are fused.

The Duration of the Treatment of Pott's Disease.—The duration of the treatment must depend upon the extent and severity of the disease. It may be divided into two periods: one during which the disease is active, when fixation is indicated, and a stage of recovery, during which supervision is required. During the first stage the destructive process may increase the direct deformity; during the later period of weakness the distortion may increase, simply because of the general inclination toward deformity and because of the atrophy of the supporting muscles. A certain increase of deformity even during treatment is common as 78 of 125 (62 per cent.) cured cases reported from the New York Orthopaedic Hospital (loc. cit.).

Tuberculosis of the spine is slow in its progress, and actual ossification that assures repair does not begin, according to Calvé,[3] until about three years after the onset of the disease, and recovery is often uncertain. The course of the disease is shortest in the cervical region, but even here two years of brace treatment will probably be required, and in the lower region double this time even in the milder type of cases. The average duration of treatment in the cases reported from the New

[1] Arch. f. Klin. Chir., 1928, vol. **151**.
[2] Orthopedic and Reconstruction Surgery, 1919.
[3] Jour. Am. Orthop. Assn., January, 1914.

York Orthopaedic Hospital (loc. cit.) being seven and one-half years. Active treatment should be continued as long as there is evidence of disease. The absence of actual pain and discomfort is of little value in determining the absolute cure if braces have been employed. The absence of muscular spasm is more significant, since it usually persists as long as the disease is active. The presence of pain on passive motion or muscular contraction or abscess would, of course, indicate the necessity of further treatment.

Direct palpation is of some value in determining the condition of the affected parts. During the progressive stage, careful, deep pressure over the spinous processes may show greater mobility of those involved in the disease. During the stage of repair and consolidation the mobility is replaced by rigidity. The appearance of the kyphosis has some significance. In the early stage of the disease its area is not clearly defined, but when consolidation has taken place its extent is shown by the rigid vertebræ, which stand out separated from the remainder of the spine by a well-marked sulcus, which is much deeper below than above the kyphosis.

Even when the disease appears to be cured, and even when operative anchylosis seems assured, removal of support should be tentative; the jacket should be replaced by the corset, or the brace by a lighter appliance; then support may be removed at night, later for part of the day, and at last, after many months, it may be discarded. Then may follow massage of the atrophied muscles of the trunk and gentle exercise.

Such careful supervision must be continued for a much longer time if the best ultimate result is to be attained, for, as has been mentioned, one should guard against the secondary distortions, which may be due simply to weakness and to the unfavorable mechanical conditions induced by the primary deformity. If curvatures of the spine are so common among normal individuals how much more likely is deformity to increase when the trunk has been weakened by disease and by long disuse of the muscles.

This secondary increase of deformity is not so much to be feared after the cure of the disease in the lumbar region, because of the favorable attitude of erectness, nor is it likely to be marked after cure in the cervical region of the spine; but in disease of the upper and middle dorsal region support must be continued long after recovery, and supervision must be exercised until after the period of adolescence, if increase of the deformity is to be prevented.

Recurrence of Disease and Later Effects of Deformity.—The disease may recur after an interval of many years of apparent cure, and such recurrences are often accompanied by the formation of an abscess or by paralysis.

If recovery from Pott's disease has been complete, and if deformity has been prevented, the condition of the patient is to all intents normal; but if the course of the disease has been prolonged, and if the deformity is great, his condition is abnormal. He is unfitted for ordinary occu-

pations, and comparative comfort is assured only by constant care. Such individuals are likely to suffer from neuralgic pain about the weakened spine on overexertion or whenever the general condition is depressed from any cause. In such cases the use of some form of light corset adds to the comfort of the patient.

In certain instances pain localized in the lateral region of the trunk may be caused by compression of an intercostal nerve, or it may be due to compression of the tissues between the last rib and the pelvis. In several cases of this character reported by Goldthwait, resection of a portion of a rib at the seat of pain relieved the discomfort.

Secondary Deformities.—While the patient is under treatment for Pott's disease one should be on the alert to prevent other deformities that may follow the general weakness and restriction of normal functions. One of these is the *weak foot,* sometimes called weak ankle or flat-foot, and with it is often associated a moderate degree of knock-knee. This may be prevented by a shoe of proper shape, of which the heel and sole are thickened slightly on the inner side.

CHAPTER II.

NON-TUBERCULOUS AFFECTIONS OF THE SPINE.

SYPHILIS.

Syphilis, in the inherited or in the later stages of the acquired form, may affect the bones of the spine and cause local deformity and symptoms that cannot be distinguished from those of Pott's disease.

Fig. 86.—Vertical anterior-posterior section of the lumbar spine, showing deposit of gumma in the posterior part of the third and fourth vertebræ. (After Fournier.)

Diagnosis.—As compared with tuberculosis it is a rare disease of the spine.[1] Its manifestations are likely to be general in character, the deformity of the spine being but one of many evidences of disease.

Whitney and Baldwin[2] in 544 cases of syphilis found involvement of the spine in 41. There may be simple arthralgia in the primary stage; gumma in the tertiary stage or in the hereditary form, and eventually Charcot's disease.

If syphilis were limited to the spine and simulated the symptoms and the deformity of Pott's disease it would require the same local treatment. Specific remedies are indicated if one suspects the presence of syphilitic taint, even if the local disease appears to be tuberculous in character.

MALIGNANT DISEASE OF THE SPINE.

Malignant disease of the spine is a comparatively rare affection, particularly so in childhood. In early life sarcoma is more common than carcinoma, and it may affect the spine primarily. Carcinoma is almost always secondary to a primary tumor elsewhere, the spine becoming involved by metastasis or by contiguity. Schlesinger,[3] in 3720 cases of carcinoma, found secondary growths in the spine in 54, but Risley[4]

[1] Jasinski: Arch. f. Dermat. u. Syph., Bd. **23**, S. 400.
[2] Jour. Am. Med. Assn., December 4, 1915.
[3] Buckley: Jour. Nerv. and Ment. Dis., April, 1902.
[4] Boston Med. and Surg. Jour., April 22, 1915.

states that the percentage of vertebral metastasis from cancer of the breast is nearly 25 per cent.

According to Levine,[1] skeletal metastases occur in 66 per cent. of the cases of prostatic cancer and in 52.3 per cent. of cancer of the breast, but in only about 3 per cent of the cases of primary cancer in other situations. In a group of 67 patients with advanced cancer of the breast under treatment at the Montefiore Hospital 50 presented multiple skeletal metastatic lesions.[2]

The spine is more often invaded than are other bones, and the lumbar region is the seat of election.[3]

Diagnosis.—Malignant disease differs from tuberculosis of the spine in that its symptoms, when once they attract attention, are usually more severe; the pain is usually persistent, and it is not relieved by support or recumbency, as is that of Pott's disease. The constitutional symptoms are more marked and the steady progress of the disease toward a fatal termination is soon apparent. Locally, the angular deformity is slight, and it may be absent. In some instances the tumor may be palpated through the abdominal wall and not infrequently other bones are later involved.

Paralysis is a frequent and often an early symptom, usually affecting sensation as well as motion.

This description applies only to disease of the bone. Small intra- or extradural tumors may cause persistent pain, sometimes aggravated by movement without deformity. In such cases the diagnosis is eventually established by disturbances of sensation and paresis.

As has been stated, carcinoma is almost always secondary to disease elsewhere, and in many instances it may be present but unsuspected at the time of operation upon the primary tumor. The same is true also of metastases in other bones, which cause no symptoms and are only discovered at autopsy. In 20 per cent. of 150 fatal cases of cancer[4] the spine was involved and in about half the cases the diagnosis had been made before autopsy. Thus if after operation for the removal of carcinoma symptoms of disease of the spine appear, one should suspect this complication.

Sarcoma is usually a primary disease of the spine. Its local symptoms do not differ from those of carcinoma. One important diagnostic point in distinguishing it from tuberculosis is the sharp outline and limited extent of the destructive process shown in the roentgen-ray picture as contrasted with the irregular and indistinct borders of the tuberculous process. In this disease the intervertebral disk is practically always involved while metastatic osteoclasis is limited to the vertebral body.

Malignant disease of the spine is a fatal affection and the treatment can be but palliative. Roentgen-ray treatment may retard the progress of the disease and relieve pain.

[1] Med. Rec., April 5, 1919.
[2] Ginsburg: Jour. Am. Med. Assn., August, 1925.
[3] Moon: Am. Jour. Roentgenol., 1919, No. 12.
[4] Berrenberg-Gassler: Ztschr. f. Chir. u. Mechan. Orthop., January, 1910.

ACUTE OSTEOMYELITIS OF THE SPINE.

Infectious osteomyelitis of the spine is comparatively uncommon, 113 cases have been recorded by Wohlgemuth.[1] It is most common in the lumbar region. The bodies of the vertebræ are usually involved, exceptionally the arches or other parts.

Symptoms.—The symptoms are similar to those of acute infectious processes elsewhere, and are characterized by sudden onset, with pain, fever, and constitutional depression. There are local pain and sensitiveness about the spine and in many instances distention of the veins in the neighborhood caused by interference with the circulation by septic thrombosis. Abscess quickly forms, and paralysis from the rapid extension of the disease is a common complication. The symptoms due to pyogenic infection and to deep-seated abscess are often pyemic in character and necrosis of the affected vertebral bodies may result in the formation of large sequestra.

In 61 cases collected from literature,[2] the situation of the disease was as follows:

Cervical region	12
Thoracic region	15
Lumbar region	24
Sacral region	10

The cause of the infection in 15 of the 20 cases examined was the Staphylococcus aureus. In most cases the original focus of infection was a furuncle, inflammation about a nail, or small abscess.[3]

In 40 of 56 fatal cases[4] the patient died of general infection, pleuropneumonia, or meningitis before the diagnosis had been made and before abscess had appeared.

	Recovered.	Died.
Suboccipital region	1	4
Cervical	2	2
Dorsal	7	3
Lumbar	13	15
Sacral	0	6
	23	30

A more localized and more chronic, and of course far less dangerous, form of osteomyelitis may occur, and abscess may be the first sign of the disease. In all cases of this character, whether acute or chronic, other bones or joints or other tissues are often involved, and in many instances an infected wound or discharging ear, for example, may indicate the source of infection.

Osteomyelitis of the pelvic bones is not uncommon, the ilium being most often involved.

[1] Wohlgemuth: Arch. f. klin. Chir., 1923, **124**, 554.
[2] Hunt: Med. Rec., April 23, 1904.
[3] Volkmann: Deutsch. Ztschr. f. Chir., 1915, Bd. **132**, s. 145
[4] Grisel: Revue d'orthopédie, September, 1903.

Treatment.—The treatment consists in the immediate evacuation and drainage of the abscess, the removal of the necrosed bone if possible, and in supporting the spine during the subsequent stage of weakness.

ACTINOMYCOSIS OF THE SPINE.

Actinomycosis of this region is extremely uncommon, the spine having been involved secondarily in about 2 per cent. of the reported cases.[1] The diagnosis may be made by the microscopic examination of the discharge from the sinuses that almost always form when bone is affected. Blastomycosis is still more rare, and is always secondary to disease elsewhere.

INJURY OF THE SPINE.

Severe strains or fractures may simulate disease very closely, and in some instances, particularly of injury of the cervical region, the diagnosis, unless confirmed by roentgen-ray picture, is practically impossible until after treatment by support and fixation has been applied, when, as a rule, if disease is absent, the symptoms, even though of long standing, quickly subside.[2]

It may be noted that in rare instances an odontoid ossicle at the apex of the odontoid process may be present and may be mistaken for fracture.

The most common injury is a forward displacement of the atlas on the axis. A number of cases have been reported recently in which the displacement was caused by violent chiropractic manipulations.[3] (See Chapter XXIV.)

A *B*

FIG. 87.—*A*, roentgen-ray shadow of original examination, showing the forward dislocation of the atlas on the axis; *B*, tracing diagram. (Blaine.)

Fracture of the spine in the middle region may cause angular deformity, and in untreated cases symptoms of pain and weakness, similar to those of Pott's disease, may persist indefinitely.

[1] Parker: Jour. Bone and Joint Surg., October, 1923.
[2] Mixter and Osgood: Jour. Am. Orthop. Assn., February, 1910.
[3] Blaine: Jour. Am. Med. Assn., October 31, 1925.

Crushing of one or more of the vertebral bodies without displacement and without severe immediate symptoms, other than the slight deformity, may be the result of injury, especially falls from a height. These cases are not infrequent, the most common site being the dorso-lumbar junction. Of 383 fractures of the spine tabulated by Ménard, 250 were in this region, viz.: tenth dorsal, 32; eleventh dorsal, 37; twelfth dorsal, 80; first lumbar, 78; second lumbar, 23. In many instances an immediate diagnosis is not made and the local deformity, which may not attract attention until several weeks after the accident, combined with stiffness and weakness, may be mistaken for Pott's disease.

Rupture of spinal ligaments may be caused by forcible flexion of the spine. The resulting deformity and weakness resemble the symptoms caused by a crush of one of the vertebral bodies.[1] Fracture of a transverse or spinous process may cause local sensitiveness and pain on movements that induce tension at the seat of injury.

Fraas[2] has recorded 12 personal cases of fracture of transverse processes in the lumbar region.

Traumatic Spondylitis.[3]—Kümmell[4] has described a form of rarefying ostitis of the spine apparently caused by injury. It is characterized by symptoms of pain and weakness referred to the back, and by a pronounced rounded kyphosis of the dorsal region. Motor disturbances of the lower extremities are frequent. This is easily explained by the fact that in cases of this character fracture, disorganization of the disks, rupture of ligaments, hemorrhage beneath the longitudinal ligament, into the muscles or into the spinal canal, have been demonstrated at autopsy. Indirect injury, shock to the nervous apparatus and the like may cause complicating symptoms in addition.[5]

Kümmell's cases differ only in degree from those of injury that have been described, and it seems probable that in certain instances there may be slight fracture or other injury that under favoring conditions may cause persistent disability of the Kümmel type. In fact, in the neglected cases of injury of the spine the pain and weakness may persist indefinitely, and the deformity may increase. In certain instances there may be a secondary infection, tuberculous or otherwise, at the seat of injury, and in others the injury may be the predisposing or exciting cause of spondylitis deformans or of Charcot's disease, but such results are unusual.

Treatment.—In all such cases, and whenever weakness of the spine persists, and if motion causes pain, a support should be applied as in the treatment of Pott's disease. If possible, deformity if of recent origin should be corrected in suitable cases by gentle manipulation under

[1] Painter and Osgood: Boston Med. and Surg. Jour., January 2, 1902.

[2] Beitr. z. klin. Chir., 1919, vol. cxviii.

[3] In a total of 797 industrial injuries of the back there were 40 fractures of vertebral processes and 30 fractures of vertebral bodies. Fractures of the transverse process are usually multiple and may be caused by direct injury or muscular action. Herndon, Jour. Bone and Joint Surgery, April, 1927. For fractures of transverse processes, see Kennedy, Ann. Surg., April, 1927.

[4] Deutsch. med. Wchnschr., 1895, No. 11.

[5] Reuter: Arch. f. Orthop. u. Unfallchirurgie, 1904, B. 2, H. 2.

anesthesia. In others, by recumbency on the convex frame. Massage and graduated exercises are of value during the period of recovery. Clinical evidence indicates that repair is slow; support therefore should be continued for at least six months and for a much longer time if the injury is of the middle dorsal region where the tendency to postural deformity is so marked. In cases of this type bone grafting or fusion, to induce ankylosis at the point of weakness is often indicated as a means of shortening the period of disability.

INFECTIOUS DISEASES OF THE COVERINGS OR ARTICULATIONS OF THE SPINE.

The "Typhoid Spine." During the course of or during convalescence from typhoid fever, and occasionally after apparent recovery from the disease, symptoms of pain, weakness, and stiffness of the back may appear, sometimes induced by sudden strain or other injury, and usually localized in the dorsolumbar region. The cause is apparently a secondary infection of the fibrous coverings and articulations of the spine, similar to the more common but more severe forms of periostitis of the tibia or other bones, from the same cause. There is usually pain on motion, reflected along the nerves. In some instances this is extreme and there may be accompanying muscular "cramps" in the limbs, local muscular spasm, and pain on pressure over the affected vertebræ. The temperature is often above normal, with irregular and sometimes extreme fluctuations in severe cases.

In many instances a neurotic element is present, induced, doubtless, by the preceding disease. The complication is most common in young adults, males in an estimated proportion of 1 to 1800 cases of typhoid fever.[1]

In 6 of 68 cases tabulated by Wurtz[2] the patients were children, and several of this class have come under my observation.

Diagnosis.—The diagnosis is usually made clear by the history of the disease of which it is a complication.

Treatment.—The treatment should be symptomatic. During the active stage, if pain is severe, the patient should remain in the recumbent position, if necessary on the stretcher frame. Locally, the application of the Paquelin cautery is of service. As soon as is practicable a back brace or other support should be applied which should be worn until the symptoms have subsided. Complete recovery is the rule, the duration of the symptoms averaging about six months. Restriction of motion may persist accompanied by slight deformity in the more severe types of cases.

This description applied particularly to cases of a mild type described by Gibney[3] as typhoid spine. Disease of the spine complicating typhoid

[1] Gall: München. med. Wchnschr., April 13, 1915.
[2] Boston Med. and Surg. Jour., June 26, 1902. Rogers: Boston Med. and Surg., Jour., vol. 118, No. 10.
[3] Gibney: Tr. Am. Orthop. Assn., vol. 2.

fever was first described by Maisonneuve in 1835. Terrillon[1] classifies the lesions of typhoid infection of the spine as:

1. Simple periostitis.
2. Periostitis with subperiosteal abscess.
3. Periostitis with ostitis.[2]

In 36 per cent. of 53 cases investigated by Silver[3] local deformity indicated a destructive process.

Other Forms of Infectious Disease. Symptoms resembling those described may follow other forms of contagious disease, notably scarlatina, but, as a rule, they are much less persistent and less severe.

Billington[4] has reported 35 cases, following cerebrospinal meningitis, in 12 of which there were distinct arthritic changes. Holst[5] has recorded 50 cases complicating the same disease, in 44 of which the disease was confined to the lumbar region of the spine.

Gonococcal arthritis of the spine is not uncommon. Its symptoms and pathology resemble those of the typhoid spine. Anchylosis is, however, more common as a result than after other forms of infection; in fact, gonorrhea is apparently one of the more common causes of spondylitis deformans.

Treatment.—The treatment, aside from that of the exciting cause, is symptomatic. Local support is indicated in many instances.

Arthritis of the Suboccipital Region.—The articulations of the occipito-axoid region are sometimes affected by what appears to be a form of acute or subacute infectious or toxic arthritis similar in characteristics to acute rheumatism. It may follow tonsillitis, diphtheria, or other contagious disease. It may be distinguished from tuberculous disease by its acute onset and from acute torticollis by the fact that all motions are restricted.

Treatment.—The treatment consists in support preferably of the jury-mast type during the acute stage, followed by massage, manipulation, and exercise to overcome the subsequent stiffness.

Spondylitis Deformans.—Synonyms.—Osteoarthritis of the spine; spondylose rhizomélique; stiffness of the vertebral column.

Spondylitis deformans is a chronic progressive disease of the spine terminating in anchylosis and deformity.

Pathology. The disease is of the nature of a chronic inflammation affecting primarily the ligaments and the periosteal coverings of the spine, a form of ossifying periostitis which binds the vertebræ firmly to one another (Fig. 88). It may begin on the lateral or on the anterior aspect of the spine; it may be limited to a particular region, but in most instances it eventually involves the entire spine and often the articulations of the ribs as well. The intervertebral disks atrophy and the spine becomes anchylosed. In some instances the margins of the

[1] Progrès Méd., April 12, 1884.

[2] In 533 typhoid bone lesions the skull was involved in 22 cases, the spine in 110, the thorax in 142, the upper extremities in 57, lower extremities in 83, and multiple bones were involved in 19. Murphy: Surg., Gynec. and Obst., August, 1916.

[3] Silver: Am. Jour. Orthop. Surg., vol. **5**, 194.

[4] Jour. Am. Med. Assn., August 30, 1924. [5] Ztschr. f. Orthp. Chir., 1924, **46**, 3.

MEDICAL LIBRARY

cartilages proliferate and become ossified in a manner characteristic of osteoarthritis of the joints. It is a very ancient disease of wide distribution being present in a large percentage of predynastic Egyptian remains as well as in the spines of the ancestors of the American Indian. It is common in horses who have been overworked before full development and causes a peculiar straddling gait.[1]

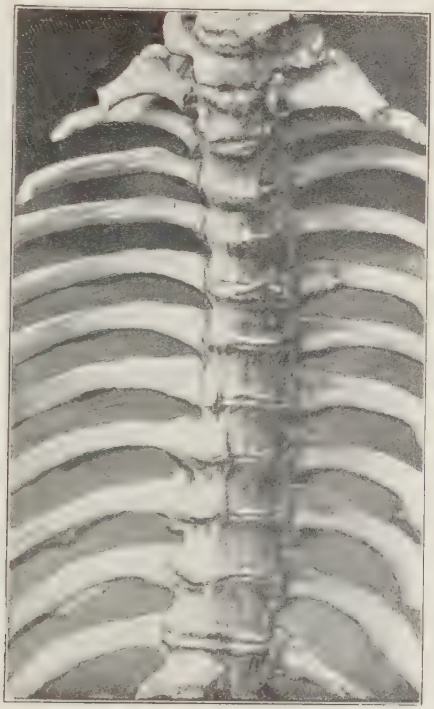

FIG. 88.—Spondylitis deformans (osteoarthritis). (Goldthwait.)

Under the general term of spondylitis deformans are included, clinically, several varieties of disease, for example:

1. The affection of the spine may be simply one of the manifestations of chronic polyarthritis—"rheumatoid arthritis" of the spine.

2. The spine may be involved together with one or more of the adjacent joints which present the characteristic symptoms of the so-called hypertrophic form of arthritis deformans osteoarthritis of the spine. This form has been designated by Marie spondylose rhizomélique (from *spondylos*, spine; *rhizo*, root; and *melos*, extremity), signifying a disease of the spine together with the adjoining "root" joints.[2]

3. The disease may be limited to the spine, and in such cases it appears to be clinically distinct from general arthritis of the atrophic

[1] Lovett and Watson (4th ed.).

[2] Marie: Rev. de méd., 1898, xviii.

or hypertrophic type. It may follow acute polyarthritis, it may be induced apparently by gonorrhea or by other forms of infection, or by injury—"traumatic spondylitis." It may begin acutely, or it may be chronic in character and progress slowly.[1] It may be limited to a particular section of the spine, although, as a rule, the other regions are progressively involved.

This form of limited spondylitis is more often seen in young adults from twenty to forty years of age, and in at least 80 per cent. of the cases the patients are males. Finally, in a mild and localized form,

Fig. 89.—Spondylitis deformans, showing the characteristic curvature of the spine. Age of the patient, twenty-three years. Duration of the disease three years; cause unknown. No other joints involved.

it is very common among middle-aged laborers. There are, it may be noted, two main types of disease. One which involves the joints of the spine primarily, causing ankylosis, but in which the vertebral bodies and intervertebral fibrocartilages are but slightly affected. The other form begins in the anterior or lateral ligaments and causes the lipping characteristic of arthritis deformans. The first type is common in young subjects and other joints are often involved. The second is common in more advanced life, particularly among laborers.

[1] Bechterew: Neurol. Centralbl., ii, 426; Senator: Berl. klin. Wchnschr., November 20, 1897.

Symptoms.—In the ordinary cases there is usually an acute onset from which the patient dates the beginning of his trouble, often so-called lumbago, followed by a gradually increasing stiffness of the spine and accompanying deformity. The patient complains of stiffness, weakness, pain in the loins, and of pain radiating forward along the ribs; sometimes of weakness in the limbs, headache, nervousness, and the like—symptoms that may be explained in part by the inflammatory process and by implication of the nerve roots, and in part by an accompanying

FIG. 90.—Osteoarthritis of the cervical region with anchylosis at the occipito-axoid articulations.

neurasthenia. In rare instances the caliber of the spinal canal may be diminished by a growth of inflammatory bone-forming tissue which causes symptoms of pressure on the cord. Eight cases have been reported from the Mayo Clinic by Parker and Adson,[1] and in 6 laminectomy was performed with relief of the symptoms. The direct symptoms are increased by jars, which are exaggerated by the inelasticity of the spine. The disease is usually progressive, and terminates

[1] Jour. Am. Med. Assn., January 3, 1924.

finally in complete rigidity of the spine, which is bent into a long kyphosis, most marked in the upper dorsal region, the lumbar lordosis being obliterated in many instances (Fig. 91).

The straightening of the spine in the middle and lower region exaggerates the forward thrust of the neck, and in some instances the patients complain of a disturbance of equilibrium, especially of a tendency to fall forward.

FIG. 91.—Spondylitis deformans illustrating the characteristic deformity. Age of the patient, thirty years. Spine rigid, with the exception of the occipito-axoid articulation. Duration two years; cause unknown. No joints involved.

FIG. 92.—Spondylitis deformans in a child.

When the disease is limited to the spine or to the spine and one or more of the larger joints the occipito-axoid articulations are not usually involved; but in the general form of the disease —"rheumatoid arthritis"—they are often primarily affected.

The types of the disease may be illustrated by a brief description of cases recently under observation.

TYPE I. *"Rheumatoid Arthritis" of the Spine.*—In this case, that of a boy ten years of age, there was characteristic general chronic

(atrophic) arthritis that involved nearly every joint of the body. The entire spine, even including the occipito-axoid joints, was rigid and the head was fixed in an attitude of extreme torticollis.

TYPE II. "*Osteoarthritis of the Spine*" ("spondylose rhizomélique").—A man aged forty-six years, after repeated attacks of so-called rheumatism involving the larger joints, gradually became disabled because of pain and stiffness of the back and because of his inability to stand erect. In this case there was complete anchylosis of the spine, except of the small joints of the cervical region, and in addition the right thigh was flexed upon the body at such an angle that

FIG. 93.—Anchylosing disease of the spine following gonorrhea causing lateral distortion of the pelvis.

the patient could walk only with an exaggerated stoop. The joints of the feet were slightly involved also. No cause other than exposure to cold and dampness could be assigned. The symptoms were of two years' duration, periods of comfort alternating with disabling attacks of "rheumatism."

TYPE III. *Spondylitis Deformans.*—The spine of this patient, a man aged forty-six years, was absolutely anchylosed in the characteristic position. The occipito-axoid joints were not involved. Fourteen years before he had suffered from a severe and prolonged attack of "inflammatory rheumatism," affecting nearly every joint, but not the

spine, and during a succeeding period of nine years he had been disabled several times from the same cause. Each illness was coincident with gonorrhea. Five years before examination the "rheumatism" had involved the spine, and since then he had suffered from persistent "lumbago." Gradually the stiffness of the spine had increased, but during this time he had been free from gonorrhea, and from rheumatism as well. The joints were normal in appearance and function. This patient suffers principally from nervousness and irritability; he is easily startled; he feels as if his forehead was clasped by a tight band. His direct symptoms are pain in the loins and pain radiating under the shoulder-blades, increased by walking or by jars. His equilibrium is disturbed by the forward projection of the head and by the obliteration of the normal lordosis, so that he feels himself constantly inclined to fall forward, whether he is sitting or standing.

Type IV. In another case very similar to this, in a man, aged thirty years, the spine had become rigid in a few months. The patient ascribed the disease to sleeping out of doors. There was in this case coincident tuberculous disease of the lungs. And in this instance the cause of the deformity may have been superficial tuberculous disease or so-called tuberculous rheumatism.

Type V. A man, aged sixty-two years, presenting the characteristic deformity and symptoms of the subacute type, gave the following account of the affection: Fifteen years before he had suffered from "chronic lumbago." The pain and stiffness, at first limited to the lower region of the spine, had, with intervening periods of remission, gradually ascended, and at the time of examination the cervical region was the seat of the more active process. He had been treated by internal remedies, by baths, and by change of climate, without avail. He knew he had the "old man's stoop," but he was surprised to learn that the cause of his symptoms was a disease of the spine. The spine was rigid, although not anchylosed, as evidenced by the discomfort on changing from one position to another. The occipito-axoid articulations and the other joints were free from disease.

This subacute form of the affection is very common, and, as in this instance, the patients are usually treated for rheumatism, muscular or otherwise, for many years before the true diagnosis is made.

Willis,[1] from an examination of 625 spines, concludes that changes of the arthritic type are practically universal after forty-five years of age, particularly in the lumbar region. Such changes are more marked in the laboring class, and explain the disabling effects of severe strains upon a spine which is relatively inelastic.

Treatment.—The general treatment, dietetic, climatic and the like, should include if possible the removal of the exciting causes, persistent gonorrhea and its sequelæ in the younger subjects being apparently the most common of these. The local treatment is symptomatic. Massage of the muscles, hot baths and the like may add to the comfort of the patient, but violent exercise or passive movements of the spine are

[1] Jour. Bone and Joint Surg., April, 1924.

harmful. Support is always indicated during the progressive stage of the affection, and it is the only efficient remedy. The support may be in the form of a light brace or jacket. It is particularly efficacious when the disease is limited to the lower and middle regions of the spine. In such cases, under efficient protection, the muscular spasm subsides and motion returns in some degree. The patient learns by experience what exercises or postures increase the discomfort, and these should be avoided if possible. The application of a cautery is often of service, and self-suspension at intervals may relieve the dragging sensation in the muscles. Rubber heels are useful in lessening the jar. Even in progressive cases one may hope to preserve the lumbar lordosis, and thus to lessen the general effect of the deformity when the spine becomes rigid. In certain instances in which the anchylosis is not established, particularly in young subjects, force may be employed with caution, to improve the contour of the spine, particularly with the aim of reëstablishing the lumbar lordosis, and thus enabling the patient to stand erect. Prolonged rest on the convex stretched frame is the most effective treatment both for the discomfort and for the deformity. As has been stated, in some cases the disease remains localized, but ordinarily it extends along the spine. When a part of the spine becomes firmly anchylosed the local discomfort lessens or ceases, and is transferred to the part where the process is still advancing. In certain cases, therefore, spinal fusion may be considered as a means of hastening fixation and preventing further deformity.

FIG. 94.—Extreme posterior curvature of the spine in adolescence, showing retraction of the abdomen. This deformity may be mistaken for spondylitis deformans.

Kyphosis of Adolescents.—A form of extreme kyphosis accompanied by stiffness and discomfort is sometimes seen. It appears to be a static deformity induced by overwork in rapidly growing adolescents, which finally becomes fixed by accommodative changes in the bones and neighboring tissues. It can hardly be classified with spondylitis deformans, although there may be some difficulty in distinguishing between the two (Fig. 94). In favorable cases partial rectification of the deformity may be partially corrected by recumbency on the convex frame and the improved contour may be assured by a fusion operation. The types illustrated in Figs. 89 and 94 are of this class. (See Vertebral Epiphysitis.)

THE RHACHITIC SPINE.

The rhachitic spine has been described in the consideration of the differential diagnosis of Pott's disease. It usually develops during the first or second year of life, in children who sit the greater part of the time; it is, in fact, simply an exaggeration of the contour that is normal in the sitting posture. The typical rhachitic kyphosis is thus a rounded projection of the lower region of the spine, which is more or less rigid according to its duration. If the deformity is extreme there may be a compensatory backward inclination of the head, which may be accompanied by contraction of the posterior group of muscles, "cervical opisthotonos."

FIG. 95.—Rhachitic kyphosis.

Treatment.—Aside from the constitutional treatment of the rhachitic condition, and from the measures that should be employed to improve the nutrition of the muscles in general, the indications are to overcome the deformity and the limitation of motion of the spine; to support it, if necessary, during the stage of weakness; and to prevent, as far as possible, the postures that favor the distortion.

The correction of the deformity may be accomplished by massage and by direct manipulation of the spine. The child lying face downward, on a table; one hand is placed on the projection, and with the other the legs are raised to throw the spine into a position of over-

MEDICAL LIBRARY HOSPITAL

extension. This stretching is performed slowly and carefully over and over again at morning and night, and the manipulation is followed by thorough massage of the muscles. If the deformity is marked and if the general rhachitic process is still active, the recumbent posture on a light frame, in an attitude of overextension may be indicated as described in the treatment of Pott's disease.

For older subjects some form of light back brace may be sufficient in connection with the massage, and systematic correction of the deformity.

The Natural Cure.—The deformity of the rhachitic spine is to a certain extent corrected when the erect posture is assumed, by the inclination of the pelvis and accompanying lordosis. This natural cure is, however, often rather a distribution of deformity than a cure, for the upper part of the projection may remain as an exaggeration of the normal dorsal kyphosis balanced by an exaggerated lordosis, "*the rhachitic attitude.*" In other instances the persistence of the lumbar kyphosis may induce a compensatory flattening of the normal dorsal kyphosis. Thus, rhachitis may cause the so-called *flat-back* as well. Both deformities predispose to the later development of scoliosis.

Scoliosis may be a direct effect of rhachitis, a deformity far more serious than the anteroposterior curvature, with which it is occasionally combined. Its treatment is considered in Chapter III.

Osteitis Deformans.—Osteitis deformans is a general disease characterized by hypertrophy and softening of the bones. The deformity of the spine is similar to that of spondylitis deformans, but the rigidity is not as marked, and the discomfort is far less than in this affection.

Tabetic Deformity of the Spine.—In rare instances deformity of the spine, either posterior or lateral, appears as a complication of locomotor ataxia. These diseases are described elsewhere.

Spondylolisthesis.—Spondylolisthesis is a deformity in which the body of one of the lower lumbar vertebræ, usually the fifth, is displaced forward and downward (Fig. 99). The relative weakness of the ligamentous support, the inclination of the upper surface of the sacrum and the mobility of the articulation favor displacement at this point. According to von Lackum,[1] the strain upon the lumbo-sacral articulation is proportionate to the angle of inclination of the superior surface of the sacrum, which is increased by an exaggerated lordosis.

SHEARING STRAIN IN PERCENTAGE OF SUPERIMPOSED WEIGHT. (VON LACKUM.)

If angle is	Pressure tending to slide the superimposed weight
25	0.42
35	0.57
45	0.71
50	0.77
55	0.82
60	0.86
65	0.91
70	0.94
75	0.97
80	0.98

[1] Jour. Am. Med. Assn., April 15, 1924.

In certain instances the spinous process may remain in its normal position, while the laminæ become elongated or separated from the

Fig. 96.—Spondylolisthesis.

Fig. 97.—Small pelvis of Prague (median section), illustrating slight forward displacement of the body of the fifth lumbar vertebra. (Neugebauer.)

body (Fig. 97). The condition was first described by Killian in 1854, and it was thoroughly investigated by Neugebauer in 1890.

The causes are congenital malformation, injury, overstrain, or disease of the lumbo-sacral articulation. Lane states that slighter degrees of the deformity are common among laborers. The trunk is displaced forward and downward in its relation to the pelvis. The sacrum rotates backward and the inclination of the pelvis is lessened or lost. The trunk is shortened and the space between the ribs and the iliac crests is correspondingly diminished. In some instances the contour of the back is flat, although the trunk is inclined backward; in others there is a sharp forward inclination above the projecting sacrum (Fig. 98). Forward bending of the spine is much restricted.

The typical deformity is most often seen in women, and it first attracted attention because of its influence on parturition. In males it is usually the result of injury. The characteristic symptoms are weakness and discomfort in the lumbar region and pain about the distribution of the lumbar and sciatic nerves. In advanced cases the gait is awkward and it may be almost ataxic in character. Several cases of transient or persistent paralysis have been recorded, caused by pressure on the cord.[1] Slight displacement following injury may involve any one of the lumbar vertebræ and cause persistent symptoms of pain, weakness and limited motion. The important physical sign is a slight prominence of a spinous process with a corresponding depression immediately above it, indicating forward displacement, usually sensitive to pressure.

FIG. 98. — Spondylolisthesis in an adolescent, induced apparently by overwork. Symptoms: inability to bend forward and pain on fatigue, radiating down back of the thighs.

Treatment.—In cases of the ordinary type, and particularly if the result of injury, a strong corset or back brace of the Knight or Taylor type is indicated. For the mild congenital cases seen in young subjects exercise to prevent the limitation of flexion and the avoidance of postures that favor deformity are usually efficacious in checking the progress of the distortion and in relieving the weakness and awkwardness that it induces.[2] If the deformity is progressive, operative fixation by fusion or bone graft is the most effective remedy. Hibbs[3] is an advocate of operative fixation in cases in which the lumbo-sacral angle

[1] Ryerson: Jour. Am. Med. Assn., January 2, 1915.
[2] Darling: Am. Jour. Roent., January, 1918.
[3] Hibbs and Swift: Surg., Gynec. and Obst., May, 1929.

is notably increased also in cases of sacralization of the fifth lumbar vertebra as the most effective means of relieving immediate discomfort and future disability.

He reports on 150 operations of this type performed 1914–1927: 79 were for the acute lumbo-sacral angle, 32 for spondylolisthesis and 32 for sacralization of the fifth lumbar vertebra. There were no operation mishaps. Fusion was satisfactory in all but 8 cases. 72.3 per cent. of the patients were entirely relieved, 14 per cent. improved, 12.7 per cent. not improved. The period of recumbency was six to eight weeks and a back brace was employed for as long a period as the symptoms

FIG. 99.—Spondylolisthesis. Showing the outline of the body of the fifth lumbar vertebra projecting into the pelvis; an absolutely diagnostic sign.

indicated. It is stated that in no case was there evidence of sacro-iliac displacement. It may be suggested that a treatment involving a long period of recumbency supplemented by support might be effective in the event of a mistaken diagnosis for instability at either articulation.

PAIN IN THE BACK.

Discomfort in the lumbar region of the character of fatigue and even actual pain are sometimes caused by disease or by displacements of the pelvic or abdominal organs. Pain in this region is also a common symptom among overworked women. It is also induced by weak feet

or by any disturbance of the balance of the spine. It is often present if the lumbar lordosis is pronounced, particularly if it is exaggerated as a compensatory deformity for dorsal Pott's disease, or for flexion of the thigh after hip disease.

Cochrane[1] has tabulated the apparent cause of pain in the back in his own practice as follows: Traumatic, 60 per cent.; secondary to posture, 10 per cent.; lumbo-sacral, 12 per cent.; sacro-iliac, 18 per cent.

Lovett[2] analyzed 83 cases of "backache," 54 in females, 29 in males. In 41 the cause seemed to be an improper inclination of the spine, usually a foward droop of the trunk or lateral inclination due to shortening of one limb. In 15 the feet were weak, 35 cases were the result of injury or arthritis. Six were caused by pelvic disorders; 5 by prominent abdomen and 1 was an acute lumbago. Conn[3] states that in 156 cases from an industrial hospital the pain was referred to the region below the tenth dorsal vertebra in 92 per cent. (See Neurotic Spine.)

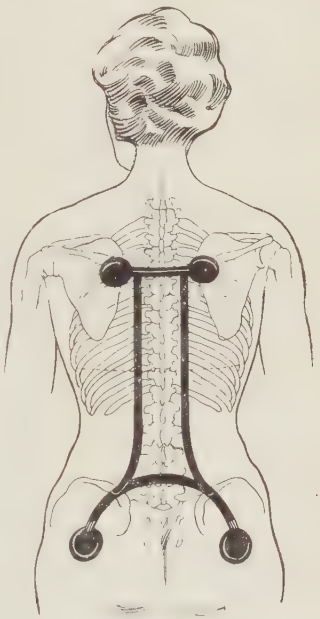

Fig. 100.—Outline of steels to be fitted to a woman's corset. (Porter and Lewin.)

As a result of strain or other injury symptoms of pain and weakness in the lumbar region, increased by sudden motions or overexertion, may be persistent and disabling. Such cases are often classed as chronic lumbago, but it is probable that there is in many instances a distinct injury of the ligaments or deep muscles of the spine, fracture of a transverse process or strain or displacement, at the sacro-iliac articulation, aggravated, it may be in certain cases, by rheumatism or other general affection of like character. Léri[4] has recently described cases of what he calls chronic lumbar rheumatism among soldiers, apparently a mild form of local spondylitis deformans.

Ludloff[5] has called attention to the fact that persistent pain about the sacrum following falls or other injuries may be explained in many instances by a slight degree of traumatic spondylolisthesis. Hunt[6] has noted cases characterized by intermittent pain and cramps in the lumbar muscles, induced by muscular exertion, which he classifies as ischemic lumbago.

[1] Edinburgh Med. Jour., April, 1927.
[2] Jour. Am. Med. Assn., May 23, 1914.
[3] Ibid., 1922, p. 1210.
[4] Presse Méd., February 28, 1918.
[5] Fortsch. auf d. Gebiete der Roentgenstrahlen, Bd. **9**, Heft 3
[6] Jour. Am. Med. Assn., July 28, 1914.

Roentgen-ray examination, now a routine in all cases of this class, has shown that irregularities at the lumbo-sacral junction are very common, for example, Aimes and Jaques,[1] in 63 cases of persistent lumbar pain, noted in 38 instances sacralization, a term implying complete or partial junction of the fifth lumbar vertebra with the sacrum, a condition found in from 3 to 4 per cent. of cases investigated by roentgen-ray examination or at autopsy. This is usually accompanied by a long transverse process on one or both sides which may articulate with the ilium or impinge upon it, causing local discomfort in certain movements or attitudes.

O'Reilly[2] states that irregularity of the transverse processes is the rule—that in but 53 of 199 cases were they alike on the two sides, there being three general types: Straight, bulbous at the ends and fan-shaped.

Lumbago.—With advancing years there is an increase of the fibrous element in muscles and a corresponding loss of elasticity and therefore greater liability to strain. The lumbar muscles because of their size and the freedom of movement of his region of the trunk are particularly susceptible, hence the popular name. Lumbago often begins with a sudden crick in the back or with general sensitiveness and pain on movement. It is a common ailment of laborers who are exposed to sudden changes in temperature and as is well known errors in diet and defective metabolism are important predisposing causes. In cases of this type vigorous catharsis is the popular and established remedy.

Treatment.—The treatment must be primarily directed to the condition of which the pain is a symptom, implying a careful consideration of the general physical condition of the patient with reference to the defective metabolism or infective foci as predisposing or complicating factors.

If motion causes pain and if the symptoms are persistent, as in the lumbago type of cases, whether due to injury or to inflammation of the fibrous or muscular tissues, support is indicated; in mild cases a stiffened corset will serve the purpose, in others a Knight brace or plaster corset may be required. During the more acute stage the application of the cautery and the support of intersecting strips of adhesive plaster, covering a wide area, even encircling the pelvis, will often relieve the pain. Later, massage, electricity and the like are of service.

In milder cases, in which the symptoms may be dependent on a general visceroptosis an abdominal belt will often afford great relief.

In those unusual cases in which localized pain is induced by certain movements, and which might be explained by friction of an elongated transverse process, as shown in a roentgen-ray picture, operative removal may be indicated.

[1] Progrès méd., August 13, 1921.
[2] Am. Jour. Orthop. Surg., May, 1920.

SCIATIC SCOLIOSIS.

Chronic sciatica in the sense of pain referred to the distribution of the sciatic nerve often induces a change in the attitude and contour of the spine that may become a permanent deformity if its cause persists. As a rule the patient habitually inclines the body away from the painful part in order to relieve it from weight, bends the body slightly forward and abducts the limb to relax the tension on the sensitive nerve or plexus of nerves. Thus the pelvis on the affected side projects, there is a lateral lumbar convexity toward the opposite side, and often the normal lumbar lordosis is lessened or lost, so that the final result may be a persistent lateral curvature, together with a change in the anterior-posterior contour of the spine. If the deformity persists second compensatory curves may appear (Fig. 101). If the sciatica is the result of a widespread neuritis, muscular weakness and muscular spasm may cause variations in the typical attitude, the muscles of one side being persistently contracted.

Fig. 101.—Typical sciatic scoliosis.

It must be borne in mind that disease of the lumbar spine, particularly at the lumbo-sacral articulation, or injury or disease at the sacro-iliac junction, may induce similar distortion of the spine accompanied by pain in the limbs. Also that injury or disease of the pelvic articulations or of the muscles or the adjacent organs or parts may induce sciatica; thus the cause of pain should be carefully sought for.

Aside from the direct treatment of sciatica, support for the spine, preferably a light corset, or brace, so arranged as to assure the lumbar lordosis and to exert firm pressure about the pelvis, is always indicated if movements of the trunk aggravates the pain. If the deformity is resistant it may be corrected

gradually, by repeated applications of a plaster jacket, or, more effectively, under anesthesia, in which case the deformity should be overcorrected, the lumbar lordosis restored and the limb and trunk fixed by a long plaster spica as described under Sacro-iliac Strain. This is the most effective remedy and is practically always indicated in chronic cases if the distortion of the spine is habitual and resistant. Sciatic neuritis as a cause of the so-called sciatic scoliosis is relatively rare. It may be differentiated from the reflected pain usually

Fig. 102

Fig. 103

Figs. 102 and 103 illustrate extreme distortion of the sciatic type.

classed as sciatica by loss of muscular power, reduction of reflex activity, alteration of sensory perception and by sensitiveness to pressure on the nerve trunk. *Caudal neuritis* may cause pain in the thighs and weakness of the muscles resembling somewhat sciatica, or sacro-iliac strain.

Neuritis in other regions of the spine may cause symptoms of reflected pain and local sensitiveness. These symptoms are increased by motion, and a local deformity, similar in character to that due to sciatica, may be present.

Gluteal Myositis.—Roberts has described cases in which symptoms somewhat similar to sciatica are complicated by sensitiveness to pressure in the gluteal region. In cases that have resisted the usual treatment by deep massage and the like, the pain has been relieved by a subperiosteal stripping of the sensitive muscles from the ilium through an incision about the superior and posterior border of the ilium.

SACRO-ILIAC DISEASE.

Tuberculous disease of the sacro-iliac articulation as compared to disease of the spine or hip-joint is a rare affection and extremely so in childhood.

Symptoms.—The symptoms are pain, weakness, limp, and change in attitude. The pain is referred to the side of the pelvis or radiates over the buttock or thigh. It is increased by jars, by turning the body suddenly, sometimes by coughing or laughing; and a peculiar feeling of insecurity and weakness is sometimes complained of. As a rule the body is inclined toward the sound side; thus the pelvis is lowered on the affected side and the limb seems longer than its fellow. In the early stage of the disease there is no deformity of the limb, but if a pelvic abscess forms, the thigh may become flexed. Locally, there may be sensitiveness to pressure over the articulation, or from within by rectal examination, and swelling in the neighborhood of the disease, although this is usually a late symptom. Pain is induced by forward bending of the body or by flexing the extended limb on the trunk, movements that make the hamstring muscles tense, by lateral pressure on the pelvis or by other manipulation that moves the articulation.

Abscess finally forms in the majority of cases. It may be extrapelvic or intrapelvic. The intrapelvic abscess may present above the crest of the ilium, or the pus may pass through the sciatic notch, or appear in the ischiorectal fossa, or break into the rectum.

Diagnosis.—Sacro-iliac disease may be mistaken for sciatic scoliosis or for disease of the *hip* or *spine*. The freedom of motion and the absence of muscular spasm when the pelvis is fixed, if the examination is carefully conducted, should exclude the former. And although the movements of the spine may be restrained by muscular spasm it is not in the same degree as when the vertebræ are diseased. The pain on lateral pressure, which is described as the most characteristic symptom, may sometimes be simulated closely by primary acetabular disease. The attitude is similar to that of sciatica, but the symptoms of local sensitiveness to jars and to manipulation are much more marked.

Prognosis.—According to the statistics the prognosis is very unfavorable, probably because the majority of the reported cases were in adults complicated by coincident disease of the lungs and by infected and burrowing abscesses, which constitute the chief danger of this form of tuberculous disease.

Treatment.—The local treatment consists in protecting the diseased parts from injury. This in painful cases requires complete rest of the

individual. Local support may be assured by a double Thomas hip splint or spica plaster including the body and both limbs. In milder cases a back brace, with a wide pelvic band so arranged that firm pressure may be made about the pelvis, supplemented by crutches may permit ambulation.

FIG. 104.—Deformity caused by persistent sciatica of the right side. This attitude is similar to that symptomatic of sacro-iliac disease or weakness.

FIG. 105.—Sacro-iliac disease in a child, showing the extrapelvic abscess above the diseased articulation.

When infected abscess is present radical treatment is usually indicated. The articulation should be freely exposed and the diseased bone should be entirely removed if possible. The incision should follow the posterior border of the ilium to the third tubercle of the sacrum. The tissues are reflected forward subperiosteally, and a

section of bone from the posterior wing of the ilium of sufficient width to completely expose the joint is resected. The diseased tissues are then thoroughly removed and the wound is packed with gauze.[1]

Smith-Peterson, after exposing the articulation by the same method, removes an oblong section of bone over the articulation instead of cutting away the wing of the ilium, as described elsewhere.

Intrapelvic abscess should be drained through a direct communication, if possible, in order to check the tendency toward burrowing. Disease of the sacro-iliac joint may be secondary to that at the lumbosacral articulation or it may be involved in other acute or chronic processes. Twenty-seven cases of osteomyelitis of the sacrum have been reported with 20 deaths.[2]



FIG. 106.—Sacro-iliac resection. On the left, cutaneous incision is shown; on the right, the line of partial removal of the ilium. (Picqué.)

INJURY OR WEAKNESS OF THE SACRO-ILIAC ARTICULATION.

Symptoms similar to those of sacro-iliac disease may be caused by falls on the buttock or pelvis or by strains. In such cases there may be an actual injury or displacement at the articulation. This condition was described by Lee, in 1893,[3] and it is now recognized as of comparatively frequent occurrence. The sacro-iliac articulations are two joints possessing a slight movement backward and forward on a horizontal plane. The forward inclination of the sacrum is about 25 degrees. If the lumbar lordosis is lessened the sacrum becomes more perpendicular, a position in which the ligaments are relaxed. When the pelvic inclination is diminished the spinal muscles work at a disadvantage and the patient is inclined to stand with the knees flexed.

[1] Picqué: Bull. Soc. de Chir., Paris, 1909, p. 35.
[2] Gaudier and Betain: Rev. de chir., vol. 31, No. 8.
[3] Tr. Am. Orthop. Assn., vol. 2.

Goldthwait, to whom we are indebted for the practical development of the subject, has called particular attention to relaxation of the pelvic articulations caused by malposition of the sacrum —which rotating from its normal forward inclination to a more perpendicular attitude no longer serves its proper function as a wedge to hold the pelvic ligaments in proper tension. This condition is favored by pregnancy and consequent relaxation of the pelvic articulations; by long confinement to bed for illness or other cause when the lumbar region, being unsupported, loses its forward inclination. Thus, it may be assumed that a lessening of the lumbar lordosis is not only a direct cause of discomfort but that it predisposes to weakness of the sacro-iliac articulation. Under favoring conditions even slight injury, often a strain at golf or tennis, may be followed by disabling symptoms resembling in some degree those of sacro-iliac disease, local discomfort in the neighborhood of the articulation on pressure, either direct or through the abdominal wall,[1] and pain radiating along the distribution of the sciatic plexus. Pain referred to the articulation is usually induced by forward flexion of the body or by flexing the extended limb on the trunk (Kernig sign). Both movements are restricted, for in this neighborhood are attached the erector spinæ muscles above and the gluteal and hamstring group below.

Roentgen-ray pictures are of comparatively little value in diagnosis and an actual laxity of the articulation can rarely be demonstrated in except cases incidental to pregnancy. At the present time nearly all cases of sciatica or pain in the gluteal or lumbar region are popularly ascribed to weakness or injury of the sacro-iliac joint. The slight change in the relation of the sacrum to the nerves lying in apposition to it being, it is assumed, the exciting cause. There are several points of difference between the symptoms due to weakness or injury at the sacro-iliac joint and similar affections at the lumbo-sacral articulation. In the former the patient cannot usually lie with comfort on the affected side. There may be pain on pressure over the articulation or at the sciatic notch, or on the posterior-superior spine. There may be pain referred to the iliac crest and there is often lateral inclination of the trunk. When the patient sits the movements of the lumbar spine are free and painless. When the lumbo-sacral joint is involved pain is referred to both limbs. All the movements of the spine are restricted and extension of the thigh causes as much pain as flexion.

According to Smith-Peterson, local pain in the region of the inferior sacro-iliac ligaments and sacro-sciatic notch was present in all of his cases, pain radiating to the posterior aspect of the thigh in 89 per cent. and to the posterior aspect of the leg in 87 per cent.

Fortunately, an exact diagnosis is not essential, since restraint is indicated whenever movement aggravates the symptoms.

The adhesive plaster strapping in broad encircling bands about the pelvis and lumbar region, drawn as tight as possible, is a very effective

[1] Baer: Johns Hopkins Hosp. Bull., May, 1917.

temporary support. Later it may be replaced with a firm, wide "surcingle" about the pelvis, held in place by perineal bands. As a rule, however, a light spinal brace (Fig. 192) or stiffened corset with a pelvic band designed to restore the normal lordosis, to restrain the movement of the lumbar spine, and to hold the pelvis firmly, is indicated.

FIG. 107.—Fracture of the pelvis; separation of the sacro-iliac articulation; impingement of the transverse process on the ilium.

If actual displacement is suspected, or if normal motion of the spine or limb is limited and painful, correction under anesthesia is indicated. The patient lying upon the back, the pelvis is fixed by an attendant, and the extended limb is then gradually flexed upon the trunk until all resistance has been overcome, the aim being by tension on the hamstrings to push the pelvis backward on the sacrum. A plaster spica is

then applied to hold the limb extended and the lumbar spine in normal lordosis. This is retained for two or more weeks and is then replaced by a spinal brace or corset. In more recent cases, and in those of a milder type, graduated stretching without anesthesia in the manner described may be effective. Or the patient, lying prone, downward pressure on the posterior iliac border on the affected side may, in some instances, relieve the discomfort.

FIG. 108.—The Smith-Peterson operation. Incision along posterior two-thirds of the iliac crest, curving around the posterior-superior spine, then running parallel with the fibers of the gluteus maximus for a distance of 2 to 3 inches.

As persistent sciatic pain may be caused by perineuritis and adhesions, forcible stretching in the manner described may be effective, and a number of cases have been reported in which separation of the adhesions from the main trunk by open dissection has given immediate relief.

Cases have been reported in which the friction of an elongated or displaced transverse process on the ilium has induced symptoms of sacro-iliac displacement or lumbago, which have been relieved by its removal.

In cases of actual displacement due to laxity of ligaments, or in those cases in which persistent pain and local sensitiveness and the roentgen picture would indicate arthritis or in which the symptoms persist in spite of conservative treatment, the operation of arthrodesis or bone implantation may be indicated.

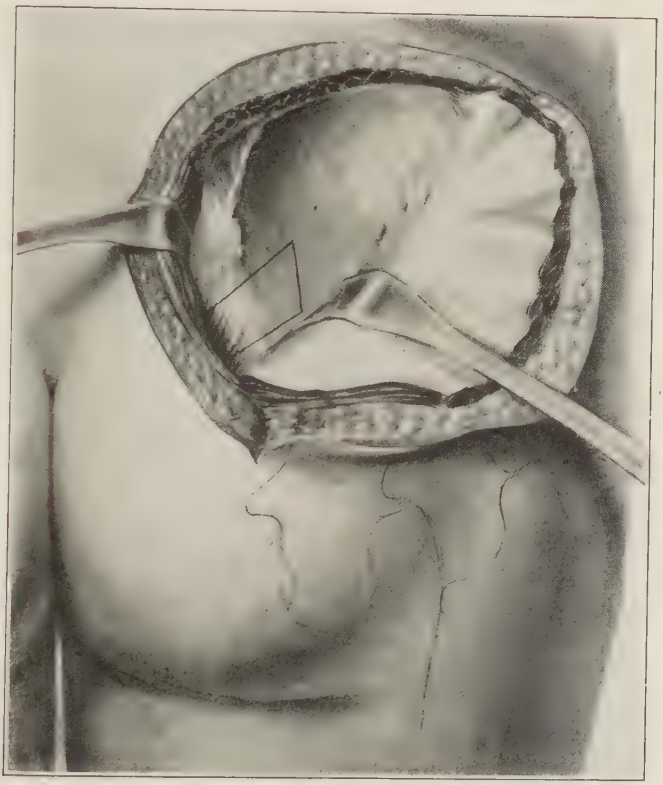

FIG. 109. -Flap outlined by incision, as described under Fig. 110, is reflected subperiosteally, exposing the lateral surface of the ilium. If the sacro-iliac joint is projected on the lateral surface of the ilium it will be found that the inferior border corresponds to the sacro-sciatic notch and the anterior border to the median gluteal line.

The Operation of Smith-Peterson.—This consists essentially in reflecting the gluteal tissues with the periosteum, sawing out a sufficient block of bone at the joint, removing the cartilaginous surface from it and from the sacrum, then replacing it and forcing the two freshened surfaces of bone into contact. The steps of the operation are well shown in the illustrations furnished by the author of the operation. Formerly a plaster spica was applied, but at present only a firm bandage is used as a support after the operation.

Smith-Peterson has found in the specimens obtained at operation

definite evidences of traumatic arthritis, the cartilaginous surfaces showing erosions and fibroid changes. In a series of 26 operative cases complete relief of all symptoms was attained in 23.

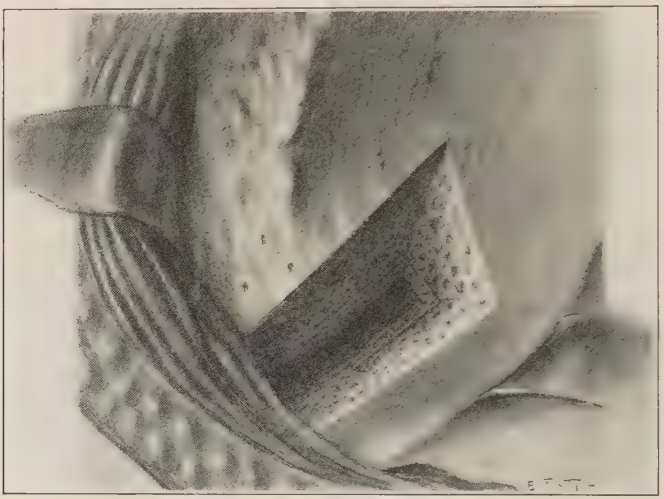

FIG. 110.—With a motor-driven saw a window is removed from the ilium; this window extends posteriorly into the inferior sacro-iliac ligament. The sacral joint surface is removed, exposing cancellous bone; joint cartilage is curetted with angulated curettes.



FIG. 111.—After denuding the block of bone of cartilage this same block is replaced and counter-sunk, so that its cancellous surface comes in contact with the cancellous bone of the sacrum.

Operative Technic of the Smith-Peterson Method.—Several changes have been made since 1921, when the operation was described. These

MEDICAL LIBRARY

are, in brief, in the shape of the wedge and in its replacement, as illustrated in Figs. 108, 109, 110, 111 and 112.

FIG. 112.—In order to further secure the counter-sunk block, and also to promote osteogenesis, the edges of the window are osteotomized.

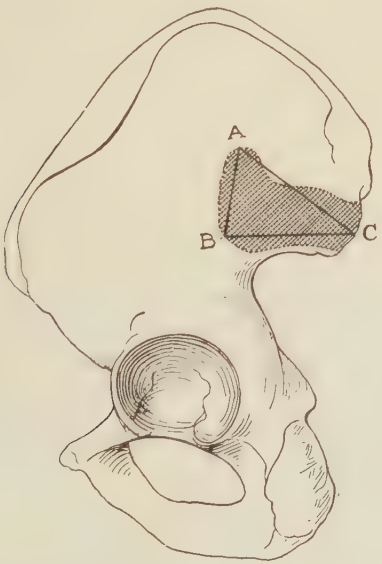

FIG. 113.—Lateral aspect of left iliac bone: The area of articulation with the sacrum is shown by shading; the triangle outlines the area through which the joint is approached. (Gaenslen, Jour. Am. Med. Assn., December 10, 1927.)

Gaenslen's Operation.—Gaenslen[1] makes an incision similar to that of Smith-Peterson. Then with a wide thin chisel splits the ilium,

[1] Jour. Am. Med. Assn., December 10, 1927.

raising a thick bone flap together with the overlying muscles of sufficient size to expose the joint area. The remaining bone is cut through and removed together with the joint cartilage. The cavity is then refilled with bone chips and the bone flap is replaced and the wound is closed. This operation has the advantage of simplicity and it should be effective.

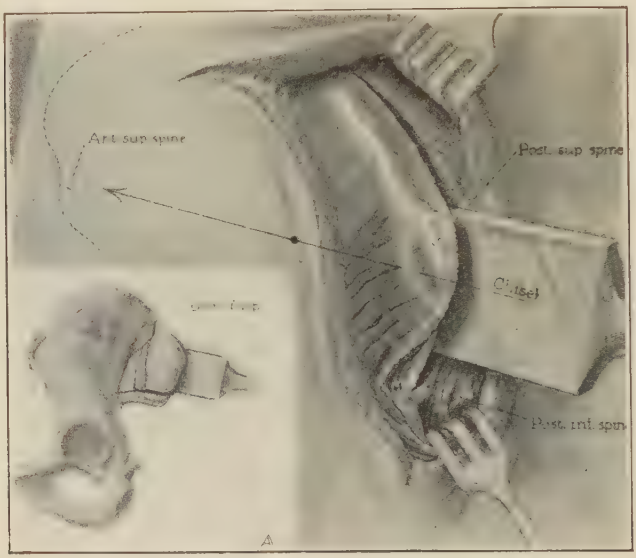

FIG. 114.—Division of posterior third of ilium into an inner leaf, which remains standing, and an outer leaf, which is deflected. Gaenslen, Jour. Am. Med. Assn., December 10, 1927.

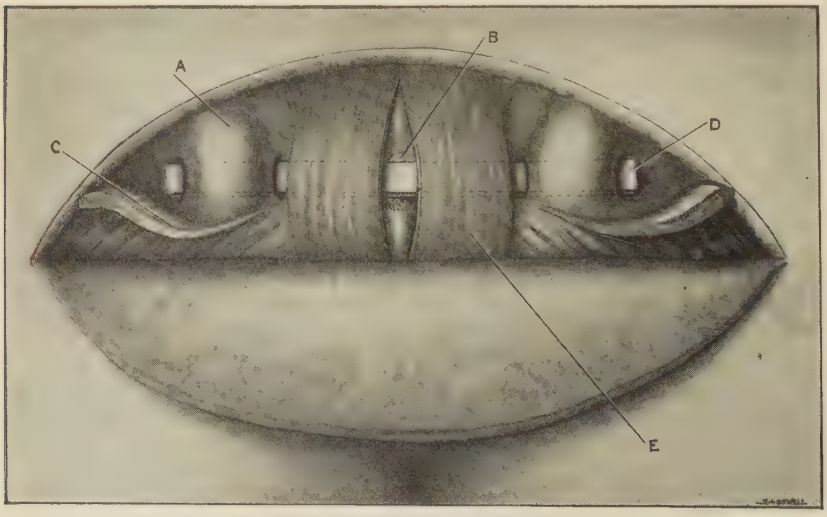

FIG. 115.—Verrall's operation.

Verrall's Operation.[1]—In contrast to the direct operations, that of Verrall of the extra-articular type may be indicated in bilateral cases or for those of tuberculous disease. The method is clearly demonstrated by the illustration. (Fig. 115.)

A graft of bone from the tibia of sufficient length and strength is placed beneath the erector spinæ muscles in contact with a bare surface on the sacrum made by separation of the periosteum and removal of the spinous process at the point of crossing and passed through openings cut through the corresponding posterior-superior spines of the ilia. The period of protection must be somewhat more prolonged than after the Smith-Peterson operation.

As a rule sacro-iliac weakness or disease is unilateral. It may be bilateral or complicated by arthritis at the lumbo-sacral junction. In such cases the operation may include the three articulations.

COCCYGODYNIA.

Pain or discomfort at the extremity of the spine may be caused by injury or disease of the coccyx; it may be symptomatic of displacement, or disease of the pelvic organs or tissues, or it may be induced or aggravated by so-called neurotic conditions.

Whatever the causes, the symptoms are similar: aching, shooting pains in the neighborhood of the coccyx, especially while in the sitting posture, or when rising from the sitting position, and sometimes on defecation or urination.

Treatment.—If the coccyx is actually bent forward, or if movement in the joints is much restricted, massage and manipulation between the thumb and the finger inserted in the rectum is sometimes effective.

Yeomans[2] advocates the injection of 80 per cent. alcohol, 10 to 20 mm. at intervals of a week or more at the point of greatest sensitiveness. Of 24 cases, 16 were cured and 7 relieved by this treatment. In 80 per cent. of the cases, the apparent exciting cause was injury. In but 4 was any abnormality present.[3] In obstinate cases the coccyx should be removed.

[1] Jour. Bone and Joint Surg., July, 1926.
[2] New York Med. Rec., August 22, 1914.
[3] Surg., Gynec. and Obst., December, 1919.

CHAPTER III.

LATERAL CURVATURE OF THE SPINE.

Synonyms.—Rotary lateral curvature; scoliosis.

Definition and General Description.—Lateral curvature of the spine is an habitual or fixed deformity in which the spine is inclined in whole or in part to one or the other side of the median line.

By limiting the term to habitual deformity one excludes simple postural inclination of the spine. For example, if one leg were considerably shorter than the other the pelvis would be tilted downward on the short side and there would be a compensatory curvature of the spine in the erect attitude, which would disappear in the sitting posture. This accommodative or compensatory inclination, and those of similar origin, are not, in the proper sense, lateral curvatures.

In persistent lateral curvature the anterior part of the column is more distorted than are the spinous processes, because lateral bending is always accompanied by rotation of the vertebral bodies toward the convexity of the curve, the spinous processes turning in the reverse direction. Thus well-marked rotation may be present, with but slight lateral deviation of the spinous processes.

In the physiological movements of the spine, direct lateral movement—that is, movement permitted by the articulations of the spine and by the lateral compression of the intervertebral disks—is limited. The larger movements must be accompanied by rotation of the vertebral bodies by which this continuous or solid part of the column is, as it were, forced from the shortened toward the lengthened side (Fig. 116). In what may be called physiological or simulated lateral curvature, produced by bending the body forward and laterally, the change in contour of the spine would be more noticeable if it could be observed from the front rather than from the back, and as lateral curvature is simply a persistent deviation of the spine, one of the so-called static deformities which are directly induced or exaggerated by superincumbent weight, and improper attitudes, it may be assumed that rotation of the vertebral bodies often precedes the lateral distortion that first attracts attention.

Slight rotation may not cause at once an appreciable degree of external distortion, and, although marked lateral curvature is necessarily combined with rotation, yet a slight degree of direct lateral inclination may exist unaccompanied by appreciable rotation. Rotation is usually understood to imply fixed deformity, while lateral deviation may mean simply an habitual posture; but it is far simpler to consider the two as parts of one distortion. The important dis-

tinction is between *habitual deformity*, implying the habitual assumption of an improper attitude in which the accommodative changes in structure have not advanced sufficiently to prevent voluntary or passive correction, and *fixed deformity*, in which the changes in the bones and other tissues have made correction difficult or impossible. The evidence of fixed deformity is rotation that persists after the lateral deviation has been overcome. It persists because the early and important changes must take place in the bodies of the vertebræ upon which the weight falls, but there is no reason to believe that habitual rotation as an accompaniment of habitual lateral curvature may not be corrected if it be treated at the proper time.

Fig. 116.—Physiological rotation accompanying flexion and lateral inclination of the trunk in the normal subject.

The distribution of the weight about the center of gravity in balancing the body in the upright position explains the characteristics of lateral curvature. As the normal contour of the spine is the result of static conditions, a change from this normal relation of one part induces a corresponding change elsewhere. If there is a primary lumbar curvature and rotation to the left in the lower region, a corresponding lateral deviation and rotation to the right in the region above usually develops, thus restoring the balance of the body. This explains the ordinary S-shaped or double curve of scoliosis, one of which is primary and the other secondary. These curves may divide the spine equally, or one may be long and the other short, and occasionally three distinct curves may be present. If the primary curve is slight, the secondary curvature will be slight also, and the primary curve persists doubtless for a time before compensation appears. In some instances the spine may be bent laterally into one long curve, "total scoliosis" (Fig. 117). This is in many instances the initial stage of the ordinary type of scoliosis, the long curve being afterward divided. In childhood total scoliosis is often combined with general posterior curvature, and it is peculiar in that the torsion of the vertebræ may be toward the concave instead of the convex side, the torsion representing probably the early stages of the secondary or compensatory curve.

It has been stated that deformity of one part of the spine is usually balanced by deformity of another. This enables the trunk to hold the erect posture, and it restores its general symmetry. If, however, a long

lateral or long posterior curvature persists, the weight can be balanced only by swaying the entire body on the pelvis, in the direction opposed to the distortion. This restores the balance, but not the symmetry (Fig. 132).

Rotation and Lateral Deviation.—Fixed rotation of the spine carries with it, of course, all the parts that are attached to it. When the patient stands in the erect attitude the simple lateral distortion is most noticeable (Fig. 117), but when the body is bent forward the torsion of the trunk becomes the prominent deformity (Fig. 118). If

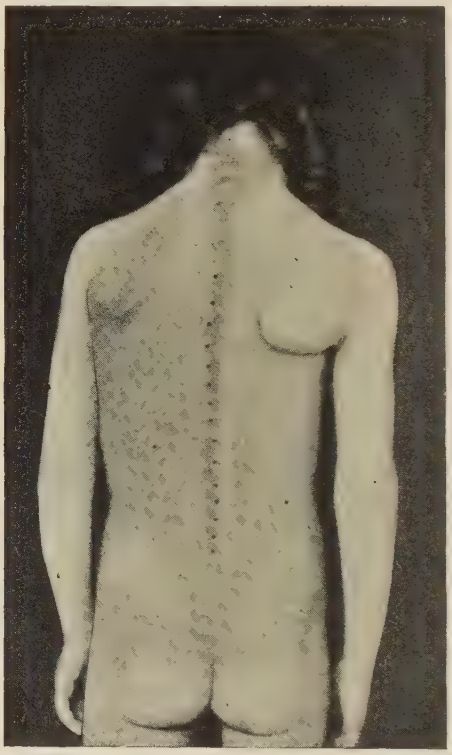

Fig. 117.—Congenital total scoliosis. Compare with Fig. 118.

the thoracic region is involved, the ribs on the side toward which the spine is rotated project backward, and on the other side of the spine there is a corresponding flatness or depression. The projection of the ribs due to the distortion of the thorax is far more noticeable than is the simple twisting of the free portions of the spine in the neck or loins; and in these regions the projecting transverse processes covered by the thick layers of muscles, yet unaccompanied by marked lateral deviation, may cause mistakes in diagnosis. In the cervical region, for example, as an accompaniment of acute torticollis, the projection

may be mistaken for abscess; and in the lumbar region it has been mistaken for a new growth attached to the spine.

Although persistent lateral curvature of the spine is always accompanied by rotation, the degree of rotation does not always correspond to that of the more evident lateral deviation. In the instance cited, rotation in the lumbar region, so extreme as to simulate an abnormal growth, may be present with but slight lateral distortion of the trunk; while in other instances the body appears to be greatly displaced to one side, although there may be comparatively little fixed rotation. Again, as has been stated, the lateral deviation of the trunk is usually more noticeable than the rotation, which in the slighter grades of deformity is only made apparent when the patient is bent forward so that the back may be inspected in the horizontal position. It may be

FIG. 118.—Congenital total scoliosis. The rotation is much greater than the lateral deviation. Compare with Fig. 117.

noted, also, that the degree of habitual lateral distortion of the body does not correspond to the degree of fixed distortion. One individual, by voluntary effort, may practically conceal advanced deformity, while another who makes no effort to correct the improper posture appears to be greatly distorted, although the fixed changes may be very slight.

The effects of the deformity, both general and local, depend upon its situation and its degree. In one instance it may be so slight as to pass unnoticed, and in another the distortion may equal that characteristic of Pott's disease (Fig. 120). If compensation is perfect—that is, if the deformity is equally distributed on either side of the median line—the general symmetry of the body may be but slightly disturbed. Or, if the compensation for the primary deformity of the lumbar region is

distributed throughout the remainder of the spine, noticeable distortion may be insignificant, but when there is a long curve involving the thoracic region the lateral and posterior displacement cannot be concealed (Fig. 121).

Changes in the Anterior-posterior Contour.—Lateral distortion involves also secondary changes in the anterior-posterior outline of the spine. If the distortion is marked the stature is shortened, especially when the

FIG. 119.—Primary lumbar curvature to the left. A "flat-back" marked rotation with but slight lateral curvature.

anterior-posterior curves are increased. In general, one may recognize two types of lateral curvature: one in which the back is flatter than normal, in which the anterior-posterior curves are diminished, and another in which they are increased. It has been stated in the account of Pott's disease that deformity in one segment of the spine always caused a change in the contour of the spine as a whole, that an obliteration or a lessening of the concavity of the lumbar region was accompanied by a

MEDICAL LIBRARY HOSPITAL

corresponding flattening of the normal dorsal kyphosis. On the other hand, that an increase in the backward projection of the dorsal region caused an increased concavity below. The variations in the anterior-posterior contour of the spine in lateral curvature may be accounted for in the same manner. In one instance the primary deformity is of the lower region, and with its accompanying backward twist of the vertebral bodies it lessens the lumbar lordosis and tends to flatten the back (Fig. 119). If, on the other hand, the deformity begins in the thoracic region, the primary effect is to increase the backward projection, and this in turn tends to exaggerate the lumbar lordosis (Fig. 122). Thus the shortening of the trunk in the lumbar region caused by the lateral deviation may be to a certain extent compensated in the first instance, while in the other both the primary and secondary distortions tend to reduce the height.

Fig. 120.—Scoliosis with marked posterior deformity.

The "High" Shoulder and the "High" Hip.—If the convexity of the primary curve is, for example, to the left in the lumbar region the trunk is displaced somewhat to the left, consequently the right pelvic crest becomes abnormally prominent, a prominence that is usually mistaken for an elevation, and in compensation there is a corresponding twist in the opposite direction above. The spine bending, and at the same time rotating toward the right, carrying with it the ribs, raises the shoulder and makes the scapula prominent. Thus it is that in the ordinary S-shaped curve the high shoulder and the prominent hip appear usually upon the same side of the body. But in less regular varieties of distortion, when, for example, there is marked general lateral deviation of the trunk as a whole, the high shoulder may be on the opposite side (Fig. 131). It is probable that the primary curvature is in most instances to the left in the lumbar region, the compensation to the right appearing at a later time. This is certainly true of the milder types of postural curvature.

Pathology.—Lateral curvature of the spine is a deformity, not a disease, nor is it ordinarily an effect of disease. For this reason the description of the pathology, which is merely a more detailed account of the deformity and of its secondary effects upon the trunk and

its contents, may, for convenience, precede the discussion of the etiology.

In such a description one must consider the trunk as a whole, its central column bent and twisted and displaced in which each component segment shares in the general distortion. The vertebra at the apex of each curve shows the greatest change. If the rotation and lateral deviation is to the right the vertebral body is somewhat wedge-shaped, the apex of the wedge being directed backward and to the left. Its lateral diameter is increased and the superior and inferior margins at the

FIG. 121.—Scoliosis with extreme lateral deviation.

narrow side project, increasing its lateral concavity (Fig. 126). Similar accommodative changes, although less marked, are to be found in the articular processes and in the laminæ; in fact, all the parts on the concave side are broadened, shortened, and lessened in vertical diameter as compared with those on the convex side of the spine. These changes affect the shape of the neural canal, which becomes somewhat ovoid in outline, the base being directed toward the convexity of the curve (Fig. 127). In the vertebræ, included in the compensatory curvature, the deformities are reversed and the intermediate segment shows the

transitional changes between the two extremes. The intervertebral disks become wedge-shaped also and atrophied on the shortened side, the changes in these softer tissues preceding, undoubtedly, those in the bones. The articulations of the vertebræ become changed in shape and position in the general adaptation to the deformity and the ligaments are shortened or lengthened according to their relation to the distortion.

On section the internal structure of the vertebræ shows the same adaptive changes that are evident on the exterior. In the narrowed parts of the bones that bear the weight the tissue is thick and compact, on the opposite side it is attenuated and atrophied.

Fig. 122.—High dorsal deformity.

The mobility of the spine is lessened by these changes in its shape and structure, primarily by the distortion, secondarily by the shortening of the tissues on the concave side, by the irregularities of the vertebral bodies, by the interference of the newly formed or transformed bone which is thrown out about the margins of the vertebræ and the articular processes, and by ossification of the periosteum and ligamentous coverings of the adjacent bones. Thus, in fixed deformity there may be, at the points of greatest distortion, practical anchylosis. The muscles of the spine, both intrinsic and extrinsic, undergo adaptative changes, and, as a rule, they are relatively weak.

The most important of the secondary deformities of lateral curvature is that of the thorax. This is somewhat difficult to describe, because the distortion of the dorsal vertebræ does not affect the thorax equally; thus, it is not twisted as a whole, nor flexed as a whole. The nature of the deformity may be better understood by considering the sternum as a fixed point; this, as a matter of fact, it is, as compared with the spine. At the apex of the convexity of the curve the ribs are drawn sharply backward, their angles project by the side of and beyond the spinous processes, sometimes covering and concealing them, and the lateral convexity of the chest is diminished or lost. On the opposite side the back is broadened and flattened. The effect of the rotation is to diminish the capacity of the chest on the convex side and to increase that of the concave side (Fig. 128). On the convex side the ribs are elevated and their inclination is increased. On the concave side the

intercostal spaces are narrowed and the inclination is lessened (Fig. 125). The anterior-posterior diameter of the chest is increased or diminished according to the change in the anterior-posterior contour of the spine. If the dorsal kyphosis is exaggerated the effect is to deepen the chest (Fig. 120); if it is diminished, the diameter of the thorax is correspondingly lessened.

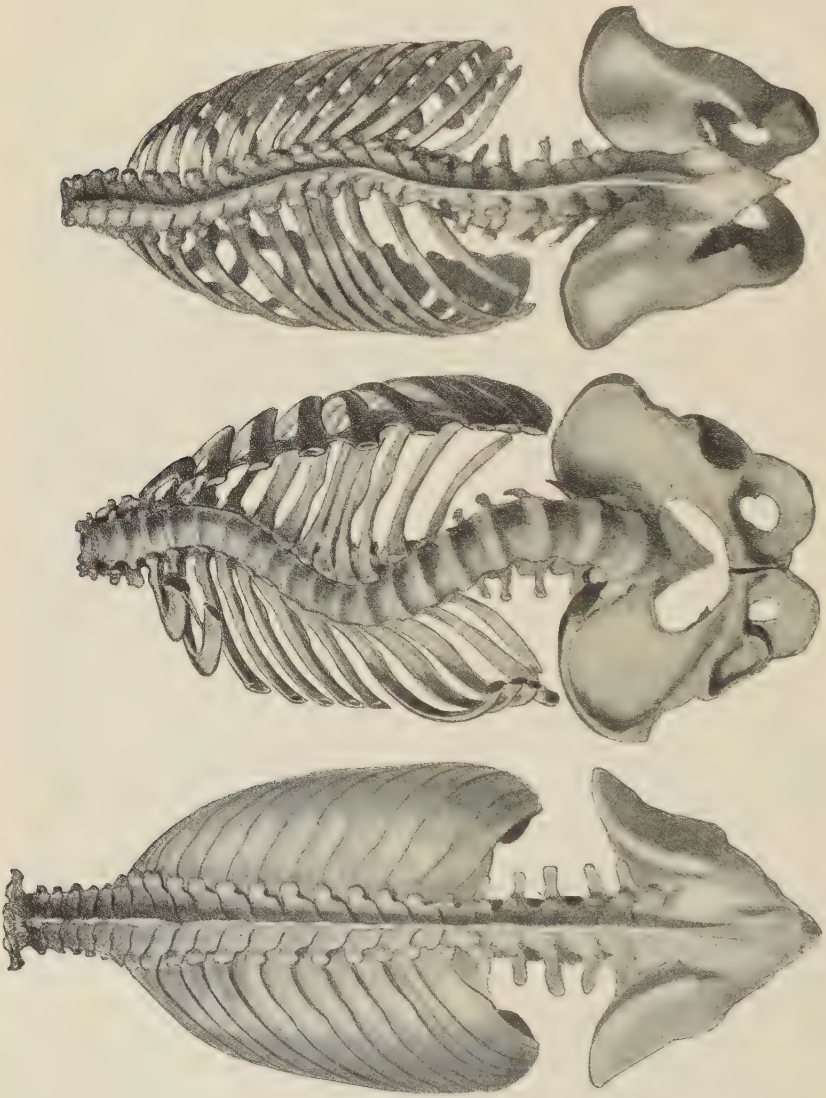

Fig. 125

Fig. 124

Fig. 123

Figs. 123, 124 and 125.—The normal spine contrasted with the scoliotic spine. (Pfeiffer.)

The cervical section of the spine, except in cases of congenital malformation, is not often involved, to a marked degree at least, in the lateral deformity. But in extreme cases, in which the neck and head

are habitually distorted, there may be accommodative changes in the skull similar to those induced by persistent torticollis.

At the other extremity of the spine the pelvis is not, as a rule, markedly deformed except in cases due directly to rhachitis. In some instances the oblique diameter, opposed to the convexity of the lumbar deformity, may be increased, and if the lateral deviation of the lumbar spine is extreme the pelvis may be so tilted that the limb on the elevated side becomes apparently shorter than its fellow.

In changes that have been described the contents of the trunk are involved to a greater or less degree. The lung on the convex side is compressed by the distorted ribs and by the displaced vertebral bodies.

Fig. 126.—Scoliotic vertebræ. (Hoffa.)

The heart may be displaced laterally or in other directions according to the character of the deformity, and the bloodvessels are changed in direction, and, it may be, altered in caliber. In those cases in which the thorax is markedly distorted the effect is similar to that of the deformity of Pott's disease; respiration is shallow and rapid, the pulse-rate is usually increased, and other evidences of interference with the vital functions may be apparent. The abdominal organs are affected, doubtless, in a similar manner, but symptoms due to this cause are not, as a rule, as clearly marked.

Bachmann[1] investigated the secondary changes induced by severe

[1] Die Veränderungen an den inneren Organen bei hochgradigen Skoliosen und Kyphoskoliosen, Bibliotheca Medica, 1900, Ab. D. 1, H. 4.

scoliotic deformity coming under his observation in the pathological institute of Breslau. In 91.3 per cent. of the subjects defect or disease of the circulatory apparatus and in 99.1 per cent. of the respiratory organs was observed.

Fig. 127.—Change in shape of the spinal canal, broader on the convex side. (Hoffa.)

Etiology. — Relative Frequency.—Lateral curvature of the spine is one of the most common of deformities. In a period of years 3252 cases were recorded in the out-patient department of the Hospital for Ruptured and Crippled, a number only exceeded by that of bow-legs, of which 5030 cases were treated during the same time.

The relative frequency of lateral curvature among children in general is illustrated by the statistics of Drachmann, who found among 28,125 school-children (16,789 boys, 11,386 girls) of Denmark 368 cases of scoliosis (1.3 per cent.), and those of Scholder, Werth, and Combe,[1] who found 571 cases of lateral curvature among 2314 school-

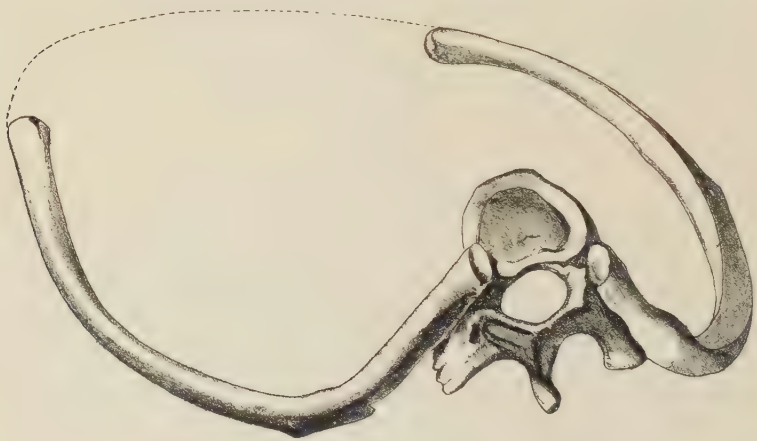

Fig. 128.—Deformity of the thorax in scoliosis. (Hoffa.)

children of Switzerland (24.6 per cent.), a discrepancy that is somewhat difficult to explain.

[1] Annales Suisses d'Hygiene Scolaire. 1901.

Sex.—Lateral curvature of the spine is far more common among females than males. Of the 3252 cases referred to, 2554 (78.5 per cent.) were in females and 698 (21.4 per cent.) were in males.

The lowest percentage of males in any one of the fifteen years was 14.8, the highest 25.1. This proportion of one male to four females is somewhat larger than in the smaller groups of cases reported by other observers.

FIG. 129.—Scoliosis of a severe type, showing the general distortion of the spine and of the individual vertebræ. (Nicoladoni.)

FIG. 130.—Scoliosis of slight degree, showing the change in the vertebral bodies. (Nicoladoni.)

The unequal distribution of the deformity between the sexes is of great interest as bearing on the question of etiology; especially so as in the cases that develop in early childhood, sex appears to exercise practically no influence. It has been suggested that curvature of the spine in a girl is looked upon with more solicitude by the mother than is the same deformity in a boy, therefore more girls are brought for treatment. There may be some basis for this argument, for it is certain that distortions of the lower extremities have been considered of greater

importance in male than in female children, because of the concealment formerly afforded by the skirts. But granting that statistics are somewhat unreliable, there can be no doubt but that this deformity is far more common among girls than boys and that the disproportion may be explained, in great part at least, by the differences in dress and in manner of life.

Age.—One thousand two hundred and ninety-nine (39.9 per cent.) of the 3252 patients referred to were less than fourteen years of age; 1576 (48.4 per cent.) were between fourteen and twenty-one; 377 (11.6 per cent.) were more than twenty-one years of age. These statistics simply show the age of the patients at the time treatment was sought, and they are of little value as an indication of the age at which deformity might have been detected had it been looked for.

There is no reason to suppose that lateral curvature of the spine differs in its etiology from similar deformities of other parts, except in so far as each region of the body is more or less susceptible to deforming influences at one time than another.

For example, rhachitic deformities of the upper extremities practically never develop except in infancy, and they begin to correct themselves when the erect posture is assumed or at the very time when distortions of similar origin of the lower extremities appear or increase. When deformities of this class, whether of the spine or limbs, appear in later childhood or adolescence it may be assumed that, in many instances at least, the tendency toward the particular deformity, or even a slight degree of deformity, was acquired at an early age, that it remained latent until conditions appeared which favored its further development. This point is illustrated by the statistics of Eulenburg of 1000 cases of lateral curvature analyzed with reference to the inception of the deformity.

Between birth and the sixth year	78
Between the sixth and seventh years	216
Between the seventh and tenth years	564
Between the tenth and fourteenth years	107
After the fourteenth year	35
	1000

It will be noted that but 142 (14.2 per cent.) of these patients were more than fourteen years of age as contrasted with the statistics of the Hospital for Ruptured and Crippled, in which 60 per cent. were beyond this age.

In 2000 cases reported by Roth the deformity was first noticed:

Between one and five years	34
Between six and ten years	190
Between eleven and fifteen years	468
Between sixteen and twenty years	209
Between twenty-one and thirty years	78
Between thirty-one and forty years	17
Over forty-one years	4
	1000

MEDICAL LIBRARY

Dr. Walter Truslow, who for several years had the immediate charge of the treatment of lateral curvature at the Hospital for Ruptured and Crippled, prepared for me statistics of a number of the cases which illustrate the same point.

But 44 of the 181 patients (22.6 per cent.) were more than thirteen years of age at the time when the deformity was first noticed, although nearly 50 per cent. were older than this when treatment was applied for. In the first table it will be noted that of the 38 patients who were ten years of age or less, 15, or about 40 per cent., were males. Of 25 of the 37 cases in which the deformity attracted attention at or before the sixth year, rhachitis was the apparent cause.

Lateral curvature of the spine is one of the penalties of the erect posture, and the force of gravity must be considered both as a predisposing and as an exciting cause of the deformity.

The more direct tendency of the force of gravity is to cause the body to incline forward and to increase the posterior curvature of the spine, but whenever there is a persistent inclination of the spine to one or the other side this inclination is likely to be increased to deformity under favoring conditions. These favoring conditions would include general weakness from any cause; overwork that may induce fatigue, and all factors, mechanical or otherwise, that may add to the difficulty of holding the trunk erect under the pressure of the superincumbent weight.

Although it is not difficult to suggest the predisposing causes of lateral curvature, it is by no means as easy to point out the direct cause of the original inclination of the spine to one or the other side of the median line that is the first step toward fixed deformity. In a certain number of cases, however, the relation between cause and effect is sufficiently evident, and these causes may be enumerated before considering the larger class in which the etiology is more obscure.

1. Lateral curvature secondary to deformity of other parts.
2. Static or compensatory deformity.
3. Deformity secondary to disease of the nervous system.
4. Deformity secondary to disease of the thoracic organs.
5. Incidental deformity.
6. Deformity due to occupation.
7. Congenital deformity.
8. Rhachitic deformity.

1. Lateral Curvature Secondary to Deformity Elsewhere.—(*a*) Lateral curvature of the spine may be a compensatory effect of torticollis, either congenital or acquired. (*b*) It may be induced by distortion of the lower extremities. For example, fixed adduction of the thigh necessitates an upward tilting of the pelvis whenever the limb is brought into the median line, whether the patient is standing, sitting, or lying; and this deformity when extreme may induce lateral curvature even in bed-ridden patients.

2. Compensatory Deformity.—The same effect is sometimes observed in certain instances of inequality of the length of the lower

extremities. In the erect posture the pelvis is tilted downward on one side, an inclination which requires lateral inclination, and if considerable, rotation of the spine as well. Simple inequality of the limbs is an occasional but not a common cause of fixed deformity, because its influence ceases in the sitting and reclining postures, and because the inequality is so often compensated, if it is extreme, by walking on the toe or by raising the sole of the shoe.

An increase in the length of a limb, such as may be caused by a fixed equinus of the foot, seems to have more influence in causing secondary deformity than does shortening, because no attempt is made to compensate for the inequality.

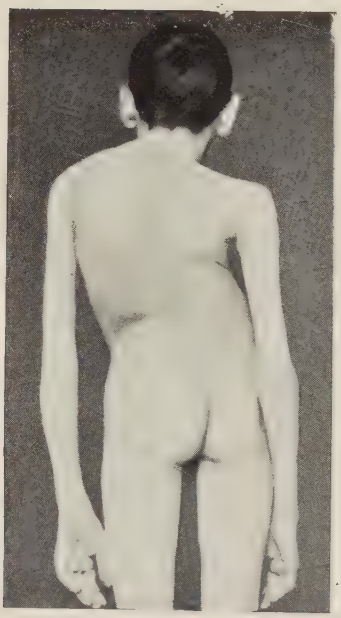

FIG. 131.—Scoliosis in a patient, nineteen years of age, caused by empyema in infancy.

FIG. 132.—Scoliosis secondary to Pott's disease in early childhood.

3. LATERAL CURVATURE SECONDARY TO PARALYSIS.—Lateral deformity of the spine may be caused indirectly by a number of distinct diseases of the nervous system, but in this connection only one need be considered—anterior poliomyelitis. It may induce deformity by distortion of a lower extremity or by inequality in the length of the limbs due to retardation of growth. It may predispose to deformity by general weakness and by the postures assumed, or the trunk may

be unbalanced by loss of function in one of the upper extremities. The most constant predisposing cause is paralysis of the abdominal muscles, and some of the more extreme cases of deformity are caused by unilateral paralysis of the muscles of the trunk. As a result the expansion of one side of the thorax is interfered with and the unaffected or less affected side taking on increased activity develops at the expense of the disabled part. Thus the convexity of the curve is usually toward the sound side.

FIG. 133.—Congenital scoliosis.

FIG. 134.—Rhachitic scoliosis.

4. LATERAL CURVATURE SECONDARY TO DISEASE WITHIN THE THORACIC WALLS.—The most common cause of deformity of this class is empyema. The lung is primarily compressed by the effused fluid, and its function is finally impaired or abolished by the adhesions that form between it and the chest wall as well as by the extension of the disease to its structure. As a result the side of the chest is retracted while the function of the unaffected lung is increased (Fig. 131). Thus, as in paralysis, the spine curves with the convexity toward the active side.

Other affections of the lungs that interfere with the function of one

side may induce lateral curvature, but the influence is less marked and direct than in empyema.[1]

FIG. 135.—Congenital lateral curvature caused by malformation of the lower lumbar and sacral vertebræ. There are thirteen ribs.

[1] See Anterior Poliomyelitis.

5. Incidental Lateral Curvature.—Lateral curvature may be caused by direct injury or by disease of the spine, for example, by fracture or by Pott's disease, or by other organic affections of the spine (Fig. 132). Distortion symptomatic of sacro-iliac disease, or the more marked deformity caused by sciatic or lumbar neuritis (Fig. 103), may, if persistent, finally induce slight permanent deformity, but such cases hardly deserve special consideration.

6. Lateral Curvature Due to Occupation.—Lateral curvature of a mild degree is incidental to certain occupations that require habitual inclination of the body. It is said to be very common among stone-cutters, for example. Such deformity developing after the growth of the body has been attained is of interest as throwing light

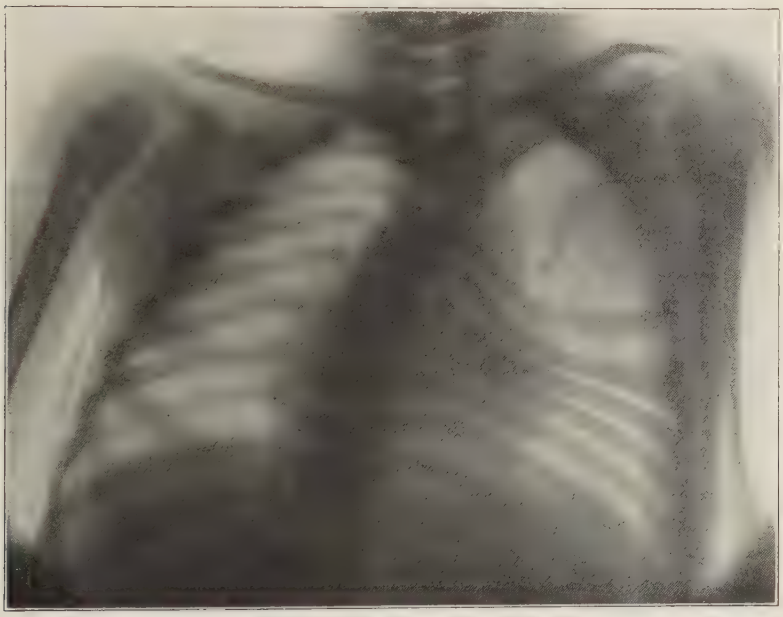

Fig. 136.—Congenital lateral curvature caused by malformation of the upper dorsal vertebræ. Several ribs are absent.

upon the etiology of the ordinary form of lateral curvature. For if habitual attitudes can thus change the contour of the developed spine, it is evident that similar postures, though far less constant, may influence the spine of a growing child, particularly in one predisposed to such distortion.

7. Congenital Lateral Curvature.—Congenital scoliosis may occur in infants otherwise normal due apparently to a constrained attitude before birth. It is usually associated, however, with other defects or deformities, for example, with cervical ribs, elevation of the scapula and the like. The deformity may be apparent at birth or it may not be observed until later years, when examination by the *x*-rays

shows supernumerary, deficient or fused vertebræ and the like (Figs. 135, 136 and 137).

According to Willis[1] there is an evolutionary tendency toward shortening the vertebral column as evidenced by the sacralization of the fifth lumbar vertebra.

Brailsford[2] found anatomical irregularities in this region in 26.4 per cent. of the cases examined, the more common being sacralization of

Fig. 137.—Congenital lateral curvature.

the fifth lumbar, elongation of the transverse process and incomplete closure of the neural arch.

8. Rhachitic Lateral Curvature.—Rhachitis predisposes to deformity of all parts of the body by lessened resistance of all the tissues. The more common deformities from this cause are the so-called rhachitic kyphosis that develops in the sitting child, and the distortions of the lower extremities in those who stand and walk. Lateral curva-

[1] Am. Jour. Surg., February, 1929.

[2] British Jour. Surg., April, 1929.

ture of the spine sometimes accompanies the kyphosis in those who do not walk, or it may exist independently of it. The lateral inclination is induced doubtless by the manner of sitting or by the manner in which the child is supported on the mother's arm; for at this period of rapid growth and increased susceptibility to deforming influences, even slight and temporary causes of this nature may be sufficient to induce the distortion (Fig. 134). Again, when the child begins to walk, the tilting of the pelvis due to distortion of the limbs, for example, to unilateral knock-knee, may also serve to disturb the equilibrium of the body and thus to induce lateral distortion.

How common rhachitic lateral curvature may be it is impossible to say, but if all rhachitic infants and children were carefully examined this deformity would be discovered in many instances in which its existence had not been suspected.

Fig. 138.—Congenital scoliosis showing rudimentary vertebræ, sacralization and an elongated transverse process.

Mayer[1] examined 220 rhachitic children with reference to this point, and in all but 3 found scoliotic deformity. This is not in accord with my experience, but I am convinced that rhachitis is of far greater importance in the etiology of lateral curvature of the spine than is generally believed, and that a large proportion of the severe and intractable cases may be traced to this cause. As has been mentioned, rhachitic scoliosis is, practically speaking, equally divided between the sexes.

[1] Bull. méd., Paris, June 15, 1901.

In about 15 per cent. of the cases under treatment by Truslow the influence of one or more of the causes that have been enumerated seemed to be apparent, viz.:

Congenital deformity	2
Torticollis	2
Empyema	4
Anterior poliomyelitis	3
Inequality of the legs of more than half an inch	6
Rhachitis	13
Total	30

In the remaining 85 per cent. of the cases the direct cause of the deformity was uncertain

Fig. 139.—Posture induced by improper desk and chair. (Scudder.)

Hereditary Influence.—By many writers the influence of heredity is considered an important factor in the etiology. That there is such an influence, is undoubted, but it is very difficult to establish its connection with ordinary cases. In 11 of 201 cases lateral curvature was present in either the father or mother of the patient; and in 17 others a brother or sister of the patient was deformed in a similar manner. In 1000 cases reported by Roth, 276 had relatives suffering from scoliosis and there were seven families in which three or more members were affected.[1]

[1] British Med. Jour., September 2, 1911.

CITY HOSPITAL

Occupation.—As occupation may induce deformity in the adult, one looks naturally to occupation as a factor in the causation of lateral curvature in childhood. Occupation in this class implies school, and it is well known that fatigue during school hours may induce improper postures, especially if the chair or desk is unsuitable or uncomfortable or the lighting defective. The influence of habitual posture is indicated in the statistics of lateral curvature among school-children recorded by Scholder, Werth, and Combe,[1] the proportion of deformity steadily rising from the lower to the higher classes (Figs. 139 and 140). Under the influence of constantly recurring fatigue an improper attitude is likely to become habitual, its character being influenced by the arrangement of the light or by the shape of the seat or desk. As Abbott has pointed out, the most perfect simulation of lateral curvature is the attitude of a child writing at a desk in which forward and lateral inclination are combined with torsion. When a habit of posture has been acquired it is likely to persist when the sitting posture is assumed elsewhere than at school, and the greater liability of girls to the deformity may be explained in part by the fact that they sew, or read, or play on the piano when boys are usually engaged in active exercises.

In 400 cases of lateral curvature under treatment at the Hospital for Ruptured and Crippled, the occupation and habits that may have influenced the deformity were recorded:

Occupation.		
School		285
Factory		19
Clerk		13
Domestic		8
Millinery, dressmaking, etc.		8
Messenger		3
Housewife		3
Teacher		2
No occupation		59
Total		400

Posture.		
Weight on right foot	48	
Weight on left foot	48	
		96
Carries books or baby on right arm	38	
Carries books or baby on left arm	36	
		74
Sits at desk or work in faulty attitude		57
Carries heavy load on one shoulder		2
Excessive use of right arm in occupation		3
Total		232

The sitting posture is not the only one in which improper attitudes may be persistently assumed, for even posture during sleep may influence the inclination of the body during the hours of activity. But the sitting position is the one in which a tendency toward lateral inclination is most likely to be acquired, since children do not often retain one attitude in the erect position for any length of time. Bradford and

[1] Bull. méd., Paris, June 15, 1901.

Lovett record an observation of the attitudes of sixty-seven healthy adults undergoing a written examination. At the end of the second hour a lateral inclination of the body was evident in all, and in three-fourths of the number to the right. In about this proportion of the cases of lateral curvature the type of fixed deformity is to the left in the lumbar and to the right in the dorsal region. Assuming that the distortion is caused or influenced by the habitual attitude during school hours, it would appear that the primary deformity should be more often of the lumbar region, for in the sitting posture the lumbar lordosis is lessened or lost; thus the bodies of the vertebræ in the lumbar region are subjected to greater pressure than in the dorsal region—a pressure

FIG. 140.—Posture induced by improper chair. (Scudder.)

which might induce the accommodative changes in the bones that accompany persistent deformity.

The possibility of distinguishing the varieties of lateral curvature in which the primary distortion is lumbar from those in which it is dorsal, by the flattening of the dorsal kyphosis in the former, and its exaggeration in the latter instance, has been mentioned.

Varieties of Deformity.—According to statistics from various sources, about three-fourths of the well-developed double curves of the spine are convex to the right in the dorsal and to the left in the lumbar region, and, as the distortion of the thorax is more noticeable of the two, it usually classifies the deformity as right or left. The dorsal curvature may be either primary or secondary, and the relative frequency of the original deformity, whether lumbar or dorsal, is in doubt, with the probability in favor of the former.

It will be noted that in 21 cases anterior-posterior deformity was present without lateral deviation, and that in 37 instances it was accompanied by lateral deviation. In the remaining 144 cases rotation was more marked than lateral deviation in 30 cases, and lateral deviation more marked than rotation in 113. In the entire number of cases in which lateral deviation was present it was single in 39 cases, double in 117 cases, triple in 24 cases.

Summary of varieties of deformity of the spine under treatment, tabulated by Dr. Truslow:

1. Simple anterior-posterior deformities:		
(a) Kyphosis	10	
Kypholordosis	1	
Lordosis	1	
	—	12
Round shoulders:		
(b) Abducted scapulæ	7	
Elevated scapulæ	2	
	—	9
2. Anterior-posterior abnormalities most marked, but accompanied by lateral deviation:		
(a) With single lateral curve	14	
(b) With double lateral curves	16	
(c) With triple lateral curves	7	
	—	37
3. Rotation more marked than lateral deviation:		
(a) With double lateral curves	22	
(b) With triple lateral curves	8	
	—	30
4. Lateral deviation more marked than rotation; direction of the curves:		
Right dorsal, left lumbar type:		
(a) Single lateral curve	22	
(b) Double lateral curves	17	
(c) Triple lateral curves	6	
	—	45
Left dorsal, right lumbar type:		
(a) Single lateral curve	3	
(b) Double lateral curves	8	
(c) Triple lateral curves	3	
	—	14
Total		147

In 890 cases of lateral curvature tabulated by Schulthess the deformity was as follows:[1]

Total scoliosis (single curve affecting the entire spine)	173	23	196
Lumbar scoliosis (single curve limited to the lumbar region)	63	34	97
Lumbo-dorsal scoliosis (single curve limited to lumbo-dorsal region)	184	164	348
Complicated scoliosis:			
(a) Right dorsal, left lumbar	...	191	...
(b) Left dorsal, right lumbar	58	...	249
	478	412	890

It will be noted that a very large proportion of these cases were in the early stage of deformity, as indicated by the absence of compensatory curves; that in 80 per cent. of the 293 cases in which the curve

[1] Ztschr. f. orthop. Chir., 1902, Bd. 10

was general or most marked in the lumbar region, the inclination was to the left; and of the complicated or more fully developed cases in which the curve was double, 73 per cent. were of the right dorsal, left lumbar type.

Symptoms.—In the majority of cases the first symptom is the deformity. This is often discovered by the dressmaker at the age when the clothing is made to fit the figure more closely. In certain instances the deformity may be preceded or accompanied by pain. This was present to a greater or less degree in about one-quarter of the cases examined by Truslow, and 440 of Roth's 1000 cases: slight in 134,

FIG. 141.—In rare instances of extreme deformity the spinal cord may be compressed and paralysis may follow. This illustration of congenital scoliosis shows a very unusual degree of displacement of the vertebral bodies.

moderate in 163, severe in 143. Pain may be simply the discomfort or the "dragging" sensation of fatigue, usually referred to the lumbar region, or it may be severe and neuralgic in type. The latter variety is more common in the cases in which the deformity is extreme. It is said to be the result of pressure on nerves, but this cause is exceptional in ordinary cases, as it is as often referred to the convex as to the concave side. When the deformity is extreme—for example, when the ribs and the iliac crest are in contact—direct pressure may explain the local discomfort referred to this region and in cases of extreme deformity, pressure paralysis may require laminectomy. There are also more general symptoms of a neurasthenic character that may be due in part to the deformity and in part to the debility of which it may

be a result or accompaniment. For it must be borne in mind that lateral curvature is one of the postural deformities whose development is favored by general weakness, as illustrated by the fact that it is often accompanied by other deformities of similar nature, particularly by the weak foot. Deformities of this class that are induced by weakness, in their turn tend to prolong and to aggravate it by hampering normal development and normal function.

In many instances symptoms of weakness and awkwardness precede the deformity. Truslow states that in a large proportion of the cases investigated, the patients had been distinctly less active than their companions, that they did not enjoy exercise, and were inclined to lead sedentary lives. Teschner[1] has called attention to the same peculiarity. He states that the patients are often indifferent, apathetic, and lazy. He has noted also a peculiar lack of coördination and muscular control as a common accompaniment of the deformity. These symptoms apply particularly to adolescence, the period of rapid growth and instability, when any latent deformity or weakness is likely to be exaggerated. (See Vertebral Epiphysitis.) In younger subjects such symptoms are far less marked or are absent. In the cases in which the deformity is extreme, symptoms due to interference with the respiratory, circulatory or nervous system, or to displacement of the abdominal organs, may be present. Such symptoms are, however, rather unusual in cases of the ordinary type. It may be noted that symptoms secondary to congenital malformations of the spine, such as pain and weakness of the area caused by cervical rib, paralysis complicating scoliosis, discomfort about the lumbar region and thigh due in part apparently to malformation of the fifth lumbar vertebra, do not appear usually until adolescent or adult life.

Diagnosis.—Posture. -When the patient stands with the back and hips bare, the lateral inclination of the body and a corresponding asymmetry of the trunk are usually apparent, even in the earliest stage of the affection. For, as has been stated, the habitual assumption of the deforming attitude precedes fixed changes in and about the spine, and this attitude will appear when the patient is asked to stand for inspection. If the inclination of the body is toward the left (Fig. 117), the left arm will hang in close apposition to its lateral border, while on the right side an interval will appear between the arm and the trunk. If there is a slight lumbar curve to the left (Fig. 119), the right iliac crest will be accentuated. The curvature in the dorsal region raises one shoulder (Fig. 134), the scapula on the affected side projects, and the distance between its posterior border and the median line is increased. Rotation of the spine is shown by the fulness or projection of one side accompanied by a corresponding flatness or concavity on the other. This is more noticeable when the patient bends the body forward so that the horizontal plane of the back is brought into view (Fig. 118). Corresponding changes, though of a less marked degree, appear on the anterior surface of the body; for example, the apparent

[1] Med. Rec., December 16, 1893.

diminution in the size of the mamma on the side of the convexity and its relative depression or elevation may attract attention.

It is probable that a change in the anterior-posterior contour of the spine precedes, in many instances the lateral deviation. Thus a general droop of the body associated with round shoulders and a flattened chest may be regarded as a predisposing cause.

Mobility.—Habitual posture implies disuse of certain attitudes and movements; thus limitation of the normal flexibility of the spine is one of the earliest signs of progressive deformity. The test of the mobility of the different regions of the spine is therefore an essential part of the examination. To test the motion in the lumbar region, one fixes the pelvis with the hands while the patient sways the body in the four directions and rotates it from side to side. It is suggested by Bradford and Lovett that direct lateral flexibility may be tested by placing blocks of wood under one foot until the limit of lateral flexion is reached, as shown by the inability of the patient to hold the elevated limb in the extended position. The experiment is then repeated on the opposite side. The flexibility of the upper part of the trunk may be tested by fixing the part below with the hands while the patient flexes, extends, and rotates the body. It is important, also, to test the range of motion at the shoulder-joints. The normal individual should be able to hold the arms extended directly above the head without increasing the lumbar lordosis. In many instances, however, it will be found that there is a marked restriction of this motion; in fact, such restriction is almost always an accompaniment of so-called round shoulders.

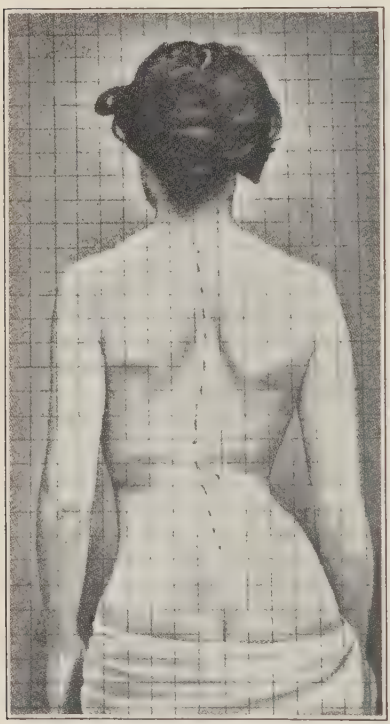

FIG. 142.—The thread screen. From the Boston Children's Hospital Report.

The height and weight, the circumference and the expansion of the chest should be recorded, and a test of the muscular strength, not only of the muscles of the trunk, but of the members as well, is of advantage as throwing light on the etiology and indicating the general line of treatment.

Record.—The most reliable of the graphic records to be used in connection with the history are photographs. The patient may stand behind a thread screen (Fig. 142) in the habitual attitude. The spinous processes, the iliac crests, and the angles of the scapulæ having been

marked, the exact amount of lateral deviation of the trunk will be shown. The rotation may be indicated also by photographing the patient in the recumbent posture.

The rotation of the spine is the most important indication of deformity. This may be recorded with sufficient accuracy by taking direct tracings of the trunk at fixed points by means of a lead or zinc tape while the patient lies in the recumbent posture.

At the Hospital for Ruptured and Crippled the shadow of the trunk cast by an electric light at a fixed distance is traced upon a large sheet of paper. Upon this outline the position of the more important landmarks is indicated. The degree of rotation is shown by transverse tracings and the line of the spinous processes is ascertained by applying a broad strip of adhesive plaster to the back, upon which the tip of each spinous process is marked. The anterior-posterior outline of the spine should be recorded, also the general attitude and the presence or absence of other evidences of weakness, such as knock-knees and weak feet.

Fig. 143.—The triangle of Michaelis. Formed by the dimples at the posterior iliac spines. The terminal spinal groove and the beginning of the gluteal notch. A useful test for pelvic balance.

Prognosis.—In the development of lateral curvature there is doubtless a preliminary or predisposing stage—a stage of progression and a stage of arrest. All deformities of this class are more likely to progress during the growing period. They are likely to become stationary when the period of growth is completed. Thus, the prognosis is worse when the deformity begins at an early age than when it first appears in adolescence. The most extreme and intractable of the simple cases are the result of rhachitis, in which the deformity appearing in infancy or early childhood has increased with the growth of the child.

If the causes of deformity are such that they operate to check the equal development of the affected part, the prognosis is even more directly influenced by the age of the patient. For example, empyema, even if the lung is irreparably damaged, does not cause appreciable deformity in the adult, but in childhood the functional activity and the growth of the side of the thorax are checked in addition to the direct effect of the adhesions and contractions due to the disease; thus the deformity is likely to be progressive in spite of the treatment. The same is true of paralytic deformity. In the ordinary type of lateral curvature in the adolescent girl the prognosis is influenced, of course,

by the general condition of the patient and by the character of the occupation. As far as the local deformity is concerned, the prognosis as regards improvement or cure depends in great measure upon the fixed changes that have taken place, and upon the degree of voluntary and involuntary rectification that is possible. In some instances the postural distortion may be considerable, yet the fixed deformity may be very slight, while in other instances the fixed rotation of the spine may be marked, although the lateral distortion is less noticeable.

A single curve is more amenable to treatment than is a double or triple distortion, because it indicates an earlier stage of deformity and because the treatment may be more effective when applied to one deformity than to several. If, however, the single curve is fixed, the appearance of a secondary or compensatory curve at another part of the spine is probable, in spite of preventive treatment.

In the majority of cases, fixed deformity of the spine as indicated by rotation is already present when the patient is brought for treatment. This fixed deformity might be overcome possibly in certain cases, and complete cure might be obtained were all conditions favorable. But in the practical sense a cure means the relief of symptoms, the checking of the progress of deformity, and the restoration of the general symmetry of the trunk. Such a cure may be obtained in many instances. The deformity of the spine becomes symmetrically divided on either side of the median line, the changes incident to maturity, particularly the increased amount of adipose tissue, serve to conceal the irregularities of the outline, and the history of the distortion is completed.

In certain instances, particularly in the more extreme cases, the deformity may increase in adult life and even in old age. In this type the symptoms of discomfort and actual pain may be troublesome throughout life, especially in the overworked and debilitated class. The symptoms directly incident to the compression and distortion of the internal organs have been mentioned.

The great majority of cases that develop or that are discovered in adolescence progress for a time and come to an end on the cessation of growth, causing finally no symptoms other than the loss of symmetry that may be more or less satisfactorily concealed by the art of the dressmaker and the patient.

It would appear, then, that lateral curvature of the spine is always of sufficient gravity to merit treatment and supervision until its cure or arrest is assured. If its discovery leads to the improvement of the general condition and to the avoidance of unhealthful influences it may be even of benefit to the patient.

Summary.—Lateral curvature in a young child is of far greater importance than in an older subject because of the probability of an increase of deformity. Extreme deformity is always a source of weakness and usually of discomfort to the patient. Incipient deformity may be cured, and cure is not impossible even when deformity is more advanced, but in this more than in any other postural deformity, absolute cure implies early diagnosis and prevention rather than the correction of fixed distortion.

The progress of deformity of the ordinary type is indicated by:

1. The habitual assumption of an attitude simulating deformity.
2. Limitation of motion in the directions opposed to the habitual attitudes.
3. Fixed lateral deviation of the spine accompanied by rotation or twisting of the column.

One rarely has the opportunity to note the development of lateral curvature, and when patients are brought for treatment fixed deformity is usually present. It is very difficult to entirely overcome fixed distortion, while it is comparatively easy to correct simple postural deformity in which the secondary changes are absent or but slightly advanced. On this account it has been customary to divide lateral curvature into two classes—the *true* and the *false*—or to speak of rotary lateral curvature as distinct from lateral curvature. Thus, the term true or rotary curvature would be limited to those cases in which the changes are fixed and in which cure is practically impossible, while false or simple or postural lateral curvature would include the early or curable class. But as the two forms are often simply stages in the same process it would seem preferable to speak of the incipient and the later stages of lateral curvature, or of *reducible* or *irreducible* deformity, the distinctions that are made in classifying distortions of similar origin elsewhere.

This point of view is of advantage because it relieves the subject of much of the obscurity that has resulted from this arbitrary division. It emphasizes the fact, also, that the habitual assumption of an improper attitude that simulates deformity is the first step toward permanent distortion, particularly in individuals who by inheritance or by constitutional tendency or by occupation are predisposed to it.

Prevention of Deformity.—Prevention includes the avoidance of all the predisposing or exciting causes of weakness as well as of deformity. These it is hardly necessary to enumerate.

The first and most important preventive measure is the discovery of deformity or the tendency to deformity at a time when it may be checked or cured. To discover deformity at this period of its development one must look for it; thus, the regular inspection of the naked bodies of the children under his care should become a routine practice of the family physician. Deformity in this sense includes not only fixed distortions, but improper attitudes and postures of every variety as well.

The importance of the attitude which is habitually assumed during occupation has been mentioned. Therefore the provision of proper *desks and seats for school-children* is a very essential part of preventive treatment.

The seat of the chair should be deep enough to support the thighs, yet it should not interfere with flexions at the knees. It should be of such height as to allow the feet to rest firmly on the floor, and it should be inclined slightly backward. The back of the chair should extend to about the level of the shoulders; it should be inclined slightly backward, but arched somewhat forward in the lumbar region in order to conform to the normal lordosis when the child sits in the erect posture. The desk should be as close to the body as is possible, so that the child need

not lean forward when reading or writing. The height of the desk should be slightly less than the level of the elbows when the child sits erect, and the inclination should be sufficient to hold the book at the

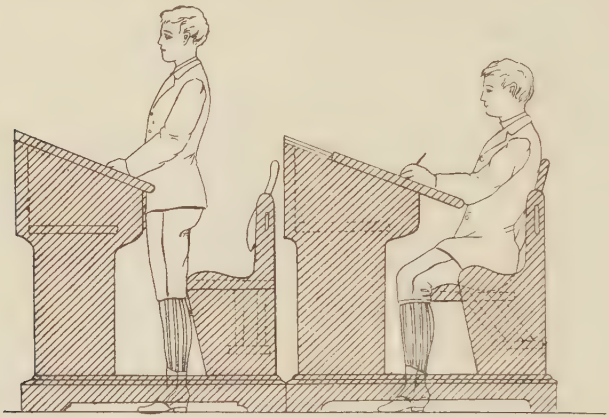

FIG. 144.—Adjustable school desks and seats. Scheiber and Klein. (Redard.)

proper distance from the eyes (Figs. 144 and 145). The vertical hand-writing is of advantage in that the children are taught to face the desk squarely, as contrasted with the lateral twist of the body, the usual attitude for writing.

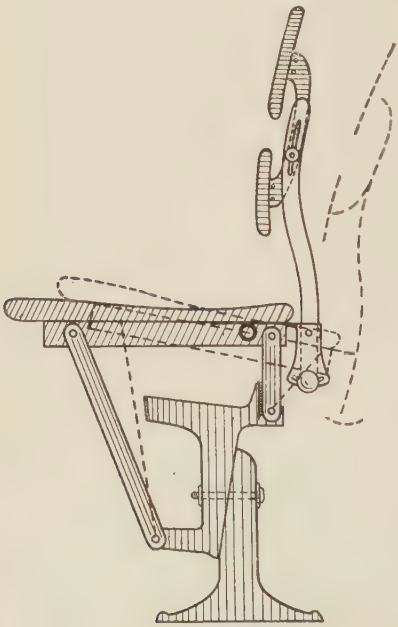

FIG. 145.—Adjustable school seat. (Miller and Stone.)

Treatment.—The treatment of rotary lateral curvature of the spine does not differ in character from the treatment of any other weakness or deformity, but as the application of the treatment is difficult the results are far from definite and satisfactory. This explains, doubtless, the apparently opposing theories and methods of treatment that are still advocated.

Principles of Treatment.—The principles of the treatment of any form of weakness not directly induced by disease may be summarized as follows:

1. To correct deformity.
2. To overcome all restriction to passive motion.
3. To strengthen the weakened muscles, especially those whose action is opposed to habitual deformity.

4. To prevent as far as may be overfatigue and predisposing postures.
5. To support the weak part by a brace if deformity cannot be prevented otherwise.

In applying these principles to the treatment of the distorted spine, the removal of restriction to passive motion in all directions, is difficult because of the variety of muscles and other tissues that may have become involved, and because the bodies of the vertebræ lying within the trunk, of which the distortion is always greater than of the spinous processes, can be only indirectly affected by voluntary or by passive movements.

The cultivation of the muscular system, and particularly of those muscles whose action is opposed to the habitual deformity, as applied to the trunk, is difficult, because there are in nearly all developed cases two curves, the one primary and the other secondary, in direction directly opposed to one another. These opposing curves are supplied in great part by the same muscles, and it is difficult by voluntary effort to lessen the convexity of one without at the same time increasing that of the other.

The avoidance of predisposing attitudes and fatigue is especially difficult because the restful sitting posture is that which predisposes deformity. Thus, only in recumbency is the spine entirely relieved from weight, and even at such times the deformity may be favored by the habitual attitude of the patient.

Finally, the spine cannot be supported without at the same time restraining its normal motion. Nor is any brace perfectly efficient, for while it may prevent the lateral deviation it can exercise little direct action on the rotation of the spinal column.

It is apparent then that it is not the difficulty of formulating principles, but the difficulty of applying them that makes the therapeutics of rotary lateral curvature of the spine perplexing. In practice one must recognize the limitations of all systems of treatment as applied to this particular deformity, and select and combine methods that may be most applicable to the particular case under treatment.

For example, in the treatment of *rhachitic scoliosis* in a young child one cannot count upon the voluntary assistance of the patient; therefore treatment by simple gymnastic exercises is impracticable. In this class of cases forcible correction of the deformity and retention by a support combined with massage and methodical manual correction, and even the removal of the superincumbent weight by recumbency on the stretcher frame, would be treatment of selection. By such means one may hope at this period of rapid growth to induce a transformation of the deformed vertebral bodies to an approximation at least of the normal. The correction of deformity, which must almost inevitably increase with the growth of the patient, would quite outweigh the disadvantage of depriving the muscles of their normal stimulus during the corrective period of treatment.

In the *ordinary type of mild deformity* in older subjects one would expect to attain the best practical results by gymnastic training and by regulation of the postures.

The advisability of a change of occupation has been mentioned. It is probable that if the patient with incipient or even more pronounced curvature of the spine were removed from school, were transferred to the country, where during the succeeding years of childhood and adolescence much of the time might be passed in active exercise in the open air, the final result would compare very favorably with that attained by active treatment under less favorable circumstances. Such complete change of occupation and surroundings is, of course, impracticable in most instances. Lateral curvature of the spine is not a serious disease, it is simply an insidious distortion which rarely causes more than comparatively slight discomfort. It is usually overlooked in the incipient stage when it might be checked or cured, and when the deformity finally attracts attention it is often no longer amenable to correction. Under these circumstances, with the uncertainty that exists as to the ultimate prognosis, the tediousness of treatment which cannot offer the assurance of definite cure, it is readily apparent why the affection is not one for the treatment of which any great sacrifice is considered essential.

A third class of cases would include the *fixed deformity in older subjects*, many of whom are obliged to assume in their occupations attitudes that predispose to deformity. In the treatment of this class a support to relieve discomfort and to prevent exaggerated distortion may be essential.

Thus there are four classes or types of scoliosis in which distinct methods of treatment may be employed:

1. Curvatures in very young children, in which correction and fixation are indicated in the hope of inducing a transformation of the bones and other tissues by natural outgrowth.

2. The milder degrees of deformity for which treatment by exercises and by favoring postures is that of selection, and in which support is a temporary and incidental adjunct, the class also in which forcible methodic correction offers a prospect of cure.

3. The more advanced cases in which support should be combined with corrective exercises or for which operative treatment is indicated.

4. Fixed deformity in older subjects, and those cases caused by disease; as, for example, by paralysis, by empyema and the like, for which constant support may be required.

As a rule, however, no absolute therapeutic distinction can be made, and treatment by exercises and postures should be employed whenever practicable in all cases, whether supports are used or not.

Posture and Exercises.—Whatever may have been the original cause of the distortion of the spine and whatever may be its degree, it is more noticeable when the patient is fatigued. Fatigue in the normal individual is evidenced by an increase of the normal anterior-posterior curves; fatigue in the deformed subject causes an increase in the pathological curves. It requires far more muscular effort to hold the deformed spine in the best possible attitude than to hold the normal spine in the correct posture. Motion in the normal spine is as free in one direction

as in another, and it simply requires a proper balancing of the muscular force to hold it in the median line. But when there is a fixed deformity, to overcome which, even in part, requires the conscious effort of the patient, it is evident that on the relaxation of this effort the spine will sink back into the habitual posture. The more confirmed the deformity the greater must be the effort to overcome it, and the more rapidly will fatigue be manifest. Fatigue, or, rather, the relaxation of conscious muscular effort, is favored by attitudes that do not require the balancing action of the muscles. For example, the sitting posture during school hours favors deformity, while the constant alternation of postures in work or play that requires muscular activity opposes it. Thus, the selection of occupations, or, at least, the restriction of the time passed in inactive postures, is an important part of treatment.

As improper attitudes are favored by weakness of muscles, and as the maintenance of the best possible position requires a greater expenditure of muscular force than is required in the normal individual, the strengthening of all the muscles of the body, and particularly of those of the back, by gymnastic exercises, even beyond the normal standard, is the most important indication in treatment.

One of the most effective systems of treatment by gymnastics is that introduced by Teschner, of New York. On the theory that lateral curvature is induced by or that its development is favored by a general lack of muscular strength and lack of muscular control and coördination, Teschner urges the necessity of the systematic cultivation of all the muscles of the body as well as those of the trunk, the part particularly at fault. He also insists upon the importance of exercising each muscular group to the point of fatigue on the theory that a muscle cannot be developed to its full capacity unless it is thoroughly fatigued by uninterrupted automatic contractions and relaxations. The term automatic implies that the patient shall be so thoroughly trained in the rhythmical movements that they require no thought for their performance. Thus, ease and grace may replace awkwardness and incoördination.

The system is modified from one taught by Attilla, a "trainer of strong men." It consists of a series of exercises with light dumb-bells, and it is supplemented by so-called heavy work. The exercises are designed for systematic cultivation of all the muscles of the body, the heavy work more directly for the correction of the deformity of the spine.

General Exercises.—The exercises should be performed before a mirror, the patient being clad in a close-fitting rowing suit, so that the attitudes may be constantly observed by the patient and by the instructor. The greatest attention is paid to the perfection of the alternating movements of the limbs in order that they may become in time purely automatic in character. During the performance of the exercises the patient holds himself in the best possible position.

These exercises were described and illustrated by Teschner in the

Annals of Surgery for August, 1895, from which they are, with his permission, reproduced.

"A pair of dumb-bells, weighing from one-half to five pounds each, according to the ability of the patient, is used in a series of twenty-six exercises.

"The Exercises.—The patient stands erect, the heels together, the toes apart, the knees thoroughly extended, the abdomen retracted, the chest high, the head well poised, and the patient looking intently and sharply into his or her own eyes in the mirror, the lips being evenly but not too firmly closed, and the facial muscles in repose. The patient should breathe easily and regularly while exercising (Figs. 146 and 147).

Fig. 146

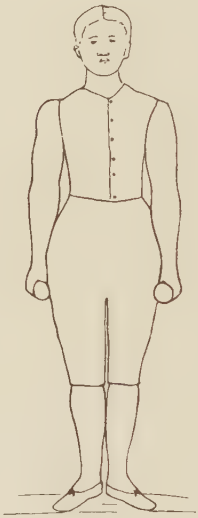

Fig. 147

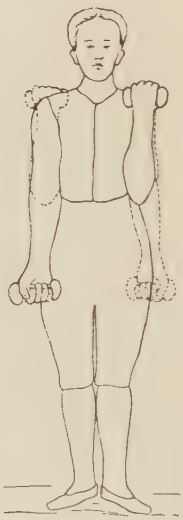

Fig. 148

"1. The upper extremities are fully extended downward, the forearms supinated, the elbows remaining close to the sides of the body, and the upper arms being fixed; the forearms are alternately and automatically fully flexed and extended, the wrists and entire body being fixed and immovable. Twenty to fifty times (Fig. 148).

"2. The same position and exercise, except that the forearms are fully pronated, and remain so during alternate flexion and extension. Twenty to fifty times (Fig. 149).

"3. Both bells over the shoulders, the arms abducted at right angles to the body and in the same vertical and horizontal planes, the forearms fully flexed upon the arms, and the wrists fully flexed upon the forearms. The forearms and wrists are then alternately and automatically extended and flexed. Ten to twenty times (Fig. 150).

"4. The same position and exercises, except that both upper extremities are flexed and extended at the same time. Five to fifteen times (Fig. 151).

Fig. 149

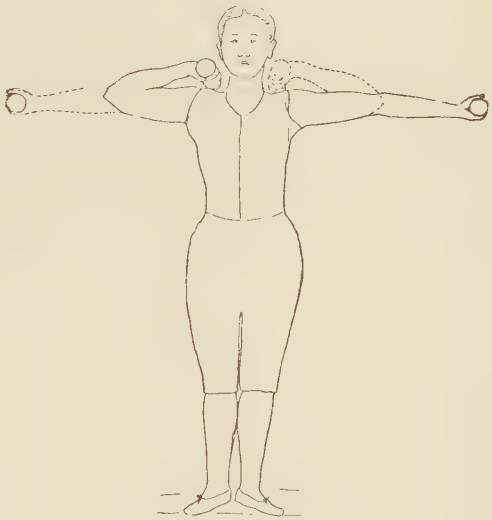

Fig. 150

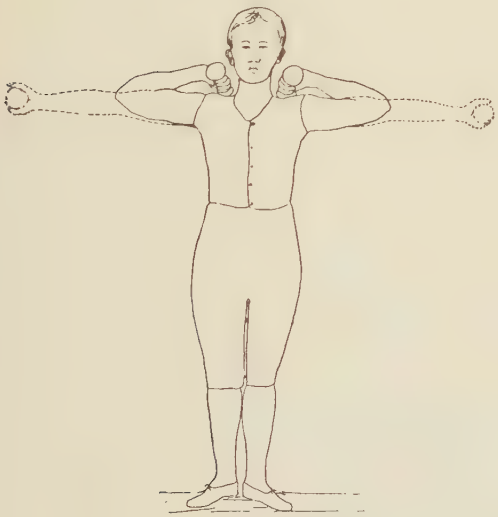

Fig. 151

Fig. 152

"5. Both upper extremities fully extended forward on a level with the shoulders, the dorsum of the hands outward. They are then fully and forcibly abducted on a horizontal plane, the patient at the same

time raising the body upon the toes, and are then permitted to recede to the original position, the body resting on the toes and heels, the

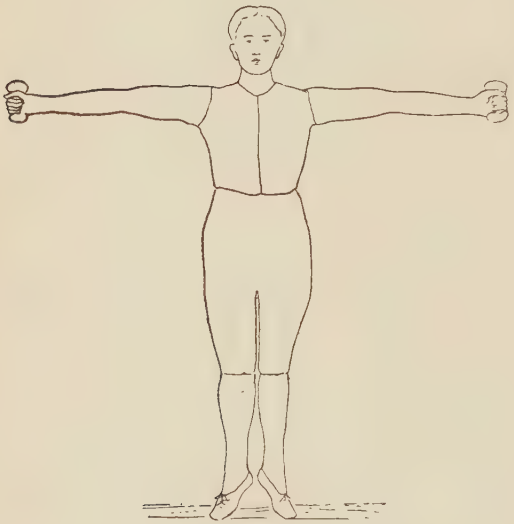

FIG. 153

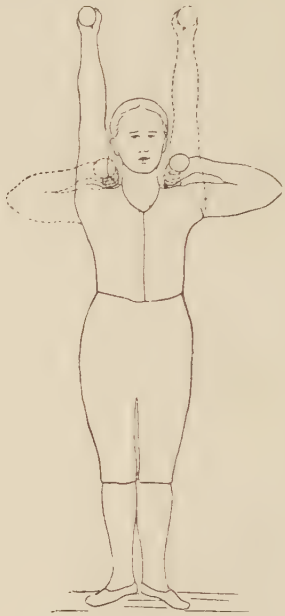

FIG. 154

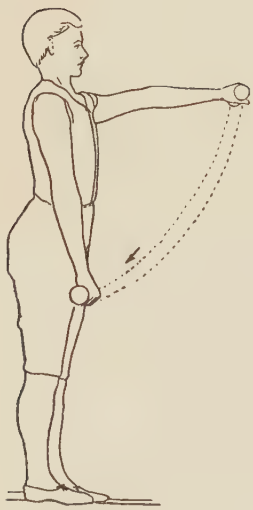

FIG. 155

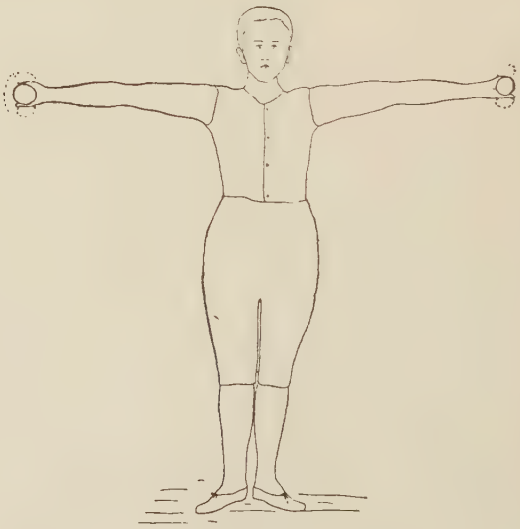

FIG. 156

elbows and wrists still rigid, the bells not being permitted to touch as they approximate each other. Five to ten times (Fig. 153)

MEDICAL LIBRARY

"6. Bells in the position of exercises No. 3 and No. 4. The arms are fully extended alternately above the head. Ten to twenty times (Fig. 154).

"7. Bells in front of the thighs, forearms pronated, and bells alternately raised to the level of the shoulders, the elbows and wrists being fixed. Ten to twenty times (Fig. 155).

"8. The arms abducted at right angles to the body, the bells rotated rapidly and forcibly forward and backward, the elbows being fixed. Five to ten times (Fig. 156).

"9. The arms abducted at right angles to the body, the thumbs upon one ball of each bell, the hands circumducted forward from above

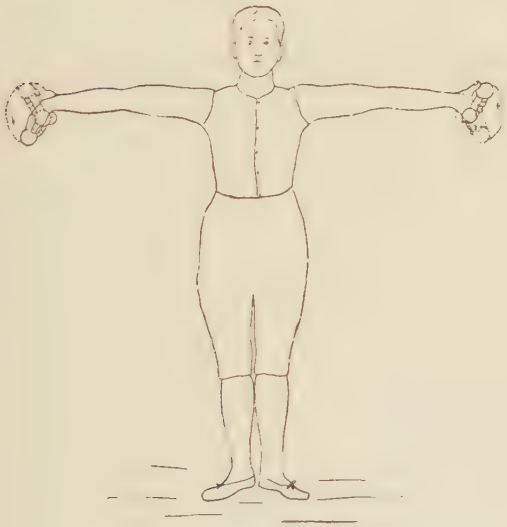

Fig. 157

Fig. 158

downward, the ball upon which the thumbs rest describing circles, the elbows and shoulders being fixed. Five to ten times (Fig. 156).

"10. The same as No. 9, the hands being circumducted backward. Five to ten times (Fig. 157).

"11. The bells to the side. Right face upon left heel, then placing the foot at right angles to right foot opposite the arch, the knees slightly flexed, the right hand at waist line against the body, the bell being perpendicular. Second part of motion: strike from the shoulder to level of the face, advancing a step upon the left foot, rapidly extending the right thigh and leg, the right foot being fixed upon the floor, and quickly back to position. Ten to fifteen times (Figs. 158 and 159).

"12. Exactly the reverse of No. 11. Ten to fifteen times.

"13. Bells extended above the head, palmar surfaces looking forward, bending down to the floor, the knees remaining extended, and return. Five to fifteen times (Figs. 160 and 161).

"14. Bells downward at the sides, raising and dropping the shoulders. Ten to twenty times (Fig. 162).

"15. Bells downward at the sides, flexing the spine laterally, first to the right and then to the left. Ten to twenty times (Fig. 163).

FIG. 159

FIG. 160

FIG. 161

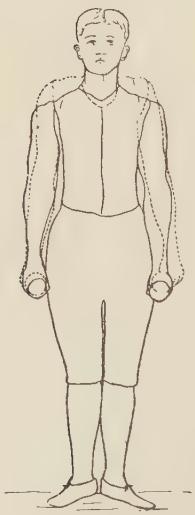

FIG. 162

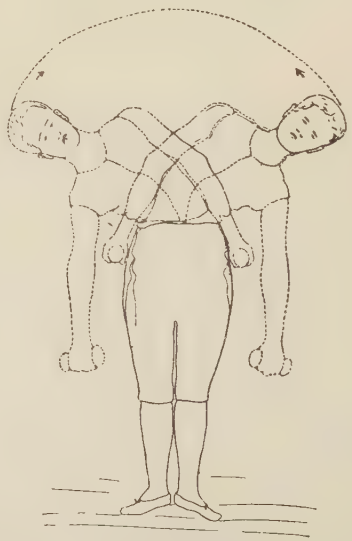

FIG. 163

"16. Both arms are extended forward to about 45 degrees and abducted at about the same angle, then forcibly crossed in front of the chest, causing the pectoral muscles to contract vigorously, the

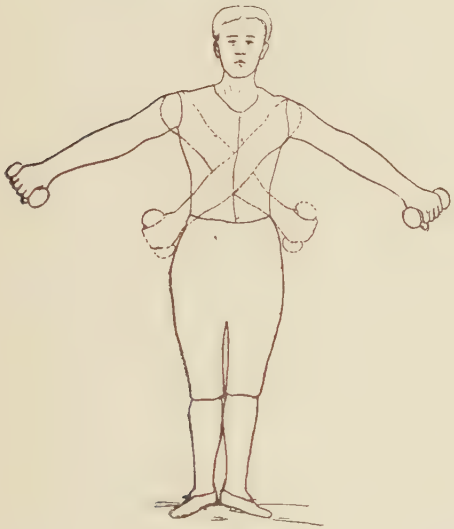

Fig. 164

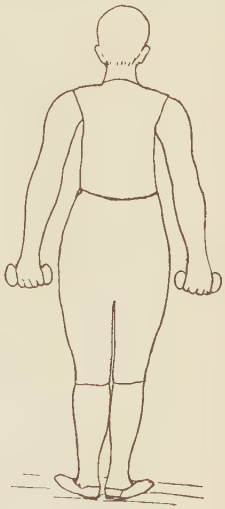

Fig. 165

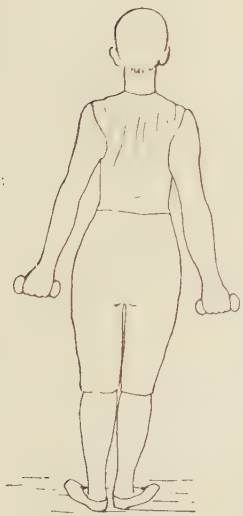

Fig. 166

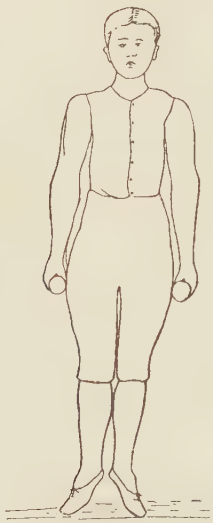

Fig. 167

elbows and wrists being fixed, and then back to the original position. Five to twenty times, alternating the right and left hands above (Fig. 164).

"17. Bells at the sides, palmar surfaces looking forward. Extend arms backward in a vertical plane as forcibly as possible, holding them rigid in the fully extended position for a few moments, and then returning the bells to the sides. Five to fifteen times (Figs. 165 and 166).

FIG. 168

FIG. 169

FIG. 170

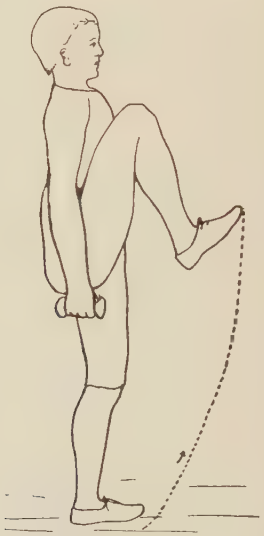

FIG. 171

"18. Bells to the sides. Raise the body upon the toes and sink to the original position. Ten to twenty times (Fig. 167).

"19. Same position. Raise the toes as far as possible from the floor, the body remaining erect. Ten to twenty times (Fig. 168).

"20. Same position. The patient squats, abducting the knees and resting upon the toes, the heels being raised, the trunk perfectly erect, then resuming first position. Five to twenty times (Fig. 169).

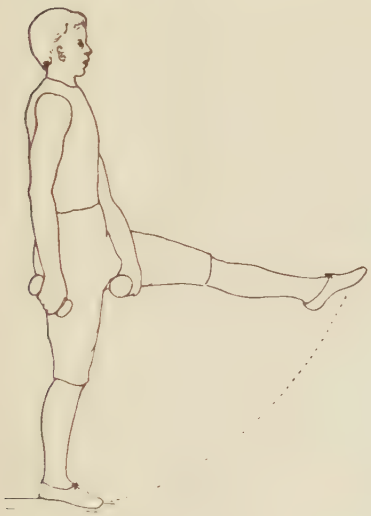

FIG. 172

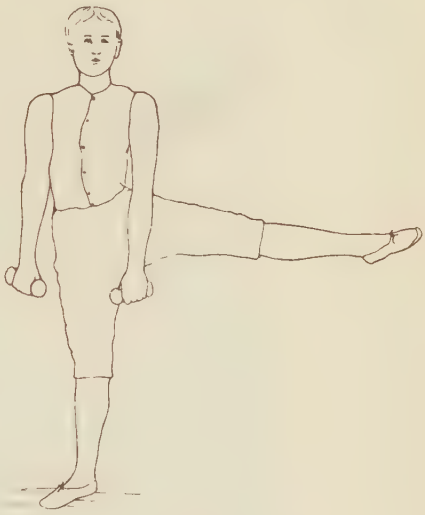

FIG. 173

"21. Same position. Standing upon left foot. Flexing the right thigh to a right angle to the body, extending the knee and ankle fully. The patient squats on the left ham, the left heel remaining on the floor, and then resumes the first position. Two to five times (Fig. 170).

FIG. 174

"22. The same standing upon the right foot. Two to five times.

"23. The same position. Alternately and forcibly flexing the thighs and the legs, causing the knees to touch the shoulders. Ten to twenty times (Fig. 171).

"24. The same position as in No. 21, extending the right lower extremity, the right bell inside the thigh, the right foot moved in a circle on a horizontal plane to complete extension backward, and resuming the first position. Two to five times (Figs. 172 and 173).

"25. The same as No. 24, standing upon the right foot. Two to five times.

Fig. 175.—Scoliosis of an advanced type accompanied by dyspnea and cyanosis. (Teschner.)

"26. The patient lying supine upon the floor, the lower extremities fully extended, the bells resting upon the chest, then raising the trunk to the sitting position, the lower extremities remaining extended, and the eyes being fixed upon the ceiling, and returning to the original position, touching the back of the head only on the floor; thus the hyperextension of the spine is maintained. Five to twenty times (Fig. 174)."

The floor exercises are especially useful, and one may add several others to those described by Teschner, viz.:

27. The patient lying as in Fig. 174, lifts each fully extended leg alternately a distance of about two feet from the floor, then lets it slowly sink to its original position. Ten times.

28. Both limbs together. Five times.

29. The patient lying extended in the prone position, places the palms of the hands on the hips and "looks at the ceiling," overextends the spine as much as possible, then sinks slowly to the original position.



Fig. 176.—The same patient swinging a 30-pound bell, showing the muscular development. (Teschner.)

30. Each leg fully extended is lifted upward alternately as far as possible (hyperextension at the hips). Ten times.

31. Hyperextension at both hips simultaneously if possible. Five times.

"When the patient has become proficient in these exercises, they should be done at home every morning and evening.

"The Heavy Work.—Bells, weighing from five to eighty pounds each, and steel bars and bar-bells, weighing from twenty-six to over one hundred and eleven pounds, are used in different ways. Bells are pushed from the shoulders above the head alternately as often as the patient is able (Figs. 177 and 178).

Fig. 177.—The patient pushing 25-pound bells; the right arm up. (Teschner.)

Fig. 178.—The patient pushing 25-pound bells; the left arm up. (Teschner.)

"The patient is instructed to swing a heavy bell with one hand from the floor above the head and down again, the elbow and the wrist being fixed, and the motion repeated as often as possible in a systematic manner; then with the other hand the same number of times and later with both. This exerts all the extensor muscles from the toes to the head in rapid succession."

(For this exercise the patient stands firmly, with the legs astride of the heavy bell, and then, bending over, he seizes it and throws the extended arm upward entirely by the action of the back muscles. The

bell is poised for a moment above the head, and it is then swung downward, carrying the extended arm between and behind the legs.)

"When a heavy bell is pushed or swung above the head on the side opposite the scoliosis, the action of the back muscles, to sustain the weight and equilibrium, is such as to cause the curved spine to approximate a straight line (Fig. 178). A similar result is produced when a heavy weight is held by the side of the erect body on the scoliotic side, the arm being at full length.

"When a heavy bar is raised above the head with both hands the patient must fix the eyes upon the middle of the bar to maintain an equilibrium. This necessitates the bending of the head backward, the straightening and hyperextending of the spine, and consequently correcting a faulty position with a weight superimposed. The heavier the weight put above the head, whether with one hand or with two, the more the patient must exert himself or herself to attain and maintain a correct or an improved attitude in order to sustain the equilibrium. (By an improved attitude I mean the greatest amount of correction of the deviation of the spine that the fixation of a deformity will allow.) Hence the greater the weight the more forcible the actions of the muscles become, and the greater the temporary reduction of a deformity. It is by means of frequent and forcible temporary reductions of deformities, by voluntary muscular action, that we can hope to improve and do improve, those cases which are amenable to any form of active treatment.

"When a patient, lying supine upon the floor, raises a heavy bar above the head so that the arms are perpendicular to the floor, the weight of the bar, the position and weight of the body, and the action of the muscles tend to broaden the entire back and shoulders, and a slow downward movement tends to widen the entire chest, and most markedly at the shoulders. The frequent repetition of the upward and downward movements plays an important part in the rapid development of the chest and back. Pushing the bells above the head, swinging them with each hand separately and with both hands together, raising a bar above the head, standing and lying down, and the exercises before enumerated, constitute one day's work.

"As the amount of work performed by a patient depends upon the last previous record of that patient, that record must be improved upon at each succeeding visit, unless there be a good reason to the contrary. Most patients can well stand three treatments a week (*vide* table). In mild habitual cases improvement in deportment is noticed by the patient's relatives and friends and by the patients themselves within the first two weeks. In these cases two months' treatment usually suffices to effect a 'complete' cure. In the more severe cases such rapid results cannot be expected, but a certain appreciable improvement is effected, and the amount of improvement depends upon the persistent continuance of the treatment. When there is fixed rotation of long standing, with bony and ligamentous changes, the prospect is not as good; but even in those cases considerable improvement will be evident.

RECORD OF THE WORK PERFORMED BY A GIRL FOURTEEN YEARS OF AGE (TESCHNER).

Date, 1895.	Regular exercises Bells.	Pushing two 10-lb. bells.	Swinging with each hand one 15-lb. bell, right to left.	Swinging with both hands two 15-lb. bells.	Pushing two 20-lb. bells.	50-lb. bar above the head.	
						Standing.	Lying down.
April 6	3 lbs.						
" 9	"	100	10–10	5	..	Instructed	Instructed
" 11	"	150	25–25	15	10	2	5
		Two 15-lb. bells	One 20-lb. bell				
" 13	"	50	25–25	25	12	5	10
" 16	"	54	30–30	35	18	7	12
" 18	"	60	35–35	40	20	7	15
			One 25-lb. bell	Two 20-lb. bells			
" 20	"	70	20–20	20	30	10	15
" 25	"	90	22–22	25	33	15	16
" 27	"	100	35–35	30	50	17	20
" 30	"	110	50–50	35	60	20	22
May 2	"	120	60–60	36	70	20	25
			One 30-lb. bell		Two 25-lb. bells	One 64-lb. bar	One 64-lb. bar
" 4	"	140	20–20	40	25	5	10
" 7	"	150	25–25	45	30	7	12
" 14	"	160	27–27	50	34	9	13
" 16	"	170	30–30	55	40	10	14

"Patients are not permitted to wear supports of any kind, not even corsets. They should not exercise until at least two hours after a meal, nor when menstruating. The general health is improved by the exercises; the patients gain in height and weight. The girth and breadth measurements, chest depth, strength tests, and lung capacity are generally increased, and the depth of the abdomen is usually decreased. In some cases, especially those of undersized patients, the increase in height is very rapid, and it is certainly more than the increase by ordinary growth. There were marked cases of flat-foot which were benefited. The flat feet became shorter through the exercises by the increase in depth of the inner arches."

This system of exercises combines a certain forcible correction of deformity and restoration of mobility by means of the "heavy work" with muscle building. It has the merit also of making an immediate mental impression upon the patient which no other system can make; for if the patient does not "strain every nerve" he must certainly exercise every muscle to preserve the equilibrium while supporting the heavy weights, and this mental impression is, undoubtedly, one of the important elements in successful treatment.

The system has the disadvantage, if disadvantage it may be called, of making class work impossible, for the patient must be under constant supervision, not only that he may be urged to the limit of his capacity, but that overstrain may be avoided as well.

It might appear from the description that the danger of overwork is great, but in a long series of cases, some of which were complicated

by defects of the heart and lungs, no unfavorable symptoms have been observed by Teschner. The system is, however, one that can be practised only by a physician.

Another system of exercises, modified somewhat from the Swedish system, more suitable for class work is that followed at the Hospital for Ruptured and Crippled. Dr. Truslow has outlined for me some of the more important exercises, and illustrated them with the photographs that are reproduced here.

The objects of the treatment are: (1) To overcome the patient's faulty habits of posture by the repeated purposeful assumption of proper postures; in other words, to counteract the deformity habit by training the mental and muscular perception of symmetry. (2) To stimulate and to strengthen the weakened muscles, particularly those muscular groups that are especially concerned in overcoming the deformities, and which, for the present purpose, may be considered as weak.

For convenience of description the exercises are divided into two classes: (1) self-correction; (2) muscle building.

Exercises in Self-correction.—The first exercises (*a* and *b*) in self-correction are for the purpose of overcoming the anterior-posterior deformities that usually accompany lateral deviation of the spine.

(*a*) Head Bending Backward.—In this exercise the chin is not tilted upward, but, the head being held level, the neck is drawn directly backward until the cervical and upper part of the dorsal segments of the spine are completely extended. Thus, by increasing the distance between the points of attachment of the sternomastoids and the scaleni, strong traction is made upon these muscles with the effect of elevating the upper part of the thorax—an important feature in the exercise.

(*b*) Trunk Bending Forward and Trunk Raising.—The patient stands in the erect posture with the spine extended and the chest expanded as in the previous exercise. The trunk is then bent forward (similar to Fig. 184), the only motion being at the hip-joints. The trunk is then raised again to the former position, care being taken to keep the hips farther back than the chest. In both flexion and extension the spine must be rigidly held in the corrected attitude, and there must be no motion at the knees. There is, of course, a movement corresponding to extension at the ankle-joints when the legs and buttocks are thrown backward to compensate for the forward bending of the body. The object of this exercise is to train the patient to keep the hips back and the chest forward.

The other exercises in self-correction are for the purpose of overcoming lateral deviation of the spine, the right dorsal, left lumbar curve being taken as the type (Fig. 179).

This series is arranged in a progression, and each one must be learned before the next in order is attempted.

(*c*) Left Neck Firm.—The left hand is placed behind the neck, the left shoulder is raised, and the left elbow is held well back. This

posture impresses upon the patient the necessity of approximating the left shoulder and the neck (Fig. 180).

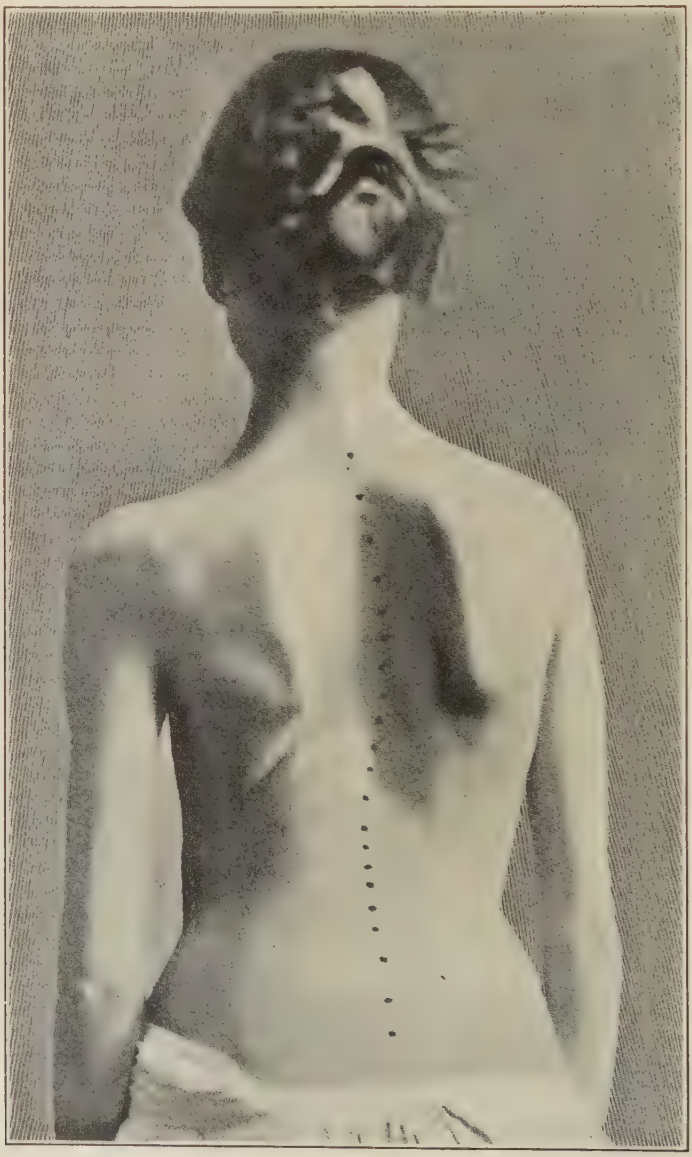

FIG. 179.—Typical lateral curvature. Right dorsal. Left lumbar.

(*d*) BODY INCLINATION TO THE LEFT.—This is a most important posture; it is intended to correct mechanically the faulty inclination

to the right and to overcome the upper curve by traction on its concavity. The patient holding the arm in the first position is instructed to stretch well out with the left elbow, rotating upward and abducting the left scapula as much as possible. This puts upon the stretch the rhomboidei and the lower half of the trapezius of the left side, thus making strong traction upon their points of attachment in the dorsal

Fig. 108.—Left neck firm.

concavity. At the same time the patient is directed to sway the pelvis to the right. This usually requires assistance at first, for it brings into action certain deep back muscles, over which one has ordinarily but little control. The shoulders must be kept level and the proper relation of the head and neck to the left shoulder must not be disturbed in this forced stretch to the left (Fig. 181).

(*e*) Chest Pressing with the Right Hand.—The patient holding the left arm in the first position presses the right hand firmly against the dorsal convexity. This posture may be employed to advantage if there is a long right dorsal curve, when it is an efficient aid to the left-sided pull of the two former exercises.

Fig. 181.—Body inclination to the left.

(*f*) Right Neck Firm.—The right hand is placed behind the neck, without, however, disturbing the improved position induced by the first exercises. With both hands placed behind the head, the arms being in a symmetrical position, there is better mechanical fixation of the head, neck, and upper part of the trunk during the next exercise (Fig. 182).

(*g*) Left Hip Twisting Backward.—In posture (*d*) the pelvis was swayed slightly to the right; it is now twisted slightly backward on the

left side to overcome the twist in the lumbar spine which usually throws this side of the pelvis somewhat forward. This correcting motion should be carried out in the lower dorsal and lumbar segments, and it should not affect the attitude of the remainder of the trunk.

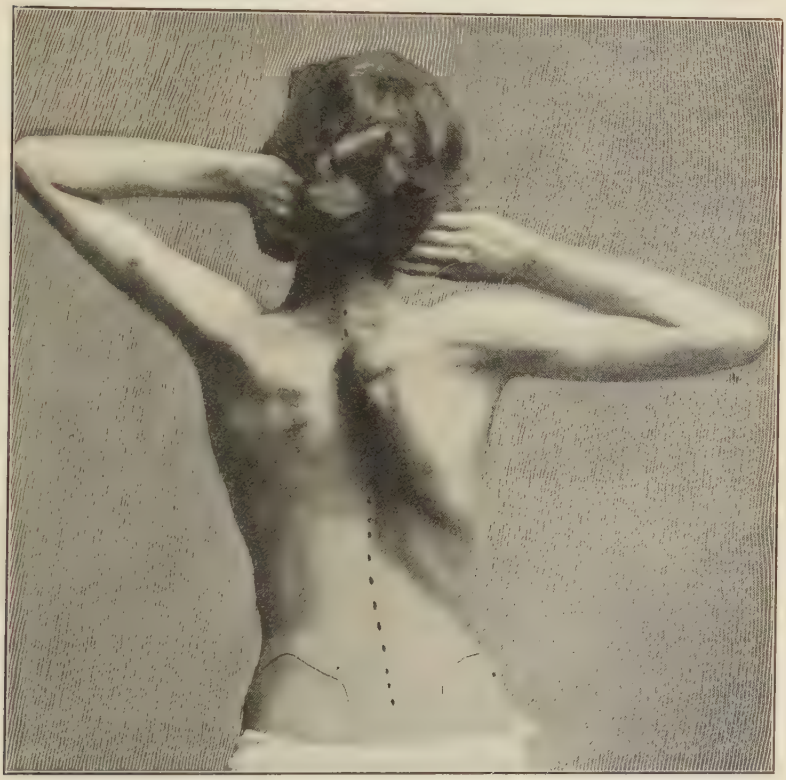

Fig. 182.—Right neck firm.

(*h*) Left Oblique Stride Standing.—The pelvic twist and right-sided sway being rigidly maintained, the left foot is placed about two foot-lengths forward and a little outward. Upon this leg the greater part of the weight of the body is now supported. This allows a slight downward tilt of the pelvis to the right, and lessens the left lumbar convexity (Fig. 183). The positions attained by the progressive exercises to this point being maintained, the patient continues with—

(*i*) Trunk Bending Forward.—In this posture motion takes place in the hip-joints only, as in the first exercise. This exercise further emphasizes the symmetrical position of the head and neck, the left-sided inclination of the upper half of the trunk, the right-sided inclination of the lower half, the twist and downward tilt of the pelvis (Fig. 184). The return to the improved standing position should be made

in this order: (1) trunk raising; (2) replacement of the left foot; (3) return of both arms to the sides. This is done slowly and carefully by the patient, who attempts to maintain the improved posture.

FIG. 183.—Left oblique stride standing.

The postures constitute a progression which cannot be learned in less than seven treatments; often much more time is required. As

MEDICAL LIBRARY

each part is learned it should be practised at home until the next treatment, when a new posture is added, if it appears that progress can be made.

Fig. 185.—Trunk bending forward.

These successive postures are in reality exercises in that it requires constant muscular effort to retain them, but they are not exercises in the sense of repeated alternations of position. The series is simply an elaboration of what is called the key-note posture. The raising of the left elbow, for example, makes it easier for the patient to overcome the distortion of the upper part of the spine; it also instructs him in the manner of holding the spine in the improved position after the arm is placed by the side.

The same is true of all the postures; each one suggests and makes correction easier, and after sufficient practice the patient should be able to assume the correct position without placing the arm or the leg in the preliminary attitude. Thus the successive postures are, as it were, letters, which, placed together one by one, make a complete word, or the best possible position that the patient can assume. At first the patient must use the letters and slowly spell out the corrected attitude, but after the muscles have been educated by the repeated assumption of each posture, and when the perception of symmetry has been acquired, the corrected attitude may be assumed at will. Finally, the improved posture will be instinctively retained, and will become habitual.

Muscle-building Exercises.—In the treatment of lateral curvature one aims to strengthen:

1. The posterior cervical muscles.
2. The dorsal and lumbar muscles.
3. The muscles of vertebro-scapular attachment.
4. The abdominal muscles.
5. The thigh and leg muscles.
6. The chest expanding muscles.

The following exercises have been selected as best adapted for this purpose. Each one should be performed five or more times according to the strength of the patient.

(*a*) Opposite Standing, Head Bending Backward, Resisted.—The patient stands before a wall or a shoulder-high horizontal bar, on which the hands are placed with the arms extended. The head is bent forward, and is then forced backward, the latter movement being resisted by the hand of the surgeon. This exercise is designed to strengthen the posterior cervical muscles.

(*b*) Opposite Bend Standing, Trunk Raising, Resisted.—The patient stands with the upper part of the thighs in contact with a table or horizontal bar. The hands are placed behind the neck and the body is bent forward on the hip-joints as in the first exercise. The surgeon, standing behind, places his right hand over the posterior dorsal prominence and his left over the lumbar projection. The patient then raises the trunk to the erect position against the combined resistance (Fig. 185). With a little practice the surgeon learns to give an outward twisting motion to his hands while resisting, which tends to untwist the spinal rotations. When the dorsal rotation to the right is marked this untwisting may be facilitated by encircling the patient's chest with the left hand, while with the right, strong forward and outward pressure is made as the patient raises the body. This exercise is for the purpose of developing the muscles of the erector spinæ group.

(*c*) Prone Lying, Head and Shoulder Raising "the Seal."—The patient lies upon a table or upon the floor, and raises the head and chest—"looks at the ceiling." Progression is made in the increased leverage of arm-weight transference.

1. With the hands on the backs of the thighs.

2. With the left hand behind the neck and the right hand on the back of the thigh.

3. With both hands behind the neck and with the elbows well out and back.

Fig. 185.—"Opposite bend standing," trunk raising, resisted.

4. "Swimming." The arm motions of swimming, in three counts. This exercise is to strengthen the muscles of the back from the head to the pelvis.

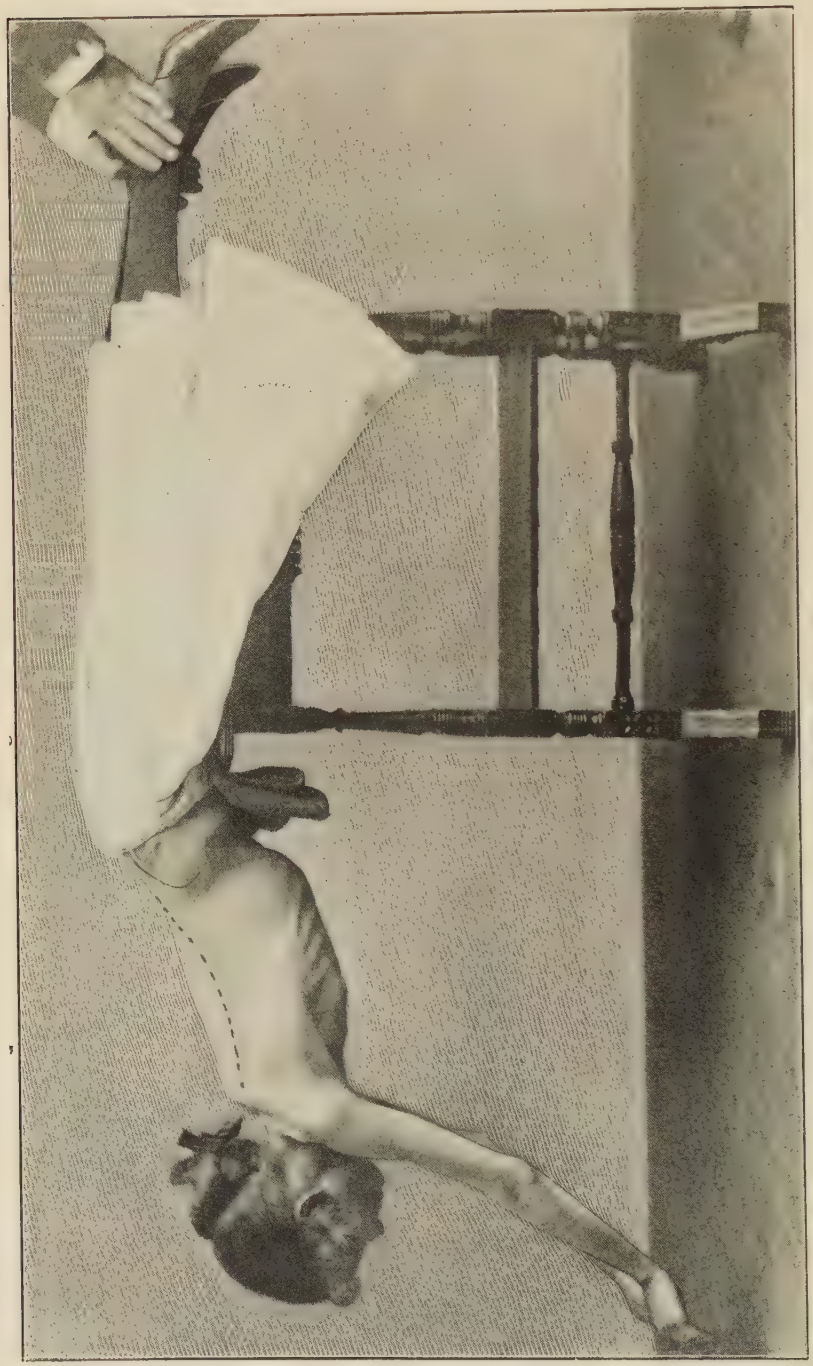

FIG. 186.—Prone lying, "diving."

(*d*) Prone Lying, "Diving."—The patient lies upon a table, the trunk and pelvis projecting beyond its edge, the limbs being fixed by a strap or the weight of another person. The body is then bent downward and is raised again to the horizontal position (Fig. 186). In this exercise assistance will be required at first. Progression is made by transference of arm weights, as in the former exercise, thus:

1. With the hands on the hips.
2. With the arms stretched out at right angles to the body.
3. With the hands behind the neck.
4. With the arms extended in the line of the body.

This exercise is for the purpose of strengthening all the muscles of the back.

(*e*) Prone Lying, Leg Raising.—The patient, lying in the prone posture upon the floor or table, lifts the limbs (overextends) alternately, the raised leg held perfectly straight. When the left thigh is extended, as much as the iliofemoral ligament will allow, the left side of the pelvis is tilted upward also, thus untwisting the lumbar spine. Progression in this exercise is made as follows:

1. Alternate leg raising, unresisted.
2. Alternate leg raising, resisted.
3. The leg motions of swimming in three counts.

In this exercise the entire lower extremities must project beyond the supporting table. The exercises are for the purpose of strengthening the lumbar muscles and the extensors of the thigh.

(*f*) Opposite Sitting, Backward Bending of the Trunk.—The patient is seated upon a bench and the feet are fastened to the floor. The trunk being held in a position of complete extension, is bent slowly backward, motion being at the hip-joint only. Progression.

1. With the hands behind the hips.
2. With the left hand behind the neck, the right hand on the hip.
3. With both hands behind the neck.
4. With both arms extended upward.

At first the body is bent backward about forty-five degrees, later until the head touches the floor. This exercise is to strengthen the abdominal muscles.

(*g*) The Horizontal Bar. "Pull-ups."—The patient hangs by the hands and is assisted to "chin the bar." The body is then allowed to sink slowly back into the former position, the elbows are held well back, and the patient is instructed to bear as much of the weight as is possible with the left arm and shoulder. This exercise corrects the dorsal curve by means of muscular activity and the lumbar curve by the weight of the suspended pelvis and limbs. The muscles used are those with vertebro-scapula attachment.

(*h*) Left Leg Standing, Pelvis Tilting.—The patient stands upon the edge of a bench, supporting the weight on the left leg, the right leg being suspended beyond the side of the bench. While the head and trunk are kept in the corrected position, the pelvis is made to tilt sharply downward on the right, by lowering the right leg, while



FIG. 187.—Lateral curvature.

FIG. 188.—The same patient, showing fixed rotation to the right in the thoracic region. (See Figs. 189 and 190, illustrating a simple corrective exercise that may be carried out by the patient.)

FIG. 189.—The patient shown in Figs. 188 and 189 inclines the body to the right, pressing the projecting ribs in with the right hand.

FIG. 190.—In the picture shown in Fig. 188 the patient inclines the body forward. The correction is illustrated by comparison with Fig. 190 in the same position.

the left is kept perfectly stiff. This has the effect of straightening the lumbar curve.

(*i*) Left Leg, "Hopping."—Both hands are placed behind the neck and the weight is supported entirely upon the ball of the left foot. In this attitude the patient hops ten or more times. This exercise, like the last, tends to straighten the spine and to strengthen the muscles of the left leg, which are often somewhat weakened from disuse.

(*j*) Respiratory, Half Reclining, Arm Extensions and Flexions, Resisted.—The patient sits in a chair with an inclined back, or lies upon a low table with hard pillows under the mid-dorsal region, so that the upper dorsal and cervical segments of the spine must be overextended. The arms are stretched upward and backward, and the hands are grasped by the surgeon, who stands behind and resists the patient's downward pull. With the upward stretch of the arms and pull by the surgeon the patient inhales forcibly. With the downward pull against resistance the patient exhales forcibly. This exercise is made in the rhythm of slow breathing.

When the patient has been thoroughly instructed in self-correction and in the exercises for muscle building, general gymnastics for systematic motor training may be given effectively to groups of fifteen or twenty pupils.

The exercises illustrated on pages 199 to 202 will serve this purpose satisfactorily.

These two systems of treatment by gymnastics have been selected as the most practicable of the many that have been devised. It may be stated that any treatment that makes the spine more flexible, that overcomes faulty attitudes, and that strengthens the muscles, must be of service to the patient, the degree of benefit corresponding to the persistence and energy of the pupil and the instructor rather than to any particular theory on which such treatment is based. The rotation of the vertebral bodies is increased by forward bending of the trunk, and, as this is the more important element of lateral curvature, it is evident that extension or overextension of the spine, combined with lateral twisting in such a manner as to reverse the habitual inclination, will most directly lessen or correct the distortion. Exercises of this character are far more effective than are elaborate systems of general gymnastics (Figs. 189 and 190).

Corrective Treatment Combined with Support.—It should be evident that treatment by gymnastic exercises, during which the deformity is but partly corrected and after which it is permitted to recur, cannot be curative. From this treatment one may hope for such improvement in the general condition, in the muscular strength and flexibility of the spine as will enable the patient to hold the body at will in better position and thus to check the progress of the deformity and to mitigate or conceal its effects.

In cases, therefore, of resistant deformity, or when for any reason simple gymnastic treatment is unsatisfactory, the following method

MEDICAL LIBRARY

of forcible methodic correction combined with support may be employed with advantage.

The plaster corset is the most practicable support because it may be applied directly by the one who conducts the treatment and thus it may be modified and renewed at frequent intervals.

It should be applied in the upright attitude as described under Pott's Disease. By suspension the normal relation of the trunk to the pelvis may be restored in great degree and the direct deformity in part reduced.

The corset should press upon the projecting ribs, but not upon the flattened part of the trunk; depressions therefore should be filled by padding beneath the shirt. If the patient is a female, pads of cotton should be placed below and in front of the breasts to prevent pressure.

Fig. 191.—Correction of a left lumbar rotation by natural leverage.

A plaster jacket is applied in the usual manner, the deformity being further corrected by pressure with the hands during the hardening stage. It is then removed and is bound and fitted with hooks for lacing.

The patient is provided with an apparatus for self-suspension so that the corset may be removed and adjusted in the original position.

The active treatment is conducted somewhat as follows: The patient is placed face downward on a narrow table, in the absence of assistance clasping it with the arms to fix the thorax. One then attempts to reduce and if possible to overcorrect the deformity by hyperextension and by lateral flexion of the trunk. Thus, if the primary lumbar curvature is to the left, the operator standing on this side of the table and with the left hand pressing downward on the convexity, with the other lifts the right thigh of the patient, hyperextends it and draws it

upward and toward the left, lifting and turning the pelvis in a manner to untwist the spine (Fig. 191).

This movement is carried out over and over again in the "pump handle" manner, the patient assisting and eventually gaining the ability to throw the limb backward and to the side without assistance. The dorsal curvature is corrected in the same manner by passing the arm beneath the thorax of the patient, hyperextending the trunk and at the same time rotating it in a manner to overcome the deformity. The manipulation, lasting about twenty minutes, should be repeated at least twice daily; the corset is then applied and it may be worn with advantage during the night (Fig. 193).



FIG. 192.—Correction of a left lumbar curvature by natural leverage, illustrating the application of greater force.

As the spine becomes more flexible so that it may be still further corrected, new corsets are applied. During the day self-suspension at intervals is of service and the patient should from time to time assume the key-note posture, endeavoring to correct the deformity beyond the degree enforced by the corset. Massage of the muscles of the trunk and self-correction exercises are useful in supplemental treatment.

By this method a continuous and satisfactory improvement is often apparent. Eventually the plaster support may be replaced by an ordinary stiffened corset.

In this method of treatment the plaster corset serves only as a retention brace, the correction of the deformity being accomplished by the manipulation and exercises. In other instances when the supplementary treatment is impracticable, as in the hospital class, a fixed

jacket may be employed, more corrective force being used in its application.

For example, the patient may be suspended in the prone posture on a strip of cotton cloth (the hammock method). As this sinks under the weight the trunk falls into the attitude of overextension, which is desirable in cases in which posterior curvature is marked, or the body may be suspended in the lateral attitude by means of a sling of cotton cloth passed about the prominent ribs, so that the weight of the body acts as a correcting force during the application of the corset.

FIG. 193.—Correction of a left dorsal curvature by natural leverage.

In using such corrective force one endeavors, if possible, to overcorrect the habitual deformity and the less marked changes in the anterior-posterior contour as well. For example, if the lumbar region is flat one attempts to reproduce the normal lordosis, and if the body is habitually inclined in one direction one endeavors to sway it to the opposite side and to efface the so-called high hip. These jackets are changed at frequent intervals. They are particularly indicated in deformity of the paralytic or rhachitic type in young subjects.

Another form of corrective support is the jacket applied after the Calot method in which corrective pressure is made by means of pads, a "window" having been cut out on the flattened or concave side to permit expansion. In treatment by fixed supports in which pressure is exerted on the deformity and space provided for correction the respiratory movements of the chest are an aid in rectification. Greater corrective force may be applied by machines as illustrated in Fig. 194, the jacket being applied to include the pressure pads.

The Abbott Treatment.—It has been stated that cure of the deformity of the spine as elsewhere implies primary overcorrection, fixation for a time sufficient to permit accommodation to the new position, and finally the reëstablishment of the muscular balance in order to maintain it.

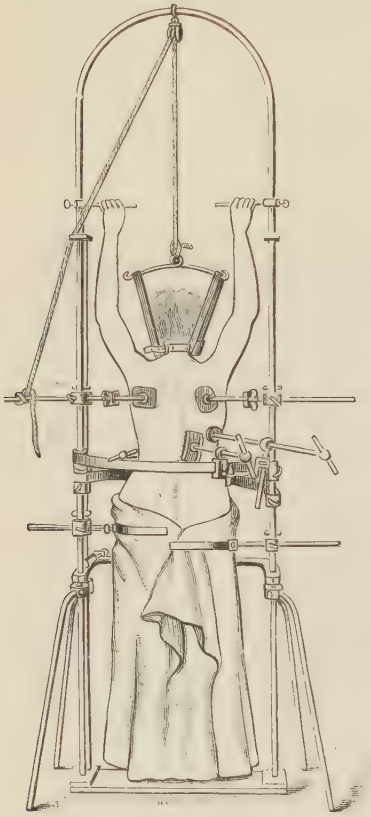

Fig. 194. — Forcible correction by means of the modified Hoffa appliance. (Bradford and Brackett.)

Although the application of the principle had been attempted by Hoffa, Wullstein and many others, it had always been considered impracticable in the great majority of cases for various reasons.

In 1911 Dr. E. G. Abbott[1] announced that the problem of efficient treatment had been solved and in a subsequent article,[2] representing two years of work, he presented his conclusions as follows:

"In a previous article the statement was made that fixed lateral curvatures of the spine yielded to treatment as easily as bow-legs or club-feet. Further experience has led me to believe that this deformity yields far more readily than either of the others."

Dr. Abbott in support of his contention presented the logical proposition that flexing and thus relaxing the spine was the first essential of correction, and that forcible correction had thus far been ineffective because it had been attempted with the spine extended. For although Lovett[3] had called attention to the fact that relaxation favored the reduction of rotation and had applied jackets with the patient supported in the prone position, forced flexion had apparently never been attempted.

The novelty of a method applying surgical principles, supported by unqualified statements of its success in the treatment of fixed lateral curvature, a class of cases considered as incurable, attracted wide attention, and it will be presented in Dr. Abbott's words.

"Lateral curvature is a simple deformity which can be created artificially and as easily corrected.

"To effect a cure the spine must be flexed and drawn to one side

[1] New York Med. Jour., June 24, 1911.
[2] Ibid., April 27, 1912.
[3] Lateral Curvature of the Spine, Boston, 1907.

by force exerted in the direction opposite to that of the fixed curve, and that, together with this, the low shoulder and the depressed ribs must be elevated and forced into a position posterior to that of the high shoulder, and bulging ribs in a patient must be placed in a position which is exactly opposite to that of the original deformity, and that with the spine flexed."

This attitude was attained by placing the patient on the back in a sagging hammock and then forcing the trunk into an attitude of apparent overcorrection by the tension of bands passed about it. A plaster jacket was then applied in which openings were subsequently made to permit further correction by the insertion of pads, as in the Calot method for the correction of the deformity of Pott's disease.

Abbott's detailed description of the application of the jacket on the frame then employed is as follows:

A frame and hammock similar to those in applying corsets in Pott's disease is employed.

The frame is made of gas-pipe in the usual dimensions: Length, five and one-half feet; width, twenty-six inches; and height, thirty inches.

The front legs are so constructed that they may be shortened twelve inches, while the rear ones may be lengthened eighteen inches. Across the front at the top is a rod of half-inch steel to which is attached one end of the hammock. In a similar position at the rear is a windlass with a ratchet, over which pass two cords, about three feet in length, terminating in loops, which slip over the extremities of another steel rod, which is passed through the hem of the other end of the hammock. By this means the hammock is held in a horizontal position and can be stretched or made to sag at will. A movable cross-piece of iron about three inches wide is placed across the frame near its center beneath the hammock. To this cross-piece is attached a light framework, about two and one-half feet long, made of half-inch iron, the rear end of which may be raised and held at any angle by a prop. Between the upper side rails of the frame, about six inches from its forward end and just beneath the hammock, is stretched a two-inch strap of leather or webbing.

The hammock itself is made of light duck about a yard in length and fifteen inches in width, and is cut diagonally across its head (Fig. 195). Its ends are turned over and sewed firmly, leaving a hem through which may be passed the steel rods which hold it to the frame. When the hammock is placed on the frame, as one side is seven and one-half inches shorter than the other, it is straight or nearly so on the short side, while on the long side it sags several inches (Fig. 196).

A cradle is thus formed in which a patient may be put and forced into an overcorrected position. The buttocks are placed upon the cross-piece; the head rests upon the front of the hammock; the strap supports the neck; the straight side of the hammock pushes the bulging ribs forward; the long side gives room for the depressed ribs to be pushed backward; the framework on which the lower limbs rest



FIG. 195.—Frame, with hammock hanging on the wall.



FIG. 196.—Frame with hammock attached.

elevates them; and the adjustable legs allow of tilting the frame, so that the body weight will assist in forcing the patient into the desired position.

In preparing the patient considerable care is necessary in order that the corset may not irritate the skin or cause sloughing of the tissues.

Saddler's felt is used for pads over all bony prominences. The rule followed in the Children's Hospital is to put two undervests on the patient so that the pads may be placed between them rather than next to the corset. Thus the felt is not destroyed, and it is much easier to insert more, if necessary, to bend the body in the desired



FIG. 197.—Frame with patient placed on it.

direction. It is very essential to place heavy pads over the following places: Back of the low shoulder, over the sacrum, over the spinous processes of the ilium, over the prominent ribs at the front of the thorax, under both arms, and over the convexity of the ribs where the band is applied to make lateral traction. If the patient is thin it is advisable to supplement the body covering by winding sheet wadding over the entire body surface covered by the corset.

The patient having been prepared in the manner described above is ready to be placed upon the frame. Here it is of the greatest importance that the most favorable position be secured, which is the same as that assumed by a person sitting obliquely at a desk. No other will produce the results.

The patient is lifted from a nearby table on which he has been prepared and carefully placed on the hammock face upward (Fig. 197). The shorter side of the hammock presses against the bulging ribs and the depressed ribs sag downward against the long side. The back of the neck rests across the strap of webbing and the head lies on that portion of the hammock between the strap and the steel rod over which the hem is passed. The buttocks rest upon the iron cross-piece, which is adjustable and slides over the frame so that any length of the hammock may be used, according to the body length of the patient. Straps are now applied around the body to pull it in the desired direction (Fig. 198). One is placed beneath the axilla of the



Fig. 198.—Frame and patient with straps adjusted.

low shoulder and carried across the frame obliquely to the opposite front corner. When this strap is tightened it not only draws the upper end of the deformed spine toward the side of the frame to which the strap is fastened, but it also elevates the low shoulder. A second strap, passed around the buttocks in the same manner that the first is passed under the axilla, is carried across the frame in an oblique direction toward the rear end and tightened. This draws the lower extremity of the body toward the same side of the frame that the axillary strap does. The next strap is passed around the patient's body over the most convex portion of the dorsal lateral curve and around the upper rail of the frame, so that when traction is made upon it the lateral curve is obliterated or a lateral curve in the opposite direction

MEDICAL LIBRARY

is made. The fourth strap may or may not be used. If the curve is extremely rigid and a rapid reduction of the deformity is desired, it is necessary. On the other hand, if time is of little consequence, and the patient is not in good condition, the use of this extra force is not advisable. The same final result is obtained with or without it. It is put in place by first passing it around the upper rail of the frame on the side to which the buttocks and axilla straps are fastened. This strap should be at least four inches wide and of sufficient length to pass across and down over the side of the patient's body and to allow the hanging of weights upon its end. This strap is for the purpose of bringing force against the anterior protruding ribs, so that they may be forced downward against the sagging long side of the hammock (Fig. 199).

Fig. 199.—Frame and patient with straps adjusted.

The arms of the patient are placed in the following positions: The one on the side of the low shoulder is elevated as much as possible, and preferably held in that position by an assistant or nurse. The other is allowed to rest on the frame rail in a position which is a little less than at right angles with the body. Weights, if they are used, are now attached to the free end of the strap which extends across the body for the purpose of forcing the ribs downward, and also to the strap which makes the lateral traction, so that it will be pulled away from the body and not left against the hammock. The frame is then tilted so that the body weight may be utilized to exaggerate the position. The original frame was afterward discarded. The weight and the inclination often employed to increase the flexion of the trunk was replaced by tension straps and by the elevation of the legs, as illustrated in the figures from photographs kindly furnished by Dr. Abbott.

"If it is intended to make the overcorrection at once (and this is often possible), or if it seems better gradually to swing the parts into such a position by using several corsets, the patient is now fully prepared for the application of the plaster of Paris.

"If, however, it is preferred in a difficult case to make the complete overcorrection with a single corset, it is necessary to apply a thick oval-shaped pad of felt over the concave side and back of the body, so that when the window is cut in the corset this pad may be removed and the corset left in suitable shape to allow the ribs to push backward and the spine to overcorrect when pads are placed in the front and sides.

"The plaster of Paris is applied in the same way as in any plaster corset, with the exception that over the elevated shoulder it is extended posteriorly up to a level with the acromion process. In trimming it, the bottom is cut shorter in front than in the ordinary corset and longer behind, in order that full flexion may be easily maintained when the patient sits or stands. At the upper end it is trimmed very high beneath the elevated arm, but is cut away on that side in front, so that the shoulder may come forward. Beneath the other arm it is trimmed low, being left high in front so that this shoulder cannot drop forward, and cut out behind so that the shoulder may push backward.

"Two large windows are cut in the corset, one behind and another in front. The former is made as large as possible. It is cut out over that part of the back where the ribs were depressed, and allows them



FIG. 200.—Frame and patient with straps adjusted.

to push backward. It is also cut far enough over the side so that the spine may overcorrect laterally still farther. On the opposite side, in front, a section of the jacket is removed to make the other window. This allows the ribs which bulge posteriorly to push forward. This position of the patient is neither esthetic nor comfortable (Fig. 200), yet he is able to be dressed and can easily walk about.

"It is perhaps needless to say that patients while undergoing this treatment do better if confined in a hospital, where the necessary care can be given them and they will be under constant observation.

"The after-treatment depends entirely upon whether the overcorrection is accomplished with one corset or whether several are used. In the former instance it is necessary to place pads of felt in the front to push the ribs back through the window cut behind, and also in some



FIG. 201.—Permanent posterior pads: these are placed over the bearing surfaces and remain in the plaster corset.

FIG. 202.—Permanent anterior pads 6 and 7 are placed over the anterior spinous processes to prevent chafing; 5 is placed over the thorax, and against this pad pressure is made to increase the flexion by inserting felt through the windows in the corset.

FIG. 203.—Removable pads. These pads are used in addition to the permanent posterior pads, and are for the purpose of shaping the corset so that the patient can be forced in the direction of overcorrection, as illustrated in Fig. 207.

cases to put pads in the side over the convexity of the lateral curve. When the corsets are first applied there is firm pressure over these places, but in a few days the change in the direction of overcorrection is so rapid that it is possible to pass the whole hand between the plaster and the patient's body at this point. Not until this relaxation takes place are the pads used, and then only of such a thickness as will not cause painful pressure. This procedure is repeated until a point in the overcorrection is reached which is satisfactory; when this is attained the corset is worn until the parts are thoroughly stretched on the short side and those on the original convex side have had time to shorten.

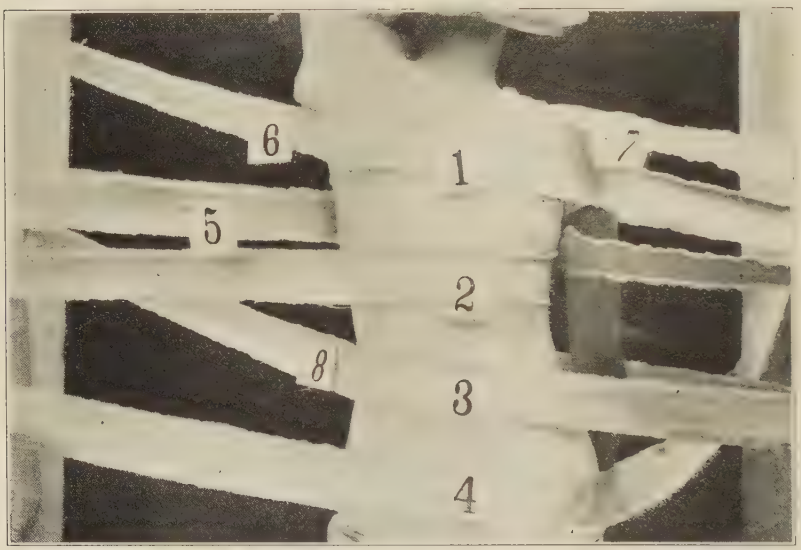

FIG. 204.—The straps, which when attached to the frame pull the patient in the direction of the normal scoliotic posture opposed to the deformity posture, are passed around the patient over the felt pads shown in Figs. 201 and 203.[1]

"In all the patients who have been put under treatment the curve was a fixed one, and in those cases presented the spines could not be straightened by muscular effort any further than this is shown in the cuts representing the original deformities. Many of the patients had been under treatment for years (corsets, braces, and exercises), with very little, if any improvement.

[1] As the details of the illustrations may be confusing, it may be well to restate the essentials of the corrective posture: They are simply to place the patient on the back in a sagging hammock and to increase the flexion assured by the weight of the body by elevating the legs. The shoulder on the low side is raised and drawn forward by the arm, while the other shoulder falls backward and downward. The pelvis is fixed and the flexion and lateral inclination of the trunk induced by the posture are further increased by tension straps. It is very doubtful if extreme force in correction or severe pressure afterward is even desirable.

"The average length of time taken to produce complete overcorrection was three weeks. In some cases ten days were sufficient, while in others it was necessary to continue the insertion of felt for six weeks.



FIG. 205.—Anterior view of plaster corset. Slit cut through plaster for the insertion of felt pads to increase the flexion of the spine.

FIG. 206.—Posterior view of plaster corset showing windows. When the body is flexed by the insertion of felt pads through the anterior slit in Fig. 205 the bearing surfaces over the bulging ribs and over the lumbar curve prevent these parts from moving, but all other parts are pushed in the direction of overcorrection.

The amount of overcorrection is easy of determination, but the length of time for the following fixation is more difficult to estimate. In most of the cases mentioned the average was two months. In some instances, however, the period of fixation was too long, making it hard to bring the spine back to the normal position under exercises. This was especially true in some of the easier cases.

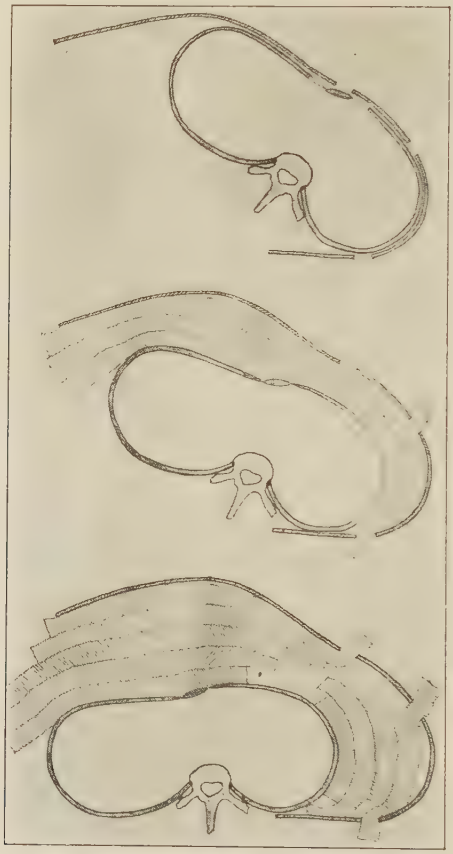

Fig. 207.—Diagram illustrating the changes which take place in the thoracic spine when felt is inserted through slits in Fig. 204. The same changes take place in the lumbar spine by this procedure, but they are not so marked. (Abbott.)

"In reviewing not only these cases, but also a number of others, it has often been not easy to determine before beginning the treatment what kind of a case would prove the most difficult to straighten. Some of the very worst deformities yielded far more readily than the light ones. There are three factors to be taken into consideration: The age of the patient and the length of time since the beginning of the

deformity; the size and shape of the body; and the amount of flexion which can be made. On the other hand, it is frequently easier in the case of an adult patient to correct a deformity of some years' standing than it is to accomplish the same result in a thick-set child in whom the curvature is of recent development.

"As the amount of rotation and its correction is the most important part of the deformity, it is not only very necessary to keep an *x*-ray record of the original curve, but it is also important to make frequent skiagraphs of the changes which follow. If care is used, the exact amount of rotation at any time may be determined, and this is of great value in deciding the final position in overcorrection. The treatment of a case after the corset is applied is extremely simple, yet it is best, as has been said before, to confine the patients to a hospital or place them where they can be under close observation. They should be allowed to walk about as much as possible, not only for the exercise, but also because the body weight in the erect position aids in turning the spine.

"When the corset is finally removed, it is very necessary to have the patient where constant treatment by exercises and massage may be carried out. It is desirable in nearly all cases to use a light brace (or celluloid corset) which will at first hold the spine in an overcorrected position, and later will allow it to come gradually back to the normal. Unless such an appliance is used, the deformity will in a short time tend to reappear, and, like club-foot, turn back into its original position.

"The general condition of the patients after the deformity has been straightened has been of much interest. Invariably the health has improved, and many have gained as much as thirty pounds in weight. One of the most striking results, especially in adults, is the increase in height; in some of the severe cases this has amounted to fully three inches. The gait also improves. What seems, however, to be of far more importance than all else is the change in their mental attitude. Life seems to present a very different aspect to them, showing indubitably that a deformed body does have a pronounced effect upon the mind.

"That fixed lateral curvature of the spine is curable by the method described in this article has been demonstrated. As the cases treated show, it has passed the experimental stage, but further experience will undoubtedly produce improved technic and superior results. The term 'curable' is used here to mean not simply that an improvement has been made in which the lateral curve is partially obliterated and the ribs bent to a different angle, but that the parts entering into the deformity are actually turned back into their normal positions."

The paper was illustrated by more than 80 figures, demonstrating the progress of the treatment to apparent cure.

It has been abstracted in preference to later articles because it presents Dr. Abbott's views, which have not been essentially changed either in theory or practice, in a condensed form.

The period that has since elapsed has been one of disillusionment for those who have tested the treatment on a large scale. Dr. Abbott, judging from subsequent articles, modified his views as to the ease and rapidity with which cure might be attained. The original correction became more extreme, the padding applied with greater pressure, and the duration of treatment was extended from weeks to months, or years, on the theory apparently that the greater the resistance the greater should be the corrective force and the more persistent its application.

FIG. 208.—The application of the corrective jacket in extension.

It would appear, however, that the corrective effect of the Abbott treatment is accomplished chiefly by posture and is dependent therefore on the flexibility of the spine. Forcible distortion of the trunk, however extreme, does not imply overcorrection of the individual segments of the deformed spine without which cure is impossible. In

MEDICAL LIBRARY

most instances the overcorrected or partly corrected section is simply displaced laterally.

Such indirect correction, if maintained for a sufficient time, will improve the general contour of the spine. The shape of the thorax also may be changed somewhat by direct pressure and by the influence of respiration. When, however, the constraint is removed the original deformity must return to a greater or less degree because the correction has been apparent rather than actual.

FIG. 209.—The jacket showing the apparent correction of the trunk.

If, then, a complete cure cannot be accomplished in a definite time the question is simply whether the prospective improvement is worth the effort required to attain it, a question of especial importance because the treatment makes its strongest appeal to patients with advanced deformity.

The disadvantages of the treatment are a grotesque attitude in which the chest is flattened and compressed and in which the thoracic and abdominal organs are placed at a great functional disadvantage. The attitude and its attendant compression cause discomfort and often pain, particularly about the neck and elevated shoulder. It impedes respiration and circulation. The pressure of the pads on the front of the chest often distorts the thorax without affecting the curvature. Pressure sores are a common incident, and several deaths, attributed to rupture of the stomach or other injury, due to violence in the primary application of the treatment, have been recorded.

These disadvantages are especially apparent when contrasted with treatment by jackets applied in the erect posture which improve the contour of the trunk and the appearance of the patient during this period of attempted correction.

One may conclude that the principle on which the Abbott treatment is based is correct and that the method is mechanically the most effective means of correcting lateral curvature of the spine, but that its effectiveness is strictly relative to the duration, the character, and the resistance of the deformity, and that confirmed lateral curvature is practically speaking an incurable deformity.

This conclusion is supported by a report of the Scoliosis Committee

of the American Orthopaedic Association, in which no cure of fixed scoliosis in the anatomical sense by any method of treatment is recorded.[1]

At the Hospital for Ruptured and Crippled the Abbott method has been discontinued in favor of correction in the upright posture.

The patient is suspended in the usual manner. The arm on the concave side is elevated and the trunk is swayed laterally by bands passed about it (Figs. 208 and 213). Elevation of the shoulder on the convex side is restrained by the plaster and an opening is cut on the concave side to permit expansion of the chest. The jackets are removed and reapplied under suspension, no relapse to deformity



Fig. 210.—The Knight spinal brace as used in lateral curvature. A leather or canvas band, made adjustable by lacings, is stretched from the posterior upright to the side bar on the side of the dorsal convexity.

being permitted. Exercises in self-correction are of advantage in preserving muscular tone and in increasing the flexibility of the spine. Under this treatment, the deformity may be lessened or even corrected if the accommodative changes are not too far advanced.

Operative Treatment.—As has been stated, the chief significance of lateral curvature of the spine is the deformity. This lessens the height and forms a noticeable prominence on the back, which is increased when the trunk is inclined forward. Thus, its further progress is favored by fatiguing occupations and by the sitting posture. The deformity, although it may be lessened by treatment, cannot be entirely corrected, and the maintenance of the improved posture requires in most instances habitual support. The object of the

[1] Dr. Abbott's most complete exposition of the treatment may be found in successive numbers of the Journal of the American Orthopaedic Association, January to June, 1917.

FIG. 211

FIG. 212

FIGS. 211 and 212.—Corrective plaster jackets. A great variety of corrective appliances are employed by various surgeons. Of all it may be stated that the external change is much greater than the internal correction. These figures (Fränkel) present one of the most effective types.

FIG. 213.—Jacket applied.

operative treatment is to enable the patient to discard braces by fixing the spine in the extended attitude, thus checking flexion which makes the deformity more prominent and which favors its further development. The most favorable type of patient is an adolescent girl with fairly advanced deformity in the dorsal region, who has undergone



FIG. 214.—The convex stretcher frame, with traction of the head and pelvis, used before and after operation.

the corrective treatment that has been described and who understands the purpose and the limitations of the supplemental operation.

On admission to the hospital, the patient is placed upon a convex stretcher frame of the form used in the treatment of Pott's disease.

FIG. 215.—The convex stretcher frame in use at the Hospital for Ruptured and Crippled.[1]

By this means the spine is extended and elongated, while the persistent pressure on the projecting ribs tends to lessen the deformity and to increase lateral expansion of the chest. In some instances particularly if the pelvis is tilted, traction both on the head and limbs is applied. This treatment is continued for several weeks, and if practicable, as long as improvement is noted, and since it is more

[1] Whitman: Jour. Orthop. Surg., July, 1921.

effective in reducing the deformity than ambulatory correction by jackets, it is now usually instituted as the primary treatment.

The operation is usually of the Hibbs type, modified as suggested by Forbes in the sense that the spinous processes are split into several parts and larger sections of bone raised from the laminæ, so that the area which usually includes the greater part of the thoracic region may be, as it were, thatched with bone splinters. The thoracic region is that of selection for operation, because here the deformity is most noticeable and because motion is so limited that fixation will cause practically no functional disability.

Within a few days after the operation the patient is replaced upon the frame for further correction of the deformity by recumbency and pressure for a period of about two months, or until consolidation is fairly complete. When ambulation is resumed a plaster or other support is applied, which is usually worn for about six months and then discarded. Attention to posture, exercises and the like are, of course, of importance in determining the final result.

FIG. 216.—Congenital scoliosis, after treatment for three years by forcible correction and fixation by plaster jackets. Showing the disappearance of the rotation.

The operation may be modified in special cases; for example, if the deformity is extreme the projecting ribs may make it impossible to carry out the details of the fusion treatment, and it is sometimes supplemented by an autogenous or beef-bone graft placed upon the concave side of the spine.[1] My associate Dr. Kleinberg[2] considers this form of graft a valuable adjunct in treatment both for initial stability and by stimulating bone production for final security. He now employs it even in the milder forms of deformity. The grafts are cut from beef bones. They are about $\frac{3}{8}$ inch in thickness and of a length to extend from one end of the main curve to the other. The graft is placed on the concave side and is fixed to the spinous processes

[1] Whitman, A.: Arch. Surg., November, 1922; Kleinberg, S.: Arch. Surg., November, 1922; also Scoliosis,1926.

[2] Am. Jour. Surg., June, 1929.

at either extremity. He has performed the operation in 54 cases with but 2 unsatisfactory results. If the posterior projection of the ribs is extreme the prominence is lessened by removing a wide section from a sufficient number. These bones are afterwards used to supplement

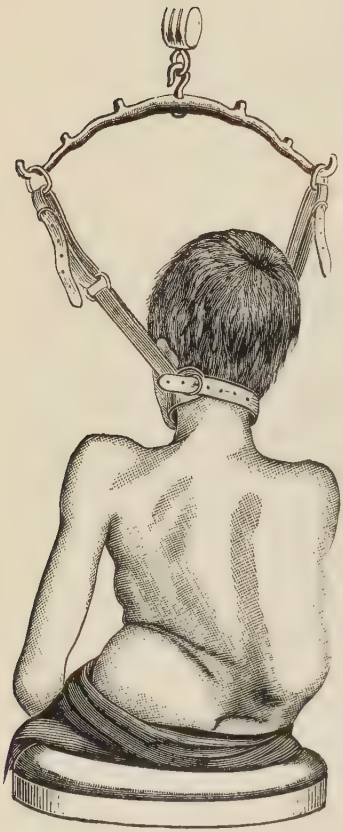

FIG. 217

FIG. 218

FIGS. 217 and 218.—Self-suspension, illustrating the effect of traction in lessening deformity induced by paralysis. In such cases support is essential. (Gibney.) These cases are now usually treated by operation fixation.

the fusion operation (A. Whitman.[1]) The operation is less applicable for deformity in the lumbar region, because here movement is more essential to function. Operative fixation has been performed in a large number of cases both of the paralytic and so-called idiopathic type with very satisfactory results and it has become an established pro-

[1] Am. Jour. Surg., June, 1929.

cedure at the Hospital for Ruptured and Crippled for well-marked deformity in adolescents.

When the deformity is dependent upon irremediable injury or disease, such, for example, as anterior poliomyelitis or empyema, some form of brace must be employed habitually to prevent excessive lateral deviation of the trunk; and in cases of fixed deformity in older subjects, especially if the patient's occupation is fatiguing, a support may be indicated to relieve symptoms of discomfort or pain.

Support is employed primarily with the aim of preventing an increase of deformity and to relieve symptoms incidental to it. It may serve, also, in some degree as a corrective appliance. If it holds the spine in the extended position or induces lordosis, it may, by relieving the anterior portion of the column in part from the deforming influence of superincumbent weight, induce or permit a slight lessening of the rotation of the vertebral bodies. On this principle a light steel brace, after the Taylor model, may be as effective as any of the more complicated appliances, as was suggested many years ago by Judson. Corsets of other material than plaster, for example, of paper, celluloid or of aluminum, as suggested by Phelps, may be employed when the deformity is fixed and when no change in the position or size of the trunk is to be expected. The Knight brace, when carefully adjusted, appears to meet the requirements fairly well, and when less support is needed an ordinary corset strengthened by light steels may be sufficient. Even in cases of this character corrective exercises should be employed with the aim of preserving as far so possible the flexibility of the spine.

Supplemental Treatment.—The Removal of Superincumbent Weight.—The removal of superincumbent weight by the assumption of the reclining posture whenever the patient is fatigued is an important adjunct in the treatment. The patient should lie, preferably, upon a hard support in the supine posture, with the arms extended above the head. If the dorsal kyphosis is exaggerated a firm cushion between the shoulders or under the projecting ribs will aid to expansion of the chest and favor the correction of the deformity.

Self-suspension.—Self-suspension, by means of the halter and pulley, is of service in overcoming secondary contractions of the tissues, and thus aiding in the correction of deformity. It is often efficacious, also, in relieving the discomfort that is sometimes a troublesome symptom when the distortion is extreme. While the patient is suspended, forcible manual correction of the deformity may be applied to advantage.

Suspension from the horizontal bar has a similar effect, although it is less effective than when the traction is made upon the entire spine. In this form of suspension the bar should be oblique in direction, the high side for the low shoulder. Thus, a passive "key-note" is induced while the patient is suspended. Exercises in this position, for example, flexion, extension, and abduction of the thighs, swaying the trunk from side to side, "chinning" the bar and the like, are useful.

Volkmann Seat.—In cases of primary lumbar curvature, or when the secondary curve of this region is pronounced, the attitude may be improved and the deformity may be corrected in part by seating the

patient on an inclined plane, the high side beneath the low hip, thus lessening the convexity of the curve.

High Shoe.—The same object may be attained in the erect posture by the use of a higher heel, or heel and sole. The elevation may be from a half-inch to an inch and a quarter, the amount being regulated by its effect upon the contour of the trunk.

Support during Recumbency.—If a corrective corset is used it may be worn with advantage at night—or a plaster bed corresponding to the posterior half of a jacket may be constructed. This is suitably padded and is fixed to cross-bars. In this the patient lies at night, deformity being prevented and a certain corrective force is also exerted. This support, according to Jaeger, is not only tolerable but is more comfortable in cases of advanced deformity than is the ordinary bed.

General Treatment.—The importance of improving the general condition of the patient, by regulation of the diet, by baths, massage, swimming exercises, and life in the open air, is self-evident. The strain upon the back should be lessened by providing proper seats and by limiting the time passed in passive attitudes, and by lessening, so far as possible, the restraint of the clothing. These precautions are of almost equal importance with the active treatment.

The Duration of Treatment.—The duration of treatment depends, of course, upon the character of the deformity and upon its causes. In the ordinary type of adolescent scoliosis the duration of active treatment is usually from three to six months. In this time the muscles may be so strengthened and the necessity for constant attention to the attitudes may be so impressed upon the patient that the simple exercises which may be performed at home may be sufficient. In such exercises the most important postures are those which hyperextend the spine. The constant effort should be to make motion in one direction as free as in another and to practise postures that tend to reduce deformity. In all cases it is well, if possible, to keep the patient under supervision during the period of growth.

In reviewing the treatment it would appear that gymnastic treatment is most efficient as a preventive measure. That it is curative only in the preliminary or potential stage of the deformity. That it is of value when properly conducted at any stage, as a means of increasing the flexibility of the spine, improving the posture, of relieving discomfort, and for its general effect on the condition of the patient.

That the Abbott method is most effective from the mechanical standpoint and may be indicated in certain cases in which the deformity may be overcome in a definite period.

That in typical confirmed cases, correction to the degree possible in complete extension is the most satisfactory method. Finally that operative fixation is an efficient method of checking the progress of the deformity and relieving the patient from burdensome supports.

That the great majority of cases in adolescent and adult life are incurable, although susceptible in most cases of improvement, and that treatment should be undertaken with an understanding of its limitations.

MEDICAL LIBRARY
CITY HOSPITAL

CHAPTER IV.

DEFORMITIES OF THE SPINE (Continued). DEFORMITIES OF THE CHEST. THE FUNCTIONAL PATHOGENESIS OF DEFORMITY.

VARIATIONS IN THE CONTOUR OF THE SPINE.

One recognizes a certain contour of the spine as normal, but there are variations from this type which, within certain limits, can hardly

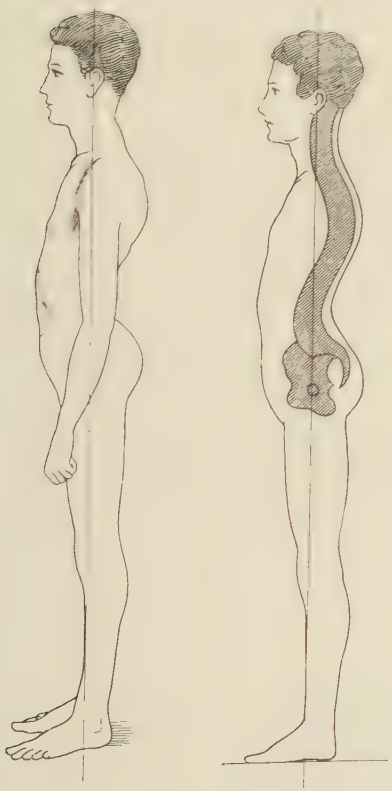

Fig. 219.—The hollow round back. (Stafel.)

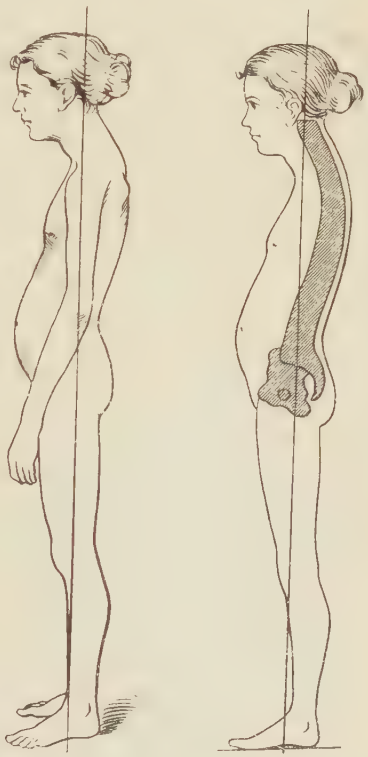

Fig. 220.—The round back. (Stafel.)

be classed as abnormal. Two of these have been mentioned: the *round back* (Fig. 220), in which there is a general forward droop most marked at the shoulders, and the *hollow round back* (Fig. 219), in which

the dorsal kyphosis and the lumbar lordosis are somewhat exaggerated. A third type is the *flat back* (Fig. 119), in which there is neither a lumbar lordosis nor a dorsal kyphosis. In the marked cases there is an actual prominence in the lumbar region, while the scapulæ project backward, overhanging the flattened dorsal spine. This type of back may be the result of a rhachitic kyphosis which was most prominent in the lumbar region, and it often follows a primary lateral rotation of the lumbar vertebræ. The flat back and the round back predispose to lateral curvature. Deviations from the normal contour of the spine are attended by a change in the inclination of the pelvis and in the relation of the support of the limbs and trunk. The round back (Fig. 220) is almost always indicative of weakness, and it is often accompanied by other postural deformities, especially often by weak feet.

VERTEBRAL EPIPHYSITIS.

Sorrel and Delahayl[1] have described, under the title of "Painful Vertebral Epiphysitis of Adolescence," cases of posterior curvature of the spine developing rapidly, often accompanied by sensitiveness to pressure on the spinous processes and the iliac crests. Buchman,[2] of the staff of the Hospital for Ruptured and Crippled, examined 65 cases of posterior curvature of the spine in youthful subjects, and in 83 per cent. found evidences of epiphyseal "disease" of this type. The changes in positive cases are in order of appearance enlargement and irregularity of the epiphyseal plaques. The intervertebral spaces are cloudy and the surfaces of the vertebral bodies indistinct. Later, in the stage of recovery, the component parts become more distinct, and both the epiphyses and the vertebral borders appear more dense than normal. Clinically the disease begins between the tenth and twenty-first year. Its onset is accompanied by fatigue and by pain in the back and limbs. There may be, as has been noted already, pain on pressure over the spinous processes and iliac crests. Buchman thinks the condition analogous to Koehler's, Legg-Perthe's and other affections of this type. It is, of course, evident that in cases of posterior deformity of the spine in adolescence there must be accommodative changes in its structure which might resemble those described. The important practical point is that cases of advancing deformity accompanied by pain should be treated by rest and corrective support rather than by exercise.

ANTERIOR–POSTERIOR DEFORMITIES OF THE SPINE.

Kyphosis.—As has been stated in the chapter on Pott's Disease, the spine is practically straight at birth. If during the early weeks of life an infant be placed in the sitting posture the head falls forward and the spine bends into a long posterior curve, the posture of weakness. The normal anterior convexity of the cervical section is established

[1] Sorrel and Delahayl: Pub. sur chir osseuse, Berck, 1924.

[2] Jour. Bone and Joint Surg., October, 1925 and Surg., Gynec. and Obst., October, 1929

when the gain in muscular power enables the infant to hold the head erect, and that of the lumbar region when the pelvis is tilted downward by the extension of the thighs in the erect posture.

In the erect posture the constant tendency of the weight of the head and of the thoracic and abdominal organs is to draw the spine forward. This tendency is resisted by the action of the posterior muscles of the trunk. Whenever, therefore, the muscular power is lessened or the body is overburdened, or whenever the spine is weakened by disease, the tendency toward the original curve of weakness becomes apparent (Fig. 221). Thus the causes of an abnormal increase in the posterior curvature of the spine are very numerous. It is, as has been stated, the characteristic attitude of weakness, as is illustrated in infancy and in old age. It is one of the common occupation deformities of adult life; it is a common postural deformity of childhood and adolescence. It may be induced by a variety of diseases that lessen the resistance of the spine or that interfere with its function, for example, by rhachitis, spondylitis deformans, osteitis deformans, Pott's disease, and affections of a similar nature.

The kyphosis of rhachitis is most marked in the lower region, that of spondylitis deformans may involve the entire spine, while the simple postural curvature is most marked in the upper dorsal region—"round shoulders." In a number of the postural deformities the increase in the dorsal kyphosis is balanced by an increased lordosis, and in this form there is simply an exaggeration of the normal curves of the spine—the "hollow round" back. In other instances there is a general forward droop of the trunk in which the lumbar lordosis may be lessened; this form is more common in childhood—the "round" back.

The forms of kyphosis that are the direct result of disease have been described elsewhere. *Postural kyphosis*—"round shoulders"—is one of the common deformities, and in childhood its etiology is similar to that of lateral curvature, of which it may be a predisposing cause. Round shoulders and the accompanying so-called flat, but in reality narrow and therefore deeper, chest may be induced also by obstructions in the respiratory passages, such as enlarged tonsils, adenoids and the like, or by bronchitis or heart disease. Another predisposing cause is clothing that prevents the full expansion of the chest and the extension of the arms, and even the weight of clothing suspended from the shoulders may be a factor in the etiology. These and other possible contributing causes should be investigated in all cases of this character.

A more extreme type of deformity is sometimes seen in adolescents, usually males (Fig. 222), induced apparently by posture and by overwork, although in most instances it may be assumed that a slighter deformity of long standing has served as a predisposing cause. In this type the deformity is resistant, and is accompanied by adaptive changes in the vertebræ that prevent complete correction.

Symptoms.—The most important symptom is the deformity itself. In adolescent cases there is often some discomfort of the nature of

FIG. 221.—Marked posterior curvature of the spine apparently induced by weakness incidental to illness. In such cases correction by rest on the convex frame is indicated.

FIG. 222.—Posterior curvature of the spine in adolescence with rigidity. A deformity that may be mistaken for that of spondylitis deformans.

strain and tire usually referred to the scapular region but in the rigid type the pain is most marked below the projection.

Treatment.—Even slight posterior curvatures of the spine check the expansion of the chest and disturb the balance of the body. Furthermore, as it has been demonstrated by *x*-ray pictures that the internal viscera may be lifted from three to six inches by muscular effort in the erect posture, it is apparent that serious and permanent displacement of these organs may result from habitual deformity. Consequently the maintenance of the erect posture from childhood to old age is of the greatest importance.

FIG. 223

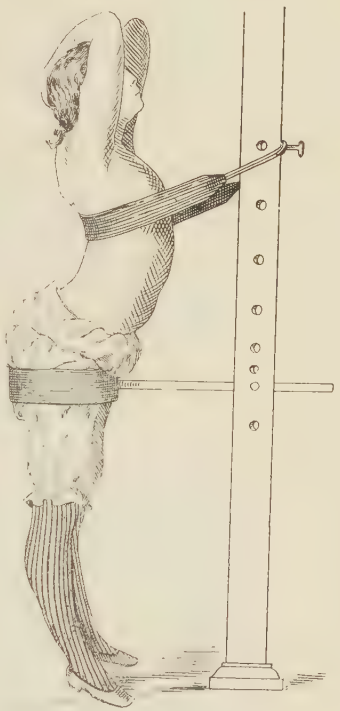

FIG. 224

FIGS. 223 and 224.—Exercises for the correction of posterior curvatures of the spine. (Hoffa.)

The treatment is similar to that of lateral curvature. The assumption of the military attitude, with the head erect, the chin depressed, the shoulders thrown back, the chest expanded, and the abdomen retracted, should be encouraged. And those exercises that expand the chest and that strengthen the muscles of the upper part of the spine are especially important. (Such exercises are illustrated by Figs. 146, 147, 153, 154, 165, 166, 167, 168, 170, 173, 174 and 175). If the range of vertical extension of the arms is limited, this restriction must be overcome before the deformity of the spine can be permanently

improved. In well-marked cases the patient should be encouraged to read or study in the prone posture. In this attitude, in which the trunk must be supported upon the elbows and the head held backward, there is necessarily an involuntary correction of the deformity. In certain instances a light spinal brace or corset may be employed during the hours when the passive attitude must be assumed (Fig. 225). Shoulder braces, so-called, are useless if the deformity is resistant, because the lumbar lordosis is increased when the shoulders are drawn backward. Clothing should not restrict the movements of the arms or trunk, and as little weight as possible should be suspended from the shoulders. Lowman[1] has called particular attention to heavy and dependent breasts as a factor in deformity and uses the support shown in the illustrations (Figs. 226 and 227). In the more extreme cases a

Fig. 225.—A brace for round shoulders. (Goldthwait.)

Calot jacket may be applied, as described in the Chapter on Pott's Disease. But by far the most effective treatment is a period of fixation on the convex frame followed by a fusion operation. Whenever a patient is under treatment for deformity of the trunk the attempt should be made to restore the general symmetry of the body. Attention is again called to weak feet as the most common and important accompaniment and predisposing cause of deformities of this class.

Lordosis.—Lordosis, or an abnormal hollowness of the back, is far less common than kyphosis. It is usually secondary to disease or deformity either of the spine or of the lower limbs. For example, lordosis may be induced by flexion contraction of the thighs; it is

[1] Jour. Am. Med. Assn., January 21, 1922.

FIG. 226.—Posterior view: broad strap used with very heavy breasts and sensitive shoulders. Otherwise narrower ones are used, sometimes passing straight down to the belt and not crossing. (Lowman.)

FIG. 227.—Front view.

a symptom of congenital displacement of the hips; it is sometimes a result of certain forms of nervous disease in which, because of muscular weakness, the body is swayed backward to retain the balance, as in the muscular dystrophies. Lordosis in the lumbar region may be a compensation for a kyphosis in the upper segment. It may be a congenital deformity; it is said to be a peculiarity of contortionists and in a mild degree it may be induced by the habitual use of high heels.

Treatment.—As lordosis is usually a secondary deformity its treatment would be included in the treatment of its causes. In some instances the discomfort which is usually present when the deformity is well marked may be relieved by a proper corset sufficiently strong to support the back. See Spondylolisthisis.

CONGENITAL ELEVATION OF THE SCAPULA.

Synonym.—Sprengel's Deformity.—Sprengel's deformity is a congenital elevation of the scapula above the level of its fellow, an elevation accompanied in most instances by rotation, so that its lower angle is brought nearer to the spine while its upper border, projecting and bent forward above the clavicle, has in several instances been mistaken for an exostosis (Fig. 228). The cervical muscles passing to the

FIG. 228.—Congenital elevation of the left scapula; with the arm elevated the scapula is in contact with the occiput, as is indicated by the deep fold; age of the patient three months.

scapula are shortened and changed in direction, and in about 25 per cent. of the cases the median border of the scapula is attached to one of the lower cervical vertebræ by a bony prolongation which may be an outgrowth from a transverse process or a detached bone jointed at either extremity. It is called the omovertebral bone. In a case reported by Jackson,[1] the bone was $2\frac{1}{2}$ inches in width at the scapular

[1] Bull. Moses Taylor Hosp., December, 1927.

MEDICAL LIBRARY
BOSTON CITY HOSPITAL

margin, 3½ inches long and attached at its apex to the fifth cervical vertebra. The mobility of the scapula is lessened, and the range of vertical extension of the arm is restricted. The deformity may be combined with torticollis or with cervical ribs or defective formation of the spine, for example, absence of vertebræ or rhachischisis. In many instances there is an accompanying lateral curvature of the spine, the convexity being usually toward the deformed side. Ninety-nine cases have been collected from literature by Zesas.[1] Forty-seven were of the right side, 36 of the left, and in 11 both scapulæ were elevated. Of 82 cases, 48 were in males. A more recent and complete review of the subject is by A. E. Horwitz,[2] of 136 cases. Scoliosis was present in 47 per cent., torticollis in 10 per cent. and asymmetry of the skull and face without torticollis in 11 per cent. In 67 per cent. there was some accompanying defect in formation.[3]

Etiology.—The etiology is doubtful, but in many instances it appears to be the result of a constrained position of the fetus. In 2 of Sprengel's cases, seen soon after birth, the arm appeared to have been fixed behind the back of the child.

It is of interest to note that, according to Chievitz, the upper limb is in its origin a cervical appendage, retaining an elevated position during fetal life, and that interference with its descent by constraint or otherwise may explain the etiology. In some instances the influence of heredity is marked, the deformity appearing in several generations, and in such cases the shape of the scapula appears to indicate a reversion to a lower type.[4] The normal scapula extends from the first intercostal space to the eighth rib. The elevated scapula is smaller than normal, the width is greater in proportion to its length, it is rotated, so that its posterior border forms an open angle with the spine above instead of below and its upper border is often inclined forward.

Congenital elevation of the scapula may be simulated by the distortion and muscular atrophy resulting from birth palsy, or even by certain cases of rotary lateral curvature in which the scapula is elevated and prominent.

In ordinary cases, operative correction is indicated at an early age. An incision is made about the upper and spinal border of the scapula and all the tissues that restrain the replacement of the scapula are divided, the bony attachment, if present, being removed. The deformity is then forcibly corrected. König[5] bores a hole in the lower border of the scapula and passes through it a band of muscle and fascia from the latissimus dorsi, the end being reattached to the muscle under sufficient tension to prevent upward displacement.

[1] Ztschr. f. orthop. Chir., 1905, Band **15**, Heft 1.

[2] Am. Jour. Orthop. Surg., 1909, vol. **6**, No. 2.

[3] The deformity was first described by Eulenburg (Arch. f. klin. Chir., 1868), but in more detail by Sprengel (Centralbl. f. Chir., 1895), who reported 4 cases in children from one to seven years of age.

[4] Neuhoff: Am. Jour. Dis. Children, May, 1914.

[5] Arch. f. Orthop. u. Unfall-Chir., 1921, vols. **3** and **4**.

A fixation support of plaster of Paris is then applied. Supplemental treatment by forcible stretching is afterward employed, as in the treatment of torticollis. Chlumsky[1] has reported a case of complete paralysis of the arm following this operation due apparently to pressure of the clavicle on the brachial plexus and mentions other cases. One case has come under my observation so that this complication is not unusual. At the first indication of pressure on the nerves, the arm should be abducted and supported by a shoulder spica.

FIG. 229.—Congenital elevation of the scapula of a moderate degree in adolescence.

Paralytic Elevation of the Scapula.—Elevation of the scapula on one or both sides may follow paralysis of the serratus magnus and the trapezius muscles. In unilateral cases the paralysis is usually peripheral, and the prognosis therefore far more favorable from the remedial stand-point than in those in which the paralysis is of central origin, and therefore of a progressive type.[2]

DEFICIENCY AND MALFORMATION OF VERTEBRÆ.

Absence of vertebræ is often associated with rhachischisis. Several cases, however, have come under my observation in which there was absence of vertebræ without other malformation. In 2 of the cases

[1] Arch. f. Orthop. u. Unfall-Chir.

[2] Mathieu divides the third and fifth ribs near the spine and attaches the border of the scapula to their proximal extremities.

the deficiency was in the cervical region, in the others in the lumbar. The noticeable shortness of the affected section of the spine was the only symptom. Supernumerary and otherwise malformed vertebræ have recently been demonstrated by roentgen-ray examinations to be a more important factor in the etiology of deformity of the spine than had been suspected formerly.

ABNORMALITIES OF THE RIBS.

Cervical Ribs.—Cervical ribs are not uncommon. They may be divided into four classes:

1. An increase in the length of the costal process but not reaching beyond the transverse process.
2. Extending beyond the transverse process, terminating in a free end or united to the first rib.
3. Longer, attached to the first rib by a ligament.
4. Complete ribs.

In most instances the anomaly is bilateral but more developed on one than on the other side.

If the rib is unilateral it is often connected with a defective supernumerary vertebra. In such instances the spine is usually deflected to form a lateral curvature toward the abnormality.

If the ribs are complete the neck appears wide and short and the projecting ribs may be felt as bony prominences (Fig. 230). In 303 cases the rib was on the left side in 91, on the right in 70 and on both in 143. Adson.[1] Of 161 recorded cases 114 were in females.[1]

The subject is of surgical interest because a number of cases have been reported in which pressure on the nerves and bloodvessels passing over the rib induced pain and even paresis of the arm and feeble circulation. The pain is usually referred to the distribution of the ulnar nerve and the atrophy is most marked in the intrinsic muscles of the hand. Similar symptoms may be caused by hypertrophy of the transverse process of the seventh cervical vertebra by abnormality of the first rib, or by pressure on a normal rib,[2] and as they do not appear, as a rule, until adolescence or adult life, it may be assumed that improper posture is the exciting cause. Corrective exercises for the forward inclination of the trunk and, if necessary, apparatus to support the shoulder girdle are indicated as a tentative treatment. In intractable cases removal of the rib may be required.

A. S. Taylor[3] exposes the rib by the same incision as for repair of the brachial plexus, viz., from the posterior insertion of the sternomastoid on the clavicle upward and outward at an angle of 45 degrees to the border of the trapezius. The deep fascia along the outer margin of the plexus is divided and drawn inward, exposing the rib. Its muscular and ligamentous attachments are divided and the rib removed as close to the spine as practicable. In some instances the rib may be divided on either side of the vessels and nerves and only

[1] Atlanta Med. Jour., vol. **31**, p. 222.
[2] Lenormant and l'Sénè: Bull. et mém. Soc. de Chir. de Paris, 1923, **59**, 997.
[3] New York State Jour. Med., March, 1922.

the section directly involved removed or the division of the scaleneus anticus of a restricting band may relieve the pressure.

Fig. 230.—Bilateral cervical ribs.

Absence of Ribs.—Absence or defective formation of ribs is uncommon. In such cases there is usually defective formation of the corresponding muscles, and lateral curvature of the spine is often present. (See Congenital Lateral Curvature.)

MALFORMATION OF THE PECTORAL MUSCLES.

Several instances in which one or both of the pectoral muscles were defective or absent have been observed at the Hospital for Ruptured and Crippled.[1] The defect is usually bilateral and as it is congenital there is little apparent disability.

ABNORMALITY OF THE CLAVICLE.

Thirty-eight cases of defective formation of the clavicle on one or both sides are recorded.[2] Of 27 cases reported by Heinecke,[3] the defect was bilateral in 20. In most instances a portion of the sternal extremity is present. The defect may be hereditary. In these cases it may be accompanied by exaggeration of the transverse diameter of the cranium and delay in ossification of the fontanelles (Cleidocranial Dyostosis). In a family group of 7 males and 4 females, the abnormality was present in 4 of the males. It appears to cause but slight inconvenience.[4]

DEFORMITIES OF THE CHEST.

Flat Chest.—The so-called flat chest is an accompaniment of the round back (Fig. 221). The shoulders and scapulæ being displaced forward the chest becomes less prominent.

Woods Hutchinson has called attention to the fact that the so-called flat chest is in reality a round chest, in the sense that the thorax is actually deeper than the normal, a persistence of the fetal type. He suggests that such persistence may be one of the causes of round shoulders, the round chest affording no adequate support for the scapulæ.

Hutchinson[5] has presented an index showing the relative depth of the chest at different ages, illustrating the progress from the keel chest of the lower orders to the bellows shape of the adult human form. This index is found by dividing the anteroposterior diameter at the nipples by the transverse diameter at the same level; hence the lower the index, the longer and flatter, more bellows-like the chest.

Embryo	105	115
At birth	101	
Under 2 years	94	
3 to 7 years	85	
14 to 18 years	80	
Adult	72	

Treatment.—The treatment of the so-called flat chest is similar to that of the round shoulders, with which it is combined—that is, by exercises conducted with the special object of improving the strength of the muscles of the back and increasing the expansion of the upper part of the chest. The importance of correcting the deformity, which interferes with the proper expansion of the lungs and thus predisposes to disease, should be evident.

[1] Martirené: Rev. d'Orthop., May, 1903.
[2] Klar: Ztschr. f. orthop. Chir., 1906, Band **15**, Heft 2.
[3] Ztschr. f. orthop. Chir., 1908, Band **21**, Heft 4.
[4] Fitchet: Jour. Bone and Joint Surg., October, 1929.
[5] Jour. Am. Med. Assn., September 11, 1897, and May 2, 1903.

Pigeon Chest.—Synonym.—Pectus carinatum.

The pigeon or keel-shaped chest resembles the quadrupedal type in that the anteroposterior is increased at the expense of the lateral diameter. The sternum is thrust forward and downward like the keel of a boat, the lateral compression being most marked at the junction of the ribs and the cartilages. This deformity is almost always acquired (Fig. 231); it is usually an effect of rhachitis, and it is described under that heading. It may be induced by obstruction of respiration caused by enlarged tonsils and the like, if this is pres-

Fig. 231.—General rhachitic distortions and pigeon chest.

ent at an early age. It may be a secondary effect of the sinking forward and downward of the upper half of the trunk, as in Pott's disease.

Treatment.—The treatment of secondary deformity would be included in the treatment of the affection of which it is the result. Manipulation, massage, and breathing exercises may be employed in the treatment of simple pigeon chest. For the more extreme cases in young subjects, graduated manual pressure on the projecting sternum in connection with forced inspiration may be employed, and in some

instances a form of truss to exert a more constant pressure may be worn with advantage. The tendency is toward spontaneous cure; in noticeable degree it is rarely seen in adult life.

Funnel Chest.—Synonym.—Pectus excavatum.

This deformity (Fig. 232) is the reverse of the pigeon chest. The sternum is depressed and the lateral diameter of the thorax is correspondingly increased. The milder types of the affection in which there are one or more depressions or hollows in the sternum are common. The extreme form, in which the entire sternum is depressed, is rare. It is practically always a congenital deformity, and it is not susceptible to direct treatment.

Minor Deformities of the Chest.—As has been stated, distortions of the chest secondary to deformity of the spine are often discovered before the original cause is suspected, and the importance of the various minor irregularities of the chest or in the direction of the ribs when once discovered is often exaggerated. They are usually the result of preceding rhachitis. The increase of the capacity of the chest by appropriate exercises aids in the correction of asymmetry.

Fig. 232.—Pectus excavatum. This patient has ocular torticollis also.

SNAPPING NECK.

Cases have been reported in which extension of the neck from a flexed position is accompanied by an habitual, painful and audible snapping caused by friction of the fifth and sixth cervical spines. Removal of the fifth spinous process relieved the symptoms.[1]

SNAPPING JAW.

This is an audible sensation of snapping on opening and closing the mouth in one or the other articulation. It is caused usually by displacement of the intra-articular cartilage, and in persistent cases this may be removed by a short incision at the lower border of the zygoma directly forward from the auricle, care being taken to avoid injury to branches of the facial nerve.

[1] Lanz: Zentralbl. f. Chir., 1917, No. 4.

SCAPULAR CREPITUS.

Creaking or grating sounds induced by certain movements of the scapula on the thorax sometimes appear without apparent cause or are developed by exercises during the treatment of lateral curvature. In some instances bony irregularities, bursæ and the like may be present, which require operative removal. Twenty-two cases are reported by Küttner,[1] and de Laroquette found scapular crepitus in 8.2 per cent. of 620 normal individuals. As a rule, the symptoms are relieved by comparative rest of the arm. In extreme cases operative exploration is indicated.

ACQUIRED LUXATION OR SUBLUXATION OF THE STERNO-CLAVICULAR ARTICULATION.

Partial displacement of the sternal end of the clavicle is not particularly uncommon. In some instances it is caused by injury; in others no cause can be assigned. Most often there appears to be a laxity of the capsular ligament that permits a displacement during certain movements of the arm. The displacement is readily reduced, but the weakness and insecurity may cause discomfort and disability.

Treatment.—In some instances the displacement may be prevented by the pressure of a pad and truss spring, attached behind to the corset or braces and passing over the shoulder close to the neck. Such an appliance is especially useful if the displacement occurs at certain times only, as in dressing the hair, playing on the violin, etc. Cures are reported as the result of the injection of alcohol into the joint from time to time, and Wolff[2] has operated with success as follows: The joint is opened by a straight incision. A fragment of bone is detached from the clavicle above and a similar one from the sternum; these, still adherent to the periosteum, are overlapped in front of the joint and the capsule is then sutured. A more effective operation is that of Marxer,[3] who binds the clavicle to the sternum by a strip of fascia passed through the adjoining bones.

DISPLACEMENT OF THE ACROMIO-CLAVICULAR ARTICULATION.

This is usually caused by a fall on the shoulder resulting in a downward displacement of the acromion. The injury causes persistent local pain or discomfort, weakness and limitation of motion, particularly of abduction of the arm.

The most effective treatment is a facial suture binding the clavicle to the acromion and to the acromio-clavicular ligament as illustrated in Carrel's diagram (Fig. 233).

[1] Deutsch. med. Wchnschr., June 23, 1904.
[2] Centralbl. f. Chir., November 30, 1893.
[3] Ztschr. f. Chir., 1925, No. 37.

MEDICAL LIBRARY BOSTON CITY HOSPITAL

ARTHRITIS OF THE ACROMIO-CLAVICULAR JOINT.

This joint may be involved in a generalized arthritis and occasionally usually as a result of injury, this articulation alone may be affected. The symptoms are local sensitiveness and pain on movements of the arm. A form of arthroplasty with the insertion of fascia to prevent friction is usually effective.

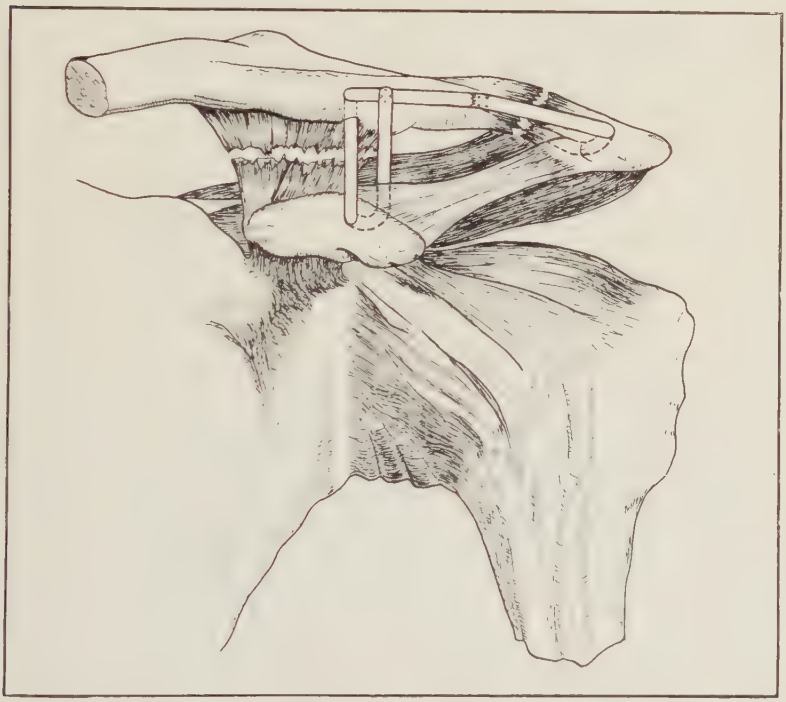

FIG. 233.—A strip of fascia, ½ inch wide and 4½ inches long, is passed through two drill holes in the clavicle and woven in the base of the coraco-acromial ligament. This latter ligament is directed upward and outward, and is almost at right angles with the new ligament, thus facilitating attachment with proper tension. The acromio-clavicular ligament may be repaired with fascia or chromic catgut. (Carrell, Jour. of Bone and Joint Surg.)

ASYMMETRICAL DEVELOPMENT.

In normal individuals there is often a slight difference between the two halves of the body, and, as is well known, inequality in the length of the lower extremities is not at all uncommon. Inequality of the two halves of the body may be congenital, and it may be evident at birth, but usually it does not attract attention until adolescence. In other instances the inequality is the result of a cerebral hemiplegia of early childhood and the resulting retardation of growth. Less often the inequality may be due to congenital hypertrophy that may affect an

entire limb. In such cases there may be an abnormal amount of normal tissue, or the hypertrophy, which becomes more marked with the growth of the child is caused by an increased blood supply, a form of congenital nevus or communication between an artery and vein (Fig. 234). In other instances the enlargement resembles elephantiasis, and may be made up of fibro-fatty tissue or a neurofibromatosis.[1] In such cases it may be feasible to remove the redundant tissue and to shorten the bones.[2]

FIG. 234.—Hypertrophy of the right forearm and hand, due to congenital nevus.

THE FUNCTIONAL PATHOGENESIS OF DEFORMITY.

Wolff's Law.—"Every change in the form and function of the bones or of their function alone is followed by certain definite changes in their internal architecture, and equally definite secondary alternations of their external conformation, in accordance with mathematical laws."

Mention has been made, and will be made again from time to time, of the adaptation of the body to abnormal conditions, and of the transformation of deformed parts toward the normal shape when improper relations of weight and strain have been removed. Wolff first called attention to the fact that the shape of a bone is the effect of

[1] Campbell: Surg., Gynec., and Obst., May, 1923.
[2] Digby: Jour. Anat., 1916.

function. It is the effect of function in that if the work required of it had been different its shape would have been different. This function has shaped not only the external contour but the internal structure as well. If a bone is broken, for example the neck of the femur, and deformity results the internal architecture is no longer suitable for the new conditions of weight and strain, and immediately a rearrangement begins, which finally transforms the internal structure, not only in the neighborhood of the injury, but in the extremity of the bone also, to adapt the deformed part as well as may be to the work that is now demanded of it.

The normal bone is braced most thoroughly and is most resistant at the points where most work is required of it. If the weight and strain are for any reason transferred to another part, its structure is strengthened there, and correspondingly weakened at the point from which the strain has been removed. With this change in the internal structure a change in the external contour keeps pace. For according to this theory, "the external contour represents mathematically simply the last curve uniting the ends of the various trajectories which make up the internal structure."

For the further exposition of this theory I quote from Freiberg's[1] review an abstract of Wolff's[2] final article.

"In showing that improper static demands made upon an extremity resulted in the formation of new masses of bone upon the surface of the bone of this extremity, or that they produce the disappearance (atrophy) of bone masses according to the nature and degree of these disturbances in static requirements, it has at once been shown in what manner deformities have their origin. For these transformations on the surface of bone are nothing other than 'deformities' in the wider or narrower sense of the term.

"Taking genu valgum or habitual scoliosis as an example, the development of a deformity in the narrow sense is thus explained. In the beginning of either of these conditions the shape of the bones is perfectly normal. As the result of excessive fatigue in their too weak muscles the patients are frequently assuming a faulty position of limb or body; they seek to control excessive excursions of their joints by the interference of the articular structures themselves instead of by muscular activity. The result is a continual alteration in the static requirements made upon the bones and the internal architecture; internal and external configuration of the bones accommodate themselves to the new conditions. Since, according to this reasoning, deformities are nothing less than the result of these transformations which the external form of bones or joints undergo in accommodating itself to faulty demands made upon them, it must be self-evident that these deformities are to be considered pathological only in the sense that hypertrophy of the cardiac muscle in valvular

[1] Ann. Surg., July, 1897, and Am. Jour. Med. Sci., December, 1902.

[2] Die Lehre von der functionellen Pathogenese der Deformitäten, Arch. f. klin. Chir., Band liii, Heft 4.

insufficiency is pathological. That which is really pathological is only the altered static requirements, the abnormal mechanical function. Far from being pathological the deformity is the only suitable or even possible form by means of which bone or joint can withstand the altered forces bearing upon it; it is Nature's way of securing the greatest possible service and strength, under new conditions, with the use of the least possible amount of material.

"The pathogenesis of deformities is therefore functional. Genu valgum, for instance, represents only the functional accommodation of femur, tibia, and knee-joint to the improper static demands made

FIG. 235.—Dislocated femur, showing the atrophy and rearrangement of the internal structure as compared with the normal (Fig. 236). (Freiberg.)

by the outward deviation of the leg. Just so are the shapes of the bones in club-foot the expressions of similar functional accommodation to an inward rotation of the foot, or even, sometimes, an inward turning of the whole lower extremity. The faulty position of an extremity under these circumstances is to be regarded rather as a cause of the deformity than as an effect. This faulty position must always occupy a place intermediate between the remote causes of deformity (hereditary predisposition, habit, muscular weakness, external conditions causing pressure or narrowing space of growth), and the anatomical results which these various remote causes bring about.

"When the altered demands upon an extremity do not occur spontaneously, as in the above instances, but, on the other hand, result from a primary disturbance in the shape of the bones, due to trauma or bone disease, with consequent softening or destruction of tissue, there is added to this a secondary change in the external configuration of the bones, and there is thus caused a 'deformity in the broad sense of the word.' The difference between the two varieties of deformity therefore lies only in the addition of a second etiological factor (the trauma, etc.) to the deformity in the broad sense. Both varieties have it in common that the shape of the bones and joints of the deformed

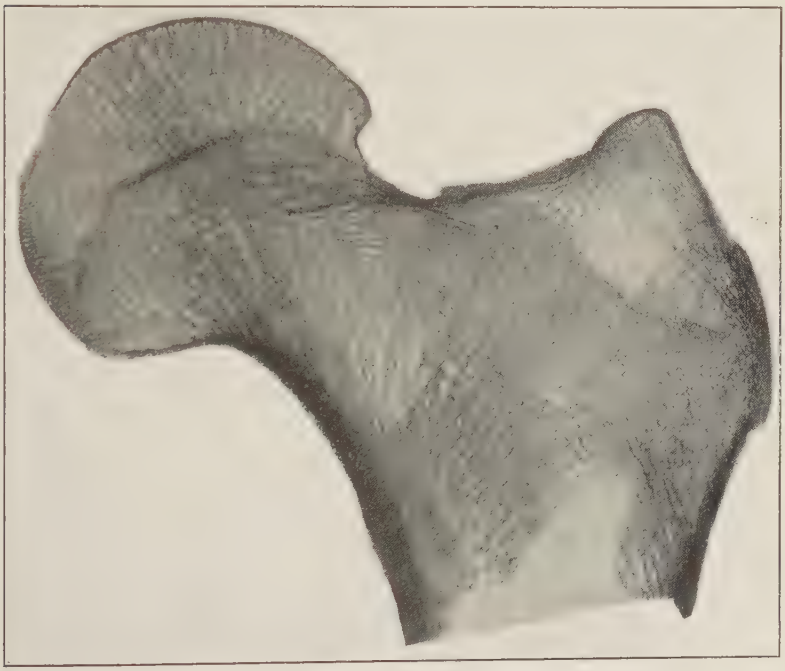

Fig. 236.—Normal femur from the same subject. (Freiberg.)

part represents nothing else than the expression of a functional accommodation to the faulty static demands made upon it.

"As a second example by means of which to explain the correctness of the doctrine of functional pathogenesis the author has selected scoliosis. In the first chapter the author showed in detail that the altered conditions in the length and height of the transverse processes of scoliotic vertebræ as well as corresponding conditions in the ribs of the scoliotic thorax are so evident as not possibly to escape notice, and that they can be explained in no other way than as functional accommodation to the circumstances of space, changed and brought about by the continual, faulty, and cramped position of the thorax;

this is as true of the convex as of the concave side of the vertebral column, to which the transverse processes and ribs in question belong. It must be manifest that changed relations of one part of the skeleton to any other part of the skeleton (as far as space conditions are concerned) necessarily bring about changes in the mechanical demands made upon this part, and therefore changes in the directions and values of the pressure, tension, and shearing strains of each and every point in this part of the skeleton. The conclusion thus drawn, that accommodation to space means the same as accommodation to function, is of greatest importance to the *general* doctrine of functional accommodation.

"The origin of the wedge-shape of the scoliotic vertebra now comes under discussion. It is assumed by the majority of writers that an abnormal softness of the bones is present in scoliosis by means of which a faulty position can model the bodies of the vertebræ as it does in the case of rhachitic disease of the bone, or as is really the case with the intervertebral disks in cases of 'habitual scoliosis.' While unsupported by any pathologico-anatomical investigations, it is allowed possible, or even probable, that such softness of the bones plays a role in many cases of scoliosis. It is certain, however, that this is by no means always the case, as evidenced by the development of scoliosis after empyema in adults, and the great exaggeration in adult life of very slight scolioses originating during youth. It is concluded, on the contrary, that the vertebra may acquire its scoliotic wedge-shape entirely independent of the pressure of the superincumbent weight. Furthermore, in the absence of any abnormal softness of the bones the body of a vertebra may lose height on the concave side and gain the same on the convex side through the 'trophic stimulus of function' purely; being simply an accommodation to the diminished space on the concave side and increased room at the convexity and the change of mechanical conditions consequent thereupon.

"This simple and natural conception of the circumstances concerning the scoliotic wedge must obtain credence, especially since the old view, corresponding to the 'pressure theory,' has been long ago disproved by Hoffa and Nicoladoni—namely, that the concave side of the wedge is the seat of atrophy, and that this atrophy accounts for the loss in height of the vertebral body on this side."

The importance of Wolff's theory, which shows how deformity may be acquired and how it may be avoided, is very evident. It is of equal importance in indicating the principles of treatment. For example, from the anatomical description of a club-foot the distortion might appear to be irremediable, but on this theory one feels assured that if the foot can be fixed for a sufficient time in the overcorrected position, the influence of the new static conditions will induce a gradual transformation, not only in soft parts, but in the bones as well, that will finally effect a cure. So, also, the correction of a distorted bone by operative means is at best imperfect; but with the change in the static conditions in a few years practically no trace of the former distortion,

either in contour or internal structure, will be evident. Scoliosis might be cured as perfectly as the club-foot or the bow-leg, were it possible to restore the normal conditions of weight and strain.

ATROPHY OF BONE.

The writings of Wolff have emphasized the fact that bone is a living tissue very readily affected by changing conditions, and that atrophy or hypertrophy may be local or general, according to the change in functional use of the affected part.

Since the Roentgen rays have come into general use, particular attention has been called to the atrophy of the internal structure of bone that follows lessened use or disuse, or from what is called trophic disturbance of nutrition from any cause. For example, after fracture or joint disease, or disease of the nervous system, or even slight injuries of the nature of sprains, atrophy of the lamellæ of the spongy portion and of the compact substance of the bone is soon apparent.

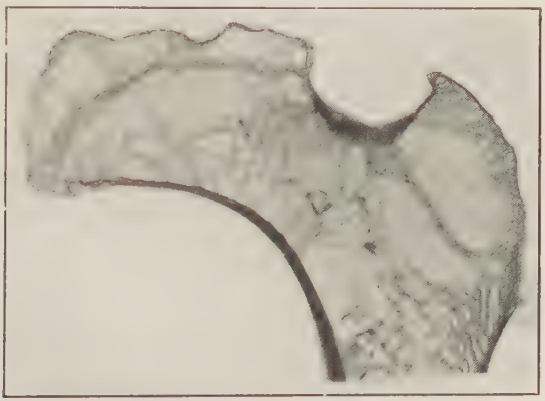

FIG. 237.—Section of femoral head of a paralytic idiot, aged thirty-five years, showing the extreme atrophy caused by disuse. (R. T. Taylor.)

This atrophy is not only rapid, but it may be widespread, as proved by the investigations of Sudeck,[1] who could distinguish atrophy of the bones of the foot within six weeks after fracture of those of the leg. Atrophy of bone is especially rapid as a result of acute affections of the joints, corresponding in this to the atrophy of the muscles under similar conditions. In the *x*-ray negative such atrophy is indicated by a loss of clearness of outline which is replaced by a peculiar blur, resembling closely the infiltration due to disease.

These nutritive changes explain the delay in recovery after apparently slight injury of a joint or other tissue. The treatment therefore should be stimulative, and functional use of the weak part should be encouraged as soon as possible.[2]

[1] Fortsch. auf dem Gebiets. der Röntgenstrahlen, Band **3**, Heft 6.
[2] Mally et Richon: Rev. de Chir., vols. **24** and **25**.

After long-continued disuse the bones may become extremely fragile and in those who have suffered from wasting disease their structure may undergo a fibrous transformation. This must be borne in mind when one attempts to correct deformity caused by paralysis, by chronic joint disease and the like.

HYPERTROPHY OF BONE.

This is usually due to disease. It may be general, as in osteitis deformans. It may affect corresponding bones, as in syphilitic enlargement and elongation of the tibiæ, or it may be limited to a single bone. Of this a familiar example is chronic osteomyelitis, which may induce thickening, and elongation of the affected bone sometimes to the extent of two or more inches.

TABLE OF WEIGHT, HEIGHT, AND CIRCUMFERENCE OF THE CHEST IN CHILDHOOD. (BOAS.)

		Pounds.	Kilos.	Height.		Chest.	
				Inches.	Cm.	Inches.	Cm.
Birth	Male	7.55	3.43	20.6	52.5	13.4	34.2
	Female	7.16	3.26	20.5	52.2	13.0	33.2
6 months	Male	16.0	7.26	25.4	64.8	16.5	42.0
	Female	15.5	7.03	25.0	64.6	16.1	41.0
1 year	Male	20.5	9.29	29.0	73.8	18.0	45.9
	Female	19.8	8.84	28.7	73.2	17.4	44.4
18 months	Male	22.8	10.35	30.0	76.3	18.5	47.1
	Female	22.0	9.98	29.7	75.6	18.0	45.9
2 years	Male	26.5	12.02	32.5	82.8	19.0	48.4
	Female	25.5	11.56	32.5	82.8	18.5	47.0
3 "	Male	31.2	14.14	35.0	89.1	20.1	51.1
	Female	30.0	13.60	35.0	89.1	19.8	50.5
4 "	Male	35.0	15.87	38.0	96.7	20.7	52.8
	Female	34.0	15.41	38.0	96.7	20.5	52.2
5 "	Male	41.2	18.71	41.7	106.8	21.5	54.8
	Female	39.8	18.06	41.4	105.3	21.0	53.5
6 "	Male	45.1	20.48	44.1	112.0	23.2	59.1
	Female	43.8	19.87	43.6	110.9	22.8	58.3
7 "	Male	49.5	22.44	46.2	117.4	23.7	60.6
	Female	48.0	21.78	45.9	116.7	23.3	59.5
8 "	Male	54.5	24.70	48.2	122.3	24.4	62.2
	Female	52.9	24.01	48.0	122.1	23.8	60.8
9 "	Male	60.0	26.58	50.1	127.2	25.1	63.9
	Female	57.5	26.10	49.6	126.0	24.5	62.5
10 "	Male	66.6	30.22	52.2	132.6	25.8	65.6
	Female	64.1	29.07	51.8	131.5	24.7	63.0
11 "	Male	72.4	32.83	54.0	137.2	26.4	67.2
	Female	70.3	31.87	53.8	136.6	25.8	65.8
12 "	Male	79.8	36.21	55.8	141.7	27.0	68.8
	Female	81.4	36.90	57.1	145.2	26.8	68.3
13 "	Male	88.3	40.04	58.2	147.7	27.7	70.6
	Female	91.2	41.36	58.7	149.2	28.0	71.3
14 "	Male	99.3	45.03	61.0	155.1	28.8	73.3
	Female	100.3	45.50	60.3	153.2	29.2	74.1
15 "	Male	110.08	50.26	63.0	159.0	30.0	76.6
	Female	108.04	49.17	61.4	155.9	30.3	79.8

MEDICAL LIBRARY BOSTON CITY HOSPITAL

PERCENTAGE OF THE PRINCIPAL TISSUES AND ORGANS IN BODY WEIGHT (VIERORDT).

	In newborn child.	In adult.
Muscles	25.05	43.40
Skeleton	13.07	17.48
Skin and subcutaneous tissues	19.73	17.77
Brain	12.29	2.16
Liver	4.57	2.75

PROPORTIONAL GROWTH OF BONES FROM EACH EPIPHYSIS.

	Distal end, per cent.	Proximal end, per cent.
Femur	69	31
Tibia	43	57
Humerus	19	81
Radius	75	25

IDEAL WEIGHTS (BALDWIN).[1]

FEMALES.

Height.	19 yrs.	20	21 22	23 24	25 29	30 34	35 39	40 44	45 49	50 over.
5 feet 0 inch	114	115	115	116	117	120	119	118	117	116
5 " 1 "	116	117	117	118	119	122	121	120	119	118
5 " 2 inches	119	120	120	121	122	125	124	123	122	121
5 " 3 "	122	123	123	124	125	128	127	126	125	124
5 " 4 "	125	126	127	128	129	131	130	129	128	127
5 " 5 "	129	130	131	132	133	135	134	133	132	131
5 " 6 "	133	134	135	136	137	139	138	137	136	135
5 " 7 "	137	138	139	140	141	143	142	141	140	139
5 " 8 "	141	142	143	144	145	147	146	145	144	143
5 " 9 "	145	146	147	148	149	151	150	147	148	147
5 " 10 "	149	150	151	152	153	155	154	153	152	151
5 " 11 "	153	154	155	156	157	159	158	157	156	155
6 " 0 "	158	159	160	161	162	164	163	162	161	160

MALES.

Height.	19 yrs.	20	21 22	23 24	25 29	30 34	35 39	40 44	45 49	50 over.
5 feet 3 inches	129	130	132	133	135	135	133	131	129	128
5 " 4 "	133	134	136	137	139	139	137	135	133	132
5 " 5 "	137	138	140	141	143	143	141	139	137	135
5 " 6 "	141	142	144	145	147	147	145	143	141	139
5 " 7 "	145	146	148	148	151	151	149	147	145	143
5 " 8 "	150	151	153	154	156	156	154	152	150	148
5 " 9 "	155	156	158	159	161	161	159	157	155	153
5 " 10 "	160	161	163	164	166	166	164	162	160	158
5 " 11 "	166	167	169	170	172	172	170	168	165	163
6 " 0 inch	172	173	175	176	178	178	176	174	172	169
6 " 1 "	178	179	181	182	184	182	179	177	177	175
6 " 1 inches	184	186	188	189	190	190	187	184	182	181
6 " 3 "	190	192	194	195	197	197	194	191	189	187

[1] These weights are without clothing. Clothes weigh from 6 to 8 pounds. It should be borne in mind that these weights are for persons of average frame and muscular development. Some allowance should be made for the heavier or more slender types of build.

CHAPTER V.

TUBERCULOUS DISEASE OF THE BONES AND JOINTS.

Etiology.—Three factors are recognized in the etiology of tuberculous disease: the infectious element (the tubercle bacillus), the predisposition of the patient, and the local condition that favors the reception and the growth of the bacilli.

Predisposition.—The predisposition, both general and local, is spoken of as lessened vital resistance. A general predisposition to disease may be inherited or it may be acquired. Thus, a history of tuberculosis in the immediate family of the patient is supposed to imply a lessened resistance to this form of disease. In a certain proportion, perhaps 25 per cent., of the cases this inherited predisposition is very direct and positive, but in the larger number the family history is as indefinite as in a similar class of patients under treatment for any other disease. The acquired predisposition is of more direct importance, since it would include the lessened vitality due to improper food and improper hygienic surroundings of every variety, together with the greater liability to depressing diseases and the more constant exposure to tuberculous infection that such conditions imply. Thus, tuberculous disease of the bones, as well as of other parts, is more common among the poor of cities than among the more favored classes.

Mode of Infection.—The tubercle bacilli may be introduced to the body by inhalation and find their way to the bronchial glands, or by the mouth and set up disease in the mesenteric glands, or infection through the nasal passages or neighboring parts may cause disease of the cervical lymphatics.

Latent Tuberculosis.—It may be assumed that disease of the bronchial and mesenteric glands is not uncommon in individuals of apparently perfect health, since it is often discovered at autopsies in those who have died from other causes. For example, in 2713 autopsies on children who died of acute infectious diseases reported by Ganghofner, tuberculous disease was found in 562, or about 20 per cent. Rothe and Gaffke[1] inoculated guinea-pigs with the material from the bronchial and mesenteric glands obtained from 400 cadavers of children, with 78 positive results (19.5 per cent.). Veeder and Johnson,[2] of St. Louis, found postmortem evidences of tuberculosis in children dying from other causes, as follows: Under two years, none; two to five years, 27.3 per cent.; five to ten years, 33.3 per cent.; ten to eighteen years, 62.5 per cent. This form of glandular disease is called latent tuberculosis. In many instances the disease may remain latent and finally disappear, or it may persist, and from time to time free bacilli or bits of infected tissue may escape into the blood and are deposited in other parts, where, under favoring conditions, local disease may be

[1] Deutsch. med. Wchnschr., July 23, 1911.
[2] Bull. New York Tuberc. Assn., 1924.

set up. Depression of the vitality from any cause should favor the progress of the glandular disease and dissemination of the infectious elements. It should also lessen the resistance of the tissues exposed to infection. This accounts for the well-known influence of certain diseases, such as measles and whooping-cough, not only in predisposing to local tuberculous disease, but in favoring its progress when it is already established. It is possible also that the bacilli that have found their way into the blood current more directly, as, for example, through wound infection, may set up primary disease of a bone or joint. In fact, it is stated by König[1] that in 14 of 67 autopsies on subjects who had suffered from tuberculous disease of the bones and joints no other foci were found in the body. In other instances the source of infection may be preëxistent disease of the lungs or of other internal organs.

In 769 autopsies on children under twelve years of age at the Hospital for Children, Great Ormond Street, London, reported by G. F. Still,[2] 269 presented tuberculous lesions. Of these 117 were less than two years of age.

The apparent channels of infection, as evidenced by the appearance of the glandular lesions, were as follows:

Respiratory:		
Lungs	105	
Probably lungs	33	
Ear	9	
Probably ear	6	
	153	= 57.0 per cent.
Alimentary:		
Intestines	53	
Probably intestines	10	
	63	= 23.4 per cent.
Other cases:		
Bones or joints	5	
Fauces	2	
Uncertain	46	
	53	

Northrup and Bovaird[3] have made similar observations at the New York Foundling Hospital:

Infection by respiratory tract	148
Infection by mesenteric lymph nodes	3
Indeterminate	48
	199

In 16 instances the process was confined to the bronchial glands, and in no instance were these glands found to be free from disease.

Bovaird[4] has collected the reported autopsies on tuberculous chil-

[1] Deutsch. Chir., 1900, L. 28a, S. 157. [2] British Med. Jour., August 19, 1899.
[3] Northrup: New York Med. Jour., February 21, 1891; Bovaird: Ibid., July 1, 1899.
[4] Arch. Pediat., December, 1901.

dren with reference to primary intestinal infection, and has called attention to the fact that the English observations are not in accord with others:

	Autopsies.	Primary intestinal diseases.
German	236	9 = 4 per cent.
French	128	0
English	748	136 = 18 "
American	369	5 = 1 "
	1481	150

Haushalter,[1] in 78 autopsies upon children dying from acute miliary tuberculosis, found in all but 4 disease of the tracheobronchial glands. In 44 this disease was the most ancient focus in the body.

Peterka[2] in 216 cases of surgical tuberculosis found evidence of infection during the first three years of life in 199. He concludes that complete cure of infection in early childhood is not attained in more than half the cases and that it is an important factor in tuberculous disease of later life. Reinhart,[3] on the other hand, from an examination of 460 cadavers, concludes that primary tuberculous infection is more common after adolescence than before, since less than 30 per cent. of the bodies under sixteen showed evidence of tuberculosis as compared to 96 per cent. of those of adult age.

Local Predisposition.—The local conditions that favor the growth of the tubercle bacilli may be induced by injury. Slight injury sufficient to cause, for example, a hemorrhage into the substance of the cancellous tissue induces a local congestion during the process of repair that provides the proper soil for the growth of the bacilli when they are deposited in its neighborhood. This has been proved experimentally by Krause and Ribera,[4] and it is supported by clinical evidence. The great preponderance of disease in the lower over that of the upper extremities in childhood may be cited as evidence of the influence of injury in the causation of disease. It may be noted also as a factor in the etiology that injury may set free dormant disease whose presence had been unsuspected.

In 577 of 3539 cases of tuberculosis of the bones and joints reported by Hildebrand,[5] König, Mikulicz, Bruns and Ribera, injury seemed to be a direct predisposing cause of the local disease (16.3 per cent.). A much higher percentage than this has been assigned by certain writers, but the exact relation of traumatism to disease can only be conjectured. For example, Voss[6] in 577 cases treated at Rostock found injury stated as the exciting cause in more than 20 per cent. Yet on further investigation in but 7 per cent. could its influence be clearly established.[7]

The primary disease is almost always in the newly formed bone about the conjugal cartilage, more often apparently, on the diaphyseal

[1] Arch. de Méd. des Enfants, March, 1902. [2] Beit. z. klin. Chir., 1912, vol. **8.**
[3] Correspondenz-Blatt für Schweizer Aerzte, Basel, September 8, 1917.
[4] Presse Méd., May 13, 1910.
[5] Deutsch. Chir., 1902, L. 13, S. 168. [6] Ztschr. f. Chir., 1904, No. 16.
[7] The literature of the subject may be found in the Arch. f. orthop. Mechanicotherasie u. Unfallchir., 1906, Band **4**, Heft 4, Deutschlander.

side. This tissue is vulnerable; it is more exposed to direct injury; it is subjected, also, to the strain of motion at the neighboring joint, and as the circulation is here more active the bacilli are more often deposited in this situation.

Ribera[1] found evidence of injury in 64 of 141 cases of disease of the larger joints. He states that, experimentally, tubercle bacilli have an especial predilection for bone marrow and that synovial membrane is very resistant to infection unless it is injured.

The vulnerability of growing bone accounts also for the relative frequency of bone disease in childhood as compared with adult life. Injury not only causes a local predisposition to disease, but it favors its progress when it is once established.

Distribution of the Disease.—In 13,308 cases of tuberculous disease of the bones and joints treated at the Hospital for Ruptured and Crippled the distribution was, in order of frequency, as follows:

Vertebræ	5,662	= 42.5 per cent.
Hip-joint	4,048	= 30.5 "
Other joints	3,598	= 27.0 "
	13,308	

In a total of 3561 cases treated at the Hospital for Ruptured and Crippled and at the Vanderbilt Clinic during a period of five years the distribution was as follows:

Vertebræ	1432	= 40.2 per cent.
Hip-joint	1123	= 31.5 "
Knee-joint	699	= 19.6 "
Ankle-joint	196	= 5.5 "
Elbow-joint	62	
Shoulder-joint	42	= 3.1 "
Wrist-joint	7	
	3561	
Trunk	1432	= 40.2 "
Lower extremities	2018	= 56.6 "
Upper extremities	111	= 3.1 "

The correspondence between these two tables of statistics is striking, and the number of cases is so large that the proportions may be accepted as approximately correct as applied to the distribution of the disease in childhood.

At the Boston Children's Hospital in a period of twenty-five years, 1869–1893, 3820 cases were treated.[2] The distribution was as follows:

Vertebræ	1964	= 51.4 per cent.
Hip	1402	= 36.7 "
Ankle	300	= 7.8 "
Knee	104	= 2.7 "
Wrist	20	
Shoulder	15	= 1.3 "
Elbow	15	
	3820	
Trunk	1964	= 51.4 "
Lower extremities	1806	= 47.2 "
Upper extremities	50	= 1.3 "

[1] Presse méd., May 13, 1910.

[2] Report of the Boston Children's Hospital.

Side Affected.—Disease of the joints is slightly more common on the right than on the left side of the body. At the Hospital for Ruptured and Crippled the proportions in the cases treated during a recent period of ten years are as follows:

Hip, right	53 per cent.
Knee, right	55 "
Ankle, right	50 "
Shoulder, right	64 "
Elbow, right	60 "

It has been stated that one of the explanations of the great preponderance of the disease of the lower over the upper extremity is the greater liability to injury. The same explanation has been advanced to account for the greater frequency of disease on the right side, which is more marked in the upper than in the lower extremity, because the right arm is more liable to overwork as well as to injury.

Sex.—Tuberculous disease of the joints is somewhat more common among males than females.

Of 3822 cases of Pott's disease treated at the Hospital for Ruptured and Crippled, 2037, or 53 per cent., were in males.

Of 3307 cases of disease of the hip-joint treated at the same institution, 1731, or 52.3 per cent., were in males.

Of 1218 cases of disease of the knee-joint, combined statistics of König and Gibney, 703, or 57.6 per cent., were in males.

Age.—In 5461 cases of tuberculous disease treated at the Hospital for Ruptured and Crippled, about seven-eighths of the patients were less than fourteen years of age.

Less than 14 years of age	vertebræ,	87.7 per cent.
	hip,	88.2 "
	other joints,	71.7 "
Between 14 and 21 years of age	vertebræ,	7.7 "
	hip,	9.2 "
	other joints,	10.7 "
More than 21 years of age	vertebræ,	4.5 "
	hip,	2.5 "
	other joints,	17.5[1] "

Of 1259 cases of Pott's disease treated recently at the same institution, 1075, or 85 per cent., of the patients were in the first decade; 50 per cent. were three to five years of age, inclusive, at the inception of the disease.

In 1000 cases of disease of the hip-joint the ages of the patients correspond closely to these; 87.2 per cent. were in the first decade and 45.2 per cent. were from three to five years of age, inclusive.

In 1000 cases of disease of the knee-joint, 75 per cent. were in the first decade and 40 per cent. were from three to five years, inclusive.

In 339 cases of the ankle-joint, 70 per cent. were in the first decade and 35 per cent. within the first three years of life.

[1] Knight: Orthopedia.

The distribution of the disease and its relative frequency at the different ages is shown by Alfer's table of statistics from Trendelenburg's clinic at Bonn.[1]

	0–5	5–10	10–15	15–20	20–25	25–30	30–35	35–40	40–45	45–50	50–55	55–60	60–65	65–70	Total
Vertebræ	89	59	32	23	9	10	3	6	3	1	4	0	0	0	239
Hip . .	58	59	43	46	9	11	6	0	4	1	1	3	0	0	241
Knee . .	47	52	47	37	20	11	23	11	11	3	2	8	6	3	281
Ankle .	5	9	10	5	2	1	1	3	2	0	3	0	2	0	43
Shoulder	0	2	2	6	3	5	3	1	1	2	2	1	0	0	28
Elbow .	7	14	14	21	12	9	6	5	9	8	5	2	2	0	114
Wrist .	1	0	0	1	5	0	0	3	1	3	2	1	3	0	20
Total .	207	195	148	139	60	47	42	29	31	18	19	15	13	3	966

This table illustrates the well-known fact that disease of the upper extremity, relatively infrequent at all ages, is proportionately far more common in adult life. Of the joints of the lower extremity the knee and the ankle are proportionately more often diseased in later life than is the hip.

The common type of infection in this country is with the human bacillus, but in bottle-fed children the bovine form is not uncommon in certain localities. Fraser investigated 70 cases of tuberculosis of the bones and joints of children under twelve years of age. In 41 bovine bacillus was found, in 26 human, and in 3 both varieties.[2]

Pathology.—When the bacilli are deposited in a part, the irritation of their toxins causes a proliferation of the fixed cells which lie in direct contact with the germs, and about these a ring of leukocytes forms. The bacilli, the epithelioid cells including often one or more giant cells, together with the surrounding leukocytes, constitute the visible tubercle of bone, a minute grayish speck in the cancellous structure. The central cells about the bacilli, increasing in number, deprived of nourishment by the obliteration of the blood spaces and poisoned by the toxins, die and are disintegrated to granular material, "caseate," and the tubercle changes to a yellow color; but the bacilli, multiplying and escaping, form new tubercles about the original focus, which coalesce as the area of the disease enlarges. Meanwhile the surrounding tissue becomes congested as the result of the irritation, and the fixed cells become organized, or partly organized, into a feeble, ill-nourished form of granulation tissue, representing an effort to shut out and to expel the foreign substances formed by the disease. Or, if this local resistance is effective, the cells become organized into firm granulations which surround and destroy the germs, and then are further transformed into scar tissue. But in most instances, either because the irritation is insufficient or because of the deficient vitality

[1] Beitr. z. klin. Chir., Band 8, Heft 2.
[2] Jour. Am. Med. Assn., January 2, 1915.

of the part, the granulations are feeble and unstable, and they in turn becoming infected by the multiplying bacilli serve only to extend the area of the disease. This granulation tissue, before and after the stage of infection, absorbs and destroys the bone. If the progress of the disease is slow, the cancellous structure is completely absorbed or is represented only by "bone sand," but if the disease infiltrates the bone more rapidly it may destroy its vitality while its structure is still retained, and a sequestrum is formed. Such sequestra, consisting of rounded, yellow, crumbling masses of cancellous structure, of the size of a pea or larger, are especially common in epiphyseal disease of childhood. In rare instances wedge-shaped sequestra are found with the base at the periphery of the epiphysis. These are apparently caused by the lodging of an infected embolus in a terminal vessel, thus cutting off the blood supply.

By the formation of new tubercles at the periphery and by the caseation of material in the center of the diseased area a cavity in the bone is formed, containing granulation tissue, often sequestra of larger or smaller size, and a variable amount of fluid, made up of serum and leukocytes. The walls of this cavity are formed by tissues in which the disease is active; the inner layer containing the tubercles in the various stages of formation and degeneration, the outer, composed of feeble, ill-nourished, granulation tissue as yet not infected, and beyond this the softened and infiltrated bone. If the disease has ceased to progress in any direction the granulations contain more bloodvessels, they are of firmer consistency and more perfectly organized, and the substance of the bone is harder, showing the evidence of repair.

One termination of the disease is by enclosure of the focus by resistant granulations, behind which the bone solidifies and shuts in the disease, or in favorable cases in which its area is small, completely absorbing and replacing it by scar tissue.

Extra-articular Disease.—As a rule the tendency of the process is to expand and to force an opening through the cortex of the bone. In certain cases this opening may form beyond the capsule of the joint, and through it the products of the disease may be discharged into the overlying tissues, forming a *tuberculous abscess*. Here the same process of infection and extension of the area of disease continues, but more rapidly than when it was confined within the bone. The surfaces of the muscles and fascia are infected, and are covered with an abscess membrane of violet or grayish-yellow color, made up of tuberculous tissue and masses of fibrin, lying upon and loosely attached to the outer inflammatory or healthy granulations.

The tuberculous fluid is usually of a thin consistency, composed of serum, leukocytes, fibrin, masses of degenerated tissue, and fragments of bone or bone sand. It is commonly of a whitish color, occasionally reddish from mixture with blood, and in the later stages, yellow and serous-like. The abscess enlarges in the direction of least resistance, and in most instances finally perforates the skin by one or more open-

MEDICAL LIBRARY BOSTON CITY HOSPITAL

ings through which its contents are discharged. Or it may cease to progress, its contents may be absorbed, adhesions may form between its walls, and a spontaneous cure is effected. Extra-articular disease, without ultimate involvement of the joint, is unusual. It is more common at those joints, like the knee, elbow, and ankle, where the bones are superficial; it is very uncommon at the hip-joint, and it is practically impossible in disease of the spine.

Perforation of the Joint.—Usually the tuberculous process about the epiphysis, enlarging its area, finds its way into the joint. While the disease is still confined to the bone, the tissues within the joint are involved in a sympathetic irritation or inflammation. The synovial membrane becomes congested and hypertrophied; the synovial fluid is increased and changed in quality; fibrin forms and is deposited upon the cartilage and upon the lining membrane of the capsule. It is stated by König that the organization of these fibrinous deposits upon the cartilage plays an important part in its destruction, even when actual tuberculous disease is absent. As a result of the sympathetic inflammation within the joint, adhesions may form which may limit the area of the tuberculous disease and retard its progress after perforation has taken place. This process is similar to the inflammatory changes in the pleura caused by underlying tuberculous disease of the lung.

When the disease comes into contact with the cartilage it disintegrates; the tuberculous granulations breaking through and spreading over its surface destroy it piecemeal, or advancing beneath it, separate it from the bone in necrotic fragments. The synovial membrane becomes thickened and infiltrated, numerous tubercles appear upon its surface, which undergo the secondary changes that have been described, and the joint becomes, practically speaking, an abscess cavity. The surfaces of the bones are disintegrated by the disease, and the destruction is hastened by pressure and friction. The capsule, distended by the fluid and solid products of the disease, is usually perforated, and a secondary abscess, communicating with it, is formed in the surrounding tissues. As results of the disease, secondary changes appear in the neighboring parts. The irritation of the periosteum if the disease is of a quiescent type, may induce the formation of irregular layers of bone or osteophytes about the joint. A new formation of connective tissue proceeding from the layer of granulations that surround the disease may extend to the muscles and tendon sheaths, binding them together and causing limitation of motion. This tissue may be very vascular and irregular in formation, and intermixed with it may be masses of gelatinous or myxomatous substance caused apparently by the venous stasis and edematous infiltration induced by the pressure of the capsular contents and extracapsular proliferation of granulation tissue. These changes in the appearance and in the consistency of the tissues about the joint are characteristic of the so-called white swelling.

Tuberculous disease may begin on the epiphyseal side of the con-

jugal cartilage, or primarily on the diaphyseal side and remain extra-articular, or in rare instances the shaft may be involved in a progressive infiltrating form of disease as in 9 of 987 cases treated in Bruns's clinic.[1] Of this the most familiar example, usually multiple in its distribution, is "spina ventosa"—a central disease of a phalanx, causing distortion of the finger.

Other Forms of Tuberculous Disease of Joints.—All of the German writers describe forms of primary synovial disease, its frequency varying from 16 to 35 per cent. of the cases. It is more common in adult life than in childhood, and at the knee than at other joints. Nichols,[2] on the other hand, states that he has examined 120 tuberculous joints and has found in every instance one or more foci in the bone that apparently preceded the disease in the joint. This is certainly not in accord with clinical experience, for one must recognize a form of disease in which the symptoms differ from the ordinary osteal type. It begins as a chronic synovitis, although the tissues are more thickened and infiltrated than in simple synovitis, and the muscular atrophy is more marked. Reflex spasm and limitation of motion are slight, and the symptoms are rather discomfort and fatigue after exertion than actual pain. Later, sometimes after many months, when it may be assumed the bones are involved, the characteristic symptoms of tuberculous disease appear. In one form of synovial disease the amount of effused fluid is large, and it is clear and serous-like in character—hydrops tuberculosis—but usually it is cloudy, and it may be purulent in character. Nichol's specimens were from advanced cases of the disease in which the primary infection could not be determined. At the present time exploratory operations are more often made in early cases for the purpose of exact diagnosis, and from the evidence thus obtained it would appear that disease of the synovial membrane often precedes that in the bone. In a series of 23 cases reported by Smith,[3] the disease appeared to be primarily synovial in 17.

As has been stated, König lays stress upon the important part played by fibrin in the changes that take place within a joint. Fibrin deposited from the effused fluid forms in successive layers upon the cartilage. Into this fibrin vessels grow from the hypertrophied and infected synovial membrane, destroying the cartilage together with the underlying bone. If the synovial disease is primary the erosion of bone is superficial as contrasted with the ordinary osteal type. Synovial tuberculosis is essentially a subacute chronic affection and it is therefore often mistaken for traumatic or so-called rheumatic synovitis.

Tuberculosis may involve any part of bone or joint, but its effects differ somewhat according to the character of the tissue involved.

Arborescent Synovial Tuberculosis.—In this form the interior of the joint is covered with villous proliferations of the synovial membrane. It is not a distinct disease, but is an irritative hypertrophy that is

[1] Zumsteeg: Beitr. z. klin. Chir., 1906, Band **7**, Heft 1.
[2] Tr. Am. Orthop. Assn., xi.
[3] Arch. Surg., March, 1926.

present in syphilitic and rheumatic as well as in tuberculous joints. Its especial interest lies in the fact that the hypertrophied synovial growths may cause mechanical interference with the function of the joint.

Arborescent villous proliferations are formed of adipose and fibrous tissue covered with a layer of round cells. The hypertrophied masses which project into the joint are often of large size (lipoma arborescens), attached to the synovial membrane by a smaller pedicle. They are single or multiple, and vary in color from yellow to deep red. They may be of a soft or firm consistency. In this form of disease there is usually pain, limitation of motion; often the swollen joint is irregular in outline; the hypertrophied synovial prolongations are sometimes apparent on palpation.[1] The exact diagnosis is usually made only after an exploratory incision, and in such an event the removal of the larger growths would be indicated. The outcome depends, of course, upon the cause, the hypertrophy depending usually on an underlying tuberculous, syphilitic, or other chronic disease. In the instances in which the hypertrophied tissue is in itself the cause of the disability by interference with function, relief may follow its removal.

FIG. 238.—Lipoma arborescens. (Painter and Erving.)

Rice Bodies.—Rice bodies are small, grayish-white bodies resembling cucumber seeds that are found in certain forms of synovial disease, and particularly in tuberculosis of tendon sheaths. They are formed of fragments detached from the proliferating synovial membrane and possibly of simple fibrin, which, under the influence of pressure and attrition in the movements of the joint or of the tendon, assume the characteristic shape and appearance. These bodies, within a tendon sheath or joint, cause a peculiar creaking, perceptible to the touch when the part is moved.

Dry Caries (*Caries Sicca*).—In this form of disease, which is apparently primarily synovial, there is but little formation of fluid and but little tendency toward cheesy degeneration of the tuberculous products.

[1] Painter and Erving: Boston Med. and Surg. Jour., March 19, 1903.

The infected granulations destroy the bone without forming sequestra, and usually without suppuration. This form more often occurs at the shoulder-joint, and it is characterized by marked limitation of motion, extreme atrophy of the surrounding parts, and sometimes by forward displacement of the partly destroyed head of the humerus that may be mistaken for a primary dislocation.

Tuberculous Rheumatism.—According to Poncet[1] chronic polyarthritis in tuberculous subjects is often caused by toxins or attenuated forms of bacilli. It may be acute in character or resembling the ordinary forms of so-called rheumatoid arthritis.[2]

Septic Infection.—After a tuberculous abscess has opened spontaneously, or if it has been incised, infection with pyogenic germs is common, and it occasionally occurs before a communication with the exterior has been established.

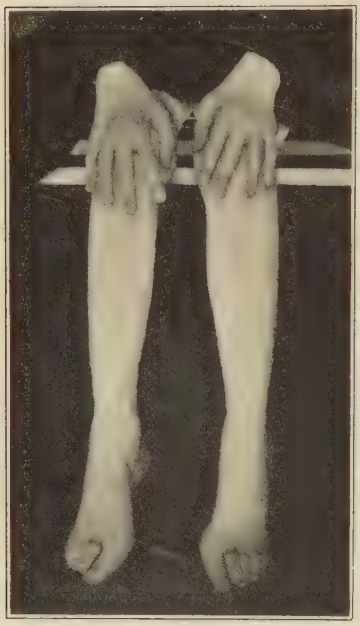

FIG. 239.—Tuberculous "rheumatism" and equinus deformity.

After such infection the surrounding tissues become infiltrated, reddened, and sensitive to pressure. The discharge is greatly increased in quantity and changed in quality. The local pain and discomfort are aggravated; if the joint is involved the destruction of the bone goes on with increased rapidity, and the constitutional effects of pyogenic infection appear. If the area of the abscess is small and if the drainage is efficient, this accident is of slight importance, and it may even exercise a beneficial effect in stimulating the circulation and dissolving the effused material about a joint. But if the abscess has burrowed widely into surrounding tissues and if it communicates with an important joint it is a dangerous complication; in fact, the greatest direct danger of tuberculous joint disease. Persistent suppuration exhausts the patient, and by lessening the vital resistance it favors the local advance of the tuberculous disease and its general dissemination. It is in this class of cases that amyloid degeneration of the internal organs is common, induced not by tuberculous disease, but by the secondary infection and its consequences. Amyloid is a proteid substance composed of amino-acids and rich in tyrosin. It is deposited about the bloodvessels and in the walls of the larger ones. The spleen, liver and lymphatic glands are first involved. Recovery is possible if the suppuration is checked.

[1] Bull. et Mém. de la Soc. Méd. des Hôp. de Paris, 1909, vol. **68.**
[2] Lyle: Ann. Surg., March, 1912.

Repair.—Repair in tuberculous disease may be accomplished by the absorption, ejection, or enclosure of the disease. The process of repair usually accompanies the advance of the destructive process, and examples of the three methods of cure may be found in a single joint.

The curative agent is the granulation tissue which forms about the area of disease, and which, finally becoming sufficiently organized to resist further infection and solidifies into fibrous tissue. In those cases in which the disease is not absorbed or completely thrown off in the abscess formation, but is enclosed, it becomes quiescent. In such cases injury, when, for example, the surrounding adhesions are broken down in the attempt to correct deformity or to overcome anchylosis, may cause local recurrence or dissemination of the disease.

Prognosis.—The prognosis will be considered more particularly in the sections on disease of special parts. The danger to life is direct and indirect, and this varies greatly with the part that is affected and with the age of the patient.

In disease of the spine the direct danger to life is greater than in joint disease, because of its situation, since it may involve the spinal cord or extend to the important organs in the neighborhood. Abscess may, in rare instances, merely by its size and situation, endanger life, and when infected it is far more dangerous because of the difficulty in providing efficient drainage. The influence of deformity and its effect in compressing the internal organs and thus interfering with the vital functions is another more remote element of danger in disease in this situation.

The danger to life from disease of the joints is in proportion to their importance. In rare instances the disease may extend from the epiphysis to the shaft of a bone and set up an extensive osteomyelitis; or the patient may be weakened by the suffering caused by active disease, but, as has been stated, the most direct and constant danger is from prolonged suppuration that follows septic infection. Danger from this source is much greater at the hip-joint than at the ankle or elbow, for example, because of the greater difficulty in preventing the burrowing of pus when infection has occurred.

The indirect danger of tuberculous disease is its dissemination to more important organs. But it by no means follows that the disease of the joint is the source of the general infection. For, as has been stated, it may be inferred that nearly every patient with joint disease has also disease of the lymphatic glands, and in a certain proportion of the cases there may be active disease of other important organs as well. Tuberculosis of the lungs, for example, is often present in the adult before the local outbreak in the joint appears, and it is in great degree because of this liability to disease of the lungs that the prognosis of joint disease becomes progressively worse with the age of the patient.

This point is illustrated by the statistics of König and Bruns on the final results of disease of the knee- and hip-joints, to which attention will be called again in the special sections. In König's cases of

disease of the knee-joint the influence of age upon the death-rate is presented in the following table:

Less than 15 years of age	20 per cent.
From 16 to 30 years	24 "
From 30 to 40 years	44 "
More than 40 years	60 "

In Bruns's statistics the death-rate was of patients in the first decade, 36 per cent.; in the second decade, 44 per cent.; older than this, 72 per cent.

In but 6 of 900 children under treatment for hip disease by Bowlby were the lungs involved.

The cure of latent tuberculosis in the lymph nodes as well as of active disease of the lungs or bones depends upon the vital resistance of the patient. This vital resistance is lessened by pain, by confinement and lack of exercise. It is directly impaired by exhausting suppuration. Under these conditions the local disease advances and a general dissemination is more probable. This accounts for the fact that death from general tuberculous infection is far more common in this class than when suppuration has been slight or absent. This point is again illustrated by the statistics referred to. The death-rate in the cases of disease at the knee without abscess was 25 per cent., with abscess 46 per cent. Death-rate in cases of disease at the hip with abscess 52 per cent., without abscess 23 per cent.

It is probable that tuberculosis may be disseminated by operations upon tuberculous joints, although the evidence upon this point is vague and conflicting. Gibney, contrasting two equal periods of thirteen years of service at the Hospital for Ruptured and Crippled, in the first of which no operations were performed on tuberculous subjects, states that in his opinion the deaths from this source have been proportionately no greater during the period of active surgical intervention than before. An investigation of the causes of deaths among the patients treated at the New York Orthopaedic Dispensary and Hospital during a period of twenty years showed that at least 25 per cent. of these were due to tuberculous meningitis.[1] During this period there had been, practically speaking, no operative intervention, yet the proportion of deaths from this cause is certainly as great as in any statistics that have been reported. It would appear, then, that the danger of dissemination is not sufficient to deter one from performing any operation that seems to be indicated by the character of the local disease or by the general condition of the patient.

Diagnosis.—Diagnosis is considered at length in the sections on diseases of the special joints. The *tuberculin tests* in suspected disease of a joint, except in young children, are chiefly of value from a negative standpoint, for the reason that tuberculous disease of the lymph glands or elsewhere is so common even among those whose joints are free from disease. According to Northman, 77 per cent. of children

[1] Personal communication from Dr. David Bovaird.

between three and seventeen years react and 100 per cent. of those between fifteen and seventeen years. Of 532 children tested by Hamberger[1] 271 reacted positively. Of those in the first year of life, but 2 per cent. reacted as compared with 94 per cent. between eleven and fourteen years. For the same reason the test is valueless as an indication of practical cure. This is illustrated by the investigations of Frazier and Biggs[2] of patients clinically cured of local tuberculosis, some by operative means, in 78 per cent. of whom a positive reaction to tuberculin was obtained. In some instances, however, a local reaction may indicate foci of disease which would not otherwise have been suspected. The von Pirquet skin reaction is usually employed, but the direct injection is more reliable. Since in the former the reaction to the bovine and human tuberculosis is the same.

Tinker, who has reported a series of four hundred tests from Johns Hopkins Hospital, states that healthy individuals react if the dose is sufficiently large. One therefore begins with small injections, from 1 to 3 mgm. of Koch's old tuberculin. This may be increased to 9 mgm., a reaction to less than this amount being practically positive if the temperature of the patient taken at intervals of two hours for at least eighteen hours has been normal. The reaction appears in from six to eight hours.

The roentgen-ray is often of value in demonstrating the effects of disease, and in certain instances may indicate its exact locality and extent. As a means of early diagnosis of joint disease in young subjects, however, it is of little importance as compared to the physical signs, because of the non-development of the bony structure of the epiphysis.

Treatment.—From what has been stated of the causes of disease it follows that the general treatment should include, if possible, an improvement of hygienic conditions, relief from the danger of further infection, open air, sunlight, and proper food. These are as essential in the treatment of tuberculosis of the bones as of other parts.

The importance of the constitutional treatment of tuberculous disease, more particularly the proper environment in which the greater part of the day and even the night may be passed in the open air, can hardly be exaggerated. Sea air and sea bathing are important agents in stimulating metabolism.

Direct Sunlight (*Heliotherapy*).—In 1903 Rollier,[3] at Leysin near Geneva, began the treatment of surgical tuberculosis by direct exposure of the body to sunlight, a practice that in a modified form has been generally adopted. The details of the treatment as conducted by Rollier are summarized by Pryor as follows:

Certain steps are very important and can be presented briefly. The insolation is very gradual and slowly completed. The diseased part is kept covered and only exposed to the sun after the coat of tan is existent over the remainder of the body. The patient is made accustomed

[1] British Med. Jour., July 9, 1910.
[2] Univ. Med. Mag., February, 1901.
[3] New York Med. Jour., June, 1915.

to open-air life and sleeping out of doors for about one week. During this period the temperature, respiration and pulse, and the results of the urine and blood examinations are recorded.

First Day.—Preparation for the sun bath includes protection from wind or draft. The head is protected by a linen cap or a small awning at the head of the bed, and the eyes shaded by colored glasses or covered with a towel. Then the patient's feet are exposed to the direct sun's rays for five to ten minutes three or four times a day at hour intervals.

Second Day.—The feet are insolated ten minutes, the legs from the ankles to knees five minutes three or four times at hour intervals.

Third Day.—The feet are insolated fifteen minutes, the legs from the ankles to the knees ten minutes, and the thighs five minutes three or four times at hour intervals.

Fourth Day.—The insolation of the previously exposed parts is increased by five minutes three or four times a day at hour intervals.

Fifth Day.—Again, the insolation of the previously exposed parts is increased by five minutes and the chest is exposed five minutes three or four times at hour intervals.

Sixth Day.—The exposure of the previously insolated parts is again increased five minutes and the neck and head are exposed five minutes three or four times at hour intervals.

Seventh Day.—If all conditions allow the patient is turned on his abdomen and the same course as described repeated.

Gradually the whole body and finally the diseased part is exposed and tanned as deeply as possible. After each insolation the patient is rubbed with spirits of camphor with a rough glove. Ultimately in the course of weeks the insolation is practised from four to six hours a day. This treatment is all carried out on the bed to secure convenience and control. Caution must be observed to prevent sunburns and dermatitis. These accidents can be entirely avoided with practice. Reactions may occur if the exposure is pushed too rapidly, and the condition of the individual must be considered, particularly if fever is present. When the children are hardened by exposure an air bath is given on cloudy days to maintain it. During the summer the children, well-tanned, can play or walk about most of the day unclothed except for a loin cloth. The patient gradually acquires a generous coat of tan, and the skin has a bronze hue, then a copper color and finally the desired chocolate brown appears to signify intensive pigmentation.

It is assumed that the direct effect of the sunlight is to increase metabolism and to raise the hemoglobin index. The character of the tan and its permanence are of diagnostic value as an index of the proportion of hemoglobin. Thus normal tanning indicates good resistance, while rapid depigmentation suggests secondary anemia. Locally it exercises a bactericidal influence, the ultraviolet rays, according to Rollier, being of the first importance. According to Bardenheuer,[1]

[1] Deutsch. Ztschr. f. Chir., vol. **112.**

MEDICAL LIBRARY OF THE BOSTON CITY HOSPITAL

of 371 cases treated by Rollier, 78 per cent. were cured, 13 per cent. improved, 6 per cent. were still under treatment, the mortality being 4 per cent. There was practically no operative intervention. Mechanical treatment of diseased joints was limited to rest in bed for long periods combined with traction in cases of deformity and pain. If plaster splints were used openings were made for the direct application of the sunlight. In Pott's disease both the kyphosis and the abdomen are exposed for the purpose. Abscesses and suppurating tracts received no other treatment. In the analysis of the report it must be borne in mind that relief of local symptoms and improvement in the general condition would not be classed as a cure from an orthopædic standpoint by which the estimation of the result is based on function.

Operative Treatment.—As far as the cure of local disease is concerned, no treatment can be as effective as the prompt and thorough removal of the focus of disease, while it is yet limited in extent, and before the joint has become involved. This is practicable, however, in but a small proportion of the cases in childhood, because it is usually impossible to locate the disease accurately and impossible to remove it without sacrificing normal bone upon which the future usefulness of the part depends. At one time early operation, even complete excision of the joint, was justified on the plea that the disease might thus be eradicated. But now that it is known that in nearly all cases other tuberculous foci exist in the body, and as the functional results after these early operations are usually inferior to those attained under conservative treatment, early excisions are limited to the adolescent or adult cases. For in this class growth has been attained and the economic conditions require that the period of disability should be as short as possible. In this class, also, early exploratory operations are often indicated, sometimes for the purpose of establishing the diagnosis, and if the disease is of the synovial type the complete removal (synovectomy) of the diseased tissue would be indicated.

Mechanical Treatment. Brace treatment is conducted with the aim of relieving the part from strain and injury. Functional use of a diseased joint delays natural repair, since it causes pain and thus reduces the reparative force, while it stimulates the disease and increases its destructive action. The details of treatment will be described in the consideration of disease of special joints.

Drugs.—The administration of drugs has a very subordinate place in treatment, since it is not believed that any drug exercises a direct action upon the local disease in the bone.

Cod-liver oil, the hypophosphites, the various preparations of iron or other tonics may be given at certain times with benefit, but the continuous administration of medicine during the years that are required to complete a cure is, of course, out of the question.

Tuberculin.—The routine administration of tuberculin has been abandoned. Temporary improvement is usually noted when the remedy is being tested on groups of cases, but this may be ascribed in great part to the better care that the patients usually receive at

such times. It may be of benefit in special cases and is not harmful if administered with caution.

Local Applications.—Iodoform.—Iodoform is supposed to exercise a direct germicidal action, and also to stimulate the formation of the granulations that cast off or absorb the tuberculous products and then become transformed into fibrous tissue. Its use is now practically limited to the treatment of tuberculous abscesses and certain forms of synovial tuberculosis. Iodoform is ordinarily employed in an emulsion with glycerin or oil, 10 c.c. of 10 per cent. mixture being injected at intervals of two or more weeks after aspiration. Several deaths from iodoform poisoning have been reported, but injections of this quantity of the drug are apparently free from danger.

Calot's Fluids.[1]—These mixtures are interchangeable, but the first is preferred if the contents of the abscess are liquid ("ripe"), the second when the products of disease are but partly broken down. The dose of each is from 2 to 12 gm. repeated at intervals of a week or more, 10 or more injections being employed in the treatment of the ordinary case. (See Pott's Disease.)

Iodoform Filling for Bone Cavities (v. Mosetig-Moorhof[2]).—Equal parts of spermaceti and oil of sesame are sterilized on a water-bath and are mixed with finely powdered iodoform in a proportion of 60 to 40 of the drug, making a yellow brittle wax melting at 50° C. When used it is heated just above the melting-point and constantly stirred. The cavity in the bone, having been made absolutely dry, is filled with the fluid, which solidifies as the temperature is lowered. The wound is then closed. The filling is slowly absorbed, its object being to preserve the contour of the bone. In a series of 220 cases reported by this author no local disturbance followed the procedure. Kaufman[3] has used plaster of Paris as a filling material since 1912 with satisfactory results. His observations are confirmed by Nystrom[4] who mixes the plaster paste with rivanal solution 1 to 1000.

Beck's Preparation.—E. G. Beck originally used for injection, bismuth and vaseline in proportion of 1 to 3. The mixture is made while the vaseline is boiling and is injected at a temperature of 110°. The abscess is evacuated by aspiration and a sufficient quantity is injected to distend the abscess cavity and thus to exercise a certain degree of mechanical pressure. In the process of absorption it is assumed that nitric acid is set free and that a germicidal action is thus exerted. To fill the abscess cavity a large quantity of the mixture may be required and the injection must be repeated at intervals. Many cases of poisoning of a mild type have been recorded and several deaths—one from

[1] Calot's fluids for injection:

No. 1.		No. 2.	
Guaiacol	1 gm.	Camphorated napthol	2 gm.
Creosote	5 "	Glycerin	12 "
Iodoform	30 "	Shake before injecting.	
Ether	30 "		
Oil	70 "		

[2] Deutsch. Ztschr. f. Chir., vol. **71**, No. 5.
[3] Ztschr. f. klin. Chir., August 15, 1925.
[4] Zent. f. Chir., May 19, 1928.

the injection of as small an amount as six ounces. Consequently the proportion of bismuth has now been reduced to 10 per cent., and white wax, in a proportion of 2 ounces to 10 pounds of paste, is added.[1] The symptoms of poisoning are headache, vomiting, loss of strength, livid color, ulceration of the gums, etc.

It is now generally held that the chief curative influence of these injections is mechanical, *i. e.*, the removal of pus, the exclusion of air and pressure on the granulation tissue; consequently, that non-toxic preparations are equally efficacious. Blanchard[2] has used white wax 1 part, vaseline 8 parts mixed while boiling, or in badly infected cases, iodin scales are mixed with the paste. After the injection a pad saturated in alcohol is bound over the sinus to prevent the escape of the fluid.

Of 150 cases reported 35 per cent. were cured by from 1 to 8 treatments. Thirty per cent. were cured in a year, and 35 per cent. remained unimproved.

Blanchard concludes that cases with sequestra, or those in which free drainage is required, or those in which the sinus is newly formed, should not be treated by this method, but that chronic cases in which the discharge is small and semipurulent are often greatly benefited by it.

Beck's mixture was originally used for the purpose of demonstrating the situation and extent of abscesses and sinuses by roentgen-ray pictures, and for this purpose it is of value aside from its possible therapeutic action. (See Sinuses.)

Carbolic Acid.—Carbolic acid in dilute solutions was at one time injected into tuberculous cavities, but its use has been generally discontinued because of the danger of poisoning. Pure carbolic acid may be injected into the fistulæ or into the abscess cavity which has been opened; it is allowed to remain for about a minute, when it is neutralized by copious injections of alcohol, after which the part is thoroughly cleansed by salt solution. Carbolic acid doubtless acts as a caustic, destroying the infected granulations and stimulating the reparative processes. Other remedies of this class, for example tincture of iodine, chloride of zinc, actual cautery and the like, are also used, and in certain cases with benefit. In the treatment of tuberculous ulcerations, ichthyol, balsam of Peru, and iodoform are among the drugs employed. Balsam of Peru dissolved in castor oil of a strength of about 10 per cent., as suggested by Van Arsdale,[3] is a very satisfactory application.

Roentgen-rays.—The roentgen-rays as a local treatment appear to act as a stimulant of the reparative process. It is of especial value as an adjunct in the cases in which the tissues about the joint are infiltrated and traversed by discharging sinuses. It must be used with caution in young subjects because of the danger of immediate injury and the effect in checking epiphyseal growth as noted in cases reported

[1] Jour. Am. Med. Assn., November, 1919.
[2] Med. Rec., May 18, 1912.
[3] Jour. Am. Med. Assn., March 14, 1908.

by Beck.[1] The so-called Alpine or ultra-violet light appears to exert a similar influence without this danger.

Active and Passive Congestion (Bier's Hyperemia).—Bier's treatment of tuberculous joint disease was suggested by the observation of Rokitansky, that phthisis was uncommon in individuals suffering from disease of the heart when the mechanical obstruction was sufficient to cause venous congestion of the lungs.

Passive Congestion.—Passive or venous congestion of a joint is attained by constricting the limb with several circular turns of a soft-rubber bandage above the affected joint sufficiently to interfere with the return of the venous blood, but not with the arterial supply.

The congestion may be localized if desirable by bandaging the limb firmly with flannel or other somewhat elastic material up to the lower margin of the joint. This, however, is not essential, and in treating disease of an extremity in which the other joints are stiffened or in which the muscles are atrophied and contracted the congestion of the entire limb is indicated. When properly applied the joint becomes swollen and dark red in color. The local temperature is raised. This is what Bier calls hot congestion, as distinct from edema (cold congestion), that would result if the rubber bandage were applied so tight as to constrict the arteries. Passive congestion should not cause or increase pain. If it has this effect it is improperly applied or is unsuitable for the case (Fig. 240).

The application should be limited to one to three hours daily in one or several periods, according to the effects.[2]

The action of the venous or passive congestion is, according to Bier, as follows:

1. It increases the formation of fibrous tissue and induces hypertrophy of the bones.
2. It has a bactericidal action in infectious joint disease, notably tuberculosis.[3]
3. It exercises an absorptive effect on the effused products of disease and on new formations that check joint motion.
4. It relieves pain and lessens the activity of progressive joint disease.

Passive congestion for tuberculous joint disease should be an adjunct to protective treatment, although this is not the opinion of Bier, who favors motion rather than fixation of the diseased joint. It may be continued indefinitely according to its effect. As a rule, pain is lessened by the treatment and muscular spasm decreases during its application, an effect explained apparently by the constriction of the muscles.

Abscess formation or appearance at least is apparently favored by the congestion. This may be treated by aspiration or incision and by injection as may seem desirable.

[1] Zent. f. Chir., 1928, No. 45.

[2] Bier: Hyperämie als Heilmittel, Leipzig, 1905, and Schmieden, Med. Rec., August 17, 1907.

[3] Gratt: Berlin. klin. Wchnschr., February 10, 1908.

Passive congestion is employed also for the treatment of chronic disability following injury, for chronic arthritis or other affection attended by infiltration of tissues, and by deficient circulation. In this class of cases the local congestion should be combined with massage. Local congestion may be attained by Klapp's suction appliances on the principle of cupping. This method may be employed with advantage in the treatment of sinuses and cavities which cannot be properly drained and for the immediate evacuation of pus through a small incision.

FIG. 240.—The application of passive congestion: *A*, the alternate point for the application of the bandage, in order to avoid atrophy from continuous pressure. *B*, the rubber bandage. (Bier.)

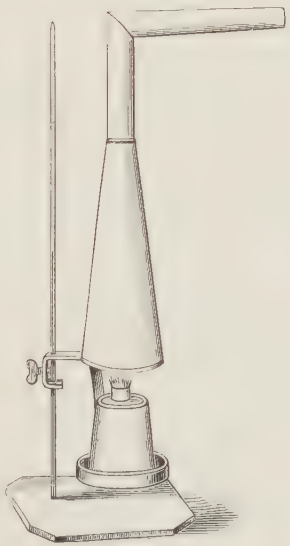

FIG. 241.—The alcohol lamp and chimney. Used for active congestion. (Bier.)

ACTIVE CONGESTION.—Active congestion is induced by the local use of heat, ordinarily hot, dry air.

In its simplest form the apparatus consists of an alcohol lamp provided with a long metal chimney reaching to a box of wood or metal, into which the limb is inserted through openings at either end. The

box has one or more small openings for the escape of air and moisture. The limb is usually wrapped in sheet wadding, and is particularly well protected from the parts of the box which may come in contact with the skin. The heat is then applied, usually to about 250° to 300° F., for from thirty minutes to an hour daily. The degree of heat is indicated by a projecting thermometer, and it is regulated by the comfort of the patient and by the observation of its effects.

Bier prefers simple boxes of wood of various shapes suitable for the different parts of the body, lined with packing cloth soaked in a solution of water glass. He considers these as efficacious as the complicated and expensive appliances, and at the command of all who desire to employ the treatment (Fig. 242).

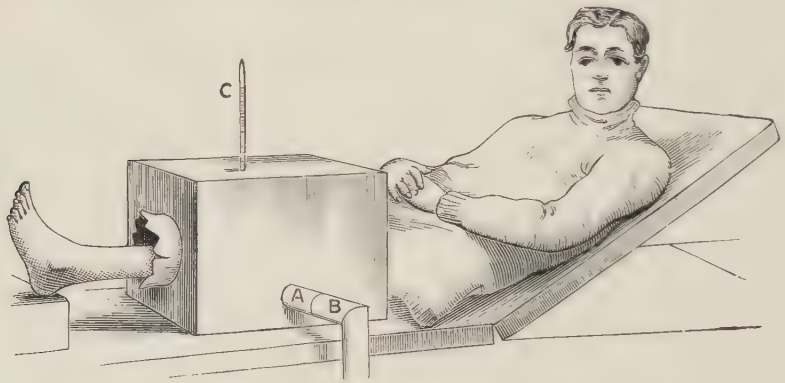

FIG. 242.—The application of the hot-air box for inducing active congestion: *C*, the thermometer; *A*, a metal pipe projecting from the box, into which the chimney of the lamp is placed; *B*, lamp chimney. (After Bier.)

The effect of the heat is to induce arterial instead of venous hyperemia, and to cause profuse local and often general perspiration. Active hyperemia is not suitable for the treatment of active or progressive joint disease. It exercises a dissolving and absorbing action on effused material and on the tissues of new formation, causing limitation of motion within a joint. It increases local nutrition and it relieves pain. It is especially indicated in the treatment of local disability after injury, chronic effusions into joints, chronic arthritis, and the like in which the circulation is deficient.

As a rule the application of local heat should be supplemented by massage. The profuse general perspiration that is induced by it is a contra-indication in weak individuals. At the present time it has been practically supplanted by radiant light and heat. (See Physiotherapy.)

CHAPTER VI.

NON-TUBERCULOUS DISEASES OF THE JOINTS.

SYPHILITIC DISEASES OF THE JOINTS.

In *early infancy* the characteristic manifestation of congenital syphilitic disease of the bones is a form of osteochondritis. Sensitive swellings appear about the epiphyseal junctions, either as small, hard tumors or as general enlargements, resembling those of rhachitis (Fig. 243). As a rule, several epiphyses are involved, more often those at the distal extremities of the bones of the lower limbs, and in these cases the pain and discomfort may induce an appearance of helplessness of the part called pseudoparalysis (Parrot).

FIG. 243.—Suppurative syphilitic epiphysitis at lower ends of radius and tibia in an infant aged one month. The child died shortly after the drawings were made and the epiphyses were found lying loose in purulent cavities. (Tubby.)

In syphilitic osteochondritis there is a multiplication and irregularity of the cartilage cells of the ossifying layer and premature calcification. Necrosis may result as shown by a zone of hard, dry yellow substance in the ossifying layer of the cartilage, about which newly formed bone is softened and in part replaced by granulation tissue. If the disease

is progressive, ulceration and suppuration may follow; the cartilage may be destroyed and the epiphysis may be separated, causing deformity and cessation of growth. The neighboring joint is usually involved in the disease. In the milder cases there is a simple sympathetic synovitis; in the advanced class a destructive arthritis. In one case seen recently in a child three months of age the symptoms of pain on motion combined with slight effusion into several joints were present without the epiphyseal enlargement. The affection may be distinguished from rhachitis by the accompanying evidences of inherited syphilis, by the irregularity of the epiphyseal enlargements, and by the age of the patient and the absence of the other symptoms of rhachitis. The roentgen-ray picture in characteristic cases shows at the diaphyseal extremities of the long bones, irregular and indented, in outline on the epiphyseal margin.[1]

FIG. 244.—Congenital syphilis.

In the *later manifestations of hereditary syphilis*, in which the bones in the neighborhood of the joint are involved in syphilitic osteoperiostitis, the joint may be sympathetically affected or the disease may actually perforate the joint. In this form of disease the synovial membrane is usually hypertrophied to such degree as to interfere with movement. The fluid is increased in quantity and the affection may resemble synovial tuberculosis. A slow, chronic, infiltrating gummatous form of disease appearing in later childhood may simulate very closely the appearance of so-called white swelling. It is more common at the knee, but other joints are often affected as well. In other instances one or more of the joints may be involved before the enlargement of the neighboring bone is apparent, the symptoms being those of chronic synovitis.

The diagnosis of hereditary syphilitic arthritis is usually suggested by the history and is confirmed by the Wassermann reaction and other evidences of the disease. According to Menzi of Turin[2] the symptoms in order of frequency in the cases under his observation were: splenomegaly, 43 per cent.; syphiloderma, 40 per cent.; mucosæ lesions, 29 per cent.; rhinitis, 20 per cent.; pseudoparalysis, 20 per cent. The most important of the later manifestations is interstitial keratitis. In a series of 77 cases in which this was present there was involvement of the joints in 56 per cent., the knee being most often affected.[3] Spina

[1] Fränkel: Archiv u. Atlas d. norm. u. path. Anatomy, 1911, vol. **26.**
[2] Twelfth Congress of Pediatrics, Naples, November 15, 1927.
[3] Hippel: München. med. Wchnschr., 1903, No. 31. [3] Chir. Krank. des Kindesalters.

MEDICAL LIBRARY BOSTON CITY

ventosa (Fig. 246), which is classed as one of the evidences of syphilis, is far more commonly of tuberculous origin, as is illustrated by the statistics of Karewski,[1] of 157 cases, in which but 3 were due to syphilis.

Acquired syphilitic arthritis usually appears in the later secondary stages of the disease, most often as a multiple subacute involvement of the larger joints, accompanied by sensitiveness of the adjoining bones. Occasionally the onset is acute and accompanied by fever, so that it may be mistaken for rheumatism. In the tertiary stage the joints may be involved, either primarily or secondarily from disease in a neighboring bone.[1] The disease is of a chronic character, characterized by gumma formation, thickening of the capsule, proliferation of the synovial membrane, and by secondary erosion of the cartilage.

Fig. 245.—Syphilitic osteoperiostitis of the tibiæ resembling anterior bow-leg. This is the most characteristic manifestation of hereditary syphilis. It induces not only deformity and hypertrophy, but elongation of the affected bone as well.

In some localities syphilitic arthritis is common, as among the negro laborers on the Isthmus of Panama. Here, according to Baetz,[2] of 100 cases of acute arthritis, 63 were caused by syphilis and 28 were gonorrheal.

[1] Bona: Berlin. klin. Wchnschr., 1907, Nos. 43 and 44.
[2] Jour. Am. Med. Assn., April 5, 1913.

On the other hand Clark, in a report on 1100 autopsies on negroes of the same class at Panama, found syphilitic disease of joints in 96. Two hundred and eighty-six of the subjects were less than twenty, yet in none of these was there evidence of syphilis, indicating that hereditary disease was comparatively uncommon.

FIG. 246.—Hereditary syphilitic disease of the metacarpus and phalanges.

FIG. 247.—Hereditary syphilitic disease of the joints. In this case the interior of the right knee-joint was lined with hypertrophied folds of synovial membrane. A complete cure followed the administration of appropriate remedies.

In a routine Wassermann test of 4736 ward patients in Johns Hopkins Hospital, the reaction was positive in 14.2 per cent. (22.9 per cent. of the colored and 7.6 per cent. of the white patients). In 6000 prisoners at Sing Sing, New York (4822 white, 1178 negroes),

the reaction was positive in 12 per cent. of the former and in 41.9 per cent. of the latter group.[1]

Syphilitic disease of the joints is comparatively rare in orthopaedic clinics as contrasted with that of tuberculous origin. This is as might be expected, since it is estimated that 50 per cent. of syphilitic infants are stillborn and that only 25 per cent. survive the first year,[2] and it is stated that of 250 persons subject to inherited syphilis only 9 lived to be sixty years old. (Sidler-Huguenin.[3]) Even among these, disease of the bones or joints, in the form that could be confounded with tuberculosis, is uncommon as compared with its other manifestations.

Disease of the bones is more common than of the joints because as contrasted with tuberculosis it usually affects the diaphyses. In 212 cases of hereditary syphilis over two years of age recorded by Fournier the bones were involved in 38 per cent. It is in further contrast of the formative rather than of the destructive type.

Treatment.—Certain writers consider hereditary syphilis to be a very important predisposing cause of tuberculous disease, and believe that many cases classed as tuberculous are in reality syphilitic, even if no history or confirmatory signs of syphilis are present. As evidence on this point the observations of Ménard may be cited. He found in 16 of 700 tuberculous cases under treatment positive signs of hereditary syphilis. The possibility of the syphilitic taint, remote or direct, should be borne in mind even if the Wassermann test is negative, and in all doubtful cases appropriate remedies should be employed.[4]

In general the treatment of the joint affection would be included in the treatment of the disease of which it is a complication. If the joint is involved in a destructive process, apparatus to ensure rest and protection is indicated. The removal of irritative disease in the neighborhood of a joint is sometimes possible in older subjects, and in this class of cases an exploratory incision for inspection of the joint is sometimes advisable (Fig. 247).

ARTHRITIS.

Gonococcal Arthritis.—Synonym.—Gonorrheal rheumatism.

So-called gonorrheal rheumatism is an inflammation of a joint caused by the presence of gonococci. It complicates from 2 to 5 per cent. of all the cases of gonorrhea, and in 75 per cent of the cases appears within fifteen days of the affection.[5] It is more common among those who are in a debilitated condition and in those who have had a previous attack.

It is stated by Klotz[6] that arthritis complicated but 2 per cent. of

[1] Jour. Am. Med. Assn., November 30, 1929.
[2] Rostenberg: Med. Rec., July 1, 1916.
[3] Schweiz. med. Wchnschr., January 20, 1921.
[4] Fisher: Jour. Am. Med. Assn., February 3, 1917.
[5] Collings, Jour. Am. Med. Assn., December 3, 1921.
[6] Berl. klin. Wchnschr., October 20, 1919.

the cases before the war, while at its end the percentage had risen to 10 per cent., owing to inefficient primary treatment and weakened physical condition.

Distribution.—In about 40 per cent. of the cases it is monarticular and the knee-joint is most often involved. In 375 cases collected by Finger the distribution was as follows:[1]

Knee	136	Shoulder	24
Ankle	59	Hip	18
Wrist	43	Jaw	14
Finger-joints	35	Other articulations	21
Elbow	25		375

Bennecke[2] has tabulated 78 cases; in 56 of the cases 18 were males and 38 females. The distribution was as follows:

Knee	31	Shoulder	4
Hip	8	Elbow	10
Ankle	9	Wrist	6
Other joints of foot	6	Fingers	4
			78

In 46 cases recorded by Markheim[3] one joint was involved in 13 cases, two joints in 12, three joints or more in 18. The order of frequency was knee, hip, shoulder, wrist, and elbow.

Symptoms.—The affection is usually of a subacute character. The joint becomes swollen and there is discomfort, and particularly weakness and stiffness on use. If the infection is more severe there may be local heat, pain, and infiltration of the tissues, with accompanying muscular spasm.

In all the forms, the infiltration of the subsynovial tissues of the capsule and of the superficial tissues is more marked than the actual effusion within the joint, and it may be inferred that in many instances the bone is itself involved, although not to the extent to be classified as osteomyelitis. The more serious cases are characterized by a peculiar edematous swelling of the deeper tissues, the skin being hot, sensitive, and glazed. There is usually intense pain on motion of the limb or on jar. After the subsidence of the acute symptoms the thickening persists and practical anchylosis may result.

Gonorrheal arthritis may be divided into three classes, according to its symptoms and physical characteristics: the serous, the serofibrinous, the purulent.

The *serous form* is, as its name implies, a simple effusion resembling other forms of subacute synovitis, although it is of a more chronic character.

The *serofibrinous variety* is the so-called plastic type of inflammation. In this form fibrin is deposited upon the cartilage and it is afterward organized by the growth of vessels into it from the synovial membrane,

[1] Taylor: Venereal Diseases, 263.

[2] Die Gon. Gelenkentzündung nach beob., der Chir. univ. Klin. in der K. Charite zu Berlin. Hirschwald, Berlin, 1899.

[3] Deutsch. Archiv. f. klin. Med., 1902, **72**, 186.

a process which erodes the cartilage upon which the granulations rest. The folds of the synovial membrane adhere to one another, the capsule is thickened, and ligaments and tendons may be involved in the adhesive inflammation. These changes within and without the joint may seriously impair its function after the cure of the active disease.

The *purulent form* is uncommon; it is similar in its characteristics to suppurative arthritis from other cases. It is attended by great local heat, pain, and swelling, and by constitutional disturbance.

In orthopaedic clinics gonorrheal arthritis is usually seen in its later stages when the acute symptoms have subsided. In these cases swelling and pain persist in many instances, and in the more severe types motion is limited or the limb may be fixed in an attitude of deformity. An obstinate, monarticular painful swelling of a joint suggests gonorrhea, and its presence or absence should always be determined, since the effective treatment of the primary cause is essential to the cure of the secondary affection of the joint. The same statement is true of painful, persistent affections of bursæ and tendon sheaths, and of obstinate forms of weak foot in which sensitive heels and stiffened toe-joints are present.

Treatment.—The first indication is efficient treatment of the urethral disease and its complications by such local and systemic remedies as may be indicated. Fuller, of New York, has reported several cases in which cure of persistent disease of joints and tendon sheaths followed direct treatment of gonorrheal disease in or about the seminal vesicles. The local treatment of the early stage of this form of arthritis is rest by splinting or by traction, together with hot or cold applications, as may seem to be indicated. Ichthyol ointment in a proportion of about 40 per cent. appears to relieve the pain and to stimulate the absorption of the effusion. If the symptoms are acute and if there is constitutional disturbance, or if the tension of the effused fluid causes discomfort, the joint should be aspirated, and if the examination shows the effusion to be seropurulent, it should be incised, irrigated with hot salt or mild antiseptic solution and closed. In the chronic form, also, when the capsule is distended by the serofibrinous effusion, incision and removal of the contents is indicated.

In the latter stages of disease of the ordinary subacute type the treatment is directed to the absorption of the effused material within and without the joint and to the restoration of functional activity. The use of hot air, massage, passive congestion, the hot and cold douche, static electricity and the like are of service in stimulating the circulation. If the limb has become deformed, and if it is fixed by adhesions and by contractions, the deformity may be corrected by forcible manipulation under anesthesia. And it may be stated that in this class of cases restoration of function to a greater or less degree is often accomplished by this means.

If, however, the limb is fixed in the proper position it is well to postpone forcible measures until the effect of the massage and gentle passive movements has been observed.

Functional use is the most effective restorative treatment after the acute symptoms have subsided. This is made possible by the employment of apparatus which limits motion to the degree the joint permits without causing discomfort.

Gonococcal Arthritis in Infancy.—This complication in infancy is usually a multiple arthritis of a pyemic character. In a series of 78 cases of gonorrheal infection treated at the Babies' Hospital[1] there were 10 cases of arthritis: 6 died directly from the disease, 2 died later from exhaustion, and in the 2 remaining recovery seemed improbable.

Puerperal Arthritis.—This is so similar in its characteristics to gonorrheal arthritis in adults that a detailed description is unnecessary. It may be stated, however, that puerperal arthritis is usually of a more severe type than the preceding affection.

Arthritis Complicating Infectious Diseases.—The joints may be involved in the course of any infectious disease. A mild form of arthritis, often involving several joints, may be a sequel of infectious disease, notably *scarlatina*. Brade[2] has reported 60 cases of joint involvement in 868 cases of scarlatina treated in St. Jacob's Hospital; 56 were of the serous type; 4 were of the suppurative form, causing the death of the patients. In but 8 of the cases was the arthritis limited to a single joint.

Arthritis may complicate pneumonia in about 1 per cent. of the cases, appearing usually about the eleventh day;[3] or cerebrospinal meningitis, as in 10 of 63 cases reported by Sainton and Mailee.[4]

Arthritis following *typhoid fever* is often of a severe and destructive type. Keen[5] has tabulated 84 cases. In 43 per cent. of these the hip-joint was affected and in 40 per cent. spontaneous dislocation occurred. In a case treated at the Hospital for Ruptured and Crippled there had been a destructive arthritis of one hip-joint, spontaneous displacement of the femur on the other side, and secondary contractions at the knees and ankles, so that the patient was bed-ridden. (See Typhoid Spine.)

Prognosis.—It is evident that the immediate reaction to bacterial infection and the final results will vary with the virulence of the infection, the natural resistance of the individual and of the part involved.[6] The bacteria reach the synovial membrane through the capillaries of the areolar tissue, beneath the endothelium, which if uninjured serves as a barrier to protect the joint cavity. If the joint is not actually involved the restriction to motion will depend upon thickening of the tissues of the joint and upon disuse of the muscles. In such cases the prognosis is good. If, however, the interior of the joint is invaded by a process that causes adhesions, and partial destruction of the cartilaginous surfaces, anchylosis is likely to follow.

[1] Kimball: Med. Rec., November 14, 1903.
[2] Leipzig, 1903.
[3] Howard: Johns Hopkins Hosp. Bull., 1910.
[4] Bull. de l'Acad. de Méd., lxxiii, No. 14.
[5] Surg. Complications and Sequels to Typhoid Fever.
[6] Poynton and Paine: British Med. Jour., November 1, 1902.

Treatment.—The treatment of all forms of arthritis complicating diseases of this class is to place the affected joint at rest, to apply heat or cold as may be indicated by the local condition, to aspirate the fluid whenever it is sufficient to cause discomfort, and to prevent the secondary distortions that lead to fixed deformities. The presence of pus is, of course, an indication for immediate incision, thus, the character of the effusion should be ascertained by aspiration, and in doubtful cases the injection of about 6 cc. of 5 per cent. solution of tincture of iodine in alcohol is recommended by Dreyer[1] as a preventive measure. As a rule, however, the joint should be opened and thoroughly washed out with warm bichloride of mercury solution of 1 to 10,000 or 15,000 and afterward closed.

The Willems[2] Method of Draining Purulent Synovitis of the Knee-joint by Active Movements.—The joint is freely exposed by bilateral incisions extending from the upper to the lower limits of the joint and the patient is forced to make methodical, frequent movements, if possible to the limit of flexion and extension, and thus by muscular contraction to force the contents of the joint out through the lateral openings. Voluntary movement which squeezes the contents of the joint out by direct pressure on the synovial surfaces must not be confounded with passive movements which simply transfer the fluid from one space to another and are more painful because they are not under the control of the patient. Steele[3] has found the method practicable even in childhood. It is, of course, evident that this method is not practicable in the treatment or in cases secondary to disease of the bones.

Spontaneous dislocation, which is comparatively common when the hip-joint is suddenly distended with fluid, is not likely to occur unless the limb is flexed and adducted. This attitude should be prevented by the use of traction or support.

The after-treatment has been indicated already.

Acute Arthritis of Infancy.—A form of acute suppurative arthritis primarily within the joint or more often secondary to disease of the neighboring epiphysis is not uncommon in infancy.

Etiology.—The disease is usually caused by staphylococci, occasionally by other forms of infection. (See Gonococcal Arthritis.) In the early weeks of life it may follow infection at the umbilicus or other surface lesion. It may be secondary to one of the exanthemata or to gonorrhea, but in many instances the origin is not apparent.

Falls or blows upon the part appear to be predisposing causes.

Townsend[4] tabulated 73 cases of acute arthritis in infancy, 18 of which were personal observations. To these I am able to add 12 others, making a total of 85 cases. In 64 of these the infection was

[1] Beitr. z. klin. Chir., August 11, 1911.
[2] Bull. et mém. Soc. de chir. de Paris, 1923, No. 49.
[3] Am. Jour. Surg., June, 1929.
[4] Am. Jour. Med. Sci., January, 1890.

monarticular; in 21 more than one joint was involved. The distribution was as follows:

Hip-joint	45 = 53	per cent.
Knee-joint	32 = 37	"
Other joints	8 = 10	"

Sex.—The sex was specified in 61 cases: males, 38; females, 23. It is of interest to note that in all reported cases the males outnumber the females. In 285 cases, including the above and others reported by Gonser, Demme, Lücke, Billroth, Schede, and Müller, the proportion was nearly 3 to 1.[1]

Symptoms.—If the infection is severe there is immediate local heat, redness, swelling and edema, great pain, and corresponding constitutional disturbance. But in many instances the local and general symptoms are less marked, the child is fretful, and the evident discomfort caused by motion at the affected joint is mistaken for the result of injury or rheumatism. In this class of cases the patient is not, as a rule, seen until several weeks after the onset of the affection. The joint is then somewhat infiltrated and enlarged, motion is painful and restricted, and the general appearances are very similar to tuberculous disease. There are also, without doubt, even milder forms of synovial infection from which recovery is rapid and practically complete. These cases are usually classed as monarticular rheumatism. Similar symptoms may be induced directly by injury; motion causes pain; the limb is flexed and persistent deformity may result unless protection is assured.

Prognosis.—If the disease is confined to the joint complete recovery may follow evacuation of the pus, but, as a rule, the neighboring bone is involved either primarily or secondarily, suppuration is prolonged, and a part of the epiphysis is destroyed before the disease comes to an end; thus, subluxation or other displacement with subsequent deformity and loss of growth are the usual results of this form of disease. At the hip-joint, for example, the laxity of the ligaments and the upward displacement of the femur that follow destruction of the head of the bone cause symptoms that in later life are often mistaken for those of congenital dislocation.

In some instances the shafts of one or more of the bones may be involved. These cases are often fatal, or, if the patient survives, there is usually necrosis of the affected bones and consequently extreme deformity.

In the cases reported by Townsend the death-rate was, in monarticular form, 18 per cent.; in the multiple form, 73 per cent.

In a total of 122 cases of all varieties tabulated by Hoffmann, the death-rate was 46 per cent. In 87 the affection was confined to one joint; in the remainder from two to five joints were involved.[2]

[1] Gonser: Jahrb. f. Kinderh., July, 1902.
[2] Med. Bull., Washington University, September, 1902.

BOSTON CITY

Treatment.—The treatment of suppurative arthritis is free incision and efficient drainage.[1] In all cases the joint must be fixed, preferably by a light wire splint, during the active stage of the disease. An apparatus is usually required to prevent deformity or to support the weak limb when the patient begins to walk. In the majority of cases in which the operative treatment has been prompt and effective useful motion is retained.

Suppurative arthritis in older subjects may follow penetrating wounds of the joint; but the infection is usually through the blood stream. Staphylococcal infections, which are the most common, originate usually in skin lesions; streptococcal from diseases of the nose and ear. In this class of cases injury seems to have an important influence in determining the situation.

Acute Tuberculous Arthritis.—In early infancy forms of acute tuberculous disease, especially at the knee-joint, may simulate closely infectious arthritis. The joint may become swollen, hot, and sensitive to pressure, and the onset may be sudden and accompanied by constitutional disturbance. Such cases are more often observed in the children of mothers suffering from advanced disease of the lungs.

ACUTE OSTEOMYELITIS.

The bone marrow is a part of the lymphatic system and all the changes characteristic of osteomyelitis are secondary to the primary disease of this tissue. Osteomyelitis is essentially a disease of childhood and adolescence. The extremities of the bones in the neighborhood of the epiphyseal cartilages on the diaphyseal side are most often involved. Trendel, from the histories of 1058 cases treated in Bruns's[2] clinic, states that it is most common in the period from the thirteenth to the seventeenth year. In one-half of the cases the femur was involved and in one-third the tibia. In some instances the source of the infection seems apparent in the exanthemata, pneumonia or other systemic disease, or in tonsillitis, furuncles, local infections and the like. In others no such cause can be assigned. In possibly 25 per cent. of the cases injury has apparently determined the site of the disease.[3] The organisms are carried to the site of election by the nutrient artery of the shaft or by the perforating periosteal arteries of the metaphysis.

The epiphysis is rarely involved primarily and the same is true of the joint. The most common types of organism are the staphylococcus and some strains of streptococci. In an analysis of 400 cases the infecting organism in 80 per cent. of the cases was staphylococci, in

[1] Mayo-Robson (British Med. Jour., October 6, 1917) has called attention to the importance of posture as an aid in draining the knee-joint. That the limb should be held vertical to the body, or that the patient should be placed in the prone posture, so that the fluid may be directed toward the suprapatella pouch where the drainage tubes are inserted.

[2] Beitr. z. klin. Chir., vol. 41, 3.

[3] Homans: Ann. Surg., March, 1912.

14 per cent. pneumococci and in but 6 per cent. streptococci.[1] The blood may serve as a nutrient media for the streptococci and the more severe and generalized forms of osteomyelitis are from this source.

The symptoms are usually chill, fever, high blood count, local pain and sensitiveness to pressure in the neighborhood of a joint which is soon distended by a sympathetic synovitis. The cancellous tissue of the extremity of the diaphysis is the seat of election.[2] The order of frequency is the upper extremity of the tibia, the lower extremity of the femur, the lower end of the humerus and the lower end of the radius. A point of extreme sensitiveness on the postero-lateral aspect may indicate the diseased area. At this point the tissues should be freely

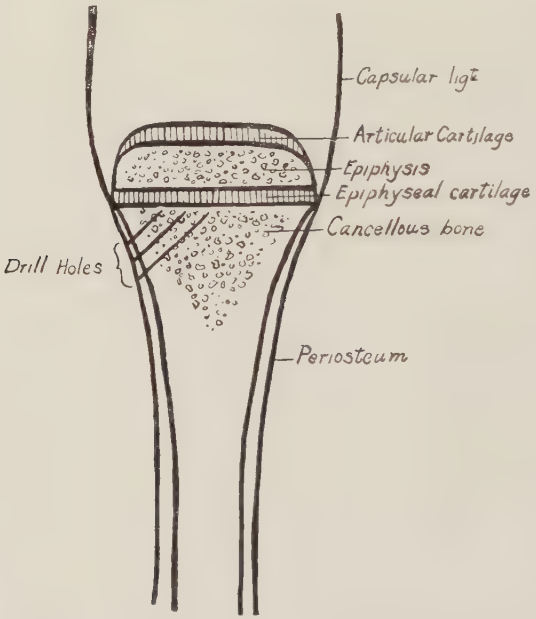

FIG. 248.—Drill holes from cortex to epiphyseal line for osteomyelitis of the tibia. (Starr.)

incised and often pus will be found, even at an early stage, beneath the periosteum. The cortex should be perforated by drill openings ½ an inch apart until red, normal marrow is reached (Fig. 248). Fixation of the limb and efficient drainage are essential. Extensive removal of bone is contraindicated, unless the pus contains globules of free fat indicating involvement of the bone-marrow. In certain instances the joint itself may be directly involved in the disease. This may be inferred if the symptoms do not subside after the bone has been opened. In doubtful cases the joint should be aspirated for the purpose of bacteriological examination, but even if pathogenic bacteria

[1] Fraser: Brit. Med. Jour., 1926, p. 605.
[2] Starr: Arch. Surg., May, 1924.

are present the treatment by incision or otherwise must be decided on the clinical symptoms; for the investigations of Fankel[1] show that specific microörganisms are present in the red marrow of the vertebræ, in the ribs and elsewhere in every form of infectious disease, and that they may be found here even when they are absent in the blood. In the blood, according to Bertelsmann,[2] they may be found in about one-

FIG. 249.—Deformities resulting from infectious osteomyelitis representing multiple involvement. In cases of this type there may be several primary foci of infection, but in most instances the process is consecutive from which it may be inferred that the bacteria are set free at intervals from the site of primary infection.

third of all cases of surgical infection and far more often when bones or joints are involved. In a series of 48 positive results, streptococci were found in 68 per cent., staphylococci in 30 per cent. If the joint contains pus it should be freely opened and an attempt may be

[1] Mitt. a. d. grenzgebieten d. Med. u. Chir., vol. 12.
[2] Deutsch. Ztschr. f. Chir., vol. 72, 209.

made to drain the joint by the Willems method. In cases of secondary, as distinct from primary, suppurative arthritis, this treatment is often impracticable, because of the extreme pain caused by movement.

The prognosis is primarily dependent upon the quality of the primary treatment. In neglected cases it is bad; for example, in 54 cases of acute osteomyelitis of the upper extremity of the femur, in all but 7 of which the joint was involved, the death-rate was 60 per cent.[1]

Fig. 250.—Tuberculous osteomyelitis localized in the lower extremities of the radius and ulna, demonstrated by the *x*-rays and removed before the wrist-joint was involved.

Localized chronic osteomyelitis in the neighborhood of a joint may simulate tuberculous disease of the joint. The onset of the affection is, however, more abrupt, the surrounding tissues are infiltrated, and the symptoms are usually more acute than in the latter affection. In this class of cases of the subacute type the lesions are often multiple, fresh foci appearing at intervals for an indefinite time. The treatment of choice when the affection is localized is the operative removal of the diseased area, which is indicated by local sensitiveness, and which in many instances may be demonstrated by the roentgen examination. One should be as sparing of the bone as possible because of the danger of retardation or irregularity of growth that almost always follows the loss of even a moderate amount of growing tissue.[2]

The Orr Treatment for Osteomyelitis and Similar Conditions.[3]—The Orr treatment exemplifies the well-established importance of rest for

[1] Gyot: Rev. des Chir. xxiv. Nos 2 and 4.
[2] Surg., Gynec. and Obst., October, 1927.
[3] Klemm: Berlin, 1914.

natural cure as contrasted with frequent dressings in the attempt to establish surgical cleanliness. The procedure is described by Orr as follows:

"1. Make a fairly large incision over the infected bone area. Spread apart the skin, muscles, fasciæ and periosteum just far enough to afford access to the diseased area and no father.

"2. Chisel a window into the affected bone area large enough so that all diseased bone may be removed and so that there are no overhanging edges of bone over the diseased area. (Less extensive in acute cases.)

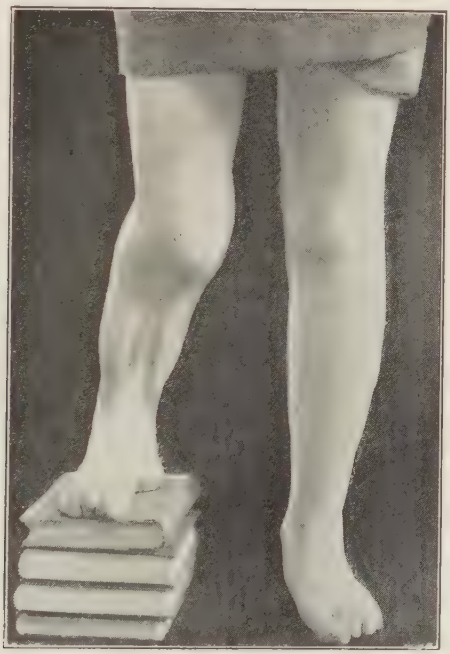

FIG. 251.—Loss of growth following osteomyelitis of the tibia and removal of part of the shaft.

"3. Clean out the diseased area gently with a curette or gouge, being careful to refrain from unnecessarily damaging the tissues undergoing repair.

"4. Dry the wound and wipe out with 10 per cent. iodine followed by 95 per cent. alcohol.

"5. Pack the entire wound wide open but not tightly with a sterile petrolatum gauze pack. Cover this with a dry sterile pad and bandage on.

"6. Now perform any reasonable forcible manipulation necessary to place the parts in correct anatomical position for splinting (abduct the arm to 90 degrees in humerus cases; dorsiflex and supinate the hand in

forearm and wrist cases; dorsiflex the foot to a right angle with the leg, in leg and foot cases, etc.).

"7. Apply a plaster support (preferably) or a suitable splint so that the parts are thoroughly immobilized in comfortable and correct position (additional weight and pully traction, Balkan frame, or even ice tongs or bone pins may be used in these infected bone lesions associated with fractures and old fracture deformities which are being corrected at the same time as the clean-up operation). It may be said that it is in the latter cases that some of the most gratifying results may be obtained by this method.

"8. Finally, the splint is not to be split nor are windows to be cut in it until the wound dressing becomes necessary. And the wound is not to be dressed at all unless there is a rise of temperature or other signs of acute sepsis. As a rule, no dressing is necessary except on account of odor, and this may not be required for several weeks. In the majority of cases the patient treated by this method will go through to complete healing with a few dressings at intervals of from ten days to four weeks.

"The odor is often offensive but if the patient is comfortable and if there is no rise in temperature this is not considered an indication for a change in the dressing."

Chronic Sclerosing Osteitis.—This is indicated by a spindle-shaped enlargement of the bone, usually the tibia, accompanied by pain, often worse at night, and sensitiveness to pressure. The majority of the patients are young adult males. The original cause is apparently some form of latent infection. The exciting cause is often injury. There is no pus formation, but a thickening and increased density of the cortex. The most effective treatment is a removal of the hypertrophied area.[1]

Brodie's Abscess.—This is a small localized abscess of a bone, usually of the tibia caused apparently by a latent infection which has become active. The symptoms are localized pain and later an enlargement of the bone. The roentgen-ray examination usually establishes the diagnosis. Evacuation of the abscess relieves the symptoms.

Hemorrhagic Osteomyelitis.—Barrie[2] has on several occasions called attention to injury as a common cause of local osteomyelitis and cyst formation. The injury is followed by a low grade of inflammation with the formation of granulation tissue which in its further transformation forms a cyst. The symptoms are slight local sensitiveness and pain, discomfort, and at times, if in a lower extremity, limp. In some instances the bone enlarges, its structure is weakened, and spontaneous fracture results (Fig. 252). (See Osteitis Fibrosa.)

If the diagnosis of hemorrhagic osteomyelitis is established and if there is no tendency to recovery under roentgen-ray treatment, the bone should be opened and the affected tissue removed, the interior thoroughly scraped and treated with iodine or carbolic acid. If the

[1] Henderson: Jour. Am. Med. Assn., March 22, 1924.
[2] Annals of Surgery, March, 1918.

cavity is a large one, and near a joint, the insertion of chips or stays from the unaffected bone may be advisable to prevent collapse and to stimulate repair.

FIG. 252.—Hemorrhagic osteomyelitis. Cyst and fracture.

ARTHRITIS DEFORMANS. OSTEOARTHRITIS AND RHEUMATOID ARTHRITIS. RHEUMATIC GOUT. DEGENERATIVE AND PROLIFERATIVE ARTHRITIS.

Under these titles are included a large group of chronic diseases of the joints whose etiology is obscure. At the present time as these diseases are often improperly classed as varying manifestations of one pathological process, the titles are often considered as synonymous.

Clinically, however, the characteristic types differ markedly from one another. In one form bone destruction is combined with bone formation, and the final result is an irregular solid enlargement of the joint, usually combined with distortion of the limb.

The term hypertrophic or degenerative arthritis may be applied to this type.

The second form resembles chronic rheumatism in its course and distribution. The joints are enlarged but the disease is essentially of the soft parts; the articulating surfaces are only secondarily and superficially involved. There is no new formation of bone or cartilage but eventually a local atrophy of the joint and of the tissues of the limb corresponding to the loss of function.

The final result is deformity and limited motion or anchylosis without bony enlargement of the joint. This form has been classed from the clinical stand-point as atrophic to distinguish it from the former or hypertrophic form of arthritis deformans when the term was used to include both varieties.

Degenerative (Hypertrophic) Arthritis.—Pathology.—This is one of the most ancient diseases, of which evidence is found in prehistoric

FIG. 253.—Degenerative arthritis. The hypertrophy of the extremities of the bones of the terminal phalanges (Heberden's nodes) is accompanied by erosion of the cartilage. The second interphalangeal joint of the second finger shows hypertrophy combined with destruction and lateral displacement. (See Fig. 254.)

remains not only of man but of animals. The characteristic type is that seen in elderly subjects, sometimes limited to a single joint—malum coxæ senile, for example. The primary effects of the disease are most noticeable in the cartilage, which becomes necrosed or fibrillated and finally worn away in the parts subjected to greatest pressure, while it is thickened and heaped up into irregular layers at the periphery, as if under the influence of pressure it had been squeezed out from the interior of the joint (Fig. 255). When the cartilage disappears,

BOSTON CITY

the bone, deprived of its natural protection, is worn away, and under the influence of pressure and friction it becomes increased in density and hardness—"eburnated"[4]—while softening and degeneration in other parts occur. Meanwhile, the irregular projections of cartilage at the periphery become in part ossified, and this, together with a formative periostitis of the adjoining bone, causes the irregular bony enlargement combined with destruction of the bearing surfaces

Fig. 254.—Atrophic arthritis. Slight superficial erosions of the bones are to be seen at several of the joints. Contrast with Fig. 253.

of the bones characteristic of the disease. The contour of the bones and their mutual relation to one another in the joint are changed. The synovial membrane becomes hypertrophied and its villi, some of which may contain cartilaginous nodules, project into the joint in shaggy fringes. These may be detached from time to time and may form loose bodies within the capsule. The synovial fluid may be greatly increased in quantity, distending the capsule, or, communicating with bursæ, it may form cysts, as is sometimes observed at the knee-

joint. But more commonly the fluid is decreased in amount. The ligaments are weakened and the tendons about the joint become adherent to their sheaths and to the neighboring tissues. The muscles atrophy and become structurally shortened or otherwise changed in accommodation to the deformity. Motion is limited by the changes in and about the joint, but anchylosis is unusual.

Although the most noticeable of the early changes appear in the cartilage, it is probable that the nutrition of the underlying bone is lowered in the beginning and that the joint is involved as a whole rather than that the disease is primarily of the cartilage.

FIG. 255.—Hypertrophic arthritis, from the Museum of the College of Physicians and Surgeons, New York.

Etiology.—Little that is positive is known of the etiology. Several factors are sufficiently evident. These are age, injury or overstrain, overweight and improper functional use. The wearing out of the joint is suggested by the appearances, and, as is well known, similar changes in slight degree are not uncommonly found in the joints of laborers of middle age. According to Beitzke's investigations of the bodies of 200 laborers, the joints of those between the ages of 20 and 40 showed changes characteristic of limited degenerative arthritis in 5 per cent., over 40, 60 per cent., over 50, 100 per cent.[1] So, also, similar changes may follow abnormal function, as in hallux valgus, or may be induced

[1] Ztschr. f. klin. Med., vol. **24**, No. 3.

by injury, particularly fractures and luxations caused it would appear by interference with nutrition. Similar changes may follow the so-called incongruities of an articulation as at the hip after the reduction of congenital dislocation, the Legg-Perthes disease and the like. In elderly and overweighted subjects the symptoms may be induced by slight disturbance of the normal relation of the bones; in the knee, for example, as a sequel of weak foot. Lessened nutrition and consequently lessened local and general resistance are also predisposing causes. In locomotor ataxia, a disease accompanied by loss of sensation and by diminished control of movement, the nutrition of the joint is lowered and its natural safeguards against injury and overwork are removed and Charcot's disease may result. It would appear, finally, that defective assimilation (metabolism) is a predisposing factor in both man and animals. The exciting cause being, presumably, in the multiple type of arthritis at least, some form of local infection.

FIG. 256.—Atrophic arthritis in a child, showing the characteristic deformity. Nearly every joint in the body was involved.

Symptoms.—In its typical form hypertrophic arthritis is an affection of middle life and of old age. It may be confined to a single joint, and in these cases one of the larger joints of the lower extremity is more often affected, particularly the hip or knee. As a rule, however, several joints are involved to a greater or less degree. Its onset is usually insidious, and the progress is slow, accompanied by remission of the symptoms.

These symptoms are usually pain, discomfort in changing from one position to another, "creaking" sensations in the affected joints, gradually increasing local enlargement and sensitiveness, limitation of motion, and distortion of the limb. Typical examples are found in the hip-joint (malum coxæ senilis) and knee, and these are described elsewhere.

Although the disease may be confined to one or more of the larger articulations, it is often accompanied by enlargement of the joints of the fingers. It should be stated, also, that there is a form of hypertrophic arthritis of comparatively slight importance in which the disease is confined to the joints of the fingers. It is more common in women than in men, often appearing at the time of the menopause. The bases of one or all of the distal phalanges become enlarged (Heberden's nodosities), and the joints stiffened and sensitive, the pathology being similar to that already described. Gradually other phalangeal joints are involved until the fingers become deformed and function is somewhat interfered with. The disease is slowly progressive, pain lessening as the enlargement and stiffness become more apparent. When the disease begins in this manner the larger joints are not often implicated, at least to a disabling degree (Fig. 253.)



FIG. 257.—Still's form of polyarthritis, showing the general atrophy, the enlarged joints, and the prominence of the abdomen, due to amyloid degeneration of the liver and spleen.

Treatment.—In general this should be directed to the removal of possible sources of infection from the teeth, tonsils or elsewhere, to the improvement of the condition of the patient, particularly to the condition of the gastro-intestinal tract which often influences the symptoms to a marked degree. The daily routine should conform to what the personal experience of the patient shows to be that best adapted to the disability. The local nutrition may be maintained by massage, electricity, graduated active and passive movements and the like. Deformity may be prevented and pain may be relieved by regulating the strain to which the weak part is subjected, if practicable, by the use of apparatus. In certain instances operative removal of villous proliferations of the synovial membrane or of solid projections that interfere with movement or arthroplasty may be of service. (See Spondylitis Deformans and Osteoarthritis of the Hip and Knee.)

Proliferating (Atrophic) Arthritis.—This form of chronic multiple arthritis differs from the preceding type in that it is rather an affection of childhood and of early adult life than of old age. It is more common in females than males. It is more acute in its onset, more rapidly progressive, and more general in its distribution.

In hypertrophic arthritis the cartilage is worn away at the center of the joint, heaped up at the periphery, and the underlying bone is

involved. In typical atrophic arthritis the affection is primarily of the fibrous coverings and of the membranes of the joint, and the cartilage is destroyed in the later stages by a pannus-like growth from the periphery. There is secondary erosion of the cartilage and of the underlying bone unaccompanied by the hypertrophy characteristic of the preceding disease. A spindle-shaped enlargement of the finger-joints is characteristic, due to the thickening of the soft parts, but the roentgen-ray picture will not show irregular bone formation but a normal contour or at most superficial erosions of the bones entering into the formation of the joint. The second interphalangeal joints are usually involved primarily. There is usually flexion contraction, and in many instances general deviation of the fingers toward the ulnar side. In younger subjects, particularly in the class of cases in which the onset

FIG. 258.—The hands of the patient in Fig. 257, showing a skin lesion.

of the disease is acute, and in which there is considerable effusion, there may be subluxation or actual luxation of the phalanges, more often at the metacarpal articulations, combined with more or less destruction of the extremities of the bones. In such instances motion is preserved in the affected joints.

In typical cases the final result in any joint is either anchylosis or limited motion accompanied by flexion deformity. There is, of course, general atrophy of the muscles and of the bones corresponding in degree to the functional disability that is present.

The onset of atrophic arthritis may be acute, resembling rheumatism, many joints being involved simultaneously. It is often subacute and even limited primarily to a single joint, slowly extending its area.

The larger joints may be involved before those of the hands, where in contrast to the degenerative form the interphalangeal joints are

primarily affected, or *vice versa*. In childhood the disease often begins in one of the larger joints, causing stiffness, deformity, and pain on motion. There is usually some local heat and infiltration of the tissues about the joint, increasing and diminishing according to the character of the disease and to the strain or injury to which the joint may be subjected. In cases of this character the affection is usually mistaken or tuberculous disease until the involvement of other joints in dicates the true character of the affection. As a rule the affection is progressive in character, both locally and generally. The range of motion in the affected joint becomes more and more restricted, the limb becomes flexed, and, finally, there may be practical anchylosis, usually due to

FIG. 259.—Proliferating arthritis in a child affecting the joints and the spine, progressive in character, accompanied by enlargement of the lymphatic glands. The attitude of the head is characteristic of suboccipital disease. The case is one of the Still type.

adhesions and contractions within and without the joint. In those cases in which the cartilage is in part destroyed by the growth of granulation tissue from the periphery there may be actual bony union. In many instances the spine becomes rigid, including the occipito-axoid articulations, and practically every joint of the body may be finally involved, so that the patient is bed-ridden and helpless.

The disease is more serious and more rapidly progressive in the young than in older subjects. There are periods of remission and of exacerbation. In most instances the disease appears to come practically to an end after many years, leaving the patient in a permanently crippled condition but comparatively free from pain, and occasionally complete recovery takes place, but this is unusual.

A peculiar form of the affection, first described by Still,[1] occurs in childhood. This begins usually in one or more of the larger joints. As a rule it progresses rapidly, and it is accompanied by enlargement of the lymphatic glands, particularly those of the inguinal region and axilla, and of the liver and spleen. There is, as a rule, moderate effusion into the joints and thickening of the overlying tissues. As the muscular atrophy is extreme, the joints appear by contrast very much enlarged. The final outcome of the disease if the patient survives is anchylosis and deformity, as in the ordinary form. Occasionally complete recovery occurs.

Etiology.—This form of chronic arthritis is now generally classed with the infectious diseases of joints, not caused by a specific germ but by streptococci, staphylococci, or other germs or their mutations, so attentuated that they do not induce suppuration.[2] Forkner and Shands.[3] investigated the synovial fluid in 60 cases and found positive cultures in 22 per cent.

The Probable Source of Infection in the Sixty-three Cases was as Follows:

Probable source of infection.	No. of cases.	Per cent.
1. Throat without history of acute tonsillitis	23	38.0
2. Infected tonsils	14	23.7
3. Prostatitis	7	11.8
4. Infected sinuses	4	6.8
5. Abscessed teeth or pyorrhea	3	5.1
6. Urethritis	3	5.1
7. Gastro-intestinal tract	2	3.4
8. Uterine cervicitis	1	1.7
9. Pyelitis and cystitis	1	1.7
10. Infected toes	1	1.7

Contributing causes are apparently a lack of vital resistance inherited or acquired, it may be, by overwork or strain, mental or physical.

Treatment.—This must be directed primarily to the discovery and removal of the primary foci of infection, whether of the teeth, the tonsils, the genito-urinary organs, the gall-bladder or elsewhere. Especial attention should be paid to intestinal stasis and putrefaction, as a cause or aggravating factor of the disease, a condition most effectively treated by high irrigations. Free catharsis should be established and diet should be easily assimilated and nourishing. Exposure to cold and wet and overexertion or strain of the painful joints must be avoided. The use of static electricity, the hot-air and the electric-light baths or any similar form of stimulation may be of service in improving the nutrition.[4] If the joints are sensitive, motion should be restricted to the painless area. Passive motion or massage that increases the pain or discomfort is harmful, but motion should be encouraged, particularly functional activity ("occupational therapy") to the point of tolerance, when the disease is quiescent.[5] The

[1] Med.-Chir. Trans., 1897.
[2] Rosenau: Jour.-Lancet, January 1, 1914.
[3] Archiv of Int. Med., November, 1928.
[4] Nathan: Am. Jour. Med. Sci., June, 1909.
[5] Boorstein: New York Med. Jour., February 7, 1923.

deformities are so characteristic that they may be in some degree restrained by anticipatory splinting, particularly of the hands and fingers. Flexion deformity may be overcome by traction or by forcible manipulation, supplemented, if necessary, by division of resistant tis-

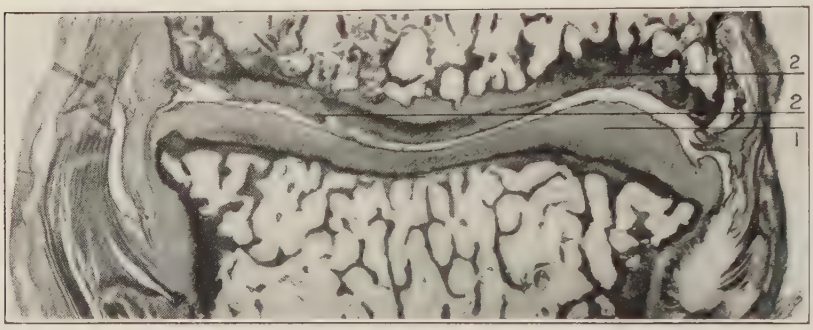

FIG. 260.—Degenerative arthritis; moderate degree. Photomicrograph of section through a phalangeal joint and adjacent phalanges shows that the line of the joint cavity is very irregular. Areas of hyperplasia of the cartilage (*1*), with, in other places, erosion of the cartilage down to eburnated bone of the opposing phalanx (*2*). In other cases the cartilage shows fibrillation (*3*). There is moderate thickening of the capsule. (Nichols and Richardson.[1])

sues when the disease is quiescent. It has even been suggested that forcible manipulation under anaesthesia may have a general as well as local remedial effect. Excision of an anchylosed joint, as of the lower jaw or elbow, may reëstablish painless motion.[2] Dr. Snyder who has

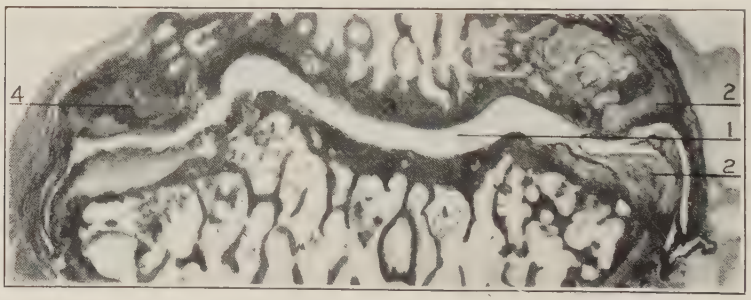

FIG. 261.—Degenerative arthritis; moderate degree. Photomicrograph of the phalangeal joint and adjacent phalanges. The line of the joint cavity is very irregular (*1*); the cartilage has been almost entirely destroyed and shows only at the margins of the joint (*2, 2*); the articular surface of the phalanges where the cartilage has been destroyed is eburnated (*3, 3*). There has been a new growth of bone at the periphery of the joint (beginning Heberden's node) (*4*). (Nichols and Richardson.)

charge of this department at the Hospital for Ruptured and Crippled, considers the examination of the blood for an excess of sugar or uric acid and regulation of metabolism by diet based on such examination as of

[1] Arthritis Deformans, Boston, 1910.
[2] Whitman: Med. Rec., April 18, 1903.

MEDICAL LIBRARY OF THE BOSTON CITY

almost equal importance to the removal of foci of infection. High colonic irrigations are employed as a routine. Active and passive movements of the joints and functional activity to the point of tolerance are

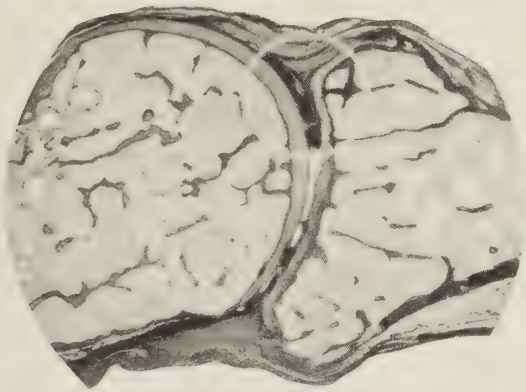

FIG. 262.—Proliferative arthritis; extreme type. Photomicrograph of section through phalangeal joint. The trabeculæ of the phalanges are less numerous than normal; the capsule is slightly thickened; the joint cavity is much reduced in size by extension inward of dense, fibrous tissue from the synovial membrane at the point indicated by the circle: this fibrous pannus is adherent to both joint cartilages, producing adhesion and loss of motion without destruction of the underlying cartilage. (Nichols and Richardson.)

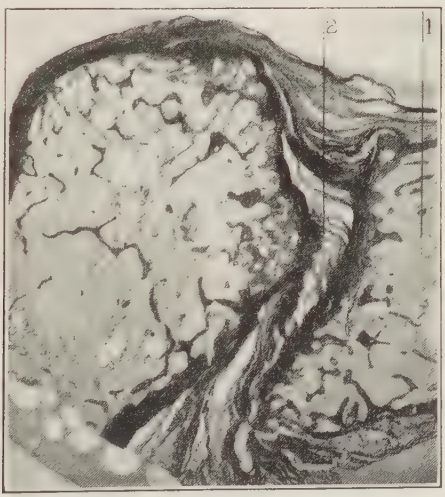

FIG. 263.—Proliferative arthritis; extreme type. Vertical section through phalangeal joint. Shows the distal phalanx (*1*); dislocated forward and downward into the palm of the hand; the joint cavity (*2*) is practically obliterated and replaced by loose, dense, fibrous adhesions. The joint cartilage has entirely disappeared; the trabeculæ of the phalanges are less numerous and smaller than in normal bone. (Nichols and Richardson.)

encouraged. The disease is looked upon as self-limited in the sense that eventually it ceases to be progressive and that the final result is determined in great degree by the prevention of deformity and by conserving natural resistance. Drugs have little influence upon the disease. The

most effective internal remedies are the thyroid and pituitary glands, which act by apparently stimulating metabolism. Autogenous vaccines are sometimes of benefit, explained apparently by the rise in temperature and hyperleukocytosis irrespective of the agent employed. On this theory, H. B. Thomas[1] has employed as a routine an injection of 50,000,000 typhoid vaccine intravenously, raising the amount at intervals of two or three days to 75,000,000. In most instances pain is relieved for a few days and permanent improvement is sometimes noted.

The treatment of infectious arthritis has been discussed. It may be that a primary infection of a single joint or of other tissues or organ may be the starting-point of multiple arthritis. In such cases operation with the aim of removing the focus of infection may be considered.

It may be noted as of interest that what appears to be typical atrophic arthritis in childhood may be induced apparently by infectious disease, such as diphtheria for example, and that improvement, or even disappearance, of the local symptoms may follow intercurrent attacks of scarlatina or measles.

Although, as has been indicated, proliferative and degenerative arthritis differ so essentially as to be classed as distinct diseases, yet there are types that it is difficult to classify as the one or the other, and in certain instances the two forms may be combined in one individual.[2]

FIG. 264.—Gout.

Gout.—Gout is comparatively of slight importance from the orthopaedic stand-point. It affects more particularly those of middle life

[1] Jour. Am. Med. Assn., September 8, 1917.
[2] G. R. Elliott: Med. Rec., September 23 and October 14, 1916.

and it is characterized by acute inflammatory attacks followed by deposits of urate of sodium on or about the articular surfaces of the affected joints. After repeated attacks the cartilage and the bone may be in part destroyed, and the joint may be enlarged by deposits in the periarticular tissues and by the inflammatory thickening of the neighboring joints. The joints most often involved are that of the great toe, the ankle, knee, and the joints of the fingers. If the feet are weakened or distorted as the effect of gout, a proper support to distribute the weight more generally on the sole is often of service. The operative removal of unsightly deposits about joints may be considered also. The general treatment of the patient is, of course, of first importance.

Fig. 265.—Gout.

Rheumatism. Certain forms of rheumatism, so-called, are of interest from the orthopaedic stand-point, notably those forms that affect the fibrous tissues and that lead to permanent changes in the joints—"plastic rheumatism." Undoubtedly monarticular arthritis is usually due to direct infection from without, as are certain forms of polyarthritis. Notably those that follow infectious diseases. A form of subacute arthritis is sometimes observed as a complication of tuberculous disease, "tuberculous rheumatism." There are other forms, for example arthritis deformans, gout and the like in which defective assimilation and lessened resistance are the important factors.

HEMOPHILIA.

Hemophilia is apparently a congenital weakness of the bloodvessels which is transmitted through females to males. In one family under observation since 1827, through four generations (207 members), there were 37 "bleeders," all males; 33 per cent. of the male descendants. Eighteen died from the effects of hemorrhage, nearly all in childhood.[1] In a family known to the writer all the males, 3 in number, died of

[1] Deutsch. Ztschr. f. Chir., vol. **76**.

hemorrhage, 2 having lived to adult age. It is assumed that the children of a man with hemophilia will remain free from the disease, that the daughters will transmit the defect to one-half of their sons and that one-half of the daughters will be carriers.

Hemorrhage into a joint in this class is not uncommon, the knee-joint being most often involved. As a rule it is the result of injury, and if the peculiarity of the patient is known the nature of the effusion is hardly doubtful, particularly as there are in many instances discolorations of the skin, either over the joint or elsewhere. The first bleeding is usually at from three to ten years of age. In some instances there is no history of traumatism, and the swelling may be accompanied by fever. This is probably the effect of the hemorrhage rather than its cause.[1]

The peculiar interest in the affection, aside from the importance of a proper diagnosis, lies in the fact that the further organization of the effused blood may cause symptoms and changes about the joint that may be mistaken for those of tuberculous disease. There may be, for example, persistent swelling, thickening of the tissues, limitation of motion, and deformity combined with more or less weakness and discomfort. These symptoms are explained by the irritation of the effused blood and by its further absorption and organization, which necessitates the formation and growth of new bloodvessels; practically, a granulation tissue is formed that erodes the cartilage upon which the fibrinous deposits rest. These secondary changes resemble the early stage of hypertrophic arthritis.

Treatment.—The local treatment is rest and protection combined with stimulating applications to hasten the absorption of the effused blood. Several deaths have been reported from hemorrhage after operative intervention in cases in which the affection had been mistaken for tuberculous disease.

HEMARTHROSIS.

Hemorrhage into a joint may occur in normal individuals, and its presence is not always indicated by superficial discoloration. The swelling is more resistant than is the ordinary effusion, and it is far more persistent. This suggests the advisability of incision and removal of the blood clots, in order to relieve the joint of burden of their organization and absorption.

SCORBUTUS—SCURVY.

This affection is sometimes attended with hemorrhage into and about the joints. It will be considered in connection with infantile rhachitis.

[1] Reinecke and Wohlwill: Archiv f. Klin. Chir., February 14, 1929.

TABETIC ARTHROPATHY—CHARCOT'S DISEASE.

Disease of the joints caused by tabes may occur in two forms, a simple chronic synovitis or as a destructive osteoarthritis. The latter is the characteristic form known as Charcot's disease.

FIG. 266.—Charcot's disease of the knee-joint showing the characteristic enlargement and outward bowing. A useful support for cases of this character is illustrated in Fig. 268.

Pathology.—It resembles somewhat in its pathology degenerative arthritis, although destruction as compared to formation is more marked. The cartilage degenerates, and, together with the underlying bone, is worn away by the movements of the limb. Accompanying the destructive process there is an exaggerated and irregular formation of cartilage and bone about the periphery of the joint. The synovial membrane is hypertrophied, and may be covered in places with calcareous plates; the contents of the joint are usually increased in quantity.

The joint disease often appears early in the course of locomotor ataxia, before its existence is suspected. It is sometimes caused directly by injury but the predisposing cause is the loss of protection due to the hypotonia of the muscles and to the attitude of hyperextension at the knees which is often habitual.

In 246 cases of arthropathy analyzed by Henderson[1] 54 of the patients were in the preataxic stage, 36 in the transitional, and in 156 the ataxia was well marked.

[1] Path. and Bact., 1905, vol. 10.

Charcot's disease is said to affect about 5 per cent. of the ataxic patients; it is more common in the lower extremity, and one or

Fig. 267.—Charcot's disease, illustrating the destruction and new formation of bone.

more joints may be involved. In the cases tabulated by Flatow the distribution was as follows:

Knee	60; in 13 cases both knees.
Foot	30; in 9 cases both feet.
Hip	38; in 9 cases both hips.
Shoulder	27; in 6 cases both shoulders.[1]

Chipault[2] notes the distribution in 217 cases as follows:

Knee	120
Hip	57
Foot	40

[1] Deutsch. Chir., 1900, **1**, 28.
[2] Le Dentu et Delbet: Traité de Chir.

Fifteen cases of Charcot's disease involving the spine have been reported.[1]

Symptoms.—The symptoms are the swelling due to the effusion, laxity of the ligaments, and deformity. There is practically no local pain or sensitiveness, and the patient's chief complaint is of the weakness and distortion of the limb. In certain cases the progress of the affection is very rapid, and the destruction of the bone may be so extensive that there is an actual luxation at the affected joint.

Diagnosis.—If the patient is known to have locomotor ataxia the diagnosis will be evident, and in any event the peculiar enlargement and thickening of the tissues, together with the excessive laxity of the ligaments, characteristic of this affection, which has been called a caricature of hypertrophic arthritis, should call attention to the disease of the spinal cord. Of this the diagnostic symptoms besides the ataxia are absence of tendon-jerks in the lower extremities, "lightning" pains in the limbs, disorders of sensation and lessened muscular tone, genito-urinary complications, and absence of reaction of the pupils to light.[2]

Treatment.—The treatment, aside from that of the disease of which it is a symptom, is efficient support to prevent progressive distortion. Excision of the knee has been performed, but in many cases the bones have failed to unite, and on this account the operation is contraindicated, except for the purpose of correcting great deformity, which prevents the application of an efficient brace. Spontaneous fracture is common in tabetic patients, both of the upper and lower extremities and degenerative changes in the fragments may prevent union. After fracture at the hip the reconstruction operation may be of service if the shaft of the femur is not deeply involved in the degenerative process. (See Chapter XXIV.)

Disease of joints *secondary to other forms of disease of the nervous system* may occur. It is most common as a complication of syringomyelia, affecting about 25 per cent. of all cases (Askgaard).[3] In contrast to locomotor ataxia, the joints of the upper extremity are far more often involved than of the lower (Borchard).[4] The symptoms of this affection are loss of sensation to pain and temperature, disturbance of nutrition and muscular atrophy. One must consider syringomyelia as a possible cause of destruction of bone, or laxity of ligaments in joints of the upper extremity, in cases sometimes mistaken for chronic arthritis.

[1] Abadie: Nouv. Icon. de la Salpêtrière, 1900, vol. **13**; Cornel: Johns Hopkins Hosp. Bull., October, 1902.

[2] According to Uhthoff the symptoms of tabes in order of frequency are as follows:

1.	Disturbances in sensibility (in the widest sense)	92 per cent.
2.	Lancinating pains	85 "
3.	Loss of patellar reflex	83 "
4.	Argyll-Robertson pupils	79 "
5.	Romberg phenomenon	71 "
6.	Ataxia	55 "

[3] Hospitalstidende, August 29, 1917.

[4] Deutsch. Ztschr. f. Chir., 1904, vol. **72**.

In Schlesinger's cases the distribution was as follows:[1]

Shoulder	29
Elbow	24
Wrist	18
Hip	4
Knee	7
Foot	7
Other joints	8
	97

Bone formation in the tissues, most often about the knee resulting in fixation, is an occasional sequel of transverse myelitis.

In all forms of joint disease secondary to affections of the nervous system the influence of injury on the ill-nourished or ill-protected part is recognized in the causation and in the progress of the disease. This indicates the principles of local treatment.

ANCHYLOSIS.

Anchylosis implies fixation in an attitude of deformity, and the term should be restricted to practical fixation caused by tissue changes within or without a joint. It is, however, often incorrectly applied to limitation of motion, such as may be caused, for example, by muscular spasm or contraction.

Etiology and Pathology.—Anchylosis is usually secondary to an infective process in or about the joint during which adhesions have formed within and without the capsule. If deformity has been allowed to persist the muscles on the contracted side are structurally shortened. If the cartilage has been destroyed, bony union often results. This is sometimes called true, as distinguished from false or fibrous, anchylosis.

The latter form, which is far more common in youthful patients, may be caused by adhesions between the folds of synovial membrane, by adhesions and contractions of the capsular and other ligaments, by adhesions between the tendons and their sheaths, by the general adhesions and contractions caused by burrowing abscesses, and by structural shortening of the muscles when the deformity has persisted for a sufficient time. It may be caused, also, by fractures or dislocations or by marginal exostoses.

Prevention and Treatment.—The danger of anchylosis may be lessened by the proper treatment of the disease of which it is a result. Even in tuberculous disease, for example, motion may be preserved in many instances by efficient protection, by which the area of the disease is restricted and its destructive effects checked. In this class of cases the joint should be fixed during the progressive stage of the disease, in the attitude in which anchylosis, if it be unavoidable will least inconvenience the patient, and, if possible, efficient traction should be employed with the aim of separating the surfaces of the adjoining bones during the progressive stage of the disease.

Formerly it was believed that prolonged fixation of a diseased joint

[1] Die Syringomyelie, Wien. 1895.

MEDICAL LIBRARY
BOSTON
312E

would of itself induce anchylosis, but now that it is known that final limitation of motion is dependent upon the severity and the duration of the disease, prolonged rest in cases in which the joint surfaces are actually diseased is believed to be the most efficient means of conserving motion.



FIG. 268.—A useful form of brace for weak knee, in which the range of motion is regulated by means of an adjustable wheel. (Shaffer.)

For although long-continued splinting of a joint causes temporary stiffening, yet, as a rule, functional use will restore all the motion of which the part is capable. This is usually true of limited movement in a joint after the treatment of fracture, but in many instances the restoration of the normal range may be hastened by passive movements under anesthesia. In all cases of this class the weakened bone should be protected by splints to prevent refracture if any degree of force is to be used.

In the treatment of infected wounds of joints free incision combined with methodical movements, if possible voluntary, and to the normal limit (the Willems method) are of greatest value in expressing the fluid from the joint and preserving function.

Passive Motion.—When the acute symptoms have subsided the absorption of the plastic material may be hastened by massage, the hot-air bath and the like, and by carefully regulated passive and active movements. Passive congestion after the method of Bier is also of value.[1] In the final stage, when there is no longer evidence of active disease, forced motion under anesthesia may be of service in breaking adhesions, especially if these are without the joint. Passive movements that cause persistent discomfort or pain, which are often employed in the treatment of stiff joints, even when the disease is active, are absolutely contraindicated. If, however, the limb during the course of the disease has become deformed, it should be restored to its proper position as soon as possible, even though force is required. This treatment is indicated in order to prevent or to overcome secondary retraction of the muscles and fasciæ.

Forcible Correction.—The class of cases in which the limb is deformed is the most favorable one in which to perform the so-called brisement forcé, because the rectification of deformity is always indicated, and in accomplishing this there is always the prospect of increasing the range of motion. If, however, there is no deformity, the advisability of forced movement will depend on the character of the preceding disease as well as upon the condition of the joint. It is rarely advisable to disturb a tuberculous joint except for the purpose of correcting deformity, at least not until long after the cure of the disease; but if the fixation has followed infectious arthritis of a mild form, or monarticular "rheumatism," and if the roentgen picture shows that the articulating surfaces are fairly normal forcible manipulation may be attempted. If under gentle manipulation the adhesions give way suddenly, permitting free motion, the prognosis is good; but if there is a peculiar, elastic, continuous resistance, as when there are extensive adhesions within the joint, there is little likelihood of attaining motion by this means. If but slight force has been exerted there is usually but little reaction, and massage and passive movement may be employed at once; but in other instances the manipulation is followed by swelling and pain, and until these symptoms have subsided fixation may be indicated. It may be mentioned that anchylosis following disease is usually accompanied by marked atrophy of the bones, and fracture may occur during forcible correction. In cases of this character the complication of fat embolism is sometimes encountered. If the deformity is of long standing, complete correction should not be attempted at one sitting. At the knee, for example, the deformity having been partly corrected by division of the resistant tissues, a plaster splint should be applied. After an interval of a week or more further correction is attempted by "reverse leverage," as described elsewhere. If the resistance cannot be readily overcome a subcutaneous osteotome is inserted just above the joint and the correction is made complete by fracturing the femur. In cases of bony

[1] Blecher: Deutsch. Ztschr. f. Chir., lx, 250.

anchylosis in youthful patients even right angular deformity should be corrected by osteotomy of the shaft rather than by removal of a wedge of bone which may involve an epiphyseal cartilage.

After subsidence of the reaction that usually follows forcible correction, passive movements within the range that is practically painless may be carried out manually, or by means of one of the so-called pendulum machines, by which the limb is moved back and forth through an arc unrestrained by muscular spasm. Functional use, when the joint is protected by apparatus that limits the range of motion to the painless area, is also of service.

FIG. 269.—Anchylosis at the hip, showing masses of new bone. (From the Museum of the College of Physicians and Surgeons.)

The roentgen-ray is of great value in demonstrating the condition of the joint and the degree of atrophy of the bones, but the history, which should indicate the character of the disease, and the physical examination are far more reliable from the standpoint of prognosis. In some instances *operative exploration* of the joint may be indicated. This permits the removal of exostoses or displaced fragments of bone after fracture that may limit motion mechanically.

BENNETT'S OPERATION.—Bennett[1] has called attention to the fact that limitation of flexion at the knee-joint is due, in many instances, to shortening of the quadriceps muscle, particularly after fracture or other injury of the femur. In such cases the tendon is exposed by an incision above the patella in the median line. The tendon is then cut from the muscle at a point about 3 inches above the patella and also from its lateral attachments to the vasti. The leg is then forcibly flexed and the central tendon being detached from the bone to which it may be adherent. The resistance to flexion having been overcome, the tendon is sutured laterally to the vasti, and the interval between the quadriceps and the central tendon closed by drawing the lateral tissues into contact. The limb is then fixed in a plaster splint in flexion until repair is complete. Afterward active and passive exercises will usually restore function.

[1] Am. Jour. Orthop. Surg., September, 1919.

Arthroplasty.—Operations for the restoration of motion in anchylosed joints are conducted on the following principles:

Sufficient bone must be removed to leave a wide interval between the opposing surfaces. These should be modelled to assure stability, preserving as far as possible the normal outline, especially at the elbow- and knee-joints. The most favorable cases for operation are those of complete bony union. The most unfavorable are those in which the bone is atrophied and degenerated, as after tuberculous disease.

Arthroplasty is most often indicated in the upper extremity where motion is more important than stability. At the shoulder-joint even complete resection of the head of the humerus does not prevent useful function, and at elbow movement, even with lessened stability, is preferable to fixation. In the lower extremity security in weight-bearing in the laboring class is of far greater importance than movement with insecurity.

The ankle-joint is a favorable locality, because motion may be usually assured by removal of the astragalus without loss of stability.

At the hip the most direct indication for operation is bilateral anchylosis, accompanied by deformity.

The head of the bone may be very much reduced in size or even resected and yet stability assured if the trochanter is removed and displaced outward and downward to permit inclusion of the neck within the acetabulum. (See Reconstruction Operation.)

Jones, in elderly subjects, cuts through the neck at its base, separates the trochanter from the shaft and, turning it downward, nails it to the extremity of the neck. A section of the shaft is then removed on a level with the trochanter minor. Thus, the extremity of the shaft comes into contact with the tissue covering the transplanted trochanter, which prevents union.

The prospect of painless controlled movement combined with stability is most unfavorable at the knee-joint, and the operation is not often indicated except in those cases in which the ability to flex the limb in the sitting posture is of greater moment than security in weight bearing.

The most favorable cases are those in which motion is restrained only by an adherent patella.

In cases in which the joint surfaces are destroyed motion is primarily dependent on the removal of sufficient bone so that they be held apart during the process of repair. An interval of $\frac{1}{2}$ inch between the opposing surfaces is necessary, and all the tissue that may restrain such separation should be removed. Union of the denuded surfaces is prevented by holding them apart by traction and by the interposition of flaps of fatty, fibrous or muscular tissue from the neighborhood, or of free fascia transplanted from the outer and upper third of the thigh or foreign substances, such as chromicized pig's bladder (Baer) may be used.

The pedicle method is more applicable at the shoulder- and hip-

joints. It has the disadvantage of difficulty in adjustment, and at other joints the tissues are often so atrophied that the material is insufficient; furthermore, sloughing of the skin may follow extensive dissection for this purpose.

The principles of arthroplasty are well demonstrated by Campbell's illustrations[1] (Figs. 270–273) of a modified Putti operation on the knee-joint. The quadriceps tendon is divided by the Z-plastic method. The patella is then separated from the femur and turned downward. The union between the femur and tibia is cut through

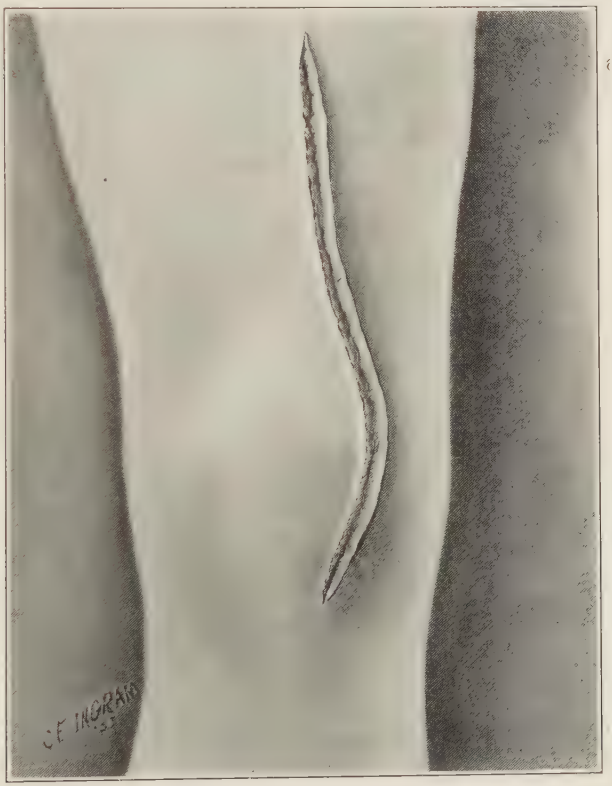

FIG. 270.—Skin incision, arthroplasty of the knee.

with a chisel and the bones fully exposed by flexing the knee. From $\frac{1}{2}$ to 1 inch of bone, following the normal contour, is removed from the femur, obliterating the intercondyloid notch, and a thin, concave section from the tibia, care being taken to assure alignment and a freedom of motion that shall permit at least 20 degrees of hyperextension. The patella is cut down in its antero-posterior diameter as thin as is compatible with strength and sufficient bone is removed from its margins to permit its periosteal and tendonous attachments to be drawn over the edges of the bone and sutured to an inferior covering turned

[1] Am. Surg., July, 1924.

upward from the mass of fatty tissue below it. The surfaces of the femur and tibia are then covered with fascia cut from the other limb, the dimensions being in some instances 8 or 10 inches in length by 4 or 5 inches in width. This is sewed above to the muscular tissue,

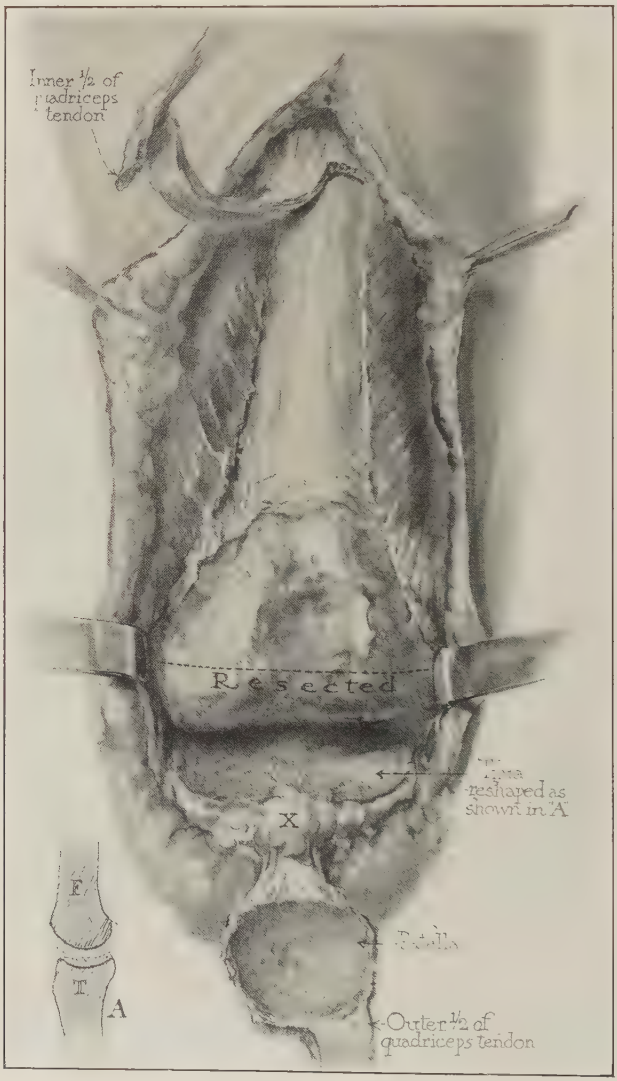

FIG. 271.—The making of one large condyle of the lower extremity of femur and one shallow cavity of the upper extremity of the tibia. As much of patella removed as possible.

passed over the condyles, attached to the posterior layer of the capsule, then carried forward over the articulating surface of the tibia and stitched carefully about the margins of the joint. The tendon of the quadriceps is then united, the margins of the capsule are sutured to

each other and the limb is placed in a form of Thomas brace jointed at the knee. The leg is supported in the extended attitude and under moderate traction for a week or more when active and passive motion is begun.

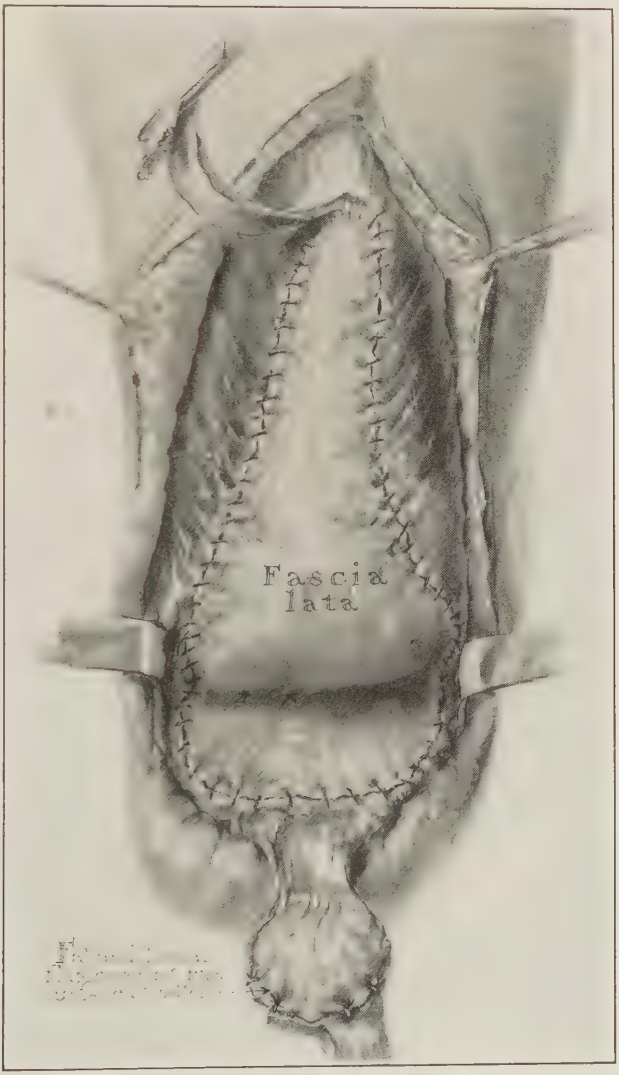

Fig. 272.—Anterior view after interposition of fascia lata from opposite limb.

Klapp[1] has called attention to the fact that at the knee-joint the cartilage on the posterior aspect of the condyles may be in fairly normal condition. In such cases the tibia is forcibly flexed to a right

[1] Ztschr. f. Chir., July 30, 1910.

angle in apposition to this surface, and by removal of a sufficient wedge of bone from the front of the lower extremity of the femur the tibia is brought to the axis of the limb, still preserving its right angular relation in the articulation. Such an operation must include, of course,

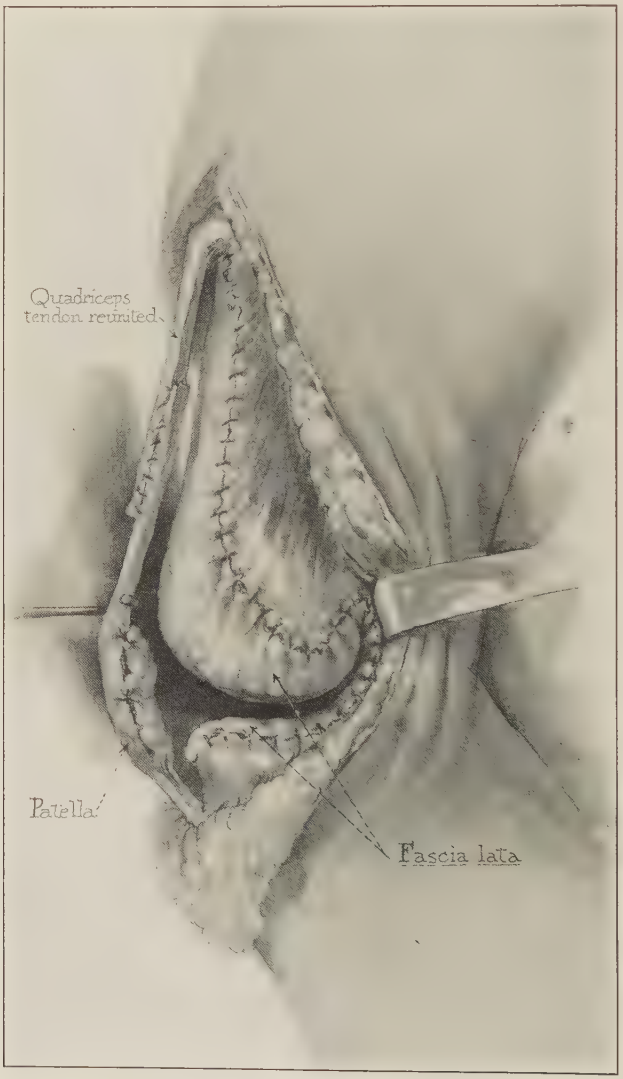

FIG. 273.—Side view showing area of attachment of fascia lata, and pedunculated flap covering patella.

the freeing of the patella if it is adherent to the bone. (See Chapter XXIV.)

MacAusland's figures[1] (Figs. 274–285, pages 321–323) illustrate clearly the same type of operation at the elbow-joint.

[1] Surg., Gynec. and Obst., September, 1924.

MEDICAL LIBRARY
BOSTON CITY

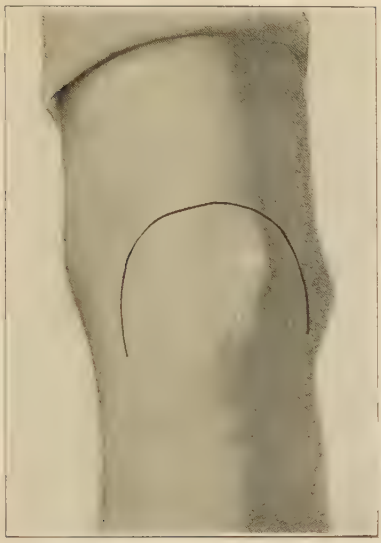

FIG. 274.—Line of incision.

FIG. 275.—Dissecting out ulnar nerve.

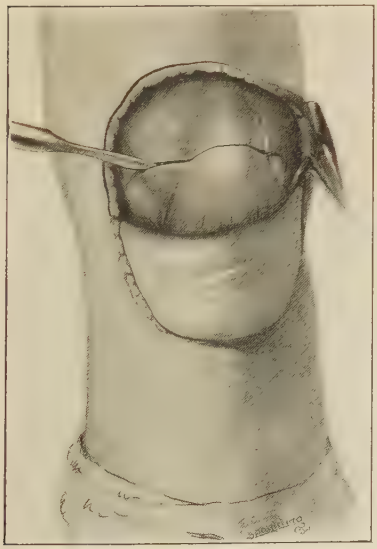

FIG. 276.—Cutting through the muscle and fascia down to the joint.

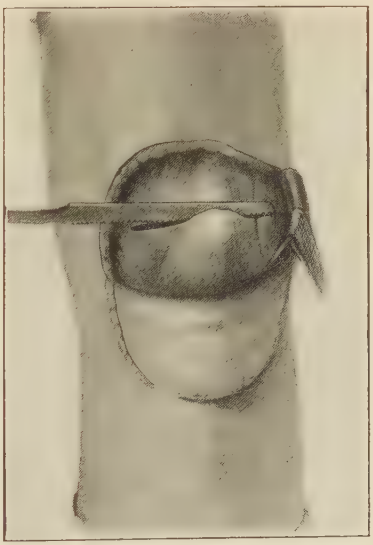

FIG. 277.—Sawing through olecranon and end of humerus.

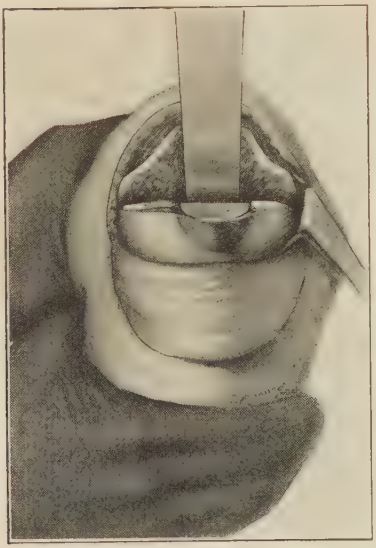

FIG. 278.—Splitting off tip of olecranon with chisel.

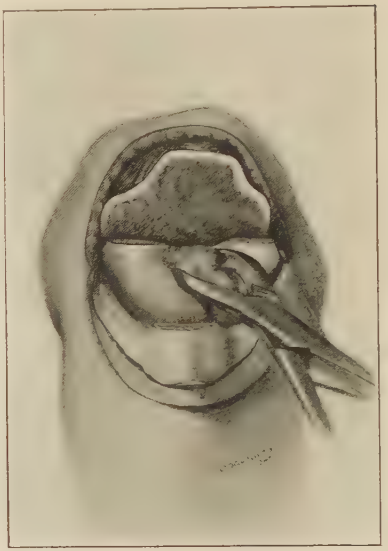

FIG. 279.—Cutting out with rongeur forceps bit of olecranon tip left in humerus.

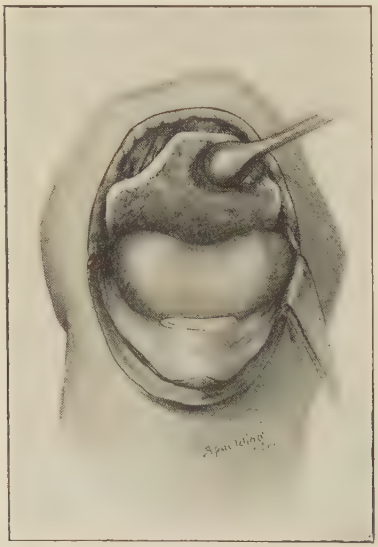

FIG. 280.—Scooping out ulna and radius with curette.

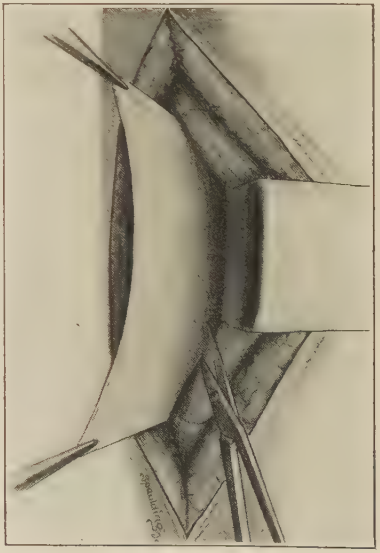

FIG. 281. — Cutting fascia lata from thigh.

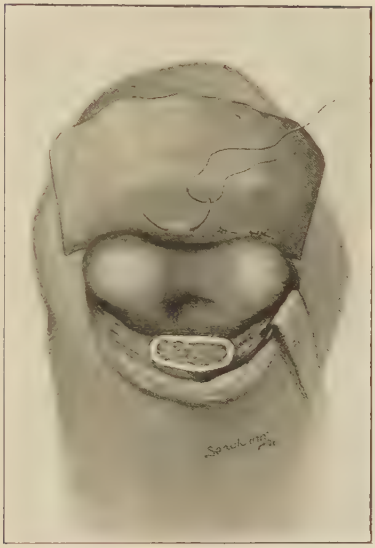

FIG. 282.—Sewing the flap of fascia lata to the elbow-joint anteriorly.

FIG. 283.—Fascia sewed over humerus; tied with chronic catgut suture.

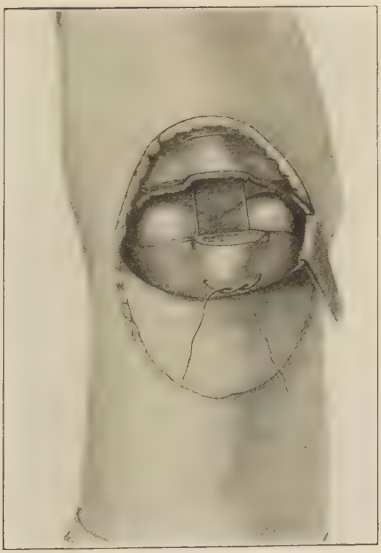

FIG. 284.—Kangaroo suture through ulna and olecranon tip.

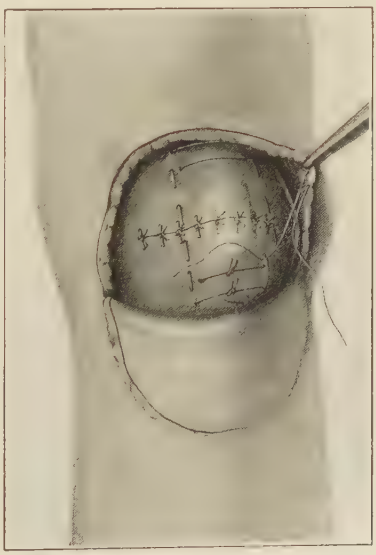

FIG. 285.—Stay sutures.

MYOSITIS OSSIFICANS.

The condition may be divided into three groups:

1. A progressive disease of unknown origin appearing in early life and involving many muscles.

2. A local form induced by repeated slight injury or strain—"Rider's bone."

3. The common form, which usually follows injury, such as tearing a muscular attachment from the bone, periosteal blood clot, interstitial myositis and the like.

The most common sites are about the brachialis anticus and the quadriceps extensor muscles. Of 233 cases reported from the German military service, but 3 were in other situations. A sensitive swelling following, for example, a dislocation at the elbow appears in ten or twelve days and at the end of three weeks the ossified tissue is evident in a roentgen-ray picture. It is possible that treatment by diathermia might induce absorption, but, as a rule, operative removal when the bone has consolidated usually at the end of about six months is the only effective remedy (Noble[1] and Gruca[2]).

MALIGNANT DISEASE OF BONE.

Carcinomata are practically always secondary to disease elsewhere. There may be widespread metastasis in the skeleton, indicated by a peculiar mottled appearance in the roentgen-ray picture, without symptoms other than "rheumatic pains." The progress of the disease is often accompanied by evidence of repair and fractures even may unit. The secondary disease of the bone may be indicated by fracture before the primary tumor has been suspected, and the patient may survive for months or even years, even after many bones are involved.

Secondary (metastatic) malignant lesions of the bone are seen in two forms: the osteoclastic, or purely destructive, and the osteoplastic, in which destruction of bone and proliferation of bone are coincident.

The osteoclastic form may best be visualized by the term "melted ice." If the various parts of the skeletal system are kept in mind as a block of ice, the lesions typify the results of directing a flame against them by a blowpipe. There are areas of destruction without any evidence of reaction. This type is most common following primary lesions in the breast. Infrequently one sees the osteoclastic and osteoplastic forms combined.

The osteoplastic form is most frequently seen following primary carcinoma of the prostate gland. The dominant note of the osteoplastic form is proliferation of bone, which gives added density to the bone involved. Commencing as a thickening of the bone along one or both sides of the sacro-iliac synchondrosis in the iliac margins, it may spread to involve all the bones of the skeleton. Occasionally there may be involvement of one or more of the lumbar vertebræ without evidence of involvement elsewhere.[3]

[1] Surg., Gynec. and Obst., December, 1924.
[2] Ann. Surg., December, 1925.
[3] Sutherland; Jour. Am. Med. Assn., December 28, 1929.

Thyroid metastases in bone are not usually malignant, and there is usually no recurrence after removal. In at least 25 per cent. of the cases there was no enlargement of the thyroid gland (Joll[1]).

The sarcoma as contrasted with carcinoma is a disease of early life, particularly of the second decade, 75 per cent. of the cases involve the femur or tibia. The disease in onset and progress is usually accompanied by sensitiveness and pain and in rapidly growing tumors by local heat. The tumor as distinct from non-malignant growths resembles callus formation, surrounding the bone involving both the medulla and cortex of the extremity of the diaphysis. Bone destruction is accompanied by bone formation and the overlying soft tissues are often involved.

From the diagnostic standpoint the most important affections are the giant-cell sarcoma and chronic osteomyelitis. The giant-cell tumor involves the cancellous tissue of the epiphyseal extremity of the bone, the favorite site being the upper extremity of the tibia. Its progress is slow and attended by but little discomfort. It enlarges laterally, expands and eventually breaks through the cortex with but little inflammatory reaction and practically no new bone formation.

The confusion between chronic inflammatory processes in bone and sarcomata is due in part to the possible combination of the two processes, the sarcoma being a secondary complication of the primary disease, as for example, osteitis deformans. In inflammatory lesions the contour of the bone is usually retained while osteogenic sarcoma in the early stage there is usually evidence of a break in the periosteum and invasion of the soft parts. The tentative, or positive, diagnosis of bone tumors is made from the history, the physical examination and from roentgen-ray examination. The more important points for consideration are summarized by Hutchinson[2] as follows:

The roentgen-ray diagnosis of bone tumors the point of origin of the growth must be considered first, that is, whether it arises from the cortex, the medulla or the periosteum. Carcinoma is ruled out if the growth originates in the periosteum, as the latter contains no epithelial cells. Carcinoma cells are metastatic in bone and begin in the region of the nutrient artery. Sarcomata may originate in the cortex, medulla, or periosteum.

The second point to be considered is whether the cortex has been destroyed or not, and if it is not destroyed, whether it is expanded. Benign tumors expand the cortex rather than destroy it.

The third point is that of bone production. Carcinoma never produces new bone. Round-cell and spindle-cell sarcomata do not produce new bone. Consequently, periosteal, osteosarcomata, enchondromata, osteomata and hematomata must be considered. Malignant disease lays down new bone perpendicular to the shaft. Benign tumors lay down new bone parallel with the shaft.

The fourth point is that of invasion. Benign tumors push aside the soft tissues, while malignant tumors include the soft tissues, in their growth. Metastatic carcinomata from the prostate to the pelvic

[1] Brit. Jour. Surg., 1923, **11**, 38. [2] United States Naval Med. Bull., 1923, vol. **18**.

bones and to the femur appear to be definitely increased in density. Bone destruction is less evident. Metastases from carcinoma of the breast, lungs, skin or uterus cause destruction of the bone with no increase in density.

Round-cell sarcoma originates in the medulla and destroys in all directions. The cortex is destroyed and not expanded. Round-cell sarcoma invades the surrounding tissues early. Spindle-cell sarcoma does not invade or destroy as rapidly as the round-cell sarcoma. Periosteal sarcoma is the most characteristic. It originates in the periosteum and invades the tissues with little change in the appearance of the cortex. In the early stages a number of fine lines of calcium deposits can be seen extending perpendicularly into the soft tissues. Later on the cortex is invaded and destroyed. Osteosarcoma appears more dense and massive and shows much earlier destruction in the cortex than the periosteal sarcoma. It occurs also in youth and early life. Periosteal and osteosarcomata are the only malignant tumors producing new bone. In comparison with most sarcomata, giant-cell sarcoma is benign. It does not tend to metastasize. It arises in the medulla and destroys a portion of the cortex. Its common site is the ends of long bones, usually the femur and tibia. It is a tumor of middle age.

Myeloma is a malignant growth which grows slowly. It shows multiple focal areas of destruction under the cortex. The cortex is thinned out but never destroyed. The symptoms are usually attributed to "rheumatism." The presence of Bence-Jones bodies in the urine assists in the diagnosis.

Endothelial myeloma (Ewing's tumor) involves the shafts of long bones or the flat bones where osteogenic sarcoma are rare. The progress is slow, the bone enlarges, accompanied by intermittent pain and swelling. The roentgen picture resembles a giant-cell sarcoma and osteomyelitis. A diagnostic feature is the susceptibility of the lesion to radium or roentgen-ray treatment, although local recurrence and general dissemination are common after apparent cure.

Myxomata resemble bone cysts. They occur in youth and may become malignant.

Enchondromata and osteochondromata may be entirely or partially cartilaginous in origin. They occur early in life and originate in the medulla over the epiphyses. They expand, but do not destroy, the cortex.

Osteomata are benign tumors growing from the cortex. In structure they resemble bone. They do not invade, but push the tissues aside and usually occur in the young.

Bone cysts resemble enchondromata. They originate in the medulla, and expand, but do not destroy, the cortex.

Fibromata are rare tumors. They do not invade and contain no new bone. They cannot be differentiated from bone cysts.

Hemangiomata are not bone tumors, but large, round, soft-tissue swellings. They contain old bodies of calcification. Ossifying hematomata are commonly seen in cases of scurvy in children. Calcium is laid down in layers parallel with the shaft.

CHAPTER VII.

TUBERCULOUS DISEASE OF THE HIP-JOINT.

Synonyms.—Hip disease, Morbus coxæ.

Hip disease is a chronic destructive disease that results in loss of function and deformity. At one time a number of pathological processes and even simple deformity (coxa vara) were included under the title, but it is now limited to tuberculous disease.

Fig. 286.—Section of the hip-joint at the age of eight years, showing the epiphyses and the relation of the capsule. (Schuchardt.) At birth the entire upper extremity of the femur is cartilaginous. According to Jacinsky, ossification begins in the head of the femur at about the tenth month; in the trochanter major at from the fourth to the eighth year; in the trochanter minor at the eleventh year. Ossification is complete at all points at about the eighteenth year.

Range of motion at the hip-joint. Extension to 20 degrees beyond the horizontal; flexion to 70 degrees; total 140 degrees. Abduction, adduction, and rotation are most free when the limb is flexed to 13 degrees. At this point the range of abduction is 55 degrees, of adduction 35 degrees; total 90 degrees. Outward rotation 40 degrees, inward rotation 20 degrees; total 60 degrees. If the limb is completely extended the range of abduction is about 45 degrees; adduction, 15 degrees.[1] Moore and Vaughan found the extreme range between flexion and extension 172.6 degrees the minimum range 120.8.[2]

Pathology.—Tuberculous disease of the hip-joint of the classical type usually begins in several minute foci near the epiphyseal cartilage of the head of the femur. Here the circulation is most active, and here the newly formed bone is least resistant. Thus the bacilli, carried by the blood, are more often deposited at this point by the vessels which in childhood are terminal and where, under favoring

[1] R. du Bois-Raymond: Berlin, 1903.
[2] Jour. Bone and Joint Surg., April, 1928.

conditions, the disease is established. These foci coalesce and an area of infected granulation tissue replaces the normal structure. If the local resistance is sufficient the disease may be confined to the interior of the bone, but in most instances it gradually forces its way into the joint and the granulation tissue, spreading under and over the cartilage, destroys it in its progress. The lining membrane of the joint becomes involved in the disease, and, finally, the adjoining surface of the acetabulum as well. In other instances the tuberculous process may begin about the epiphyseal junctions of the acetabulum or primarily in the synovial membrane.

FIG. 287.—"Wandering of the acetabulum" in hip disease. (Krause.)

Waldenström,[1] from observations on 83 cases of hip disease, nearly all in children, concludes that the primary infection was apparently of the neck of the femur in 22, of the head in 3, of the acetabulum in 28, of the synovial membrane in 15, and indeterminate in 15. Of the 22 cases in which the neck was involved, the disease was near the upper border in 7, the lower border in 15. In 14 instances the disease was confined to the neck. Kepler and Erkes,[2] on the other hand, in 235 cases found the primary focus in the neck in 8 per cent., in the acetabulum in 11 per cent. and in the head of the femur in 80 per cent. This accords with the generally accepted opinion, which is, however, based on conjecture rather than on physical evidence.

From the clinical stand-point, primary disease of the acetabulum may be inferred if the patient is particularly susceptible to movements of the trunk, or if lateral pressure on the pelvis causes pain; or if a roentgen-ray picture shows greater erosion of the acetabulum than of the head of the femur. If the disease is confined to the neck, the symptoms are less distinctive and deformity (coxa vara) may be an early indication of weakness. There are cases in which the symptoms of the disease are slight and in which swelling about the joint is noticeable; in such cases it is probable that disease of the synovial membrane is present without marked involvement of the head of the femur or of the acetabulum.

[1] Stockholm, 1910.

[2] Arch. f. klin. Chir., 1914, Band **105**, Heft 3.

MEDICAL LIBRARY
BOSTON CITY

In the common or osteal form of disease, while the tuberculous process is still confined within the head of the femur, the joint shows evidences of sympathetic irritation; the synovial membrane is congested and the fluid within the joint is increased in quantity. These changes become more marked as the disease progresses, the lining membrane becomes thickened and granular, and adhesions between its folds lessen the capacity of the joint. An amount of tuberculous fluid, large enough to be recognized as an "abscess," is present in about half the cases at some time during the course of the disease. This fluid usually finds an exit from the capsule into the tissues of the thigh, but occasionally it may pass through the acetabulum into the pelvis. In rare instances

Fig. 288.—Erosion of the head of the femur and of the upper border of the acetabulum. Formation of new bone (osteophytes) about the acetabulum.

the disease may not enter the joint, but may find an opening in the neck through the adherent capsule. In such cases the joint is, in most instances, finally involved unless the disease is removed by surgical means. There are cases, also, in which the disease, confined within the head of the bone, so weakens it that it becomes distorted to a marked degree without destruction of the cartilage.

If the disease involves the neck of the bone its angle may be diminished, a form of coxa vara; or the head of the bone may be separated at the epiphyseal junction, with consequent upward displacement of the shaft.

In by far the larger number of cases all the tissues of the joint are involved and the head of the femur and the acetabulum are eroded

to a greater or less degree. In such instances the destructive effects of the disease are increased by the pressure and friction of the soft-

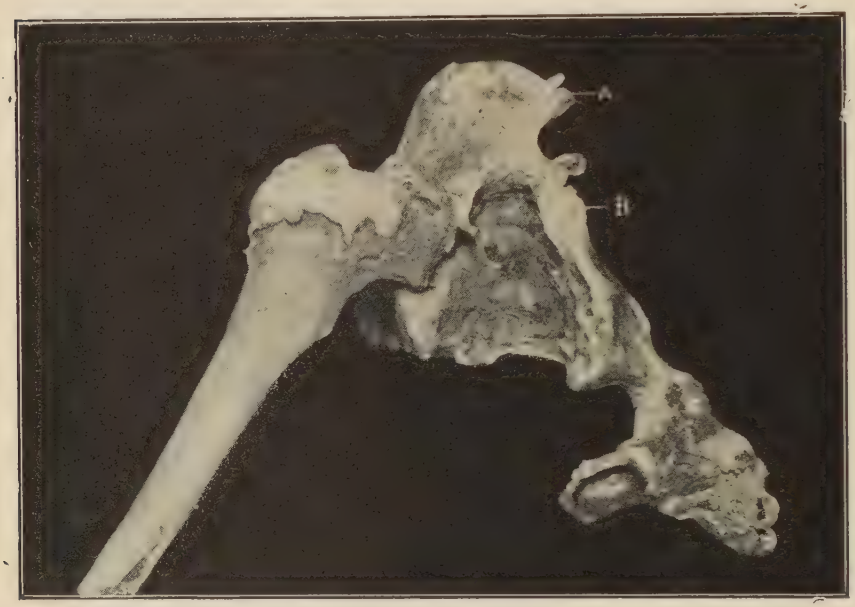

Fig. 289.—Erosion of the head of the femur and of the upper margin of the acetabulum. *A*, anterior-superior spine; *B*, anterior-inferior spine.

ened bones on one another, aggravated by muscular contraction. Thus at the upper margin of the acetabulum and the inner and upper surface of the femur there is greater loss of substance than elsewhere (Fig. 289).

Fig. 290.—Erosion of the head of the femur and destruction of the acetabulum.

The appearances in advanced cases of this type, as seen at operation or autopsy, may be summarized as follows: The head of the femur is deeply eroded, its cartilaginous covering has practically disappeared, or is in part still adherent in necrotic shreds. It lies in seropurulent fluid, embedded in the gelatinous granulations that line the capsule and partly fill the acetabulum.

In certain instances the disease may extend to the adjoining surface of the pelvis, or

the acetabulum may be perforated (Fig. 290), or the medullary cavity of the femur may be implicated. Occasionally the disease may be from the first of an acute destructive type, whose course is but little influenced by treatment, but in the majority of cases the progress of the disease and its destructive effects may be greatly modified by efficient protection of the joint.

In the natural cure of the disease the focus within the bone, if it be small, may be absorbed and replaced by scar-like tissue; or the products of the disease may be separated from the healthy parts, and discharged by abscess formation. In other instances a part in which the disease is still active may be enclosed within the newly formed tissue. Here the process may remain quiescent or it may cause relapse many years after the apparent cure. Or portions of necrosed bone, enclosed within the capsule, may prolong suppuration after the tuberculous disease has ceased to progress.

Etiology.—The etiology of tuberculous disease is discussed in Chapter V.

Relative Frequency.—Tuberculous disease of the hip-joint is the most common and the most important of the affections of the joints, ranking second to Pott's disease. In a total of 7845 cases of tuberculous disease treated in the out-patient department of the Hospital for Ruptured and Crippled during a period of fifteen years 3203 were Pott's disease, 2230 were hip disease, while the remaining 2412 cases included all the other joints.

AGE AT INCIPIENCY.

Less than 1 year	9	Between 16 and 17 years	14
Between 1 and 2 years	39	Between 17 and 18 years	1
Between 2 and 3 years	107	Between 18 and 19 years	5
Between 3 and 4 years	155	Between 19 and 20 years	0
Between 4 and 5 years	158	Between 20 and 21 years	3
Between 5 and 6 years	139	Between 21 and 22 years	3
Between 6 and 7 years	90	Between 22 and 23 years	1
Between 7 and 8 years	51	Between 23 and 24 years	2
Between 8 and 9 years	51	Between 24 and 25 years	3
Between 9 and 10 years	40	Between 25 and 26 years	1
Between 10 and 11 years	33	Between 26 and 27 years	1
Between 11 and 12 years	19	Between 27 and 28 years	1
Between 12 and 13 years	18	Between 28 and 29 years	1
Between 13 and 14 years	23	Between 30 and 33 years	4
Between 14 and 15 years	7	Between 33 and 36 years	1
Between 15 and 16 years	8	Age not stated	12
			1000

Age.—Hip disease is essentially a disease of early childhood, although no age is exempt. In a series of 1000 consecutive cases of hip disease, 88.1 per cent. of the patients were in the first decade of life, and 45.6 per cent. of these were from three to five years of age, inclusive.

Sex.—Sex exercises but little influence in predisposition, although the disease is slightly more common among males than among females.

In the 1000 cases referred to, 553 (55.3 per cent.) were in males, 447 were in females. In 3307 cases treated at the same institution, 53 per cent. were in males.

Side Affected.—In disease of this as of other joints the right is somewhat more often affected than the left. In the 1000 cases 506 were on the right side, 483 were on the left, and in 11 cases both joints were involved. In a larger number of cases treated in the department 53 per cent. were of the right joint.

Symptoms.—Tuberculous disease of the hip-joint is a chronic, insidious affection characterized by painful periods often induced by overstrain or injury, or that indicate more rapid advance of the destructive process, or infection with pyogenic germs. In the early stage of the disease the joint is simply sensitive, and the symptoms vary with the increase of the tension within the bone, the susceptibility of the patient, and the strain to which the weakened part is subjected. This sensitiveness is first indicated by an involuntary adaptation to the weakness of the affected joint, or, as popularly expressed, the patient favors the limb.

The important symptoms of disease of the hip-joint, in the sense of attracting attention to the affection, are *pain and limp*. Of the two, pain is much the less significant. Hip disease is by no means a painful disease, and although patients are often brought for treatment because of pain, it is usually apparent, on examination, that the disease must have existed long before the acute exacerbation called attention to its serious character. Even in cases in which the disease is far advanced, one may be assured that the patient has never complained of pain.

Pain.—The characteristic pain of hip disease is "pain in the knee," referred, as is the pain of Pott's disease, to the more important distribution of the nerves, whose filaments are irritated by the local process. The hip-joint is supplied by the gluteal, the anterior crural, the sciatic, and the obturator nerves, but the pain is more often referred to the distribution of the last, thus to the inner side of the knee.

The pain of hip disease is induced by sudden or unguarded movements, or by overuse; therefore it is rather an occasional than a constant symptom. If it is persistent it almost always indicates the increased tension either within the bone or within the joint that accompanies abscess formation.

Night Cry.—Pain at night is of importance, as it more often attracts attention than the occasional complaint of discomfort during the day. It is a common symptom when the disease is at all acute in character, and it is often present when pain, during the period of activity, is apparently absent. It may be inferred, as an explanation of this symptom, that the joint gradually becomes more sensitive under the strain of use during the day, and that the relaxation of the voluntary and involuntary protection of the muscles permits sudden movements that excite spasmodic muscular contractions, which force the

sensitive parts against one another. This causes a sharp cry. If the disease is acute, it may be noted that the child is holding the thigh with the hands or pressing upon the limb the other foot, the evidence of pain being unmistakable. In the less sensitive conditions the patient does not wake after crying out, but simply moans or is restless for a time. If awakened it makes no complaint of pain and the cry is supposed to be caused by a "bad dream." This cry may be repeated several times, usually in the early part of the night.

Local pain and sensitiveness to pressure are unusual unless the disease is acute in character, or unless the tissues overlying the joint are infiltrated, as in abscess formation.

Limp.—The limp is the most important of what may be classed as the objective signs of the disease. A limp is a change in the rhythm of the gait, the step being relatively shorter on the affected side. It is evident that any interference with the function of the limb will cause this irregularity which can be concealed or diminished only by accommodating the normal member to its disabled fellow. Thus inequality in length of the limbs or limitation of motion in the joint, or distortion, or weakness or pain, may cause an arrhythmical gait. Several of these factors may be combined in the causation of the final disability of hip disease, but in the beginning the limp is due rather to sensitiveness than to restriction of function. Thus the patient favors the joint by resting on the limb for a shorter time than on its fellow, and by bearing more weight upon the front of the foot than upon the heel. If the joint is very sensitive, the patient may bear practically all the weight upon the front of the foot, the slight plantar flexion at the ankle with flexion at the knee and hip lessening the jar of direct impact.

The limp is practically a constant symptom of hip disease; it is, as a rule, more noticeable in the morning or on changing from an attitude of rest than during activity. It may be intermittent even though it is probable that in most instances some change from the normal gait might be detected by a practised eye.

Physical Signs.—The other symptoms of disease of the hip-joint are more properly physical signs that become evident on examination. These are: *Limitation of motion, distortion, change of contour, and atrophy.*

Stiffness.—Limited motion ("stiffness"), due to reflex muscular spasm, is by far the most important sign of the disease. It indicates that the sensitive tissues of the joint can no longer permit the normal range. It is the first and the last sign of disease; it precedes the limp, and it persists long after pain has ceased to be a symptom, and until repair is complete.

Reflex muscular spasm limits motion in *every direction.* At an early stage of the disease the motion, whether voluntary or passive, may be perfectly free to the last quarter of its normal range, where it is checked by a peculiar elastic resistance. If an attempt is made to force the limb beyond the limit set by the muscular resistance the pelvis follows the movement. The contraction of the surrounding muscles, including

those of the trunk even, may be appreciated by the eye and by the hand, and the patient's expression is one of discomfort and apprehension.

The degree of muscular spasm corresponds to the sensitiveness of the joint rather than to the extent of the disease. Thus it may vary from day to day and even from hour to hour, and in the acute phases of the disease motion may be for a time so absolutely restricted as to simulate anchylosis.

FIG. 291.—Apparent lengthening. Fixed abduction of 45 degrees. When the antero-superior spines are on the same plane, as in the illustration, the deformity is evident. (See Fig. 292.)

Reflex muscular spasm is evidence of a sensitive joint; it is, of course, not diagnostic of the tuberculous process, but unless it is the direct effect of injury it indicates disease, and if this disease is chronic and confined to a single joint it is, in childhood at least, almost always tuberculous in character. At first the restriction of motion is caused almost entirely by reflex muscular spasm, as is shown by the fact

that when the patient is anesthetized the range of motion becomes practically free. As the destructive process progresses motion is still further restrained by adhesions and contractions within and without the joint.

FIG. 292.—Apparent lengthening. When the abducted limb is brought to the median line the pelvis is so tilted that it seems longer. (See Fig. 291.)



FIG. 293.—Right angular flexion in hip disease partly concealed by the compensatory lordosis and by the flexion at the knee and ankle.

Distortion of the Limb.—Persistent reflex muscular spasm is always accompanied by a certain change in the attitude of the limb, slight flexion being the earliest indication of distortion here as at every other joint. With flexion there is usually abduction with slight outward rotation of the limb.

FLEXION, ABDUCTION, AND OUTWARD ROTATION; APPARENT LENGTHENING.—This is the passive attitude or the attitude of rest and in disease it shows the instinctive adaptation of the limb to a sensitive joint. Flexion lessens the direct jar and abduction places the limb

aside, as it were, making it a prop and adjunct of its fellow instead of an active aid in the propulsion of the body. This attitude is not voluntarily assumed by the patient; it is involuntary and persistent. The limb is apparently lengthened, because it is held away from the axis of the body, and in order to bring it into the middle line and parallel to its fellow the pelvis must be tilted downward on the diseased side and upward on the other. The sound limb is drawn upward and the affected limb is lowered in accord with the degree of abduction for which compensation is made (Fig. 292). If the anterior-superior spines of the pelvis are placed upon the same plane, the distortion becomes evident (Fig. 291). Thus the deformity of the limb is concealed or compensated by a tilting of the pelvis which twists the lumbar spine into a lateral convexity toward the lower side.

FIG. 294.—The degree of fixed flexion is shown when the lumbar spine is held in contact with the table by flexing the other thigh.

In the same manner persistent flexion of the limb is concealed by tilting of the pelvis forward, and by an increased hollowness or lordosis of the lumbar region (Fig. 293). Normally, in childhood at least, the lumbar spine and the popliteal surface of the knee should touch the table when the patient lies upon the back; but if the thigh is fixed in flexion the lumbar region must be arched and raised from the table when the limb is in contact with it. Thus in order to make the flexion apparent, the lumbar spine must rest upon the table, and this is possible only when the limb is raised to a degree corresponding to the deformity (Fig. 294). If the spine were rigid, as in spondylitis deformans, this compensation would be impossible, and if the patient were placed upon his back the limb could not be brought down to the table; or if both limbs were distorted, as is sometimes the case when both hip-joints are diseased, the limbs would remain widely separated or crossed over one another, according to the character of the deformity.

FLEXION, ADDUCTION, AND INWARD ROTATION; APPARENT SHORTENING.—If the disease is of a more acute type, and if locomotion be permitted, the attitude usually changes to one of increased flexion, and adduction and inward rotation replace abduction and outward rota-

MEDICAL LIBRARY BOSTON CITY

tion. This attitude is an indication that the joint is so disabled as to be of little service, thus the limb is instinctively drawn into a more protected attitude, where it may be used as little as possible. If the patient is confined to the bed, or does not walk, as in infancy, the atti-

FIG. 295.—Apparent shortening. The adduction of the right thigh is made evident by the involuntary crossing of the legs when the anterior-superior spines are on the same plane.

FIG. 296.—Apparent shortening. When the adducted limb is placed in the line of the body, the pelvis is tilted upward on the adducted side and downward on the other. The patient has compensated for the apparent shortening by flexing the knee on the sound side. This does not appear in the photograph.

tude of abduction may persist, although the muscular spasm may be intense. Thus it would appear that locomotion has a distinct influence on the character of the distortion.

Adduction causes apparent or practical shortening, for in order to bring the adducted limb to the middle line of the body and parallel to its fellow, the pelvis must be tilted upward on the affected side and

downward on the other, the lumbar spine bending with the convexity toward the lower side (Figs. 296 and 299). If the level of the pelvis be restored, the adducted limb will be crossed over its fellow and the deformity is made evident (Fig. 295).

FIG. 297.—The final effect of hip disease when untreated. The natural cure, with flexion and adduction. Compensatory recurvation of the knee on the sound side is also shown.

FIG. 298. — Untreated hip disease. Flexion deformity to nearly a right angle with the body. Trochanter two inches above Nélaton's line. Compensatory lordosis.

As has been stated, the attitude of flexion, adduction, and inward rotation, if it appears early, is usually an indication of acute disease and of corresponding intensity of muscular spasm. But in most instances it is associated with the later and destructive stage of the disease, and it by no means indicates that the preceding symptoms have been more than ordinarily acute. In fact it is the attitude character-

istic of a so-called "natural cure" (Fig. 297) when mechanical treatment has not been employed. It more often accompanies the later course of the disease, because its causes are in great degree mechanical.

This is illustrated by König's statistics of 499 cases of hip disease.

In 267 cases the limb was abducted, and in 31 per cent. of these there was actual shortening.

In 232 cases adduction was present, and in 70 per cent. the limb was shorter than its fellow.[1]

The mechanics of the distortion as indicative of the destructive stage of the disease will be made clearer if it be compared to the deformity caused by dorsal dislocation of the hip. In this displacement the femur, forced upward and backward upon the pelvis, is fixed in an attitude of extreme flexion, adduction, and inward rotation. Each of the destructive changes of hip disease, the enlargement of the acetabulum, the depression of the neck of the femur, and the erosion of the head of the bone, is accompanied by an elevation of the femur upon the pelvis or an approximation to a dorsal displacement (Fig. 304). If this displacement occurs suddenly, as in certain cases of acute disease attended by effusion and rupture of the capsule, the limb immediately assumes an attitude typical of dorsal dislocation; but in the ordinary form of disease the changes are very gradual the pelvis and the femur, being in most instances undeveloped, more readily accommodate themselves to the changed conditions, so that the actual distortion is less marked than in a similar subluxation of traumatic origin in the adult; but the simile will serve to illustrate the mechanical causes of distortion, and why such deformity may recur after correction, even though the disease has entirely disappeared. Outward rotation of the limb is usually associated with abduction, and inward rotation with adduction, but in

FIG. 299.—Stage of apparent shortening. The left limb is adducted 35°, making an apparent shortening measured from the umbilicus of more than two inches. In order to reduce the obliquity of the pelvis, the adducted leg must be crossed over its fellow. (See Fig. 295.) The apparent shortening is compensated by the flexion at the knee on the sound side. This is not made clear in the photograph.

[1] König: Das Hüftgelenk, Berlin, 1902.

certain instances outward rotation may be combined with adduction and inward rotation with abduction. These irregular attitudes are more often observed in cases that have received mechanical or operative treatment than in those in which the disease has pursued its natural course.

As has been stated, the distortions of the early stage of hip disease are caused almost entirely by muscular contraction which relaxes under the influence of an anesthetic, but after a time the attitude is

FIG. 300.—Advanced disease, showing upward enlargement of the acetabulum and the obliquity of the pelvis due to adduction. Actual shortening 1 inch, apparent shortening 3 inches.

confirmed by accommodative changes in the muscles and fasciæ, and by contractions and adhesions about the capsule. Thus an attitude originally a symptom persists after the cure of the disease.

One may conclude then that flexion is practically an invariable symptom in hip disease because complete extension, the attitude that puts most strain upon the joint, is first restricted. Flexion in the milder or in the earlier class of cases is usually combined with abduction and outward rotation, the attitude of inactivity. Increased

flexion, accompanied by adduction and inward rotation is an indication of a more acute phase of the disease. If the attitude is retained for a time it becomes fixed by accommodative changes in the tissues; thus the distortion is not unusual in cases in which the damage to the joint may be very slight, as, for example, when it follows some form of infectious arthritis. But in most instances the attitude is indicative of more advanced disease and of destructive changes within the joint.

Changes in the Contour of the Hip.—The changes in contour are caused primarily by the attitude of the limb. If, as is usual, it is flexed, abducted, and rotated outward the buttock appears somewhat flatter and broader than its fellow. The gluteo-femoral fold is lower because of the tilting downward of the pelvis and it is shallower because of the flexion. If the thigh is adducted, the gluteal fold is elevated and shortened. On the anterior aspect the inguino-femoral fold is deepened and lengthened by flexion and adduction while abduction makes it less noticeable. Hoffman has called attention to the fact that the genitals and the intergluteal fold point toward the adducted and away from the abducted thigh. Adduction makes the trochanter more prominent and abduction makes it less prominent.

To these primary changes in the appearances must be added the effect of atrophy or of infiltration and swelling, due directly to the disease. A certain amount of swelling indicating effusion into the joint is often apparent in the inguino-femoral region, and infiltration of the deeper tissues is sometimes evident on palpation. In such cases there is usually a certain sensitiveness to deep pressure behind or in front of the trochanter. Palpable abscess is unusual in the early stage of the disease.

Atrophy.—Atrophy is an important sign of joint disease. It is often appreciable to the eye and to the hand, and it is always demonstrable by measurement. It is an important symptom, because, if well-marked, it shows that the disease must have existed for some time, whatever may be the statement of the patient's relatives.

The atrophy affects the muscles of the entire limb, although it is somewhat more marked in the muscles of the thigh than in the calf. In the ordinary case of hip disease in childhood, when the patient is first brought for treatment, it averages from one-half to one inch in the thigh and somewhat less in the calf, and, as has been stated elsewhere, atrophy of muscles is accompanied by a corresponding atrophy of bone as well.

The Causes of Atrophy.—Admitting that the secondary causes of atrophy are somewhat obscure, one cause, and by far the most important, is very evident. This is physiological disuse, and thus diminished nutrition of the limb, which has become incompetent to carry out its full function. Manifestly disuse will be most complete in the presence of active and painful disease of a joint. Atrophy is a constant symptom of simple disuse in the absence of disease. If a bone has been broken, atrophy of the muscles is observed. If anchylosis of a joint occurs from any cause, whether it be from injury or disease,

atrophy of the muscles, whose function has been abolished, follows. Even the atrophy caused by disease of the hip-joint is greater when the limb has been fixed in apparatus than when none has been applied, although the treatment has allayed the pain and has checked the progress of the disease. This point is illustrated by the observations of Brackett,[1] who contrasted the atrophy of hip disease in two groups of patients, in one of which motion had been permitted, while in the other fixation, as complete as possible, had been employed. In the first group the average of atrophy was but 1 per cent. of the volume of the thigh and 0.89 per cent. of that of the leg, as contrasted with 23 per cent. and 17 per cent. in the second class.

FIG. 301:—Illustrating the destructive type of hip disease. The limb having been fixed in abduction. No displacement is present.

According to the investigations of Bum,[2] simple fixation of a sound limb induces more rapid atrophy than is caused by disease of a joint when function has been permitted.[3]

The atrophy caused by physiological disuse and diminished nutrition affects all the components of the limb. The skin becomes thinner, the muscles lose in volume, the contractile substance is replaced in part by fat and by fibrous tissue, and the medullary canals of the bones enlarge at the expense of the cortical substance.

[1] Tr. Am. Orthop. Assn., vol. **4.**
[2] Ztschr. f. Chir., December 9, 1905.
[3] Wien. med. Presse, 1906, vol. **51.**

In childhood disuse often causes a retardation in growth of the entire extremity. This may be apparent in the foot when it is placed by the side of its fellow, while the diminished growth in the length of the limb may be demonstrated by measurement. Brackett, in a series of cases, found this shortening to be distributed as follows: average loss of the femur 6.6 per cent. and of the tibia 5.4 per cent. of the normal length.

Atrophy becomes less noticeable after function is resumed, the degree of final inequality depending upon the severity of the disease, the duration of the treatment, and upon the impairment of function. But even when free motion in the joint is retained, a certain degree of atrophy always persists and the loss in growth is never regained. If motion is completely lost the muscles about the joint lose in bulk in proportion to the disuse of their normal function; whereas the bones of the limb which are still used to support the weight retain to a greater degree their normal size and length. Contrasted with this atrophy there is a relative hypertrophy of the sound limb, which is forced to assume more than its share of work.

Fig. 302.—Dislocation secondary to disease of the hip-joint.

Actual Shortening.—Actual shortening of the limb is an effect rather than a diagnostic symptom of hip disease.

The causes of actual shortening may be classified as:

1. Disuse of the limb.
2. The effect of the disease upon the epiphyseal cartilage of the head of the femur.
3. The more general destructive effects of the disease that cause upward displacement of the femur.
   (*a*) Erosion of the head.
   (*b*) Erosion of the acetabulum.
   (*c*) Depression of the neck of the femur.
   (*d*) Dislocation.

Disuse, particularly of weight-bearing throughout a long period, causes a certain amount of shortening of the entire limb. To this the shortening of the bones of the leg and of the foot may be attributed in great part. If the epiphyseal cartilage uniting the neck and

the head of the femur is destroyed in whole or in part or if the disease hastens union at this point, a certain loss of growth must follow. This is, of course, slight in degree, because growth here is relatively unimportant compared with that at the lower extremity of the femur.

Erosion of the head of the femur and of the upper border of the acetabulum are usually combined in those cases in which the shortening is in part dependent on upward displacement of the trochanter (Fig. 288). Depression of the neck of the femur is usually caused by disease of its substance and is uncommon. Elevation of the trochanter, due to one or more of these causes, a form of subluxation, is very common, particularly so in those cases in which the protective treatment has been inefficient. Greater displacement follows fracture of the weakened neck and complete destruction of the head, and occasionally a fairly normal femur may be actually dislocated as a result of sudden effusion into the joint with rupture of the capsule—a form of pathological dislocation (Fig. 302).

It may be stated also that partial or complete anterolateral displacement is not uncommon. In such cases there is marked outward rotation of the limb with but slight shortening, the head of the bone presenting by the side of the anteroinferior spine of the pelvis.

Retardation of Growth.—As has been stated, all the components of the limb are affected by the retardation of the growth; Brackett's observations on this point have been mentioned, and the accompanying table showing the relative measures of the bones in cases under treatment by Döllinger[1] presents the subject in a convenient form:

No. of case.	Age at inception.		Duration of disease.		Length of femur in cm.		Difference.	Length of tibia in cm.		Difference.
	Years.	Months.	Years.	Months.	Diseased.	Normal.		Diseased.	Normal.	
1	8	6	..	6	28½	28	+½	24.0	24.0	..
2	3	4	..	8	23	24	1	19.0	19.0	..
3	2	10	1	8	24	24	..	19.5	19.5	..
4	5	..	2	..	29	30	1	23.5	23.5	..
5	6	..	2	..	27	28	1	23.0	23.0	..
6	7	..	2	..	32	33	1	27.0	27.0	..
7	9	..	2	..	37	37	..	30.0	30.0	..
8	1	..	4	..	22	24	2	18.5	19.0	0.5
9	13	..	4	..	38	41	3	34.0	34.0	..
10	4	6	5	..	32	34	2	27.0	27.0	..
11	..	2½	6	..	26	27	1	21.5	23.0	1.5
12	13	..	7	..	38	40	2	33.0	33.0	..
13	2	..	8	..	35	36	1	28.0	28.0	..
14	6	..	8	..	38	38	..	31.0	32.0	1.0
15	11	..	8	..	40	44	4	34.0	34.0	..
16	5	..	10	..	45	46	1	....	....	..
17	5	..	11	..	41	44	3	31.0	37.0	6.0
18	6	..	14	..	44	48	4	36.0	39.5	3.5
19	2	..	18	..	36	46	10	38.0	38.0	..
20	2	..	28	..	44½	45	½	37.5	37.5	..

H. L. Taylor made a similar investigation of 33 cases under treatment at the Hospital for Ruptured and Crippled. In these cases the

[1] Ztschr. f. orthop. Chir., 1892. vol. 1.

MEDICAL LIBRARY BOSTON CITY

shortening of the bones was found to be more generally distributed than in those reported by Döllinger, as is illustrated by the following table:

Case.	Sex.	Age.	Side.	Duration of disease, years.	Duration of treatment, years.	Abscess.	Shortening in inches.				
							Entire limb.	Femur.	Tibia.	Foot.	Patella.
1	F.	3½	Left	1	1	No	½	—	½	⅜	⅛
2	M.	7	Right	1½	1	No.	¼	x	¼	⅜	⅛
3	M.	5	Left	2	1	No	⅛	¼	¼	⅛	⅛
4	M.	5	Right	2	1½	No	¾	¼	⅜	⅜	¼
5	M.	6½	Left	2½	1½	Yes	¾	¼	⅜	⅜	¼
6	F.	4½	Left	3	3	No	—	—	—	—	¼
7	F.	6½	Right	3	—	No	½	—	¼	—	—
8	M.	6	Right	3	2½	No	1⅜	¼	¼	½	⅜
9	F.	13	Left	3½	2	No	¾	—	⅝	⅛	½
10	F.	7	Left	3½	3½	No	1⅜	½	¾	⅞	¼
11	M.	7	Right	3½	3½	Yes	1	¼	¾	¾	⅜
12	F.	11	Right	3½	1½	No	1¾	¼	⅝	¼	⅛
13	F.	9	Left	3½	3½	No	1¼	—	½	½	⅛
Average		7	—	2½	2	—	¾	⅛	½	¼	⅛
14	M.	7	Right	4	4	No	1	¾	¼	¾	½
15	F.	8½	Right	4	4	No	1	¼	½	¼	⅜
16	F.	12	Right	5	4	Yes	3¼	½	1¼	⅝	x
17	F.	11	Right	5½	4	Yes	2¼	1	½	¼	½
18	F.	13	Left	6	3	No	2	½	1⅛	½	¼
19	F.	12	Left	6	4	No	⅞	¾	¾	⅝	⅜
20	F.	10	Left	6½	4	No	1¼	¼	¼	—	¼
21	M.	14	Left	7	x	Yes	2½	x	¾	¾	¼
22	F.	15	Right	7	5	No	2¼	x	1	½	x
23	M.	9½	Right	7	½	Yes	1¼	—	½	¼	x
Average		11	—	5½	3½	—	1¾	½	¾	½	⅜
24	F.	13	Right	8	7	Yes	2½	¼	1½	¼	¼
25	M.	15	Right	9	6	Yes	4½	2	1¾	x	x
26	M.	10½	Right	9	x	No	1½	½	⅛	¼	½
27	F.	18	Right	9	7	No	2¾	x	1	½	¼
28	M.	18	Right	11	10	Yes	2	½	1	⅝	x
29	F.	15	Left	11	7	Yes	3	¼	⅞	¼	⅜
30	F.	15	Right	11	5	Yes	1	¼	¼	½	¼
31	F.	15	Right	11½	9½	Yes	3	¾	¾	½	½
32	F.	16	Left	14	1	No	1½	¾	¾	⅛	½
33	F.	21	Left	17	6	Yes	5½	2½	2½	¾	¼
Average		15	—	11	6	—	2¾	⅞	1	½	⅜

— Measurements equal. x Measurements not taken.

Measurements of the femur from the apex of the great trochanter to the knee-joint. Patella measured transversely. The cases are grouped according to the duration of disease and the averages are given separately for each group.

Taylor measured also 10 cases of unilateral poliomyelitis, in patients of an average age of thirteen years, with an average duration of disability of ten years. The average shortening in these cases was $1\frac{3}{4}$ inches, and in no case was it greater than $2\frac{1}{2}$ inches. It will be noted that the retardation of growth in this group corresponds closely with that of the third group of cases of hip disease, in which the disability was of about the same duration. Taylor concludes that the retardation

of growth from unilateral hip disease in childhood is dependent in great degree upon the duration of the disability and upon the corresponding restraint of function.

Actual Lengthening.—Lengthening of the limb is occasionally observed during the active stage of the disease, caused, it may be inferred, by granulations within the acetabulum that press the femur outward and downward. Actual lengthening of the femur is uncommon, but it does occur, induced, it may be, by stimulation of the growth of the epiphysis of the head; but the most extreme instances are those in which the upper portion of the shaft of the femur is involved, the lengthening being the effect of an irritative hypertrophy. This is more commonly the result of extra-articular disease.

General Symptoms of the Disease.—Debility.—If the disease is sufficiently painful to cause loss of sleep and to affect the appetite, pallor and loss of flesh and strength may be expected. It must be borne in mind, however, that the patient may have been in poor condition long before the local tuberculous disease was acquired. At all events, from the diagnostic stand-point at least, the local disease has no characteristic influence upon the general condition, and the appearance of perfect health is not at all unusual among patients with hip disease.

Fever.—It is probable that a slight elevation of temperature might be detected in a large proportion of the patients, and in such cases actual appreciable fever often follows overexertion of injury. Fever, as a symptom of infected abscess in the later course of the disease, is, of course, of importance, but in the early stages of the disease the record of the temperature would be of but little diagnostic value.

History and Method of Examination.—In considering the differential diagnosis of tuberculous disease of the hip-joint one should keep its characteristics in mind. It is a chronic disease, in that the symptoms have usually persisted for weeks or months before the patient is brought for treatment. It is essentially a monarticular disease, thus differing from rheumatism and similar affections in which several joints are involved. It does not get well; thus it may be differentiated from injury and from the minor affections that simulate some of its symptoms. It causes a limp. It is accompanied by reflex muscular spasm, usually by a certain degree of deformity and by general atrophy of the muscles of the limb.

The importance of the inheritance and of the personal history of the patient has been mentioned already in the consideration of Pott's disease. In recording the history in this as in all other chronic diseases of childhood one attempts to ascertain the approximate duration of the pathological process rather than the duration of the more acute symptoms for which the patient has been brought for treatment. One asks, therefore, when the child was last perfectly well, and, bearing in mind the remission of symptoms, one asks if limp or pain had been noticed at any time before the more acute symptoms. In the history there is almost invariably mention of a fall, and one must ascertain whether the fall had any influence in the causation of the symptoms, remembering that the weakness and interference with function due to joint disease more often cause falls than falls cause joint disease.

Physical Examination.—One begins the physical examination by the observation of the general condition of the patient, and notes the attitudes and the character of the limp. The patient's clothing is then entirely removed, that one may observe the contour of the part and the general influence of the affection upon the mechanism of the body. The patient is then placed on his back upon a table, with the limbs parallel to one another, so that length and size may be compared. If the pelvis is level when the limbs are parallel, there can be no persistent abduction or adduction, for when the two anterior-superior spines are on the same plane such distortion is always evident. If the lumbar spine and the popliteal surfaces of the knees rest on the table simultaneously it shows, too, that persistent flexion is absent. One next tests the function of the hip-joints, always beginning with the sound side for the purpose of comparison, and in order that the patient may become accustomed to the manipulation before the one suspected of disease is tested. Disease within a joint is accompanied by muscular spasm that limits motion in every direction, thus differing from other affections outside the joint that may limit its motion in one or more but not in all directions.

One compares the flexion, abduction, adduction, and rotation of the limbs while the child lies upon its back; it is then turned upon its face to test for extension by holding the pelvis flat upon the table with one hand while the thigh is gently elevated with the other (Fig. 16). The normal range of extension in childhood is about 20 degrees backward from the line of the body, and limitation of this range is the earliest indication of the deformity of hip disease. It may precede the restriction of the extremes of motion in other directions, although this is unusual, and if this motion is unrestricted disease of the joint may be, practically speaking, excluded. The character of the reflex spasm that limits motion and the indications of discomfort when the limit has been reached have been described.

Measurements.—The measurements of the limbs are then made. One first ascertains the actual length of the limbs by measuring from the anterior-superior spines of the pelvis to the extremities of the internal malleoli, actual shortening being, of course, absent in the early stage of the disease. The second measurement is from the umbilicus to show the amount of apparent shortening or lengthening that may be present if the limb is distorted. The actual length of the limbs, as measured from the anterior-superior spines, is but slightly affected by tilting of the pelvis, but as the umbilicus is in the middle line of the body above the pelvis measurement from this point simply shows the actual distance to the malleoli. Persistent adduction causes compensatory obliquity of the pelvis; consequently the malleolus on the affected side is drawn upward or nearer to the umbilicus, while the other is carried downward to a corresponding distance (Fig. 292). If, then, the measurements from the umbilicus to the malleoli do not correspond relatively with those from the anterior-superior spines, when the limbs are parallel and in the median line, it shows distortion; adduction, if the limb is relatively shorter, abduction, if it is relatively longer than is shown by the measurement from the anterior-superior

spine. It has been stated that the measurement from the anterior-superior spine is not greatly changed by distortion. It is, however, shortened by abduction, and it is in less degree lengthened by adduction. This is explained as follows: When the limb is in the line of the body the trochanter is below the anterior-superior spine from which the measurement is made. Abduction of the limb raises the trochanter toward the plane of the anterior-superior spine, and consequently lessens the distance from this point to the extremity of the limb. Adduction, on the contrary, lowers the trochanter and increases the distance between these two points. Ordinarily, the variation from this source is slight. But in an adult the average difference between the greatest shortening in the distance from the anterior-superior spine and the internal malleolus caused by abduction and the greatest lengthening by adduction is about 2 inches. Therefore, if the distortion is considerable, the error must be corrected by placing the sound limb in the same attitude in which its fellow is fixed. The measurements will then be relatively, though not absolutely, accurate. Flexion of one thigh causes a tilting forward of the pelvis that lessens the distance between the anterior-superior spine and the malleolus on both sides, although not to an equal degree. It is customary, therefore, if the flexion is considerable, to raise the unaffected limb to the line of its fellow in making the comparative measurements, stating in the record that the limbs have been measured at the angle of the deformity and are therefore shortened.

In this connection it may be noted that a slight difference in the length of the limbs is not uncommon (78 per cent. of 128 observations), usually in favor of the right side, the variation being one-fourth to one-half inch.[1]

Method of Estimating the Degree of Distortion of the Limb.—As has been stated, when the pelvis is level, distortion of the limb is apparent, and the degree of distortion can be measured by the goniometer (Fig. 294). It may be estimated also by "Lovett's table."[2] This method is described by its author as follows:

Table for Estimating the Degree of Lateral Distortion. Distance between Anterior-superior Spines in Inches.

Difference in inches between real and apparent shortening.	3	3½	4	4½	5	5½	6	6½	7	7½	8	8½	9	9½	10	11	12	13
¼	5°	4°	4°	3°	3°	2°	2°	2°	2°	2°	2°	2°	2°	1°	1°	1°	1°	1°
½	10	8	7	6	5	5	4	4	4	4	4	4	4	3	3	3	3	2
¾	14	12	11	10	8	8	7	7	6	6	5	5	5	4	4	4	3	3
1	19	17	14	13	11	10	9	9	8	7	7	7	6	6	6	5	5	4
1¼	25	21	18	16	14	13	12	11	10	9	9	8	8	7	7	7	6	6
1½	30	25	22	19	17	15	14	13	12	12	11	10	10	9	9	8	7	7
1¾	36	30	26	23	20	18	17	15	14	13	13	12	11	10	10	9	8	8
2	42	35	30	26	23	21	19	18	16	15	14	14	13	12	13	10	10	9
2¼	..	40	34	30	26	24	21	20	19	17	16	15	14	14	13	12	11	10
2½	..	..	39	34	29	27	24	22	21	19	18	17	16	15	14	13	12	11
2¾	..	..	..	38	32	29	27	25	23	21	20	19	18	17	16	14	13	12
3	..	..	..	42	35	32	29	27	25	23	22	21	19	18	18	16	14	12
3¼	..	..	..	..	39	36	32	30	27	26	25	22	21	20	19	17	15	14
3½	..	..	..	..	..	40	35	33	30	28	26	24	23	22	21	19	17	16
3¾	..	..	..	..	..	..	38	35	32	30	28	26	25	23	22	20	18	17
4	..	..	..	..	..	..	42	38	35	32	30	28	26	25	23	21	19	18

[1] Bristow: Ann. Surg., July, 1909.

[2] R. W. Lovett: Boston Med. and Surg. Jour., March 8, 1888.

"To measure by this method the patient is made to lie straight with the legs parallel. Real shortening is measured with the ordinary tape-measure, and apparent shortening is obtained in the same way. It may be repeated that real or bony shortening is measured from the anterior-superior iliac spines to each malleolus, and that practical shortening is found by a measurement taken from the umbilicus to each malleolus. The difference in inches between the two kinds of shortening is seen at a glance. The only additional measurement necessary is the distance between the anterior-superior spines, which is taken with the tape. Turning now to the table: if the line which represents the amount of difference in inches between the real and apparent shortening is followed until it intersects the line which represents the pelvic breadth, the angle of deformity will be found in degrees where they meet. *If the practical shortening is greater than the real shortening, the diseased leg is adducted; if less than real shortening, it is abducted.* Take an example: Length (from anterior-superior spine) of right leg, 23; left leg, $22\frac{1}{2}$; length (from umbilicus) of right leg, 25; left leg, 23;

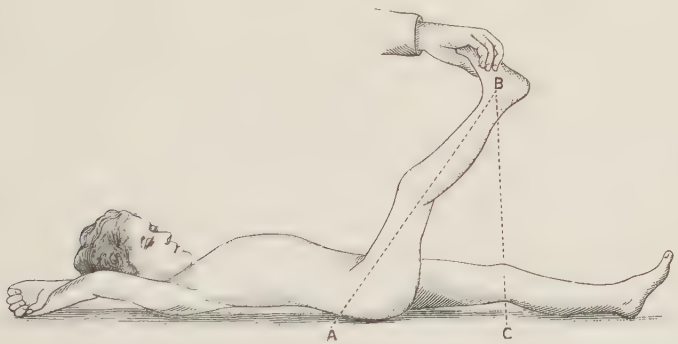

FIG. 303.—Kingsley's method of estimating flexion.

real shortening, $\frac{1}{2}$ inch; apparent shortening, 2 inches; difference between real and practical shortening, $1\frac{1}{2}$ inches; pelvic measurement, 7 inches. If we follow the line for $1\frac{1}{2}$ inches until it intersects the line for pelvic breadth of 7 inches, we find 12 degrees to be the angular deformity; as the practical shortening is greater than the real, it is 12 degrees of adduction of the left leg. If apparent lengthening is present its amount should be added to the amount of actual shortening."

If flexion is present the degree may be ascertained by raising the flexed limb until the lumbar spine touches the table, when the angle formed by the thigh with the body may be measured with the goniometer (Fig. 261) or its degree may be ascertained by Kingsley's table:

"The patient lies upon a table flat on his back and the surgeon flexes the diseased leg, raising it by the foot until the lumbar vertebræ touch the table, showing that the pelvis is in the correct position. The leg is then held for a minute at that angle, the knee being extended, while the surgeon measures off 2 feet on the outside of the leg with a tape measure, one end of which is held on the table, so that

the tape-measure follows the line of the leg (*A–B*). From this point on the leg (*B*) where the 2 feet reach by the tape-measure, one measures perpendicularly to the table (*B–C*), and the number of inches in the line *B C* can be read as degrees of flexion of the thigh by consulting the Table. For instance, if the distance between the point on the leg and the table is $12\frac{1}{2}$ inches it represents 31 degrees of flexion deformity of the thigh.

TABLE FOR ESTIMATING THE DEGREE OF FLEXION. (KINGSLEY.[1])

0.5 inches.		1°	6.5 inches.		16°	12.5 inches.		31°	18.5 inches.		50°
1.0	"	2	7.0	"	17	13.0	"	33	19.0	"	52
1.5	"	3	7.5	"	19	13.5	"	34	19.5	"	54
2.0	"	4	8.0	"	20	14.0	"	36	20.0	"	56
2.5	"	6	8.5	"	21	14.5	"	37	20.5	"	58
3.0	"	7	9.0	"	22	15.0	"	39	21.0	"	60
3.5	"	9	9.5	"	24	15.5	"	40	21.5	"	63
4.0	"	10	10.0	"	25	16.0	"	42	22.0	"	67
4.5	"	11	10.5	"	27	16.5	"	43	22.5	"	70
5.0	"	12	11.0	"	28	17.0	"	45	23.0	"	75
5.5	"	14	11.5	"	29	17.5	"	47	23.5	"	80
6.0	"	15	12.0	"	30	18.0	"	48	24.0	"	90

"If the leg is so short it is impracticable to measure off 24 inches, one can measure 12 inches; ascertain from here the distance to the surface on which the patient is lying in a perpendicular line in the same way, then doubling this distance, and looking in the Table as before the amount of flexion is found."

ATROPHY.—The circumference of the thighs, the knees, and the calves is then measured at corresponding points to test for atrophy or for other irregularities that may require explanation. The atrophy of joint disease affects the entire limb, and it is an unfailing symptom except in the earliest stage of the disease. It might be concealed in the thigh by a deep abscess, but it would still appear in the calf.

Local Signs of Disease.—The hip-joint is so concealed by the overlying tissues that the local sensitiveness and swelling which usually accompany similar disease at the knee and ankle are often absent. Firm pressure before or behind the trochanter, or over the head of the femur, usually causes some discomfort, however. In many instances a peculiar resistance of the deeper parts, caused by infiltration of the tissues that cover the joint, is evident on palpation; and swelling about the joint and thigh, caused by effusion or by deep abscess, is not unusual when patients are first brought for treatment. Sensitiveness of the skin and local elevation of the temperature may be present if the disease is acute, particularly if an abscess is on the point of breaking through the skin.

Diagnosis.—The diagnosis of tuberculous disease of the hip, except, perhaps, in the stage of inception, is not difficult, and errors are due rather to neglect of a systematic examination than to any particular obscurity that the ordinary case may offer.

Local Irritation.—Strain of the muscles of the thigh, enlarged glands in the groin, irritation or disease of the genitals may, in infancy or early childhood, cause persistent flexion of the thigh and pain on

[1] G. L. Kingsley: Boston Med. and Surg. Jour., July 5, 1888.

attempted correction. Simple muscular strains quickly recover, while the inflamed glands and other causes of local irritation are usually apparent on inspection.

"Growing Pains."—So-called growing pain is probably due in many instances to strain or overuse and disappears on rest.

Local Injury.—It would appear that injury, often of a trivial character, may cause congestion in the neighborhood of the epiphyseal cartilage of the head of the femur and that injury of this character in delicate children may be a predisposing cause of tuberculous disease. Such a sensitive condition causes a limp, pain, or discomfort on overuse and restriction of motion. These symptoms may last a few days or a few weeks; they may disappear and recur from time to time, and they can only be distinguished from those of incipient disease by continued observation. (See also Fracture of the Neck of the Femur and Epiphyseal Displacement.)

Perthes' Disease.—This resembles incipient hip disease so closely that the diagnosis can be made only on roentgen-ray examination. It is described elsewhere.

Synovitis.—In certain cases of injury synovial effusion may be present, although this is unusual.

In the cases in which the functional disturbance is caused by local irritation or by slight strain the symptoms are of sudden onset and are evidently of trivial importance, but if there is any doubt as to the diagnosis the hip should be bandaged and the patient should remain in bed or at rest until the complete subsidence of the symptoms or their persistence makes the diagnosis clear.

Anterior Poliomyelitis.—Occasionally anterior poliomyelitis may be accompanied by pain on motion in the affected limb before paralysis is apparent, but in a few days at most the diagnosis is evident.

Rheumatism.—"Rheumatism," a term popularly used to include all forms of subacute arthritis induced by infection, or by defective metabolism, "toxic arthritis," is usually of sudden onset. It is almost always migratory in character and it is accompanied by fever. If it were confined to a single joint, as occasionally in young children, and if the history were obscure, the diagnosis might be uncertain for a time. In such cases appropriate remedies should be employed with the local treatment.

It may be noted that the so-called growing pain of rheumatism is more often in the muscles of the thigh or calf or hamstring tendons than in a joint, and is often accompanied by sensitiveness to pressure, indicating a mild type of myositis.

Scurvy.—This is also an affection whose symptoms are general in character. It is therefore more likely to be confounded with rheumatism than with a local disease. In rare instances one joint only appears to be involved, but this is, as a rule, the knee rather than the hip. Pain on motion of the limbs, in an infant artificially fed, always suggests scurvy.

Infectious Arthritis and Epiphysitis.—Mild forms of infectious arthritis may follow scarlatina, diphtheria, pneumonia, and, in a more severe

and destructive form, typhoid fever. As a rule, however, several joints are involved, and, although the affection might be mistaken for rheumatism, it could hardly be confounded with local tuberculous disease.

Infectious arthritis or epiphysitis of the hip-joint is not uncommon in early infancy. It is of sudden onset, accompanied by high fever and by constitutional disturbance. These symptoms, together with the local heat and swelling, caused by the rapid formation of pus, show the character of the affection and indicate the necessity for prompt surgical intervention.

Gonorrheal arthritis is a form of joint infection that in adult age may resemble somewhat the subacute form of tuberculous disease. As a rule, however, it is of sudden onset and is evidently associated with the local disease.

Extra-articular Disease.—Disease in the neighborhood of the joint as of the trochanter or of the tuberosity of the ischium, may cause a limp and pain; in most instances the local sensitiveness and local swelling indicate the seat of the disease, while motion of the joint is limited only in the directions that cause tension on the sensitive parts.

Arthritis Deformans of the Hip.—This affection when confined to the hip-joint may be mistaken for tuberculous disease, and at times the diagnosis may be obscure. It is, however, essentially a disease of adult life, and it is in most instances accompanied by other evidences of a general disease.

Chronic Polyarthritis. — This affection in childhood may begin in a single joint. The pain may be severe, and there may be spasm and distortion of the limb. The diagnosis is usually made clear by the successive involvement of other joints.

Pott's Disease.—Disease of the lumbar region of the spine before the stage of deformity, when the pain is referred to the lower extremities, and in which unilateral psoas contraction causes a limp, is often mistaken for hip disease, although the distinction between them is very clear. Psoas contraction limits extension only; all the other movements of the limb are unrestrained. The muscular spasm, of which the psoas contraction is a part, is a spasm of the muscles of the spine about the seat of disease, as is evident on examination. Other causes of psoas contraction have been mentioned in the consideration of Pott's disease. In exceptional cases active disease of the lower region of the spine in young children may set up spasm of the muscles about the hip, and *vice versa*, so that it may be impossible to decide at the first examination whether the irritation is in the hip or in the spine or in both.

Sacro-iliac Disease.—Disease of the sacro-iliac junction is very uncommon in childhood. The symptoms and the attitude resemble sciatica rather than hip disease. There is local pain at the seat of disease upon lateral pressure on the pelvis, and if the pelvis be fixed the motion at the hip-joint will be found to be practically free and painless.

Pelvic Disease.—Localized disease of one of the pelvic bones may cause discomfort and a limp. The cause of the symptoms is usually explained by the appearance of an abscess.

BOSTON CITY

Disease of the Bursæ about the Joint.—Inflammation of the bursæ about the hip may cause local swelling and sensitiveness, a limp and limitation of motion in certain directions, but the characteristic muscular spasm of hip disease is absent. Iliopsoas bursitis forms a fluctuating swelling in Scarpa's space, gluteal bursitis a localized swelling of the buttock.

Coxa Vara.—Depression of the neck of the femur is a simple deformity. It causes a limp and more or less discomfort, but the character of the deformity, shown by the actual shortening and by the elevation and prominence of the trochanter, distinguishes it from hip disease, in which these are late symptoms. In coxa vara there is unequal limitation of motion, abduction, flexion, and inward rotation being somewhat restricted, while extension and adduction, the first movements limited in hip disease are, as a rule, not.

Fracture of the Neck of the Femur in Childhood or Traumatic Coxa Vara.—Fracture of the neck of the femur in childhood is often of what may be termed the green-stick variety, a depression of the neck of the femur without actual separation of the fragments; and in many instances the patients are able to walk about within a short time after the accident. In such cases the limp and discomfort, attended during the stage of repair by a certain degree of muscular spasm, are often mistaken for the symptoms of disease. The history of the accident followed by immediate disability, the shortening and the elevation of the trochanter are usually sufficient to exclude disease. In doubtful cases the roentgen-rays may be required to establish the diagnosis.

Epiphyseal Fracture.—Epiphyseal fracture or displacement is more common in adolescence. It may be induced by slight injury, and if the displacement is not complete the patient is often able to use the limb. A more detailed description of injuries of this class may be found elsewhere.

Congenital Dislocation of the Hip.—Congenital dislocation of the hip causes a limp, but it is a limp that has existed since the child began to walk and that is unaccompanied by the symptoms of disease. The nature of the disability should be apparent on examination.

Hysterical Joint.—In hysterical subjects a limp, apparent pain, and distortion of the limb, often following slight injury, may simulate disease. Hysteria is very uncommon at the period of life in which tuberculous disease is most frequent. Patients of this class usually present other symptoms of hysteria; the characteristic signs of disease, muscular spasm and atrophy, are absent, while the apparent discomfort and the voluntary distortion are quite out of proportion to the physical evidences of injury or disease.

The Roentgen-rays in Diagnosis.—Roentgen pictures are of far more value in demonstrating deformity than in establishing early diagnosis of disease, especially of the hip in early childhood, when so large a part of the extremity of the femur is cartilaginous; the only constant indications of disease being atrophy of the shaft of the femur and a blurred outline, "fogginess," of the parts actually involved. The pictures are of value, however, in showing the destructive effect of

the disease on the head of the femur or acetabulum, and thus giving one a clearer conception of the actual condition of the joint than would be possible otherwise (Fig. 301). In older subjects it may be possible to demonstrate the presence of disease in the interior of the bone by this means, but in any event roentgen-ray pictures are of value only when interpreted by knowledge of the physical signs.

Method of Recording a Case.—The record should contain the general history of the patient together with an account of the more important symptoms, and of the treatment that may have been employed. The physical examination should include the weight and height for comparison with the normal standard, and as a basis on which to judge the future progress of the case. Then follows a brief description of the gait and attitude, of the character of the distortion, if it be present, and of the changes from the normal contour. If restriction of motion is present, its causes are stated if possible; whether, for example, it is due to simple muscular spasm or in part to adhesions and contractions.

The presence or absence of heat and swelling, of abscesses, sinuses and the like is indicated. If there is actual shortening of the limb its causes and distribution should be stated; whether it is the result of simple retardation of growth or of elevation of the trochanter, as may be ascertained by Nélaton's line and by Bryant's triangle.

If the elevation is due in great part to the enlargement of the acetabulum, while the upper extremity of the femur remains fairly normal in shape, the projection of the trochanter is more noticeable, and the distortion of the limb in adduction is greater than when the elevation is the result of destruction of the head of the bone. In this class of cases roentgen-ray pictures are of service in showing the actual condition of the joint (Fig. 300).

A condensed account of the more important points in the physical examination may be presented by the formula used at the Hospital for Ruptured and Crippled, as follows: R.A.—R.U.—R.T.—R.K.—R.C.—A.G.E.—A.G.F.—A.S.P.—L.A.—L.U.—L.T.—L.K.—L.C.

"A" indicates the distance from the anterior-superior spines to the internal malleoli.

"U," from the umbilicus to the same points.

"T," "K," and "C," the circumferences of the limb at the thighs, knees, and calves.

"A.G.E." indicates the angle of greatest extension.

"A.G.F.," the angle of greatest flexion. Thus the restriction of the range of anterior-posterior motion at the hip is shown by these measurements.

"A.S.P." is the transverse diameter of the pelvis between the anterior-superior spines, the measurement required in Lovett's table for ascertaining the degree of lateral distortion.

If, for example, the record reads:

R.A. 18½—R.U. 20 —R.T. 11 —R.K. 8¾—R.C. 7¾—A.G.E. 150—A.S.P. 7
L.A. 18½—L.U. 21¼—L.T. 10¼—L.K. 8¼—L.C. 7¼—A.G.F. 90

it would show at a glance that there was no real shortening, that the limb was abducted because of the one and a quarter inches of apparent

lengthening, according to the table, the equivalent of 10 degrees of abduction. It would show that there was permanent flexion of 30 degrees and a range of motion between the limits of flexion and extension of 60 degrees, as compared with the normal of about 130 degrees.

The following details of the 1000 cases of hip disease will illustrate the character of the cases treated at the Hospital for Ruptured and Crippled:

THE DURATION OF DISEASE WHEN TREATMENT WAS BEGUN.

Three months or less	396	Four years	21
Three to six months	170	Five years	17
One year	124	From five to ten years	35
Two years	75	From ten to forty years	16
Three years	29	Not stated	37
			920

THE DEGREE OF DEFORMITY PRESENT ON FIRST EXAMINATION.

No deformity	130	55 degrees of flexion	10
5 degrees of flexion	44	60 degrees of flexion	26
10 degrees of flexion	89	65 degrees of flexion	8
15 degrees of flexion	69	70 degrees of flexion	22
20 degrees of flexion	118	75 degrees of flexion	2
25 degrees of flexion	32	80 degrees of flexion	11
30 degrees of flexion	135	85 degrees of flexion	1
35 degrees of flexion	56	90 degrees of flexion	12
40 degrees of flexion	70	More than 90	1
45 degrees of flexion	41	Not stated	55
50 degrees of flexion	68		1000

RESTRICTION OF MOTION AT FIRST EXAMINATION.

Normal motion	30
A range of motion through 105 degrees	14
A range of motion through 90 degrees	65
A range of motion through 75 degrees	49
A range of motion through 60 degrees	95
A range of motion through 45 degrees	67
A range of motion through 30 degrees	112
A range of motion through 15 degrees	95
A range of motion through 5 degrees	157
No motion	147
Not stated	169
	1000

ATTITUDE OF THE LIMB AT FIRST EXAMINATION.

Flexion to a greater or less degree	814
No flexion	130
Not stated	56
	1000

OTHER DISTORTIONS RECORDED.

Abduction	254
Adduction	167
External rotation	166
Internal rotation	58

ACTUAL SHORTENING WHEN TREATMENT WAS BEGUN.

¼ inch	129	2¼ inches	5
½ inch	143	2½ inches	5
¾ inch	22	2¾ inches	2
1 inch	51	3 inches	2
1¼ inches	9	3¼ inches	2
1½ inches	16	3½ inches	2
1¾ inches	6	9½ inches	1
2 inches	21		416

Shortening absent or not stated in	584
Abscess not present in	105

Treatment.—The principles that should govern the treatment of a disease are best indicated by the study of cases that have received no treatment, and that present, therefore, the natural history of the affection.

A characteristic case of tuberculous disease of the hip-joint begins insidiously. It causes a slight limp and at times discomfort and pain. At first there is slight flexion of the limb, usually combined with abduction, the instinctive assumption of the attitude of rest. As the disease progresses the limb becomes less capable of performing its proper function; the range of motion becomes more and more restricted, and the attitude changes to one of increased flexion and adduction, the attitude in which the limb is best protected from injury because it is least capable of function. Pain is more constant, abscess is often present, and the constitutional effects of a depressing disease may be apparent. This progression of symptoms and attitudes is so fairly constant that hip disease was formerly divided into stages corresponding to these early and later manifestations of its effects. When the limb has reached the position of greatest protection, when motion which at first was limited only by the involuntary spasm of the muscles that are now atrophied, is restricted by adhesions and contractions, pain often ceases, the general health improves, and effective repair begins. During the progressive stage erosion of the opposing surfaces of the joint has advanced, always more rapidly at the points of mutual pressure and friction, the upper and inner surface of the head of the femur and the upper margin of the acetabulum, and here the disease remains active while repair progresses at the points which have been relieved from irritation. Thus in many instances the upper margin of the acetabulum is destroyed and a subluxation of the femur takes place (Fig. 289), a displacement favored by the attitude of flexion and adduction, and induced by muscular spasm and by pressure upon the limb. In some instances there is complete displacement, and when the diseased parts are thus separated from one another by this form of pathological dislocation relief of symptoms and practical recovery may quickly follow, although sinuses leading to areas of local disease or to fragments of necrosed bone may persist for many years.

Nature's cure of hip disease implies recovery with a shortened and distorted limb, a final result which is common enough even when treatment has been employed to explain the popular conception of what hip disease entails (Fig. 300).

As has been stated, it was customary in former years, when treatment was neglected or was less efficient than at the present time, to speak of a first, second, and third stage of hip disease, corresponding to the character of the deformity, but early or later stage as used by the writer refers to the inception and progression of the local pathological process, not to the distortion of the limb.

There are cases of hip disease in which the primary focus in the head of the bone is so limited in extent that perfect functional cure may result under any form of treatment, or even non-treatment. And

there are others in which the disease is of such a destructive character that the result must be disastrous in spite of treatment. But there can be no doubt that by early diagnosis and by efficient protection prolonged suffering may be prevented, that useful function may be preserved, which would otherwise have been lost.

The object of treatment is to prevent the symptoms and the effects of the disease that have been outlined as characteristic of the untreated cases. To relieve the pain that depresses the vitality of the patient. To relieve the muscular spasm that induces distortion of the limb, and that stimulates the activity of the destructive process by increasing the pressure and friction of the diseased surfaces of the opposing bones. To correct and to prevent deformity and to prevent, as far as may be by lessening the pressure and by restraining motion, the upward displacement of the femur that causes irremediable distortion.

There are cases in which radical removal of the diseased parts may be indicated, and there are times when acute symptoms may require absolute rest of the patient. But in the management of a chronic tuberculous disease, throughout the period of years that must elapse before cure is accomplished, the primary requirements of the treatment that have been indicated must be met, as far as may be, by appliances that permit exercise in the open air.

Mechanical Treatment.—Effective treatment of a diseased joint should assure adequate rest and protection. If the disease is in the earliest stage and confined to the interior of the bone, rest offers the most favorable condition for repair and for preservation of the joint. If the disease is further advanced, it affords an opportunity for Nature to check its progress and to preserve, it may be, a part of the joint from invasion. If the joint is already involved, rest offers the best opportunity for repair by preventing friction that stimulates the progress of the disease and increases its destructive effects. Whatever checks or retards the progress of the disease relieves its symptoms and thus preserves the vital resistance, both local and general, upon which the cure of the disease ultimately depends. Complete rest of a diseased joint of the lower extremity necessitates in order of importance, splinting, stilting and traction.

Splinting naturally signifies the fixation that may be attained by the application of a splint, extending a sufficient distance on either side of the part to be fixed.

Stilting—the elevation of the foot from the ground so that jar and pressure on the diseased articulation may be removed.

Traction—a sufficient force exerted upon the limb to overcome and to control the spasmodic action of the muscles.

The knee-joint, the junction of two levers of similar size and function may be easily fixed by apparatus. But the hip-joint is a ball-and-socket joint which permits free motion, and, being the junction of the trunk and the limb, two segments of different size and function, it is especially difficult to control. For this reason as much as any other, perhaps the mechanical treatment of hip disease has been the

subject of controversy for many years. And even at the present time one can hardly describe it adequately without contrasting the methods of treatment that are in common use.

Such an exposition should begin naturally with a description of what has long been known as the American treatment, in which traction has always occupied the most important place. For although many of the claims originally made for it have been abandoned, and although it is no longer a routine of orthopaedic clinics, it best illustrates certain preliminary and supplementary details of the treatment that are of value in other forms of disease or injury.

The Traction Hip Splint.—The traction hip splint consists of a pelvic band and an upright. The pelvic band is made of sheet steel about an eighth of an inch in thickness and one and one-eighth inches in width, sufficiently strong to support the weight of the body without yielding, bent into a U-shape to conform to the pelvis, but wide enough to cause no anterior-posterior pressure. As Taylor puts it, there should be room enough for the pelvis to move freely in it. This band embraces about three-quarters of the pelvis at a point just above the trochanter. It is covered with leather and is provided with a strap to complete the circumference. Upon the pelvic band four buckles are placed for the attachment of the perineal bands. The two buckles on the front band are placed directly above the attachments of the adductor muscles, on either side of the genitals. Behind, the buckles are placed much farther apart, somewhat to the outer side of each ischial tuberosity, upon which in great part, the weight of the body is to be supported. The pelvic band is bolted firmly to the upright at a slight inclination, corresponding to the inclination of the pelvis. The upright extends from the top of the trochanter to two or more inches below the sole of the foot. It may be made in one piece or in two sections overlapped and attached to one another by screws to allow for adjustment (Fig. 305). It is turned inward at a right angle below the foot and is shod with leather or rubber. The foot-piece may be provided with a windlass (Fig. 305), or the traction may be made by simple straps attached on either side (Fig. 310). At about the middle of the upright is placed a support of light steel, which is provided with a broad leather strap for the purpose of fixing the thigh to the brace and supporting the knee. In some braces a second similar support is placed at the upper part of the stem; in others the knee is supported only by a broad leather pad which covers its inner surface and is attached to a cross-piece on the upright by straps, as in the Taylor brace. In the Taylor brace, which has served as a model for all similar appliances, the upright is a steel tube into which slides a rod, supporting the foot part of the brace, the two parts being joined with a rack-and-pinion attachment and lock, so that the brace may be lengthened or shortened by means of a key (Fig. 309).

Traction Plasters.—Traction upon the limb is made by adhesive plaster, preferably that known as moleskin (yellow) plaster, which is far less irritating to the skin than rubber plaster.

These plasters should be cut to correspond to the lateral aspect of the thigh and leg, thus: wide above and narrow below, reaching from the trochanter on the outer, and from the pubes on the inner side, to the malleoli (Fig. 320). The lower ends are reinforced by a second layer of plaster and to them buckles are attached. The plasters are then applied to the limb and are held in place by a bandage which is smoothly applied and then sewed, to prevent disarrangement. The object of the bandage is primarily to assure the adhesion of the plaster and secondarily to keep it clean. It can be replaced by a properly fitted covering of stockinette or by a stocking leg.

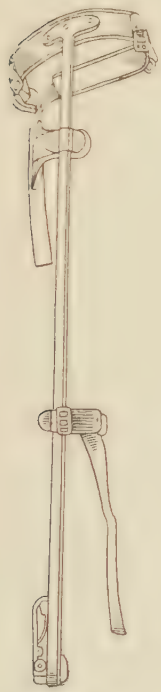

FIG. 304

FIG. 305

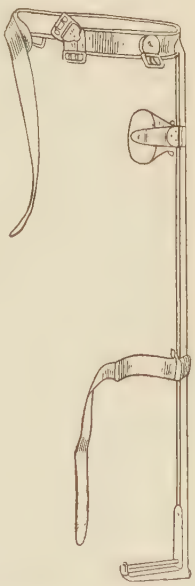

FIG. 306

FIGS. 304, 305 and 306.—The traction hip splint, with overlapping upright and windlass, used at the Boston Children's Hospital. (Bradford and Lovett.)

Another method of applying the plaster, designed to obtain a better hold upon the limb, is that devised by Taylor, and described by him as follows: "The first important object is to seize the leg in such a manner as to exert against it an unyielding force. This should be done in such a manner as will not interfere with the circulation, nor injure the knee, by unequal strain either below or above it. In other words, the whole leg should be grasped in such a manner that the knee will be supported. It may be done as follows: A strip of adhesive plaster, long enough to reach from the waist to the foot, and from three to five inches wide at the upper and about one-third that width

at the lower end, is taken and cut into five tails, as shown in the accompanying illustration (Fig. 307). A piece from 4 to 6 inches long is cut from the center tail and added to the lower end to strengthen it; and, if the patient be strong, one or two more pieces are laid on the same place, where a buckle is attached. Two similar straps are prepared, one for the inside and one for the outside of the leg, and laid against the lateral aspects of the leg, the ends with the buckles beginning about 2 inches above the internal and external malleoli, and the center tails reaching the entire length of the leg and thigh, to the



Fig. 307

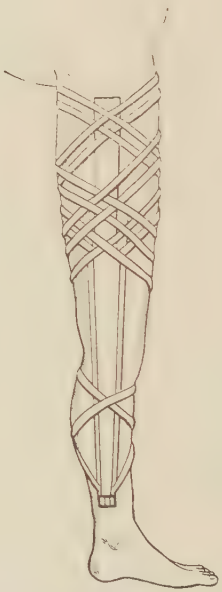

Fig. 308

Figs. 307 and 308.—C. F. Taylor's method of applying adhesive plaster.

perineum inside and the trochanter on the outside. The lower strips or tails are then wound spirally around the leg to the pelvis and afterward the other two pairs of tails, which are cut down to just above the knee, are also wound about the thigh in the same manner. When completed the thigh is involved in a network of strips of adhesive plaster, which act equally and without pressure on the whole surface. The leg has about one-fourth of the attachments, and the thigh three-fourths, which is found to be the right proportion to protect the knee equally from compression or strain. A few turns of the roller bandage

MEDICAL LIBRARY
BOSTON CITY HOSPITAL

are then made around the ankle just under the lower ends of the straps, which serves as a protection to the flesh under the buckles, and then it is continued over the straps on the whole leg. Thus prepared, the patient is ready for the splint."

At the Boston Children's Hospital the lower ends of the adhesive straps terminate in tapes that extend below the foot for attachment to the windlass, which is used with the cheaper form of brace.

Perineal Bands.—Perineal bands are made by covering a firm, wide, unyielding band of webbing with several folds of blanket or similar material and then binding it smoothly with canton flannel. These are made in different lengths and sizes, as may be required.

The "High Shoe."—The best and lightest material for raising the shoe worn on the sound foot to correspond with the brace is cork, and the ordinary thickness is $2\frac{1}{2}$ inches. A good and cheap substitute may be made of light wood provided with a leather sole, and in certain cases a patten of metal may be used.

The Application of the Traction Hip Splint.—The traction brace is applied in the following manner:

The patient lying upon his back, the pelvic band is first adjusted and is strapped about the body. The perineal supports are then drawn firmly into place so that pressure on the upright does not move the pelvic band from its proper position, just above the trochanter. The brace is then pushed upward against the resistance of the perineal bands, while the limb is at the same time drawn downward and is fixed by attaching the straps to the buckles at the ends of the adhesive plasters. If the brace is provided with a windlass or ratchet, further traction is applied to the point of tolerance by means of the key, care being taken in adjusting the brace that it does not project so far below the foot as to more than equal the extra length provided by the high shoe on the sound side. The knee band is then adjusted and in many instances a strap is placed about the ankle and the brace to assure greater security. The shoe is then put on, the leg clothing is drawn over the brace, and the patient is allowed to stand. If in walking the patient is inclined to tilt the foot downward and to bear the weight on the toe, a strap is attached to the middle of the foot-piece and fastened to a buckle on



FIG. 309.—The original traction hip brace provided with an abduction screw and a strap to regulate the inclination of the pelvic band on the upright.

the heel of the shoe with sufficient tension to hold the foot in the horizontal position.

By means of this brace the weight is borne entirely upon the perineal bands; thus the joint is relieved from pressure and from jar. The perineal bands should be accurately adjusted to pass upward in front, parallel to one another on either side of the genitals, in order to avoid pressure on the inner borders of the thighs; while behind they turn diagonally outward in order to pass over the tuberosities, which are best adapted for weight-bearing.

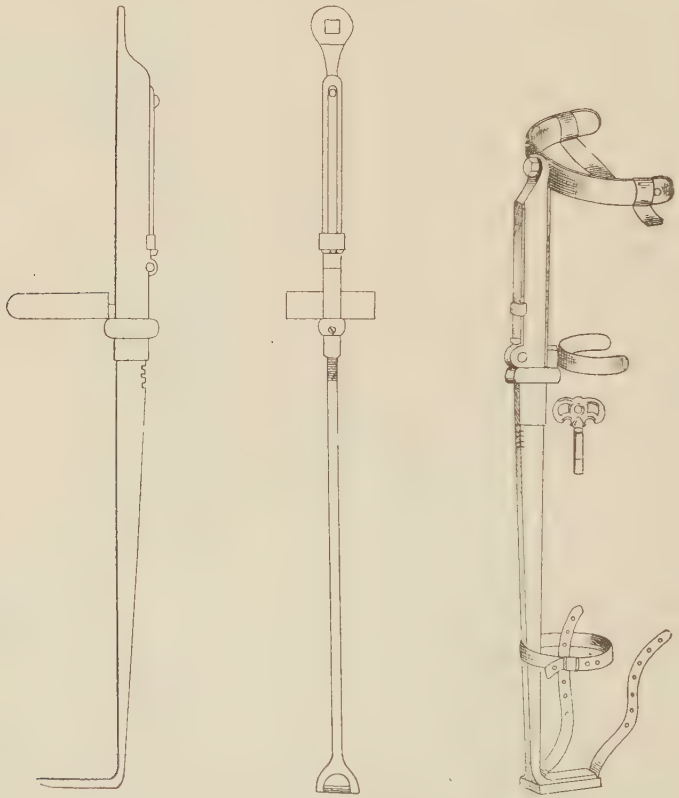

FIG. 310.—The Judson brace. This has but one perineal band, and the upright is bolted firmly to the pelvic band.

In the original Taylor hip brace the pelvic band was bolted to the upright in a manner to permit anterior-posterior motion, and the inclination of the pelvic band was regulated by a strap attached to the upright for better adjustment (Fig. 309), when the limb is flexed to a marked degree. This brace has been modified by Taylor by shortening and changing the shape of the pelvic band for the use of but one perineal support (Fig. 320); a similar form of brace is used by Judson. The shortened pelvic band lessens the restraint of the brace

upon the motion of the limb, and seems to offer little compensating advantage.

The Bradford brace is a modification of the Thomas knee splint with an attachment to prevent adduction. This provides a solid support for the perineum and better fixation of the joint.

Before the traction brace is used in ambulatory treatment, distortion of the limb, if it be present, should be reduced; or if the disease is particularly acute, preliminary rest in bed until the subsidence of the symptoms is advisable.

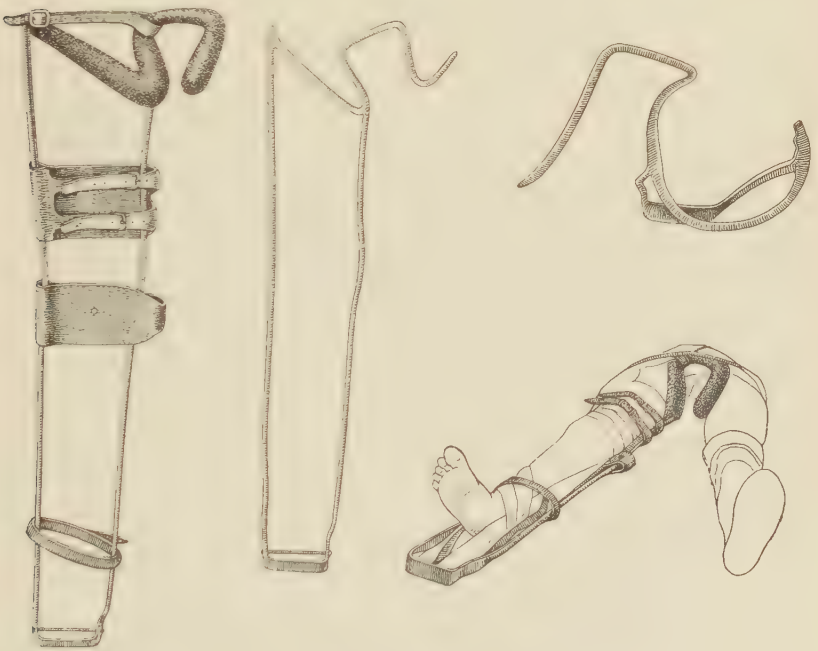

FIG. 311.—The Bradford abduction brace.

The Reduction of Deformity by Means of the Traction Brace.—The patient lies in bed upon a firm mattress; the distorted limb is then raised to slightly more than a sufficient angle, to relax the contracted muscles and to straighten the lumbar lordosis; it is then abducted or adducted if necessary until the level of the pelvis is restored. The pelvic band is made to conform to this greater relative inclination of the pelvis by lengthening the posterior strap; the brace is then applied, the limb behind held in the attitude of deformity by a sling or support (Fig. 312), and as much traction as the patient can tolerate is exerted by lengthening the upright. The direct traction exerted by the brace may be reinforced by means of a cord running over a pulley at the foot of the bed, in the line of the brace, to which a weight of ten or more pounds (Fig. 319) is attached. Thus the pressure of the perineal

bands is somewhat lessened. Efficient traction will quickly reduce recent deformity caused by muscular contraction, and as this is lessened the position of the limb is correspondingly changed until it lies extended and parallel with its fellow. If adduction is combined with flexion the perineal band on the side opposite to the disease is tightened from time to time, or a direct push against the opposite adductor region may be exerted by means of a bar attached to the brace opposite the knee (Fig. 349). In ordinary cases the deformity may be reduced by this means in from two to six weeks.

If, as in most instances, the brace is not at immediate command the deformity may be reduced by direct traction.

FIG. 312.—The reduction of flexion by means of the traction hip splint. (C. F. Taylor.)

Reduction of Deformity by the Weight and Pulley.—The traction plasters are applied to the limb in the manner already described, and the patient is placed on his back on a narrow, firm mattress. The limb is raised until the lumbar vertebræ rest upon the bed and it is then moved to one or the other side, if lateral distortion is present,

FIG. 313.—Traction acting improperly as leverage in hip disease: *P*, pulley; *W*, weight; *F*, fulcrum. (Howard Marsh.) (See Fig. 314.)

until the level of the pelvis is restored. In this position the limb is supported on a pillow, or better, on the adjustable triangle used with the traction hip splint (Fig. 313). A pulley is then attached to the foot of the bed in a prolongation of the line of the flexed limb. The wheel may be screwed to the top of a narrow board, which may be raised or lowered on the foot of the bed as required. To the buckles on the plaster traction straps a stirrup carrying the cord is attached. This stirrup is simply a spreader of thin wood or metal slightly wider than the foot, provided at either end with straps or tapes, its pur-

pose being to prevent direct pressure on the malleoli (Fig. 341). By means of a weight suspended at the foot of the bed traction is made upon the limb to the extent that the comfort of the patient will permit. As in Buck's system of traction, the foot of the bed may be raised to increase the friction of the body and thus to counteract the traction force, but in the treatment of children this is inefficient and counter-traction must be provided. A simple method is to attach two

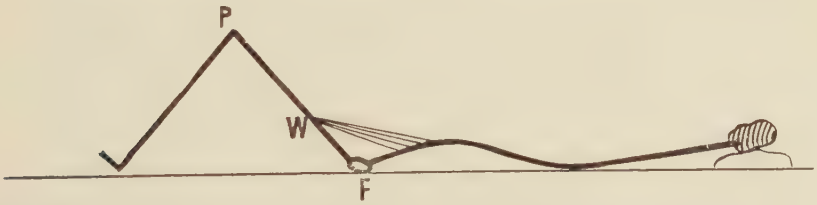

FIG. 314.—Posture of the limb in hip disease in which traction should be applied in order to avoid leverage. *P*, pulley; *W*, weight; *F*, fulcrum. (Howard Marsh.)

perineal bands, as described in connection with the traction brace, to strong tapes that pass above and below the patient's body, to be fixed to the head of the bed at a suitable distance from one another; thus the pelvis is supported by prolonged perineal bands.

In order to assure efficient and constant traction the patient must be prevented from sitting up. For this purpose a swathe about the body or shoulder straps may be applied and attached to the bed.

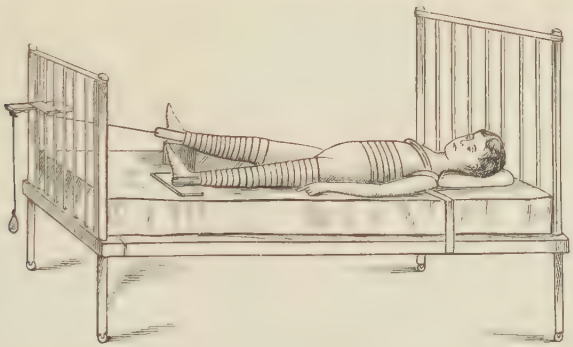

FIG. 315.—Traction in hip disease. Marsh's method of fixing the patient in bed with shoulder straps and a long T-splint on the sound side. (Howard Marsh.)

A convenient appliance is that of Marsh: "This consists of a piece of webbing, passing across the front of the chest and ending in two loops, through which the two arms are passed, and through which is threaded another piece of stout webbing which runs transversely across the surface of the bed under the child's shoulders, and is fastened at its two ends to the sides of the bedstead. When this is in action the patient's shoulders are kept flat on the bed, so that he can neither sit up nor turn on his side. This chest band does not cause the slightest

discomfort. It is not, of course, fixed tightly, and when the child finds that he cannot sit up he makes no further attempt to do so; and as he lies flat the band is loose."

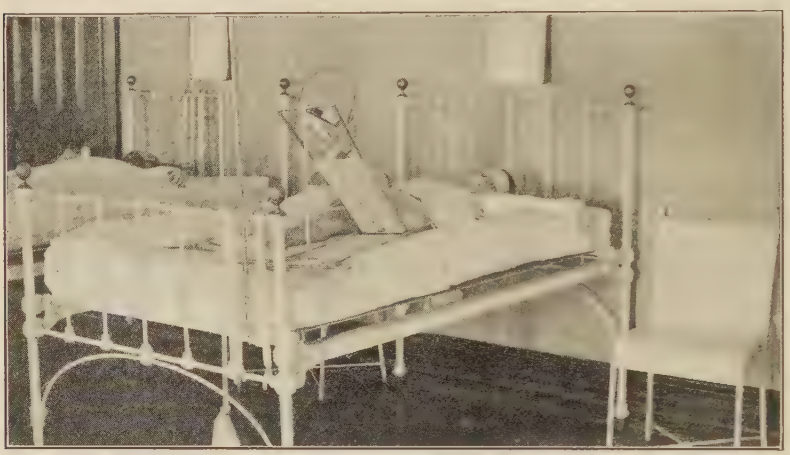

Fig. 316.—Traction by means of weight and pulley. (R. T. Taylor.)

It is often of advantage, particularly if the disease is active, to use some form of apparatus to fix the patient more thoroughly. Marsh uses a long lateral splint of thin board reaching from the axilla to a

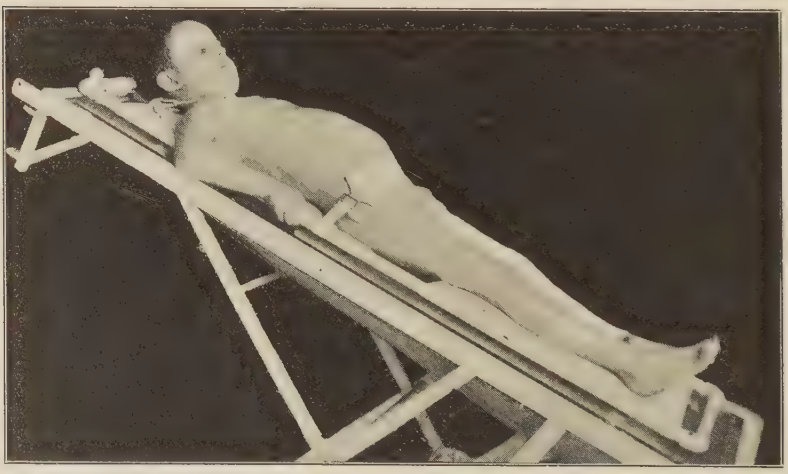

Fig. 317.—Method of fixing the patient to the Bradford frame for traction in hip disease. (R. T. Taylor.)

crossbar below the sole of the foot. To this the patient's body and sound limb are bandaged (Fig. 315).

For the same purpose a plaster spica bandage or a Thomas splint may be applied on the sound side, but a more convenient appliance

is the frame of gas-pipe covered with canvas that has been described in the chapter on Pott's Disease. Upon this frame the patient can be fixed, the limb being elevated by a support attached to the frame or independent of it (Figs. 316 and 317). It is perhaps needless to suggest that the bedclothes must not rest upon the elevated limb; in fact, that the patient must for a time be enclosed in a tent of bedclothes if the deformity is extreme. At first the traction weight must not be great, but as the perineum becomes accustomed to pressure as much weight as can be tolerated is used, from ten to twenty pounds being the average. This may be reduced at night and increased during the day. Great care must be taken to prevent painful pressure on the perineum by careful adjustment and frequent inspection of the perineal bands.

If the frame is used it may be provided with a windlass at the bottom for traction and with an arched band of metal across the pelvis for the attachment of the perineal bands, which behind are fastened to the side bars at a higher level. Thus the frame may be made an independent recumbent splint on which the patient may be moved about. If, however, one desires to exert traction to the point of distraction, the weight and pulley arrangement is more satisfactory; in this case the limb should be placed in an attitude of slight flexion and abduction, so that the femur may be drawn more directly from the acetabulum.

Lateral Traction.—Thus far longitudinal traction has been considered, but lateral traction or traction in the line of the neck of the femur deserves some consideration.

Thomas, who condemned all forms of traction as deceptive and irrational, and especially longitudinal traction, speaks thus of lateral traction: "For surely if relief from pressure be required, the only direction in which this is possible is clearly in the axis of the neck of the femur. Any method of extension in the axis of the body merely transfers the pressure from the upper part of the acetabulum to the lower quarter."[1] This contention is purely theoretical, as there is no evidence to show that injurious pressure is exerted upon that part of the acetabulum. On the contrary, the specimens from subjects who have been treated by longitudinal traction in recumbency and by means of the traction hip splint almost invariably show the effect of pressure upon the upper part of the head of the femur and upon the upper adjoining margin of the acetabulum. Moreover, the neck of the femur is in childhood so short and is set upon the shaft at so great an angle that longitudinal traction, if the limb is slightly abducted, is, practically speaking, in the line of the neck so that even from the theoretical stand-point the question of injurious pressure could only arise in the treatment of adults. The advantage of lateral traction in the treatment of hip disease was urged by Phelps[2] as early as 1889, and it has been applied as a routine practice in ambulatory treatment by Blanchard,[3] of Chicago, since 1872.

[1] Loc. cit., p. 10.
[2] New York Med. Rec., May 4, 1889. [3] Tr. Am. Orthop. Assn., vol. 7.

The effect of lateral traction in recumbency has been carefully investigated by C. G. Page.[1] His conclusions are that lateral traction alone is of no benefit, but if applied, together with longitudinal traction, it gives great relief in certain acute cases. The longitudinal traction should be twice as great as the lateral, 10 and 5 pounds being

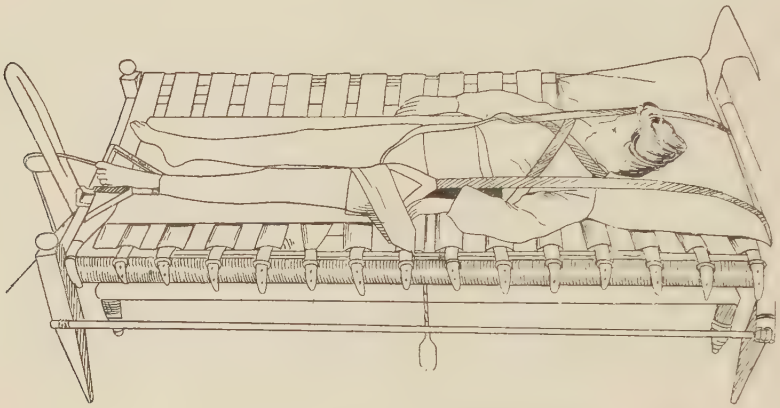

FIG. 318.—Lateral and longitudinal traction in hip disease. (Page.)

the average weights employed in his experiments. The method is shown in the illustration (Fig. 318).

The brace should be worn day and night. The perineal bands may be loosened at times to permit cleansing the skin with alcohol and for powdering, in order that the skin may be kept dry; but at such times,

FIG. 319.—A method of reducing flexion in hip disease. The long brace is adjusted to the angle of deformity, and in addition to the direct traction of the apparatus weights are attached to the brace itself. In the illustration counter-traction, by means of perineal bands attached to the head of the bed, is shown.

if the disease be acute, manual traction should be made until the brace has been readjusted. The adhesive plasters, if of moleskin, may often remain in position for three months or longer. When they

[1] Boston Med. and Surg. Jour., September 13, 1894.

BOSTON CITY

are removed the limb is gently bathed with alcohol. Excoriations are unusual unless rubber plaster is used. If the skin is abraded the part should be powdered with boracic acid and protected from the plaster by a layer of gauze.

The Relative Efficiency of the Traction Hip Splint.—In analyzing the action of this brace it is evident at once that it is thoroughly effective as a stilt to relieve the joint of weight-bearing. It is effective as a traction appliance, in the sense of relieving muscular tension, in direct proportion to the care that is exercised in its adjustment. Traction by this appliance may be made constant and effective, even to the point of practical fixation while the patient is in bed, or when crutches are used, in ambulatory treatment. But when the apparatus is used in locomotion the traction straps alternately relax and tighten as the weight of the body falls upon and leaves the brace in walking. When the brace is off the ground the joint is subjected to the traction that the brace exerts, plus its weight, as contrasted with cessation of traction and the relief from the weight when the brace supports the body at the alternate step. Thus the critics of the brace assert that it exercises a pumping action of the joint. As a matter of fact, the observation of patients under treatment by this method will show that little actual traction is exerted in the ordinary cases; that the so-called traction really serves principally for the adjustment of the brace, which by its weight exercises a certain intermittent traction during locomotion. The hold of the encircling band upon the pelvis assures a considerable restriction of motion; but whatever splinting action it may have depends upon the degree of traction, which is never effective enough, however, to prevent a certain amount of motion; according to the experiments of Lovett, a range of at least 35 degrees even when the brace is properly adjusted.[1]

The traction hip splint was not designed for fixation. On the contrary, Davis, its inventor, Taylor, who changed it into a practicable form, and Sayre, who further modified it, each believed that motion, except when the joint was fixed by muscular spasm, was desirable as a means of preserving function and that the traction permitted it without friction.

Motion without friction in this sense would seem to imply actual separation of the opposed bones, or distraction as distinct from traction. That actual distraction is possible at the hip-joint both in health and disease is proved by the experiments of Brackett[2] and by those of Bradford and Lovett. These experiments show that a traction force from ten to twenty pounds is required to cause one-eighth to one-quarter of an inch of actual lengthening of the limb, even in childhood, although if the muscles are atrophied and the joint disorganized by disease a much less weight will separate the joint surfaces as may be demonsatrated by roentgen-ray pictures. Under ordinary conditions, however, it is, to say the least, unlikely that the

[1] R. W. Lovett: New York Med. Jour., August 8, 1891.

[2] Brackett: Tr. Am. Orthop. Assn., vol. 2; Bradford and Lovett: New York Med. Jour., August 4, 1894.

feeble and intermittent traction exerted by a hip splint, when used as an ambulatory support, can be sufficient to separate the bones from one another or even to relieve the muscular spasm that causes deformity.

At the present time the theory that motion in a joint of which the component bones are actually diseased is of benefit, or even that it is harmless, has few supporters even among those who use the traction brace exclusively. On the contrary, the motion that cannot be prevented is tolerated because it is believed that no more effective protection can be attained by any method of ambulatory treatment.

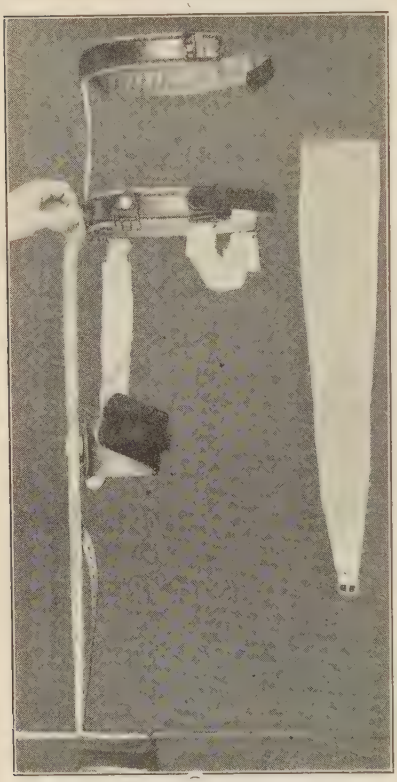

FIG. 320.—The long, inexpensive brace with solid upright, showing the perineal bands and the adhesive plaster, as used in hospital practice.

In all acute cases a period of rest in bed with traction, sufficient to relieve pain and to reduce deformity is indicated. This if supplemented by open air and sunlight is the most effective, general and local treatment and it may be prolonged indefinitely with advantage. When ambulation is resumed the braced limb is made pendent by means of the high shoe and crutches, so that uninterrupted traction may still be exerted, and the brace is only used as a supporting appliance when the symptoms indicate that the disease is quiescent.

In hospital practice, which is the decisive test of practical efficiency, the original hip brace has been in great degree discarded as ineffective in relieving the symptoms and in preventing deformity.

In its place the long traction brace in some form is now used as providing better fixation.

This is illustrated in Fig. 320. To the pelvic band of the traction brace a bar is attached which extends in the axillary line to about the middle of the scapula where it supports a chest band of thin metal covering about three-fourths of the thorax, the circumference as at the pelvis being completed by a strap. The brace should be constructed so as to hold the limb in about 15 degrees of abduction. If it is properly adjusted, it assures practical fixation of the joint.

The efficiency of the apparatus may be still further increased by replacing the perineal bands with a metallic ring. This ring, which fits the upper extremity of the thigh closely, is attached to the upright at an inclination corresponding to the line of the groin (Fig. 322).

FIG. 321.—The long hip splint applied.

FIG. 322.—The long brace, with Thomas ring and extension upright, similar to Phelps' brace.

FIG. 323.—Rear view of brace.

NOTE.—If braces of this type, Figs. 317-320, are used the upright should be fixed to the pelvic band at a lateral inclination in order to hold the limb in about 15 degrees of abduction.

(The Thomas ring is described fully in connection with his knee splint.) It is a better support because it prevents anterior-posterior motion within the pelvic band, which the perineal straps permit. The ring may be used as the only support or it may be combined with a perineal band on the opposite side. This is of advantage if there is a tendency toward adduction.

The apparatus is most satisfactory when the hollow upright of the Taylor brace is used. This is light and strong, and is provided with an arrangement for effective traction, but in hospital practice the upright is made of solid metal, and the traction is made by simple

FIG. 324.—The Phelps hip splint.



FIG. 325.—A chair to be used with the long hip splint. The patient sits upon the sound side, while the splinted half of the body remains in the extended position, the brace resting on the floor.

straps. The metallic ring, besides providing better fixation, is a firm support that cannot be removed by the patient. It is, of course, more difficult of adjustment, and it is not suited to the treatment of young children because of the difficulty in keeping it clean and dry.

The Thomas ring was first applied to a hip splint by Phelps (Fig. 324). He urged the advantages of fixation and traction, and his brace, of which that last described is simply a slight modification, is provided with an arrangement for lateral traction. Practically speaking, this is a tape by which the lower third of the thigh is held in apposition to the upright. It hardly seems possible that appreciable lateral

traction can be exerted on the joint by this means if the metallic ring is properly fitted to the thigh. The simple straps do not afford as effective traction as the rack and pinion, nor is the brace, as usually constructed, sufficiently strong to bear the weight of the body without bending. It should be stated, however, that this form of brace is intended to be used with crutches rather than as a walking appliance.

Certain objections to this attempt to combine effective splinting with traction and stilting have been urged by those who believe in the efficiency of the ordinary traction brace. For example, it is said that the splinting is ineffective because the movements of the trunk are transmitted to the joint, while this is not true of braces that do not extend above the pelvis.

As a matter of experience, it will be found that motion of the upper part of the trunk is absorbed, as it were, in the flexible lumbar region of the spine before it reaches the joint. If, however, such motion or any motion causes discomfort or aggravates the symptoms, the patient should be confined in the recumbent posture until the acute phase of the disease has passed. It is said that the brace is cumbersome, that the patient cannot sit with comfort, and that it prevents normal activity. A long brace certainly weighs more than a short one, and if a brace prevents flexion of the hip and spine it is evident that the patient cannot sit with comfort in an ordinary chair.

The patients themselves, however, make little complaint of the brace, even when it has been substituted for an ordinary traction splint; while the greater restraint of activity is a favorable element of treatment, since children who do not suffer pain are much more likely to be too active than to be harmfully restrained by any form of appliance. These objections are trivial if one is convinced that the dangerous and deforming disease that is under treatment may be more easily controlled and that the final result is likely to be better and to be more rapidly attained by this means than by another.

The Thomas Treatment of Hip Disease.—H. O. Thomas,[1] writing at a time when in America it was generally believed that motion was essential to the well-being of a diseased joint, and when fixation was supposed to predispose to, or to actually induce, anchylosis, states "that continuity of extension *per se* is not a remedy in hip-joint disease; in its application it involves unavoidably a fractional degree of fixation which is sufficient to mask the evil of this ridiculous malpractice."

The conclusions on which his treatment is based are these:

"The main obstacle to the cure of an inflamed joint is the friction and pressure of its surfaces; consequently the attainment of rest, that is, of immobility of the articulation, ought to be the principle which should guide the treatment. Pressure and concussion are less to be feared than friction. Effectual rest can only be obtained by mechanical treatment, and for this purpose the appliances which I

[1] Diseases of the Hip-, Knee-, and Ankle-joints Treated by a New and Effective Method, 1875, p. 10.

here recommend are effectual. The more an inflamed joint is moved the stiffer does it become; while the more effectually it is fixed, the sooner and the more completely is its capability of movement restored. To ensure permanency of cure the control should be maintained for a period beyond the time when resolution has taken place. This prolonged arrest of a joint's movements, for even an unnecessarily long period, I have never found to do harm."

Thomas's conclusions have now been generally accepted, although his methods are rarely used in this country.

The Thomas hip splint is described by him substantially as follows: A flat piece of malleable iron, three-quarters of an inch wide and three-sixteenths of an inch thick for children, and one inch by one-quarter inch for adults, long enough to extend from the lower angle of the scapula to the middle of the calf, forms the upright. This is fitted to the body of the patient, passing from the lower angle of the scapula, in a perpendicular line, downward, over the lumbar region, across the pelvis, slightly external, but close to the posterior spinous process of the ilium and the prominence of the buttock, along the course of the sciatic nerve to a point slightly external to the calf of the leg. It must be carefully modelled to this track. The lumbar portion of the upright must be invariably almost a plane surface, but it must be twisted slightly on its long axis at the junction of the upper and middle third, so that the anterior surface of the lower part may look slightly outward to correspond to the contour of the buttock and thigh. A second and double bend is made in the upright at the point where it passes the buttock, so that the thigh part lies on a slightly higher plane than the body part, but parallel with it. The upright is then provided with chest, thigh, and leg bands (Fig. 326).

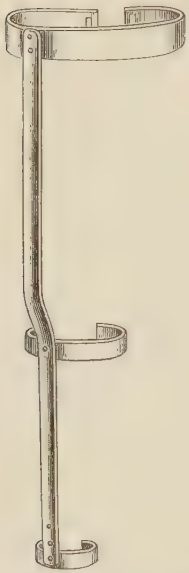

Fig. 326.—The splint in its simplest form, not yet padded or covered. (Ridlon.)

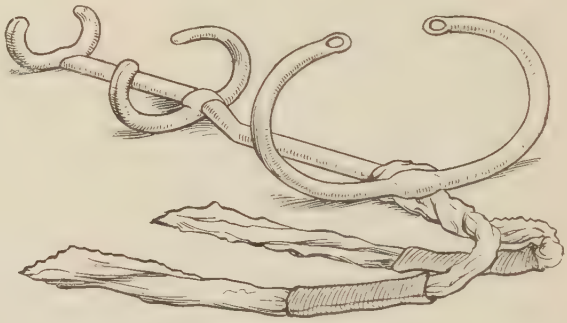

Fig. 327.—The Thomas hip splint, covered and fitted with shoulder straps. (Ridlon and Jones.)

The chest band is of hoop iron, one and a half inches in width by one-eighth of an inch in thickness. This is bent into an oval to corre-

spond with the shape of the chest, being four inches less than the circumference at this point if the patient is an adult, and of a corresponding size for a child. It is riveted to the upper extremity of the brace, so that one-third of its length shall be on the side corresponding to the diseased joint and two-thirds on the other. The thigh band and leg band are of similar material, three-quarters by one-eighth of an inch in size. The thigh band, in length equal to two-thirds of the circumference of the thigh, is fastened to the upright at a point one or two inches below the buttock, and the calf band, equal in length to half the circumference of the leg at the calf, is riveted to the lower extremity of the brace. Both the thigh and leg bands are attached to the brace at points slightly to the inner side of the center, so that the outer arm of each band is somewhat longer than the inner. The brace is padded with thin boiler felt and is covered smoothly with basil leather. In fitting the brace to the patient the long part of the chest band should be made to hug the body closely, while the short arm should be somewhat away from it. The anterior surface of the thigh part of the upright should have a perceptible outward twist and should be somewhat on the inner side of the popliteal space. Thus the instrument is prevented from rotating outward and becoming a side splint. The chest band is closed with a strap and buckle; it is suspended by shoulder straps, and the leg between the two bands is attached to the brace by means of a flannel bandage. Ridlon states that in practice this bandage is usually replaced by a strip of basil leather passed across the front of the limb close down to the upper border of the patella, thence backward and downward to the stem of the splint and pinned to the covering, so that the resistance to the downward working of the brace is borne by the quadriceps femoris muscle. The ordinary shoulder straps may be replaced by a single bandage looped about the upper part of the stem (Fig. 328). This bandage is twisted for a length of about six inches, then separated, the ends being carried over the shoulders, are passed through holes in the corresponding ends of the chest band, where they are knotted, and finally the two ends are tied to one another, completing the circumference of the chest band.

This brace is fitted by the surgeon directly to the patient's body as he stands erect. If the limb is already flexed the foot is raised by blocks until the lumbar lordosis is straightened; the brace is then bent to fit the angle of deformity and is applied in the usual manner.

The brace is made of iron because it is less elastic than steel and because it can be more easily twisted by wrenches. It must be heavy and strong in order to splint the part effectively, and it can only be an effective splint when it is fixed in its proper position and exercises direct pressure upon the hip-joint. In cases in which the brace has been properly adjusted a deep furrow should appear in the buttock directly over the neck of the femur. Once fitted to the patient it is changed only at infrequent intervals and always by the surgeon, who is particularly careful not to move the limb during the active stage of the disease.

The double Thomas hip splint is made by joining two single splints. These are riveted to the chest band above and are connected at the lower ends by a crossbar unless the brace is to be used in the reduction of deformity. Care must be taken that the uprights pass to the outer side and not directly over the posterior-superior spines of the ilium.

The Reduction of Deformity by the Thomas Method.—Preferably in the treatment of children the double brace is applied, the sound limb being fixed in the extended position while the flexed limb is supported by the other arm of the brace, bent to the angle of deformity. The patient is confined to the bed and, as the muscular spasm relaxes under the influence of enforced rest, the brace is straightened slightly by wrenches from time to time, at a point opposite the joint, to conform to the improved position until symmetry is restored. In resistant

FIG. 328.—Method of changing the line of pressure on the skin from the Thomas hip splint by drawing the tissues to one side. (Ridlon and Jones.)

cases this gradual relaxation is hastened by straightening the brace somewhat at intervals, to which the attached limb must conform—a gradual forcible reduction of deformity. According to Ridlon and Jones, the flexed limb is often forced to conform to the straight brace by a temporary exaggeration of the lumbar lordosis, which lessens as the muscular spasm subsides under treatment.

The treatment is divided by Mr. Thomas into stages:

1. A preliminary stage of rest in bed for the reduction of deformity and to allow for subsidence of acute symptoms.

2. The patient is then allowed to go about on crutches wearing an iron patten at least four inches in height under the sound foot (Fig. 329).

3. When all symptoms of disease have subsided and when atrophy of the muscles is marked the brace may be removed at night.

MEDICAL LIBRARY OF THE BOSTON CITY HOSPITAL

4. The brace is finally discarded, but the patten and crutches are still used in walking.

The records of Mr. Thomas show the average time of confinement to the bed to be twenty-two weeks, and the average duration of treatment twenty-one months.

FIG. 329.—Thomas splint applied with patten and crutches.



FIG. 330.—A modified form of Thomas brace employed in the treatment of infants. The pelvic band assures better fixation. The screws at the lower extremity are arranged to permit the addition of a foot-piece for traction.

It is stated by Ridlon[1] that in actual practice these principles were not carried out, for nearly all the children treated under Thomas's direction at the time his observations were made were walking about without the high patten and crutches, even before the deformity had been overcome and while muscular spasm and pain persisted.

[1] A report of Sixty-two Cases of Hip Disease Observed in the Practice of Hugh Owen Thomas, New York Med. Jour., October 4, 1890.

This was, however, probably an exigency of practice among the poor, and at all events it is in line with Thomas's contention that pressure and concussion are less harmful than friction.

Modifications of the Thomas Brace.—Although not so stated in his book, Thomas used at times a short brace extending only to the lower part of the thigh, thus permitting motion at the knee. This was apparently designed as a convalescent splint, although its use was not restricted to that class of cases. In certain cases a strip of iron, "the nurse," was screwed to the lower extremity of the long brace, prolonging it beyond the foot in order to prevent the patient from bearing weight upon the limb.

The Thomas brace, so effective in preventing and overcoming flexion deformity, does not prevent lateral distortion. In fact, in 24 of the 58 patients examined by Ridlon,[1] adduction was present; a larger proportion, it would appear, than would be found in a like number of cases under treatment with the traction brace. This tendency to lateral distortion may be guarded against by placing a half-band of material similar to the chest band about the side of the pelvis; on the same side for adduction, on the opposite side for abduction of the limb.

The Thomas brace has a great advantage over other appliances in its simplicity. It can be made by a blacksmith, but it must be fitted by the surgeon. This fitting requires great care. In the words of Mr. Thomas: "The fitting although sometimes successful in one visit, may at other times occupy many days. The surgeon should mold, by reducing or increasing the various curves, until the instrument ceases to tend to rotate, and at none of its angles irritates the patient." He concludes, in a general answer to the criticisms that have always been made on the difficulty of adjustment of the appliance, as follows: "What I can invariably do must be possible to others."

Treatment by Plaster Supports.—The treatment of hip disease in the more important clinics in this country has greatly changed in recent years, and fixation of the diseased joint in the position most favorable for recovery with limited function is now generally recognized as the most important element of mechanical treatment.

The period of complete inactivity is shortened and weight-bearing is permitted when it causes no discomfort, in order to avoid the atrophy, loss of growth and muscular and ligamentous relaxation that may follow complete and prolonged disuse of the limb.

The routine of treatment as applied in hospital service may be outlined as follows:

Deformity, if present, is at once reduced under anesthesia by traction and gentle leverage, and the limb is placed in full extension, 20 degrees of abduction, and fixed by a long spica. If the disease is of a more acute type traction plasters are applied to the limb and a spica plaster support, reaching from the ankle to the mammary line, carefully molded about the pelvis and hip, is adjusted. The patient is then placed in bed with a traction weight of ten pounds or more.

[1] Loc cit.



FIG. 331



FIG. 332

FIG. 333

FIGS. 331, 332 and 333.—Different forms of plaster supports used in the treatment of hip disease.

This treatment is continued until all acute symptoms have subsided, a wheeled couch on which the patient lies taking the place of the bed during the day. The immediate correction of deformity followed by fixation in the desired attitude has a manifest advantage over the tedious reduction by traction which necessitates long confinement to the bed with no compensatory advantages except the avoidance of a so-called operation (Fig. 335).

After several weeks or months, weight-bearing is tested, and if it causes no immediate or subsequent discomfort it is permitted. If the joint is sensitive to weight-bearing, although it causes no actual pain, axillary crutches or a perineal splint may be used for a time. As soon as the indications permit, the long spica is replaced by the Lorenz plaster support, permitting motion at the knee and in the lumbar spine, but supporting the joint by accurate adjustment to the pelvis. With this appliance a certain degree of flexion of the limb cannot be prevented, nor is it within limits undesirable when weight-

FIG. 334.—The short plaster spica, combined with traction used after reduction deformity.

bearing is permitted, as it lessens the direct jar on the joint. With care the attitude of abduction may be assured during the entire course of treatment. This is of the greatest importance, for when the head of the femur lies deep in the acetabulum direct pressure is removed from its upper part and the corresponding surface of the acetabulum, the points which most often present evidence of pressure erosion.

If the patient is seen early before deformity has appeared the short spica is applied without preliminary traction and locomotion is permitted if the symptoms indicate that the joint will tolerate it.

This treatment, in which the degree of protection is adapted to the character of the disease, differs from that of Lorenz, which is practically a routine ambulatory treatment by the short spica, as decidedly as from the routine treatment by braces.

The principles are those that govern the treatment of tuberculous disease of the lungs, periods of rest alternating with an activity regulated by the symptoms. It is a compromise between the treatment of the local disease and the effect of this treatment upon the limb and

upon the patient. Thus, acute symptoms at any stage of the disease indicate rest in bed, the long spica and traction, discomfort, a lessened activity and relief from weight-bearing. If, however, the local disease is quiescent, weight-bearing without motion improves the nutrition of the limb and that of the body in general.

Fig. 335.—The long plaster spica bandage. The dotted line indicates the position of the steel support.

Application of Plaster Splints.—The long spica is often applied in out-patient practice. It is a better protection than the less comprehensive forms in that it prevents movements of the leg, diminishes the jar on a sensitive joint, and enclosing the foot lessens the danger of edema in the extremity. If, however, the disease is acute, rest in bed with traction in the manner described is indicated.

A plaster splint to assure support should fit closely, consequently it should be applied with as little padding as is practicable. A covering of shirting, such as is used in the application of the plaster jacket, is fitted to the body and the limb reinforced with one or more layers

of cotton flannel bandage, those parts that are likely to be subjected to pressure—the toes, the heel, the malleoli, the condyles of the femur, the sides of the pelvis, the anterior-superior spines, and the thorax—being further protected by cotton wadding or other material. The



Fig. 336.—The Schultze pelvic support for the application of the plaster spica.

plaster bandage should cover the lower half of the thorax, and it should extend to the ends of the toes. It should be applied under slight traction, very carefully around the adductor region and reinforced beneath the buttock, which should be entirely covered and supported. At this point, in the line in which the bar of the Thomas hip splint, a strip of malleable steel, long enough to reach from the



Fig. 337.—Box with adjustable sacral support of the Lorenz model used for the application of the plaster spica.

middle of the trunk to the lower third of the thigh may be incorporated in the plaster for greater security (Fig. 335). The plaster splint is reinforced in front of the hip and beneath the knee, the points at which the support is likely to break before it becomes firm. The

proper anterior-posterior support of the buttock, consequently of the hip-joint, which is of the first importance, is almost invariably neglected in the ordinary application. The spica may be applied in the upright posture by means of the swing, as used in the application of the plaster jacket, the weight being supported in part by the sound leg while the other is pendent. Usually it is applied with the patient in the reclining posture, the body lying on a shoulder rest, and a sacral support. The arms are then drawn above the head to increase the capacity of the thorax, while the limbs are supported by an assistant (Fig. 338).

In the more recent cases deformity may be practically reduced at the second application of the bandage, because of the relaxation of



Fig. 338.—A pelvic support in use. The patient presents fixed flexion to 135 degrees and fixed adduction of 35 degrees.

the spasm assured by the rest and fixation; thus it is particularly useful in the treatment of young children in outdoor practice, for whom hospital care would otherwise be required.

The Short or Lorenz Spica.—The short spica is used as routine treatment of hip disease in Lorenz's clinic in Vienna and in a somewhat modified form this principle of treatment has been accepted in many of the clinics in this country, the aim being to fix the affected limb in an attitude of slight flexion and abduction, the primary attitude of hip disease, by accurate adjustment to the pelvis and at the same time permitting movement in the lumbar spine and at the knee. A close-fitting covering of shirting is drawn over the limb and pelvis, and a wide friction bandage is then introduced between the skin and

shirting to serve as a "scratcher." The bony prominences are suitably protected in the manner described, and the bandages are then applied, being drawn closely, and carefully molded about the pelvis and thigh, so that movement in the joint may be controlled. The upper and lower extremities of the bandage are cut away as illustrated (Fig. 340), and the shirting is then drawn over the margins of the plaster and sewed. This makes a smooth covering and holds the padding in position. If

FIG. 339.—The short spica of the Lorenz type showing the adjustment to the pelvis.

FIG. 340.—Rear view of the short spica.

the bandage is extended below the knee it is more efficient in checking the action of the long muscles which are attached to the pelvis and to the leg. It should be stated that in the treatment of some of the more acute cases by Lorenz the weight of the body is removed by a prolongation or stirrup of sheet steel which projects beyond the foot, the two extremities being incorporated in either side of the plaster bandage in the neighborhood of the knee (Fig. 345). In the better class of cases a leather support provided with a steel foot-plate extend-

MEDICAL LIBRARY OF THE BOSTON CITY HOSPITAL

ing slightly below the foot and a joint at the knee is used in German clinics. The short spica bandage in combination with the traction hip brace (Fig. 347) answers the same purpose and is more efficient if somewhat more cumbersome.

The importance of the attitude of abduction as a means of relieving pressure and preventing deformity has been mentioned. To assure this position in ambulatory treatment the lateral elevations of the spica should overlap the short ribs and if necessary a perineal band may be used as illustrated in the figure (Fig. 344). A cork sole of about an inch in thickness may be used on the abducted side to prevent tilting of the pelvis.

Fig. 341.—The spica with traction and the wheeled couch used at the Hospital for Ruptured and Crippled.

The advantages of immediate correction of deformity under anesthesia have been mentioned. It should not be employed if the deformity is of long standing and if the disease is active or of the destructive type accompanied by infiltration of the tissues or by a discharging sinus. In such cases traction is to be preferred and in certain instances in which because of general shortening of the contracted tissues and subluxation of the femur, reduction by this method is impracticable, correction should be deferred until the process of repair is practically completed.

The impression that one might receive from descriptions of the treatment of hip disease is that most cases begin acutely, or that

FIG. 342.—The Lorenz spica, showing the adjustment to the pelvis. In this case it is extended below the knee, but in many instances motion at the knee-joint is permitted.

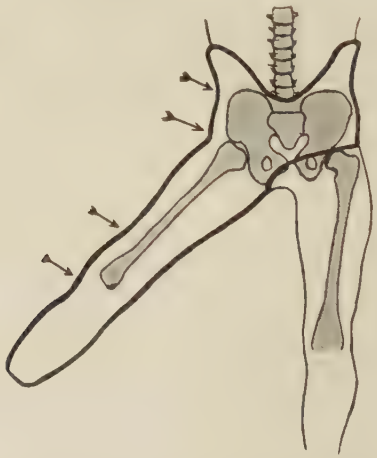

FIG. 343.—The short spica applied with the limb in abduction, showing the manner in which it is molded about the pelvis and knee to assure fixation, and the removal of direct pressure from the head of the femur by this attitude.

Fig. 344.—The Lorenz spica with the perineal band. A shoe with a cork sole should be worn on the abducted side.

when the patients are brought for treatment the disease is in an acute stage, or that deformity is present, so that preliminary recumbency is required. In a large proportion of the cases, however, the symptoms are not acute, nor is deformity present. In such instances the hip splint or plaster spica may be applied without preliminary recumbency, and if the joint is fixed in the normal attitude and protected,

Fig. 345.—The Lorenz stilt, sometimes used in the treatment of the more painful cases. This is incorporated in the plaster bandage above the knee and it extends below the foot.

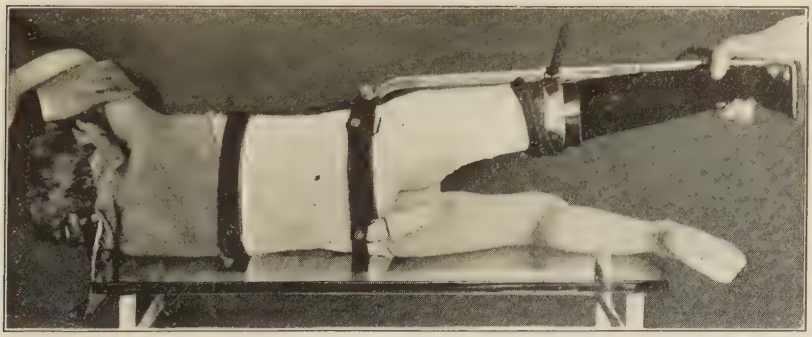

Fig. 346.—The short spica bandage reaching to the knee in combination with the long traction brace. One perineal band has been removed in order to show how the joint is supported by the bandage.

a relatively rapid recovery without deformity and with a fair range of motion may be hoped for.

Review of the Mechanical Treatment.—Traction is the most efficient means of assuring rest of a diseased joint if the patient is recumbent or if the limb is pendent. Under careful and constant supervision some traction may be exerted by an ambulatory splint, but under ordinary conditions the traction hip brace is only efficient as a stilt in relieving the pressure and shock of weight-bearing. It does not prevent motion at the joint nor does the traction prevent friction.

Fig. 347.—The Lorenz spica combined with the traction hip brace, sometimes used when the diseased joint will not permit weight-bearing. The perineal strap prevents displacement of the plaster appliance.

The most accurate statistics of final results in cases treated by this apparatus illustrate also its ineffectiveness in preventing deformity. Thus in a total of 35 cases treated at the New York Orthopaedic Dispensary[1] practical anchylosis was present in 74 per cent. and in 60 per cent. the limb was distorted to a greater or less degree.

The Bradford brace, if properly adjusted, holds the limb in abduction and indirectly splints the joint. It is therefore the most efficient of the short traction braces.

The long traction brace adds the element of splinting in which the short braces are deficient, and it is therefore far more satisfactory in the treatment of the acute or destructive types of cases.

The Thomas brace is an efficient splint and fixes the joint more perfectly than other braces, but it does not hold the limb in the abducted attitude, as is desirable, or even prevent adduction.

Plaster supports enable one to dispense with the services of a mechanic, a great advantage in many instances. The long spica with traction in recumbency is the most satisfactory treatment for acute disease. The long spica including the foot is of service in the treatment of young children in out-patient practice.

[1] Shaffer and Lovett: New York Med. Jour., March 2, 1878.

The short spica is efficient in selected cases in proportion to the accuracy of its adjustment.

The vexed question is that of early weight-bearing, as opposed to complete cessation of function, from the inception to the end of the disease, a period of several years.

From the practical standpoint, what has been described as the treatment by plaster supports is far more satisfactory both to patient and surgeon than the old routine treatment by the traction brace. A

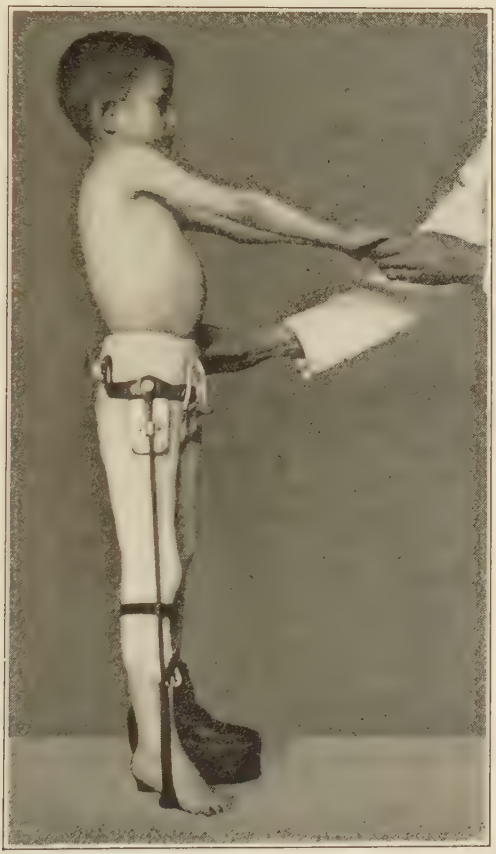

FIG. 348.—Lateral view. The shape of the pelvic band is like that illustrated in Fig. 350.

comparison of final results is, however, impracticable. It is claimed that splinting and weight-bearing will favor anchylosis. If the surfaces of the femur and of the acetabulum are denuded of cartilage and are held in apposition, the process of repair should cause adhesion, fixation, and cure, as contrasted with deformity and subluxation, which would separate the mutually diseased surfaces. Under such conditions anchylosis, which is the best assurance of cure and future comfort, is an end to be desired rather than avoided. Loss of motion is, more-

over, very common in cases treated by contrasting methods. For example, in a series of cases illustrating final results treated exclusively by the traction hip splint, there was practical fixation in 74 per cent.[1] It may be assumed also that efficient splinting of the joint with the limb in an attitude of selection, combined with modified weight-bearing, is more likely to check the destructive changes in the joint than is stilting with inefficient splinting. As a matter of personal experience it may be stated that some of the most disastrous results from the functional stand-point have followed the most careful treatment by the traction brace, due to complete disuse through a period of years.

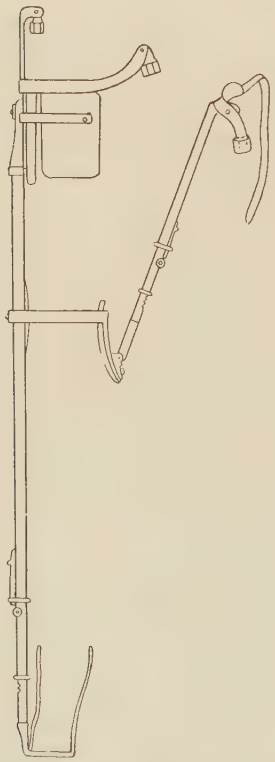

FIG. 349.—The Taylor hip splint as used by Taylor in the later years of his practice with but one perineal band. The illustration shows also an appliance for preventing or for correcting slight degrees of adduction, while the brace is in use as a walking appliance. The abduction bar is buckled about the upper extremity of the other thigh. (H. L. Taylor, Medical News, March 23, 1889.)

Weight-bearing should not be permitted if it causes discomfort, or if abscess is present, or if the disease is of a destructive type. In such cases the long traction brace is the most satisfactory appliance. The best treatment is that which is adapted to the patient's surroundings and to his general and local condition, a treatment therefore of selection as opposed to one of routine.

Treatment during Stage of Recovery.—It is much easier to assure one's self that the disease is still active than to decide when it is cured. For the symptoms may have been quiescent for months or years even, under the protective treatment, and yet they may recur on the slightest provocation when this treatment has been discontinued.

To judge of the probable duration of the disease in a given case, one must consider its area, its quality, and its complications. If, for example, the primary symptoms indicate that the focus of infection is of limited area and is contained within the bone, rapid recovery possibly in a year, may be expected; but in the ordinary type of disease in which the joint has been invaded, repair can hardly be anticipated in less than three or four years. If sufficient time has elapsed to

[1] Loc. cit.

permit of natural cure, if there have been no symptoms of active disease for a year or more, and if the roentgen-ray picture is satisfactory it may be assumed that convalescence is established. If a brace has been employed it may be modified to serve as a protection by attaching it to the shoe so adjusted as to be slightly longer than the limb, in

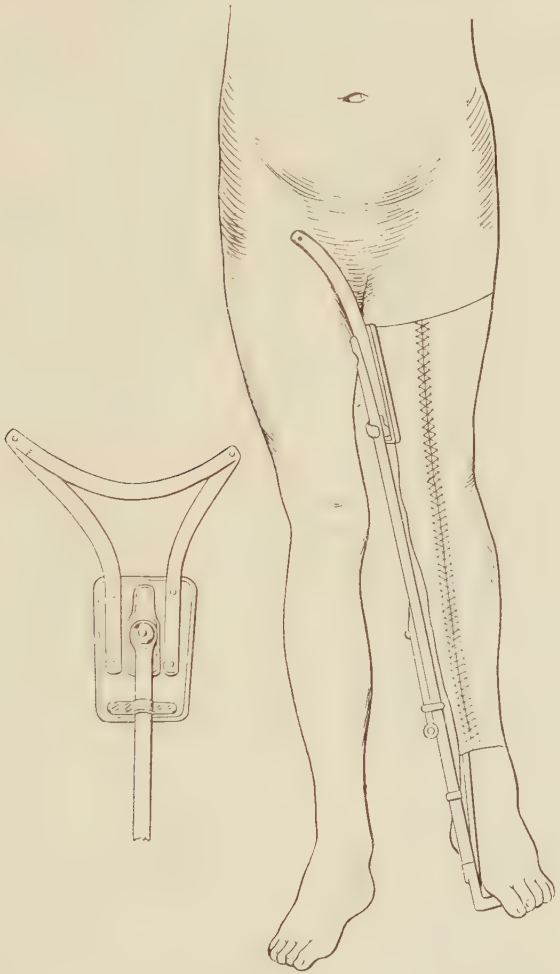

FIG. 350.—Taylor's median abduction brace as a bed splint to overcome adduction by counter-pressure upon the sound side.

order that direct concussion and pressure may be lessened (Fig. 351). Or a brace jointed at the knee, after the Taylor pattern, may be employed.

This brace is so adjusted as to be slightly longer than the limb, so that the heel does not touch the bottom of the shoe (Fig. 354). Thus the weight is in great part supported on the perineal band. The weight

of the brace may be in part supported and incidentally slight traction may be exerted by adhesive plaster applied above the knee (Fig. 355). The foot-plate, to which the upright is attached, is shown in Figs. 354 and 356.

Fig. 351.—Modified brace to be worn during convalescence. Same patient as in Fig. 319. The thoracic part has been removed and the lower end of the stem has been made into a caliper, passing through the heel of the shoe. The stem is extended by means of the key until the heel is lifted slightly from the shoe; thus the hip is relieved from shock.

As the strain upon the part is increased, one watches carefully for the return of muscular spasm or for restriction of the range of motion. If the range of motion does not diminish, and if the deformity that may be present does not increase or does not appear if it were absent, the brace may be removed at intervals and finally discarded.

As has been stated, the short spica after the Lorenz model is an admirable support during the period of recovery. It checks motion at the joint, yet it permits the function of support, and thus a

Fig. 352.—Judson's perineal crutch. This support suspended from the shoulders may be employed as a substitute for axillary crutches. It is also used as a convalescent splint in the treatment of hip disease.

gradual rebuilding of the bony structure which has become atrophied during the course of the disease. By means of this appliance the limb may be held in the desired position of moderate abduction, and it is particularly effective when the limb, because of destructive changes in the joint, is inclined toward adduction.

MEDICAL LIBRARY BOSTON CITY HOSPITAL

The period of supervision even in favorable cases should be protracted, for no patient can be considered free from the danger of relapse for a long time after apparent cure. If there is firm bony union, as in exceptional cases, cure is assured; but if there is simple fibrous anchylosis, and particularly if there is upward displacement of the trochanter, there is a strong tendency toward flexion and adduction, even though the disease is cured. This tendency should be resisted by persistent "stretching" in the directions of abduction and extension, and if necessary apparatus must be again applied, to reduce the deformity or to hold the limb in proper position until stability is assured. When the brace or plaster has been discarded, the patient should be trained to walk with equal steps, placing the limb, as far as possible, on an equality with its fellow and adapting in like manner the stronger to the weaker member.

This has an important influence in checking the tendency to deformity and in modifying or even concealing the limp, a point to which Judson has repeatedly called attention.

Fig. 353

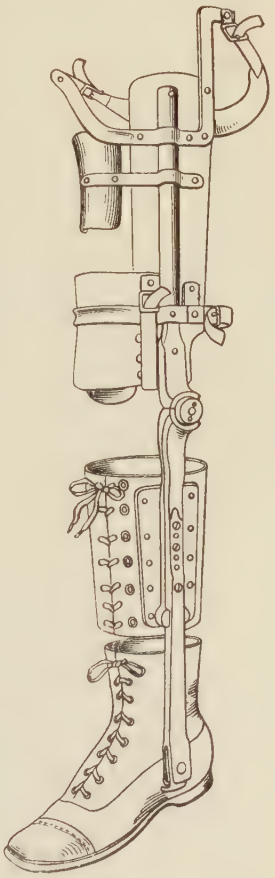

Fig. 354

Figs. 353 and 354.—Convalescent hip splint, allowing motion at the knee. (Taylor.)

Bilateral Hip Disease.—Ninety-five cases of bilateral hip disease were treated in the Hospital for Ruptured and Crippled during a period of ten years.

As a rule the second hip is affected some time after the symptoms of disease of the first have been apparent, but occasionally both joints are involved simultaneously. In most instances the symptoms are

rather subacute, owing, very likely, to the fact that the activity of the patient is so restricted.

Treatment.—The treatment is similar in principle to that of the unilateral form. The patient during the greater part of the course of the disease must be confined in the recumbent position, although not necessarily in bed. The double Thomas hip splint or spica plaster

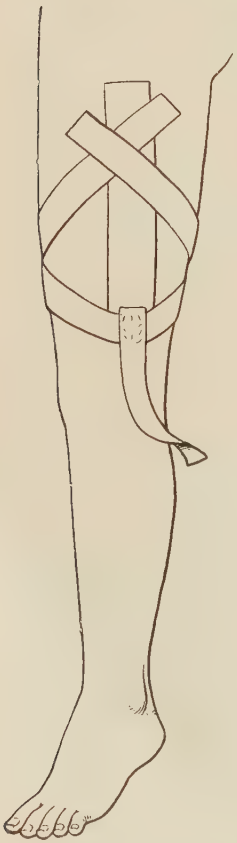

Fig. 355

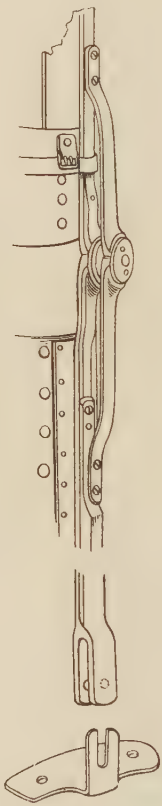

Fig. 356

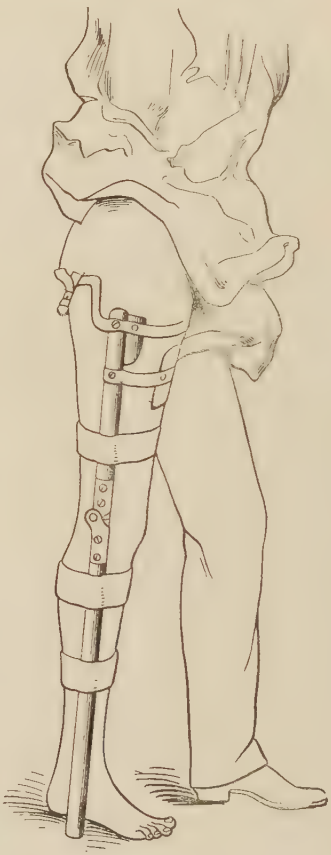

Fig. 357

Figs. 355 and 356.—Details of the Taylor convalescent hip brace. Fig. 355, the adhesive plaster. Fig. 356, the foot-plate showing the method of attachment.

Fig. 357.—The action of the Taylor convalescent hip brace in removing direct pressure, illustrated by wooden model.

support may be used. If the disease is acute, traction is added in the manner already described. If the disease of one hip is acute and is attended by abscess formation, excision for the purpose of lessening the strain upon the patient may be advisable.

If motion is greatly restricted in both joints, locomotion, unless crutches are used, is very difficult, as motion at the knees can supply only in small part the function of the hip-joints. In such instances

excision or arthroplasty with the aim of restoring motion in one joint may be considered.

Hip Disease Combined with Disease of Other Parts.—The most common combination is with Pott's disease. The two processes may be distinct, but occasionally it would appear that the disease of the hip is caused by the infection of an abscess, which, coming from the spine, remains for a long time in contact with the capsule of the joint. In 5 of 130 cases of disease of the hip-joint, of which the final results were reported by Gibney, Waterman, and Reynolds (page 415), Pott's disease was a complication in 2 instances preceding and in 3 following the disease at the hip. The combination of the two diseases makes the mechanical treatment difficult. Recumbency offers the best opportunity for the effective adjustment of apparatus when the disease of either part is acute. At a later period crutches may be employed, together with the necessary braces.

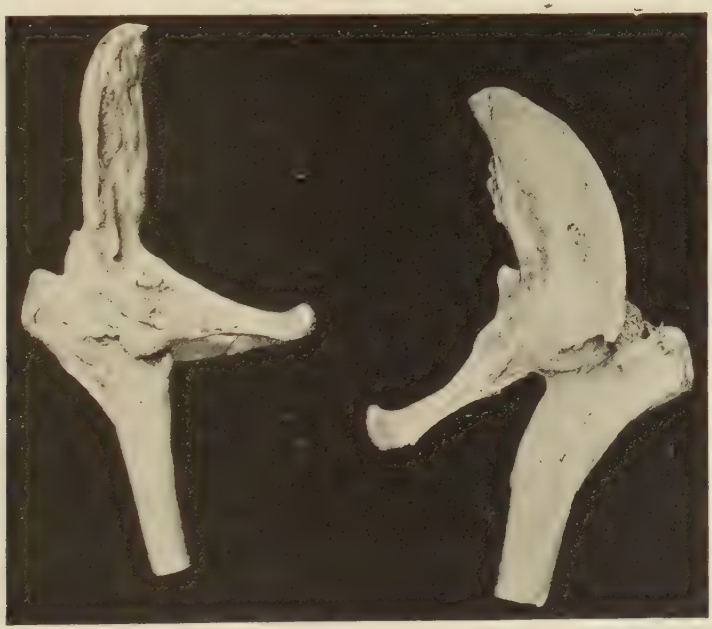

FIG. 358.—Double hip disease, terminating in bony anchylosis.

Hip Disease in Infancy.—Hip disease in infancy is far less common than in early childhood. It presents nothing of special interest except that its effect upon the function of the joint and upon the development of the limb is usually more marked than in older subjects. Tuberculous disease of this joint must be differentiated from infectious epiphysitis, in which prompt operative treatment is indicated. A modified Thomas brace is most efficient in treatment (Fig. 330).

Hip Disease in the Adult.—Hip disease in the adult may present the typical symptoms of the ordinary form, but it is usually of the more subacute type. Not infrequently there is coincident tuberculosis of the lungs.

The subacute form of tuberculous disease is often difficult to distinguish from arthritis deformans, if this is limited to the hip-joint. The mechanical treatment is not difficult, but operations to induce anchylosis may be be advisable to hasten the cure of the disease. This is far more important than in childhood, because few adults can afford the time required for the natural cure and because in many instances the general condition of the patient may demand relief from the depressing effects of the local disease. It may be noted, however, that it is very difficult to induce anchylosis in these cases, the most effective method being complete removal of all the diseased bone from the extremity of the femur together with the cartilage from the acetabulum. The trochanter is then cut away in order to permit the complete inclusion of the head of the femur in the acetabulum, its inner surface having been laid bare it is apposed to a freshened surface cut in the rim of the acetabulum. Wedges of bone cut from the tibia inserted in the open spaces between the head of the femur and the acetabulum will hasten to final consolidation or if the space between the remains of the head is a large one the trochanter may be turned about and its narrow outer extremity from which the tissues have been removed driven into the interval. The so-called extra-articular arthrodesis as a routine treatment of confirmed disease will receive special consideration later. (See page 408.)

Fig. 359.—Left hip disease, showing swelling caused by abscess, also the absence of flexion deformity.

Abscess Complicating Hip Disease.—It may be assumed that a limited collection of the fluid products of the tuberculous process is present in nearly every case of hip disease in which the joint surfaces are actually involved. In many instances it remains within the joint. In a larger proportion of the cases the capsule is perforated, the fluid escapes, and, if the quantity is sufficient to form an appreciable tumor, it is classed as an abscess. Such abscesses may be detected in about 50 per cent. of the cases that are treated under ordinary conditions.

In 1472 final results collected from various sources the percentage of abscess was as appears in the following table:

39 cases reported by Shaffer and Lovett[1]	69.0 per cent.
82 cases reported by Gibney[2]	60.0 "
390 cases reported by Bruns,[3] Tübingen	58.3 "
568 cases reported by König,[4] Göttingen	56.6 "
125 cases reported by Sasse,[5] Berlin	50.0 "
82 cases reported by Prendlsburger,[6] Vienna	51.0 "
98 cases reported by Bradford,[7] Boston	37.0 "
84 cases in private practice, C. F. Taylor[8]	25.0 "
552 cases from Lorenz clinic	47.0 "

Most often the abscess first appears upon the anterior and upper part of the thigh, in the space between the sartorius and tensor vaginæ femoris muscles. In other instances it may be detected first on the inner side of the thigh, or it may form a tumor beneath the gluteal muscles, its situation being influenced by the point at which the capsule is ruptured.

In rare instances the acetabulum may be perforated and a pelvic abscess may be formed, or the pus may find its way into the pelvis along the iliopsoas muscle; and occasionally a pelvic abscess may exist which appears to have no direct communication with the joint.

The weakest point of the capsule is in the anterior wall, where it is covered by the iliopsoas muscle and by its bursa, which often communicate with the joint. A second weak place is in the posterior wall.

In a total of 321 abscesses in hip disease recorded by König[9] the situation was as follows:

On the inner side (inside the femoral artery)	26
Front of the joint (between artery and anterior-superior spine)	126
Region of the trochanter	63
Posterior surface	49
In the pelvis	41
In other situations	16

The tuberculous abscess is a symptom and common accompaniment of hip disease, which, in cases treated under proper conditions, is not of great importance; and yet, on the other hand, it is recognized as a dangerous complication. It is dangerous to life because of

[1] New York Med. Jour., May 21, 1887.
[2] New York Med. Rec., March 2, 1878.
[3] Beitr. z. klin. Chir., 1895, vol. 30.
[4] Die Spec. Tuberculose der Knoch u. Gelenke, Berlin, 1902.
[5] Arbeit aus der Chir, klin. der K. Univ. Berlin (Bergmann's clinic), 1896.
[6] Behand. der Gelenktuberculose und ihre Endresultate aus der klinik Albert, Wien, 1894.
[7] Am. Jour. Med. Sci., December, 1908.
[8] Boston Med. and Surg. Jour., March 6, 1879.
[9] Loc. cit.

the profuse suppuration that may follow infection, and to function because of the adhesions and contractions that may result. This is evident in all statistics. It is clearly shown in those of Bruns. In this list the mortality in the non-suppurative cases was 23 per cent., and of the suppurative 52 per cent.

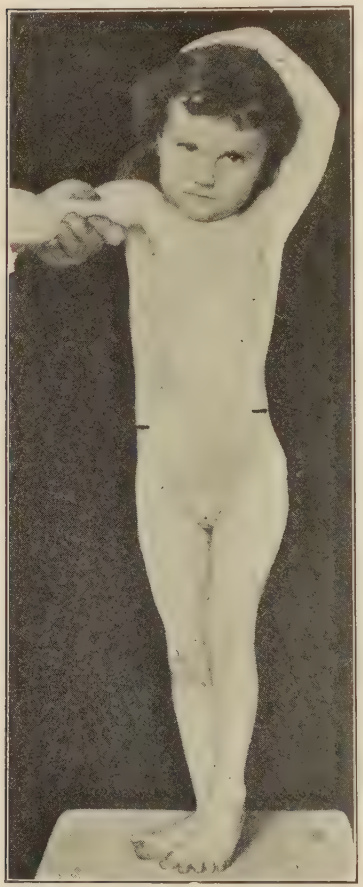

Fig. 360.—Untreated hip disease. Slight flexion and adduction (apparent shortening). The scar of a former abscess is seen on the outer aspect of the thigh.

Significance. — If abscess appears early in the course of the disease, it usually indicates that it is of a destructive character, and that the interior of the joint is involved; therefore function is less likely to be preserved than in those cases in which the disease has been confined to the interior of the bone.

Abscess formation is often preceded by pain, by an increase of muscular spasm and consequent distortion, and often by an elevation of temperature. These acute symptoms subside and a fluctuating swelling appears. It may be inferred that the pain in such a case was due to the tension of the abscess within the capsule and that the relief of pain followed perforation and the escape of the fluid.

In perhaps the larger proportion of cases, more especially those in which the joint has been protected, the appearance of the abscess is not preceded by acute symptoms, such as have been described. Its appearance is long delayed, and but for the swelling its presence would not be suspected.

As the progress of the disease is influenced by the strain and injury to which the part is subjected, so abscess, a symptom of disease, is more common in those cases in which early and efficient treatment has been neglected; for the same reason its subsequent course is directly influenced by the protection that the diseased joint receives.

The danger from abscess is infection. Occasionally the abscess may become infected before an opening forms. Such infection may be inferred when the overlying tissues are hot and sensitive, and when fever is present; but, as a rule, the abscess is sterile until the skin is perforated. If the abscess sac is small and if drainage is efficient, and

especially if communication with the joint has been occluded, infection is of slight consequence. But if before the opening has formed the abscess has perforated intermuscular fasciæ and has extended between the layers of muscles in various directions, infection is likely to cause severe local and constitutional symptoms. The thigh becomes the seat of an infectious cellulitis, pockets of pus form which cannot be properly drained; hectic, emaciation, and loss of appetite follow, and if the profuse discharge of pus persists myaloid degeneration of the internal organs may result. Such patients are said to die of exhaustion, but the cause of exhaustion is an infected abscess.

Treatment.—Admitting that abscess is a symptom whose importance stands in direct relation to the care that has been exercised in the treatment of the disease, and that in the better class of cases the danger from this source is slight, still it is also true that abscess is the chief danger in hip disease. One's views as to the treatment are likely to be influenced by the class of cases with which he is most



Fig. 361.—Abscess in hip disease. The brace is provided with the Thomas ring and with the ratchet extension.

familiar. Some surgeons have advocated absolute non-interference with the symptomatic abscess on the ground that in many instances it finally disappears by spontaneous absorption, or that the communication with the joint may close, so that the danger of infection after an opening has formed is slight. Finally, that the results after non-interference are better than those reported after operative treatment. Others insist that all collections of fluid of this character should be drained as soon as they are discovered, because of the danger of infection before an opening forms and because of the advantage gained by preventing burrowing of pus. Little could be said against this latter course were it not that infection is as common after operative treatment as when a spontaneous opening forms, the only advantage in favor of the artificial opening being that the cavity with which it communicates should be smaller and more direct than when the fluid has undermined the tissues in various directions, but this is offset by the fact that at least 20 per cent. of abscesses disappear without treat-

ment. In fact, as compared with indiscriminate incisions, the let-alone treatment should be preferred when proper after-treatment cannot be assured.

It would appear, however, that the middle course, between the extremes, is the safest, and especially so, as by far the larger number of patients must be treated under conditions that do not permit of proper care. At the Hospital for Ruptured and Crippled abscesses are treated symptomatically. If a swelling appears but remains quiescent and causes no symptoms it is not disturbed. If it enlarges, the tension of the fluid is relieved by aspiration, which may be repeated as required, compression, after the evacuation of the fluid, being applied by means of a pad and bandage. If the contents are of such a nature that aspiration is unsatisfactory, a small incision is made, the contents are expressed and the opening is immediately closed with sutures. This procedure by which infection is avoided may be repeated at intervals. It may be employed also when deep-seated abscess within the joint causes painful tension.

If the abscess is of large size, or if acute symptoms are present, the child is admitted to the hospital. Here the same general principle is followed, but in certain instances it may be thought advisable to explore the joint in addition to opening the abscess. In such cases the incision must be longer, the wound is then closed with superficial and deep sutures, and a firm dressing is applied. This operation, if performed under aseptic precautions, causes no disturbance, and it removes necrotic material which must be an obstacle to spontaneous absorption. In many instances the abscess is permanently cured, although if the condition that induced it remains unchanged fluid will again accumulate, and if so a spontaneous opening will form in the line of the incision. This operation is not a radical cure of the abscess or of the disease; it is simply a means of thorough evacuation for the purpose primarily of accomplishing what the aspirator does only in part. If the abscess has become infected its contents are completely removed, the wound is then packed with gauze, and provision is made for efficient drainage.

In the treatment of abscesses the injection of iodoform emulsion, in connection with the aspiration or incision, has been thoroughly tested. The results, as far as the disappearance of the abscess was concerned, were not as good as from simple aspiration; and as the procedure, being somewhat of the nature of an operation, caused the patients some discomfort and anxiety, it was discontinued. From the clinical stand-point there is little evidence that these injections exercise any particular influence upon the disease, but, theoretically, iodoform should lessen the infectiousness of the tuberculous fluid, and by local irritation stimulate the growth of granulation tissue. (See Calot's Injections.)

Sinuses.—Treatment.—When the disease is active the sinuses that serve as drains should not be disturbed. And in the advanced cases when disease is quiescent and when the tissues about the joint are of

MEDICAL LIBRARY BOSTON CITY HOSPITAL

the peculiar, resistant, "porky" consistency, active measures, either for the purpose of closing sinuses or for the correction of deformity, should be deferred. In many instances, however, sinuses persist as tuberculous fistulæ, serving no useful purpose. In this class the complete removal of the infected tissue by excision or by thorough curetting is the most effective remedy. The various applications of pure carbolic acid, solution of salicylic acid, iodoform emulsion, balsam of Peru and the like are of some service. The most satisfactory supplemental treatment of this class is Beck's mixture. Sufficient is injected to completely fill the sinus, which if it is no longer necessary as a drain often closes, the mixture being gradually absorbed, otherwise the injected material is extruded.

Exploratory Operations.—In certain instances exploratory operations may be indicated. If, for example, pain and swelling indicate tension within the capsule it may be relieved by a small direct incision or the joint may be explored with the possibility of finding a localized focus of disease that may be removed.

The joint may be opened by an anterior-lateral incision, beginning one inch to the outer side of the anterior-superior spine and extending downward about three inches. This exposes the line of junction between the tensor vaginæ femoris and the gluteus medius muscles. When these are separated from one another the anterior surface of the capsule of the joint is laid bare. If more room is required the Smith-Peterson exposure may be employed. The capsule is then incised in the line of the neck and through the incision the head of the bone may be extruded by rotating the limb outward and extending it. By this means the character of the disease may be ascertained and in certain instances localized foci in the neck or in the head of the bone may be removed. If the operation is undertaken primarily for the removal of disease localized in the neck, the incision (Fig. 362), with the division and upward displacement of the trochanter, gives better access to the joint. The wound is then closed or drained as may seem advisable. By such intervention the course of the disease may be shortened in some instances, although cure by this means is unusual.

Temporary anterior dislocation of the head of the femur by means of the anterior-lateral incision may be of value in acute and painful disease, since the symptoms are usually relieved by spontaneous displacement. Posterior dislocation for this purpose has been performed by Bradford in several cases with satisfactory results, the bone being again replaced when the disease had become quiescent.[1] The object of this operation is to remove the apposing bones from direct contact, and to relieve the muscular spasm that accompanies acute disease.

Exploratory operations may be of special value in the later stages of the disease, to ascertain the cause of long-continued suppuration, or of abnormal delay in repair, which may be due to detached or adherent fragments of necrosed bone within the joint. This point is

[1] Tr. Am. Orthop. Assn., vol. 13.

illustrated by the statistics of 61 cases of hip disease treated by excision by Poor.[1] In 15 of these loose bone was found in the joint, and in 7 the head of the bone was detached.

In 98 cases investigated by Lehman[2] at the Würzburg clinic sequestra were present in 20.4 per cent., and in 70 per cent. of 88 cases treated by Riedel.[3]

An exploration of the joint by one familiar with surgical technic should be free from danger, and it may be of much value. Direct removal of the disease by tunneling through the trochanter has been advocated by Huntington. This might be successful if the focus were confined to the neck and were clearly defined in the roentgen-ray picture, but such cases are very exceptional.

Excision of the Hip.—The operation of excision is now classed as a treatment of necessity in certain cases, usually those in which recovery under conservative treatment is considered very doubtful. For example, when there is progressive failure in health; when it is impossible to drain the joint effectively after infection; when there is evidence of extension of the disease to the shaft of the femur or to the pelvic cavity, or when other serious complications exist.

In certain instances the excision may follow an exploratory operation; in such cases the anterior-lateral incision may be employed and the neck and head of the bone only may be removed. In this operation the diseased tissue is removed as thoroughly as possible with the sharp spoon, by scrubbing with iodoformized gauze, and by flushing with hot water. If the joint is not infected it is dried; iodoform emulsion may be injected or the pure carbolic acid may be applied, and the various tissues are then sewed in layers; pressure is applied, the aim being to secure immediate union.

In typical cases the operation is performed because of extensive disease and infected abscess, and in such instances usually the entire upper extremity of the bone to the trochanter minor is removed.

A satisfactory method is that of König.

An incision about five inches in length is made in a line joining the trochanter and the posterior-inferior spine of the ilium. About two-thirds of the length is above and one-third over the trochanter. The incision is deepened to expose the capsule and the surface of the trochanter, from which one removes the insertion of the gluteus maximus and the tendons of the medius and minimus. The muscles are separated in the line of the incision and the capsule is widely opened. With a thick, strong knife he detaches all the muscular attachments to the anterior margin of the trochanter, while the limb is rotated outward, removing, if possible, a thin section of periosteum and bone. The same process is then repeated on the posterior surface, the limb being rotated inward. The trochanter is then removed.

The acetabular insertion of the capsule, together with the adjoining

[1] New York Med. Jour., April 23, 1892.
[2] Inaug. Diss., Würzburg, 1896.
[3] Centralbl. f. Chir., 1893, vol. **20**, Nos. 7 and 8.

upper border of the acetabulum, is then cut away and the neck of the femur is separated from the shaft with a saw or chisel. All the diseased parts are then removed, including the acetabular wall and adjoining bone, if necessary. The wound is partly closed with drainage, and the extremity of the femur is placed within the acetabulum, where it should be retained for a time by a plaster bandage or Thomas brace provided with traction straps. When the patient begins to walk a hip splint or other support is used for a time to prevent deformity. One of the most efficient supports of this class is the short spica, the limb being fixed in an attitude of overextension and moderate abduction for many months, with the aim of obtaining bony or fibrous anchylosis.

Another form of incision is that of Rydygier,[1] shown in Fig. 362.

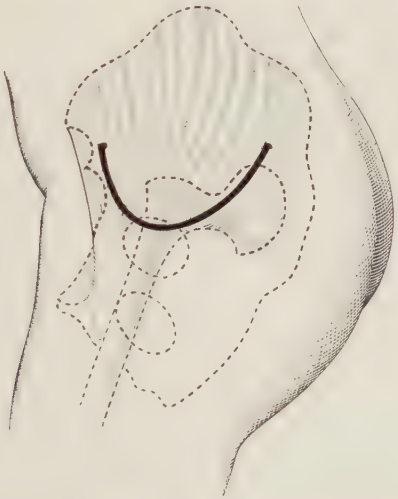

Fig. 362.—Rydygier's incision for excision of the hip.

The flap is lifted, the trochanter major is cut through and with its attached muscles turned upward. The capsule is then opened and the femur is dislocated for inspection. All the diseased parts, including the entire acetabulum, if necessary, together with the capsule, are then removed. Complete removal of the acetabulum is indicated when it is perforated, a procedure particularly advocated by Bardenheuer.

The success or failure of excision of the hip as a life-saving operation, provided the diseased bone has been removed, is determined by the after-treatment, and in this drainage is the first essential. The opening must be large and the shaft of the bone must be drawn down by efficient traction, so that it may not obstruct the opening, and the exuberant granulations must be removed from time to time. Short

[1] Mosetig-Moorhof: Wien. klin. Wchnschr. 1905, No. 20.

glass drainage tubes of diameter up to one and one-half inches as suggested by Phelps may be used with advantage. Through such a tube or speculum the gauze is inserted, the opening permitting inspection.

The importance of an open-air life (the sun treatment) after these operations can hardly be exaggerated. The lack of this, the inefficiency of the after-treatment in securing proper drainage, and the postponement of the operation until amyloid changes are advanced explain the unsatisfactory character of the results.

The functional results after excision in this class of cases are not as good as those that may be obtained when the operation has been performed at an earlier period. If motion is retained there is usually a

FIG. 363.—Hyperextension at the knee following disease of the hip-joint and its treatment by the traction brace.

corresponding weakness of weight-bearing function. In many instances there is upward displacement of the shaft of the femur upon the ilium with consequent flexion and adduction deformity, while in a third class of cases a movable joint of sufficient strength may be preserved. The ultimate shortening is considerably greater than after conservative treatment. This is accounted for by the upward displacement of the femur and by the removal of the two epiphyses of its upper extremity.

In a period of twelve years, 1888 to 1899 inclusive, 149 operations of excision were performed at the Hospital for Ruptured and Crippled. During this time 1283 cases of hip disease were treated in the wards and 1870 new cases were recorded in the out-patient department.

Thus the operation was performed in 11.6 per cent. of those in the hospital, but the relative frequency of the operation in the entire number of patients under treatment was considerably less than this. In 99 of the 119 cases the later results of the operation were ascertained. Of these 52 were dead and 47 were living. Of the 52 deaths 9 were due directly to the operation, "shock;" 28 were caused by exhaustion (persistent suppuration); 9 by tuberculous meningitis; 7 by other causes. Thirty-seven deaths occurred within six months and 10 others within one year of the operation. Of the 47 patients living at the time of the investigation, 26 were cured. Of the remaining number about one-half were in poor condition, so that recovery could not be expected. It is evident that in a large proportion of the cases the operation was unsuccessful as a life-saving measure, since suppuration persisted.

FIG. 364.—Extreme deformity after hip disease, showing the attitude before operation. (See Figs. 365 and 366.)

Amputation. — Amputation at the hip should follow excision if suppuration persists and if the condition of the patient does not improve, provided the internal organs are not hopelessly diseased. The operation of amputation after complete excision is a simple procedure and it should not be attended with great danger.

FIG. 365.—The favorite attitude in recumbency. (See Fig. 364.)

Correction of Deformity.—The various methods of correcting deformity during the active stages of the disease have been described, and the importance of preventing deformity throughout the entire course of treatment has been emphasized. At the present time, for one reason or another, deformity from this cause is very common, either because its importance is not appreciated or because it is considered as a necessary concomitant of the disease, treated by apparatus, as it is in the natural cure. At all events, in many instances it is allowed to persist until the accommodative changes about the diseased joint have fixed the limb in the deformed position.



FIG. 366.—After correction by osteotomy and division of the contracted tissues. (Gibney.) (See Figs. 364 and 365.)

In this class of cases, in which the muscles are structurally shortened and in part transformed to fibrous tissue, and in which the anterior wall of the capsule has become retracted and adherent to the surrounding parts, forcible reduction under anesthesia, or osteotomy, may be required. If the disease is quiescent or cured, if the head of the femur or what remains of it is in the normal position, and if a fair range of motion remains, forcible reduction after division of the bands of fascia or the muscles that hold the limb in the deformed position is advisable.

In cases in which the head of the bone is destroyed, motion persisting (pathological excision) one may attempt to secure an anterior transposition of the upper extremity of the femur, and to attain this result one proceeds as in reducing or transposing the congenitally displaced hip — by longitudinal traction, by forcible abduction, combined with massage of the adductors, and, finally, by gradual extension—preceded usually by division of the resistant parts about the anterior superior spine. The limb is then fixed by a plaster spica in an attitude of moderate abduction and overextension. Later the abduction is lessened, but the overextended position is maintained for many months, and is assured by passive movements after the support is removed. As a rule however the bifurcation or reconstruction operation is more effective. These procedures are described elsewhere.

Femoral Osteotomy.—If the deformity is fixed by bony anchylosis or by firm, fibrous adhesions within the joint; or if it is feared that violence may stimulate dormant disease; or if there is such a degree of upward displacement of the femur upon the pelvis that the deformity

is likely to recur after replacement, it is better to correct the deformity by an osteotomy of the femur.

The patient, having been prepared for operation, is turned upon the side and a sand-bag is placed between the thighs. A small osteotome, about the shape of a lead-pencil, of which one extremity is flattened to a cutting edge (Vance's instrument), is pushed directly through the soft parts to the femur at a point about two inches below the apex of the trochanter. It is turned until its cutting edge is at a right angle to the shaft and it is then driven through the cortical substance of the bone. When it has penetrated at one point it is withdrawn, and adjoining portions are cut until about half the circumference is divided, when with slight force the bone may be fractured. If the deformity is of long standing, division of the contracted tissues in the adductor region and below the anterior-superior spine may be required.

The limb is then fixed in complete extension and moderate abduction by a long plaster spica bandage, which should remain in position for several months, although the patient may be allowed to bear weight on the limb a few weeks after the operation. The long spica may be replaced by the short one at the end of two months. The latter or some similar appliance should be used until tests show that there is no longer danger of recurrence of the deformity.

The advantages of the subcutaneous method are simplicity and since it is essentially a fracture of the weakened bone there is but little tendency toward displacement of the fragments. No dressings are required, except a pad of gauze over the minute opening. If there is anchylosis between the femur and the pelvis no support will be required after the bone has united, but if there is motion in the joint some fixative appliance should be employed for a time to prevent recurrence of the deformity.

An open operation is preferable for older subjects, the femur being divided with a curved chisel to prevent antero-posterior displacement of the fractured surfaces. There are other cases of this type in which long after apparent cure the pain returns, apparently caused by injury or by friction. In such cases the Lorenz bifurcation operation, may be indicated. After dividing the femur in an oblique direction one aims to force the pointed extremity of the shaft into contact with the capsule of the joint below the upper fragment and thus to gain a new base of support and relieve the old articulation of the strain of direct weight-bearing, as contrasted with osteotomy, of which the object is simply the correction of deformity. In cases in which motion is preserved, and yet because of depression or shortening of the femoral neck abduction is checked by contact of the trochanter with the pelvis, cuneiform osteotomy as described in the treatment of coxa vara, should be performed, and in selected cases in which motion is retained, but in which abduction is checked by contact of the trochanter and the rim of the acetabulum, the reconstruction operation should be considered (Fig. 367). (See Reconstruction Operation.)

Extra-articular Arthrodesis.—The best assurance of permanent cure of a diseased joint is its complete obliteration by bony anchylosis. This is a comparatively rare spontaneous result in tuberculous disease of the hip, and various attempts have been made in the past to secure fixation by operation, more especially in the cases in adult life in which there is little prospect of natural cure and in the cases in childhood in which destructive changes are so extreme as to prevent useful function.

Recently operative fixation as a routine treatment in cases in which the diagnosis has been confirmed by examination of the tissues has been

FIG. 367.—The correction of adduction deformity by cuneiform osteotomy showing the new bearing surfaces.

advocated by Hibbs. His contention is based on personal experience with treatment by the traction hip splint, which for many years was the standard routine at the Orthopaedic Hospital.

Of 150 patients thus treated, 1904–1921, 36 or 24 per cent. were dead. In 71 cases the disease was still active. In 41 cases it was quiescent and in but 2 was there a useful range of motion.[1]

While it may be admitted that firm ankylosis assures the best results in advanced cases in which the destructive disease has irremediably injured the function of the joint, it does not follow that the fixation operation is indicated before the natural resources have been tested.

Anchylosis is far more difficult to attain at the hip than at other joints, because only small areas of bone can be brought into direct

[1] Smith and Watters: Jour. Am. Med. Assn., January 21, 1928.

MEDICAL LIBRARY
BOSTON CITY HOSPITAL

contact. It is of advantage if fixation may be attained without opening the diseased joint.[1] A practicable method is that described by Hibbs,[2] modified from that of Hass[3] (Fig. 368), which is in a sense extra-articular, corresponding to operative fixation of the spine (Fig. 369).

An incision is made from above downward, beginning 2 inches behind the anterior-superior spine, crossing the great trochanter and ending at a point 3 inches below its base. The capsule of the joint is exposed by separating the muscles in the interval between the

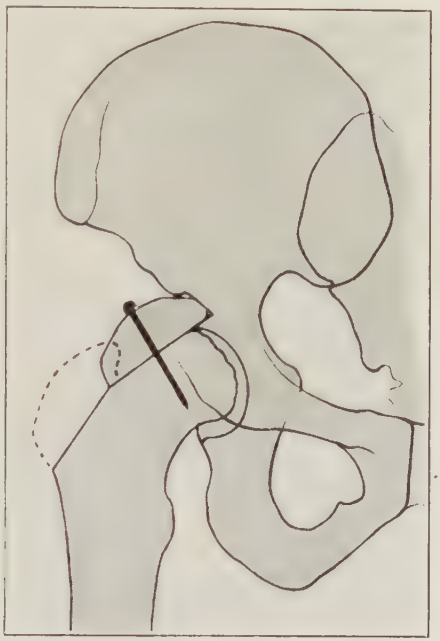

FIG. 368.—Haas' method of extra-articular fusion.

gluteus medius and maximus. The anterior three-fourths of the trochanter, including 2 inches of the shaft, is cut through and separated in the form of a wedge. The capsule is then incised and the cortex removed from the neck. The upper part of the acetabular rim and adjoining bone are cut and pried upward with a chisel and into this opening the lower end of the separated and reversed trochanteric wedge is placed lying in contact with the femoral neck and held in place by the remainder of the trochanter. The available periosteal tissues of the pelvis and femur are attached to one another. The wound is closed and a double spica is applied. The position of

[1] For a full description of the various operations see L'arthodise de la Hanche daus la Coxalgie, Felix Béard, Lyon, 1929.

[2] Jour. Bone and Joint Surg., July, 1926.

[3] Ztschr f. Chir, 1922, No. 40, 1922.

election of the limb is about 20 degrees of abduction and flexion. In cases of marked distortion, however, in which correction would involve violence to the diseased joint the limb is fixed in the attitude of deform-

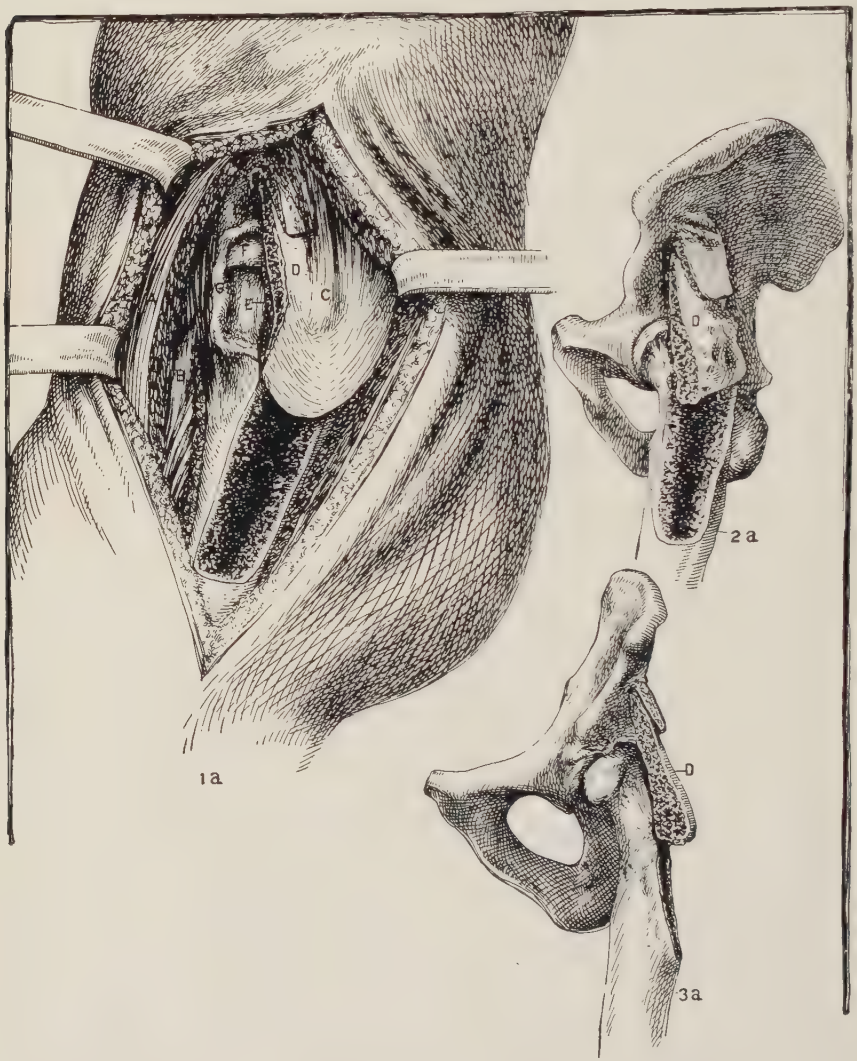

FIG. 369.—A, tensor femoris muscle divided; B, vastus muscle divided; C, gluteus medius and minimus muscles, which were cut through anteriorly and above trochanter; D, in 1a, 2a and 3a trochanter turned up with lower end under iliac bone flap; E, raw bone superior surface of neck of femur; F, head of femur in acetabulum; G, capsule of joint. (Hibbs.)

ity with the aim of correcting it later by osteotomy. In 90 per cent. of the 20 cases reported bony anchylosis was attained with complete relief of the symptoms.

Prognosis.—Mortality.—The direct mortality of hip disease is determined, in great degree, by the immediate or remote effects of abscess. This is illustrated by the statistics of Bruns, in which the mortality from all causes of the non-suppurative cases was 23 per cent., as compared with 52 per cent. in those in whom suppuration was present.

The mortality among the patients treated at many of the German clinics is much higher than in the corresponding class in this country.

At Tübingen, according to Wagner,[1] it was 40 per cent.

At Kiel, according to Mummelthy, it was 48.59 per cent. in non-operative cases and 53.96 per cent. in operative cases.

At Marburg, according to Marsch, it was 35 per cent. in non-operative cases and 40.4 per cent. in operative cases.

At Heidelberg, according to Huismans,[2] it was 46.6 per cent. in non-operative cases and 58 per cent. in operative cases.

At Zurich, according to Pedolin,[3] it was 37.7 per cent. in non-operative cases and 54 per cent. in operative cases.

At Vienna, according to Prendlsburger,[4] it was 17 per cent. in all cases.

In 552 cases from Lorenz's clinic it was 18 per cent.

At Göttingen, according to König,[5] 40.3 per cent.

Dollinger[6] estimates the mortality from all causes in German clinics as 48.8 per cent. In non-suppurative cases as 16.5 per cent.

In a total of 636 cases treated by conservative methods by Rabl, 1859 to 1894, definite results were ascertained in 519;[7] 335 were hospital cases. Of these 216 were cured (64.4 per cent.), 70 died (20.8 per cent.), and 49 (14.4 per cent.) were still under treatment; 184 were treated as out-patients. Of these, 132 were cured (71.5 per cent.), 35 died (19.2 per cent.), and 17 (9.2 per cent.) remained under treatment.

Ménard[8] in a series of 1321 cases treated under favorable conditions estimates the mortality at 7 per cent.

In 288 cases treated at the Hospital for Ruptured and Crippled, New York, reported by Gibney,[9] the death-rate was 12.5 per cent.

In 93 final results of cases treated at the Boston Children's Hospital there were 6 deaths, 6.4 per cent.[10]

In private practice the statistical reports of final results show the death-rate to be extremely small. C. F. Taylor,[11] 94 cases, including 24 in which suppuration was present, 3 deaths. L. A. Sayre,[12] 212 cases, 5 deaths. Lorenz,[13] 60 cases, with 3 deaths.

In the clinics of this country the death-rate has been estimated to

[1] Beitr. z. klin. Chir., 1895, vol. **13**.
[2] Quoted by Binder: Ztschr. f. orthop. Chir., 1889, Band **7**, Heft 2 and 3.
[3] Centralbl. f. Chir., July 25, 1896, No. 30. [4] Loc. cit.
[5] König: Das Hoeftgelenk, Berlin, 1902. [6] Handb. d. orthop. Chir., 1906.
[7] Zur Conserv. Behand. der tuberculosen Knochen und Gelenksleiden, J. Rabl, Leipzig und Wien, 1895.
[8] Étude sur Coxalgie, 1907. [9] New York Med. Jour., July and August, 1877.
[10] Bradford: Loc. cit. [11] Boston Med. and Surg. Jour., March 6, 1879.
[12] New York Med. Jour., April 30, 1892. [13] Wien. Klinik, 1892, 10 and 11.

be from 10 to 15 per cent., a rate of mortality much lower than that reported from those abroad. This is accounted for in part by the fact that patients are of a better class and in part because they receive earlier and more efficient mechanical protection.

The causes of death, according to Wagner's statistics of 124 cases, were as follows:

Hip disease	35
General tuberculosis	37
Tuberculous meningitis	13
Tuberculosis of the lungs	11
Acute miliary tuberculosis	5
Amyloid degeneration	8
Septic infection	12
Intercurrent disease	3
	124

Thirty per cent. of the deaths occurred in the first year of the disease, 26 per cent. in the second year, and 20.4 per cent. in the third year.

The percentage of recovery was 65 per cent. of those in the first decade of life, 56 per cent. of those in the second, and but 28 per cent. of those in the third decade.

The causes of death in 50 cases among 778 patients treated at the New York Orthopaedic Dispensary and Hospital during the years 1877 to 1884 were:[1]

Tuberculous meningitis	20
Amyloid degeneration	5
Exhaustion	3
Tuberculosis of the lungs	3
Tuberculous peritonitis	1
Septicemia	1
Convulsions	1
Unknown	16
	50

Of 96 deaths recorded at the Alexandra Hospital, London (a mortality of about 26 per cent. of the cases treated), the causes were:

Tuberculous meningitis	16.1 per cent.
Albuminuria and dropsy	20.8 "
Tuberculosis of the lungs	8.3 "
Exhaustion	9.4 "
Erysipelas and pyemia	3.1 "
After operation	9.4 "
Intercurrent diseases	7.3 "
Unknown	25.0 "
	99.4 "

The direct mortality of hip disease should include all deaths due to operation, those caused by exhaustion, and amyloid degeneration which is almost always the result of profuse suppuration secondary to pyogenic infection. Tuberculous meningitis, a common and apparently an unavoidable cause of death, is not necessarily a complication

[1] Shaffer and Lovett: New York Med. Jour., May 21, 1887.

of the local disease, except in so far as a lowered vitality may predispose the patient to it, since it may have been due to new infection or induced by the primary focus which preceded the tuberculosis of the hip.

It is believed that operative interference is sometimes the direct cause of tuberculous meningitis, and it is of interest in this connection to note that 20 of 50 deaths, or, rather of 34, in which the cause of death was known (58 per cent.), were due to this complication among the cases treated at the New York Orthopaedic Dispensary and Hospital, where no operations were performed.[1] While of 52 deaths in a total of 99 cases treated at the Hospital for Ruptured and Crippled, in which excision was performed, but 9 were caused by tuberculous meningitis.[2]

The normal death-rate among cases under fair hygienic conditions is illustrated by statistics from the Hospital for Ruptured and Crippled at a time when no operative or mechanical treatment was employed.[3] This was 12.5 per cent.; 4.5 per cent. from exhaustion, 4.5 per cent. from amyloid degeneration, 1.75 per cent., from tuberculous meningitis, 1.75 per cent. from intercurrent diseases.

Thus nearly 75 per cent. of the deaths were due more or less directly to suppuration.

Functional Results.—In a certain proportion of cases perfect function may be retained, the proportion depending upon the accuracy of diagnosis in excluding mild types of arthritis or affections which are often mistaken for tuberculous disease; upon the situation and the extent of the disease, and upon the timeliness and efficiency of the treatment.

Recovery with perfect function which implies a normal joint and therefore a limited area of disease is not a test of relative efficiency of mechanical treatment since approximately the same result might be attained by any form of adequate protection.

In a total of 280 cases from the private practice of Dr. L. A. Sayre,[4] in which the final results were known, 73, or 26 per cent., recovered with perfect motion, and 120 or 42 per cent., retained good motion. These results are far better than may be expected in the ordinary class of cases in which the diagnosis has been confirmed by modern methods.

In a series of 51 cases illustrating final results of treatment at the Boston Children's Hospital, there was practical fixation at the joint in 33 (60 per cent.). In 16 perfect motion was retained. Adduction was present in 21 (40 per cent.). The trochanter was above Nélaton's line in 19 (37 per cent.[5]).

In 35 final results treated by the traction hip splint at the New York Orthopaedic Dispensary practical fixation was present in 74 per

[1] Shaffer and Lovett: New York Med. Jour., May 21, 1887.
[2] Townsend: Med. News, June 26, 1896.
[3] Gibney: New York Med. Rec., March 2, 1878.
[4] New York Med. Jour., April 30, 1892.
[5] Bradford and Soutter: Loc. cit.

cent. of the patients.[1] The report of a recent investigation of cases treated at the same institution is presented in detail.[2]

HIP-JOINT DISEASE.

Total number of cases of hip-joint disease treated	461
Number of boys treated	236
Number of girls treated	225
Number of cases with right hip involved	242
Number of cases with left hip involved	219
Average duration of disease on admission, years	2
Average age on admission, years	7
Average duration of treatment, years	7½
Number patients cured	171
Number under treatment at present time	44
Number died	60
Number could not be located	215
Of cases cured, number with less than 1 inch shortening	40
Number with less than 2 inches shortening	59
Number with less than 3 inches shortening	60
Number with more than 3 inches shortening	21
Number with adduction and flexion deformity combined	36
Number with flexion without adduction deformity	17
Number with bony ankylosis	13
Number with fibrous ankylosis	49
Number with no destruction of femoral head (Roentgen examination)	32
Number with partial destruction of femoral head (Roentgen examination)	86
Number with complete destruction of femoral head (Roentgen examination)	88
Number with partial acetabular destruction but no evidence of disease of femoral head (Roentgen examination)	6
Number with dislocation (Roentgen examination)	3
Number with thigh flexion from 15 to 90 degrees	73
Number with more than 90 degrees' thigh flexion	45
Number with perfect function without deformity	35
Number with relaxation of knee-joint	20

The effect of mechanical treatment and of the various measures employed for the correction of deformity is well illustrated in two series of ultimate results in cases treated at the Hospital for Ruptured and Crippled, reported by Gibney.[3] In the first series of 80 cases no mechanical or operative measures were employed, the treatment being simply hygienic and symptomatic; the results therefore represent natural cure under supervision. The duration of the disease was three years in 23; three to six years in 28; six to ten years in 16, and fifteen years in 1 case.

In 35 cases the shortening was two inches or more, and in nearly every case there was more or less deformity, viz.:

In 2 there was flexion to	90
In 3 there was flexion to	110
In 3 there was flexion to	120
In 19 there was flexion to	135
In 19 there was flexion to	145
In 18 there was flexion to	150
In 11 there was flexion to	160–170

[1] Loc. cit.

[2] Humphries and Durham: Jour. Am. Med. Assn., January 27, 1917.

[3] Loc. cit.

In 4 no estimate was made. Distortions other than flexion are not specified.

In 12 instances motion was retained of from 15 to 90 degrees.

In the second series[1] of 107 cured cases, mechanical and operative treatment was employed, although the protection assured was in many instances far from efficient. In many of these cases the disease was in an advanced stage, and deformity was present in more than half of the number when treatment was begun, and yet all of them recovered without marked flexion and presumably without adduction, as this deformity is not mentioned.

No flexion	47
Flexion of 10 degrees	30
Flexion of 10 to 20 degrees	20
Flexion of 20 to 30 degrees	10
	107

In 69 cases the shortening was one inch or less, 35 having no shortening. In 38 it was more than an inch.

Perfect motion was retained in	13
Good motion was retained in	22
Limited motion was retained in	41
There was anchylosis in	31
	107

As has been stated, the mechanical treatment in these cases was not sufficiently effective to prevent deformity, and to attain these results osteotomy with or without division of contracted tissues was performed in 19 cases, forcible correction with or without tenotomy in 30 cases, and in 4 cases the joint was excised.

If the joint has been actually invaded by disease so that a part of its articulating surface has been destroyed, motion must be impeded both in area and quality. In such cases the joint is somewhat weakened, and it is often sensitive, although in many instances not to the extent of interfering seriously with the ability of the patient. In this class discomfort in damp weather or pain on overexertion is experienced, symptoms similar to those complained of by rheumatic subjects. Absolute anchylosis is therefore a far more satisfactory result in patients of the laboring class.

Simple shortening, due to retardation of growth, unaccompanied by deformity, is of comparatively little importance. Firm anchylosis in a symmetrical position ensures a strong and useful limb, the flexibility of the lumbar region compensating for the loss of motion at the joint. In such cases the disability may be very slight, and the effect of the loss of motion may be more apparent in the sitting than in the erect posture, for the patient must, as it were, sit upon his back, an attitude which perceptibly reduces the sitting height.

[1] Gibney, Waterman, and Reynolds: Tr. Am. Orthop. Assn., 1898, vol. 11.

Flexion, if of moderate degree, does not cause disability, but flexion of more than 30 degrees increases the lumbar lordosis and makes the buttock prominent with erect posture the deformity so characteristic of the natural cure (Fig. 297). Great flexion, for example of 60 to 90 degrees, causes an exaggerated lordosis which is almost always a source of pain or discomfort to a patient who is obliged to stand much of the time.

Abduction, unless of an extreme degree, is of advantage since it serves as a compensation for actual shortening of the limb.

Adduction, on the other hand, which necessitates an upward tilting of the pelvis in order to restore the parallelism of the limbs, is the most disastrous of all the distortions, since it causes a practical shortening often greater than that due to the destructive effects of the disease.

The motion that is retained after recovery from hip disease is usually considered as the test of successful treatment. This is by no means the fact, for in many instances motion is preserved because the joint is destroyed and because what remains of the upper extremity of the femur is supported by the tissues on the dorsum of the ilium—a form of pathological dislocation. Motion thus explained is an indication of inefficient treatment rather than of success, for in such cases deformity is almost always present, and the support is insecure.

Deformity is far more disabling than loss of motion, and the best safeguard against final deformity is to prevent it during treatment, and to retain so far as may be the joint surfaces in proper relation to one another. Whatever motion is preserved will then be of service to the patient, and even if anchylosis follows the result may still be classed as good.

Deformities of Other Parts Caused by Hip Disease.—Deformities of other parts are often observed as secondary results of hip disease, usually in cases that have not received proper treatment. In the spine an exaggerated *lordosis* as a compensation for flexion is not uncommon, and *lateral curvature* may follow distortion of the pelvis caused by adduction. In the limb *knock-knee* may follow persistent adduction of the thigh, or it may be an effect of laxity of the ligaments without such distortion. Another deformity is *genu recurvatum*. This is particularly marked in cases treated by the traction hip brace in which weight-bearing has been prevented for long periods and as a compensation for deformity. It is supposed to be one of the effects of traction, but it is also observed in cases in which traction has never been employed. In cases in which the muscular atrophy is great, *laxity of the ligaments* of the knee-joint is common, and not infrequently subluxation of the tibia also. A slight degree of *equinus* with accompanying exaggeration of the arch is not uncommon among patients who have been treated by the traction apparatus, in which the foot being pendent is inclined downward to guide the brace in walking. Practically speaking, all these secondary deformities may be prevented by proper supervision of the patient during the period of treatment.

As a rule patients who have recovered from hip disease finally discard all apparatus, or at most use only a cane as a support, and many prefer to walk habitually on the toe rather than to equalize the length of the limbs by a special shoe.

By far the larger number of this class, having accommodated themselves to whatever weakness and distortion may be present, are able to undertake the ordinary occupations of life. Of the cases reported by Bradford and Soutter 98 per cent. of the patients recovered with useful limbs. Of the patients treated at the New York Orthopaedic Dispensary and Hospital in the report by Shaffer and Lovett already referred to, in whom the final results as regards motion and symmetry were certainly not above the average, it is stated that there was not a single individual who was incapacitated from doing a full day's work at his or her trade or occupation. None used crutches and but one used a cane.

CHAPTER VIII.

NON-TUBERCULOUS AFFECTIONS OF THE HIP-JOINT.

The relative frequency and importance of the various affections of the hip-joint that cause disability are indicated by the following statistics of König's[1] clinic at Göttingen:

Tuberculous disease	568	=	75 per cent.
Infectious arthritis following typhoid fever:			
Scarlatina and the like	110		
Gonorrheal arthritis	30		
Arthritis deformans	22		
Injuries	11		
Contractions, cause unknown	6	=	+25 per cent.
Coxa vara	5		
Tumors	2		
Pyemic suppuration	3		
	757		

Several of the affections enumerated are very uncommon in childhood, while injury and coxa vara are relatively more important. Coxa vara and fracture of the neck of the femur in early life are considered at length in Chapter XV.

TRAUMATISMS AT THE HIP-JOINT.

It is probable that injury at the hip-joint, or functional strains, may induce congestion about the epiphyseal cartilage of the head of the femur. In this class of cases there is usually discomfort at night after overexertion, "growing pain," and there may be a limp and restriction of motion. These symptoms may disappear in a few days or they may recur from time to time. If the injury is more severe there may be local sensitiveness and even swelling—synovitis. This congestion, with the lessened local resistance induced by it, may be a predisposing cause of tuberculous disease. Injury of the cartilage and of the underlying bone may cause persistent discomfort, limitation of motion and eventually nutritive changes in the joint (arthritis deformans of adolescence). Undoubtedly cases of this type are sometimes mistaken for hip disease and go to swell the number of favorable results ascribed to one or another system of treatment.

Treatment.—All cases of this class require careful supervision. Strains or other injuries in young children are best treated by a supporting bandage and by rest in bed until the symptoms disappear. If the sensitive condition persists, protective treatment, by a short plaster bandage, should be employed, the diagnosis being reserved

[1] Das Hüftgelenk, Berlin, 1902.

MEDICAL LIBRARY BOSTON CITY HOSPITAL

until it is made clear by the progress of the case. Chronic synovitis of the hip-joint, especially in the adolescent or adult, unless it is a direct result of injury, is usually tuberculous in character.

ARTHRITIS.

Acute Infectious Arthritis.—Acute "Epiphysitis" at Hip-joint.—Acute arthritis, caused by infection with pyogenic germs, is not uncommon in infancy and early childhood. It is sometimes described as epiphysitis although the infection usually involves the extremity of the diaphysis as in other forms of osteomyelitis. Of 52 cases in which but a single joint was involved the hip was affected in 26.[1] The primary infection may be a wound, suppurating ear and the like; it may follow pneumonia or one of the exanthemata, and its location may be determined by injury.

Symptoms.—The symptoms are of sudden onset, accompanied usually by high fever and prostration. The hip becomes swollen, hot, and sensitive both to motion and pressure.

Treatment.—The treatment is early and free incision and efficient drainage, the limb being afterward supported by some form of splint. In neglected cases a spontaneous opening forms and suppuration ordinarily persists for several months; the epiphysis is usually destroyed in whole or in part, and in consequence the joint becomes somewhat loose and flail-like (Fig. 370). Many of these cases seen in later years, but for the history and the scars about the joint, might be mistaken for congenital dislocation. In certain instances the symptoms are less acute and the diagnosis from tuberculous disease can be made positively only after a bacteriological examination of the fluid that may be removed from the joint by aspiration.

FIG. 370.—The later effect of acute epiphysitis of the right hip at three months of age. The scar is shown.

In the class of cases in which the disease is confined to one joint and in which the shaft of the bone is not involved, the prognosis is good if efficient drainage can be established. In 12 cases treated at the Hospital for Ruptured and Crippled there were 3 deaths.[2]

[1] Townsend: Am. Jour. Med. Sci., January, 1890.
[2] Townsend: Loc. cit.

During the active stage of the disease the limb should be supported in extension and abduction to prevent displacement. If the head of the femur has been destroyed there is usually upward and backward dislocation. This induces flexion and adduction of the limb and great disability. In such cases one should, under anesthesia, force the femur forward to the neighborhood of the anterior-superior spine and to fix it there for a long period by the application of a Lorenz spica bandage applied with the limb in an attitude of abduction and hyperextension. The operation is in detail similar to the Lorenz method for replacing the congenital dislocation. (See Congenital Dislocation of the Hip.) If this is unsuccessful the upper extremity of the femur may be implanted in the acetabulum by open operation, or the Lorenz bifurcation operation may be performed. (See Reconstruction Operation.)

Subacute Arthritis.—In the forms of arthritis that may complicate infectious diseases several joints are usually involved, and the affection is often subacute in character.

Undoubtedly there are mild cases of infection at the hip-joint terminating in partial or complete recovery. In such cases, often classed as rheumatism, there is usually some infiltration about the hip, flexion deformity, limitation of motion, and pain or discomfort referred to the affected joint. A satisfactory treatment is the application of ichthyol ointment in a strength of about 25 per cent., the joint being fixed by a posterior wire splint or light Thomas hip brace.

Hoke has reported cases of what he calls toxic arthritis due to intestinal putrefaction. Prompt evacuation of the bowels and regulation of the diet are the first indications in the treatment of cases of this type.

Gonococcal Arthritis.—Gonococcal arthritis of this joint is an affection not uncommon in adult life, and in its symptoms and effects it may resemble tuberculous disease or perhaps more closely osteoarthritis. The treatment of infectious arthritis in general is discussed elsewhere. Deformity should be corrected by rest in bed with traction, and protective treatment should be employed while the sensitiveness persists. The short spica plaster bandage, if properly applied, is a satisfactory support.

SPONTANEOUS DISLOCATION OF THE HIP-JOINT.

If the hip-joint becomes distended with fluid the capsule may be ruptured and sudden displacement may occur.

Degez[1] has collected from literature 79 cases of this character. The displacement occurred in the course of the following diseases:

Typhoid fever	32
Rheumatism	24
Scarlatina	13
Variola	3
Gonorrheal arthritis	3
La grippe	2
Erysipelas	1
Eruptive fever	1

[1] Rev. d'Orthop., January 1, 1899.

Such accidents[1] may be guarded against by preventing flexion and adduction or extreme outward rotation of the limb and by evacuation of the fluid that distends the joint. The femur should be replaced as soon as possible before it has become fixed by adhesions and contractions. Even if treatment has been delayed for months, by means of preliminary traction and by the use of manual force, as in the reduction of congenital dislocation, one may succeed in replacing the femur. In cases of longer standing the acetabulum is usually filled with new material, which must be removed by the open method before replacement is possible. As an alternative operation one may force the head of the femur into the anterior position and fix the limb, for several months, in the attitude of extension and abduction. If the outward rotation is excessive, or if a tendency toward adduction persists, a secondary osteotomy of the shaft below the trochanter minor may be performed. However early reduction is accomplished, limitation of motion is to be expected, and in many instances absolute anchylosis. On this account the limb should be supported in slight abduction and extension until the tendency to deformity is under control.

EXTRA-ARTICULAR DISEASE.

Occasionally tuberculous disease, or other form of destructive ostitis, may begin in the neighborhood of the trochanter major. The symptoms are local pain, sensitiveness, and swelling of the soft parts. Later thickening and irregularity of the underlying bone become evident.

The symptoms are limp and discomfort. If the disease involves the capsule or is sufficiently acute to cause sympathetic congestion of the joint, there may be general limitation of motion; but, as a rule, this is slight or absent. In many instances the focus in the bone may be demonstrated by a roentgen-ray negative. If the disease is tuberculous or of the subacute type, abscess in the trochanteric or gluteal region may be the first indication of disease.

The treatment is prompt removal of the focus of disease before the joint or the shaft of the femur has become involved.

Disease of the pelvic bones in the neighborhood of the joint may simulate hip disease. The diagnosis is made by the local swelling and sensitiveness, and by the freedom of motion in the directions not restrained by sensitive tissues that are involved in the disease.

Gluteal Bursitis.—An enlargement of one of the bursæ lying beneath the gluteal muscles may cause a rounded, fluctuating swelling in the buttock. It may be sensitive to pressure and it usually causes a limp and some discomfort on motion, dependent upon the degree of inflammation that may be present. Occasionally the bursitis may be caused by injury, but in most instances it is the result of tuberculous infection. The bursa may communicate with a diseased hip-joint, but usually it is a distinct and primary affection.

[1] Graff: Deutsch. Ztschr. f. Chir., February, 1902.

Iliopsoas Bursitis.—The iliopsoas bursa is of a conical form about two and one-half inches in length and one and one-fourth at its widest part. It lies base upward in front of the capsule of the hip-joint, extending from the trochanter minor to and sometimes over the brim of the pelvis.[1] Not infrequently it communicates with the joint. If the bursa is enlarged it forms a swelling in Scarpa's space of a somewhat quadrilateral form. Sometimes a central indentation indicates the position of the iliopsoas tendon.[2] This causes a distinct enlargement of the upper and inner aspect of the thigh. It is usually accompanied by slight flexion, abduction, and outward rotation of the limb, an attitude that relieves the tension on the sensitive part. Zuelzer has collected from literature 45 cases of gluteal and 15 of iliopsoas bursitis. This illustrates the relative frequency of the two affections.[3]

Simple bursitis may be distinguished from disease of the joint by the absence of characteristic muscular spasm and general limitation of motion. Acute inflammation of a bursa may simulate local abscess.

Treatment.—Chronic disease of bursæ is usually tuberculous in character. Aspiration may be employed as a primary measure. As a rule, however, incision, drainage or, if possible, removal of the sac is indicated. The iliopsoas bursa may be reached easily by a vertical incision between the femoral artery and the crural nerve.

MALIGNANT DISEASE ABOUT THE HIP-JOINT.

Carcinoma of the upper extremity of the femur is almost always secondary to a primary tumor elsewhere, as of the breast or prostate. The symptoms are often indefinite and fracture of the weakened bone may be the first indication of the disease. Sarcoma is, on the other hand, practically limited to youthful subjects and is usually primary, and is far less common in this situation than at the knee. The character of the disease soon becomes evident in the general enlargement of the upper extremity of the thigh, but in the early stage diagnosis can be made only by means of the roentgen-ray or by exploratory incision.

CYSTS OF THE FEMUR.

In rare instances cysts may cause enlargement, weakening, and deformity of the upper extremity of the femur. The symptoms are discomfort, limp, and outward bowing of the upper third of the femur. Of 24 cases reported 13 were of the upper extremity of the femur, 1 of the lower end, 3 of the upper extremity of the tibia, 3 of the upper portion of the humerus. The affection is usually discovered during the growing period, 70 to 80 per cent. of the cases being in the second decade of life, the symptoms often becoming apparent after injury,

[1] Lund: Boston Med. and Surg. Jour., September 25, 1902.

[2] The trochanter minor to which the tendon is attached, lies at the junction of a line dropped from the anterior-superior spine and a horizontal line from the superior border of the symphysis pubis, Wierzejewsky, Zent. f. Chir., 1927, vol. **38**.

[3] Deutsch. Ztschr. f. Chir., Band **1**, Heft 1 and 2.

which may be also an exciting cause. In some instances spontaneous fracture occurs.[1]

Cysts[2] may be caused by the organization of a blood clot, or by other form of localized osteomyelitis of a mild character (giant-cell sarcoma and osteitis fibrosa). A number of cases of this type have been reported by Taylor and Barrie.[3] Operative removal of the cyst and its contents is indicated as the first essential of repair.

FIG. 371.—Chondrofibroma resembling osteitis fibrosa.

OSTEITIS FIBROSA.

This is characterized by enlargement and deformity, usually outward bowing in the neighborhood of the trochanter, by limp and discomfort as the bone becomes weaker. The roentgen-ray picture shows a general blurring in place of the marrow and cortex. Immediate operative removal of the diseased tissue is indicated. This is difficult when the neck of the femur is involved. In such cases spon-

[1] Mikulicz: Ztschr. f. Chir., November 19, 1904.
[2] Ropke: Arch. f. klin. Med., Band 1, s. 126.
[3] Jour. Am. Med. Assn., October 13, 1917.

taneous fracture of the neck may not unite, and the reconstruction operation may be indicated. Osteitis fibrosa is described elsewhere. Chondroma causes similar symptoms and the roentgen-ray picture resembles that of osteitis fibrosa. The removal of the tumor must be radical in order to prevent recurrence.

Fig. 372.—Arthritis deformans (see Fig. 373.)

ARTHRITIS DEFORMANS.

Osteoarthritis of the Hip-joint.—Osteoarthritis is not infrequently confined to the hip-joint. In this form it is essentially an affection of adult life or old age (malum coxæ senilis), although it occasionally occurs in young subjects. It is far more common in males than in females. It is characterized in its later stages by destruction of the cartilage of the head of the femur at pressure points and by wearing away of the underlying bone with formation of ecchondroses about the margins of the acetabulum and femoral head which may become ossified into irregular masses of bone. The acetabulum enlarges and the head of the femur becomes flatter, and in advanced cases may be subluxated. In the early stage of the affection the fluid within the joint may be increased in amount, but later it is diminished in quantity and changed in quality as the synovial membrane becomes transformed in part to fibrous tissue. The etiology of osteoarthritis is discussed elsewhere. At this joint, injury and congenital or acquired predisposi-

tion, so-called incongruity in the articulation, are of especial importance in the etiology and in the subsequent progression of the disease.

FIG. 373.—The outline drawing of arthritis deformans (Fig. 372) shows in the dotted lines the reconstruction operation with the remodelled head and transplanted trochanter.

FIG. 374.—Arthritis deformans, showing bone formation about the border of the acetabulum. The dotted (Shenton's) line shows the symmetrical curve joining the inner border of the neck of the femur and the lower border of the pubic bone as contrasted with that on the diseased side.

Symptoms.—The early symptoms are usually subacute in character. They are neuralgic pain in the limb, "sciatic rheumatism," stiffness

on changing from rest to activity, and sensitiveness to direct pressure on the joint, so that the patient often lies habitually on the other side. The movements of the joint become somewhat restricted, and the patient notices that he cannot take a long step or ride with comfort. The roentgen-ray picture at this stage shows only a diminution of the intra-articular space and an increased density at the area of greatest pressure. In more advanced cases creaking or grating in the joint is perceptible. There is an apparent thickening about the trochanter which is usually displaced upward, owing to the progressive changes in the acetabulum and in the head and neck of the femur. The limb is shortened and it is often distorted, usually in an attitude of flexion and adduction, and marked atrophy is apparent, appearances that, but for the history, might be mistaken for fracture. So also in the earlier period of the disease the limp, the pain, and restriction of motion with the attendant atrophy may simulate very closely tuberculous disease of a subacute type.

FIG. 375.—Typical changes in the head of the femur of arthritis deformans, showing the destruction of cartilage.

The progress of the disease may be very slow or it may be rapid, being dependent in great degree upon the strain to which the part is subjected. In this it resembles tuberculous disease.

Treatment.—In the class of cases in which the disease is confined to a single joint one may hope to check the progress of the destructive process by lessening the strain upon the joint, by regulation of the patient's habits and occupation, and to improve the nutrition of the part by massage and other forms of local stimulation. Passive movements in the directions of abduction and extension, are of service in restraining the tendency toward deformity.

If deformity is present it should be reduced by traction and rest in bed or by carefully regulated force under anesthesia. Afterward a hip brace (Fig. 352) that will remove the weight and limit the range

MEDICAL LIBRARY BOSTON

of motion, or a support of the character of a Lorenz spica of plaster, leather, or other material may be used.

FIG. 376.—The reconstruction operation for arthritis deformans. The rounded, smooth extremity of the neck offers comparatively little opportunity for friction, and the transplanted trochanter permits abduction.

FIG. 377.—Arthritis deformans with subluxation. Note the coxa valga.

Operative Treatment. In exceptional cases the symptoms are induced by marginal exostoses, the articular cartilage being otherwise in apparently normal condition. In such instances temporary relief



FIG. 378.—The under surface of the head showing normal bone.



FIG. 379.—The resected portion showing the changes in cartilage.

FIG. 380.—After the operation. Compare with Fig. 377.

may follow their removal. It is evident that whatever may have been the exciting cause of the disease, its progress is favored by the mutual friction of the bones on one another. In suitable cases, therefore, the reconstruction operation is indicated. The cartilage of the head of the

femur together with sufficient of the underlying bone is removed so that the extremity may be shaped to a smooth rounded surface of about the diameter of the neck. The trochanter is separated in the line of the neck and implanted on the shaft, as described elsewhere (Chapter XXIV). The limb is fixed in extension and moderate abduction for several weeks until the trochanter has united to the shaft. Then active and passive movements are begun, the limb being at first suspended to lessen friction. Ambulation is permitted when it causes but little discomfort. By this operation, pain may be relieved, useful motion retained and the progress of the disease checked. In the cases in which the after-treatment, specifically methodical manual stretching to assure abduction and extension, has been efficient the results have been extremely satisfactory.

The alternative treatment, more especially indicated for advanced cases attended by adduction deformity, is the induction of anchylosis. The joint is opened by an anterior incision along the inner border of the sartorius muscle. The upper extremity of the head in the plane of the neck and a sufficient section of the roof of the acetabulum are cut away with a chisel so that the two surfaces may be brought into accurate apposition by abducting the thigh, preferably about 10 to 15 degrees. to attain this attitude tenotomy of the adductors may be necessary. The wound is closed and the limb is fixed in a long spica plaster support. After several weeks, a short spica may be substituted for ambulation. This operation usually relieves the pain but firm anchylosis is not attained for many months. An analysis of the final results of the operations performed at the Massachusetts General Hospital, and those reported by Page[2] showed that ankylosis was attained in but 53 per cent. of the cases, and that in 75 per cent. adduction deformity was present. This indicates that the operation should be supplemented by bone implantation or similar procedures. (See Arthrodesis.)

OSTEOCHONDRITIS DEFORMANS COXÆ JUVENILIS.

Synonyms.—The Legg-Perthes disease, Coxa plana.

Osteochondritis is a term applied to a class of cases formerly mistaken for mild forms of hip disease. The name signifies that the process takes place within the head of the femur and does not involve the articular cartilage as in juvenile arthritis deformans. It was first described by A. T. Legg,[3] of Boston, in 1909, as an obscure affection of the hip-joint; by Calvé,[4] in 1910, under the name of pseudocoxalgia, and in more detail by Perthes[5] in the same year. The disease is most common in the first decade and is limited to the period of growth; is far

[1] Whitman: Ann. Surg., November, 1924; June, 1925.

[2] Brit. Jour. Surg., July, 1924.

[3] Boston Med. and Surg. Jour., July 17, 1910; Surg., Gynec. and Obst. March, 1916; Am. Jour. Orthop. Surg., July, 1918.

[4] Rev. de Chir., July 10, 1910; Jour. Orthop. Surg., October, 1921.

[5] Deutsch. Ztschr. f. Chir., 1910, vol. cvii; Arch. f. klin. Chir., 1913, p. 779; Taylor, Allison, Kidner: Am. Jour. Orthop. Surg., October, 1915; Nieber: Ztschr. f. orthop. Chir., March, 1915.

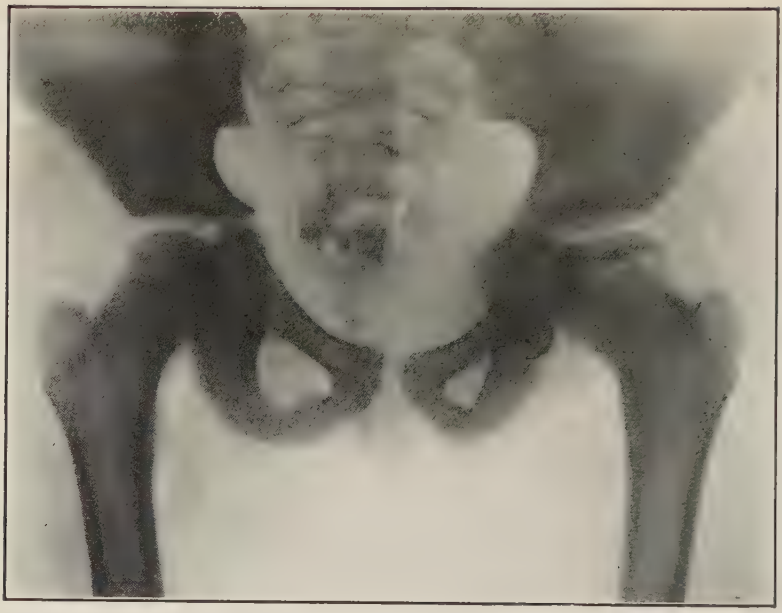

FIG. 381.—Osteochondritis, showing the characteristic changes in the head of the femur at an early stage.

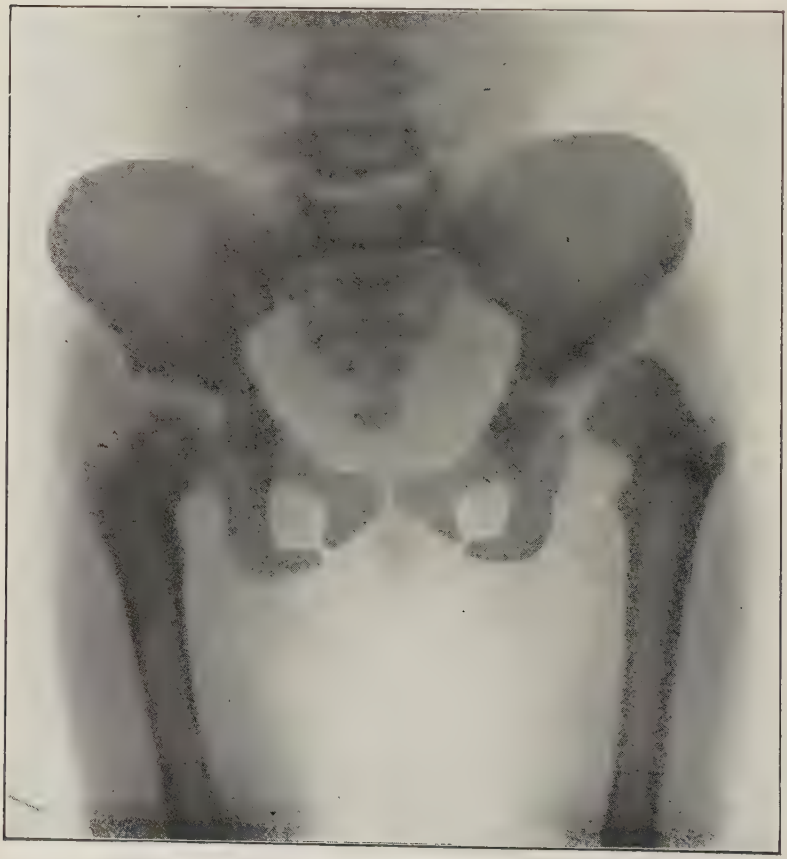

FIG. 382.—Bilateral osteochondritis.

more frequent in male than female children and in about three-fourths of the cases is unilateral. The symptoms are limp and at times discomfort in the hip and thigh on overuse and strain. There is usually slight atrophy, and limitation of the extremes of motion, particularly in abduction and inward rotation. In more advanced cases abduction is much restricted and there may be slight shortening of the limb. In other instances the onset may be more acute and may be mistaken for rheumatism. The diagnosis is made on roentgen-ray examination

FIG. 383.—Incongruity of the articulation due apparently to osteochondritis in childhood, causing symptoms of arthritis deformans in later life.

which shows characteristic changes. The epiphysis is flattened and broadened and its ossifying center is distorted and often segmented. The epiphyseal cartilage is irregular in outline. The neck appears broader and shorter than normal and the angle may be lessened. In some instances the acetabulum seems to be enlarged and irregular in outline.

The most characteristic physical sign of the affection on direct examination at open operation is flattening of the upper surface of

the head of the femur, and for this reason the name coxa plana has been suggested.

Osteochondritis must be differentiated from coxa vara, fractures particularly of the epiphyseal type, from congenital and acquired irregularities of the head of the femur and from tuberculous disease for which until it was identified by Legg it was usually mistaken.

The progress of the disease has been divided into stages, an initial stage lasting possibly six months and a fragmenting stage in which the nucleus of the epiphysis breaks into several parts. The head changes its contour, flattens and the roof of the acetabulum may become more oblique. This is followed by a stage of repair and by readaptation of the joint to the new conditions.

In a group of 74 cases observed by Flemming-Moller,[1] 58 presented a practically perfect functional recovery. In 16 a limp and restriction of motion persisted and in the remaining 9 cases (12 per cent.) there was pain stiffness and permanent disability.

Legg[2] has analyzed later results in 40 cases. He recognizes two types, the "mushroom" in which the head is flattened and expanded, and the "cap" in which the bone center becomes segmented and the epiphysis "migrates" toward the trochanter. In this form the symptoms are more persistent and the eventual disability greater than in the mushroom type.

Pathology.—A study of specimens obtained by operation in patients under my care, by Zemansky[3] and Lippman[4] seem to warrant the conclusion that in its typical form, osteochondritis deformans is of the nature of Köhler's disease and the like, a disturbance of nutrition resulting in limited necrosis with secondary changes influenced by local and general factors. The sequence being as follows:

1. Inadequacy of blood supply, possibly induced by injury particularly that in the ligamentum teres.

2. Subchondral necrosis of the bone and marrow to a greater or less degree.

3. The absorption and disintegration of the dead bone by granulation tissue which usually invades and destroys the epiphyseal cartilage in whole or part.

4. Collapse of structure and deformity of the head.

The character of the deformity determines the subsequent disturbance of function.

It may be noted that there is no similarity between this affection and epiphyseal displacement as suggested by certain writers. In the one case the normal head together with the cartilage is displaced. In the other the epiphysis is primarily involved and is deformed but not displaced.

[1] Acta-Rad., 1926, vol. **5**.
[2] Jour. Bone and Joint Surgery, January, 1927.
[3] Am. Jour. Surg., 1928, **4**, 160.
[4] Ibid., June, 1928.

Treatment.—In mild cases the treatment should be symptomatic. The strain upon the joint should be lessened by limiting the activities

FIG. 384.—The "cap" type of Legg-Perthes disease of an advanced stage illustrating mechanical interference with motion (see Fig. 385).

FIG. 385.—The reconstruction operation for Legg-Perthes disease. Compare with Fig. 384.

of the patient. If there is pain on movement, the application of a short spica is indicated. Protection from the pressure of weight-bearing, if applied in the early stage of the affection, might lessen the final deformity of the head, but the opportunity is rarely offered. Supervision should be continued as long as the symptoms persist—usually for a year or more.

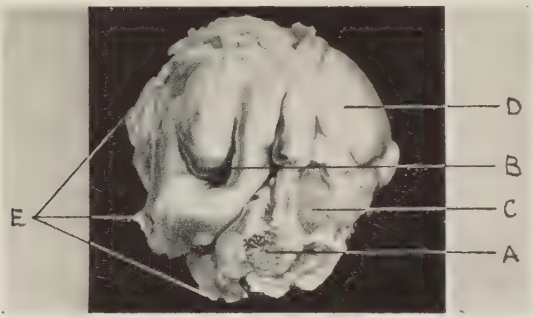

FIG. 386.—Resected head in Legg-Perthes disease. *A*, Area of thin cartilage; B, Crypt with subchondral hemorrhage. C, Operative injury. D, Fairly normal contour. E, Shreds of capsule. The crumpling of the articular cartilage is caused by the absorption of the underlying bone. (Zemansky.)

Operative Treatment.—In a certain proportion of the cases particularly those in adolescence, the initial symptoms are severe and disabling indicating an extensive area of necrosis, and if the roentgen picture confirms this diagnosis operative treatment may be indicated to shorten the period of disability and to prevent the secondary changes in the joint in adaptation to the deformity (arthritis deformans).

For this reason in a number of instances the reconstruction operation has been performed.[1] The deformed head is reshaped into a round symmetrical extremity, the diseased tissue and whatever remains of the epiphyseal cartilage being removed. The trochanter is transplanted thus restoring the mechanical relation of the joint. See Reconstruction Operation.)

OSTEOCHONDRITIS ISCHIOPUBICA.

In some instances the acetabulum seems to be involved and cases have been described in which the symptoms resembled those of the femoral form of osteochrondritis, but in which the disturbance of nutrition seemed to be at the acetabular junction of the pubes and ischium as indicated by haziness and thickening at this point.

[1] Whitman: Am. Jour. Surg., 1928, **4**, 169; **5**, 385; 1929, **6**, 792.

BOSTON CITY HOSPITAL LIBRARY

CHAPTER IX.

TUBERCULOUS DISEASE OF THE KNEE-JOINT.

Synonyms.—White swelling, tumor albus.

Tuberculous disease of the knee-joint is next in frequency and importance to that of the hip. It is, however, far less dangerous to life, and the prognosis, as regards function, is much better than in the former affection. This is accounted for by the simplicity of the joint and by its situation at a distance from the trunk, at the junction of two levers of nearly equal length and size. As the problem of protection by mechanical means is comparatively simple it is more often applied, and in proportion to its efficiency the injury is lessened and the tendency to deformity is checked.

Fig. 387.—Section of knee-joint at the age of eight years, showing the epiphyses of the femur and tibia and their relation to the capsule. (Krause.)

The centers of ossification in the epiphyses of the femur and tibia are present at birth. Ossification is completed in each at about the twentieth year.

The range of motion is from slightly more than complete extension to about 50 to 60 degrees of flexion. In complete extension the tibia is rotated outward on the femur. In midflexion the laxity of the ligaments permits a range of outward rotation of about 25 degrees while inward rotation is limited to 5 to 10 degrees.

Pathology.—The disease may begin in the epiphysis of the femur or in that of the tibia, occasionally in the diaphysis or in the patella or in the head of the fibula, or primarily in the synovial membrane.

In 547 cases,[1] about two-thirds of which were in adults, treated at König's clinic at Göttingen by operative procedures which permitted inspection of the joint, 281 (51.4 per cent.) were apparently examples of primary osteal disease; 266 (48.6 per cent.) were primarily synovial. The focus was in the femur in 93 instances (33.1 per cent.), in the tibia in 107 (38.1 per cent.), in the patella in 33 (11.7 per cent.), and in more than bone in 48 (17.1 per cent.).

The examination of a joint permitted by arthrectomy or excision cannot be sufficiently thorough to exclude disease of the bone and to establish the diagnosis of primary disease of the synovial mem-

[1] Die Specielle Tuberculose der Knochen und Gelenke, Berlin, 1896.

brane, but in 92 instances the opportunity was offered by amputation at the thigh, 80 of the patients being adults. This examination, presumably thorough, showed the primary disease to be of the bone in 50 cases, while in 35 the synovial membrane was apparently the seat of the primary affection. In 17 of the 50 cases in which the disease was osteal, the focus was in the femur; in 7 it was in the internal condyle, in 6 in the external condyle, and it was in other situations in 4 cases. In 17 the primary disease was of the tibia; in 5 of the internal tuberosity; in 5 of the external tuberosity; in other situations, 7. In

FIG. 388.—Acute tuberculous arthritis of the knee.

5 instances the primary disease was of the patella, and more than one bone was involved in 11 cases. Of 314 cases, chiefly in adults treated by operation in Garré's clinic, 13 were surely, and 115 apparently, of synovial origin. In 187 cases both bone and synovia were involved. In 6 cases the original disease was apparently of the bone, and in 3 surely so. The femur was involved in 44 cases, the tibia in 38, the patella in 3, and more than one bone in 120 cases.[1] Nichols[2] states

[1] Beitr. z. klin. Chir., vol. **87**, Heft 1.
[2] Tr. Am. Orthop. Assn., vol. **11**.

that he has examined 120 tuberculous joints of adults and children, after excision or amputation, or at autopsy, and in every instance primary foci in the bone were discovered. He believes primary disease of the synovial membrane to be very uncommon, and asserts that examinations are of no particular value as establishing the absence of primary osteal disease unless the bones are sawed into thin sections. From the clinical stand-point, however, one recognizes two distinct types of tuberculous disease: one beginning as a chronic synovitis of which the early symptoms are subacute, a type more often seen in adults (Fig. 389); and the more common class, especially in childhood, in which the symptoms of pain, muscular spasm, and deformity seem to indicate clearly primary disease of the bone.

Fig. 389. — Tuberculous disease of the knee in an adult. The synovial type.

The proximity of the active disease in the neighborhood of the joint sets up a sympathetic irritation within it, and an accompanying synovitis. If the disease is progressive the synovial membrane becomes thickened and adhesions form between its folds that gradually lessen the capacity of the joint and diminish its mobility. When perforation takes place the granulation tissue spreads over the surface of the cartilages, destroying them in its progress and eroding the underlying bone; or if the joint is filled with tuberculous fluid the cartilage may be macerated and separated in necrotic shreds. The direct destructive effects of the disease are increased by pressure and friction if the joint is not protected by mechanical means. The hypertrophied synovial membrane and the thickened and diseased capsule explain the peculiar elastic resistance on palpation called pseudofluctuation. In more advanced cases there is in addition a reactive inflammation in the overlying tissues, accompanied by a formation of fibrous tissue that involves the tendons and muscles. These changes within and without the joint cause the firm, resistant tumor characteristic of "white swelling."

Etiology.—The etiology of tuberculous disease has been discussed in Chapters V and VII.

Occurrence.—Tuberculosis of the knee-joint is essentially a disease of early life, although it is less strictly confined to childhood than is disease of the spine or hip. Sex exercises but little influence, and the

two sides are affected in nearly equal numbers. These points are illustrated by the following table of 1000 consecutive cases treated at the Hospital for Ruptured and Crippled.

AGE AT INCIPIENCY OF KNEE-JOINT DISEASE.

1 year or less	25	23 years old	12
2 years old	45	24 years old	8
3 years old	91	25 years old	3
4 years old	164	26 years old	2
5 years old	84	27 years old	4
6 years old	75	28 years old	5
7 years old	66	29 years old	7
8 years old	74	30 years old	1
9 years old	65	31 years old	1
10 years old	60	32 years old	2
11 years old	46	33 years old	1
12 years old	20	34 years old	1
13 years old	19	35 years old	4
14 years old	17	36 years old	0
15 years old	12	37 years old	2
16 years old	10	38 years old	1
17 years old	20	39 years old	1
18 years old	8	40 years old	1
19 years old	8	41 years old	1
20 years old	8	50 years old	1
21 years old	12		
22 years old	13		1000

Males	512	Right	485
Females	488	Left	515

Symptoms.—The general characteristics of tuberculosis have been described in the chapters on Pott's Disease and Hip Disease. In the description of these affections, however, but little stress was laid on local sensitiveness and local swelling, because the diseased parts lie at a distance from the surface and are concealed by the muscles and other tissues. At the knee, on the other hand, the joint is superficial, and even slight effusion changes, to a perceptible degree, its contour. If the disease is progressive, sensitiveness to pressure, elevation of the local temperature, and infiltration or thickening of the tissues are usually present.

Even when the patients are seen comparatively early in the course of the disease the history of the affection almost always indicates that it is chronic and progressive in character. The importance of establishing this fact has been mentioned in the consideration of hip disease, and it may be stated again that a chronic painful disease of a single joint, accompanied by a tendency to deformity, is, in childhood, almost always tuberculous in character.

The symptoms of tuberculous disease may be classified as *limp, pain, local heat, sensitiveness and swelling, muscular spasm and limitation of motion, distortion and atrophy.*

On physical examination one will note the character of the limp and the slight flexion of the limb that usually accompanies it. The joint is, as a rule, somewhat enlarged, the normal depressions about the

patella and the prominences of the component bones being less accentuated than on the opposite side. There is usually slight local elevation of temperature and sensitiveness to pressure, varying in degree with the character of the disease. In certain cases effusion is present, sufficient to be classed as synovitis, but in most instances the swelling is due, in great part, to the thickening of the synovial membrane and capsule, which gives the sensation of elastic resistance rather than of actual fluctuation.

Limitation of Motion.—The most important diagnostic sign is limitation of the range of motion caused by muscular spasm. The normal range is from complete extension (180 degrees) to a degree of flexion, limited by contact of the calf and the thigh. Even in the early stage of disease slight limitation of complete extension is present, due to reflex muscular spasm, and usually a corresponding limitation of the complete flexion. On sudden movements the characteristic reflex contraction of the muscles is apparent. In most cases this limitation of motion and consequent flexion deformity is well-marked on the first examination. Atrophy of the muscles of the thigh and calf, dependent upon the duration of the disease and upon the interference with function, is present, and this atrophy is more noticeable because of the enlargement of the knee.

In certain cases, more often seen in infancy and early childhood, the symptoms are more acute and the progress of the disease is so rapid that it may simulate an infectious epiphysitis (Fig. 388).

In another type, apparently a primary disease of the synovial membrane, more common in adults, the early symptoms are very similar to those of simple chronic synovitis. The joint is swollen by a distention of the capsule, pain is not troublesome except on jars or sudden twists of the limb, and muscular spasm and limitation of motion are evident only after a careful examination. In this class months or years may pass before the symptoms become as disabling as in the osteal type of the disease.

Primary and Secondary Distortions.—At the hip-joint, in which the range of motion is extensive, the deformities resulting from disease are somewhat complex, causing, for example, apparent shortening or lengthening, according as the limb is adducted or abducted. But the movements that the knee-joints permit are much simpler, and the primary distortion is simply flexion. Complete extension of the limb, the limit of normal motion in that direction, brings the joint surfaces into close apposition; the ligaments are then tense and no lateral motion is permitted. This is the attitude in which the greatest efficiency of the limb for weight-bearing is assured. When the ability of the knee for carrying out its normal weight-bearing function is impaired by disease which makes the parts sensitive to pressure and strain, the range of extension is lessened and the limb is persistently flexed to a greater or less degree, corresponding to the sensitiveness of the joint. The agents that adapt the limb to the habitual attitudes

are the muscles under the control of the nervous system. In this sense the primary distortions are due to muscular action, but it is certainly not true that these muscles antagonize one another, and that the stronger overcoming the weaker cause the deformity, since the extensors at this joint are stronger than the flexors, and since flexion is the primary deformity at every joint which is diseased without regard to the relative strength of the opposing muscular groups.

In disease at the knee-joint, as at other joints, the extremes of motion in every direction that the joint permits are limited by muscular spasm, but limitation of extension, which is so essential to normal use, is at once evident, while limitation of flexion, the extreme of which is unessential, is only apparent on examination, and it may be absent even. Flexion is, then, the primary distortion at the knee, and other deformities may be classed as secondary.

Secondary Deformities.—Of these the most common is outward rotation of the tibia upon the femur. When the limb is fully extended the tibia is fixed, but when it is flexed lateral motion is possible in outward rotation, and in the attitude of flexion the traction of the biceps upon the head of the fibula tends to rotate it upon the femur. This deformity is also favored by the use of the limb in the attitude of outward rotation, which is always assumed when the weakness or stiffness of the knee-joint is present, and by the secondary knock-knee that often accompanies the disease.

Subluxation or backward displacement of the tibia upon the femur is another secondary deformity. When the leg is flexed upon the thigh the articulating surface of the tibia glides backward upon the condyles of the femur. Here it becomes fixed by muscular contraction, and later by the secondary changes within the joint. If muscular spasm is extreme, this alone may cause the subluxation; but there are other factors: one is the destructive action of the disease, which is usually most marked at the point at which the bones are in contact, and the other is the leverage exerted upon the joint. This is exemplified by the increase of the displacement that is often observed when an attempt is made to straighten the limb by force, against the resistance offered by the contracted tissues on the flexor aspect. The same leverage, in slighter degree, is exerted when the weight of the distorted limb is supported on the heel in the recumbent posture, or when the limb is extended in the act of walking, or if the upper extremity of the tibia is not supported during the period of treatment by apparatus (Fig. 391).

Knock-knee (genu valgum) is another secondary deformity. This is explained in certain instances by the hypertrophy of the internal condyle caused by disease, but it is induced more directly by the use of the flexed and somewhat disabled limb in the passive attitude of outward rotation. Genu varum is uncommon, and it is usually the result of the destruction of a part of the internal condyle of the femur or of the tibia, or of irregular epiphyseal growth.

The character and the relative frequency of the deformities are

indicated by the statistics of König's[1] clinic: of 150 cases of knee-joint disease treated by arthrectomy, 128 of these being in children. In 94 cases flexion was present; in 50 from a slight degree to 135 degrees; in 16 from 135 degrees to 90; in 28 to a right angle or less. Together with the flexion were combined other deformities as follows: Genu valgum in 60 cases; moderate in 42; extreme in 18. Genu varum in 1 case. Subluxation of the tibia in 20 cases. Outward rotation of the tibia in 10 cases.

Fig. 390.—Untreated disease of the knee-joint involving the shaft of the femur, illustrating lengthening and the hypertrophy of the femur, the subluxation and outward rotation of the tibia, the atrophy and the characteristic deformity.

As has been stated, the primary deformity of knee disease is simple flexion. If the disease is of an acute type this flexion increases rapidly.

[1] Loc. cit.

If it is subacute in character, or if the disease is primarily of the synovial membrane, the progress of the deformity is slow. In ordinary cases secondary distortions appear at a later time and especially when the disease has reached the destructive stage; and they are most marked in patients who have persistently used the deformed limb without protection.

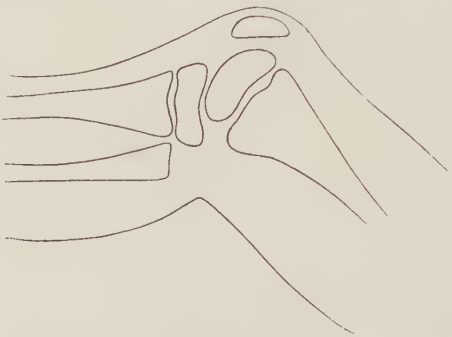

Fig. 391.—Flexion deformity at the knee-joint, with slight subluxation of the tibia.

Actual Shortening and Actual Lengthening.—Retardation of growth is, of course, not an early symptom of disease; in fact, actual lengthening of the limb, due to the irritative effect of the disease, is common. This lengthening, sometimes to the extent of an inch or even more, may persist throughout the entire course of treatment, but after the cure of the disease a corresponding retardation of growth that will

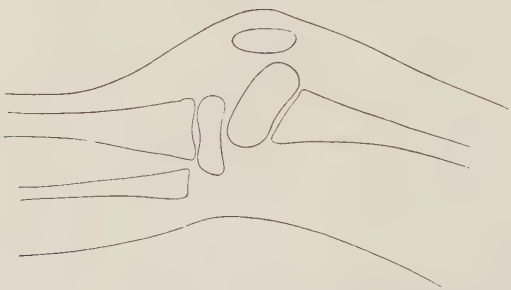

Fig. 392.—After forcible correction, showing the increase of the posterior displacement. Drawing from the roentgen-ray photographs of an actual case in which the limb had been corrected by direct force in the ordinary manner. See reverse leverage, Fig. 394.

more than equalize the length of the limbs may be expected. If the disease is of the destructive type the ultimate shortening may be considerable; two or more inches is not unusual.

Leusden,[1] in 33 cases under treatment in the clinic at Göttingen, 1896–1898, found slight shortening in 2, equality of length in 18, lengthening of the femur on the diseased side in 13.

[1] Deutsch. Ztschr. f. Chir., Band **51**, Heft 3 und 4.

MEDICAL LIBRARY BOSTON CITY HOSP

In 116 cases of tuberculous disease of the knee the limbs were measured by Berry and Gibney[1] with reference to this point. In 72 of these there was actual lengthening of the femur, from which it may be inferred that in at least 26 per cent. of the cases examined the primary disease was of the femur.

In 17	¼ inch.
In 34	½ "
In 15	¾ "
In 6	1 "
72 = 62 per cent.	

In a total of 106 apparently cured cases treated at the New York Orthopaedic Hospital the limb was lengthened in 10, there was less than one inch of shortening in 73, less than two inches in 7, and more than two inches in 14.[2]

H. L. Taylor,[3] from an examination of 40 cases of tuberculous disease of the knee, concludes that the limb is almost always longer in the first two years of the disease, usually longer during the second two years, but usually shorter when the period of growth is completed. The lengthening is in most instances of the femur.

Diagnosis.—Tuberculous disease is a local destructive process that is, as a rule, confined to a single joint. This is an important point in the differential diagnosis from general or constitutional affections like rheumatism, arthritis deformans and the like, in which several joints are involved. The following affections may be considered in differential diagnosis.

Injury of the Knee.—Strains of the knee in childhood are often followed by limp and by persistent flexion and pain. In such cases the onset is sudden and the symptoms usually disappear quickly under treatment. Synovitis of traumatic origin is usually indicative of a more severe injury. If it persists the diagnosis may be doubtful because tuberculous infection may have followed the original injury. This emphasizes the importance of the careful treatment and continued observation of injuries of this class, especially in weak children.

Synovitis.—Chronic synovitis of doubtful origin, which shows no tendency toward recovery, is in childhood almost always tuberculous in character.

Hemarthrosis.—Effusion of blood into the knee-joint may cause inflammatory symptoms during the stage of absorption and organization of the clot that resemble those of disease. The sudden onset and the personal history of the patient, who may be known as a bleeder, will explain the symptoms.

Infectious Arthritis.—This is of sudden onset, attended by the constitutional and local symptoms of acute infection.

"**Rheumatism.**"—This, in early childhood, may be confined to a single joint, but it is of sudden onset, it is usually accompanied by

[1] Am. Jour. Med. Sci., October, 1893.
[2] Humphries and Durham: Jour. Am. Med. Assn., January 27, 1917.
[3] Tr. Am. Orthop. Assn., 1901, vol. 14.

constitutional disturbance, and after a time other joints become involved.

Arthritis Deformans.—Disease of this character, of the monarticular form, is more common in adult life. The symptoms are rather of the rheumatic than of the tuberculous type.

Syphilis.—The later manifestations of syphilis in adults may resemble somewhat those of tuberculosis, but they are rarely confined to a single joint.

Charcot's Disease.—Charcot's disease of the knee-joint is characterized by sudden effusion, by rapid destruction of the joint, and consequently by weakness and deformity; but pain is usually very slight and muscular spasm is absent. The diagnosis of disease of the spinal cord will indicate the nature of the local process of the joint.

Sarcoma.—Sarcoma, beginning at or near the extremity of the femur or of the tibia, may simulate tuberculous disease very closely. If the tumor is of the periosteal type, it usually forms a more localized and irregular swelling than could be accounted for by tuberculous disease. Central sarcoma may simulate tuberculous disease also, but the progress of the tumor is more rapid. The clinical distinction between the two is that tuberculous disease is very amenable to treatment so far as its symptoms are concerned, while the progress of sarcoma is but little influenced by treatment. It may be stated, however, that the roentgen-rays are the only means of early diagnosis, the destruction of the substance of the bone about the tumor being much greater than that caused by the tuberculous process.

Hysterical Joint.—Some of the symptoms of disease may be simulated by hysterical subjects, but there is always an absence of the positive physical signs that invariably accompany a destructive disease. These and other affections are described at length in the following chapters.

Treatment.—The treatment of tuberculous disease of the knee in childhood should be conservative, operative intervention being simply incidental to protective treatment. In adult life, on the other hand, the radical removal of the disease may be indicated as a primary measure. The reasons for this distinction are obvious. In childhood the duration of treatment is of no particular importance as compared with the final functional result, but in adult life the shortening of the period of disability and the definite assurance of cure may be of far greater moment than the preservation of motion.

In childhood, under favorable conditions, ultimate recovery, with fair functional use of the joint, may be anticipated; while a radical operation, although it may cure the patient in a shorter time, takes away the possibility of a cure with motion. In adult life a rigid limb is a strong and useful support, but in childhood the removal of portions of the epiphyses and of the epiphyseal cartilages entails a progressive inequality in the limbs, due to loss of growth; furthermore, unless the limb is protected by mechanical means, deformity is the rule, even though the disease has been thoroughly removed. Thus the treatment

of routine is, in childhood, at least, protection; protection from the traumatism of motion, from the shock of impact with the ground, and from the pressure of muscular spasm and contraction. The importance of constitutional treatment for all forms of tuberculous disease needs no further emphasis.

Fixation of the joint, which is so difficult to assure at the hip, is easily attained at the knee, and, as has been stated, the results are correspondingly better. At the hip-joint one of the most common causes of shortening and deformity is upward displacement of the femur upon the pelvis, but at the knee, if the limb is supported in the attitude of extension, the apposition of the broad surfaces of the femur and the tibia prevents displacement, while muscular spasm, a symptom whose intensity is in proportion to the degree of harmful motion that is permitted, is easily controlled.

Reduction of Deformity.—The first step in treatment is the reduction of deformity that may be present, and as the chief function of the leg is to support weight, the proper attitude in which to fix the limb is complete extension. Whatever motion the patient retains will then be about the point of greatest usefulness. In the cases in which an opportunity for reasonably early treatment is offered the only deformity is flexion induced by muscular contraction. In this class of cases the spasm, and consequently the deformity, may be readily overcome by placing the joint at rest.

The Plaster Splint.—The most efficient splint for this preliminary treatment is a close-fitting plaster support, applied to include the pelvis and the foot, to prevent edema of the unsupported part, which is common after the first dressing and until the circulation of the limb has become adapted to the new conditions. In the application of the bandage the bony prominences of the knee and ankle are protected by cotton. A cotton flannel bandage is then applied smoothly, and directly upon this the light plaster bandage. At the second application, at the end of a week, the subsidence of the spasm will permit the straightening of the limb. In cases of longer standing several successive applications of the bandage may be required, together with manual extension during the application; or an anesthetic may be administered. Under anesthesia the muscular spasm relaxes and deformity, even of some standing, may be reduced by traction and by slight leverage, the head of the tibia being supported and drawn forward by the hands as the deformity is gently reduced.

Traction.—Deformity may be reduced also by traction with the weight and pulley, the leg being supported so that no direct leverage is exerted at the seat of the disease (Fig. 393).

Forcible Correction by Reverse Leverage.—In the more resistant cases, especially if accompanied by subluxation, the following method may be employed.

The patient is anesthetized and is placed face downward on a table, the feet projecting over its end. The body of the patient is then elevated by means of pillows to conform to the deformity—that is, the

thigh is raised sufficiently to permit the tibia to lie evenly upon its anterior border on the table. The operator then holds the head of the tibia firmly against the table while the assistant exerts intermittent and gradually increasing downward pressure on the thigh, but never to the extent to lift the tibia from the table; thus, further subluxation is impossible. As the contraction gives way the pillows are removed. Usually the deformity may be reduced at one sitting, but if it is very

Fig. 393.—Traction and counter-traction in disease of the knee-joint. (Marsh.)

resistant complete correction is not attempted. At the conclusion of the operation adhesive plaster straps for traction and a close-fitting plaster bandage are applied (Fig. 394).

Rest in bed with traction is enforced for a time, and the ordinary brace is then applied. This is, in the author's experience, the most effective and satisfactory method for reducing deformity. If the contraction is of long standing, preliminary open division of the flexor tendons is advisable. The deformity is then in part corrected, complete rectification being deferred until repair is complete.

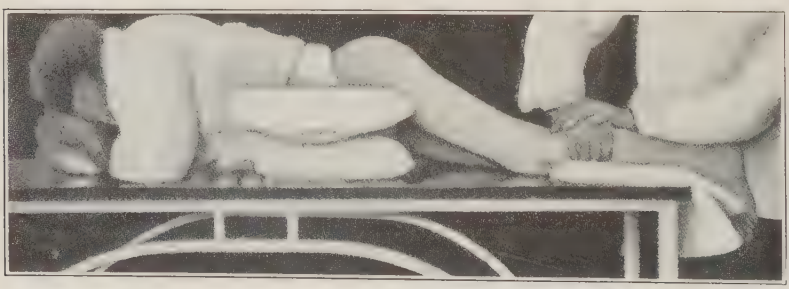

Fig. 394.—The author's method of correcting flexion deformity at the knee by reverse leverage. The folded sheet indicates the degree of subluxation present. In resistant cases of this type an assistant applies the pressure on the thigh.

The Billroth Splint.—The Billroth splint, as modified by Stillman, is an effective appliance for overcoming resistant deformity. A thick pad of felt is placed over the upper surface of the condyles of the femur and a thinner pad in the popliteal region over the upper border of the tibia. Other points that may be subjected to pressure are similarly protected, especially the dorsum of the foot and the perineum. A plaster bandage is then applied from the groin to the toes, made

especially thick and strong in the popliteal region. On either side of the knee two curved, slotted steel bars attached to expanded tin splints and joined to one another by an adjustable bolt are incorporated in it (Fig. 395). When the bandage hardens it is completely divided into two parts by a circular cut about the knee, and the bolts in the slots are so adjusted as to form a hinged splint, the center of motion being somewhat above and in front of the knee-joint. When the limb is slightly extended the position of the hinges has a tendency to lift the tibia and to separate it from the femur. This straightening opens the cut in the popliteal region, which is held open by a wedge

Fig. 395.—Tuberculous disease of the knee in an adult, with the form of Billroth splint used at the Hospital for Ruptured and Crippled.

of cork. In this manner by the insertion of larger wedges the limb is gradually straightened from day to day until the deformity is overcome, or until a new bandage is required. If the pressure on the front of the femur, when the leverage is exerted, becomes painful, a part of the padding is removed.

In the treatment of older subjects greater force may be employed by means of osteoclasts. One of the best machines of this type is the Bradford-Goldthwait genuclast (Fig. 396). The more violent methods should not be employed during the active stages of the disease; and whenever considerable force is required in young subjects the possibility of separating the epiphysis of the femur, forcing it backward and

thus pressing upon the popliteal vessels, should be borne in mind. In fact in all cases in which deformity has been corrected one should assure oneself by subsequent examination that the circulation of the extremity is not impaired. In resistant cases of this type the open operation and posterior capsulotomy if required should be employed rather than extreme force.

Mechanical Treatment.—The most efficient mechanical appliance for the treatment of tuberculous disease during the acute stage at the knee is the Thomas *knee brace*. This consists of two lateral uprights which support the limb on either side, terminating below the foot in a crossbar shod with leather or rubber, which serves as a stilt, and above in a ring that fits the upper extremity of the thigh, and supports the weight of the body. The brace is made of iron wire from three-sixteenths to three-eighths of an inch in thickness. The ring is of an irregular ovoid shape, flattened in front, expanded behind and wider on the inner than on the outer side (Fig. 397). This ring is welded to the uprights at a lateral and anterior-posterior inclination. The lateral inclination forms an angle with the inner bar of 135 degrees (Fig. 399), the anterior-posterior inclination forms an anterior angle of 145 degrees (Fig. 397) with the same upright, which is set upon the ring at a point slightly in advance of its fellow. The objects of the shape of the ring and of its inclination are these: its anterior part is flattened to conform to the surface of the groin; its posterior segment is expanded to accommodate the thickness of the buttock; the anterior-posterior inclination adjusts it to the tuberosity of the ischium. The lateral inclination follows the line of Poupart's ligament from the inner to the outer bar, which in order to assure better support and less pressure, rises above the level of the trochanter major.

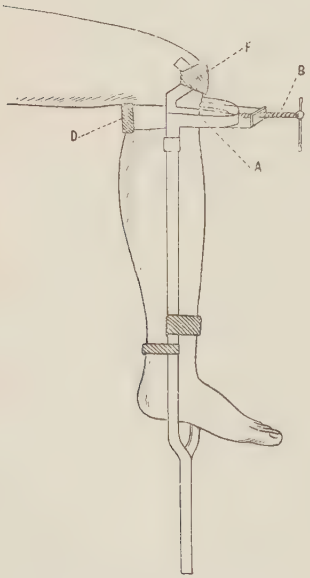

Fig. 396.—The Bradford-Goldthwait genuclast for the correction of flexion deformity and subluxation at the knee. Counter-pressure is applied over the lower extremity of the femur. Subluxation is prevented during the forcible correction by means of the screw and strap beneath the head of the tibia, by which it is drawn forward.

The ring is made somewhat larger than the thigh to allow for padding with felt. This should be thicker on the inner and posterior surface, where the weight is borne, than on the anterior and outer part. The padded ring is then smoothly covered with basil leather. As used at the Hospital for Ruptured and Crippled, in the treatment of sensitive or progressive cases, the brace is made two or three inches longer than the leg, to serve as a stilt like the hip splint. To

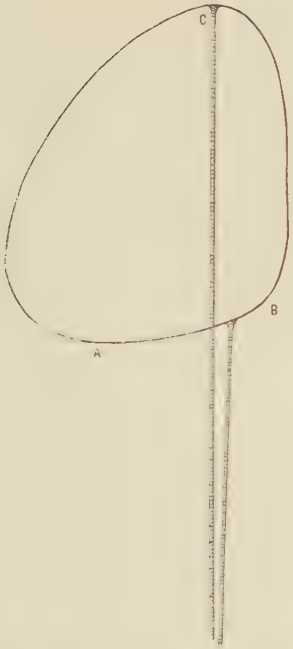

FIG. 397.—The Thomas knee splint, showing the inner bar *B* placed farther to the front than the outer bar *C; A* is the lowest part of the ring; upon this rests the tuberosity of the ischium.

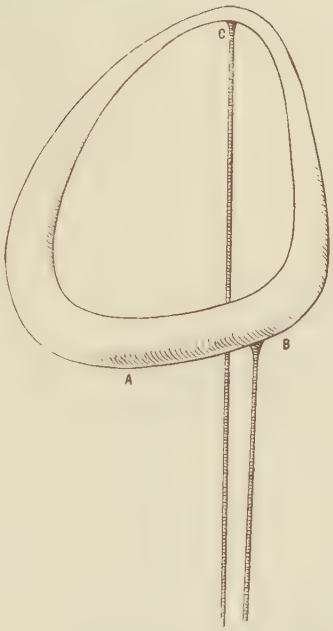

FIG. 398.—The ring of the Thomas knee splint after padding. (Ridlon.)

FIG. 399.—Thomas knee splint. Showing the front of the ring.

FIG. 400.—Showing the back of the ring. (Ridlon.)

the foot-piece two straps are attached on either side to provide for traction on the limb and to hold the brace securely in its place. A band of leather is drawn between the bars at the upper third and another at the lower third of the brace to serve as supports for the thigh and calf. Adhesive plasters, reaching from the knee to the ankle, provided with buckles above the malleoli, having been applied, the ring is pushed firmly against the perineum and is held in position by buckling the straps to the traction plasters with as much tension as the comfort of the patient will permit. The thigh and leg supports should fit the parts perfectly; the knee is then fixed in its place by a bandage drawn about it and the lateral bars. Ankle and heel straps complete the adjustment (Fig. 401).

FIG. 401.—The Thomas knee brace.

In cases in which the joint is very sensitive and in which there is a tendency to deformity the entire limb is in addition enclosed in a light plaster bandage, so-called "skin fitting," applied directly upon a cotton flannel bandage.

If the brace is attached by means of the adhesive plaster straps, a certain degree of traction is assured, together with additional accuracy of adjustment; and by the traction and by the direct pressure on the knee the slighter degrees of deformity may be reduced without discomfort. In acute cases preliminary rest in bed is advisable, and crutches may be employed in the early stages of ambulatory treatment. But during the greater part of the active stages of the disease the brace serves as a perineal crutch and by the use of bandage pressure from before backward, or toward one or the other upright, flexion or lateral distortion of the limb may be corrected during the course of treatment. This brace may be used in the treatment of very young children if it is carefully fitted and if the parts are kept clean and dry, and it is an effective brace for all ages, and for all conditions of disease.

The Caliper Brace.—The traction may be discarded and the brace may be held in position by a shoulder band, or it may be used as a so-called caliper splint. In this form it was almost exclusively employed by Mr. Thomas in his later practice and at the present time by

MEDICAL LIBRARY BOSTON CITY HOSPITAL

Ridlon,[1] the long brace being used simply for a bed splint. As a caliper brace the two bars are cut off, turned directly inward at a right angle, and are inserted into a steel tube, which is passed through the heel of the shoe. The bars are made slightly longer than the limb, so that the patient's heel is lifted nearly an inch from the inside of the shoe when walking; thus, the jar of impact with the ground is prevented. The brace is fixed in position by a leather band beneath the knee and another beneath the calf, and the limb is held extended by pressure pads applied to the thigh and leg, as illustrated (Fig. 402). Ridlon uses the brace to reduce deformity by direct pressure backward on the knee by means of bandages, opiates being given to relieve pain.

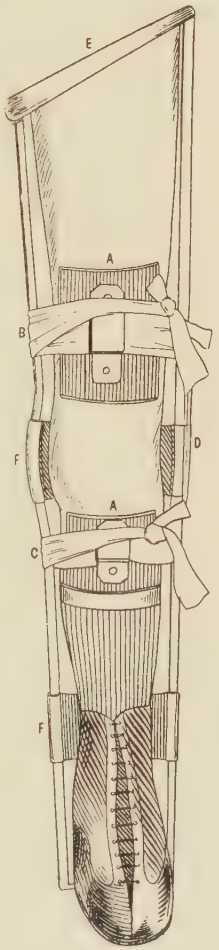

FIG. 402.—The caliper. *E*, the ring around the upper part of the thigh. *A*, pad for backward pressure. *B*, bandage. *C*, bandage. *F*, leather sling for support at the back of the limb. *D*, a strip of bandage fastening together the pressure pads to prevent slipping and consequent loss of pressure. (Ridlon and Jones.)

Other braces may be employed, for example, the traction hip brace, but as the Thomas brace answers every requirement, it seems unnecessary to describe others in this connection. The plaster splint is an unsatisfactory support in the treatment of children because it does not hold its place securely. To make it effective as a splint it must either include the pelvis or the foot. It is therefore unsuitable as a routine appliance. When the disease is no longer active weight-bearing is permitted, but splinting of the joint is continued until the disease is practically cured. For this purpose a light brace with two lateral uprights may be used.

Accessory Treatment.—The accessories to protective treatment, which, of course, includes the proper attention to the general condition of the patient, are local applications, injections, and venous stasis. They are classed as accessories because none of them is essential to successful treatment.

The local application of cautery, applied at intervals of a week, or less, may add to the comfort of the patient and stimulate the reparative processes. The roentgen-rays, violet rays and the like appear to act in a somewhat similar manner; they relieve pain, and in most instances the infiltration of the tissues becomes less marked.

Ichthyol ointment of a strength of about 40 per cent. relieves pain and local congestion in certain instances. Firm compression by means

[1] Tr. Am. Orthop. Assn., vol. 6.

of a flannel bandage or by the adhesive plaster strapping is of value, especially in the infiltrating, "boggy" type of disease. The knee is the joint into which injections may be made most easily. Such injections are more likely to be of service in the synovial than in the osteal type of disease. (See page 274.)

Bier's treatment by passive congestion may be easily applied and its effects should be tested. The limb up to the joint is firmly bandaged by a flannel bandage. A rubber band is then applied immediately above the joint with sufficient tension to retard the return of the venous blood. The joint then becomes swollen and congested. The congestion is applied for an hour or more at a time, once or twice daily. Passive congestion apparently increases the stability of the granulation tissue and its further transformation to fibrous tissue. (See page 277.)

Treatment during Convalescence.—During the active stage of the disease the brace must be worn day and night. During the stage of recovery it may be used as a caliper and finally shortened so that the limb may support weight and may be removed at night to permit motion at the knee. Later a form of walking brace (Fig. 268) permitting limited motion at the knee may be of service; but this is not an essential in treatment. If slight knock-knee persists after recovery, it may be overcome by the use of a Thomas knock-knee brace, which will also serve as a protection to the weak joint. The indications of cure have been discussed under Hip Disease. In brief, when sufficient time has elapsed to permit of natural cure; when there have been no symptoms of active disease for months; when muscular spasm has disappeared, one may tentatively remove the brace in the manner described. But any symptom of disease, and particularly increasing limitation of the range of motion, or a tendency toward deformity which resists the manipulative correction that must always be employed in the after-treatment of stiffened joints, indicates the necessity for continued protection. If anchylosis is present, supervision and occasional corrective treatment are usually required during the period of growth to assure final symmetry.

Complications.—Extra-articular Disease.—In certain cases, especially in young children, the disease about the epiphyseal cartilage of the femur or of the tibia may find its way to the exterior before it invades the joint. This fortunate course is indicated by local sensitiveness and swelling over one of the condyles of the femur or about the head of the tibia. In such instances the thorough removal of the disease is indicated, or if a roentgen-ray picture shows that the disease is accessible, even though it is not immediately below the surface, an exploratory operation may be advisable. An incision is made, usually over the internal condyle of the femur. The periosteum is raised and a portion of the cortex is removed in order to expose the spongy bone on either side of the epiphyseal cartilage.

In many instances an area of softening will be found. This must be thoroughly removed. The cavity may be treated with pure carbolic acid or the cautery, or filled with iodoform emulsion and the

wound is then closed. In favorable cases prompt operative intervention may cut short the course of the disease.

Abscess.—Abscess is present as a complication in about one-third of the cases that have received efficient protection, and in a larger percentage of those in which treatment has been neglected.

It was present in 51 per cent. of König's cases[1] and in 47 per cent. of 300 final results reported by Gibney.[2] At the knee, as at other joints, the infected abscess is the most dangerous complication of the disease, as is illustrated by König's statistics:

Death-rate in cases without abscess	25 per cent.
Death-rate in cases with abscess	46 "

Although in many instances abscess indicates an extensive and destructive disease of the bone, yet the exhausting suppuration that is an indirect cause of death is suppuration from infected areas in the thigh and leg, which may have little direct relation to the extent of the original disease. It should be the aim in treatment to prevent this burrowing of fluid after the capsule has been perforated, and to prevent overdistention of the capsule, even in order to lessen the macerating effect of the tuberculous fluid upon the cartilages. When the fluid within the joint is of considerable amount, and when it is increasing in quantity, it may be removed by aspiration, or a better procedure is to incise the capsule. This will permit thorough removal of its fluid and solid contents, after which the opening may be closed with sutures.

Tuberculous abscess which has perforated the capsule may be treated in the same manner, or it may be drained subsequently, according to the indications. Unless the abscess is infected careful bandaging of the thigh and leg should prevent burrowing.

Synovial Tuberculosis.—In the forms of synovial tuberculosis that resemble chronic synovitis the fluid, if the quantity is large, may be evacuated by an incision in the capsule. This should be of sufficient size for inspection—masses of fibrin and hypertrophied and diseased tissue should be removed. Afterward the interior of the joint may be treated with an application of a strong solution of chloride of zinc or pure carbolic acid. The wound should then be closed and a plaster support should be applied. By the operative treatment repair is stimulated and adhesions form which lessen the capacity of the capsule. Later a protective brace should be worn to guard the joint from sudden twists and strains and to limit the range of motion within the painless arc (Fig. 268). The adhesive-plaster strapping may be employed in cases of this class with great advantage. It is in this type of disease that passive congestion is most effective. The same is true of the injection of iodoform emulsion or other remedies of this class. Theoretically, such treatment should hasten repair, should modify the infectious quality of the tuberculous fluid and lessen the danger of infection with pyogenic germs.

Operative Intervention.—Arthrectomy.—When, as in exceptional cases, the disease is progressive and shows no tendency toward re-

[1] Loc. cit.

[2] Am. Jour. Med. Sci., October, 1893.

covery, and particularly if an infected abscess communicating with the joint makes efficient drainage difficult, the operation of arthrectomy may be indicated. If, on the other hand, the disease appears to be confined to the synovial tissues one may hope by its complete removal to hasten recovery.

An Esmarch bandage having been applied, the joint is thoroughly exposed by an internal lateral incision and outward displacement of the patella. A complete synovectomy is then made, and if foci in the bone are present they are excavated with the chisel and scoop. If infection be present the joint may be packed with gauze, the leg being fixed in the position of flexion; but in other instances the wound is closed with or without drainge, as may seem advisable. In a large proportion of cases primary healing may be obtained. By the procedure one may hope to hasten repair by removing the products of the disease, but in all but exceptional cases the functional result will be limited motion or anchylosis. The operation, even if of a radical type, has the advantage over complete excision in that less bone is removed and that the epiphyses, in part, at least, remain; thus the immediate as well as the ultimate shortening is less than after excision.

Results of Arthrectomy.—The direct death-rate of the operation is small. In 150 cases reported by König but 3 deaths were attributed to the operation itself. The final results in 114 of these cases, in which the operation was performed in childhood, were as follows:

Patients cured and living	90	
Cured of the local disease, but not living at the time of the investigation	10	
Practically cured, insignificant fistulæ remaining	2	
	102	= 89.5 per cent.
Living, not cured	5	
Deaths before the cure of the local disease	7	
	12	= 10.5 per cent.

Thus in 89 per cent. of the cases the operation was successful so far as the cure of the local disease was concerned. In 75 per cent. of the successful cases immediate cure was attained; in 25 per cent. fistulæ persisted for a longer or shorter time. In 10 cases some motion was retained, but in others anchylosis followed the operation. In about 70 per cent. of the cases the limb was practically straight; in 30 per cent. it was distorted. This shows the necessity of continued supervision and in many instances of protective treatment during the growing period in all cases in which anchylosis is present from whatever cause.

In 48 cases in which the operation had been performed before the tenth year, and in which the limbs were straight, the influence of the operation on the growth was investigated.

Number of cases.	Years elapsed since operation.	Average shortening in cm.
6	2	1.0
5	3	1.6
4	4	1.0
3	5	2.0
19	6–7	2.0
11	8–13	2.5

These measurements indicate that the shortening is not likely to be very great as a result of the operation, certainly very much less than after complete or even partial excision performed at the same age.

Excision.—Radical excision of the joint in childhood has been practically abandoned, because of the great shortening that results.

Early excision in adult cases is often indicated because it will assure a cure of the disease in a short time, whereas mechanical treatment will at best require years of disability with no certain prospect of absolute cure at the end of the period. If, therefore, the disease has progressed sufficiently to indicate that a natural cure could be accomplished only by anchylosis, or if the time required for cure is of importance to the patient, early excision may be advised in the case of the adult or adolescent whose growth is nearly completed.

Fig. 403.—Deformity and shortening resulting from excision of the knee in childhood.

The operation is performed under the Esmarch bandage. The joint is exposed by the anterior incision, passing below the patella as in operation of arthrectomy. In advanced cases all the diseased tissues including the patella and the capsule are cut away leaving only the skin. Sections of the bones, usually following the contour of the articular surfaces, are removed sufficient depth to include all the diseased area and so fashioned as to permit the bones to be brought into close apposition. They should be fixed by strong sutures of catgut passed through the anterior apposed surfaces of the femur and tibia or by bone pegs. The vessels having been ligated, the wound may be closed with or without drainage, as may be indicated by the character of the disease. A plaster-of-Paris dressing is applied and the limb elevated so that the weight of the leg may be utilized to assure pressure of the apposed bones. Mechanical protection should be provided until union is secure.

There are various modifications of the operation. If the disease is of a superficial character, the patella may be retained, imbedded in the anterior surfaces in the tibia and femur and fixed by bone screws.

Operative fixation of the knee may be considered in younger subjects when the disease, undoubtedly tuberculous, shows little tendency

toward repair. The basis of the argument for fixation is that the eventual result of conservative treatment, after years of comparative disability, will be limited motion attended by discomfort. In this class of cases very little bone is removed, fixation being in part dependent on the apposition of the denuded patella to the tibia and femur and the formation of new bone about the periphery.[1] It would appear that as a rule this type of operation is to be preferred to the more radical arthrectomy which usually results in practical fixation. The question of operative fixation must be decided by the circumstances in the individual cases. From the esthetic standpoint anchylosis in complete extension is preferable to flexion for a male subject, but on this point the patient should be consulted.

Results of Excision.—In König's statistics of 300 excisions, 6 deaths were due directly to the operation, and 23 others occurred during the course of the after-treatment—a total of 29 (9.6 per cent.).

In 23 instances amputation was afterward performed because of failure of the operation. The good results are classed by König as 75 per cent., the bad as 25 per cent. In 193 cases the position of the limb in after years was investigated. It was straight in 175, distorted in 18, all but 1 of this latter group being in children. Of 400 resections of the knee in Bruns' clinic final results were ascertained in 379 cases. The early results were as follows:

Discharged, well	343
Discharged with fistulæ	29
Amputated	17
Dead	17
Not cured	4

Final results:

Well	280	Good results 87.9 per cent.
With fistulæ	3	
Dead, but cured of local disease	45	
Dead, not cured	3	
Living, not cured	10	Bad results 12 per cent.
Dead, not cured	6	
Died in clinic	7	
Amputated	23	

Curvature of the limb:

Straight	27.1 per cent.
Moderately flexed	28.0 "
Markedly flexed	44.9 "

Amputation.—This operation is indicated as a life-saving measure. When the disease is so extensive as to require complete removal of the epiphyses in early childhood, amputation is the preferable operation, as the limb, aside from requiring constant protection to prevent deformity, will be so short as to be of little practical use.

Operations for the Relief of Final Deformity.—In the majority of the cases deformity can be rectified by one of the methods already de-

[1] So called extra-articular fixation by the application of autogenous bone grafts to either side of the joint has been employed also.

scribed. If, however, there is bony anchylosis in an attitude of marked flexion the limb may be straightened by linear osteotomy of the femur just above the joint, supplemented if the deformity is extreme by a secondary osteotomy of the tibia. If flexion deformity is of long standing, division of the hamstring tendons is often required supplemented by posterior capsulotomy. In such cases the correction should not be completed at the first operation but preferably at several sittings to permit the adaptation of the soft parts and the bloodvessels to the new attitude. Simple osteotomy is to be preferred to cuneiform osteotomy in young subjects, as no bone is removed.

Genu valgum may be corrected by a similar operation. (See Osteotomy for Knock-knee.)

In certain selected cases the joint may be opened for the purpose of separating the bones and interposing flaps of fibrous tissue. Although the prospect of restoring useful motion is slight, it will at least serve to correct deformity if this be present. (See Arthroplasty.)

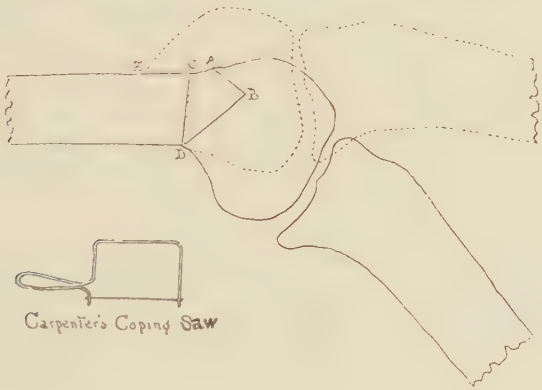

FIG. 404.—Jig-saw osteotomy, assuring security. (Osgood.)

Prognosis.—The most important statistical evidence on the course and the outcome of tuberculous disease of the knee-joint in childhood has been presented by Gibney. The statistics completed in 1892 were the result of an investigation of 499 cases treated during a period of twenty years, 1868–1887. In but 300 of these could definite information be obtained.[1]

Eighty-seven per cent. of the cases were in children, and 51 per cent. of the patients were less than five years of age at the inception of the disease.

The cases were divided into three classes, according to the treatment that had been followed:

1. The expectant treatment. In this class no apparatus had been employed, or, if employed, it had been inefficient.

[1] Am. Jour. Med. Sci., October, 1893.

2. The fixation treatment. In this class the joint had been more or less efficiently splinted, but not protected from impact with the ground.

3. The protective treatment. In this class the joint had been splinted and protected from jar, and the mechanical treatment had been efficient.

The results were classified as follows:

	Total.	Excisions.	Amputations.	Deaths.	Under treatment.	Cured
Expectant	71	5	3	3	9	51
Fixation	190	9	1	35	31	114
Protection	39	0	0	2	11	26
	300	14	4	40	51	191

Mortality.—The total deaths in the 300 cases were 40 (13.3 per cent.); 26 of these were from causes directly or indirectly connected with the disease (8.6 per cent.), viz.:

Operative shock	1
Prolonged suppuration	16
Tuberculous meningitis	6
Phthisis	3
	26
Intercurrent disease	14
	40

Function.—The functional results as regards motion in the cases in which conservative treatment had been continued to the end, including the cases still under observation, 242 of 300, were as follows:

	Total.	Motion retained.	Anchylosed.
Expectant	60	44 or 73 per cent.	16
Fixation	145	113 or 77 "	32
Protection	37	34 or 95 "	3
	242	191 or 79 per cent.	51

Of the 191 patients who retained a movable joint, 74 had had abscesses, 3 or more cicatrices being present in 39.

As to the range of motion, in 74 it was from 45 degrees to normal and in 41 more than 90 degrees; thus 30 per cent. of the patients retained a fair range of motion.

Deformity.—In 51 cases anchylosis was present; in 16 of these the limb was practically straight, in 35 it was flexed more than 30 degrees (69 per cent.).

These statistics again illustrate the great tendency toward deformity, when during the growing period there is anchylosis at the knee from whatever cause.

BOSTON CITY HOSPITAL

In the 191 cases in which motion was retained the limb was practically straight in 125 (65 per cent.). In 49 others the flexion was less than 25 degrees, and in but 16 could the deformity be classed as bad (8 per cent.).

In 10 cases only did relapse occur after apparent cure.

In but 16 of the 449 cases was there involvement of other joints while the patients were under observation (3.2 per cent.). In 8 of these the spine was diseased, in 2 the hip, and in 6, other joints.

Of 106 apparently final results reported from the New York Orthopaedic Hospital (*loc. cit.*). There were 39 with motion from full extension to 90 degrees of flexion, 36 with motion from full extension to 15 to 90 degrees of flexion, 13 with anchylosis in a straight position, 13 with anchylosis in flexion, and 5 with flexion deformity without anchylosis. The average duration of treatment seven years. The death-rate was 6.2 per cent.

The influence of age upon the death-rate and the ultimate causes of death are illustrated by König's statistics, the death-rate being much higher, at least in the cases in early childhood, than in this country.

According to König's statistics, the death-rate, direct and indirect, from disease of the knee-joint, was as follows:

323 children (1 to 15 years of age), deaths	65	= 20 per cent.
225 patients (16 to 30 years of age), deaths	61	= 24 per cent.
68 patients (31 to 40 years of age), deaths	30	= 44 per cent.
74 patients more than 40 years of age, deaths	45	= 60 per cent.

Causes of Death.

Deaths from causes not connected with the disease	14	= 2.0 per cent.
Deaths following operations	18	= 2.5 per cent.
Deaths caused by tuberculosis, 141 = 22.5 per cent. of all cases and 80 per cent. of all the deaths.		
Tuberculosis of the knee	1	
Tuberculosis of the lungs	94	
General tuberculosis	30	
Tuberculous meningitis	7	
Acute miliary tuberculosis	3	
Tuberculosis of other parts	6	
	141	

It may be noted that 16 of the 40 deaths in Gibney's cases were due to prolonged suppuration, and that of 51 cases still under observation 26 had been treated for ten years or longer, and were still uncured. This indicates that in a larger proportion of the cases conservative methods should have been supplemented by more radical treatment. Still, taken as a whole, the results, although the mechanical treatment was, in many instances, far from efficient, are much better than any others that have been presented.

On this evidence the following conclusions seem to be justified: The death-rate in childhood from all causes should be less than 10 per cent. The duration of treatment is from two to ten years. Recovery with a useful range of motion, if the diagnosis has been made at an early

stage and if efficient mechanical treatment has been employed, particularly if it may be combined with the sunlight treatment, may be predicted in 50 per cent. of the cases.

Deformity may always be prevented by treatment and by supervision. Under favorable conditions radical operations are not often indicated, but when indicated they should not be delayed too long. Amputation of the limb should prevent death from prolonged suppuration. In a certain proportion of cases the disease may be cut short by early exploratory operations for the removal of foci of disease in the bone before the joint has become involved, and in cases of the chronic type operative fixation may be indicated.

Although the benefits of protective treatment are as evident in disease of the adult as in childhood, yet early operation is often indicated in this class, because of the necessity for shortening the period of disability, and because excision assures a straight and useful limb.

CHAPTER X.

NON-TUBERCULOUS AFFECTIONS AND DEFORMITIES OF THE KNEE-JOINT.

STRAINS AND INJURIES OF THE KNEE IN CHILDHOOD.

Injury of the knee in childhood may cause local discomfort and persistent flexion of the leg, even when but little synovial effusion is present. In this class of cases the application of a plaster splint, under sufficient traction to overcome the deformity, is of service in placing the part at rest and preventing further injury. The importance of treating promptly slight injuries of the joints in childhood, especially in the class of patients predisposed to tuberculous infection, has been mentioned already in the consideration of hip disease.

Muscular "cramp," a form of tetanic contraction, induced possibly by injury or by a mild form of arthritis (toxic), which fixes the limb in a flexed or extended position, is sometimes seen in children of a susceptible or nervous temperament. The treatment is similar to that of strains.

SYNOVITIS.

Acute Synovitis.—The knee from its size and construction is especially liable to injury,[1] which if of any severity is usually followed by effusion of fluid within the joint (synovitis). Its symptoms are discomfort, swelling, local heat, and limitation of motion. The patella floats when 30 cc. of fluid is contained in the joint, the normal capacity being about 200 cc.

Treatment.—Injury and its attendant synovitis may be treated immediately by splints, by elevation of the limb, by the application of ice-bags and the like. Aspiration should be employed whenever the effusion is sufficient to cause tension or discomfort and should be repeated as often as indicated. Repair is hastened by functional use if it be adapted to the degree of injury of the joint. One of the most efficient methods of treatment is that by means of the adhesive-plaster strapping advocated by Cotrell and Gibney. The entire surface of the knee, except a narrow space in the popliteal region, is firmly strapped with overlapping layers of adhesive plaster, extending from the upper third of the leg to the middle third of the thigh; and over this a flannel bandage is applied; or, if the leg is swollen, the entire limb should be firmly bandaged with elastic stockinette bandage, from the toes to the upper third of the thigh in addition. The adhesive plaster

[1] Causing more "wastage" to foot-ball teams than all other injuries combined, Austin and Campbell, Can. Med. Jour., November, 1927.

serves as a support which permits a certain degree of motion sufficient to stimulate the circulation, and thus to hasten the restoration of the normal condition. If greater compression is desired, the entire joint may be covered with the adhesive plaster as suggested by Hoffmann.[1] A pad of cotton is placed in the popliteal space, a close-fitting stocking leg is drawn over the knee, and about this circular bands of plaster are drawn as tightly as the comfort of the patient will permit. The adhesive plaster strapping is renewed from time to time, as the swelling diminishes, and its use is continued until the symptoms have entirely disappeared. If the synovitis persists and if the capsule is thickened so that its capacity for absorption is diminished, it should be incised, the contents removed by flushing with hot salt solution—afterward the interior may be treated with tincture of iodine or carbolic acid—the aim being to lessen the irritability and to stimulate the reparative process. In more advanced cases the removal of the thickened and degenerated synovial membrane is indicated.

In cases of chronic synovitis the muscles are atrophied and the ligaments are relaxed. Thus weakness and discomfort may persist indefinitely unless the normal tone is restored by massage and by regulated exercises. In cases of the more severe type a supporting brace is indicated for the purpose of preventing lateral movement and limiting the anterior-posterior range to the painless arc (Fig. 268).

Chronic and Recurrent Synovitis.—Chronic synovitis is of far greater interest from the orthopaedic stand-point than the acute form because it is usually symptomatic of some general or local pathological condition or change within the joint.

Bennet[2] has analyzed 750 cases, the apparent causes of the effusion being as follows:

LOCAL.	
1. Internal derangement of the joint	428
2. Loose bodies in the joint	24
3. Genu valgum	4
GENERAL.	
1. Osteoarthritis	107
2. Rheumatism and gout	30
3. Syphilis	42
4. Gonorrhea	28
5. Malaria	18
6. Hemophilia	3

In 56 cases no cause could be assigned and 13 were instances of "quiet effusion."

Incidental Synovitis.—Strains of the knee-joint slight in degree may be induced by genu valgum, by slipping patella and the like, and discomfort about the knee is not infrequently an accompaniment of the weak foot. It may be stated also that simple overweight or strain may induce discomfort, creaking sensations, and slight effusion in the

[1] New York Med. Jour., January 27, 1900.
[2] Lancet, January 7, 1905.

joint. In fact, overweight is the most constant of all the aggravating causes of weakness in the knees of the character described. Reduction of weight by proper diet is therefore an important indication for treatment.

Intermittent Synovitis (Quiet Effusion). — Painless synovitis at the knee and occasionally at other joints is sometimes observed particularly in young females. It has apparently some connection with menstrual irregularities. Recurrent effusion of a similar character in one or both knees is occasionally seen in older subjects. Without appreciable cause, and occasionally at fairly regular intervals of from fifteen days to a month or more, the joint fills with fluid, the principal discomfort being the tension. The swelling persists for several days and disappears. In the intervals the joint appears to be normal except for a certain laxity of the ligaments. Fifty-five cases from literature have been collected by Schlesinger.[1] It is classed by Kamp[2] as a trophic vasomotor neurosis. Thyroid extract has been employed in cases of this character with apparent benefit.[3] (For complete bibliography, see Bierring.[4])

In rare instances *primary sarcoma* of the capsule may cause chronic synovitis. The principal diagnostic points are the local or general thickening of the capsule and the blood-stained fluid obtained on aspiration. The course of the disease is very chronic and its malignancy is slight. Thorough removal of the capsule with or without excision would seem to be indicated.

One case has come under my observation and 11 others are reported,[5] in but 1 of which was there general dissemination of the disease.

Other forms of synovitis or joint disease dependent upon general constitutional causes or upon direct infection have been considered in Chapter VI.

INJURY TO CARTILAGE.

In the majority of cases the injury caused by a strain of the knee or other joint is limited to the muscles and ligaments, the internal lateral ligament being most vulnerable.

In some instances discomfort on weight-bearing, at first slight, increases after two or more weeks, from which it may be inferred that the articular cartilage has been injured.

Cartilage is a non-vascular structure which in the process of repair is penetrated by newly formed bloodvessels, and becomes swollen and sensitive particularly to direct pressure. In cases of this class complete functional rest is indicated for a time.

[1] Nothnagel: Spec. Path. u. Jour. Wien., 1903, 1–27.
[2] Deutsch. med. Wchnschr., March 21, 1907.
[3] Ribierre: Bull. de la Soc. Méd. des hôp. de Paris, 1910, **27**, 96.
[4] Jour. Am. Med. Assn., September 23, 1921.
[5] Zülig: Corresp.-Blatt für schweitzer Aerzte, vol. **47**, 197.

INTERNAL DERANGEMENT OF THE KNEE-JOINT. (Hey, 1782.)

Internal derangement signifies sudden interference with the function of the joint which may be due to (*a*) displacement or fracture of a semilunar cartilage; (*b*) other injury; (*c*) loose bodies in the joint.

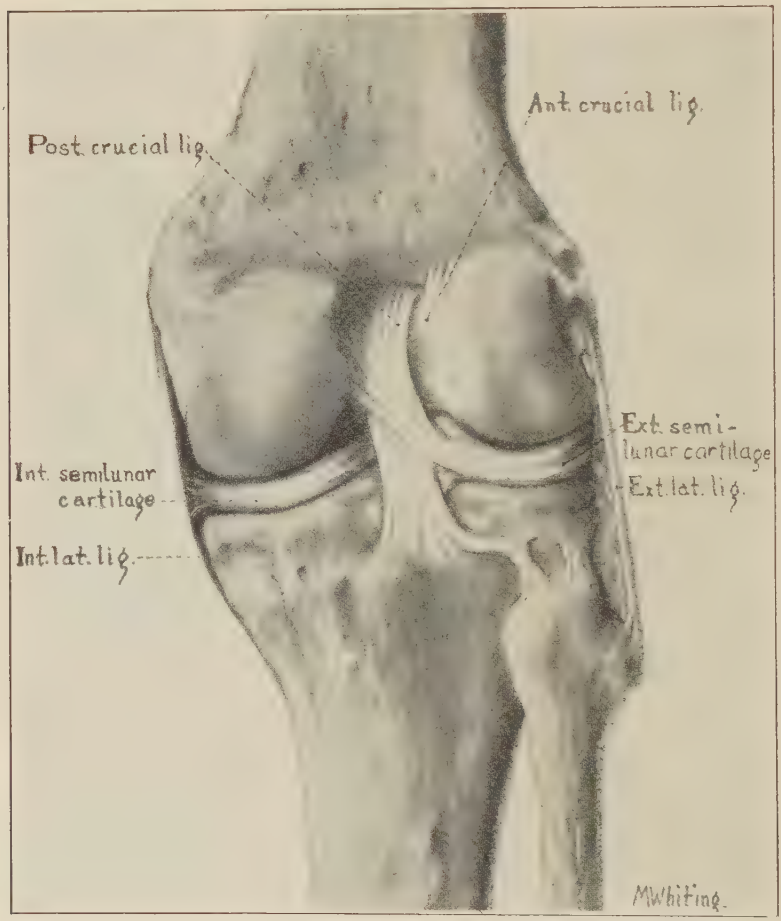

FIG. 405.—Intimate relation of internal semilunar cartilage to internal lateral ligament and the lack of this relation of the external semilunar cartilage to the external lateral ligament. (Henderson.)

Displacement of a Semilunar Cartilage.—By far the most common cause of sudden interference with motion at the knee-joint is displacement of the internal semilunar cartilage. This is caused usually by a wrench or sudden inward rotation of the femur on a fixed tibia in the attitude of flexion.

There is pain, often a sensation of something slipping, followed in at least half of the cases, by inability to extend the limb.

The accident is especially common among miners who work with the knees flexed, and those who engage in violent exercises, as football.

An effective method of reduction is that of Whitelock:

Place the patient flat on his back. Standing on the outer side of the affected limb, flex the leg on the thigh and the thigh on the trunk as much as possible; at the same time adduct the limb until the flexed knee comes to lie across the middle line of the body at the navel. With the limb in this position all the ligaments and tendons are slackened. Take hold of the ankle with one hand and grasp the knee with the other to steady it. With the hand on the ankle, abduct the tibia from the femoral condyle, so as to open the space as widely as possible, then with the leg used as the long arm of a lever work it to and

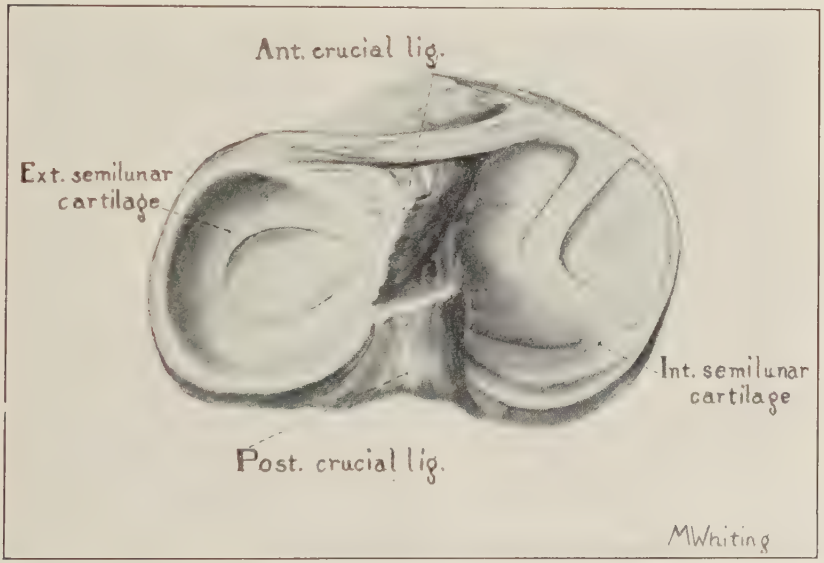

FIG. 406.—The common type of tear, called by Rutherford Morison the "bucket-handle fracture;" the loop prevents extension. (Henderson.)

fro with slight movements of rotation until the cartilage is felt to slip back, the patient experiences relief, and the knee becomes capable of full extension. When the external cartilage is at fault, the abduction of the tibia must be from the external femoral condyle and the rotation in the opposite direction.

In some instances an anesthetic may be required. Displacement of the semilunar cartilage, whether causing "locking" or not, is usually followed by effusion, sensitiveness to pressure over the internal border of the tibia—and by the ordinary symptoms of the sprain which may involve the internal lateral ligament. The accident having once occurred, is likely to recur; the patient recognizing the movements that are likely to cause the displacement, learns also the proper manipulation for its replacement.

Displacement of the external cartilage is comparatively uncommon, because it is less exposed to strain by the movements of the joint and less intimately connected with the capsule. The symptoms are like those described, the discomfort being referred to the outer aspect of the joint. It is one of the causes of the snapping knee. In cases of this class, the slipping cartilage may often be distinguished by the examiner's finger.

In other instances somewhat similar symptoms may follow injury at the knee; pinching of the synovial membrane, bruising or fracture of the cartilage, or a strain of one of the ligaments within the joint, being assigned as causes. In cases of this character, in which symptoms recur from time to time, the joint may become weak and insecure, partly because of the repeated synovial effusion and partly because of the muscular relaxation.

FIG. 407.—Cage support for knee in chronic arthritis when full extension is not allowed. (Jones and Lovett.)

Treatment.—If the displacement is primary, after reduction, the limb should be fixed in a plaster splint for two weeks or more to allow for reattachment at the point of rupture. Afterward the joint may be protected by the adhesive-plaster strapping, and when the effusion has been absorbed massage and exercises for strengthening the muscles should be employed. The patient should avoid predisposing attitudes and should cultivate "straight walking" in order to remove the strain from the inner aspect of the joint.

MEDICAL LIBRARY
OF THE
BOSTON CITY HOSPITAL

In the more chronic cases in which the ligaments are lax, a brace which will permit anterior-posterior motion but prevent lateral mobility, may be required. The Campbell brace (Fig. 268), used by Shaffer, is a light and effective support that interferes little, if at all, with the use of the limb. Jones uses a brace to limit lateral motion; what is called a cage splint, which is like a Campbell brace in its action, but not attached to the shoe, holding its place by pressure, and various forms of knee caps and bandages are applied by the patients.

If the diagnosis of displaced or fractured cartilage can be established,[1] and if it is the cause of serious disability it should be removed. The same may be said of isolated foreign bodies which are known to be the cause of the symptoms.

The operation[2] should be performed with the leg flexed upon the thigh, and dependent. A perpendicular incision, about 3 inches in length, is made midway between the internal lateral ligament and the patella. When the capsule is opened the detached cartilage, drawn away from the tibia by the tension on the capsule, comes into view. It may be normal in appearance or yellowish in color and distorted.

It is divided into two parts by continuing the incision downward. The anterior half may be detached by the forceps.

The posterior part is attached to the capsule from which it must be dissected in order to remove it easily.

The synovial and capsular incisions are then united with fine catgut, the wound is closed, and a thick sheet-wadding bandage, usually reinforced by a thin board splint, is applied in slight flexion at the knee. At the end of a week or more the patient may walk about with the support of adhesive-plaster strapping. In cases of long standing, in which there is laxity of the ligaments, the Campbell brace may be applied with advantage. Perfect functional recovery is the rule often within a few weeks.

The operation for a displaced external cartilage is conducted in the same manner, the incision being made on the external aspect of the joint.

If, as in some instances, the infrapatella pad of fat is thickened and congested it should be removed, also projections from the synovial membrane that may interfere with free movement of the joint. In cases of this character the incision should be prolonged upward to permit complete exposure.

Immediate functional use has been urged by certain surgeons on the ground that thus adhesions and limited motion may be prevented. It seems, however, more reasonable to place the part at rest for a time sufficient to permit union of the wounds. According to the report of the Alder Hay Military Hospital,[3] the average time required after this operation before return to duty was four months.

[1] In some instances the displaced cartilage may be demonstrated by the injection of oxygen, which shows in the roentgen-ray picture a black space between it and the tibia.

[2] Jones: Ann. Surg., December, 1909. Whitman: Med. Rec., July 22, 1916.

[3] British Med. Jour., December 28, 1928.

Loose Bodies in the Knee-joint.[1]—Loose bodies in the knee-joint may be composed of portions of fibrin, fragments of synovial membrane, or bits of cartilage or bone and the like (osteochondritis dissicans). In certain forms of synovial tuberculosis, arthritis deformans or similar chronic affections, loose bodies may be present in large numbers (osteochondromatosis). From the therapeutic stand-point, however, the important cases are those in which the joint is otherwise normal. In this class the foreign body is sometimes detected by the patient as a smooth, movable object on one or the other side of the patella; but in many instances the first sign of its presence is interference with the function of the joint. After a sudden movement or when the knee has been flexed, as in the kneeling position, or without appreciable cause, severe pain in the knee is felt and the joint may be fixed in the position of flexion. By massage, manipulation, or spontaneously the foreign body is dislodged from between the surfaces of the bone and movement becomes free and painless, but discomfort remains for a time and in most instances synovial effusion follows. These symptoms recur at intervals, and the disappearance of the movable body from its accustomed place at such times may demonstrate its relation to the disability.

OSTEOCHONDRITIS DISSECANS (KÖNIG[2].)

In its typical form this is a semi-detached fragment of cartilage with a portion of underlying bone on the under surface of the internal condyle of the femur in the neighborhood of the insertion of the posterior crucial ligament. At a later period it may be separated and become a loose body in the joint, in some instances increasing in size after its detachment. The affection is most common in male adolescents and is supposed to be induced in most instance either directly by injury or by subsequent disturbance of nutrition.

The symptoms are discomfort, weakness and catching or locking of the joint, the disability corresponding to the interference with function. The diagnosis is made by roentgen-ray examination which shows slight elevation of the fragment above an irregular base.

Lehr[3] reports the results in 106 cases observed at Kiel, 1914–1926. In two-third of the cases there was spontaneous cure, the fragment remaining firmly attached or reuniting to the bone.

Treatment.—Operative removal is indicated, if warranted by the symptoms and if the diagnosis is clearly established. This may be easily accomplished by an incision on the inner side of the patella.

[1] According to Immelmann (Ztschr. f. ärtz. Fortbildung, 1904, No. 5), in 30 per cent. of normal individuals a sesamoid bone (the "fabella" noted by anatomists in the sixteenth century) may be found beneath the external head of the gastrocnemius muscle that might on a roentgen-ray examination be mistaken for loose body within the joint. It is present in about 20 per cent. of individuals and is usually bilateral, see also Simon (Ztschr. f. Chir., March 13, 1926).

[2] Deutsch Ztschr. f. Chir., 1890, vol. **27**.

[3] Ztschr. f. Chir., May 25, 1929.

The depression in the condyle is usually covered by connective tissue and should not be disturbed. If the cartilage has become detached or if, as in some instances, there are more than one, thorough exposure of the joint may be required. In most instances the long internal incision with outward displacement of the patella is sufficient, but the median division of the patella as suggested by Jones gives the most complete exposure.

Osteochondritis dissecans though more common at the knee, may involve any joint. Weil[1] has recorded 50 cases observed at the Breslau clinic. In 20 per cent. of these both elbows were involved.

The apparent cause is injury to the capitellum and the most constant symptom limitation of motion. The diagnosis being established by roentgen-ray examination, removal of the obstruction is indicated.

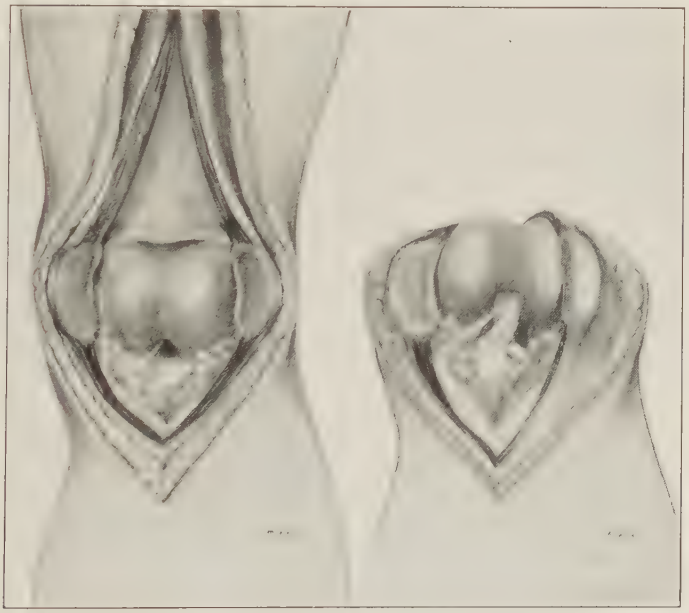

FIG. 408.—Complete exposure of the joint by the median incision of Jones, showing division of tendons and fat pad with ligamentum mucosum intact and attached to intercondylar notch. Floor and lower edge of quadriceps pouch is seen above. (Brackett.)

OSTEOCHONDROMATOSIS.

In some instances loose bodies are multiple, usually as a complication of the various forms of arthritis. In fairly normal joints they are most often produced[2] apparently by osteo-cartilaginous transformation of projecting fringes of synovial membrane. Removal is indicated, but the prognosis is naturally less favorable than in

[1] Ztschr. f. Chir., May 5, 1928.
[2] Fisher: British Jour. Surg., April, 1921.

cases of the preceding class.[1] Henderson notes that the knee-joint is divided into anterior and posterior compartments, the anterior of which is most readily exposed by an incision in front of the fibula; the posterior, by one just in front of the inner or outer hamstrings.

Loose bodies in the ankle, elbow, and other joints are of similar origin.

Kappis[2] records 45 cases of loose bodies in the elbow-joint, caused by detachment of cartilage from the capitellum. In 21 of these, injury appeared to be the cause.

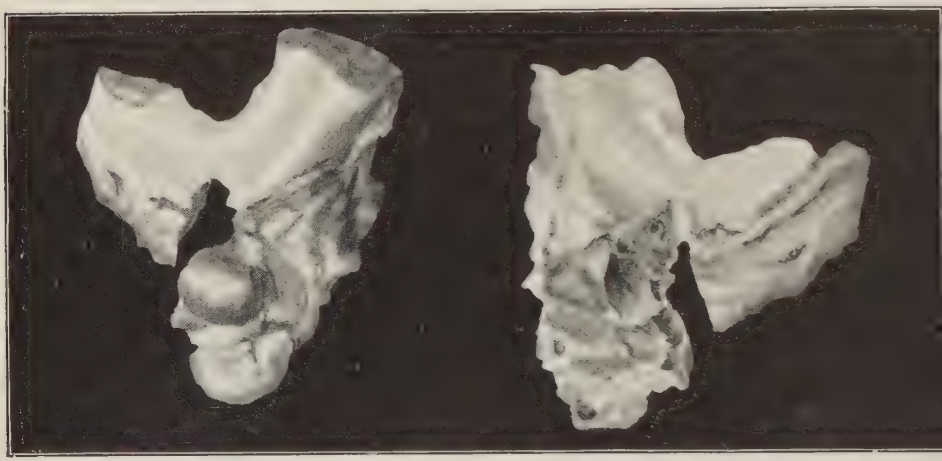

FIG. 409.—Photograph of a typical specimen of cyst of the external semilunar cartilage (Ollerenshaw, British Jour. Surg., April, 1921.)

CYSTS OF THE SEMILUNAR CARTILAGES.

The cyst usually appears as a small, resistant, somewhat sensitive swelling on the external surface of the tibia just below the joint. It gradually enlarges and causes discomfort and sometimes interferes with the movement of the joint. It contains a gelatinous fluid and communicates with one or more cystic formations in the external cartilage, which is usually hypertrophied. The cysts are apparently of the nature of ganglia, of the type often seen at the wrist-joint. They are far more common in the external than the internal semilunar cartilage. Of 58 cases, 40 were of the external cartilage. Of 35 cases, 26 were in males, which would seem to indicate the influence of injury in the etiology. Ollerenshaw[3] thinks the cysts develop from preëxisting spaces in the cartilage.

Complete removal of the cartilage is the only effective treatment.

[1] Henderson: Am. Orth. Assn., May, 1917.
[2] Deutsch. Ztschr. f. Chir., 1920, No. 157.
[3] British Jour. Surg., April, 1929.

RUPTURE OF THE LIGAMENTS.

Severe wrenches of the knee may cause rupture of the lateral ligaments or rupture of the crucial ligaments, usually the anterior with avulsion of the tibial spine or its anterior tubercle. If efficient support at the time of the injury and subsequent protection are assured, the patients usually recover with but little impairment of function. Displacement of the tibial spine, if it interferes with function, may require removal

FIG. 410.—Multiple bodies composed of cartilage and bone contained in a cyst of the popliteal space. (See Fig. 411.)

Lateral Ligaments.—In cases of persistent laxity of the joint resulting from rupture of the internal lateral ligament, McMurray[1] has restored security by substituting the tendon of the sartorius. This is separated from the fascia, displaced forward and its upper portion implanted

[1] British Jour. Surg., January, 1919.

in a groove cut in the internal condyle, where it is sewed to the periosteum at sufficient tension to prevent separation of the bones. The internal lateral ligament is then plicated and correspondingly shortened.

Fig. 411.—Bodies removed Fig. 410 with a portion of lining membrane, showing the process of formation. The bodies are composed of bone covered with cartilage.

The Crucial Ligaments.—The longer and more important is the posterior-anterior, or external, running from the posterior-external aspect of the intercondylar notch forward, downward and inward to its attachment in front of the anterior tibial spine.

The posterior-posterior, or internal, runs from its attachment on the front and the inner part of the intercondylar notch downward, outward and backward to a point on the posterior margin of the tibia, close to the popliteal notch.

The anterior ligament checks anterior displacement, the posterior checks posterior displacement, and both limit internal rotation of the tibia. Thus, rupture of the anterior ligament permits the tibia to slip forward when weight is borne, while hyperextension results from rupture of the posterior ligament. Rupture of both is usually accompanied by injury of other ligaments with a resulting flail-joint.

Hey-Groves replaces the anterior ligament—that most often ruptured—by a strip of the ilio-tibial band about eight inches in length, which, attached below to the tibia, is passed through a hole bored in the external condyle then through another, beginning just in front of the tibial spine and ending externally just over the prominent part of the internal tuberosity of the tibia. The band, having been drawn through at the proper tension, is then drawn upward

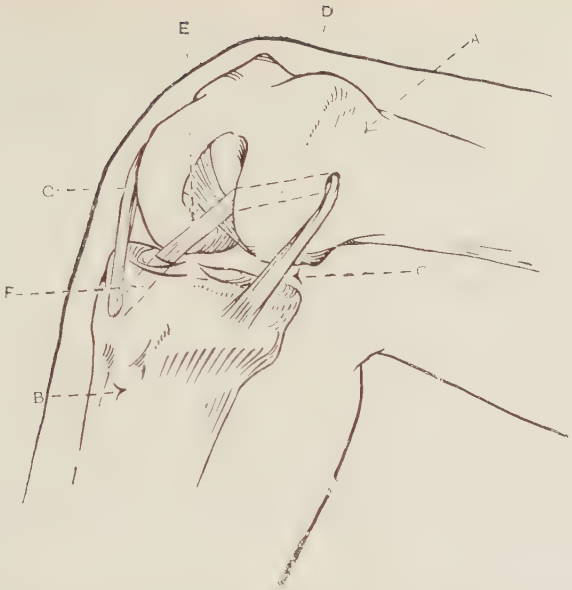

FIG. 412.—Repair of the anterior crucial ligament. *A*, femur; *B*, tibia; *C*, ilio-tibial band; *D*, tunnel in external condyle of femur; *E*, intra-articular portion, forming new ligament; *F*, tunnel in tibia; *G*, terminal part of fascial band turned up to supplement the internal lateral ligament. (Hey-Groves.)

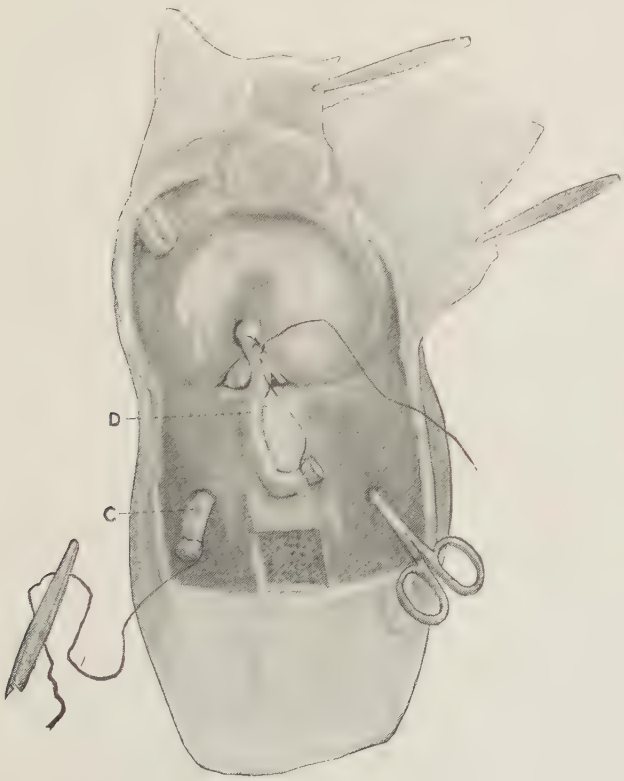

FIG. 413.—Showing the semitendinosus, D, being drawn through the lateral tuberosity of the tibia. The gracilis, C, is already in position. (Edwards.)

and attached securely to the surface of the internal femoral condyle, thus reinforcing the lateral ligament. In this operation the joint is opened by a U-shaped incision passing below the tubercle of the tibia. This is cut from the shaft, and the patella and capsule are reflected upward.

Edwards[1] uses the tendons of the gracilis and semitendinosus muscles for the same purpose, as shown in Fig. 413.

HYPERPLASIA OF FATTY TISSUES—HOFFA'S DISEASE.

Hyperplasia of Fatty Tissue within the Joint.—The largest of the pads of fibro-fatty tissue within the knee-joint is of a somewhat triangular form, its base lying in the interval between the femur and the tibia, its apex projecting upward, held between the femoral condyles by the ligamentum patellæ and the ligamentum mucosum. This may become enlarged and sensitive to motion and pressure, usually as the result of injury or overstrain. The patient suffers from discomfort, particularly on changing from a position of rest to activity and from creaking sensations or even interference with motion. At times synovitis may be present, and in many instances a resistant swelling is apparent on either side of the patella and its ligament.

On opening the joint, a firm, yellowish-red prominent mass is seen beneath the patella ligament, often with lateral prolongation into the joint.

Treatment.—Complete extension at the knee causes pressure on the sensitive tissue. Thus limitation of this movement by a brace or other means may be indicated. If the symptoms are not relieved by rest, strapping or other conservative treatment, the removal of the hypertrophied tissue is indicated. Sensitive tumors of a similar nature may appear in other parts of the joint and folds or masses of hypertrophied synovial membrane, the effect usually of repeated inflammation may induce similar symptoms. In such cases exploration of the joint, for the purpose of ascertaining the cause of the symptoms or for removal of the obstructing parts, is advisable.

It may be emphasized that protection of weakened knees from overstrain is a very important element in treatment, irrespective of the cause of the disability. Thus the reduction of the body weight is of the first importance if the patient is corpulent. A high chair should be provided in order to lessen the strain on rising from the sitting posture, and stair climbing which requires fifteen times the energy required for walking on a plain surface, should be avoided if possible.

BURSITIS.

Prepatellar Bursitis.—Synonym.—Housemaid's knee.

Enlargement of the bursa lying over the patella and its ligament is common among those who have to kneel much of the time; hence the

[1] Brit. Jour. Surg., January, 1926.

MEDICAL LIBRARY
OF THE
BOSTON CITY HOSPITAL

popular name. Occasionally cases of acute bursitis, in which there is considerable effusion into the sac, are seen, and these are sometimes mistaken for synovitis of the knee.

Treatment.—In acute cases strapping the front of the knee with strips of adhesive plaster which will limit motion and provide compression is an effective treatment. If the effusion is considerable it may be relieved by aspiration or incision. In chronic cases cure can be attained only by the removal of the thickened sac.

Pretibial Bursitis.—Beneath the ligamentum patellæ, occupying the space between the tendon and the periosteum of the tibia, is the deep pretibial bursa. It is, according to the investigations of Lovett,[1] as wide or somewhat wider than the tendon; its upper border is on a level with the joint, its lower border reaches to the tubercle of the tibia, and, being slightly longer on the outer than on the inner border, it is somewhat triangular in shape. It does not communicate with the knee-joint.

Enlargement of this bursa is, as a rule, the result of injury, but, as bursitis elsewhere, it may be a complication of infectious diseases, rheumatism and the like.

Symptoms.—The symptoms are stiffness at the knee and pain on sudden movement, especially when strain is exerted on the tendon complete flexion or extension of the leg as in active use. The tubercle of the tibia seems enlarged and is sensitive to pressure, and a swelling on either side of the ligament is usually evident.

Treatment.—The affection, if at all acute, may be treated by relieving the strain and pressure on the tendon, by fixation of the limb for a time in a plaster bandage or other form of splint. Later the adhesive-plaster strapping will provide sufficient fixation and pressure. The absorption of the fluid may be hastened by the application of the cautery. If the swelling is persistent, the fluid may be evacuated by aspiration or incision or the sac may be removed.

ENLARGEMENT OF THE SUPERFICIAL PRETIBIAL BURSA.

A small bursa, lying upon the insertion of the ligamentum patellæ, may become enlarged, causing an apparent hypertrophy of the tubercle of the tibia which is sensitive to pressure. It may be treated by strapping with adhesive plaster, and the prominent tubercle should be protected by some form of bunion plaster.

BURSÆ AND CYSTS IN THE POPLITEAL REGION.

A small bursa, lying beneath the insertion of the biceps, when enlarged and sensitive may cause disability and discomfort that may be mistaken for displacement of the external semilunar cartilage. It may be, however, easily identified and removed.

[1] Boston City Hospital Reports, 1897, 8th series.

Bursitis of the sac lying between the inner head of the gastrocnemius and the semimembranosus muscles may cause a fluctuating swelling on the inner side of the popliteal region. It may be treated by compression, by incision, or by complete removal as may seem advisable.[1] Cysts in the popliteal region often communicate with the knee-joint and are complications of rheumatic or tuberculous disease. In such cases they are of interest principally from the diagnostic stand-point.

Fig. 414.—The projection of the epiphysis simulating of injury to the tibial tubercle.

INJURY OF TIBIAL TUBERCLE. ("OSGOOD—SCHLATTER DISEASE.")[2]

In childhood and adolescence, the tibial tubercle, a tongue-like prolongation of the epiphysis of the tibia, is not united to the shaft and may be partly separated from its attachment by sudden strain or contraction of the quadriceps extensor muscle. The symptoms are local pain, sensitiveness, and apparent enlargement of the tubercle. The diagnosis may be confirmed by roentgen-ray examination. In other instances one or both tubercles may be enlarged or sensitive without history of direct injury from which it may be inferred that a disturbance of nutrition similar to that occurring at other ossifying centers may be the primary cause. In 15 of 17 cases reported by Pomeranz[3] the patients were males.

[1] Riedal: Deutsch. Ztschr. f. Chir., 1915, vol. **132**, 144.
[2] Beitr. z. klin. Chir., vol. **38**, No. 3.
[3] Am. Jour. Surg., February 25, 1925.

Treatment.—The limb should be fixed in the extended position by a plaster splint until union is firm.[1] If actual displacement is present open operation for reduction and reattachment is indicated.

Hodgson[2] has called attention to the fact that the roentgen-ray examination is often misleading and that pictures of both knees should be compared before deciding on operative intervention, since the peculiar tongue-like prolongation of the epiphysis often appears to be separated from the tibia on the uninjured side (Fig. 414).

CHONDROMALACIA OF THE PATELLA.

Irregularities in the shape of the patella, particularly about its margins, apparently of congenital origin, have been noted as a cause of disability in soldiers on the march.[3]

Aleman,[4] in a series of 220 arthrotomies on young soldiers in the Garrison Hospital at Stockholm, found softened areas on the under surface of the patella in 33 per cent, which he ascribed to injury of the cartilage in childhood.

The symptoms were creaking sensations and synovitis.

Aleman classes this form of chondromalacia as one of the predisposing causes of localized arthritis deformans.

The removal of the diseased area in 22 cases, apparently relieved the symptoms by lessening the friction.

ACQUIRED GENU RECURVATUM.

Synonym.—Back knee

Genu recurvatum, as the name implies, is a deformity in which the knee is habitually overextended.

Etiology.—Acquired genu recurvatum may be a simple local deformity, or it may be secondary to weakness or distortion of other parts. Local or primary genu recurvatum may be an effect of rhachitis, or of disease or injury of the femur or tibia. In this form the femur may be curved sharply forward above the joint, or the upper extremity of the tibia may be bent backward at the epiphyseal junction, and flexion may be limited by the obliquity of the articulating surfaces.

More often the deformity is secondary. It may be, for example, an effect of equinus, either congenital or acquired, in which the knee is strained by the effort of the patient to place the heel upon the ground. It may be caused by the use of a brace in the treatment of hip disease, if the knee-joint is not properly supported, and it is often seen also as a result of disease at this joint, for which no apparatus has been employed. It even appears in some instances on the sound side, apparently as a form of compensation for the shorter limb (Fig. 297). It is

[1] Osgood: Boston Med. and Surg. Jour., January 29, 1903.
[2] Jour. Am. Orthop. Assn., February, 1918.
[3] Todd: Ann. Surg., December, 1921.
[4] Acta Chir. Scand., 1928, vol. 63.

one of the comparatively infrequent complications of disease at the knee-joint, for which the leg has been supported by the brace in an extended or overextended position, or in which the growth at the epiphyseal cartilage of the femur or tibia has been irregular. In rare instances it is the direct result of injury, as when the limb has been suddenly forced into an overextended position, and the posterior ligaments, and possibly the crucial ligaments, also, have been ruptured or weakened. It is most often, however, an accompaniment of paralysis of the posterior thigh muscles or of the gastrocnemius muscle, or both. A slight degree of overextension at the knees is not uncommon in children who have the so-called loose joints, and it is often observed in ataxic subjects.

In many cases genu recurvatum is combined with a varying degree of knock-knee, and there is often an abnormal mobility at the joint that permits a certain amount of posterior displacement of the tibia. In extreme cases of this class there may be well-marked subluxation.

Symptoms.—The symptoms, aside from the deformity, are weakness and insecurity caused by the hyperextension when weight is borne. If the deformity is extreme, the strain upon the weakened parts usually causes discomfort. Flexion is rendered difficult because of the abnormal relation of the joint surfaces and by the accommodative changes in the ligaments and muscles, so that in extreme cases the patient swings the leg along in the extended or overextended position.

Treatment.—If the recurvation is caused by deformity of the bones, the normal relations may be restored by osteotomy of the tibia or femur, as may be indicated. Deformity secondary to distortions elsewhere may be treated by remedying the primary cause.

Traumatic genu recurvatum may be treated by fixation in the flexed position until the repair is complete, afterward by massage and support if necessary. The ordinary form of overextended knee, combined with lateral mobility, must be supported by a brace which checks extension slightly within the normal limit. In selected cases shortening the posterior portion of the capsule and reinforcing it with strips of fascia or sections from the neighboring tendons attached to the bone may be of service.

CONGENITAL GENU RECURVATUM.

Synonym.—Anterior displacement of the tibia.

The most common of the congenital deformities at the knee is the so-called genu recurvatum, in which the knee is bent somewhat backward; or, in other words, the leg is hyperextended on the thigh. The condition is often spoken of as an anterior dislocation, but this term should be limited to the more extreme cases (Fig. 415). Ordinarily the range of extension is merely exaggerated, while flexion is limited. The extensors of the knee and the anterior part of the capsule are shortened, and the patella, if present, is usually displaced upward. In the more marked cases the hamstring tendons may be displaced for-

ward and the articulating surfaces of the bones may be changed in accommodation to the fixed attitude.[1]

The appearance in well-marked genu recurvatum is very peculiar; it is as if the patient's leg were reversed, for the popliteal depression has become a prominence and the range of overextension seems to represent normal flexion. In such cases the leg may be brought to the straight line, but greater flexion is resisted by the retracted tissues, and when the pressure of the hand is removed the leg is drawn back to the deformed position by the contraction of the quadriceps extensor muscle.

FIG. 415.—Congenital genu recurvatum.

Accompanying Deformities and Malformations.—Genu recurvatum is not infrequently accompanied by varus or valgus deformity at the knee, more often by the latter, and by laxity of the ligaments. In many instances the patella is absent or is rudimentary, and not infrequently the deformity is accompanied by malformations or defective development of other parts.

Rechman[2] has collected 188 cases. Of those analyzed, 19 were in males, 29 in females; 18 were unilateral, 35 bilateral.

Dislocation of the hip was present in 27, and abnormalities of the feet in 29 cases. In at least half the cases the patella is absent or rudimentary.

Etiology.—The deformity in cases of simple congenital recurvatum may be explained by an abnormal and fixed position *in utero*, and in certain cases seen soon after birth the mechanism is clearly shown by the habitual attitude. The thighs are sharply flexed on the body; the dorsal surfaces of the hyperextended knees are in relation to the abdomen, while the feet may be brought into contact with the face or trunk according to the degree of deformity. The retarded development of the quadriceps extensor muscle explains the rudimentary patella which is often an accompaniment of the deformity.

[1] Delanglade: Rev. d'Orthop., May, 1903.
[2] Arch. f. orthop. Mech. und unfall. Chir., 1914, Band **13**, Heft 3.

Treatment.—The treatment of the hyperextended knee is very simple. It consists in massage of the atrophied and contracted muscles, com-

FIG. 416.—Roentgen-ray picture of patient 415, showing the anterior displacement of the tibiæ on the femora.

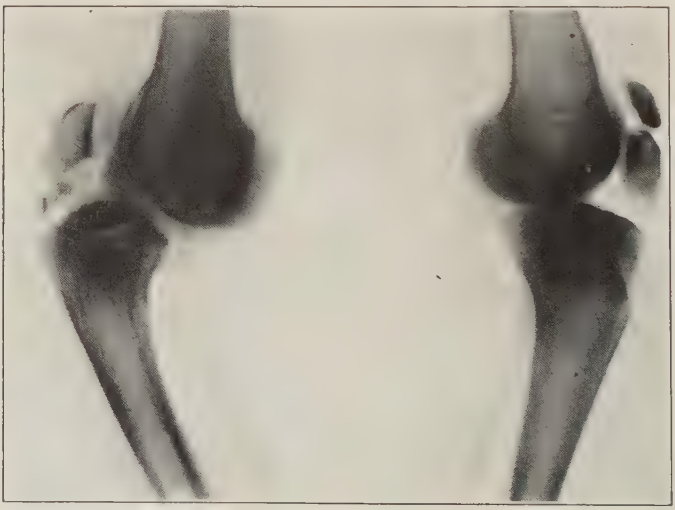

FIG. 417.—The mother of patient 416, who had the same congenital deformity. Displacement and laxity persist on the right side. The patellæ were probably injured during treatment, or the reduplication on the right side may be congenital, a so-called patella sesamoid or bipartem.

bined with more or less forcible manipulation in the direction of flexion. If, as is often the case, the leg seems to be drawn forward by spasmodic muscular action, the methodical massage should be combined with the use of a simple posterior splint.

If there is more resistance manual force may be applied under anesthesia, and the deformity may be overcome at one or several sittings, or the shortened tissues, particularly the tendon of the quadriceps or the ligamentum patellæ may be lengthened at open operation.[1] The limb is then fixed in a flexed position until the tendency to recurrence has been overcome. When the child begins to walk a light lateral brace may be necessary to ensure perfect functional use of the joint, as in many instances laxity of ligaments and muscular weakness may persist for a long time.

RUDIMENTARY OR ABSENT PATELLA.

As has been stated, a rudimentary patella is a frequent complication of genu recurvatum or of any congenital defect or deformity of the knee or limb that involves imperfect development of the quadriceps extensor muscle. In many cases of this type it is impossible to distinguish the patella during the early months of infancy, but later a minute patella appears that slowly increases to an approximately normal size.

Absence of patella under the same conditions is less frequent, although Potel collected 100 cases from literature.

Treatment.—The treatment of rudimentary patella is included in the massage and stimulation of the atrophied or rudimentary muscle with which it is usually associated, and the support that the weak or deformed knee may require.

PATELLA BIPARTA.

This is a congenital condition and is usually bilateral. There is a fairly normal patella with a small secondary patella, most often at its upper external angle (Fig. 417). The two adjoining bones have smooth surfaces and are joined by fibrous tissue. In a series of 63 cases of injury of the knee, 3 per cent. were instances of this anomaly which had been mistaken for fracture.[2]

CONGENITAL AND ACQUIRED DISPLACEMENT OF THE PATELLA.

The patella may be displaced upward as a result of extreme genu recurvatum, and in rare instances it may be displaced inward or downward, but far more often the displacement is outward. Fifty cases of this form are recorded, in most of which it was a complication of congenital genu valgum.

[1] Leo Mayer: Am. Jour. Orth. Surgery, August, 1918.
[2] Adams and Leonard: Surg., Gynec. and Obst., November, 1925.

Acquired persistent displacement in which the patella lies on the outer aspect of the external condyle is most often an accompaniment of extreme genu valgum. The first step in treatment must be the correction of the distortion of the limb, but if the deformity is of long duration the tissues on the anterior aspect will have become so shortened that flexion will be much limited when the normal relation is restored, so that elongation of the contracted tissues may be required, otherwise the operative treatment is the same as for slipping patella.

FIG. 418.—Slipping patella of the left side.

SLIPPING PATELLA.

This term is applied to an abnormal laxity of the supporting tissues that allows occasional displacement of the patella upon or to the outer side of the external condyle.

Etiology.—This disability is more common among females than males and is more often unilateral than bilateral. The abnormal mobility may be an inherited peculiarity; it may be due to weakness of the quadriceps extensor muscle, or to imperfect development of the patella or of the external condyle; or the original displacement may have been due to injury. In many instances, however, the predisposing cause is genu valgum, as a consequence of which the patella is carried toward the external condyle. Slight occasional displacement sufficient to cause discomfort is a not uncommon accompaniment of weak feet, an indication, as a rule, of muscular weakness or relaxation.

Weimuth[1] has collected 66 cases. Of these 32 were of congenital, 14 of traumatic (rupture of internal ligaments), and 20 of pathological origin (knock-knee).

[1] Deutsch. Ztschr. f. Chir., lxi; Bade: Ztschr. f. orthop. Chir., 1903, **11**, 451.

MEDICAL LIBRARY
BOSTON CITY HOSPITAL

Symptoms.—If the slipping of the patella is a frequent occurrence it causes comparatively little pain, but when the parts are less relaxed the displacement is likely to be followed by a certain amount of effusion into the joint and by the symptoms of a sprain. It is usually the result of a misstep or sudden movement when the thigh muscle is relaxed or of extreme flexion of the leg. As a rule there is a sense of insecurity and weakness at the knee in those who are subject to the accident.

Treatment.—The treatment varies according to the condition of the parts about the joint. If the displacement is the direct result of violence the limb should be fixed for a time in a plaster splint, which may be replaced by the adhesive-plaster strapping or a knee-cap. The improvement of the muscular tone by exercises is always an important part of treatment whether or not support is employed. In cases in which the slipping has become habitual and particularly when the ligaments of the joint are much relaxed, a light brace should be employed to prevent lateral motion and to limit the range of flexion at the joint, if this predisposes to the displacement.

Operative Treatment.—If the position of the patella that predisposes to the further displacement is a consequence of genu valgum the rectification of the deformity will, as a rule, remedy the secondary disability. If the displacement appears to be caused by laxity of the capsular ligament, as well as by the abnormal position of the patella, an operation for the purpose of limiting the mobility and restoring the proper relation of parts may be conducted in the following manner: A long, curved incision is made about the inner side of the knee, the lower extremity of which crosses the ligamentum patellæ. The skin-flap having been reflected, the contracted capsule may be divided on the outer side without disturbing the synovial membrane. The patella is then forced inward and the redundant tissue on the inner side is folded and sutured, or a section of the capsule may be removed, sufficient in size to hold the patella in its proper position. The ligamentum patellæ is then split into equal halves and the outer half passed under the inner and attached to the periosteum of the inner border of the tibia and to the attachment of the sartorious muscle (Goldthwait) or its bony insertion may be transplanted, as shown in Fig. 419. Both McAusland and Goldthwait have found this operation efficient without reefing the capsule. As an additional safeguard, a section of the semimembranosus tendon may be transplanted to the inner border of the ligamentum patellæ or the tendon of the gracilis may be used for the same purpose[1] (Whitlock). A more radical procedure is that of Krogius.

The contracted capsule is first thoroughly divided on the outer side as in the previous operation and the patella is forced over to its normal position. From the redundant capsule on the inner side a strip one inch or more in width from the tibia to and including the muscle

[1] Ztschr. f. Chir., 1904, No. 24.

is separated from the synovial sac and the musculo-aponeurotic section is carried over the patella to fill the opening in the outer part of the

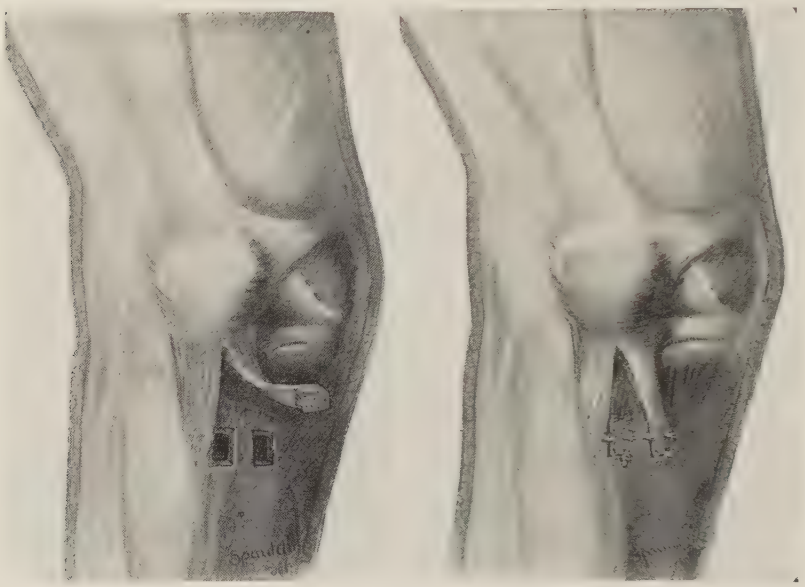

FIG. 419.—Showing methods of transplanting long insertion of patella tendon. (MacAusland and Sargent.)

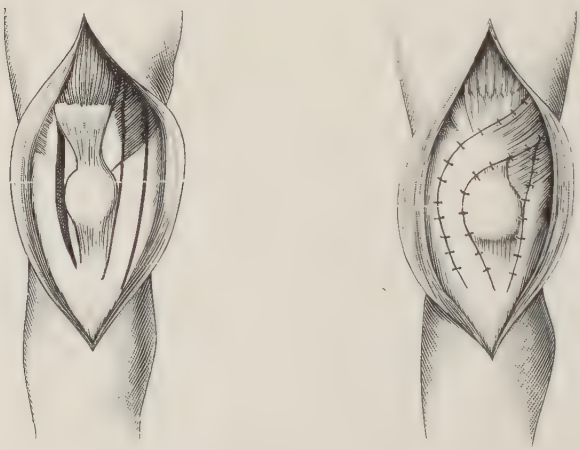

FIG. 420.—Krogius' operation for displaced patella.

capsule. The various incisions are then closed with sutures. After operation the limb should be held in the extended position for a time, and it should afterward be supported by a brace or knee-cap for

several months. Subsequently massage and exercise for restoring the tone of the weakened muscles should be employed.

Albee[1] would prevent displacement by elevating the external condyle. This is split on its outer aspect, pried upward with a chisel and the interval filled with a graft taken from the tibia. Gallie[2] attaches the patella to the internal condyle by fascia passed through holes bored in the bones (Fig. 421).

Fig. 421.—Diagram showing fixation of patella by fascial transplant. The strip of fascia is in the form of a closed loop passing through tunnels in the patella and internal condyle, with its ends overlapping widely at A. (Gallie.)

ELONGATION OF THE LIGAMENTUM PATELLÆ.

In certain cases the ligamentum patellæ may be abnormally long, so that the patella lies habitually above its proper position. This elongation may be one of the evidences of general relaxation of the ligaments of the knee, and thus a predisposing cause of the slipping patella or of the abnormal mobility at the knee-joint.

Etiology.—The elongation of the tendon may be a congenital peculiarity or it may be acquired. It is most often observed as an effect of hemiplegia or paraplegia.

[1] Med. Rec., August 4, 1915.
[2] Jour. Bone and Joint Surg., July, 1925.

Symptoms.—The symptoms of elongation of the ligamentum patellæ, as distinct from those of the general laxity of the ligaments that is often present, are weakness and disability, usually noticeable on walking up or down stairs, or after overexertion. Shaffer, who first called attention to the disability from this cause, thinks that it may be a predisposing cause of displacement of the semilunar cartilages.[1]

Treatment.—In this, as in other forms of insecurity or of abnormal mobility at the knee, a brace that permits only anterior-posterior motion will, as a rule, relieve the symptoms. If the ligament is of such a length as to require it, it may be shortened, or the tubercle of the tibia may be removed and implanted at a lower point, as suggested by Walsham.[2]

OTHER CONGENITAL DEFORMITIES AT THE KNEE.

Congenital displacements are uncommon. As a rule they are incomplete and are caused by laxity of the ligaments and by defective formation of the bones or other parts.[3]

Snapping Knee.—A very slight form of partial recurrent displacement is the snapping or clicking knee not uncommon in early infancy, in which the tibia on sudden extension of the limb springs forward or rotates outward on the femur with an audible snapping sound. This movement appears to be the result of voluntary muscular contraction combined with laxity of ligaments and very possibly with irregular movements of one or other of the semilunar cartilages. In some instances the subluxation appears to cause pain or discomfort. The ability to displace the tibia on the femur by muscular action is sometimes noted in older subjects. In such cases it may be the result of injury such as rupture of ligaments or irregularity within the joint. Occasionally the snapping may be caused by slipping of the biceps tendon or by displacement of the external semilunar cartilage.

Treatment.—The treatment of congenital dislocation or subluxations of the knee consists in reposition, support, and massage of the weak part. The snapping knee of infancy may be supported by a flannel bandage, or, in the more marked type of laxity of ligaments, it may be fixed for a time in a brace. Complete recovery is the rule.

Congenital Contraction.—Slight limitation of the range of extension of one or both knees is not infrequent. As a rule it is easily overcome by massage and manipulation. In the more extreme cases there may be an accommodative forward bending of the lower extremity of the femur.

General Contractions.—Congenital contraction at the knees of a more marked and resistant form may be combined with flexion contraction at the hips, or it may be one of a series of contractions at other joints. In the latter instance other congenital deformities, such as

[1] Tr. Am. Orthop. Assn., xi.

[2] Med. Weekly, February 17, 1893.

[3] Drehmann: Die Cong. Lux. des Kniegelenks, Ztschr. f. orthop. Chir., 1900, Band **7**, Heft 4.

club-hand or foot, or evidences of defective development are usually present. For example, certain joints may be fixed in flexion or fixed in extension. In some instances the contraction or the partial anchylosis appears to be due simply to long-continued fixation *in utero*, and to consequent non-development of the muscles. In others it is caused by disease, as chondrodystrophia.

Prognosis.—The prognosis depends upon the cause of the contraction or fixation. In most instances, under careful and continued treatment, the range of motion may be in great degree restored.

Treatment.—The treatment consists in regular massage and manipulation, with the aim of increasing the range of motion. Deformity, if present, may be rectified in the usual manner.

CHAPTER XI.

DISEASES AND INJURIES OF THE ANKLE- AND TARSAL-JOINTS.

TUBERCULOUS DISEASE OF THE ANKLE-JOINT.

Disease of the ankle-joint is the third in the order of importance, although it is far less common than is disease at the knee.

In five consecutive years 1788 cases of tuberculous disease of the joints of the lower extremity were treated at the out-patient department of the Hospital for Ruptured and Crippled. In 54.1 per cent. of these the hip-joint was affected; in 36.2 per cent. the knee-joint, and in but 9.7 per cent. the ankle-joint.

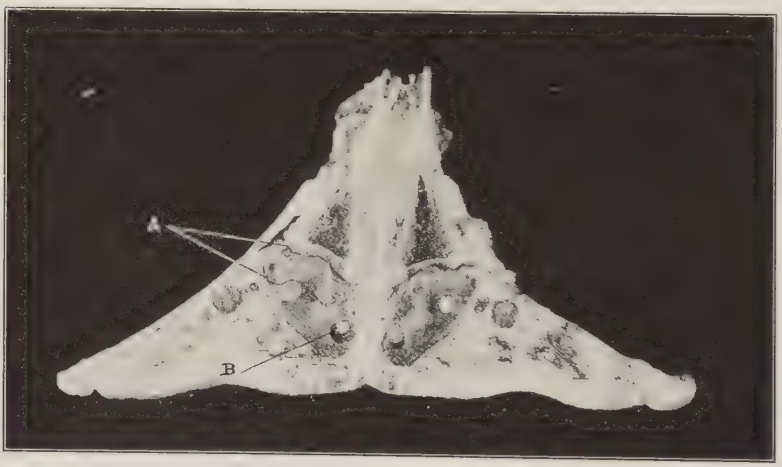

Fig. 422.—Tuberculous disease of the ankle and tarsus. *A*, disease of the ankle and subastragaloid joints. *B*, cavity in the os calcis containing sequestrum.

Pathology.—The pathology of tuberculous disease at the ankle differs in no essential particular from that of disease of the hip and knee. It does not, therefore, call for special consideration. It is of interest to note, however, that abscess is a more common complication at this than at the other joints.

In 30 final results of disease at the ankle reported by Gibney,[1] abscess was present in 25 (83 per cent.). In 78 final results reported

[1] Am. Jour. Obst., April, 1880.

by Prendlsburger[1] abscess was present in 68 (87 per cent.), as contrasted with a percentage of 69 and 51 at the knee and hip, respectively. This greater liability to abscess is probably apparent rather than actual, since the ankle-joint is so superficial that fluctuation may be detected here that would be overlooked at the hip, and because an opening usually forms before sufficient time has elapsed to permit of absorption.

Situation of the Disease.—Otto Hahn[2] investigated the cases of tuberculous disease of the ankle and foot treated at Tübingen during a period of fifteen years. These cases were 704 in number in 685 patients, in 19 both feet having been involved.

In 309 of the cases the disease was of the ankle-joint. Of these 51 per cent. were osteal in origin. The primary focus was in the internal malleolus in 11, the external in 7, in both in 5. It was in the astragalus in 116 cases.

In 16 instances the disease of the ankle was secondary to primary infection of the os calcis, and in 5 cases both the astragalus and the os calcis were diseased.

Of 88 cases investigated by Stich[3] the ankle-joint was involved in 88 per cent., in 45 per cent. the disease being limited to this joint. The astragalar-navicular joint was involved in 29 per cent., and the astragalar-calcaneoid joint in 36 per cent.

Sever[4] has tabulated 252 cases with references to location.

Location of Disease (by Operation or Roentgen-rays).

Astragalus	74
Os calcis	45
Scaphoid	14
Cuboid	14
Tibia (lower end)	42
Fibula (lower end)	19
Internal cuneiform	6
Middle cuneiform	6
External cuneiform	5
First metatarsal	12
Second metatarsal	5
Third metatarsal	4
Fourth metatarsal	2
Fifth metatarsal	4
	252
Occurring in more than 1 bone	40

Etiology.—The etiology of tuberculous joint disease does not require further comment. It may be noted, however, that tuberculous disease at the ankle is relatively more common in later childhood and adult life than is the same affection at the knee and hip.

Of 1000 cases of disease of the hip-joint, 12 per cent. were in patients more than ten years of age.

[1] Loc. cit.
[2] Beitr. z. klin. Chir., 1900, Band **26**, Heft 2.
[3] Beitr. z. klin. Chir., vol. **45**, 587.
[4] Jour. Am. Med. Assn., December 17, 1910.

Of 1000 cases of disease of the knee-joint, 25 per cent. were in patients more than ten years of age.

Of 339 cases of disease of the ankle-joint, 30 per cent. were in patients more than ten years of age.[1]

Of the 339 patients 177 were males (52.2 per cent.); 162 were females (47.8 per cent.). The disease was of the right ankle in 173 cases; of the left in 166.

AGE AT INCIPIENCY OF ANKLE-JOINT DISEASE IN 339 CONSECUTIVE CASES TREATED AT THE HOSPITAL FOR RUPTURED AND CRIPPLED.

1 year or less	5	24 years old	2
2 years old	42	25 "	3
3 "	43	26 "	3
4 "	44	27 "	4
5 "	34	28 "	4
6 "	24	29 "	2
7 "	19	30 "	2
8 "	8	31 "	0
9 "	9	32 "	1
10 "	9	33 "	2
11 "	11	34 "	1
12 "	8	35 "	0
13 "	4	36 "	2
14 "	4	37 "	2
15 "	4	40 "	4
16 "	6	43 "	1
17 "	2	44 "	1
18 "	4	45 "	4
19 "	3	46 "	2
20 "	3	48 "	1
21 "	4	50 "	1
22 "	5		
23 "	2		339

AGE OF THE PATIENTS TREATED FOR ANKLE-JOINT AND TARSAL DISEASE AT TÜBINGEN. (HAHN.)

	Males.	Females.	Total.
1 to 10 years	45	28	73
11 to 20 years	149	91	240
21 to 30 years	89	34	123
31 to 40 years	32	28	60
41 to 50 years	37	27	64
51 to 60 years	35	26	61
61 to 70 years	18	11	29
71 to 80 years	6	1	7
81 years	1	0	1
	412	246	658

Four hundred and twelve of the 658 patients were males (62 per cent.); 246 were females (38 per cent.). In 27 the sex was not stated.

Symptoms.—The symptoms are usually subacute in character, and are often mistaken for sprain or rheumatism. In some instances they appear to follow an injury, but in the majority of cases in childhood no cause can be assigned. The ankle becomes sensitive to sudden movements; the patient limps, and there is complaint of discomfort after overuse and of pain at night. The limp differs in character from

[1] Statistics from Hospital for Ruptured and Crippled.

MEDICAL LIBRARY
OF THE
BOSTON CITY HOSPITAL

that caused by hip or knee disease. The patient walks with the limb rotated outward, bearing the weight upon the heel and upon the inner border of the foot, active leverage "spring" being avoided.

Primarily the symptoms are those of a persistent, somewhat painful disability at the ankle, causing *stiffness* and *limp;* later *deformity* appears.

Deformity.—The primary deformity of ankle-joint disease in the subacute cases is valgus, induced by a persistence of the passive attitude. In more advanced cases it becomes equinovalgus, and when the limb is no longer capable of supporting weight, but is held pendent, the equinus predominates.

FIG. 423.—Tuberculous disease of the left ankle.

The joint is usually somewhat enlarged. In some instances the swelling is uniform; in others it is localized in front or behind one of the malleoli. This swelling is not, as a rule, like that of simple effusion into the joint, but the tissues have the peculiar elasticity characteristic of thickening and infiltration. There is usually a perceptible increase in the local temperature, and pressure directly upon the malleoli causes discomfort. The voluntary movements of the joint are restricted, and passive movements show the characteristic reflex muscular spasm, limiting both dorsal and plantar flexion.

Subastragaloid Disease.—If the astragalus is primarily diseased, the symptoms are usually first apparent in the ankle-joint, but in certain cases the joint between the astragalus and the os calcis is first involved. Disease at the subastragaloid joint is usually classed as ankle-joint

disease, although the swelling is most marked at a point somewhat below the malleoli (Fig. 424).

In this form forced lateral motion of the os calcis causes discomfort and the range of adduction and abduction of the foot is restricted, while dorsal and plantar flexion may be unrestricted.

Astragalo-navicular Diseases.—If the disease is limited to this joint the foot is usually fixed in an attitude of persistent abduction, and as the process is usually of the subacute type it may be mistaken for rigid weak foot.

Diagnosis.—The principles of differential diagnosis of tuberculous disease from other affections have been considered in detail in the description of disease of the larger joints.

FIG. 424.—Tuberculous disease of the subastragaloid joint.

In childhood a chronic, painful disease confined to a single joint in which motion is limited by muscular spasm, and in which there is a tendency to deformity, is almost certainly tuberculous in character.

In adult life also the same statement applies, and distinguishes tuberculous disease from "*rheumatism*," *arthritis deformans*, or other multiple joint diseases. Forms of *infectious arthritis* may be differentiated by the history. *Sprains* or other injury may be distinguished by the history of the onset and by the absence of local signs of serious disease. In weak or painful *flat-foot* the symptoms are localized at the medio-tarsal joint. It should be borne in mind, also, that the pain from a weak or injured foot is felt, as a rule, only when it is in use;

whereas in tuberculous disease of the bone, pain is common when the part is not in use, particularly at night.

Treatment.—In disease of this, as of other joints, functional rest is indicated. This necessitates fixation of the joints and stilting of the limb, if weight-bearing causes discomfort. A light plaster splint should be applied, extending from the extremities of the toes to the upper third of the leg, supporting the foot at a right angle with the leg and in an attitude of slight inversion, in order to guard against the tendency toward valgus. This deformity is very common after the cure of the disease, and it often subjects the patient to the additional discomfort of the weak foot.

Reduction of Deformity.—If the foot has become distorted before the patient is brought for treatment, a plaster bandage may be applied in the attitude of deformity, and at the subsequent applications of the dressing, when the muscular spasm is lessened, the malposition may be reduced by gentle manipulation. In resistant cases immediate reduction of the deformity under anesthesia may be advisable. Throughout the entire course of treatment the greatest attention must be paid to the attitude. Deformity is easily prevented, but is often very difficult to correct, especially during the later stages of the disease, when the tissues are infiltrated and sensitive, and especially if discharging sinuses are present.

Other retentive appliances may be employed, but they are inferior to a properly applied plaster support, which holds its place by accuracy of adjustment, which most effectively prevents motion, and which exercises a certain degree of compression upon and general support of the swollen joint. The bandage is usually renewed at intervals of a month, but it may be retained indefinitely if it is properly protected by a light shoe or slipper. When the disease is no longer active a light brace of the type illustrated in the chapter on Talipes, to be worn inside the shoe, may be substituted for the plaster support. The Bier method of passive congestion may be applied by means of a bandage above the knee. The adhesive-plaster strapping may be used beneath the plaster bandage if local compression and more comprehensive support is desired.

The most satisfactory brace to serve as a stilt in connection with the local support is the Thomas brace, which has been described in the section on Disease of the Knee-joint.

If patients are treated efficiently, the discomfort or inconvenience attending the disease is slight. As a rule the swelling of the joint becomes more localized and finally an abscess appears beneath the skin. It is then advisable to remove the fluid and other contents by means of a simple incision. In most instances a sinus persists for a time. If the discharge is slight, the part may be dressed with ichthyol, balsam of Peru or other application, and the whole enclosed again in the plaster bandage; or, if it be more profuse, an opening may be made and the dressing applied outside the plaster bandage. When the stage of recovery is reached, stilting apparatus may be discarded,

the patient being allowed to bear the weight on the foot, protected by the plaster bandage or other support.

Operative Treatment.—Early operation, especially of a gouging character, involving the articulations should be avoided. An effective operation of this class often involves the sacrifice of bone that would be spared in the natural cure, and it entails an irregularity in the growth and causes deformity in after-life that may be irremediable (Fig. 425).

Similar operations in the treatment of fistulæ, or abscess, while the tissues are thickened and edematous and while the disease within the joint is active, should be postponed until the process of repair is more advanced. During the stage of convalescence, however, cure may be hastened by the removal of persistent foci of disease, or sequestra in the bone, or tuberculous tracts in the overlying soft parts.

In the adult or adolescent, and in exceptional cases in childhood, operative treatment may be indicated when, for example a roentgen-ray picture shows a focus in a single bone of the tarsus. If the disease is confined to the ankle-joint, astragalectomy may assure the removal of the disease and the retention of motion.

The operation is performed under the Esmarch bandage; a curved lateral incision is made passing beneath the external malleolus from the neighborhood of the tendo Achillis to the anterior aspect of the joint. The lateral and capsular ligaments are divided, after which the foot may be displaced inward. The astragalus is exposed and it may be removed easily by dividing the ligaments about its head and its attachments to the os calcis. (See Astragalectomy.) All the diseased tissue in the soft parts and in the bone must be removed thoroughly. If the disease has not extended to the tarsus, and if it seems to have been completely removed, the wound may be closed, but in most cases it should be packed for a time with gauze. In all cases the foot should be displaced backward so that the malleoli may rest upon the anterior extremity of the os calcis, otherwise calcaneus deformity may result as in cases reported from Garrè's clinic.[1] The after-treatment is conducted as if the operation had not been performed, support and fixation being continued until it is evident that the disease is cured.

Removal of the astragalus does not interfere to a marked extent with the function of the foot, nor does it cause noticeable deformity. As a primary operation, permitting inspection and the opportunity for thorough removal of all disease in the neighboring parts, it should always be performed in preference to extensive gouging, which is, as a rule, of little avail. As at other tuberculous joints, operative fixation of the ankle-joint, if the disease is localized it may be considered. The operation is of the so-called extra-articular type, by turning up sections from the os calcis and sliding down fragments from the tibia or by inserting bone grafts.

Prognosis.—Disease at the ankle is not only less common, but it is less dangerous than that of the larger joints, because it is remote from

[1] Syring: Beitr. z. klin. Chir., Band **87**, Heft 1.

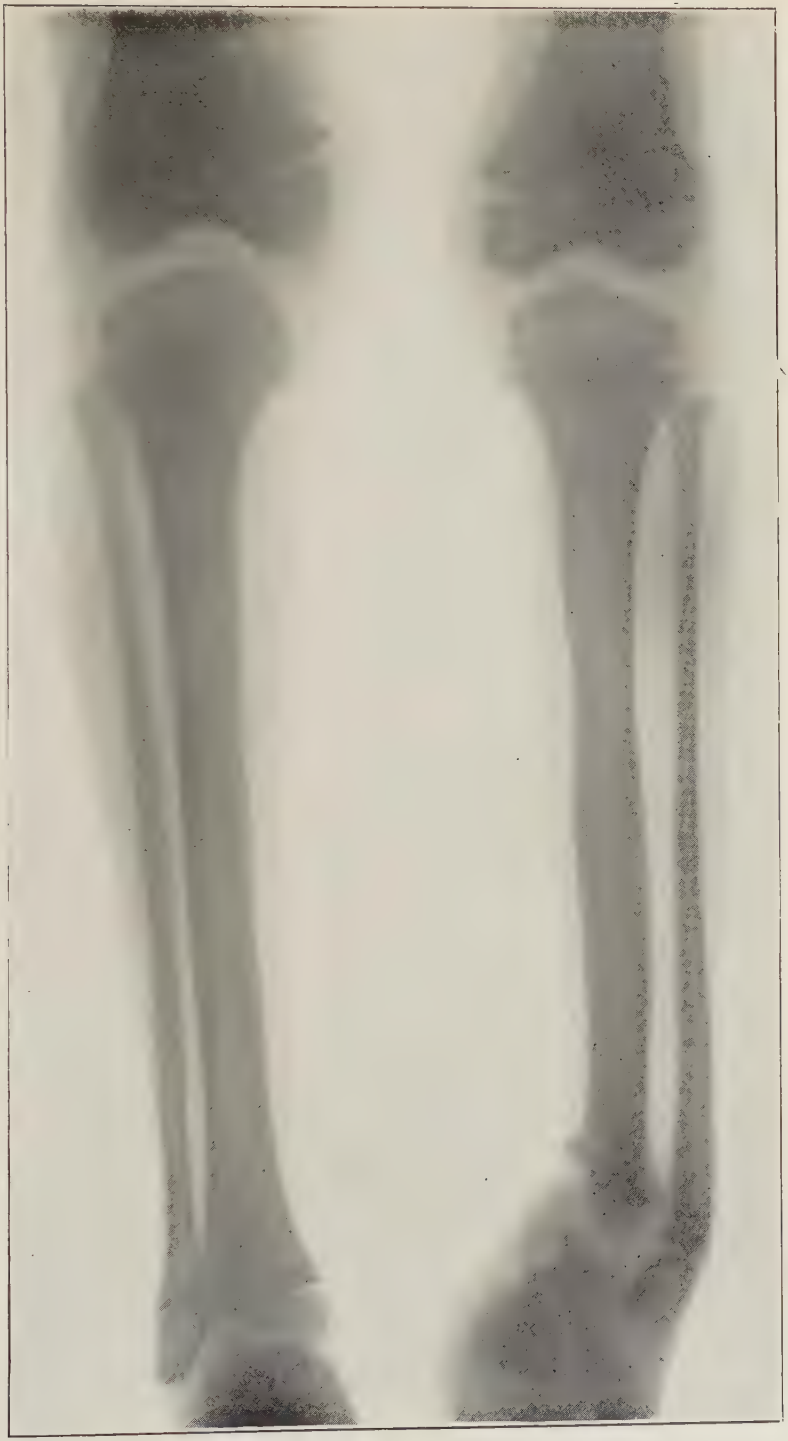

Fig. 425.—The epiphyses of the lower extremities at the age of six years, showing the effect of operative removal of bone at the ankle-joint for tuberculous disease at the age of three years, in causing subsequent deformity of the foot and shortening of the limb. Ossification is present at birth in the lower epiphysis of the tibia.

important structures, and because there is less opportunity for the burrowing of infected abscesses. The duration of the disease here is, as a rule, shorter than at the knee or hip, and the final results in childhood are almost always excellent. Often free motion is retained at the ankle, and even if the astragalus is fixed by disease the mobility in the other joints of the foot is sufficient to compensate very effectively for the anchylosis. Shortening of the limb is of comparatively little consequence. It is not often more than an inch, and it may be absent. The growth of the foot is often considerably retarded, partly from disuse and partly because of the destructive effect of the disease upon the tarsal bones.

Of 29 apparently final results reported from the New York Orthopaedic Hospital[1] there were 15 with free motion without deformity. Limited motion without deformity, 6; limited motion with deformity, 2. There were 6 deaths in a total of 50 cases, 21 of which could not be traced. The average duration of treatment was four and one-sixth years.

In the 30 cases reported by Gibney, treated expectantly, in which the mechanical treatment was far from effective, 6 patients recovered with normal motion; 11 with practically normal function. In 7 there was good motion. In 6 there was anchylosis, and in 3 persistent valgus. In all the limb was efficient. In 20 instances there was no limp, and in but 1 case was it marked. In no instance was a crutch, cane, or other support used. The average duration of the disease was three years and three months, a minimum of one year, a maximum of six years. There were 2 deaths, of which but 1 was dependent upon the disease, septicemia being the cause assigned, though it is stated that practically all the bones of the tarsus were involved. In this case amputation was evidently indicated.

The prognosis and the treatment of tuberculous disease of this region is quite different in cases in adult life. Rogers[2] traced 17 of 27 cases treated at the Massachusetts General Hospital. In but 4 of which was the result of conservative treatment satisfactory. Early resection or amputation is, therefore often indicated.[3]

TUBERCULOUS DISEASE OF THE TARSUS.

Tuberculous disease of the joints of the foot, not involving the ankle, is not uncommon.

In 386 of the 704 cases reported by Hahn, the disease was limited to the foot. In 141 cases the mediotarsal joint was involved; in 51 of these the disease was confined to this joint; in 46 the ankle was involved; in 29 the disease extended forward to the tarso-metatarsal articulation, and in 16 the three joints were diseased. In 78 cases the tarso-metatarsal joint was involved, in 33 of which the disease did not extend beyond this articulation.

[1] Humphries and Durham: Jour. Am. Med. Assn., January 27, 1917.
[2] Boston Med. and Surg. Jour., vol. **164**, p. 811.
[3] Gaenslen and Schneider: Jour. Am. Med. Assn., October 8, 1921.

Distribution among Individual Bones.—In these cases the distribution was as follows:

The astragalus	170;	disease confined to the single bone in 8
The calcaneum	200;	disease confined to the single bone in 87
The cuboid	116;	disease confined to the single bone in 18
The scaphoid	82;	disease confined to the single bone in 2
The cuneiform bones	86;	disease confined to the single bone in 8
Metatarsal bones	45;	in one-half of these the disease was of the first metatarsal, either alone or in connection with the adjoining cuneiform bone or phalanx.

In a total of 1483 cases, including these and others reported by Audry,[1] König,[2] Mondan,[3] Munch,[4] Spengler,[5] Vallas,[6] Czerny,[7] Dumont,[8] Sever,[9] the relative frequency of the disease in the bones of the foot and ankle appeared to be as follows:

Leg bones	147, 9.9 per cent.	Scaphoid	124, 8.4 per cent.
Astragalus	365, 24.6 "	Cuneiform bones	126, 8.7 "
Os calcis	384, 26.3 "	Metatarsus	137, 9.2 "
Cuboid	168, 11.4 "	Phalanges	22, 1.4 "

In disease limited to the astragalo-navicular joint the swelling and sensitiveness are localized in front of the ankle on the inner side of the foot. Adducton is restricted, and the foot is often fixed in an attitude of persistent abduction. Disease of other bones or joints of the tarsus is indicated by the local swelling and sensitiveness.

Treatment.—Disease of the tarsus shows a marked tendency to extend from one bone to another until the entire foot is involved. Consequently if an early diagnosis is made of a distinctly localized process prompt removal of the affected bone is indicated; but in most instances the disease is too extensive to permit of its radical removal. In such cases operative intervention is contraindicated, and the treatment by protection similar to that employed in disease of the ankle is indicated. In childhood the prognosis is very good even when the disease is extensive, but in adult life amputation of the foot may be advisable because of the time required to assure a natural cure and because an artificial leg provides a better support than a stiff and sensitive extremity. Amputation is almost always indicated, if there is coexistent disease of the lungs.

KÖHLER'S DISEASE.

Köhler's disease is an affection of the navicular first described by him in 1908.[10]

There is usually slight sensitiveness to pressure on the bone, and occasionally the overlying tissues appear somewhat thickened. At

[1] Rev. de Chir., 1891.
[2] Schmidt's Jahrb., 1884, vol. **204**.
[3] Deutsch. Chir., vol. **1**, 66.
[4] Deutsch. Ztschr. f. Chir., 1879, vol. **11**.
[5] Deutsch. Chir., 1897, vol. **44**.
[6] Ibid., vol. **1**, 66.
[7] Volk: S. klin., vol. **5**, No. 76.
[8] Deutsch. Ztschr. f. Chir., 1882, vol. **17**.
[9] Jour. Am. Med. Assn., December 17, 1910.
[10] München. med. Wchnschr., vol. **44**, No. 254.

times the patient complains of discomfort and limps, but, as a rule, there is but little disability. In the roentgen-ray picture the bone or its ossified center appears to be abnormally dense, shortened anterior-posteriorly and correspondingly broader. The affection is apparently limited to the developmental period, and is of a similar type to coxa



Fig. 426.—Köhler's disease.

plana. In specimens examined there seemed to be an inflammatory necrotic zone in the bone, the marrow being replaced by fibrous tissue[1] (localized osteitis fibrosa). In some instances injury appears to be an exciting cause. The symptoms are transitory and a return to a practically normal condition under the protection assured by a flat-foot support is the rule in a year or more. If the symptoms are more marked the temporary support of a plaster bandage holding the foot in slight inversion may be indicated.

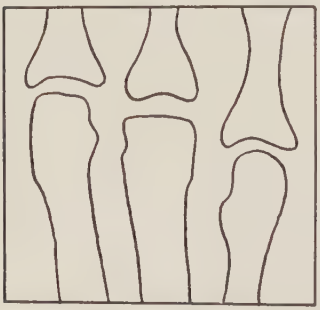

Fig. 427.—Köhler's disease, showing flattening of the metatarsal head and thickening of the shaft.

Köhler's Disease of the Head of a Metatarsal Bone.—A similar disease is sometimes found in the head of a metatarsal bone, usually the second, sometimes of the third or fourth. It is a disease of the growing period. There is some discomfort on pressure and movement at the affected joint and the epiphysis of the metatarsal head appears flattened in the roentgen-ray picture. It is more common in females than males and for this reason the influence of ill-shaped shoes and high heels has been suggested as a predisposing cause. A specimen from a girl, aged fifteen years, showed as in the navicular disease, the spongy bone changed to connective tissue, together with inflammatory changes in the periosteum resembling arthritis deformans. The treat-

[1] Lécine and Mouchet: Rev. d'Orthop., March, 1924.

MEDICAL LIBRARY
BOSTON CITY HOSPITAL

ment should be protection by a foot plate during the painful period, or resection of the affected part if the disability is prolonged.[1]

INJURIES OF THE ANKLE-JOINT.

Sprain.—The ankle is, from its position, especially liable to injury; in fact, the term "sprain" is popularly associated with this joint.

Etiology.—A sprain is most often caused by an unguarded movement, by which the foot is turned suddenly inward or outward, with sufficient force to injure the synovial membrane, to rupture some of the fibers of the muscles, to strain tendons and tendon sheaths, and even to rupture ligaments. If the foot is twisted inward the injury is most marked on the outer side of the joint; if outward, on the inner side of the ankle. In the slighter degrees of sprain the injury may be confined to the tissues about the joint, but in most instances there is effusion within the capsule, even hemorrhage when injury has been severe.

FIG. 428.—A method of applying adhesive-plaster strapping for sprain of the ankle.

Symptoms.—The immediate symptoms of sprain are pain, often intense, of a throbbing character, swelling, heat, and in many instances discoloration of the surrounding parts, even extending over the leg and foot.

Treatment.—If an opportunity for immediate treatment is offered, the swelling and the effusion of blood may be restrained by wrapping the limb from the toes to the knee with a thick layer of absorbent cotton and bandaging it firmly. As much compression being exercised as the comfort of the patient will allow; the thick covering restrains motion and the elastic pressure prevents swelling. The stockinette bandage (Fig. 429) may be used for the same purpose. If the injury has been severe and if the part is very sensitive to motion or jar

[1] Bragard: Ztschr. f. Orth. Chir., 1924, **46**, 1. Von Dittrich: Archiv. f. orth. u. unfall Chir., 1927, Bd. 24.

the joint may be fixed in a light plaster bandage. This may be cut down the front to permit massage of the foot, ankle, and leg, which is of great service in hastening the absorption of the effusion. Aspiration of the joint is indicated if the synovial effuson causes tension.

The use of hot air, hot and cold water, and static electricity and the like are of service also in relieving the discomfort and more especially in stimulating the circulation, upon which repair depends.

By far the most effective treatment during the stage of recovery and as an immediate application for sprains of slighter degree is the adhesive-plaster strapping which has been popularized by Gibney. His method is as follows: Strips of adhesive plaster about three-quarters of an inch in width and from nine to eighteen inches in length are prepared. A long strip is placed with its center beneath the heel, and the two ends are carried upward over the malleoli, to a point at the junction of the middle and lower thirds of the leg. A second strip

FIG. 429.—The stockinette bandage. An effective means of reducing swelling and protecting the sensitive joint to be used in combination with massage.

is placed at the posterior extremity of the heel, and the two ends are carried forward somewhat beyond the tarso-metatarsal junction on either side. Another strip is then placed by the side of the first, and the fourth by the side of the second, until the entire ankle is smoothly covered, except for a space about two inches in width directly on the front of the ankle. One takes particular care to make the plaster fit well about the malleoli and reinforces it at the points of greatest sensitiveness. A light bandage is then applied and the patient is encouraged to use the foot in walking. The plaster may be applied in a variety of ways; a satisfactory method is as follows, after the preliminary massage for the purpose of reducing the swelling: One end of a strip of adhesive plaster about three feet long and three inches wide is applied to the lateral aspect of the leg just below the knee-joint; it is carried down the side of the leg over the malleolus, beneath the heel and arch, and up the other side to a point opposite the beginning where it is fixed by a circular band about the calf. If the sprain

is of the outer side of the ankle, sufficient tension is made upon the outer half of the plaster to hold the foot slightly abducted. If, as is more common, the sprain is of the inner side, the inner half is drawn firmly beneath the arch, carrying the foot toward inversion so that all strain may be removed from the sensitive part. This band of plaster is reinforced by one or more laps so that the lateral aspect of the ankle is completely covered. And in addition the entire ankle is then enclosed with narrow, overlapping strips which cover all the tissues well beyond the sensitive area. The foot and leg are then bandaged to assure the adhesion of the plaster. When the joint is firmly held by the supporting plaster the patient can, as a rule, walk with comfort; and he is encouraged to do so, for functional use, provided it does not cause additional injury, is the most effective stimulant of the circulation; thus the patient applying, as it were, an automatic massage, cures himself.

As the swelling subsides the plaster strapping wrinkles, and it must be renewed, about three applications being required, as a rule, the last of which is allowed to remain until all of the symptoms have disappeared. Vigorous massage before applying the new dressing is of service in hastening the cure. It is perhaps needless to state that preliminary shaving of the part will add to the comfort of the patient.[1]

Chronic Sprain.—A chronic sprain may be the result of an inefficiently treated acute injury, in which an improper attitude originally assumed to spare the sensitive part finally becomes habitual. In other instances persistent disability may be the result of fixation of the joint for too long a time in splints. Such disuse causes atrophy of the muscles and of the bones as well, while the effused material within and without the joint remains because of the imperfect circulation. The same disability may follow simple disuse of the injured part. It is more often observed in nervous individuals who exaggerate the importance of the injury and the discomfort that it causes. In such cases the limb may be discolored by venous congestion, the foot may be edematous and the movements may be limited by adhesions or by muscular adaptation to the habitual attitude.

In other instances the original injury may have caused a slight subluxation of the astragalus, sufficient to throw the foot into an attitude of abduction, in which it has become fixed by the secondary changes in the muscles and ligaments. In some cases of this class the original sprain was at the medio-tarsal or at the subastragaloid joint, and its effect has been traumatic weak foot. It may be stated, also, that many of the so-called sprains of the ankle are simply injuries of a weak foot, a disability to which the treatment should be directed. (See Weak Foot.)

Treatment.—Treatment must be conducted with the aim of restoring the normal range of motion and so supporting the part that nor-

[1] According to Beardsley, adhesive plaster may be easily removed by applying oil of wintergreen to its surface. This permeates its substance and dissolves the adhesive substance.

mal functional use may be permitted. If adhesions have formed and if the foot is persistently held in an abnormal attitude, forcible manipulation under anesthesia may be required as a preliminary treatment, followed by fixation for a time in a plaster support, in the attitude directly opposed to that which has been habitual. In this class of cases the habitual attitude is usually one of equinovalgus; the foot should be fixed for a time, therefore, in a plaster support in a position of extreme varus, at a right angle with the leg, and upon it the patient is encouraged to bear his weight both in standing and walking. When all discomfort has disappeared, a support, usually a light leg brace to prevent lateral motion, and if the arch is depressed a foot plate also, should be worn for a time. The most effective curative agent is functional use, but massage, hot air, passive manipulation, and exercises are valuable accessories.

Injuries of this class are very amenable to treatment, conducted with the aim of restoring normal function, if proper support is provided during the period of pain and weakness.

Fracture of the Tarsal Bones.—If the injury has been severe, especially a fall from a height, fracture of the tarsal bones should be considered as a possible complication of the sprain. One should compare the relative height of the malleoli above the heel on the two sides, since a lessened distance is proof of fracture of the astragalus or os calcis or both. Thickening at this point and slight lateral displacement of the foot are confirmatory signs.

In fractures of this class the upper articulating surface of the astragalus often retains its normal contour. So that dorsal and plantar flexion may be but slightly restricted while adduction and abduction movements proper to the subastragaloid joints are lost.

Treatment.—In all suspicious cases roentgen-ray pictures should be taken and if fracture and displacement are present, one should under anesthesia attempt to mould the foot to an approximately normal contour, especially at the arch. This is important if the os calcis is fractured, as one of the fragments is often forced downward into the tissues of the sole. A plaster splint is then applied. After consolidation of the fracture passive movements should be persistently employed particularly in adduction. As a rule an arched foot plate should be worn during the period of recovery. In certain instances operative treatment is indicated to remove projecting fragments of bone. If discomfort on lateral movement persists a subastragaloid arthrodesis is indicated or the entire astragalus may be removed if movement in the ankle-joint is restrained by deformity of the articulating surfaces.

Fracture of the other bones of the tarsus is less common and of comparatively slight importance.

TENOSYNOVITIS.

The sheaths of the tendons about the ankle-joint, if involved in a sprain of the ankle, may cause persistent interference with function;

or strain of a tendon and of its sheath may induce disability if the joint is uninjured. The symptoms of acute tenosynovitis are discom-

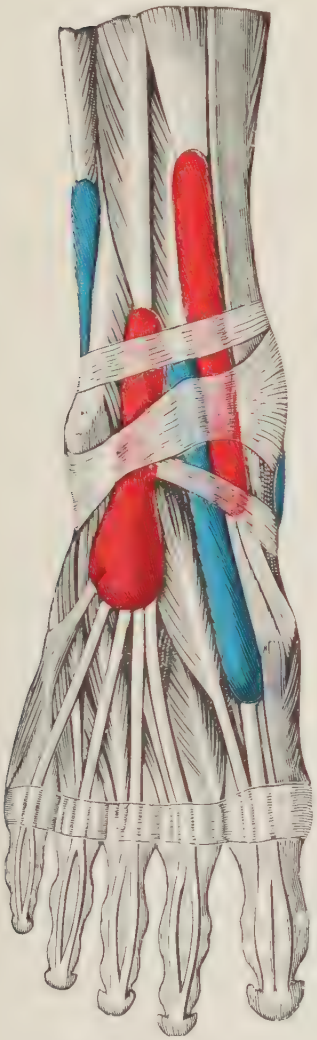

FIG. 430.—The anterior annular ligament of the ankle and the synovial membranes of the tendons beneath it artificially distended. (Gerrish's Anatomy.)

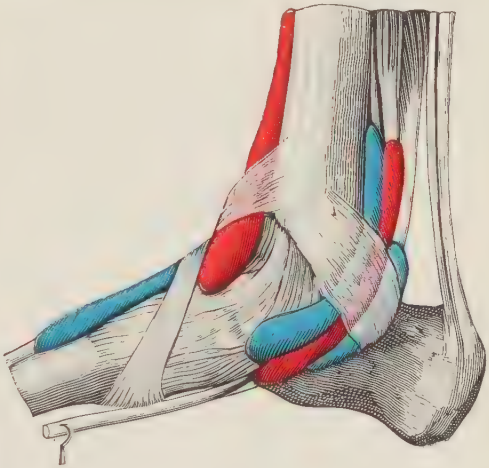

FIG. 431.—The internal annular ligament of the ankle and the artificially distended synovial membrane of the tendons which it confines. (Gerrish's Anatomy.)

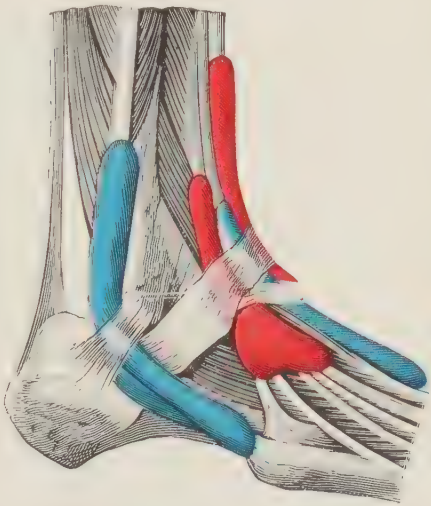

FIG. 432.—The external annular ligament of the ankle and the artificially distended synovial membranes of the tendons which it confines. (Gerrish's Anatomy.)

fort on motion of the affected tendon, and this motion may be accompanied by a peculiar creaking which is apparent on palpation and usually there is slight local swelling and sensitiveness to pressure about the affected part.

At the ankle-joint all the tendons are provided with sheaths; on the front of the foot are three—the sheath of the tibialis anticus, which extends from a point about two inches above the extremity of the malleolus to the navicular bone (Fig. 430); that of the extensor longus hallucis, from the annular ligament to the head of the first metatarsal, and the common sheath for the extensor communis digitorum, extending from a point about half an inch above the malleoli to about one inch below the annular ligament. Behind the internal malleolus are the common sheaths of the tibialis posticus and flexor longus digitorum, beginning about an inch above the extremity of the malleolus and extending to the astragalar-navicular junction and that of the flexor longus hallucis of about the same extent (Fig. 430). Behind the outer malleolus is the sheath of the two peronei, beginning one inch above the malleolus, dividing into two portions for the two tendons and ending just behind the tuberosity of the fifth metatarsal bone (Fig. 431). These sheaths are often utilized in tendon transplantation.

Treatment.—Simple traumatic tenosynovitis should be treated by rest and by compression. An effective treatment is strapping with adhesive plaster, so applied as to prevent the movements of the foot that cause discomfort. In more painful and persistent cases a plaster bandage to assure absolute rest may be necessary. Cautery applied over the affected part is of service. Chronic tenosynovitis may follow injury or complicate the flat-foot, or it may be the result of gonorrhea or other infectious disease. In chronic cases when the palliative treatment is ineffective, thorough removal of the affected sheath is indicated. (See Achillobursitis.)

Tuberculous Tenosynovitis.—A persistent and increasing swelling of a tendon sheath always suggests tuberculous disease. In such instances the sac is thickened and often contains the so-called rice bodies. Prompt and complete removal of the diseased sheath is indicated, and by this means a permanent cure may be attained in most instances.

TUMORS OF TENDON SHEATHS.[1]

These are comparatively rare and are most common in the hand interfering with the action of the fingers.

Fibromata, chondromata, sarcomata and fatty tumors occur. The most common tumor is the giant-cell myeloma, its cause being probably an effusion of blood and its subsequent organization.

SWELLING ABOUT THE ANKLES.

Occasionally, often in combination with weak feet there are distinct swellings about the ankles. The most common is in front of the external malleoli. This is apparently a bursa-like formation, or a

[1] Buxton: British Jour. of Surg., April, 1923.

proliferation of fatty and connective tissue, "Boule prémalleolaire. In most cases the patients are fat and the apparent cause is overweight.

FIG. 433.—Painful swellings about the ankles, common in overweighted subjects.

The patients usually complain of weakness and discomfort. The treatment, aside from reduction of weight and support for the weakened arch, is massage, strapping and bandaging. The operative removal of the sensitive tissue is indicated in obstinate cases.

CHAPTER XII.

DISEASES AND INJURIES OF THE ARTICULATIONS OF THE UPPER EXTREMITY.

TUBERCULOUS DISEASE OF THE SHOULDER-JOINT.

Disease at the shoulder is very uncommon in childhood. In 1883 consecutive cases of joint disease—Pott's disease being excluded—treated in the out-patient department of the Hospital for Ruptured and Crippled in a period of five years, the shoulder-joint was involved in 38 instances (2 per cent.). Of 1900 cases of joint disease treated at Billroth's clinic, the shoulder was involved in 14, or less than 1 per cent. At the Boston Children's Hospital but 17 cases were recorded in a total of 7474 cases of tuberculous disease of spine and joints, illustrating its infrequency in early life.[1]



Fig. 434.—Section of the shoulder-joint at the age of eight years. (Schuchardt.) Ossification appears in the epiphysis of the head of the humerus at the end of the first year; a second point appears in the greater tuberosity during the second year. These unite between the fourth and sixth years. Ossification is complete between the eighteenth and twentieth years. The angle formed by the head and shaft is from 130° to 140°. The range of motion at the joint between adduction and abduction is about 90° and between flexion and extension (anteroposterior movement) somewhat less.

Pathology.—The disease usually begins in the head of the humerus, often in the neighborhood of the *bicipital groove*, where the blood supply is most free. In 32 observations on adults recorded by Mondan and Andry[2] the primary disease was of the head of the humerus in 23

[1] Sever: Boston Med. and Surg. Jour., March 24, 1910.
[2] Rev. de Chir., 1892.

MEDICAL LIBRARY BOSTON CITY HOSPITAL

cases, of the humerus and scapula in 4, of the scapula alone in 1, and in 3 instances it appeared to be primarily synovial.

In the majority of cases abscess forms and appears near the anterior insertion of the deltoid muscle. In advanced cases the tissues of the axilla and of the adjoining thorax may be infiltrated and perforated by numerous sinuses. Not infrequently the disease is of the form called caries sicca, in which there is no enlargement of the joint, but progressive destruction of the head of the humerus by granulation tissue. This form is characterized by extreme muscular atrophy and by practical anchylosis.

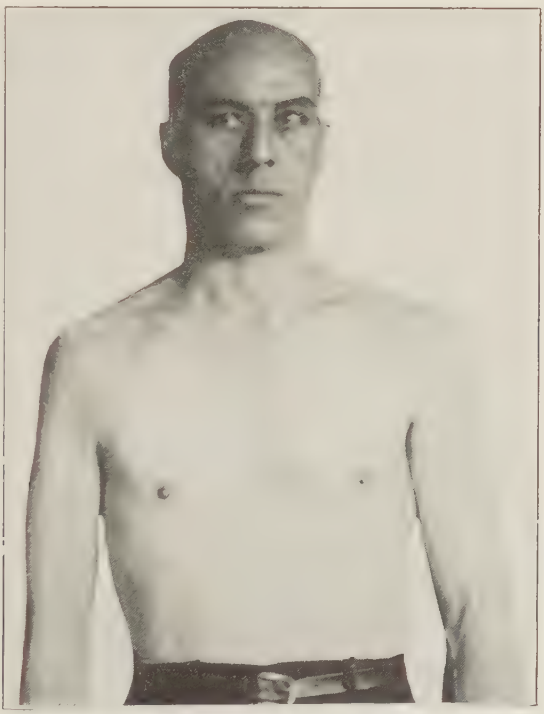

FIG. 435.—Tuberculous disease of the shoulder-joint, showing the atrophy.

Townsend[1] made a detailed report on 21 cases treated at the Hospital for Ruptured and Crippled during the years 1889 to 1893. Ten of these were less than ten years of age; 7 were between ten and twenty, and 4 were more than twenty. The youngest patient was three and a half and the age of the oldest was thirty-five years. In 5 cases the disease was secondary to disease of other parts; in 1 case to Pott's disease; in 2 to hip disease, and in 2 to disease of the knee-joint.

[1] Tr. Am. Orthop. Assn., vol. 7.

AGE AT INCIPIENCY OF DISEASE AT THE SHOULDER-JOINT IN SIXTY-TWO CONSECUTIVE CASES TREATED AT THE HOSPITAL FOR RUPTURED AND CRIPPLED.

1 year or less	1	13 years old	3
2 years old	6	15 "	2
3 "	1	18 "	3
4 "	3	19 "	5
5 "	3	20 "	4
6 "	1	23 "	1
7 "	3	26 "	2
8 "	4	27 "	1
9 "	6	34 "	1
10 "	1	48 "	1
11 "	5	56 "	1
12 "	4		
		Total	62

Males, 38; females, 24; right, 35; left, 27.

Symptoms.—The history of the case will indicate the persistent and progressive character of the disability, but the symptoms characteristic of tuberculous disease are far less marked at the shoulder than at other joints. This is explained by the fact that the upper extremity is not subjected to weight-bearing and because the mobility of the scapula upon the thorax lessens the injury caused by unguarded movements of the arm. This movement of the scapula masks the interference with the function of the joint, and the strain caused by overuse is lessened by the unconscious restraint of motion. In fact, even when anchylosis is present the patient may think that motion is but moderately restricted.

The symptoms of the disease may be classified as *pain, sensitiveness, restriction of motion, atrophy.*

There is usually a dull ache about the joint, with occasional neuralgic pain referred to the elbow and arm. The discomfort is increased by movements that pass beyond the limits allowed by the mobility of the scapula, especially on attempting to rotate the humerus, as in clothing one's self or brushing the hair. The joint is sensitive to pressure; thus the patient finds that he cannot lie on the affected side at night.

On examination the limitation of motion caused by muscular spasm will be evident if the scapula is fixed.

Pressure about the head of the humerus usually causes pain, and in many instances local heat and swelling are present. The atrophy of the shoulder muscles is often extreme and that of the other muscles of the limb is well marked.

As has been stated, abscess is a common accompaniment of the disease, and in such cases the tissues about the joint are swollen and infiltrated. In other instances there is progressive destruction of the head of the humerus without abscess formation (caries sicca). In cases of this type the flattening of the shoulder may be so extreme as to be mistaken for subcoracoid dislocation.

Treatment.—The treatment of the disease here as elsewhere is rest. To assure absolute functional rest in older subjects the wrist should be

attached to the neck by a sling, the elbow being flexed to an acute angle; the arm is then fixed to the thorax by a bandage. Local rest and compression may be still further assured by strips of adhesive plaster applied over the shoulder and extending to the back and chest; or a shoulder-cap of leather or plaster may be employed. In the treatment of children the arm should be fixed during the progressive stage of the disease by a plaster splint in right angular abduction. This assures fixation and eventually such a degree of abduction as will enable the muscles attached to the scapular to raise the arm sufficiently for functional requirements.

FIG. 436.—Tuberculous disease of the shoulder-joint.

If the focus of disease seems to be localized in the roentgen-ray picture, an exploratory operation for its early removal may be indicated Arthrectomy in younger subjects may be considered, when suppuration is persistent or when for other reasons it may seem best to attempt to remove the diseased area. Operative fixation (arthrodesis) may be indicated in suitable cases in which the diagnosis has been established. Excision of the joint or a plastic operation after cure of the disease may be advisable, for the purpose of restoring motion in adolescent

or adult cases or an osteotomy below the joint may be performed to improve the attitude.

Prognosis.—The duration of the disease appears to be from two to five years. The death-rate is higher than in disease of the joints of the lower extremity, because a larger proportion of the patients are adults, and in this class tuberculosis of the lungs is not an infrequent complication.

It is impossible to speak positively of the results of the conservative treatment of disease of the shoulder. The disease is uncommon, and protection is almost never applied in the incipient stage, nor efficiently and persistently employed to the end. The ordinary result is, therefore, anchylosis, usually of the fibrous rather than of the bony variety.

If the disease appears in early life the growth of the limb may be seriously interfered with; an inch or more of shortening from this cause is not uncommon.

TUBERCULOUS DISEASE OF THE ELBOW-JOINT.

Tuberculous disease of the elbow-joint is the fourth in order of frequency, preceding the shoulder and the wrist. Of 1883 consecutive cases of joint disease treated at the Hospital for Ruptured and Crippled 56 were of the elbow.

Pathology.—The primary disease is in most instances osteal, as in 92.8 per cent. of the cases investigated by Scheimpflug, 44 in number.[1] The original focus of infection is somewhat more often of the ulna than of the humerus. Of the ulna the olecranon process, and of the humerus the external condyle appear to be the points of election. Disease of the head of the radius is comparatively infrequent.

AGE AT INCIPIENCY OF DISEASE AT THE ELBOW-JOINT IN FIFTY-NINE CONSECUTIVE CASES TREATED AT THE HOSPITAL FOR RUPTURED AND CRIPPLED.

1 year or less	2	13 years old	3
2 years old	5	14 "	2
3 "	8	15 "	1
4 "	5	17 "	1
5 "	5	19 "	1
6 "	4	21 "	1
7 "	8	23 "	2
8 "	1	25 "	1
9 "	2	29 "	1
10 "	5		
11 "	1	Total	59

Males, 28; females, 31; right, 27; left, 32.

Occurrence.—In 119 cases reported by Ollier the olecranon was involved in 73, the humerus in 33, and the radius in 12 instances.[2] And in the cases investigated by Kummer[3] and Middledorpt,[4] the ulna was more often the seat of the primary disease than was the

[1] Festschrift f. Billroth, 1892.
[2] Karewski: Chir. Krank. des Kindesalter, 268.
[3] Deutsch. Ztschr. f. Chir., vol. **27.** [4] Arch. f. klin. Chir., vol. **33.**

humerus, but in 81 cases treated in König's clinic the primary disease was of the humerus in 43, of the olecranon in 36, and of the radius in 2 instances.

Symptoms.—The symptoms are those of a chronic, persistent, destructive disease—*pain, local sensitiveness and swelling, stiffness, deformity, atrophy.*

The pain is usually localized at the elbow. It is increased by sudden movements, and as the bones are so superficial there is usually local sensitiveness to pressure, most marked over the seat of the disease. In the early stage the swelling is slight, and it is of the peculiar

FIG. 437.—Tuberculous disease of the elbow-joint.

elastic character due to thickening of the tissue rather than to effusion within the capsule, but as the disease progresses the joint assumes the peculiar spindle shape characteristic of "white swelling." The degree of elevation of the local temperature depends upon the activity of the disease. The most important physical sign is the restriction of motion due to the characteristic muscular spasm which becomes evident when the limit of painless motion is passed. The limitation of extension and flexion gradually increases, and finally the limb becomes fixed in an attitude midway between flexion and extension, with the forearm in an attitude between pronation and supination. This is the characteristic deformity of the disease.

Atrophy of the muscles of the arm and forearm is present, corresponding to the severity and duration of the disease and to the functional disability of the joint.

Treatment.—The treatment here as elsewhere consists essentially in placing the joint at rest in the attitude at which anchylosis or limitation of motion will least inconvenience the patient, and at the elbow-joint this is practically at right angular flexion with the forearm midway between pronation and supination (Fig. 438).

In the treatment of young children the wrist may be attached closely to the neck by means of a sling, in an attitude of acute flexion at the elbow (the Thomas method) within the clothing. Or a light plaster splint may be used to fix the wrist, being supported by a sling.

Fig. 438.—Tuberculous disease of the elbow-joint; the stage of recovery.

This enables the patient to dress himself without moving the joint and at the same time protects it from injury. Other forms of splints may be employed, but the plaster support answers every purpose. It should, of course, extend from the axilla to the wrist, and in sensitive cases it may include the hand also. The Bier treatment may be easily applied and its effects should be tested in all cases.

Reduction of Deformity.—In many instances the arm is fixed in the semiextended attitude when the patient is brought for treatment. A simple and effective means of reducing deformity in childhood is that suggested by Thomas. When it is impossible to bring the wrist to the neck, one bends the neck toward the wrist and attaches the

two by a bandage which the patient is unable to remove. From this uncomfortable attitude the patient can free himself only by drawing the forearm toward the neck and thus reducing the deformity. At the next visit the same procedure is repeated, until finally the elbow is flexed to the required degree. A permanent sling may be constructed of a leather wrist-band and a tube of leather to pass about the neck, through which the bandage may be drawn; thus the pressure on the wrist and neck may be lessened. In the very resistant cases reduction of deformity under anesthesia may be required but this is not often necessary.

Operative Treatment.—In some instances it is possible to remove small foci of disease from the humerus, or from the adjoining bones before the joint is involved. The position of the disease may be indicated by sensitiveness or swelling, and in older subjects a roentgen-ray picture may demonstrate its position accurately.

Excision of the Elbow.—Excision is often advisable in adolescent or adult life, because by this procedure the disease may be removed in most instances, and because motion may be assured.

Oschman has recently investigated the final results of the operation performed on this class at Kocher's[1] clinic at Berne, 1872–1897. In 40 of 45 cases the operation was performed for tuberculous disease. There were no deaths referable to the operation. Of the entire number of cases 15 were dead, but 11 of these survived the operation for from five to twenty years. Eight of the deaths were due to tuberculosis, 2 to other causes, and in 5 the cause of death was unknown. In 96 per cent. of the cases the local disease was cured. In 68 per cent. of the cases the patients were able to use the limb at hard labor, and in the others it was efficient for light work. In 6 cases there was subluxation or luxation; in 5 the joint was not firm. In 59 per cent. the motions were practically normal. In 11 per cent. the joint was anchylosed.

Prognosis.—If the case is treated at an early stage the prognosis in childhood is good. The duration of treatment may be estimated at two years or more, and a fair range of motion will be preserved in half the cases. Anchylosis in the right-angled position does not, however, seriously inconvenience the patient, provided the cure is absolute. The loss of growth is usually less than when the upper epiphysis of the humerus has been destroyed, the final disproportion depending, of course, upon the age of the patient and upon the degree of function that is preserved.[2]

TUBERCULOUS DISEASE OF THE WRIST-JOINT.

Disease of the wrist-joint is very uncommon in childhood. In a total of 3105 cases of tuberculous disease treated in the out-patient department of the Hospital for Ruptured and Crippled during a period

[1] Arch. f. klin. Chir., Band **60**, Heft 2.

[2] In 38 final results of non-operative treatment reported by Sever good motion was retained in 12. In 16 anchylosis was present. (Loc. cit.)

of five years, 98 were of the upper extremity, and in but 4 of these was the wrist-joint involved. Of 43 cases in which the joint was resected by Ollier, the youngest patient was thirteen years of age.

FIG. 439.—Tuberculous disease of the wrist- and knee-joints, showing the characteristic deformities in neglected cases of a severe type.

FIG. 440.—Tuberculous disease of the right wrist-joint, showing the swelling and the limitation of motion.

MEDICAL LIBRARY
OF THE
BOSTON CITY HOSPITAL

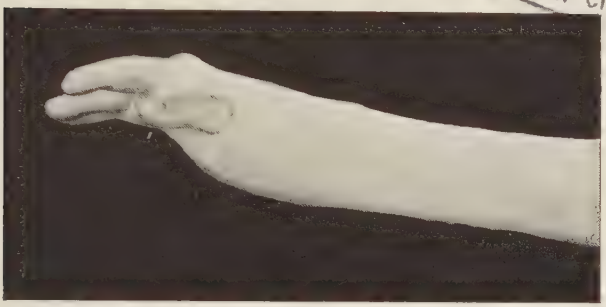

FIG. 441.—Treatment of tuberculosis of the wrist-joint by plaster of Paris, showing the proper attitude



FIG. 442.—Tuberculous disease of the carpus.

FIG. 443.—Tuberculous disease of the left wrist-joint. The irregularity and the diminished size of the carpal bones indicate the extent of the destructive process. The patient, the mother of the child with Pott's disease (Fig. 10), died soon after from tuberculosis of the lungs.

Of 990 cases of disease of the joints in childhood, reported by Karewski, the wrist was involved in 31.[1]

Disease of the wrist in older subjects is less infrequent, although at all ages it is rare as compared with disease in other joints. Tuberculous disease of the metacarpus and phalanges (spina ventosa) is, however, far more common.

AGE AT INCIPIENCY OF DISEASE AT THE WRIST-JOINT IN EIGHTEEN CONSECUTIVE CASES TREATED AT THE HOSPITAL FOR RUPTURED AND CRIPPLED.

2 years old		1	19 years old		2
6	"	1	20	"	2
9	"	1	25	"	2
12	"	2	26	"	2
14	"	1	27	"	1
16	"	2			—
17	"	1		Total	18

Males, 11; females, 7; right, 12; left, 6.

Symptoms.—The symptoms of tuberculous disease of the wrist are, as in other situations, *pain, local swelling* and *sensitiveness, limitation of motion,* caused by muscular spasm, and *atrophy.* In advanced cases the hand is usually flexed somewhat upon the arm.

Treatment.—The treatment of this, as of other joints, is functional rest, with support in the attitude in which anchylosis or limitation of motion will cause the least inconvenience. A light plaster splint extending from the elbow to the tips of the fingers, applied over a flannel bandage drawn as tight as the comfort of the patient will permit, is a satisfactory support; or a leather splint or other form of appliance may be used. The hand should be supported in an attitude of moderate dorsal flexion, which will permit the flexor muscles to close the fingers easily if the wrist becomes fixed by the disease. If flexion deformity is present it should be corrected slightly at each application of the bandage, until the desired attitude is attained (Fig. 428). The flannel bandage exercises a certain degree of compression upon the wrist, which seems to be of benefit, and in certain instances this compression and fixation may be still further increased by the application of adhesive plaster. Bier's treatment by passive congestion may be applied, and according to reports it is especially efficacious in this situation. When the disease of the joint is quiescent, or in the stage of recovery, the bandage or splint may be shortened to permit the use of the fingers.

Prognosis.—The prognosis as regards function in cases treated promptly in childhood should be good. Sorrel and Longnet[2] from observations on 47 cases treated by a palmar splint permitting movement of the fingers and sunlight, conclude that good function may be assured in 80 per cent of the cases. In the adult, wrist-joint disease seems to be very often accompanied by disease of the lungs; thus the prognosis as to life is bad. In this class of cases early excision is usually recommended, with amputation as a final resort.

[1] Chir. Krank. des Kindesalter, Berlin, 1894.
[2] Rev. d'Orthopédie, January, 1928.

SPINA VENTOSA.

Central disease of the long bones of the foot and hand is the most common form of diaphyseal tuberculosis. While the cortical substance is destroyed from within it is often replaced in part by a formation of periosteal bone from without, which in turn may be destroyed by the advancing disease. In the early cases the affected bone is enlarged, spindle-shaped, and is somewhat sensitive to pressure. At this stage repair may take place with but little ultimate change from the normal, but in many instances the bone is perforated and in part destroyed, the neighboring joint is involved, and the finger becomes stunted and distorted.

According to Benci and Mezzari,[1] disease of the fingers was present in 4.21 per cent of the tuberculous cases under their observation. In 50 per cent but one phalanx was involved; usually the first phalanx of the middle finger. In 66.27 per cent of the cases there were other foci of disease.

In 159 cases tabulated by Karewski,[2] the metacarpal bones were diseased in 65 instances; the phalanges in 57; the metatarsal bones in 29, the phalanges of the toes in 8. In a number of instances several of the bones and larger joints were involved also (159 cases in 135 patients).

The disease is more common in the early years of life, 84 of the 135 patients being four years of age or less, 38 of these being less than two.

Spina ventosa of the phalanges may be treated by rest and compression, and both splinting and compression may be assured by adhesive-plaster strapping. If the joint is involved amputation of the finger may be indicated, because of the distortion, and loss of growth that may be expected. Tuberculous disease, limited to a single bone of the carpus or metacarpus, may be treated by operative removal of the disease.

PERIARTHRITIS OF THE SHOULDER—STIFF AND PAINFUL SHOULDER—SUBDELTOID BURSITIS.

Under the title of scapulohumeral periarthritis, Duplay,[3] in 1872, described a painful affection of the shoulder induced by injury, dependent upon an inflammation of the bursa lying between the deltoid and supraspinatus and infraspinatus muscles and the coraco-acromial ligament. But under this title are now included a number of affections that cause similar symptoms in which it would appear that the interior of the joint is not involved.

Symptoms.—In a typical case of so-called periarthritis the patient complains of a dull pain about the joint and sensitiveness to pressure just below the acromion process or over the bicipital groove and occasionally a swelling is evident on the anterior aspect of the joint.

[1] Chir. Orig., November 13, 1929.
[2] Chir. Krank. des Kindesalter, Berlin, 1894.
[3] Arch. gén. de méd., Paris, 1872.

The pain is increased by motion, particularly by abduction or by rotation at the shoulder. In mild cases only unguarded movements cause pain, but in most instances there is a constant sensation of discomfort which is increased to acute pain by sudden movements or jars. The part becomes sensitive to pressure, so that the patient avoids lying on the shoulder at night. In certain instances the pain may radiate about the shoulder and down the arm, and there may be weakness and numbness of the fingers. Gradually the passive movements of the joint are diminished in range, and atrophy of the shoulder muscles appears.

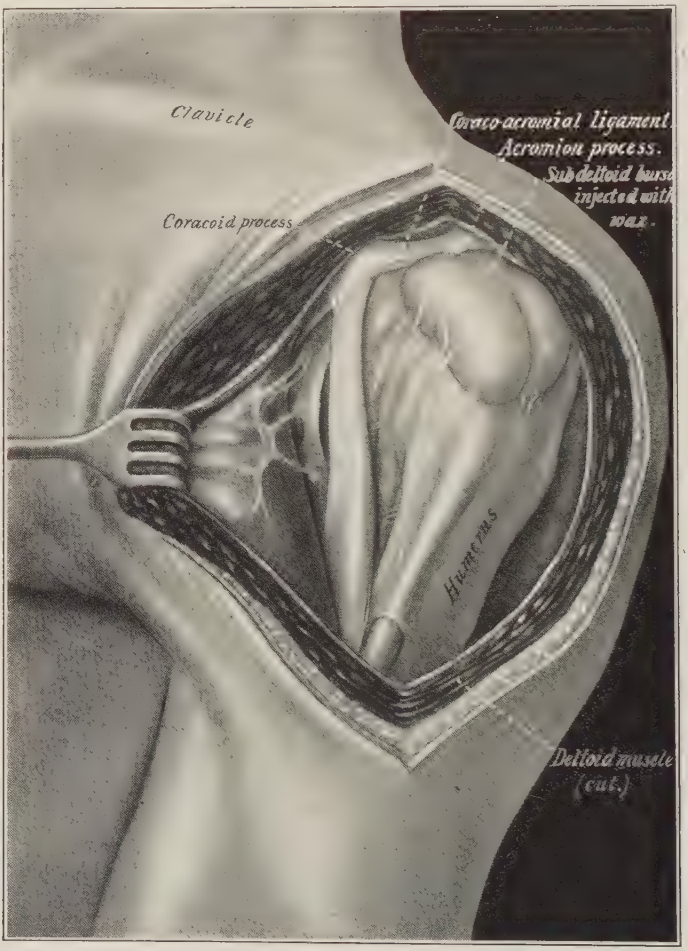

FIG. 444.—The subdeltoid bursa. (Baer.)

These symptoms usually pass as "rheumatism," but there is no fever, no involvement of other joints, no swelling, and as a rule, no general sensitiveness to pressure, as is usual when the synovial membrane of the joint is involved. In certain instances the symptoms

follow injury, strain or exposure to cold, or they appear without apparent cause. In typical cases the symptoms are due to inflammation of the subdeltoid bursa, as originally described by Duplay. This bursa lies beneath the deltoid muscle, separating it from the joint. According to Baer it is about the size of a silver half-dollar (Fig. 444). It sends a prolongation beneath the acromion process and the coraco-acromion ligament. If the bursa is enlarged it presents a mechanical obstacle to abduction and in acute cases one that is sensitive to pressure. Symptoms somewhat similar may be caused by inflammation of the subcoracoid bursa, lying between the tip of the coracoid and the capsule, extending to and over the lesser tuberosity. In such cases rotation is more directly restrained than abduction. By *tenosynovitis* of the biceps tendon as suggested by local sensitiveness at the bicipital groove, and by the creaking sensation at this point when the muscle is in use. By arthritis of the acromio clavicular articulation indicated by local pain and sensitiveness at this articulation.[1] By injury or rupture of the supraspinatus tendon,[2] and doubtless by unclassified injury, subluxation at the shoulder and intra-articular disease in the incipient stage. It is probable also that in some cases the nerves in the neighborhood of the joint may be secondarily implicated in an inflammation of bursæ, or directly injured by the original traumatism, if such preceded the symptoms. Thus neuritis may add to the discomfort and prolong the disability.

Treatment.—During the acute and painful stage the arm should be kept at rest. Cautery may be applied and the joint should be enclosed in adhesive-plaster strapping, and if the weight of the limb causes discomfort it should be supported. In certain instances tension on the sensitive part may be relaxed by supporting the arm in an attitude of moderate abduction. In very painful cases infiltration with a weak solution of novocaine, 0.5 to 0.125 per cent. in warm water usually relieves the sensitiveness and lessens the muscular spasm. The needle is inserted beneath the acromion and from 30 to 55 cm. of the fluid injected. After the pain has subsided the limb is moved gently and finally supported in abduction.[3] When the acute symptoms have subsided passive movements, massage, and static electricity and the like are of service. Voluntary exercises should be employed when they no longer aggravate the symptoms. In the cases of longer standing in which motion is restricted, apparently by adhesions without the joint, forced movements under anesthesia to the extremes of the normal range in all directions are usually of benefit. In such cases it may be well to support the limb for a time in the abducted attitude to prevent the reformation of the adhesions. Afterward passive motion, massage and exercise must be employed to prevent the return of the restriction. Particular attention should be paid to abduction, since this is the movement most often restricted. The patient should be

[1] Sievers: Deutsch. Ztschr. f. Chir., vol. **129**, 583.
[2] Codman: Boston Med. and Surg. Jour., July 27, 1911.
[3] Schulhof: Ztschr. f. Chir., May 29, 1926.

seated in a chair. The surgeon standing over him presses firmly on the shoulder with one hand, and with the other gradually raises the arm to a right angle with the trunk. If these cases are treated carefully in the early stage recovery is usually rapid, but if neglected the symptoms may persist indefinitely.[1]

Operative.—In cases in which it is evident that the symptoms are caused by effusion within the bursa, the fluid may be removed by aspiration or an open operation may be indicated. An incision about 2 inches in length is made through the anterior fibers of the deltoid muscle or directly downward from the tip of the acromion. The sac is opened, its contents removed and, if practicable, its walls should be dissected from the neighboring tissues. Brickner[2] has called attention to the fact that calcareous deposits are usually not in the bursa but in the sheath of the supraspinatus tendon lying beneath it. These deposits induced by injury of the tendon often form rapidly, and may be removed through an incision at the base of the bursa, although they are of less importance than was at one time assumed, as they usually disappear spontaneously and are apparently of a fatty rather than a calcareous nature. One should also investigate the condition of the supraspinatus tendon and if as in cases reported by Harbin[3] it is in a state of calcareous degeneration the areas may be resected and the tendon repaired. The arm should then be supported in the abducted attitude or, as Brickner has suggested, attached to the head of the bed which is raised on blocks so that the tendency of the body to slide downward assures the elevated position of the arm. Operative treatment early in the disease will greatly shorten its duration and is indicated in suitable cases.[4]

SNAPPING SHOULDER.

In rare instances, as compared to the same condition at the hip and knee, cases of snapping shoulder are encountered. In a case recorded by Bristow,[5] the snapping which was audible and painful when the arm was abducted and rotated, was caused by friction between the lesser tuberosity and the muscular fibers from the short head of the biceps passing to the coracoid process, a developmental anomaly representing the upper element of the tripartit coracobrachialis. In other cases the friction has been between the anterior fibers of the deltoid and the acromion or the cause may be an exostosis or possibly a slight degree of subluxation. Operative treatment is indicated in cases in which the disability is caused by friction.

[1] Codman: Boston Med. and Surg. Jour., May 31, 1906; Baer: Johns Hopkins Hosp. Bull., No. 195.
[2] Interstate Med. Jour., April, 1915.
[3] Arch. Surg., April, 1928.
[4] Carnett: Surg., Gynec. and Obst., October, 1925.
[5] Jour. Bone and Joint Surg., January, 1924.

CHRONIC BURSITIS.

Chronic bursitis at the shoulder-joint is comparatively infrequent. The bursæ most often involved are the coracoid, the subscapular, and the subdeltoid. Of these the last is the most often affected. Sixteen cases have been reported by Blauvelt,[1] and three others by Ehrhardt.[2] The enlarged bursa forms a fluctuating swelling most noticeable on the anterior and outer aspect of the shoulder, the symptoms being discomfort, weakness, and limitation of motion of the arm. The disease is usually tuberculous in character, and it should be treated by complete removal of the sac if possible.

EPICONDYLITIS—TENNIS ELBOW.

Tennis elbow is a type of injury usually caused by strain or overexertion.

The symptoms are weakness and pain on supination and pronation and often slight swelling and sensitiveness to pressure about the external condyle of the humerus. According to Osgood the cause is an inflammation of a small bursa lying beneath the conjoined tendon of the extensor muscles between it and the epicondyle. This may be removed by a direct incision through the tendon. Similar symptoms occur in other situations over bony prominences, the styloid process of the radius, the head of the fibula, the tip of the acromion and elsewhere. In some instances the pain may be relieved by alcohol injections, otherwise operative removal of the sensitive tissue is indicated.

Jones has indicated the most effective conservative treatment of epicondylitis. Direct pressure is made at the sensitive point by several thicknesses of adhesive plaster fixed in place by adhesive tape. A similar pad for compression is then placed upon the muscle below the joint. The first pad is designed to press out the effused fluid and thus to permit direct contact of the separated tissues. The second is by pressure on the muscles to limit their activity. The same principle applies to similar injuries of other parts.

Mills[3] has noted in these cases, that if the wrists and fingers are fully flexed and the forearm pronated, complete extension at the elbow is restricted and painful. He therefore places the arm in this attitude and forces it into complete extension making firm pressure with the thumb over the sensitive spot. In some instance there is an audible click when the resistance gives way.

The manipulation may be carried out in some instances without an anesthetic. Mills thinks the condition similar to a displaced cartilage in the knee caused by a subluxation of the radius or displacement of the orbicular ligament.

[1] Beitr. z. klin. Chir., vol. 22.
[2] Arch. f. klin. Chir., vol. 60.
[3] British Med. Jour., January 7, 1928.

SPRAIN OF THE WRIST.

This is a very common accident. The most effective treatment is the adhesive-plaster strapping applied about the metacarpus, wrist, and lower half of the forearm. If the pain on motion is severe sufficient plaster is applied to splint the part and to limit movement to the point of comfort. If the injury is of a slighter grade the compression and support of a single layer of plaster is usually sufficient. This dressing prevents strain, and yet it permits a certain degree of functional use, which is the most effective means of restoring a joint to its normal condition by hastening the absorption of the effused material within and without the injured part.

Chronic Sprain.—Persistent weakness and stiffness may follow treatment of a sprain by splints or when for any reason disuse of function has been long continued. In many instances, however, the sprain was in reality a fracture or displacement of the carpus. All chronic sprains, therefore, should be examined by means of the roentgen-rays in order that the presence or absence of more extensive injury may be determined.

The treatment is similar to that of the acute sprain: aside from operative interference to remove direct obstructions to movement, protection from injury, and functional use to the extent of which the part is capable. With this, passive congestion, massage, hot air, and electricity or other form of local stimulation may be employed with advantage. The same treatment is indicated when the joint is stiff and painful as the result of rheumatism or other inflammation, provided the stage of recovery has been reached.

FRACTURE OF THE CARPAL BONES.

Fracture of the carpal bones not infrequently complicates sprains, the scaphoid being most often involved. The relative frequency of injury to the carpal bones is illustrated by the statistics of Destot: scaphoid, 150; semilunar, 26; other bones, 14. Dislocation of the semilunar bone also is not uncommon. It is caused apparently by forced dorsiflexion of the hand. It is usually displaced anteriorly, the concave surface directed forward. In some instances it causes pain by pressure on the nerves or interferes with the circulation. In recent cases replacement is often possible by dorsiflexion of the hand and direct pressure on the bone; otherwise its removal is usually indicated. The fractured scaphoid should be removed if it causes persistent disability.

KIENBOCK'S DISEASE.

This is an affection of the semilunar bone similar in etiology and symptoms to Köhler's disease of the tarsal scaphoid. It is most common in young adults of the laboring class. The semilunar becomes flattened or otherwise distorted and the movements of the wrist are

MEDICAL LIBRARY
BOSTON CITY HOSPITAL

somewhat restricted and painful. Buckman[1] has tabulated 202 reported cases, males 145, females 37. Right 94, left 38. In persistent cases removal of the bone is indicated[2] through a dorsal incision.

FIG. 445.—Kienbock's disease showing increased density and flattening of the semilunar, an appearance similar to that of Köhler's disease of the scaphoid.

TENOSYNOVITIS.

Acute.—Tenosynovitis more especially of the flexor tendons is common at the wrist-joint. It is usually induced by strain or overuse of a muscle or muscular group.

Movements of the muscles that are involved cause discomfort, and there is usually local sensitiveness and a creaking sensation on palpation over the affected tendon sheath. The same symptoms with more sensitiveness to direct pressure may be caused by inflammation of the peritendinous tissues. The adhesive-plaster strapping, so applied as to exert compression and to prevent the motion, that causes discomfort, is the most effective treatment.

Chronic.—Chronic tenosynovitis, causing progressive enlargement of a tendon sheath, with accompanying symptoms of weakness and discomfort, is usually tuberculous in character. If the disease is of long standing, extending into the palm of the hand, it may be advisable, as a preliminary treatment, to simply evacuate the contents, including the rice bodies, through an incision. An astringent solution may be injected, and after its removal the incision may be closed.

[1] Ann. Surg., June, 1928.
[2] Partsch. Zeut. f. Chir., May 26, 1928.

Pressure is then applied, with the aim of securing partial adhesions of the apposed surfaces. As a rule, however, radical removal of the diseased tissue is indicated.

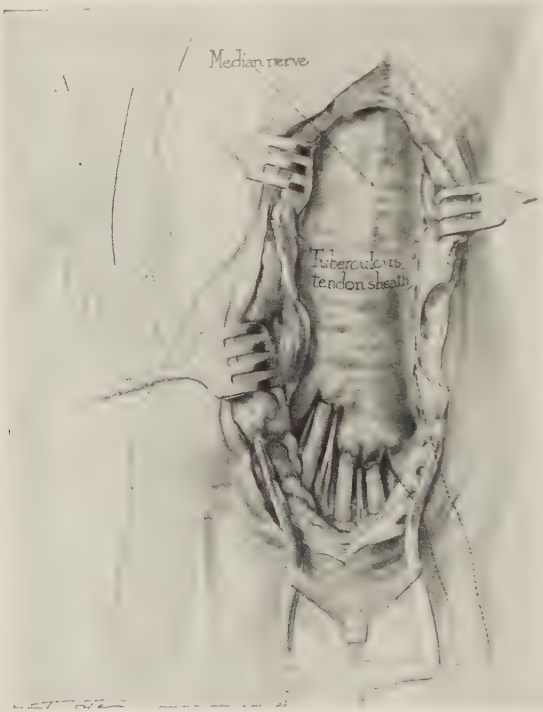

FIG. 446.—Operative incision and appearance of tuberculous tendon sheaths. (Kanavel.)

SUPERNUMERARY BONES OF THE WRIST.

Supernumerary bones occur at the wrist-joint, but are less common and less important than those of the foot. These are os triangularis, which may be mistaken for fracture of the styloid process of the ulnar; os epipyramis, which resembles a fracture of the semilunar. The navicular may be in two parts, resembling fracture. The names of the other bones are os paratrapezium, os versalium and os ulnare externum.

CHAPTER XIII.

DEFORMITIES OF THE UPPER EXTREMITY.

CONGENITAL DISLOCATION OF THE SHOULDER.

This may occur in two forms, one in which there is actual misplacement before birth, and the other in which a dislocation is caused by violence at birth. In either case the displacement is almost always backward upon the dorsum of the scapula (subspinous). Thus the arm is abducted and rotated inward, and the head of the displaced bone may be felt in its abnormal position. Cases of congenital displacement in other directions are recorded, but these are so unusual as to be of little practical importance.[1]

True primary displacements of either variety are comparatively uncommon, many of the reported cases being secondary to the habitual malposition induced by obstetrical paralysis (Fig. 452). According to Porter,[2] 29 cases are recorded in literature, in at least half of which the diagnosis is doubtful. It is, of course, apparent that both displacement and paralysis may be coincident and caused by injury at birth.

OBSTETRICAL PARALYSIS.

Partial or complete paralysis of the muscles of the arm may be a result of difficult or protracted labor. It may be induced by direct pressure on the brachial plexus, but most often it is caused by traction on the trunk or the head, or by violent twists of the neck during delivery. It is a comparatively common injury, 69 new patients having been registered at the Hospital for Ruptured and Crippled in a single year, 39 of these being less than one year of age. In rare instances the paralysis may be bilateral. In some cases the nerve roots may be torn apart, in others the injury may be principally to the sheath causing hemorrhage, and in the process of repair scar tissue forms which presses upon the nerve elements. The fifth and sixth roots are most often injured, consequently the common form of paralysis is the upper arm type, involving the deltoid, the supra- and infraspinati, the biceps, coracobrachialis, the supinators of the forearm and, in part, the pectoralis major. Thus, the power of abduction and external rotation at the shoulder, of flexion and supination of the forearm is lost and the arm hangs in an attitude of inward rotation with pronated forearm. If the injury is more severe the muscles of the hand may be involved, usually in association with the upper arm form of paralysis. In the more extensive form of paralysis pupillary inequality is sometimes present, due to involvement of the sympathetic system.

[1] Scudder: Am. Jour. Med. Sci., February, 1898.
[2] Tr. Am. Orthop. Assn., 1900, vol. 13.

Obstetric Paralysis in Eleven Hundred Cases. (Sever[1].)

Boys	551
Girls	549
Right arm affected	670
Left arm affected	430
Both arms affected, upper arm type	35
Both arms affected, whole arm type	22
Both arms affected, type not recorded	6
Upper arm type	829
Whole arm type	208
Difficult labor	584
Ether used	502
Normal labor	57
Head presentation, including face	443
Breech presentation, including foot and version	142
Presentation not known	458

In a group of 460 cases, 400 were of the upper arm type.[2] In 81 cases operated on by Sharpe,[3] the fifth and sixth roots were injured in 62, the seventh in 21, the eighth and first dorsal in 19.

In rare instances the humerus may be dislocated, or the upper epiphysis may be displaced, or the clavicle fractured, either in combination with the injury of the plexus or distinct from it.

Eventually under the influence of unbalanced muscular action, the head of the humerus is displaced backward, subluxated, so that the arm is abducted on the scapula, flexed forward and rotated inward. All movements are restricted by the accommodative changes in the capsule and other tissues, and in later years the condition may be easily mistaken for true congenital dislocation.

Whether cases reported as congenital displacement of the humerus are secondary to paralysis or not, it is evident that all cases of obstetrical paralysis should be carefully examined with regard to a complicating dislocation, and that the secondary deformity induced by paralysis should be prevented.

Treatment.—During the first month after birth the shoulder of the paralyzed arm is often somewhat swollen, and motion may cause pain. In such cases rest is indicated. The arm should be placed against the side, and the hand, with the fingers extended, should be supported on the chest beneath the clothing. When the primary sensitiveness has subsided, each of the joints of the extremity should be moved systematically to the limit of the normal range of motion several times in a day. For example, the humerus should be hyperextended and rotated outward at the shoulder; the forearm should be supinated and the wrist and fingers should be extended, if they are involved in the paralysis. The muscles should be massaged, and the arm should be supported by a sling, or preferably in an attitude of abduction at the shoulder and supination at the elbow by a light splint (Fig. 448). Recovery may be complete, although it is often delayed for many

[1] Jour. Am. Med. Assn., December 12, 1925.
[2] Sever: Am. Jour. Orthop. Surg., August, 1916.
[3] Surg., Gynec. and Obst., January, 1917.

FIG. 447.—Congenital dislocation of the left humerus, illustrating the characteristic attitude.

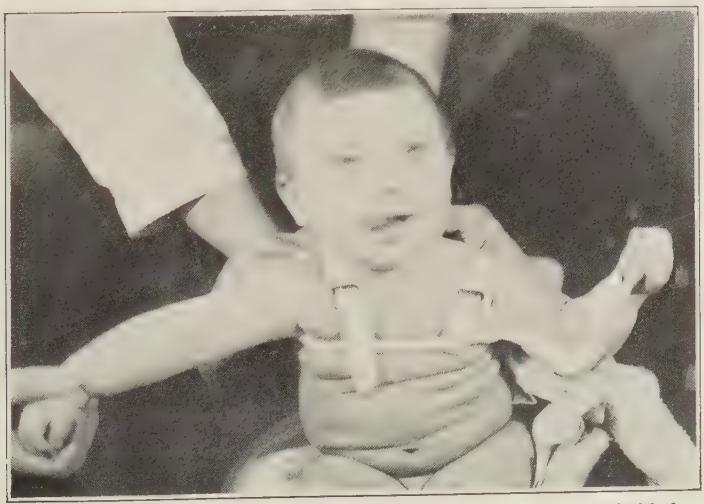

FIG. 448.—Wire splint used in the treatment of obstetrical paralysis to hold the arm in abduction and outward rotation and the forearm in supination.

months. As a rule traces of the injury are evident in atrophy of muscles, particularly of the deltoid and of the supra- and infraspinatus group, and a certain weakness of the arm persists, even though no actual paralysis remains.

In many instances recovery is but partial, the arm is weak, certain muscles are paralyzed, and there is much restriction of movement at the shoulder. The growth of the member is retarded; the upper extremity of the humerus is atrophied; the acromion process may be bent downward; the coracoid distorted in accommodation to the deformity and, as has been mentioned, the attitude is that characteristic of posterior dislocation. Not infrequently, although the actual paralysis is slight, the disability is extreme because of the displacement which restricts movement and causes noticeable deformity. The first indication in treatment, therefore, is to replace the head of the humerus in the proper position and to overcome all restriction to normal motion. This applies to the congenital as well as to the acquired disability.

FIG. 449.—Rear view.

Reduction of Deformity.—The principles of the treatment of the displaced humerus are to reduce the deformity, to fix the part for a time sufficient to prevent relapse, to restore function so far as may be by systematic passive motion, and by exercise. The method employed by the author with success is somewhat similar to the Lorenz treatment of congenital dislocation at the hip.[1]

The child having been anesthetized, is brought to the edge of the table. The shoulder is grasped firmly with one hand in order to restrain the movements of the scapula, and with the other the arm is drawn upward and backward over the fulcrum of the thumb, which lies behind the joint. This, the so-called pump-handle movement, alternately relaxing and stretching the contracted parts, is carried out over and over again with slowly increasing force, the aim being to force the head

[1] Whitman: Jour. Ment. and Nerv. Dis., 1904; Ann. Surg., July, 1905.

of the bone forward, and thus to thoroughly stretch the anterior part of the capsule. When this has been accomplished there is a distinct depression behind, and the head of the humerus projects in front, at a point below its proper position.

One then attempts to overcome the abduction and to force the head upward by changing the grasp on the scapula and using the thumb in the axilla as a fulcrum. When the arm can be carried across the chest to the normal degree of adduction, the final and often most difficult part of the process, namely, to stretch the tissues sufficiently

FIG. 450.—The characteristic attitude of inward rotation and pronation in obstetrical paralysis in infancy.

FIG. 451.—Typical subluxation at the shoulder secondary to obstetrical paralysis. The patient was treated successfully by the method described.

to permit the proper degree of outward rotation, is undertaken. This is best accomplished by flexing the forearm and using this to exert leverage on the humerus, care being taken, of course, to avoid the danger of fracture. When the head of the bone has been replaced, it will be noted that the tension on the anterior tissues causes flexion of the forearm; this must be overcome in the same manner, and, finally, the limitation to complete supination. The extremity is then fixed in the overcorrected attitude by means of a plaster support which includes the thorax. That is, the arm is drawn backward so that

the head of the humerus is made prominent anteriorly, the forearm is flexed and turned outward to the frontal plane, while the hand is placed in extreme supination, the upper arm lying against the lateral thoracic wall.

In the very resistant cases it is impracticable to complete the operation at one sitting. When, therefore, as much force has been exercised as seems wise, a plaster bandage is applied to hold the arm in an intermediate position with the head of the humerus forced forward, and after an interval of two or more weeks the further correction is undertaken. In the treatment of older subjects the forcible manipulation may be preceded or supplemented by division of resistant parts.

FIG. 452.—The deformity of obstetrical paralysis in adolescence.

As has been stated, when the head of the bone is forced forward a distinct depression and evident relaxation of the tissues is noted on the posterior aspect of the joint. The object of the fixation is to permit the contraction of the posterior wall of the capsule and the obliteration of the old articulation, consequently the part must be fixed for a period of at least three months. When the plaster support is removed, the after-treatment is of great importance. This consists of

MEDICAL LIBRARY
BOSTON CITY HOSPITAL

daily passive forcible movements to the extreme limits in the directions formerly restricted, namely, outward rotation, backward extension, and eventually abduction of the humerus and supination and extension of the forearm. For in all these cases there is a strong tendency to a relapse in some degree to the original posture. When motion has become fairly free, the disabled member must be regularly exercised and reëducated in functional use. Under this treatment the weakened and almost completely atrophied muscles usually gain surprisingly in power and ability, and the longer it is continued the better will be the final result. Even if the muscles about the shoulder are paralyzed the ability and appearance of the arm are greatly improved by the reduction of the deformity.

FIG. 453.—The shoulder spica as applied after the reduction of the deformity of obstetrical paralysis showing the palm of the hand directed backward, indicating the overcorrection of inward rotation and pronation. At the next dressing the arm will be brought to the side of the trunk with the forearm turned outward to a right angle.

If the contractions are more resistant an open operation is indicated as modified by Sever from that of Fairbank.[1] An incision is made between the deltoid and the pectoralis major. The tendon of the latter is divided and further outward rotation brings the insertion of the subscapularis lying upon the joint capsule into view. When this is cut the resistance to outward rotation may be easily overcome by manipulation. Deformity of the acromion, if it interferes with the

[1] Am. Jour. Orthop. Surg., August 5, 1916.

downward movement of the humerus, may be corrected by osteotomy. The arm is then fixed in plaster or splint in the manner described. Division of muscles that induce deformity, in this as in other paralytic disabilities enables one to completely reduce the deformity, lessens the tendency to recurrence and makes the subsequent functional training easier. The operation is therefore indicated in resistant cures and in older subjects. The opportunity for muscle transplantation is very limited. In cases of resistant pronation the pronator radii teres may be transplanted and attached to the tendons of the extensor carpi radialis longus and brevis to correct pronation and to reënforce the dorsiflexors. In intractable cases, persistent inward rotation may be corrected by osteotomy of the humerus.

FIG. 454.—Skin incision and isolation of pectoralis major. Cephalic vein at outer edge of pectoral. Arm abducted and rotated out. (J. W. Sever.) (Jones and Lovett.)

FIG. 455.—Sound under subscapular tendon. The pectoralis major has been divided. The joint capsule shows at bottom of cavity. (J. W. Sever.) (Jones and Lovett.)

Repair of Obstetrical Injury to the Brachial Plexus.—It is evident that if repair of the ruptured or otherwise injured cords of the brachial plexus does not take place, recovery is impossible. If in spite of protection in the manner described, there is no evidence of returning power in the muscles after a period of three months, particularly in those cases in which the muscles of the forearm are involved, an exploratory operation is indicated.

Kennedy[1] has operated on a number of cases for this purpose, in one instance as early as two months after birth, and a large number of cases in early infancy have been operated on recently by William Sharpe.

[1] British Med. Jour., 1903, p. 298.

Kennedy's method as modified slightly by A. S. Taylor[1] is described by the latter as follows:

"The patient is anesthetized and brought to the table with the field prepared for operation. A firm cushion is placed beneath the shoulders, the neck is moderately extended and the face turned to the sound side. The incision passes from the base of the sternomastoid muscle backward and slightly upward, following the fold of the skin to the anterior border of the trapezius. After the skin, platysma and deep fascia are divided, the omohyoid muscle is exposed near the clavicle, and lying beneath it are the suprascapular vessels. These structures may be retracted downward, or, if the case requires the extra room the omohyoid may be divided, and then the vessels cut between double

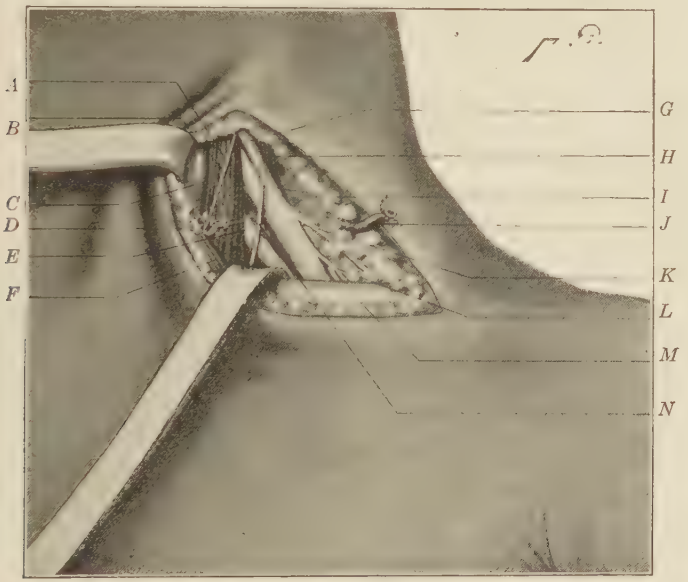

FIG. 456.—Operation for relief of brachial paralysis. (Taylor.) *A*, scalenus anticus muscles. *B*, phrenic nerve. *C*, internal jugular vein. *D*, transversalis colli artery. *E*, seventh root. *F*, omohyoid muscle. *G*, fifth root. *H*, scalenus medius muscle. *I*, sixth root. *J*, transversalis colli artery. *K*, suprascapular nerve. *L*, external anterior thoracic nerve. *M*, clavicle. *N*, nerve to subclavius. The incision now follows the fold of the neck across the posterior triangle as described in the text.

ligatures. The transversalis colli vessels are seen a little below the middle of the wound and are divided between double ligatures.

"The dissection is rapidly carried through the fat layer to the deep cervical fascia covering the brachial plexus, which fascia is usually thickened and adherent to the damaged nerve roots. This fascia is divided in the line of the original incision and is dissected away for the free exposure of the nerves (Fig. 456). The damaged nerves are

[1] Jour. Am. Med. Assn., vol. 48, No. 2.

usually noticeably thickened and of greater density than normal nerves. The extent and distribution of the paralysis, determined before operation, gives the clue as to which nerves are at fault. Usually the junction of the fifth and sixth roots is the site of maximum damage. The thickened indurated areas are determined by palpation and are excised by means of a sharp scalpel. Scissors should never be used for this work.

"The nerve ends are brought into apposition by lateral sutures of fine silk involving the nerve sheaths only, while the neck and shoulder are approximated to prevent tension on the sutures. Cargile membrane is wrapped about the anastomosis to prevent connective-tissue ingrowth. The omohyoid muscle, if divided, is sutured. The wound is closed with silk. A firm sterile dressing is applied, and a bandage is applied to approximate head and shoulder so as to prevent tension on the nerve sutures. This position must be maintained for at least three weeks. The most feasible method of accomplishing this result is a plaster-of-Paris support placed on the child and allowed to harden in the proper position before operation. It is then trimmed and removed. When the nerve suturing is finished the splint is slipped on, the wound is then closed, the dressings applied, and the child put to bed without danger of pulling the nerve ends apart.

"It will be noticed (Fig. 456) that the tissues to be excised lie in close proximity to the phrenic nerve and internal jugular vein, and to the junction of the cervical sympathetic communications with the spinal nerve roots. The suprascapular nerve comes off from the junction of the fifth and sixth cervical nerve roots, which as already stated, is usually the site of maximum damage. This nerve is very small in children, but it should be sutured with the greatest care, since it innervates the external rotators of the humerus, the paralysis of which permits the posterior dislocation of the shoulder often seen in the older cases."

Operations on the plexus of somewhat doubtful utility at best can have no influence on the disability unless distortions and contractions have been previously overcome in the manner already described.

RECURRENT DISLOCATION OF THE SHOULDER.

Recurrent dislocation of the shoulder is in most instances a sequel of traumatic dislocation. The cause of the instability is usually laxity of the capsular ligament and weakness of the supporting muscles, the result, it may be, of too early use of the arm after the accident. As a consequence of the weakness of the supra- and infraspinatus muscles the head of the femur is habitually lower than normal and the contraction of the pectoralis major, teres minor, and latissimus dorsi tends to displace it downward and forward. In rare instances greater derangement of the joint caused by fracture of one or other of the articulating surfaces, rupture or displacement of ligaments or muscles, or permanent paralysis of the deltoid muscle may be present.

The displacement, which may be partial or complete, recurs at intervals and is a very serious disability.

Treatment.—If the patient is seen immediately after a displacement and if the dislocation has recurred but a few times and at long intervals, it may be inferred that the disability is the result of simple laxity of the capsule and of muscular weakness. In such cases a period of fixation followed by massage and exercise of the atrophied muscles may result in cure. The patient should be carefully questioned as to

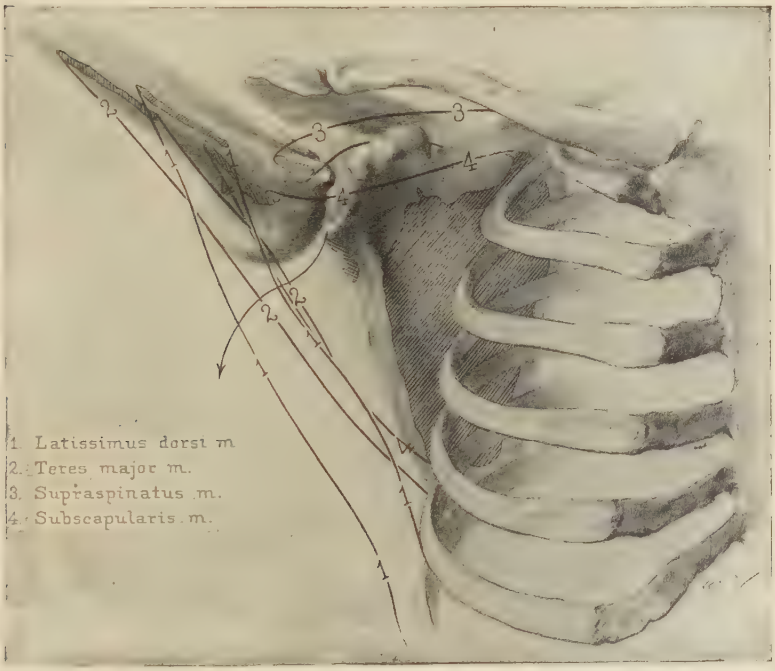

FIG. 457.—Action of muscles about the shoulder; the deltoid and the supraspinatus abduct the arm and support it; the adductors are the pectoralis major and latissimus dorsi; the subscapularis is the chief inward rotator; the chief outward rotator is the infraspinatus; the subscapularis with the minor scapular muscles oppose forward displacement when the limb is abducted. Anterior view of shoulder-joint with origin and attachment of muscles concerned in the dislocation. (Henderson.)

the particular movements of the arm that are likely to cause the displacement, which is, as a rule, forward beneath the coracoid process. Most often elevation and forward inclination, as in reaching for an object above the head, seem to be the predisposing movements that should be restrained. A simple and often an effective means of treatment is the application of a shoulder-cap of canvas that fits closely about the shoulder and upper arm. This is held in place by bands crossing the body and buckled beneath the other arm; from the lower border of the cap one or more bands pass downward and are attached

with the braces to the trousers, so that elevation of the arm is restrained before the point of instability is reached.

Operative.—If these milder measures are ineffective, an operation to reduce the size of the lax capsule may be performed. The arm being slightly abducted, an incision is made from the coracoid process downward and outward along the line of the cephalic vein to a point below the upper border of the tendinous insertion of the pectoralis major. The deltoid and the pectoralis major are separated, exposing in the upper border of the wound the coracobrachialis, and in the lower angle the upper part of the insertion of the pectoralis major muscles. The upper three-fourths of this insertion is divided in order to expose the head and neck of the bone. The humerus is then rotated outward and a portion of the insertion of the subscapularis muscle, stretched over the head of the humerus, is divided. The capsule is thus laid bare. It is incised and overlapped to the required degree by mattress sutures.

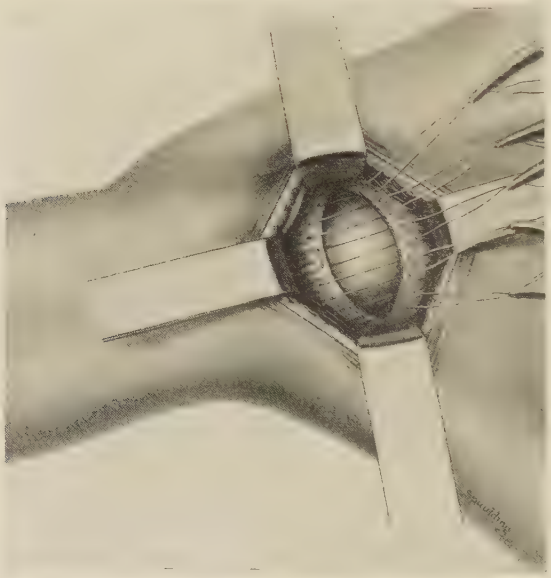

FIG. 458.—The Thomas method. (MacAusland.)

T. T. Thomas, the arm being abducted, makes an incision in the axilla, just posterior to the axillary vessels. This leads directly to the thin part of the capsule. The only important structure is the circumflex nerve, which passes about the head of the humerus. This must be identified and retracted upward. A cross-section of capsule is then removed and sutures are applied in the usual manner.

Sever[1] thinks that the action of the pectoralis major is the active agent of displacement and laxity of the subscapularis, the predisposing

[1] Jour. Am. Med. Assn., April 21, 1921.

cause. He therefore would divide the tendon of the former and shorten that of the latter in addition to the capsule operation.



FIG. 459.—Capsule, showing overlapping (capsulorrhaphy), with four doubled chromic catgut sutures in place.[1]

Quilting the weakened capsule with strips of fascia from the thigh offers more permanent resistance to redisplacement than simple suture. Girgolaff[2] bores a hole in the humerus just below the capsular insertion. Through this he passes a wide band of fascia, crosses it as shown in Fig. 460 and attaches one end to the acromion and the other to the coracoid process.

One of the simplest and most effective operations is that devised by Dr. Nikola of the staff of the Hospital for Ruptured and Crippled by utilizing the long head of the biceps as a ligament. It is described by him as follows:[3]

1. An incision above the coracoid process downward on the border of the deltoid muscle.

2. The upper and anterior fibers of the deltoid muscle are divided close to the clavicle and, if more exposure is necessary, more of the clavicular portion of the deltoid muscle may be stripped subperiosteally.

3. The pectoralis major and cephalic vein are retracted inward, and the deltoid outward.

[1] Henderson: Surg., Gynec. and Obst., May, 1921.
[2] Centralbl. f. Chir., January 16, 1926.
[3] Jour. Bone and Joint Surg., January, 1929.

4. The tendon of the long head of the biceps is exposed up to its origin. To do this, it is necessary to divide the transverse humeral ligament which holds the tendon in the bicipital groove and to split open the capsule in the line of the fibers continuous with the transverse humeral ligament. The bicipital branch of the anterior circumflex artery accompanies the tendon in the bicipital groove.

5. The tendon of the long head of the biceps is divided about 1 inch below the cut margin of the transverse humeral ligament, after placing stay sutures of black silk in the proximal and distal parts, so that the ends may be under control. The elbow is flexed at about 45 degrees during this step and the rest of the operation.

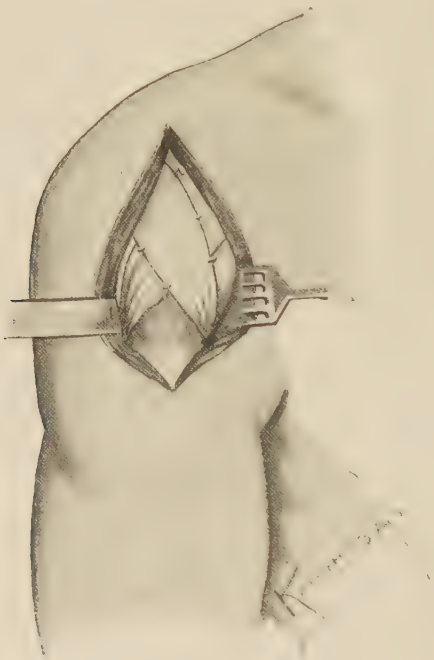

FIG. 460.—Girgolaff's method.

6. A hole is drilled through the head of the humerus beginning just below the transverse humeral ligament, using a $\frac{1}{4}$-inch drill. This should be so directed that it comes out at about the center of the articular surface of the head.

7. A probe or flexible aneurysm needle is passed through the tunnel and the arm rotated out so that it is easier to thread the probe. Next the probe is threaded and the tendon pulled through tunnel and united with the distal part, using black silk (see Fig. 460).

8. Tension is made on the proximal part and sutures made through tendon and periosteum near the bicipital groove so as to fix the tendon and remove tension on the newly sutured section.

MEDICAL LIBRARY
BOSTON

9. The transverse humeral ligament and capsule are sewed with a continuous No. 1 plain catgut; the cut part of the deltoid with a few mattress sutures; the skin with No. 1 plain catgut.

10. The shoulder is put up in simple Velpeau bandage, reënforced with adhesive plaster, with arm close to chest and elbow flexed to 45 degrees, and is kept up for three weeks.[1]

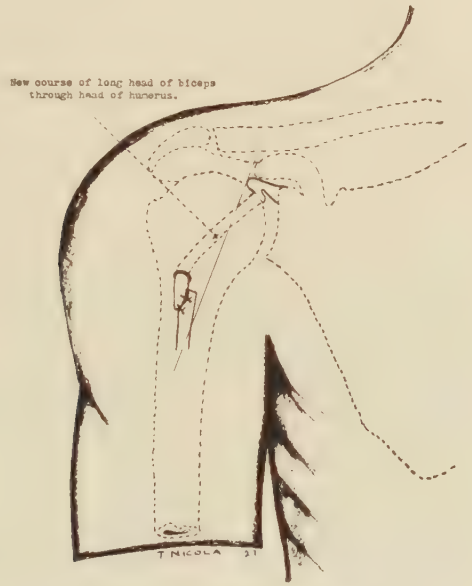

FIG. 461.—Nicola's operation.

In advanced cases in which the relaxation of the supporting muscles is evidently the predisposing cause the Clairmont operation[2] may be of service. This consists essentially in separating the posterior quarter of the deltoid muscle from its insertion, passing it forward under the humerus and attaching its extremity to the anterior border of the deltoid as near the coracoid process as possible, so that it may form a sling beneath the head which becomes tense when the arm is abducted. In the operation the first incision is made downward along the anterior border of the deltoid and the quadrilateral space through which the muscle flap is to be passed is enlarged by dividing the upper borders of the tendons of the latissimus dorsi and teres major muscles. The anterior circumflex artery is exposed in the upper border of the wound. The flap of deltoid is made through a posterior incision, and its base being about one and half inches wide. It is separated with its periosteal insertion from the shaft and split upward until the circumflex nerve is encountered.

[1] It may be noted that Durante, a Polish surgeon devised a somewhat similar operation in 1927 by transplanting the long head of the biceps to the acromion process.

[2] Archiv. f. klin. Chir., 1909, vol. **89**.

Ollerenshaw[1] sutures the anterior extremity of the muscle flap to the anterior border of the subscapularis and tendon. The various incisions are closed and after repair appropriate exercises are begun. Operations of this type are indicated only in obstinate cases.

CONGENITAL DEFORMITIES OF THE ELBOW.

Congenital displacement of the ulna is one of the rarest of deformities. The displacement is usually incomplete, and it is associated with laxity of the ligaments.

Congenital displacement of the radius is much more common, 53 cases having been reported.[2]

In many instances the head of the radius is displaced backward; thus the forearm is pronated and extension is usually limited. Removal of the head of the radius and forcible correction are usually indicated.

FIG. 462.—Bilateral congenital pronation of the forearms.

CONGENITAL PRONATION OF THE FOREARM.

This deformity is usually bilateral and there is in most instances a fusion of the upper extremities of the radius and ulna, usually to the

[1] Jour. of Orth. Surg., May, 1920.

[2] Blodgett: Am. Jour. Orthop. Surg., January, 1906.

extent of about 2 inches (Fig. 462), the radius being twisted in adaptation to the attitude.

The deformity is often hereditary and it is twice as common in males as females. The patient may be unconscious of the defect until his attention is called to it. Of 141 cases reported 85 were bilateral.[1] There are two main types, one in which the head of the radius is absent and the two bones completely fused; the other in which the radial head is displaced toward the flexor side of the arm.

Treatment.—The bones may be cut apart with a chisel and separated by the insertion of a flap of fibromuscular or transplanted fascia. If the head of the radius alone is fixed it may be removed or a section of bone may be removed below the point of union. The attitude may be improved by operative treatment and in favorable cases some motion may be regained.[2]

CUBITUS VALGUS—CUBITUS VARUS.

Cubitus valgus, in which the forearm is abducted at the elbow, and cubitus varus, in which it is inclined in the other direction, are occasionally seen as congenital deformities. They are, in most instances, associated with laxity of the ligaments.

Similar deformities are not uncommon during the progressive stage of rhachitis, but they usually disappear after the erect attitude is assumed.

The supinated forearm forms an angle with the upper arm, opening outward when the limb is extended at about 173 degrees in males and 167 degrees in females.[3] This is called the "carrying" angle, because the hand is held at some distance from the body while the arm is in contact with the trunk. The angle is caused by the obliquity of the plane of the elbow-joint, and it is not apparent when the forearm is pronated. What may be called normal cubitus valgus is common among women, and in certain instances it may be exaggerated to deformity. Acquired cubitus varus is usually the result of direct injury. Both deformities may be treated by osteotomy of the humerus just above the articulation after the method used to correct similar deformity at the knee. If in addition to the lateral deformity motion is restricted by displaced fragments of bone or by exuberant callus it is advisable to open the joint for the direct correction of lateral deformity. The arm should be fixed in full extension and supination by a shoulder spica plaster bandage, the limb being elevated. Thus the danger of swelling and constriction, almost inevitable if the limb is pendent, may be avoided (Fig. 463). Cubitus valgus caused by fracture and displacement of the external condyle is a common cause of late ulnar paralysis which may not appear until several years after the

[1] Mouchet and Lélue: Rev. de Orthop., September, 1925.
[2] Tomesku: Zeit. f. Orth. Surg., 1927, vol. 48.
[3] Whitman: Annals of Surgery, May, 1908.

injury. This is caused apparently by tension on the nerve, and may be relieved either by correction of the lateral deformity or by transplantation of the nerve to the anterior aspect of the joint.[1]

In a series of 97 dislocations at the elbow there was an accompanying paralysis of the ulnar nerve in 13 cases, of the median in 1, and of the musculospiral in 2.[2]

FIG. 463.—The shoulder spica. This support is used after correction of lateral deformity at the elbow and in the treatment of fractures with lateral distortion. The same support is used in the treatment of epiphyseal fracture at the shoulder, the fragments being held in apposition after reduction by fixing the humerus in a nearly perpendicular attitude with forward inclination. The arm may be fixed by this appliance in any relation to the trunk, the forearm flexed, pronated or supinated, according to the indications.[3]

SUBLUXATION OF THE WRIST.

A peculiar displacement of the hand forward and usually toward the radial side, first noted by Begin in 1825 and again by Dupuytren in 1834, was described at length by Madelung[4] as "spontaneous subluxation." In these cases the radius is curved forward at its lower extremity, the ulna projects on the dorsal surface and there is abnormal

[1] Platt: Brit. Jour. Surg., January, 1926.

[2] R. Watson Jones: Journal of Bone and Joint Surg., January, 1930.

[3] Potter: Jour. Anat. and Phys., vol. **29**, 488. Hubscher: Deutsch. Ztschr. f. Chir., vol. **53**.

[4] Arch. f. klin. Chir., vol. **23**.

separation of the bones of the forearm from one another at the wrist. As a consequence the wrist is enlarged, the ligaments are relaxed, dorsal flexion of the hand is restricted, and, if the deformity is extreme, pronation and supination also. Destot suggests the term curved radius as more properly descriptive of the affection, as there is no subluxation except in extreme cases. The deformity was bilateral in about half the cases, 100 of which, together with dissections, have been tabulated by Pilatte.[1] The symptoms, aside from the deformity and limitation of motion, are weakness and sensations of discomfort about the dorsum of the wrist.

Etiology.—The deformity most often develops in later childhood and adolescence. The predisposing causes of the affection are, apparently, relaxation of the ligaments, adolescent weakness, and, probably, slight preëxisting rhachitic deformity of the same character. The exciting causes are occupation and injury.



FIG. 464.—"Spontaneous subluxation of the wrist."

Treatment.– The treatment is rest, massage, forcible manipulation in the direction of extension, and a support of leather or other material to hold the hand in the extended position. In well-marked cases the deformity of the radius should be corrected by osteotomy. Deformities of the hand due to overgrowth of one or other of the bones of the forearm or to loss of growth caused by disease or operative treatment are occasionally seen. Radical operations in early life which involve removal of growing bone should always be avoided.

SUBLUXATION OF THE RADIUS.

This is most common in early childhood caused by forcible traction on the arm. The symptoms are persistent pronation and restriction of flexion.

The subluxation may be reduced by forced supination and flexion as indicated in some instances by an audible snap. In older subjects an open operation and repair of the orbicular ligament may be required. Resection of the displaced head causes but little disability.

[1] Thèse de Paris, 1919.

CONGENITAL DEFORMITIES AT THE WRIST.

Simple congenital dislocation at the wrist is extremely rare. Displacement of the wrist and hand is usually associated with defective development of the bones of the arm, and the deformity is usually classed as club-hand.

FIG. 465.—Club-hands and club-feet.

CLUB-HAND.

Congenital distortions of the hand may be divided into four primary varieties, according to the direction in which the hand is turned, viz.:

1. Forward or palmar.
2. Backward or dorsal.
3. Lateral to the radial side—radial.
4. Lateral to the ulnar side—ulnar.

Lateral and anteroposterior distortions occur also in combination.

Etiology.—There are two distinct varieties of club-hand:

1. In which there is simple distortion caused apparently by intrauterine restraint and pressure. In certain cases of this class there may be limited motion at both the shoulder- and elbow-joints and defective muscular development.

2. In which the deformity is associated with defective development of the radius or ulna and often with congenital abnormalities of other parts.

In the palmar and dorsal distortions the bones of the arm are usually normal. The lateral deviations of the hand are often complicated by

defective formation of the radius or ulna, and as in talipes due to absence of the tibia or fibula the hand may be malformed also.

Deficient formation of the radius with corresponding distortion is the most common. Of this 114 cases are recorded. In 56 cases it is stated that the deformity was unilateral, in 46 bilateral. In 44 cases the radius was absent; in 12 cases a part was present; 60 per cent. of the patients were males.[1]

Fig. 466.—Congenital absence of radius and the bones of the thumb. (Weigel.)

The most important form of club-hand is, then, that due to absence or to defective formation of the radius. As in talipes valgus due to absence of the fibula, the tibia is short and often bent sharply forward, so in this form of club-hand the ulna is usually short and bent inward. The hand may be perfect in formation, but, as a rule, the thumb is absent or rudimentary, and other adjoining bones, together with the corresponding ligaments and muscles, may be absent also[2] (Fig. 466).

The hand occupies practically a right-angled relation to the ulna, and as this bone is usually bent inward as well, the direction of the hand is often reversed and is parallel to the forearm. As a rule the hand is also somewhat bent forward, so that the deformity might be described as radiopalmar (Fig. 467).

Treatment.—In those forms of club-hand in which the structure is normal the deformity may be overcome, as a rule, by manipulation, and support by the plaster bandage or otherwise, as described in the treatment of talipes. Massage and muscle training are required in the

[1] Antonelli: Ztschr. f. orthop. Chir., 1905, vol. **14.**

[2] Stoffel u. Stempel: Ztschr. f. orthop. Chir., 1909, **23**, Heft 1 und 2.

after-treatment. If the deformity is complicated by defective muscular development and limited joint motion, massage and passive manipulation may be required for years. Complete recovery is unusual.

Fig. 467.—Congenital club-hands, showing the short and deformed forearms, also genu varum. (Gibney.)

In slighter cases of radial club-hand, due to defective development, it may be possible by manipulation and tenotomy to replace the hand in its normal position, but this is unusual. After division of the contracted tissues, Sayre[1] removed a portion of the carpus and implanted the head of the ulna at the point of resection. McCurdy[2] sawed through the ulna, leaving the extremity in relation to the carpus and sutured the proximal fragment and the semilunar bone to one another. Thomson[3] replaced the hand by subcutaneous tenotomy and by the removal of a cuneiform section of bone from the lower end of the ulna.

The operation of splitting the ulna into an ulna and radial portion and implanting the carpus between the two has been performed by Bardenheuer.[4] Albee[5] has inserted a bone graft extending from the radial side of the carpus to the lower third of the ulnar. Subsequently the bowing of the ulnar was corrected by osteotomy. The results were very satisfactory. The immediate effect of the various operative procedures was favorable, but no final results have been reported.

In any event some form of apparatus must be used during childhood at least, to support the hand, whether the operation has been successful or not. It is therefore better to defer radical treatment. At best the arm will be short and the defective hand will be weak as compared with the normal.

CONTRACTIONS AND DISTORTIONS OF THE FINGERS.

Congenital Contraction of the Fingers.—The most common form of congenital contraction and one that is sometimes hereditary is that

[1] Tr. Am. Orthop. Assn., vol. **6.** [2] Ibid., vol. **8.** [3] Ibid., vol. **9.**
[4] Verhand. der deutsch. Gesell. f. Chir., 1894, 23 Kong.
[5] Ann. Surg., January, 1928.

MEDICAL LIBRARY POST

of the little finger (hammer-finger) of one or both hands. This is semi-flexed and extension is checked by what appears to be a congenital shortening of all the soft parts on the flexor side. In other instances several fingers may be similarly affected.

Treatment.—If treatment by manipulation and splinting is begun early the deformity may be overcome by lengthening the contracted tissue. In later life the prospect of perfect cure by any method of treatment is slight, because of the strong tendency to recontraction after the finger has been straightened.

Webbed Fingers.—In the most common form of this deformity two or more fingers are joined by skin and fibrous tissue to the first phalangeal joints, but sometimes throughout the entire length of the fingers. In other instances the web may be thicker, containing muscular fibers from the apposed parts, and, occasionally, the bones of the two fingers may be joined to one another, even to the finger-nails.

Etiology.—The cause of the deformity is arrest of development before the fingers have been separated from one another; thus the thumb, which is differentiated from the other parts of the hand as early as the seventy-fifth day of intra-uterine life, is rarely involved, as compared with the fingers, which are separated from one another at a later period.

Treatment. -In all but the extreme grades of deformity the fingers may be separated from one another, operative treatment being conducted according to the rules of plastic surgery.

Congenital Displacements of the Phalanges and Distortions of the Fingers.—These deformities are not particularly uncommon. They should be treated by manipulation and by splinting at as early a period as is practicable. Other congenital deformities and malformations of the hand do not call for extended comment.

Trigger-finger. —Synonyms. —Jerking finger, snapping finger.

This affection was first described by Nélaton under the title "Doigt à Ressort." On extending the closed hand one finger remains flexed. If the flexion is overcome by greater muscular effort or by passive force the finger flies back to complete extension with a sudden snap or jerk; hence the name. In well-marked cases the same difficulty and the subsequent snap occur on flexing the finger. The middle and ring fingers are more often affected, but sometimes the thumb or the other fingers may be involved.

The patient usually complains somewhat of stiffness and pain in the finger, but the functional disability is the principal symptom.

Etiology.—The cause of the disability is interference with the motion of the tendon in its fibrous sheath, either because of a reduction of its caliber due to injury or inflammation, or to an enlargement or irregularity of the tendon itself. In most instances the obstruction appears to be in the neighborhood of the metatarso-phalangeal joint.[1]

The duration of the affection is indefinite.

[1] Marches: Deutsch. Ztschr. f. Chir., vol. **79**, 364.

Treatment.—If the obstruction appears to be of inflammatory or traumatic origin it may be treated by splinting and later by massage. In confirmed cases the sheath should be opened to remove the obstruction. As a rule it is only necessary to split the sheath to assure relief.

The bibliography is large; the more recent articles are those of Poulsen,[1] who reports 64 cases, and Hauck.[2]

Stenosing fibrous tenovaginitis at the styloid process of the radius was first described by Quevain in 1895: It is characterized by a sensitive point and slight swelling over the styloid process and by discomfort whenever the hand is turned toward the ulnar side. It involves the common sheath of the extensor longus and brevis pollicis, as it passes over the radius beneath the dorsal ligament. It is far more common in females than in males. Immediate relief follows the splitting of the thickened sheath.

Snapping Thumb.—This is not infrequently seen in infancy and is of the nature of a trigger finger. It may be cured in most instances by splinting.

Cases of snapping wrist have been reported caused by subluxation of the semilunar on the os magnum.

Ganglion.[3]—A ganglion is a cystic swelling about a joint or tendon sheath. The dorsal surface of wrist is the seat of election. It is more common in females than males. The ganglion is usually attached to the capsule of the joint or to a tendon sheath, but does not communicate with the interior. There are usually several cystic divisions of the tumor containing a gelatinous mucoid fluid.

The symptoms are the tumor and usually some discomfort on certain movement of the hand.

Treatment.—Spontaneous disappearance sometimes occurs. Rupture followed by pressure is often effective. Careful operative dissection is indicated in cases of the resistant type and for those connected with the tendon sheaths.

Mallet-finger.—Synonym.—Drop-finger.

This is caused usually by a blow upon the terminal phalanx, which ruptures or weakens the attachment of the extensor tendon at the base of the phalanx so that it is habitually flexed sometimes nearly to a right angle.

The treatment of confirmed cases must be by incision and reattachment of the tendon to the periosteum.

"Baseball-finger" is the reverse displacement of the terminal phalanx, which is dislocated backward, forming a bayonet-like deformity. There is often, in addition, injury of the base of the phalanx that causes subsequent irregular hypertrophy.

If reposition is impossible open incision may be employed to correct the deformity.

[1] Arch. f. klin. Chir., vol. **94**, Heft 3.
[2] Ibid., 1923, vol. **123**.
[3] Carp and Stout: Bull. New York Academy of Medicine, May, 1928.

Dupuytren's Contraction.—Dupuytren's contraction is a deformity of the hand caused by contraction of a part of the palmar fascia and of its prolongations to one or more of the fingers. The fingers are flexed as a consequence to a greater or less degree, and in advanced cases they may be drawn to close contact with the palm. The ring finger is most often primarily affected, but, as a rule, two or more fingers are somewhat involved in the contraction.

In a large proportion of the cases both hands are affected, but not as a rule simultaneously, the contraction beginning in the second hand several years after the deformity in the first. Right, 227; left, 108; both, 313; ring finger, 304; fifth finger, 238; medium, 114; index, 31; thumb, 23.

FIG. 468.—Lewin's splint for mallet-finger. Cut from thin metal and the bands closed about the finger.

The contraction is much more common in men than in women, males, 495; females, 78.[1] It is practically confined to middle and later life.

Etiology.—The etiology is uncertain. It is claimed that the deformity is more common among those who are subject to gout or rheumatism. It appears, also, to be an hereditary affection in certain instances. Krogius[2] records the case of a man with bilateral contraction, fifteen of whose descendants had the same deformity. He concludes that the palmar fascia was originally muscle and that the contraction begins in embryonic vestiges of that structure. Injury or irritation of the palmar tissues, incident to certain occupations, would seem to explain the disproportionate liability of the sexes to the affection.

Pathology.—The characteristics of the deformity are explained by the anatomy of the palmar fascia. This consists of a strong central portion, and two thinner lateral parts that cover the muscles of the thumb and little finger. It is made up of longitudinal fibers continuous with the tendon of the palmaris longus, and the annular ligaments. It divides into four processes that are attached to the digital sheaths, to the integument at the clefts of the fingers, and to the superficial transverse ligament. Prolongations of the fascia pass along the lateral

[1] Kanavel, Koch and Mason: Surg., Gynec. and Obst., February, 1929, vol. 15.
[2] Ztschr. f. Chir., July 24, 1920.

aspect of the fingers and are attached to the periosteum and to the tendon sheaths of the first and second phalanges.

The cause of the contraction appears to be a chronic plastic inflammation of a part of the fascia, which becomes hypertrophied and finally contracts, drawing the finger toward the palm in the manner described. The affection progresses, as a rule, very slowly but in rare instances the onset is more acute, attended by thickening and sensitiveness of the fascia.

Symptoms.—The first symptom is usually the deformity; the patient finds it impossible to completely extend one or more of the fingers; the tissues about the base of the finger seem stiff, and when it is forcibly extended a hard, elevated cord may be felt extending from about the center of the palm to the second phalanx, most prominent at the metacarpo-phalangeal articulation.

To this the skin is adherent, and as the contraction increases it is thrown into elevated ridges. Later other bands appear if the contraction affects, as it usually does, other portions of the fascia. In many instances no pain is experienced unless the contracted fascia is forcibly stretched or is pressed upon. In other cases complaint is made of neuralgic pain in the hand and even in the arm and back. Occasionally the first symptom to attract attention may be a sensitive nodule in the skin at the base of the finger.

The contraction usually increases slowly until the finger that is most affected is drawn to the palm.

Treatment.—When the contraction interferes with the function of the hand operation is indicated by removal of the contracted fascia, usually by long incisions over the prominent bands. The skin is carefully separated from the adherent fascia which, with its lateral prolongations to the joints, is dissected from the underlying parts. Gill removes the fascia by an incision following the central palmar fold and inserts a free flap of fat and fascia between the skin and the tendons.

In severe cases several incisions are required. The wounds are sutured and the hand and fingers are supported on a splint in a slightly flexed position in order that the circulation may not be restricted. Later massage and stretching will complete the cure.

ISCHEMIC PARALYSIS AND CONTRACTION.[1]

Paralysis and contraction may follow prolonged constriction. This is most often seen in the forearm and hand in young subjects, as a result of treatment for fracture about the elbow.

Symptoms.—The prodromal symptoms are pain, swelling, discoloration, loss of sensation and finally of motion. It is estimated that moderate constriction for six hours may cause paralysis which, in cases of the milder type, is limited to the extensor group. The sequence of the etiological factors following constriction are impairment of venous flow, extravasation of blood and serum, swelling and pressure on bloodvessels and nerves. Thus, as an immediate treatment free incision

[1] Volkmann: Centralbl. f. Chir., 1881, **8**, 801.

would seem to be indicated. In characteristic cases of contraction seen at later periods the hand is flexed on the forearm, and the fingers at the interphalangeal joints are contracted to a right-angular attitude. Extension is restrained by a resistant shortening of the tissues on the

FIG. 469.—Volkmann's ischemic paralysis. Finger splints applied. (Jones and Lovett.)

flexor aspect of the arm caused by fibrous degeneration of the muscles the result of traumatic myositis. The affected part is atrophied and cold. Sensation in the fingers is often diminished or lost as in about 60 per cent. of the cases, due probably to secondary involvement and constriction of the nerves.



FIG. 470.—Volkmann's ischemic paralysis with finger and flat splints applied. (Jones and Lovett.)



FIG. 471.—Volkmann's ischemic paralysis with finger and flat splints applied in hyperextension. (Jones and Lovett.)

Treatment.—Prevention.—The possibility of this complication should be borne in mind when treating fractures or correcting deformity at the elbow. The hand should be examined frequently and the patient should be instructed to move the fingers from time to time. Pain and swelling indicate the necessity for complete relief of constriction. Neglect of this precaution is indicated by the fact that in 37 of 107 cases there was sloughing of the tissues on the palmar side of the arm.

If paralysis is present the hand should be at once supported in hyperextension to prevent contraction. In most cases, however, confirmed deformity is already present when the patient is brought for treatment.

Corrective.—The most efficient method of treatment is that of gradual correction advocated by Jones. This is conducted methodically along the line of least resistance. It may be noted that although the fingers are rigidly contracted at the interphalangeal joints when the hand is extended, the contraction is lessened if the wrist is flexed. One begins, therefore, by flexing the hand on the forearm to relax the tension. Straight splints are then applied to the flexor side of the fingers and from day to day more pressure is applied until each finger is straightened. When this is accomplished a palmar splint of metal bent to fit the deformity is applied to the forearm and hand. This is gradually straightened to extend the splinted fingers on the hand. When these are hyperextended, one begins in the same manner to correct the flexion at the wrist until in successful cases after weeks or months, hyperextension at all the deformed joints has been accomplished. During the treatment the power in the extensor group increases and sensation improves. Massage, manipulation exercises and the like for an indefinite time are of course essential supplements to the correction of deformity.

Fig. 472.—Device for relief of writers' cramp. The model is obtained by holding a wet plaster bandage in the hand. It is copied in willow wood hollowed out in the center. The pen is then placed in the block, as illustrated. (Sayre.)

Operation.—If the contraction resists mechanical correction a long incision may be made in the contracted tissues in the forearm from which the adherent fascia is dissected. The shortened tendons are then lengthened, preferably at the junction with the muscular substance. Page and Bailey[1] employ a muscle sliding operation by separating the muscles from the internal condyle and the ulnar and displacing them downward. Shortening of the bones in adaptation to the contraction seems inadvisable.

[1] British Jour. Surg., October, 1928.

CHAPTER XIV.

CONGENITAL AND ACQUIRED AFFECTIONS LEADING TO GENERAL DISTORTIONS.

RHACHITIS.

Synonym.—Rickets.

Rhachitis is a constitutional disease of infancy caused by defective nutrition, of which the most noticeable effect is distortion of the bones,

Etiology.—The predisposing cause is constitutional weakness. This may be inherited or it may be the direct effect of illness, but most often it is the result of improper hygienic surroundings, particularly lack of sunlight, damp rooms, and overcrowding. The direct cause of the disease is defective assimilation. In most instances this is due to the substitution of artificial food for the mother's milk, in others to improper diet after the infant is weaned; in rare cases it may be the result of prolonged lactation, or it may be caused by the defective quality of the mother's milk. The disease, therefore, begins usually between the ages of six and eighteen months, although it is by no means confined to these limits. According to Baginsky the age of onset in 623 cases was as follows:

	Male.	Female.	Total.
3 to 6 months	35	8	43
6 to 12 months	101	72	173
1 to 1½ years	115	105	220
1½ to 2 years	64	49	113
2 to 2½ years	18	24	42
2½ to 3 years	9	12	21
3 to 4 years	2	5	7
4 to 13 years	4	0	4
	348	275	623

In most instances improper surroundings and improper nourishment are combined in the causation of the disease; thus rhachitis is relatively common in large cities. In New York the most extreme cases are observed among the Italian and the colored children. The former are usually nursed, but are improperly fed after weaning, while the latter, if nursed at all, are usually allowed a mixed diet even during the early months of life.

Pathology.—The manifestations of a disease induced by impaired nutrition are, of course, general in character. In rhachitis there is a mild degree of anemia, and general weakness and relaxation of the voluntary and involuntary muscles. As a result the circulation is impaired and the power of assimilation is diminished; thus congestion and enlargement of the internal organs, intestinal catarrh, bronchitis and the like are common accompaniments of the disease. The most

marked and characteristic changes are in the bones; these consist in a diminution of the earthy substances and in overgrowth of osteoid tissue.

"The essential features of the morbid processes are, first, an exaggeration of the processes immediately preparatory to the development of true bone; secondly, an imperfect conversion of this preparatory tissue into true bone; and thirdly, a great irregularity of the whole process." (Erichsen.)

On section of rhachitic bone it will be noted that the periosteum is increased in thickness, and is adherent to the underlying softened and spongy tissue. The medullary canal is enlarged, and its contents are abnormally vascular. The epiphyseal cartilage, normally a thin, bluish line, is much increased in thickness. It appears to be thickened and infiltrated, and it has lost its former translucency. Microscopic examination at this point, where growth is most active, shows marked irregularity in size and shape of the columns of cartilage cells;. the zone of calcification is lacking or is ill-defined, and masses of cartilage cells are found unchanged in what should be the area of true bone. The same irregularity of line and shape is observed in the medullary spaces of the newly formed osteoid tissue.

As a direct result of the changes that have been described, the epiphyseal junctions are enlarged and the shafts of the bones are thickened by the formation of osteoid tissue beneath the periosteum. The indirect effects of the disease, and of the weakness that it causes are deformities, the nature of which will be indicated under the heading of Symptoms. The stage of weakness is followed by that of repair, which sometimes goes on with great rapidity; the softened bones become abnormally hard, "eburnated," and premature ossification at the epiphyseal junctions may account in part for the dwarfing of the stature, observed as one of the final results of severe rhachitis.

Symptoms.—As the disease is the effect of imperfect assimilation its more pronounced symptoms are preceded by those of indigestion, such as flatulence, constipation and the like. Profuse perspiration, especially about the head, and restlessness at night are common symptoms. Teething is often delayed or is irregular. The infant is slow in its movements, and makes little effort to stand or to walk at the usual time, and if the disease is active the affected parts may be sensitive to pressure.

Deformities.—One of the earliest and most constant evidences of rhachitis is the enlargement about the epiphyseal junctions, an enlargement caused in part by the direct hypertrophy and in part by pressure upon the softened tissues. The enlargements at the junctions of the ribs and the costal cartilages, the *rhachitic rosary,* and at the wrists and ankles, *double joints,* are almost invariably present in well-marked cases. The more general distortions are in part the effect of atmospheric pressure, in part the effect of the force of gravity and habitual postures, and in some instances muscular action or injury may deform the softened bones. These deformities differ greatly according to the

MEDICAL LIBRARY
THE
555
BOSTON CITY HOSPITAL

time of onset of the disease, and with its duration and severity. The head may be oblong in shape, or rectangular, *caput quadratum*, and it sometimes presents prominences in the frontal and parietal regions due to thickening of the bone, and on the posterior aspect depressed and softened areas, *craniotabes*. The fontanelles are abnormally large, and they may remain open long after the usual time of closure.

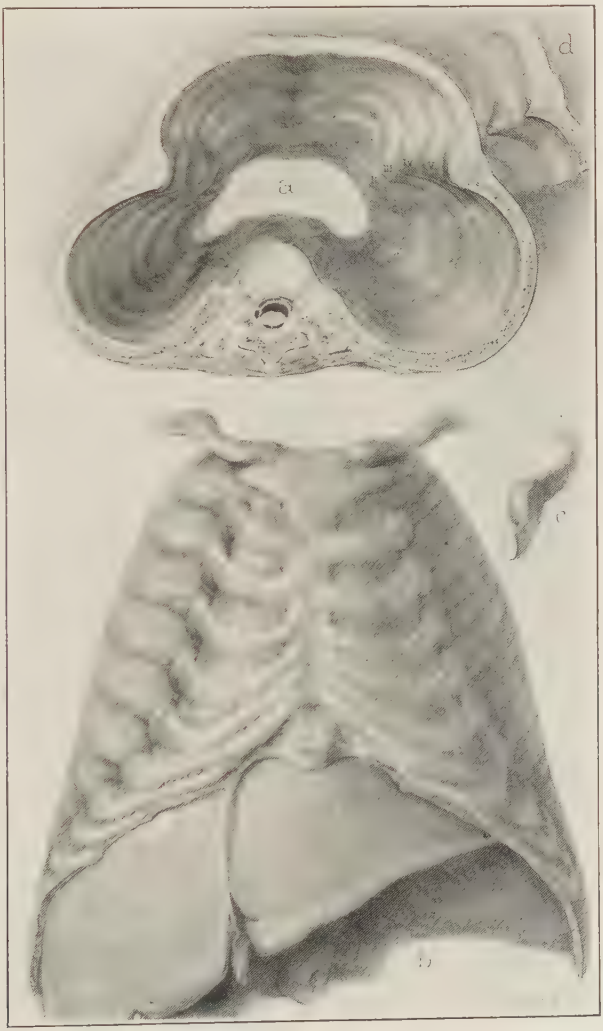

FIG. 473.—The rhachitic chest. (Howland)

The thorax is compressed from side to side, the compression being most marked in the middle region, where the ribs have the longest cartilages and the least direct support. The back is flattened and the sternum is thrust forward forming the *pigeon breast*. The lower ribs

are everted to accommodate the distended abdomen, *pot belly*. In well-marked cases the rhachitic chest presents two distinct grooves: one transverse in the axillary line, *Harrison's groove*, and the other passing upward by the side of the rhachitic rosary. The deformities of the trunk are in great degree caused by atmospheric pressure, but they are increased if the child assumes the sitting posture habitually. In this attitude the body is inclined forward, the clavicles are distorted, and the spine is bent into a more or less rigid posterior curve, most marked in the lower dorsal and lumbar regions, the *rhachitic kyphosis*. Less often there may be a lateral deviation or *scoliosis*.

FIG. 474.—General rhachitic deformities, showing distortions of the arms and legs induced by posture.

The arms may be distorted by the efforts of the child to support the body in the sitting posture, or by active exertion, as in creeping (Fig. 474). Occasionally the deformity may be localized at the elbow, and sufficiently marked to merit the name *cubitus varus* or *valgus*, corresponding to genu valgum or varum; or the principal distortion may be a dorsal convexity of the lower extremity of the radius.

Spindle-shaped phalanges are sometimes noted among the early signs of rhachitis in young children.[1]

The bones of the lower extremities are often distorted, primarily by the habitual postures assumed in sitting or creeping, occasionally

[1] Neurath: Wien. Klin., vol. 40, No. 1617.

exaggerated by green-stick fractures, and these deformities usually increase when the erect attitude is assumed. In some instances it would appear that the femoral necks are twisted backward somewhat; this distortion, induced apparently by the cross-legged attitude of sitting, may explain in part the limitation of inward rotation that is sometimes observed in rhachitic children. Depression of the femoral necks (coxa vara) may be present also, although this deformity does not, as a rule, attract attention until a much later period of life. The changes in the pelvis are of special interest to the obstetrician. These are essentially an increase in the sacro-vertebral prominence due to the forward and downward displacement of the sacrum, an abnormal expansion of the ilia, caused by pressure of the abdominal contents, and, in some instances, a decrease of the lateral diameter, an effect of the pressure of the femora upon the yielding bone.

Fig. 475. — Typical rhachitic deformities of mild degree.

In the milder type of rhachitis in older children who walk, the deformities are often confined to the trunk and lower extremities. In such cases, in addition to the changes in the bones, there is usually a prominent abdomen and increased lordosis, combined with slight habitual flexion at the hips and knees, the *rhachitic attitude.*

If the disease is severe and general in its manifestations it may be accompanied by pain, by sensitiveness of the affected bones, and by such weakness of the lower extremities as may simulate paralysis, *rhachitic pseudoparalysis.* It is probable, however, that the cases in which the pain is extreme, "acute rhachitis," are, in reality, scurvy or scurvy and rhachitis combined, scurvy rickets so-called.

Rhachitis, as described, is the type ordinarily seen in hospital practice, and its manifestations are unmistakable. In its milder form it is not uncommon among children whose hygienic surroundings are good. In such cases the most marked symptom is weakness. The child is often fat and well developed, although, as a rule, pale. The abdomen is somewhat enlarged and slight prominences at the epiphyseal junctions, particularly at the wrists, may be made out. The legs appear small in proportion to the body, and the ligaments are lax, so that if the child stands the feet are flat and assume the attitude of valgus. In this class, in which the child is said to have weak ankles, knock-knee is common.

The most common symptom of rhachitis of the mild type is the failure of the child to attempt to walk at the usual time, about fourteen months.

A child of normal intelligence who is not ill and who has not suffered from exhausting disease and does not walk at two years of age is probably rhachitic.

Prognosis.—The duration of the progressive stage of rhachitis depends upon the age of the patient and upon the treatment. In cases that are untreated and in which the predisposing causes continue, the period of repair may be delayed for several years or longer, as shown by the fact that the child makes little effort to stand. But, in most instances, the rhachitic child begins to walk during the third year, and at this time, the deformities of the lower extremity, knock-knee, bow-leg, flat-foot and the like usually develop or become aggravated, while those of the upper extremity may become less noticeable.

The deformities of rhachitis tend to disappear or to become less marked with growth; the concavities of the distorted shafts are filled by accretions of periosteal bone, which is again absorbed from the interior as the medullary canal straightens itself. The thickened diaphyses and enlarged epiphyses become more symmetrical under the influences of rapid growth and increased functional activity, but traces of severe rhachitis always remain, and many of the more noticeable and permanent distortions of the trunk and of the lower extremities are due to this cause.

The prognosis as to the outgrowth of rhachitic deformities depends upon the duration and the severity of the disease and upon the function of the deformed part. Rhachitic distortions of the arms almost always disappear under the influence of the force of gravity. The rhachitic chest is rarely seen in the adolescent or adult. The rhachitic kyphosis is corrected or modified when the erect posture is assumed, but rhachitic scoliosis, on the other hand, usually increases with the growth. Distortions of the lower extremities may occasionally entirely disappear, and in most cases they are less marked in the adult than in the child. Stunting of the growth is a constant effect of severe and prolonged rhachitis; it depends in part upon the arrest of development and deformity during the active stage of disease and in part upon premature consolidation at the epiphyseal junctions.

Treatment.—The treatment of rhachitis consists essentially in a reversal of the conditions under which it developed. It is therefore dietetic, hygienic, and medicinal. Deformity, the effect of the disease, may be prevented by guarding the weakened bones from overstrain, and it may be remedied, if it be present, by manipulation or by mechanical or by operative treatment.

The more detailed treatment of rhachitis may be found in works on pediatrics. The most effective remedies are cod-liver oil and sunlight, the next pure milk and green vegetables.

The patient, protected by proper woollen underclothing, should pass as much time as possible in the open air and sunlight, and should sleep in a well-ventilated room. Daily salt baths are recommended for older children, and regular massage of the extremities and of the abdomen should be employed. Medicinal treatment is of secondary

importance. The bowels should be regulated and digestion should be aided by proper remedies. For anemia, which is usually present, the syrup of the iodide of iron is of value; cod-liver oil serves both as a food and medicine and according to the investigations of Howland[1] it has an almost specific action on rhachitis. It is unlikely that any drug has a very direct influence on the disease. Phosphorus in doses of $\frac{1}{200}$ to $\frac{1}{100}$ of a grain is often given, and is supposed to lessen the abnormal congestion of the bones, while the deficiency of lime salts may be supplied possibly by the administration of lime in some form, the syrup of the lactophosphate of lime being a favorite prescription.

The prevention of deformity, other than by the means already enumerated, consists in preventing habitual postures that predispose to deformity, and in daily massage and manipulative correction of incipient distortions. Young infants and those whose bones are especially vulnerable should spend much of the time in the reclining posture. An abdominal binder should be applied in the cases of so-called pot belly to support the weakened muscles and to stimulate thoracic breathing. The stretcher frame or similar appliance is especially useful in the treatment of this class of cases. The treatment of the more advanced deformities, by braces or by operation, is described elsewhere.

"LATE RICKETS."

Late rickets is, as the name implies, an affection presenting all the characteristics of the common infantile form. This, in rare instances, appears in later childhood or even in adolescence; in most instances the affection appears to be a continuation or recrudescence of the infantile form; in others no history of a preceding affection can be obtained.[2]

Adolescence when growth is rapid is a period of instability when static deformities develop, or if already present are exaggerated, particularly in subjects living under unfavorable conditions, who are overburdened or overworked.

By many writers the term late rickets is improperly used to explain genu valgum, coxa vara and the like in subjects of this class, although none of the distinctive signs of the disease are present.

RENAL RICKETS.[3]

In cases of chronic nephritis in childhood, changes at the epiphyseal junctions resembling those of rhachitis are sometimes observed, growth is retarded and the bones become fragile.

[1] Bull. Johns Hopkins Hosp., April, 1921.

[2] Drewitt: Tr. London Path. Soc., 1881, vol. **32**; Clutton: St. Thomas' Hosp. Reports, 1884, vol. **14**; Horwitz: Am. Jour. Orthop. Surg., November, 1909; Emslie: St. Bartholomew's Hosp. Rep., 1906, vol. **43**.

[3] Brockman: British Jour. Surg., 1927, vol. **15**.

INFANTILE SCORBUTUS.

Synonyms.—Scurvy, scurvy rickets.

Scurvy in infancy, as at other periods of life, is a constitutional disease dependent upon impaired nutrition, caused primarily by unsuitable food. The disease was originally described by Smith and Barlow as scurvy rickets, but it may, and often does, occur independently of the latter affection.

Pathology.—The pathological changes most often found in cases of the advanced type are hemorrhages beneath the mucous membranes and beneath the periosteum of the affected bones. Separation of the epiphyses may occur in extreme cases.

Symptoms.—The disease is most common in infants from six to eighteen months of age, of the better class, fed upon sterilized milk or for whom sterilized milk has been the basis of the diet. In some instances the patients are evidently ill-nourished, but in others they may appear to be in good condition. The early symptoms resemble rheumatism. The child shows evidences of discomfort when certain joints, usually of the lower extremity, are moved, and as the disease progresses it may scream whenever it is turned or lifted. The painful joints are sensitive to pressure and they may be somewhat enlarged, but local heat and redness, as well as fever, are, as a rule, absent. After dentition the gums may be swollen and spongy, and hemorrhages into the skin or beneath the mucous membranes may occur. In extreme cases the swelling about a joint due to effusion of blood and accompanied, it may be, by separation of the epiphyses may be mistaken for the symptoms of infectious epiphysitis or even for sarcoma.

Treatment.—The treatment consists primarily in the regulation of the diet, particularly in the substitution of fresh uncooked milk, properly modified, for the patent food or sterilized milk that may have been employed. This should be supplemented by orange juice or that of other fresh fruit. The change of diet usually relieves the symptoms. During the painful stage of the disease complete rest in the horizontal position on a pillow or frame may be indicated; later, massage of the limbs and back may be of service in improving the nutrition and remedying slight deformity.

CHONDRODYSTROPHIA.[1]

Cases that present the signs of what appears to be severe general rhachitis at birth are not especially uncommon. The trunk seems long and the upper arms and thighs are disproportionally short and distorted, as compared to length of the stunted limbs. The head is large. The face is flattened, the nose sunken and the skin may be thickened, the chest presents a pigeon-like distortion, and the extremities of the bones appear to be generally enlarged. The hands and

[1] This was first accurately described in 1890 by Parrot, under the title of Achondroplasia, Bull. Soc. d'anthropol. de Paris.

feet are short and broad and the joints seem relaxed. In some instances the back is curved into a rigid kyphosis or scoliosis, and restricted motion or apparent fixation of many of the joints may be present.[1]

Etiology and Pathology.—These cases were formerly supposed to be instances of intra-uterine rhachitis. Chondrodystrophia is not, however, the result of a disturbance of nutrition; it is due apparently to the defective evolution of the process of endochondral ossification, beginning at different periods of intra-uterine life, the apparent enlarge-

FIG. 476.—Chondrodystrophia in infancy.

FIG. 477.—Chondrodystrophia; age four and three-fourths years; height, 34 inches; normal height, 41 inches. (See Fig. 478.)

ment at the joints being due to formation of periosteal bone at the diaphyseal extremities. Rhachitis is characterized by thickening about the epiphyseal cartilages and by delayed ossification. In chondrodystrophia, on the contrary, there is atrophy of the epiphyseal cartilages. On section of a bone the shaft is seen to be thickened, stunted, and irregular in outline. The epiphyses are often of normal

[1] Roos: Ztschr. f. klin. Med., vol. **48**; Schirmer: Centralbl. f. d. Grenzgeb. d. Med. u. Chir., 1907, No. 10.

size and consistency but the connecting cartilage is irregular and atrophied.[1]

Chondrodystrophia is sometimes seen (Fig. 479) in a very mild form; the appearance of the child suggests rhachitis, but the stunting of the growth is greater than is ever the result of rhachitis of corresponding severity.

Cretinism.—Cretinism due to lack of thyroid secretion, may cause a similar dwarfing of the stature, and may be combined with chondrodystrophia, but the symptoms of mental deficiency that accompany

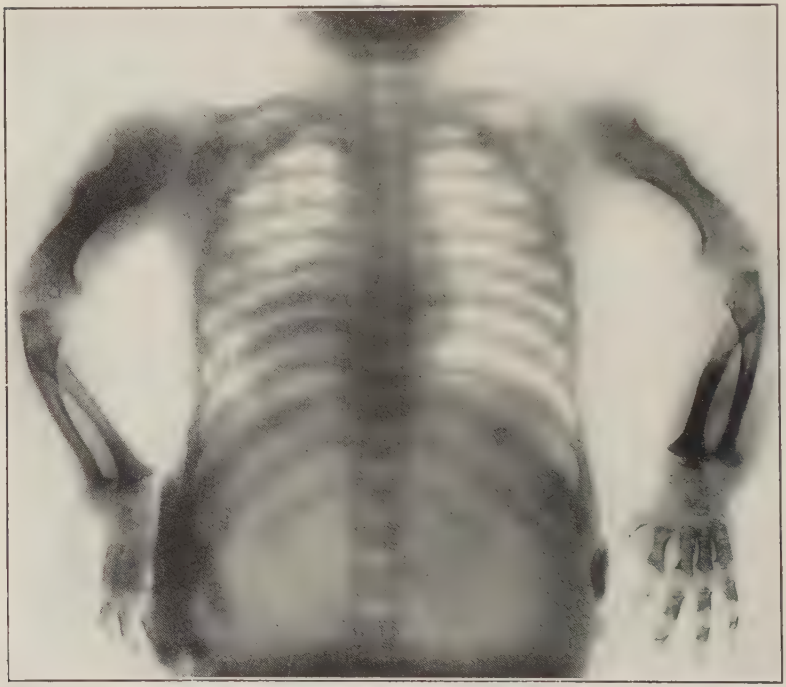

Fig. 478.—Chondrodystrophia, roentgen-ray picture of patient Fig. 477, showing the characteristic changes in the diaphyses of the upper extremities contrasted with the comparative symmetry of the trunk.

cretinism are lacking in this affection (Fig. 480). In some instances hydrocephalus may be present with consequent mental deficiency, and, according to Dandy,[2] the intellect is inversely proportional to the size of the head.

Prognosis.—The more extreme distortions of the limbs lessen or disappear in the process of development. The patient is, however, dwarfed, the average height in adult age, according to Schirmier, being

[1] Jansen: (Feebleness of Growth and Congenital Dwarfism, London, 1921), considers amniotic pressure as the important factor in the etiology of this and similar congenital abnormalities.

[2] Bull. Johns Hopkins Hosp.

MEDICAL LIBRARY
THE
BOSTON CITY HOSPITAL

from 33 to 53 inches, the large head and the stunted extremities indicating the cause.

1 2

FIG. 479.—Chondrodystrophia of slight degree, contrasted with ordinary rhachitis in sisters. 1. Chondrodystrophia. Broad, short, very flexible hands; trunk disproportionately long; knock-knees. Age, five and a half years; height, 30½ inches; normal height, 40 inches. 2. Rhachitis, bow-legs; age, four years; height, 32 inches; normal height, 36 inches.

FIG. 480.—Cretinism in infancy. Cretinism and myxedema are due to lack of thyroid secretion.

Treatment.—The treatment of chondrodystrophia consists in regular massage and manipulation of the distorted parts and of the stiffened joints. If the deformity of the spine is extreme and if the joints are weak, rest on the stretcher frame is advisable. If congenital cretinism is suspected the administration of thyroid extract is indicated.

FIG. 481.—The illustration shows the short shafts with abruptly expanded ends characteristic of achondroplasia. The bones of the upper extremity are on the right, and those of the lower on the left. Note the relative length of the clavicle, which, being largely a membrane bone, shows no shortening. (R.C.S. Museum, No. 4163.1.)

These macerated bones are those of a full-time fetus, born dead, and were taken from a very unusual case described by Shattock. The specimen is entitled in the Catalogue, "Achondroplasia and Rickets;" and the justification for the latter part of the title appears to lie in the porous thickened condition of the pelvis and cranial bones (No. 4163.3), and of portions of the surface of some of the long bones. (Pathol. Soc. Trans., 1880, **32**, 369.) (Courtesy of the British Journal of Surgery.)

DYSCHONDROPLASIA.

Dyschondroplasia was first described under this title by Ollier in 1898.[1] It is a chronic affection of the bones resembling in some degree the local changes of chondrodystrophia, but irregular in its distribution, often limited to one side of the body, which is otherwise normal in appearance, or to one of companion bones, particularly the ulna and fibula. The growth of the affected bone is irregular and it is usually much shorter than its fellow.

FIG. 482.—Dyschondroplasia.

It apparently begins at an early stage of ossification and affects primarily the extremities of the *metaphyses* near the epiphyseal junctions causing deformity, distortions of the articulating surfaces, shortening of the bones and often the formation of exostoses. As the disease does not, as a rule, cause discomfort, attention is first attracted to hard lumps on the arm or leg, to the shortening of a lower limb or to limited motion of a joint. Roentgen-ray examination shows the

[1] Lyon Méd., 1898.

affected bone usually enlarged and irregular at one or both of the articulating extremities, with areas of expansion and lessened density of the shaft.

The exostoses appeared at the extremities of the bones where membrane and cartilage join, as in the pelvis and scapula as well as in the long bones. It would appear that the developing bone at the epiphyseal junctions is not properly modeled by periosteal pressure. Bones that develop exclusively from membrane as those of the skull and those that develop from cartilage as the sternum, carpal and tarsal bones are not involved.

A number of bones are usually involved, including often several of the metacarpal or phalangeal bones, of which the cortex may be expanded by the formation of bone cysts. Dyschondroplasia is much more common in males than in females and sometimes occurs in successive generations of the same family.[1]

MULTIPLE CARTILAGINOUS EXOSTOSES.

Diaphyseal Aclasis.

This is a congenital condition closely allied to and often combined with dyschondroplasia. The exostoses usually increase in size during growth. They may be small, causing no symptoms, and are discovered by chance, or they may form large masses interfering with function. In such instances there is usually retardation of growth or irregular development of the bones as in dyschondroplasia. The only effective treatment is the operative removal of such of the exostoses as cause inconvenience.

OSTEITIS FIBROSA.

Osteitis fibrosa is a chronic disease, characterized by fibrous transformation of the marrow, often by cyst formation, by expansion, weakening and deformity of the affected bone.

Histologically, it is a circumscribed, endosteal, fibrogenous, osteoplastic metaplasia. Metaplasia implying the transformation of one kind of tissue into another of the same embryological type. Thus the marrow changes to fibrous tissue or to mucoid or to fatty material, or into cartilage or bone.

The disease may involve many bones, or it may be limited to one. Its common site in the latter instance is the upper or lower extremity of the femur or humerus. The affected bone is usually enlarged, weakened and often deformed under the strain of weight-bearing. There is slight local discomfort and sometimes sensitiveness to pressure. The diagnosis is made by roentgen-ray examination which shows the degenerative changes described, usually well defined from the surrounding healthy tissue, thus distinguishing it from sarcoma. There are several types of osteitis fibrosa. (1) A limited process usually becoming a

[1] Ehrenfried: Am. Jour. Orthop. Surg., June, 1917.

cyst; (2) a more extensive form involving the entire shaft of a long bone; (3) a generalized form involving many bones. Of 21 cases reported by Bergmann, but 3 were of the generalized form.[1] The cause is unknown. The localized process may be induced by injury; the general form may be induced by lessened vital resistance and some form of toxemia.[1] If the disease is localized, thorough removal of the affected area is indicated. In any case the weight-bearing bone should be protected to prevent deformity or fracture,[2] since repair of the cortex weakened by the disease is often long delayed. If, therefore, the disease is extensive the insertion of a bone graft may be advisable.

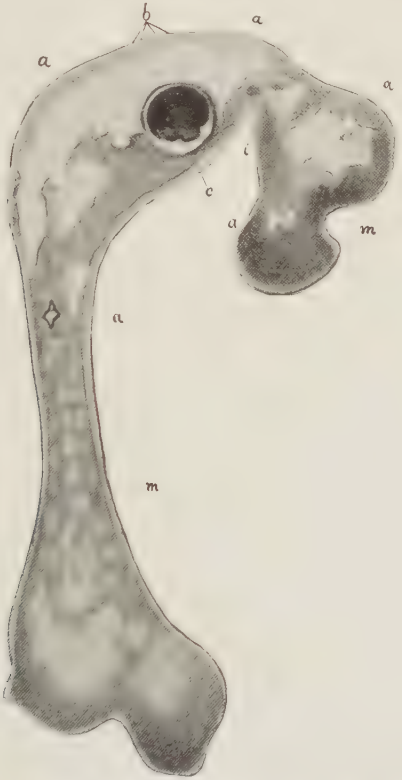

FIG. 483.—Femur from von Recklinghausen's case. (*a*) White fibrous tissue; (*b*) white porous bone formed within the fibroma; (*c*) cyst with dark brown slimy material; (*m*) several brown pigmented spots strewn in the yellow marrow and the remains of the spongiosa of the epiphysis; (*i*) region of impaction. (Reproduced from the Brit. Jour. Surg., 1914, **2**, 59.)

In a generalized form (osteitis fibrosa cystica) it is known as von Recklinghausen's disease, and is characterized, as in the local type, by enlargement of the affected parts and eventually by deformity or fracture resembling thus in its symptoms osteomalacia.

[1] Ztschr. f. Chir., 1926, vol. **3**.
[2] Knaggs, R. L.: British Jour. Surg., April, 1923.

MULTIPLE MYELOMA.

Multiple myeloma is a primary neoplasm of the bone marrow, affecting chiefly the vertebræ, ribs and sternum, the substance of the bone being replaced by tumor tissue.

The disease is usually one of middle life. It is attended by discomfort, by deformity and often by fracture of the affected bones, which are usually irregular in outline and sensitive to pressure. Emaciation and disability are usually rapidly progressive. Bence-Jones albumosuria is present in approximately 65 per cent. of the cases.

Geshichter and Copeland[1] have collected 438 cases from literature.[2]

FRAGILITAS OSSIUM.

Synonyms.—Idiopathic osteopsathyrosis. Osteogenesis imperfecta.

Idiopathic fragility of the bones or osteopsathyrosis is of congenital origin. The bones, particularly those of the lower extremity, are delicate in structure and are usually shorter than normal. The epiphyseal cartilages appear to be relatively normal but the periosteal growth of bone is deficient. The bone is soft, in part cartilaginous, and the periosteal tissue extends into its substance. In such cases there may be distortions at birth, apparently caused by intra-uterine fractures, and in after-life fracture may follow the slightest accident or even ordinary movement. Blanchard[3] has reported a case in which there were 70 distinct fractures between the ages of two months and twenty-seven years. A similar case was for many years under treatment in the Hospital for Ruptured and Crippled. For a part of the time the trunk and legs were enclosed in a plaster-of-Paris casing to prevent the fractures that followed even ordinary movements. At the age of fourteen the strength of the bones had increased sufficiently to enable the patient to walk about with the support of braces, but in stature he resembled a child of seven years.

Fractures in this class of cases are attended with but little pain. They unite slowly with but small callus. It is practically impossible to prevent a certain amount of deformity. With advancing years the liability to fracture may diminish, but, as a rule, the patient is disabled and dwarfed in suture. These patients appear in early infancy to be weak and anemic. Blue sclerotics are a common accompaniment of the condition due to transparency of the sclera, caused it is supposed, by lack of fibrous tissue in the eye as in other structures. In this type hereditary influence is marked. It is stated that one-half the offspring of the affected individual will transmit the disease.[4]

The treatment is protective. Massage, the Bier treatment and the like may be of some service in improving local nutrition. Medication is of little avail.[5]

[1] Archiv. Surg., April, 1928.
[2] New York Med. Rec., May 9, 1914.
[3] Tr. Am. Orthop. Assn., vol. **6**.
[4] Apert, Bull. de la Soc. Ped de Paris, July 17, 1928.
[5] Porak: Bull. et Mém. de la Soc. Obst. et Gynec. de Paris, 1840; Salvetti: Beitr. z. path. Anat. und allg. Path., 1894, vol. **16**; Nathan: Am. Jour. Med. Sci., February, 1905.

There are many other conditions that cause local or general fragility of the bones and thus an increased liability to fracture. Among the local causes are tumors, cysts, inflammatory processes, syphilis and the like. The general conditions would include the weakness of old age, and the condition called senile rickets or osteomalacia in which

Fig. 484.—General marble-like appearance of the bones of the hands, forearm and arms; transverse, parallel, disk-like bands in the phalanges and metacarpals; fracture of the distal epiphysis of left radius. (Davis.[1])

progressive deformity is attended by pain; the atrophy caused by disuse incidental to chronic joint disease, or the weakness that may be caused by certain diseases of the nervous system. In other instances the weakening may be the direct result of disease, as, for example, osteomalacia or rhachitis.

[1] Davis, Y. G.: Archiv. of Surgery, 1922.

OSTEOSCLEROSIS—MARMORKNOCHEN—FRAGILITA GENERALISATA.

This condition, which resembles fragilitas ossium, differs from it in that osteoporosis is combined with areas of density, indicating an increase of endosteal bone formation and disk-like transverse layers of lime salts near the epiphyseal extremities of the shafts of the bones. It was originally described by Schonberg in 1904 under the title of Marmorknochen. The fractures as compared to those of fragilitas ossium are far less common, nor is dwarfing of the stature observed. As a rule, the condition is discovered by chance. It is of congenital origin and the treatment must be symptomatic. Eighteen cases have been analyzed by Clairmont and Schinz.[1]

Changes in the bone, usually the tibia, similar to sclerosing osteomyelitis may occur in childhood.[2]

OSTEOMALACIA.

Synonym.—Mollities ossium.

Osteomalacia is a disease of an inflammatory nature, characterized by an absorption of the earthy substances (decalcification) of the bones and by deformity. The disease is particularly one of adult life. It is far more common among females than males, and pregnancy, in about half of the cases that have been reported, seemed to be the exciting cause. The disease usually begins insidiously. The symptoms are pain on motion, referred to the pelvis and to the thighs. This is supposed to be of a rheumatic nature until the character of the affection is made evident by the weakness of the limbs and by the deformities. These deformities are of greater interest to the obstetrician than to the surgeon, for when the affection complicates pregnancy the distortion of the pelvis may be so great as to prevent normal delivery.

Osteomalacia in Childhood.—Three cases of osteomalacia in childhood have been reported by Siegert,[3] and one case has come under my observation. The patient, one of twelve living children of healthy parents, was nursed by his mother for the usual period, and until the age of four years he appeared to be perfectly healthy. At this time, without known cause, general weakness became apparent, and at the same time deformities of the lower extremities developed. At the age of six years he was unable to stand. The condition of the patient at nine years of age is shown in Fig. 485. The patient had never suffered from pain or discomfort. The lower extremities were somewhat atrophied from disuse, the bones were abnormally flexible and were distorted to a moderate degree. The epiphyses were not enlarged.

[1] Arch. f. klin. Chir., 1925, vol. **132.**
[2] Froelich, Tibia Ebournés, Rev. d'Orth., 1929, **1**, 1.
[3] München. med. Wchnschr., November 1, 1898.

MEDICAL LIBRARY BOSTON CITY HOSPITAL

Treatment.—As the etiology of the affection is unknown, the treatment is therefore experimental or symptomatic and palliative. Involution of the thymus gland has been suggested as a cause and the administration of this substance may be of service.

FIG. 485.—Osteomalacia in a child.

Senile Osteomalacia.—Weakening of the bones accompanied by discomfort, pain and progressive deformity sometimes occurs in old age.

Hunger Osteomalacia.—During the war a number of cases of acquired osteomalacia, apparently the result of malnutrition, were reported in Germany and Austria. The symptoms were fatigue, drooping posture, bowing of the bones of the lower extremity and spontaneous fracture.

The process appears to be an absorption of the lime in the bones and the formation of an osteoid tissue. The marrow space is relatively enlarged and the periosteum thickened and hyperemic.

Local Osteomalacia.—When deformity of a bone appears and increases without apparent cause it is often assumed that a local disease—"local rickets or local osteomalacia"—is present.

Local weakness and deformity may be caused by injury or by subacute osteomyelitis and the like. If there is a distinct local disease that deserves the name of local osteomalacia its cause has not been determined.

OSTEITIS DEFORMANS.

This disease was first described by Paget[1] in 1877. It is a chronic inflammatory affection of the bones, characterized by hypertrophy

FIG. 486.—Osteitis deformans in a female seventy-three years of age. (Lunn.[2])

FIG. 487.—Osteitis deformans of both femora most marked on the right side. Duration of symptoms three years. Symptoms, increasing outward bowing of the limbs, also pain and weakness after overexertion. In cases of this type fractures may occur which readily unite and in cases of noticeable deformity operative correction may be considered.

[1] Med. Chir Tr., vols. 40 and 65.
[2] Prince: Am. Jour. Med. Sci., November, 1902.

and softening. "The bones enlarge, soften, and those bearing weight become unnaturally curved and misshapen."

Section of an affected bone shows it to be markedly increased in size, and somewhat in length, by a combination of rarefying and formative osteitis. The inner layers become porous, and at the same time new bone is deposited beneath the periosteum.

FIG. 488.—Normal tibia and foot.

FIG. 489.—Osteitis deformans. Hyperostosis and decalcification. (Fitz.) Contrast with Fig. 488. In this generalized form the bones become very fragile and multiple fractures may occur.

The disease appears to be confined to adult life, and it is apparently more common among males than females and in rare instances two or more members of the same family may be affected. Of 67 cases collected by Packard, Steele, and Kirkbride,[1] 61 per cent. were in males.

[1] Am. Jour. Med. Sci., November, 1901.

As a rule the lesions are symmetrical and general in distribution, the bones of the lower extremity, the skull, and the spine being more often involved. Thus the head progressively increases in size, and the legs become bowed. If the spine is affected it bends forward, forming a long, more or less rigid kyphosis.

Aside from the deformities and the characteristic enlargement of the bones, the symptoms are not marked. At times complaint is made of pain usually supposed to be rheumatic until the characteristic changes in the bones appear. The disease is extremely chronic in its course, and, as a rule, the general health is not seriously affected. Sarcoma may develop, usually in the bone most involved and finally cause death many years after the onset of the disease.[1] Its etiology is unknown, and its treatment is palliative.

FIG. 490.—Advancing sclerosis. (Brit. Jour. of Surg.)

FIG. 491.—Complete sclerosis. (Brit. Jour. of Surg.)

Localized Osteitis Deformans.[2]—A disease resembling in its general characteristics osteitis deformans may appear in a single bone or in corresponding bones of the lower extremity (Fig. 487). It may per-

[1] Bird: Arch. Surg., 1927, vol. **141**.

[2] First described by Bowlby (Trans. Path. Soc., London, 1883, vol. **34**).

sist indefinitely, with but little tendency toward the general involvement of the bones characteristic of Paget's disease, as originally described. The affected bone increases both in length and size and usually bends in a weight-bearing extremity. Eventually the process of bone softening and thickening may come to an end. A sclerosis follows, as shown in the accompanying illustrations.

The treatment is symptomatic, being directed especially toward relief of strain that induces discomfort and increases the deformity. In some instances the distortion may be so extreme that the adjustment of support is difficult, and in such cases operative correction usually be cuneiform osteotomy is indicated.[1] Fractures, either partial or complete, unite, but protection is required for a longer time than under normal conditions.

Leontiasis Ossea. —This is a form of disease allied to osteitis deformans, characterized by irregular enlargement of the bones of the face or skull. It appears to be a form of chronic periostitis or osteitis. The symptoms depend on the mechanical effects of the enlarging bone, which may obstruct the nasal cavities or encroach upon the intracranial contents. In some instances removal of the hypertrophied bone may be feasible.

SECONDARY HYPERTROPHIC OSTEO-ARTHROPATHY.[2]

Osteo-arthropathy is an inflammatory disease of the bones characterized by hypertrophy, clubbing of the fingers, and effusion into certain of the joints. The hypertrophy is caused by a deposition of layers of bone beneath the periosteum of the metacarpal and metatarsal bones, the phalanges and the distal extremities of the adjoining bones of the arms and legs. Less often the area of the disease is more extensive, involving the femora, the humeri, and even the spine.

Osteo-arthropathy is most common in young subjects and is usually a complication of preëxisting chronic disease, which causes interference with the circulation and which is accompanied by suppuration. Thus it is most often found in combination with disease of the lungs as in 65 of 93 cases collected by Janeway. The clubbing of the terminal phalanges and hypertrophy of the finger-nails first appear, later an increasing enlargement of the wrists and ankles, and of the hands and feet, accompanied by discomfort, sensitiveness to pressure, and often by effusion into the neighboring joints, symptoms that would be classed as rheumatic were it not for the evident hypertrophy.

The clubbing of the fingers is due, in part at least, to impairment of the circulation, and the connection of the disease of the bones with that of the lungs has suggested the theory that it is caused by the absorption of toxins, and that its etiology is similar to the amyloid hypertrophy of the internal organs that sometimes follows chronic

[1] Fränkel: Forts. de Roent. Str., 1918, Bd. **25.**

[2] Marie: Rev. Méd., Paris, 1890, **10**, 1; Bamburger: Wien. klin. Wchnschr., 1889, No. 11; Deutsch. Chir., 1899, L. 28; Alexander: St. Bartholomew's Hosp. Rep., 1906, vol. **42.**

disease of bones and joints attended by suppuration. The treatment is symptomatic, and as the affection is almost always secondary to graver disease, but little is known of its outcome. It is certain, however, that the secondary osteo-arthropathic symptoms become less marked or may even disappear as the patient recovers from the original disease of the lungs or other organs. The affection is very uncommon in childhood. In one characteristic case observed by the writer[1] complete recovery followed the cure of Pott's disease and chronic bronchitis, the hypertrophied phalanges alone remaining.

ACROMEGALY.[2]

This affection, like the preceding, is characterized by progressive enlargement of the hands and feet, but it differs from osteo-arthropathy in that all the tissues are involved. The hypertrophy of the bone is limited to the extremities, and is slight compared with that of the soft parts. The most noticeable change is in the face, the tissues of the nose, lips and ears being enlarged and thickened, together with the underlying bones, so that the expression is markedly changed. The affection most often appears or attracts attention in early adult life. It is usually slowly progressive, and it may be accompanied by mental impairment.

Acromegaly is common among those of gigantic stature, the local hypertrophy and the gigantism both being due to increased secretion of the pituitary gland.

"Two conditions, one due to a pathologically increased activity of the pars anterior of the hypophysis (hyperpituitarism), the other to a diminished activity of the same epithelial structure (hypopituitarism), seem capable of clinical differentiation.

"The former expresses itself chiefly as a process of overgrowth—gigantism, when originating in youth—acromegaly when originating in adult life. The latter expresses itself chiefly as an excessive, often a rapid, deposition of fat with persistence of infantile sexual characteristics when the process dates from youth, and a tendency toward a loss of the acquired signs of adolescence when it first appears in adult life." (Cushing).[3]

According to Keith,[4] all the tissues, including the alimentary, renal, and connective-tissue systems, with the exception of the brain and sexual system, are involved in an overgrowth due to an awakening or continuation of a normal process which should cease when the adult stage has been reached, the cause being a disorderly enlargement of the pituitary gland.

[1] Whitman: Pediatrics, February 15, 1899.
[2] Acromegaly was first described by Marie, in 1886.
[3] Jour. Am. Med. Assn., July 24, 1909.
[4] Bull. Johns Hopkins Hosp., May, 1922.

CHAPTER XV.

CONGENITAL DISLOCATION OF THE HIP AND COXA VARA.

CONGENITAL DISLOCATION AT THE HIP-JOINT.

Of all the congenital dislocations, or, perhaps, more properly, misplacements, that of the hip-joint is by far the most common and the most important.

Statistics.—Congenital dislocation of the hip is much more common in females than in males. In 1362 cases collected from different

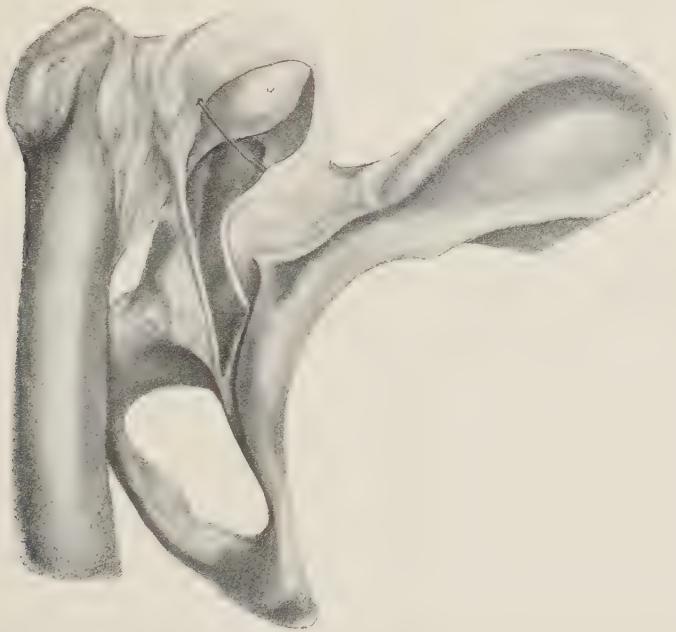

Fig. 492.—Congenital dislocation of the hip, showing the elongated capsule and the right-angled relation of the neck to the shaft of the femur. (William Adams.)

sources by Hoffa, 1189 (87.2 per cent.) were in females and 173 (12.7 per cent.) in males. Of 1039 cases seen at the Polyclinic in Milan, 867 (83.4 per cent.) were in females, 172 (16.6 per cent.) in males.[1] In 413 cases from the Vienna Institute, 344 (83.6 per cent.) were in females, 69 (16.4 per cent.) in males. In 1879 cases reported by Putti[2] 84.9 per cent. were in females and 15.1 per cent. were in males.

[1] Bernacchi: Ztschr. orthop. Chir., vol. **2**, 275. For complete review of the literature see Schultze: Arch. f. Mechanotherapie u. unfall. Chir., 1908, **7**, 1. For statistics, Rev. d'orthop., July 1, 1914.

[2] Surg., Gynec. and Obst., April, 1926.

In 801 cases from the records of the Hospital for Ruptured and Crippled 655 (81.6 per cent.) were in females and 146 (18.3 per cent.) in males. Thus in a total of 5494 cases; 850 were in males, or about 1 in 8.

The dislocation is more often unilateral than bilateral. In Hoffa's series of 1362 cases, 860 (63.1 per cent.) were single; 392 of the right, 468 of the left side. In 502 cases (36.9 per cent.) the displacement was bilateral. In the cases reported by Putti 60 per cent. were unilateral.

STATISTICS OF 801 CASES OF CONGENITAL DISLOCATION OF HIP RECORDED AT THE HOSPITAL FOR RUPTURED AND CRIPPLED.

		Per cent.
Males	146	18.35
Females	655	81.65
	801	100.00
Right hip	206	26.07
Left hip	353	44.69
Both	231	29.24
	790	100.00
Not specified	11	
	801	
Males.		
Right hip	43	30.49
Left hip	55	39.02
Both	43	30.49
	141	100.00
Not specified	5	
	146	
Females.		
Right hip	163	25.10
Left hip	298	45.94
Both	188	28.96
	649	100.00
Not specified	6	
	655	

The dislocation at the time when the patients are brought for treatment is usually posterior, upon the dorsum of the ilium; occasionally it is anterior, the head of the bone presenting below the anterior-superior spine. It is probable, however, that the primary displacement is often directly upward, for in the cases detected in infancy this position is common.

Pathology.—The pathological anatomy of the dislocation was first clearly demonstrated by Dupuytren in 1826, and since 1890, when the open operation was first performed, the exact relation and the appearances of the different components of the joint have been described in detail by Hoffa, Lorenz, and other operators.

MEDICAL LIBRARY BOSTON CITY HOSPITAL

The condition of the joint varies with the age of the patient and the strain and friction to which the displaced parts have been subjected. In early infancy it may be assumed that the head of the bone lies in close proximity to what is, in some instances, a practically normal acetabulum; in others to one that is somewhat rudimentary, often shallow and small, sometimes of an oval or of a somewhat triangular shape. The *acetabulum* is covered with normal hyaline cartilage, the ligamentum teres is present, and the capsule is of nearly normal structure. At a later time, when the joint is exposed at operation at the age of five or more years, the capacity of the rudimentary acetabulum is lessened by a deposit of fat and fibrous tissue. As a rule, however, it appears to be of fair size and depth. The *capsule* is elongated to accommodate the upward displacement of the femur. It is hypertrophied, especially where it covers the upper part of the head of the bone, and it may be drawn into shape like an hour-glass; the upper part contains the head of the femur; the anterior wall is drawn tightly across the acetabulum, forming at its upper border a narrow slit-like communication, through which the ligamentum teres passes if it be present (Fig. 493). The interior of the capsule is in part lined with synovial membrane, and it often contains more synovial fluid than is found in the normal joint.

Fig. 493.—Congenital dislocation of the hip, showing the original and the acquired acetabula. (Lorenz.)

The *ligamentum teres*, although probably present at birth in a large proportion of the cases, becomes attenuated and ribbon-like with the increasing elongation of the capsule, and after the age of five years, or at the time when the open operation is performed, it is usually absent, and far more often in the bilateral than in unilateral cases. According to Lorenz, in 52 cases between two and a half and five years it was present in 17; in 48 cases beyond the age of five years it was present in but 4. In rare instances it may be hypertrophied. In my own experience the ligament is present in nearly all cases, although it is often so rudimentary that it might be easily overlooked.

A shallow *secondary acetabulum*, formed in part by the direct pressure of the head of the bone through the adherent capsule, and in part the result of irritation of the periosteum, is usually found upon the ilium (Fig. 502), but it is not often of sufficient depth to assure a secure

support for the head of the femur; thus its upper margin gradually recedes or two distinct depressions may be formed, one above the other. The upper extremity of the *femur* is usually somewhat atrophied. The neck is often shorter than normal, and its angle may be lessened, and in many instances its forward inclination is increased, usually by anterior torsion of the shaft. At birth under normal conditions the anterior inclination of the neck is about 35 degrees. When the erect posture is assumed the pressure on the tense capsule tends to force the neck backward to the adult angle of 10 to 15 degrees. As this influence is lacking if the femur is displaced the original inclination persists. The head of the femur may be nearly normal, although in the roentgen picture the ossifying center of the head usually appears smaller and the anterior inclination of the neck is usually increased. At a later period in walking children the head is usually somewhat flattened on its posterior and under surface, or it may be somewhat conical, acorn-like in shape, or again compressed from side-to-side to an almond shape or otherwise distorted.

There are secondary changes in the bones of the *pelvis*. In unilateral dislocation the pelvis is usually somewhat atrophied on the affected side, and a lateral inclination of the spine may be present. The final changes in the pelvis caused by the bilateral dislocation are more important; its inclination is increased, the lumbar lordosis is exaggerated, the sacrum is forced forward and downward so that the anterior-posterior diameter is diminished; the tuberosities of the ischia are everted and the transverse diameter of both the inlet and outlet of the pelvis is increased.

The long *muscles* of the thigh are shortened, while those attached to the pelvis and trochanter are changed in direction and are usually lengthened. There is also a slight general muscular atrophy that is particularly marked in the gluteal group.

The changes that have been described are in part congenital, in part accommodative, and in part due to the influences of attrition and injury, to which the abnormal mobility predisposes. Thus, they become more marked with increasing age, and in some of the adult specimens but little resemblance to the normal parts remains (Fig. 494).

As a rule congenital dislocation of the hip is not accompanied by defective development or deformity elsewhere, although cases are sometimes seen in which a general laxity of ligaments is present or in which the dislocation may be one of a series of deformities and malformations.

Etiology.—In a small proportion of the unilateral cases the displacement may be caused by injury at birth, but the fact that approximately 85 per cent. of the patients are females makes it evident that the essential cause can be neither injury nor disease.

Hereditary influence may be established in a few instances. The writer has examined 3 female children in a family of 9, in each of whom there was dislocation of the left hip, the order being the third,

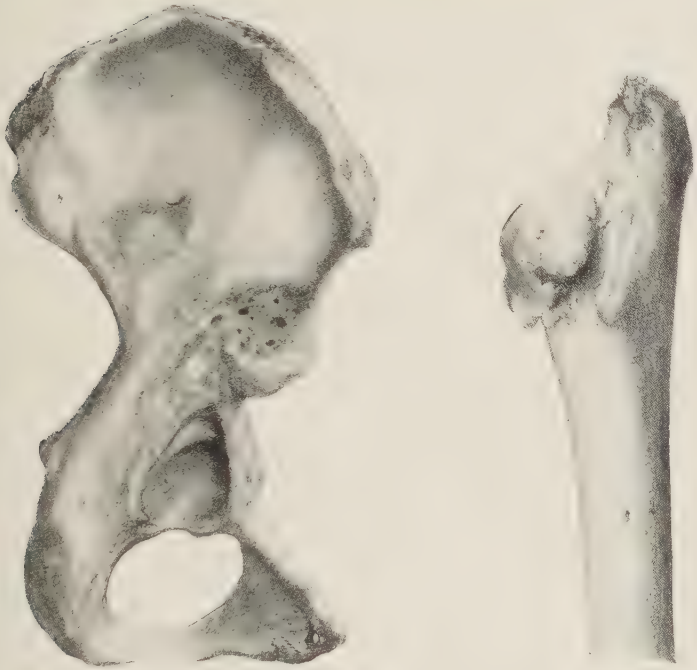

FIG. 494.—Congenital dislocation of the hip in adult age, showing the abnormal shape of the acetabulum, the depressions in the ilium caused by the pressure and friction of the head of the femur, and the destructive effect of this pressure and friction upon the femur. (Adams.)

FIG. 495.—Secondary acetabula in a patient, aged seventeen years. In this case in spite of the apparent stability of the secondary articulation there was pain and disability.

eighth, and ninth child. Also twins in another family, one with single and the other with double dislocation. And in 4 instances congenital displacement was present in the mother of the patients. Vogel,[1] from an investigation of 200 cases, concludes that heredity might have had some remote influence in 30 per cent.—viz.: In 6 instances the mother had congenital dislocation, in 9 the father, in 7 sisters of the father, in 8 sisters of the mother, in one, both father and mother. In 25 per cent. of the cases there had been breech presentation. Putti noted hereditary influences in 13 per cent. of 1879 cases under his care.

Of the various theories that have been advanced to account for the condition, the most reasonable seems to be a predisposing attitude of flexion and adduction of the thigh abnormally prolonged. Dislocation at this joint is comparatively common because the acetabulum is relatively shallow in fetal life, four-tenths as compared to six-tenths of a sphere in adult life. Thus, in newborn children it covers but one-third of the head of the femur, while at the age of five years it is sufficiently deep to contain one-half of it.

Heusner and Marcwald,[2] from an examination of 85 fetuses, conclude that the greater liability of females to the dislocation is explained by the disproportionate laxity of the capsule as compared with males.

It is probable that the dislocation, in some cases at least, is at birth a subluxation only, which becomes complete through muscular action and by the use of the limb in standing and walking.

Symptoms.—The displacement does not, as a rule, attract attention until the child begins to walk, although in some cases the mother may have noticed a peculiar breadth of pelvis, or a "lump" on the buttock, or a "snapping," about the hip-joint, or a peculiar attitude of the limb before this time. In the very unusual event of the opportunity for diagnosis in early infancy, in confirmation of the physical signs, the roentgen picture may show an abnormal separation of the femur from the acetabulum, a delayed development or absence of the ossifying center of the head and an ill-defined roof of the acetabulum.

Unilateral Dislocation.—If the displacement is of one side, a *limp* is immediately apparent, which becomes more noticeable as the child grows older. The limp is peculiar, and its character is explained by its cause; for the shortened limb, owing to the elasticity of the capsule, becomes still shorter when the weight falls upon it; thus in walking there is a peculiar lunge of the body toward the short side, that has been likened to the motion in walking down stairs. When weight is borne on the dislocated limb the pelvis is tilted downward on the sound side, because the gluteal muscles are not sufficiently strong to balance the pelvis. This is the so-called Trendelenburg sign of congenital dislocation. In the ordinary form the head of the femur is displaced upward and backward, and in compensation the pelvis is tilted toward the short limb and its inclination is increased; it is thus twisted downward and forward so that the anterior-superior spine

[1] Deutsch. Ztschr. f. Chir., vols. **3** and **4**, 71.
[2] Ztschr. f. orthop. Chir., 1902, Band **10**, Heft 4.

lies at a lower level and in advance of that of the opposite side (Figs. 496 and 497).

At an early age the *shortening* of the limb, due to the elevation of the trochanter, is from one-half to three-quarters of an inch. In later childhood the elevation is from one and one-half to two inches, and in adult life it may be considerably more.

FIG. 496.—Unilateral dislocation, showing the inclination of the body toward the shorter limb.

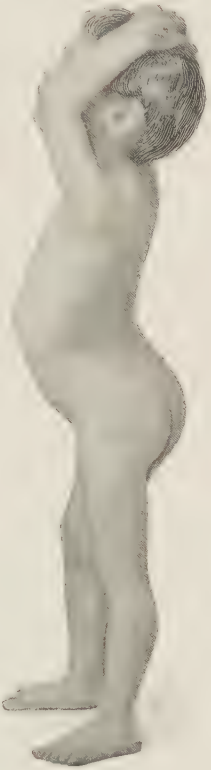

FIG. 497.—The same patient before operation, showing the abnormal lordosis and rotation of the pelvis.

The effect of the displacement is also shown by a flattening of the *buttock*, and usually the elevated and prominent *trochanter* may be seen as an abnormal lateral projection, on a level with the anterior-superior spine, which is, as has been stated, somewhat tilted downward. In infancy *motion* in the false joint is more free than normal, and the abnormal mobility can be demonstrated by alternate traction and upward pressure on the limb, but as the femur becomes larger and the upward displacement increases, the mobility is restricted. The range of abduction is much diminished, and in extreme cases the limb may become permanently adducted and flexed, thus adding the



FIG. 498.—Congenital dislocation in an adolescent, illustrating the flexion contraction in a well-marked case.

FIG. 499.—Bilateral congenital dislocation of the hip, showing the exaggerated lordosis. In cases of this type the range of abduction and extension is usually restricted.

apparent shortening of adduction to that caused by the dislocation (Fig. 498).

Bilateral Dislocation.—In bilateral dislocation the shortening of the limbs is, as a rule, equal or nearly so, and if, as is usual, both femora are displaced backward, the pelvis is tilted forward; thus in compensation "the hollow" of the back is increased, the abdomen protrudes, the buttocks are flattened, the pelvis appears to be abnormally wide, and the thighs are separated by a considerable interval (Figs. 499 and 500). The limp characteristic of the single displacement is replaced by an exaggerated *waddle*, a "sailor gait."



FIG. 500.—Congenital dislocation of both hips, illustrating the separation of the thighs, the abnormal breadth of the pelvic region, and the prominent trochanters.

FIG. 501.—Bilateral anterior congenital dislocation. The lordosis is far less marked than in the ordinary form.

General Symptoms.—In early childhood there are no special symptoms other than the limp or the waddle, but as the child becomes more active it often complains of discomfort after exertion. It is easily fatigued, and at times it may suffer actual pain. These symptoms are, of course, more marked in the double than in the single displace-

ment, because in the latter case the normal limb is capable of bearing more than its share of the strain. The symptoms often increase during adolescence, but they may become less troublesome in adult life, when the head of the bone may have found a permanent resting place on the pelvis; a security which is often assured by a corresponding limitation of the range of motion. The shortening and the secondary effects of the displacement, of course, persist, so that the individual, as compared with the normal standard, is more or less disabled and in certain instances noticeably deformed. In a large proportion of the cases, particularly in the unilateral form, there is an increasing discomfort and disability during adolescence, indicative of the mechanical changes in the unstable articulation (arthritis deformans).

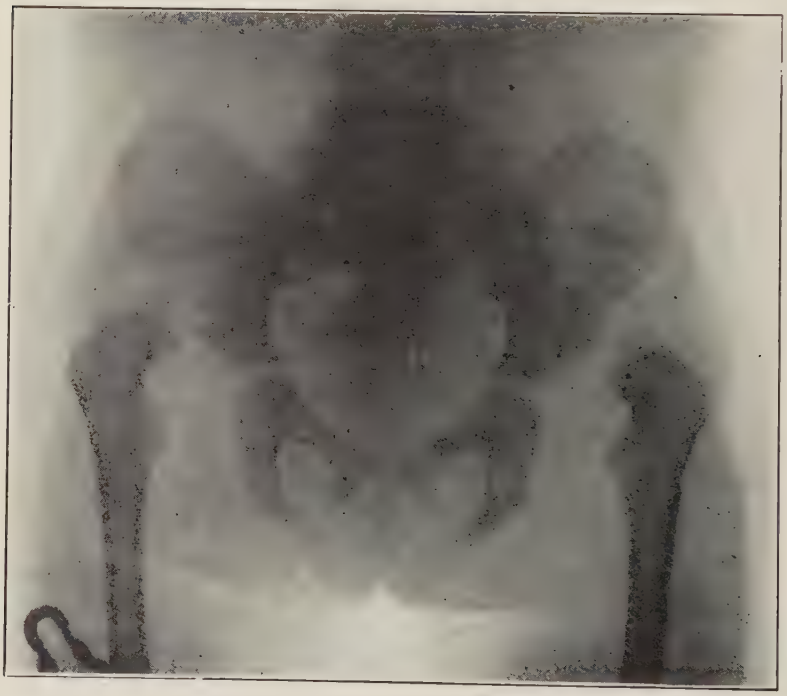

FIG. 502.—Bilateral congenital dislocation of the hip illustrating antetorsion of the femoral necks.

The great majority of the patients are females, and, because of the less laborious occupations and the distinctive dress, the disability and its effects are less serious than if the displacement were more equally divided between the sexes.

Anterior Dislocation.—The symptoms of the unilateral anterior dislocation, in which the head of the bone lies beneath the anterior-superior spine, are much less marked than in the ordinary form because the relation of the pelvis to the femur is more nearly normal. The shorten-

MEDICAL LIBRARY
BOSTON CITY HOSPITAL

ing is less and the limp is less noticeable because the resistance of the tissues attached to the anterior-superior spine is sufficient to assure a relatively secure support.

In bilateral anterior dislocation the entire body is swayed slightly backward, but the lumbar lordosis is not increased; in fact, the back is often peculiarly flat. Otherwise the symptoms do not differ, except in degree, from those of the posterior displacement (Fig. 501).

Supracotyloid Displacement.—As has been stated, in early cases the displacement may be a form of subluxation in which the head lies but slightly above the normal position. The same upward displacement is occasionally found in older subjects. The physical signs are similar to those of the anterior displacement.

Fig. 503.—Bilateral dislocation in adolescence. This patient was practically disabled by pain and weakness.

Diagnosis.—The diagnosis except in earliest infancy offers no difficulty. The history of the limp or waddle noticed when the child began to walk and yet unaccompanied by pain or preceded by injury or disease is in itself sufficiently distinctive. If the displacement is of one side, measurement demonstrates the shortening as compared with the other limb, a shortening that is explained by the prominence of the trochanter and its elevation above Nélaton's line. Traction or upward pressure on the limb will demonstrate the abnormal mobility of the displaced head; and finally, if the thigh be flexed and adducted to its extreme limit, the neck and head of the femur can be easily distinguished moving under the gluteal muscles when the limb is rotated. Thus it may be differentiated from depression of the neck of the femur (*coxa vara*), in which, although the trochanter is elevated, the neck and head of the bone cannot be palpated when the limb is flexed and adducted, and in which the abnormal mobility, characteristic of the dislocation, is absent. Again, coxa vara is almost never a congenital affection; therefore the history itself would practically exclude it.

Upward displacement of the femur not infrequently follows *infectious epiphysitis* or *arthritis* of infancy or early childhood. In such cases a part of the upper extremity of the bone is usually destroyed, so that the head cannot be distinguished on palpation. Although the other

physical signs are similar to those of the congenital displacement, the scars about the joint present the evidence of former disease, and the history is almost always available for diagnosis. Thus, as a rule, such disabilities, as well as traumatic dislocations or other results of injury or disease, are readily excluded. The bilateral dislocation presents, of course, the same physical signs as the single form; it is even more easily recognized by the peculiar appearance and distinctive gait of the patient. The waddling gait may be simulated by that of extreme *bow-legs,* but the hip-joints are, in this deformity, normal in appearance and function. The swagger of *lumbar Pott's disease* is also somewhat similar, but this is an acquired painful disease of the spine, in which the hip-joints are normal in appearance and usually so in function.

Progressive muscular dystrophy may be mentioned as causing a somewhat similar gait and attitude, but here the resemblance ceases.

As has been stated, the diagnosis of congenital dislocation can be easily made by physical examination; the only real difficulty is experienced in certain dislocations or subluxations of the anterior type and in cases seen in early infancy in which the dislocation may be incomplete, but opportunity for such early diagnosis is rarely offered. In doubtful cases a roentgen-ray picture will make the diagnosis clear (Fig. 502). Its chief value however is in the demonstration of abnormalities, particularly the antetorsion of the neck which may require correction in order to assure stability after reduction of the dislocation.

Treatment.—Dupuytren, in 1829, after a careful study of the anatomy of the deformity, came to the conclusion that it was not only incurable but that palliation of its effects even was hardly attainable; and for sixty years the statement was generally accepted, although cures were attained in all probability by Pravaz of Lyons (1847), and certainly at a much later time by Paci, of Pisa (1887).

The term dislocation naturally suggests replacement and retention of the displaced bone in its proper place as the only effective treatment, and in 1890 Hoffa first achieved these essentials by opening the joint from behind and enlarging the rudimentary acetabulum to a size sufficient to contain the head of the bone. The details of the operation were afterward modified by Lorenz,[1] and at the present time the original operation has been to a great extent supplanted by bloodless reposition, but to Hoffa belongs the credit for the introduction of the modern treatment of this disability.

The Lorenz Operation of Bloodless Reduction, Retention and Weight-bearing.—This treatment was based on the knowledge gained by the open treatment that an acetabulum of fair size is practically always present and of sufficient capacity to retain the head of the femur if the limb is fixed in a favorable attitude.

It has been proved, also, that the head of the femur in most instances may be forced within the rudimentary acetabulum. Once this contact or reposition is attained, the limb must be fixed to prevent dis-

[1] Pathologie und Therapie der Angebornen Hüft. Verrenkung, Wien, 1895; Ueber heilung der Angebornen Hüftgelenk Verrenkung, Leipzig u. Wien, 1900.

placement, and as soon as possible the patient must stand and walk in order that weight and friction may deepen the socket. Meanwhile the capsule and other tissues adapt themselves to the new condition, while the muscles regain their capacity for normal function. That the acetabulum may be actually enlarged by the pressure of the head of the femur is indicated by the formation of secondary depressions of sufficient size to form joints of fair stability often found upon the pelvis in anatomical specimens from older subjects (Fig. 495), and may be demonstrated by successive roentgen-ray pictures of patients under treatment.

The Lorenz Operation. It seems expedient to present the basic procedure as established by Lorenz before describing the variations which may be employed with advantage in individual cases. The first step

FIG. 504.—Reduction of dislocation of the right hip. First step. The operator overcomes the resistance offered by the adductors by forcible massage.

in the typical operation is to overcome the resistance of the tissues, namely, of the capsule and of the long muscles that have become structurally shortened in accommodation to the upward displacement of the head of the femur. The second step is to reduce the dislocation, or rather to force the head of the femur over the posterior-inferior border of the acetabulum. The third is to increase the security of the articulation by stretching the anterior border of the capsule. The fourth is to fix the parts securely in a plaster splint.

When the operation was devised the dislocation was rarely detected or treated in infancy and the following description applies to a case of the ordinary resistant type in a patient from four to six years of age.

The patient is placed upon a table with a thick folded sheet beneath the buttocks. The assistant, standing opposite the operator, fixes the pelvis with his hands (Fig. 504). In some instances better control is

assured by pressing the flexed thigh of the sound side downward against the abdomen, as in the Thomas test for flexion in hip disease.

The operator first flexes the thigh to a right angle with the body, then forcibly abducts it, at the same time kneading the tense muscles with the ulnar border of the hand, if necessary stretching and rupturing the fibers until the limb can be forced down to the plane of the body. One next overcomes the shortening of the tissues on the posterior aspect by flexing the limb, extended at the knee, upon the trunk, gradually forcing it downward until the toes may be placed against the patient's face (Fig. 505). During this maneuver the assistant fixes the pelvis by holding the extended thigh of the sound side firmly against the table. The next step is to overcome the resistance of the

Fig 505.—Forcible flexion of the extended limb on the abdomen. Second step in the operation.

tissues on the front of the joint. The pelvis is fixed by the assistant. The leg is then flexed upon the thigh, and the thigh is forced downward behind the plane of the body, or the patient may be turned upon the side, as in Fig. 506. After this preliminary stretching, traction is made upon the limb, and if with slight effort the trochanter can be drawn down to Nélaton's line reduction is attempted.

Reduction.—The pelvis having been fixed as in the first position, the limb is slowly and forcibly abducted over a wedge of wood suitably padded, the apex of which is placed between the trochanter and the pelvis (Fig. 507). As the limb is gradually forced downward to and behind the plane of the body, the head of the femur is forced upward until it finally snaps over the posterior and inferior border

of the acetabulum. Reduction is usually accompanied by a distinct jar, and often by an audible thud. It is also indicated by tension upon the hamstring muscles, which causes resistant flexion of the leg.

FIG. 506.—Forcible extension of the thigh. Third step in the operation.

The patient is then turned upon the sound side and the pelvis, having been fixed by the assistant, the operator rotates the limb from side to side and at the same time presses the trochanter downward and forward with the aim of forcing the head more completely within the

FIG. 507.—Reposition. The thigh is forcibly abducted over the padded wedge. Fourth step in the operation. The wedge is of hard wood of the following dimension: length, 9½ inches; height, 3½ inches; base, 3 inches.

acetabulum. The security of the reposition is then determined. One tests successively the stability or depth of the superior margin of the acetabulum by reducing the abduction; of the posterior margin by

lifting the thigh ventralward, and in a similar manner the inferior border. Upon this examination the prognosis is made; if the stability permits an approximation to the normal position before displacement occurs the prognosis is good. If, on the other hand, the margins of the acetabulum are so ill-formed that displacement occurs very easily the prognosis is bad.

The operation is varied somewhat in certain instances. If after the manual stretching the trochanter still remains above Nélaton's line, one attempts to overcome the remaining resistance by direct traction in the line of the body. Counter-resistance is furnished by a folded sheet passed between the thighs about the perineum, the two ends of which are tied about a corner of the table. Traction on the limb is made by one or two assistants while the operator supports the pelvis and presses downward and inward upon the trochanter. Occasionally reposition is effected during this maneuver—that is, the head is drawn over the superior instead of the posterior border of the acetabulum.

Fig. 508.—The position in which the limb is held when the plaster support is supplied. In the treatment of younger subjects the plaster splint should include the leg and foot.

Preliminary Traction.—In the treatment of older patients and of more resistant cases preliminary traction in bed is advisable. The traction must be continuous, heavy weights to the point of toleration being employed for two or more weeks. This is of great advantage.

Reduction in Two Sittings.—If the reduction proves to be difficult, requiring more force than is deemed safe, the limb should be fixed in a plaster spica in the attitude of abduction, the actual reposition being deferred for one or more weeks.

After reposition the plaster support is applied. A close-fitting covering of stockinette is drawn on over the limb, threaded as it were, with a long bandage, the "scratcher." The patient is then placed upon the pelvic rest and the limb is held in the position of greatest stability at a right angle with the trunk and lying behind the plane of the body.

BOSTON CITY

The pelvis and thigh are thoroughly and thickly covered with layers of sheet-wadding or cotton. This is bandaged firmly, to assure a slight elastic compression.

The plaster spica is then applied. This should be thick and firm. The bandages are drawn snugly around the pelvis and thigh by a series of reverses and figure-of-eight turns, clasping the iliac crests and thoroughly covering in the buttock. The lower part is cut away to permit motion at the knee-joint, especial care being taken to evert the edges and thus to prevent pressure. The ends of the shirting are then drawn smoothly over the bandage and are sewed to one another (Figs. 509 and 510).



FIG. 509.—A plaster support applied by Lorenz, illustrating the extreme thickness of the pelvic portion and discoloration of the adductor region.

The operation in the older type of case is usually followed by swelling and discoloration in the adductor region and more or less pain, of a starting, spasmodic character, especially when the limb is moved. This soon passes away, usually during the first or second week, and the child is then encouraged to stand. As it is only with extreme difficulty that the foot on the operated side can be brought to the floor, a cork-soled shoe from $1\frac{1}{2}$ to 3 inches in height may be worn to facilitate walking.

As has been stated, walking is encouraged in order that weight-bearing and the stimulation of functional activity may increase the stability of the joint by deepening the acetabulum and accentuating its borders. In most instances the range of extension at the knee is for a time somewhat restricted. This restriction is overcome by passive force and by the voluntary effort of the patient. The first support is retained from three to six months or for a longer period, the skin being kept in good condition by daily vigorous rubbing with the hand beneath the supporting splint. In addition the leg should be regularly massaged; after a few weeks the splint becomes loose

about the pelvis. This will permit rubbing of the buttocks. One is able also by palpation of the anterior region to ascertain whether or not the head of the femur is in proper position.

FIG. 510.—Unilateral congenital dislocation, showing the Lorenz spica. A shoe with a cork sole about 2 inches high should be worn on the operated side while the attitude of exaggerated abduction is maintained.

In six months or when it may be assumed that the accommodative changes of the muscles about the joint and the contraction of the capsule will prevent redisplacement, the limb is let down somewhat so that the patient is able to walk about without the aid of a high shoe. The second support is retained for three months or more, and it is then removed, the period of retention being from six to twelve months, according to the stability of the joint at the time of reduction. In the treatment of very young children, when in testing the stability at the time of operation the femur is not displaced, even when the normal position is approached, the limb may be fixed by the plaster in a less distorted attitude—what Lorenz calls the indifferent position of flexion, abduction, and outward rotation.

So, also, when the tests at the operation show fair stability a second

spica need not be applied after a preliminary retention of six months, or even a much shorter time if proper supervision can be provided, but it is better to err on the side of safety in the matter of fixation.

When the support is finally removed the attitude of moderate abduction and outward rotation persists for a time, in some instances for several months. This being an indication of stability, is considered a favorable sign, and no attempt is made to correct it. If, on the other hand, as in the older class of patients, the fixed abduction persists the patient should be anesthetized and the contracted tissues carefully stretched. In many cases of this character the cause of the distortion is a partial pubic displacement, the head of the bone forming a well-marked projection beneath the femoral artery. This projection may be reduced by flexing the limb, and in certain instances it may be well to fix the limb for a time in a slightly flexed position until the tendency toward the anterior displacement is lessened. In

FIG. 511.—Illustrating the limitation of the range of abduction in the attitude of right-angular flexion in bilateral dislocation.

the after-treatment the limb is massaged, particularly the posterior and lateral muscles of the hip, and the child is encouraged to abduct and to extend the thigh, and bearing the weight on the operated limb to sway the other limb laterally to the extreme limit. Passive movements are made, also, in the direction of abduction and extension, the ability to reproduce the first or operation position during the early treatment being considered essential. In certain instances the child for a time should sleep in this position, the attitude being assured by placing the child in a support of plaster corresponding to the posterior half of the original spica.

Bilateral congenital dislocation is treated in the same manner as the unilateral. Both hips are operated upon at one sitting, and are fixed in the typical attitude. Walking is, of course, difficult, but the child is usually able to stand, and after several months it is often able to get about on its feet after a fashion.

FIG. 512.—The after-treatment following the removal of the plaster spica in a case of bilateral dislocation, illustrating hyperextension of the thighs.

FIG. 513.—Axillary abduction an attitude that forces the head downward. This may be of advantage when the upper border of the acetabulum is defective.

When the second spica is applied the limbs are let down somewhat, but the degree depends, of course, on the initial stability. The after-treatment is the same as for the single dislocation, except that the subsequent period of awkwardness is much longer. Massage and exercises (Fig. 512) are far more important than in single dislocation, as the weakness is greater. The primary position during sleep may be assured by a cushion roll or wooden frame as used by Lorenz.

There are many variations of the treatment, notably that of Davis who reduced the displacement by pressure from behind, the patient lying in the prone position.[1] The primary essentials in reduction are that the head of the femur be brought behind and below the acetabulum, where resistance both of bone and soft parts is least, and that after reduction the lower and anterior wall of the capsule shall be thoroughly stretched. Some surgeons place the limb primarily in extension, inward rotation and normal abduction. Some fix the limb for a few months only and then employ massage. Others reduce the displacement by machines, which are mechanically of advantage in resistant cases, but which are not essential. In fact if resistance may not be sufficiently overcome by preliminary traction before the operation to permit reduction by manipulation, an open operation is indicated rather than the use of extreme force.

Prognosis.—The Lorenz operation as a treatment of routine is not without danger. The death-rate attributed to anesthesia is disproportionately large in the cases reported, and in this the violence of the manipulations is undoubtedly an important factor.

In 450 operations reported by Lorenz the following accidents occurred:

Fracture of the neck of the femur in	11 cases.
Fracture of the pelvis in	3 "
Peroneal paralysis in	3 "
Crural paralysis in	5 "
Sciatic paralysis in	3[2] "

In the last cases the paralysis persisted; in the others it was temporary. In one case the femoral artery was ruptured, the patient recovering without ill-effect. In one case gangrene of the extremity necessitated amputation at the hip-joint.

It may be estimated that from 50 to 75 per cent. of the unilateral and 50 per cent. of the bilateral cases may be anatomically and functionally cured, the percentage being, of course, far higher in the cases in which at operation the reduction is found to be of fairly secure type. Even if the reduction is not successful the posterior displacement may be converted into an anterior one in the sense that the head of the

[1] Dixon: Jour. Bone and Joint Surg., October, 1925.

[2] Eighty-eight cases of paralysis induced by the operation have been tabulated by Bade, from 1–3 per cent. of the cases reported by various surgeons. In 16 the peroneal nerve was involved, in 61 the sciatic and in 11 the paralysis of the limb was complete. Recovery is the rule in from three to eight months. Verhandlung d. Gesell. f. Orthop. Chir., 1909.

femur is forced forward below the anterior-superior spine. This improves the static conditions, and further displacement is to a great extent checked by the firm tissues attached at this point.

The Lorenz method has been described as a routine treatment because for many years the bloodless operation was applied with little discrimination, the apparent or actual reduction of the dislocation being classed as success.



Fig. 514.—The cure of congenital dislocation. The same patient is shown in Fig. 511.

With the lapse of time it has been demonstrated that in many instances the later results of these successful cases have not been satisfactory.

Progressive changes in the head of the femur similar to those of the Legg-Perthes disease, which may be ascribed to injury are not unusual and lack of mutual adjustment of the components of the joint may lessen its stability and impair its function.

In former years one had comparatively little opportunity to treat the dislocation in infancy. Lorenz considered the age of four as the most favorable time because the reduction was more stable, and because ambulation provided the functional weight-bearing, which he considered of the first importance in the reconstruction of the joint.

It is now generally admitted that treatment should be undertaken as soon as control of the bladder is established, since it is evident that the changes in adaption to the deformity are obstacles to success that increase with growth.

Rocher[1] has reported on 1500 cases illustrating the influence of age on the result.

Unilateral, two to four years	85 per cent cure.
Bilateral, two to four years	70 per cent. cure
Unilateral, four to six years	75 per cent. cure
Bilateral, four to six years	50 per cent. cure

In infancy the dislocation may be easily reduced without rupturing the muscles by gradual stretching and by pressure the thumb below the trochanter (Fig. 515). As the reduction is less stable than

[1] Paris Chir., December, 1928.

at a later period the head of the femur should be forced into the lower part of the joint by slight axillary abduction and a long spica applied which will assure security with wide exposure of the genitals. In the primary position the head of the femur pressed against the anterior and inferior wall of the capsule. This is of advantage in that it enlarges the capacity of the joint anteriorly and permits retraction of the posterior expanded portion which originally formed the joint. These changes it may be assumed have in a young subject become sufficiently advanced at the end of three months to permit a more perfect reposition. The patient is again anesthetized, and while by pressure on the trochanter the head of the bone is held in its original position the contraction of the tissues that resist adduction is overcome

FIG. 515.—Reposition in young subjects, the thumb being used as the fulcrum to reduce the left hip.

and the limb is rotated inward until the patella points directly forward, a plaster support is then applied to fix the limb in extension and in from 15 to 45 degrees of abduction, according to the stability of the reposition. This support is often extended to the ankle in order to fix the limb in slight inward rotation by flexing the limb slightly at the knee. In this position the head of the femur is placed as well as may be within the acetabulum, so that weight of the body in standing and walking may actually aid in functional reconstruction. The second period of fixation is for about the same length of time. A third change toward the more normal attitude may be made under anesthesia if it seems desirable, the period of retention being determined by the original stability, by subsequent tests and by roentgen pictures. In all doubtful cases the period of fixation should be at least a year.

Of the intrinsic obstacles to success the most important is anteversion of the neck which if extreme requires inward rotation of the limb to place the head actually within the acetabulum.

As is well known, anterior torsion of moderate degree is not unusual in the femora of apparently normal joints. Furthermore, anterior torsion is more marked in early than in later life. According to Le Damany, at birth the torsion angle is from 30 to 60 degrees, from two to four years 35 degrees, six to twelve years 25 to 30 degrees, in adult life 10 to 12 degrees.[1]

FIG. 516.—The bandage applied after the reduction of bilateral dislocation, showing a favorite method of progression on a chair.

Since the anterior inclination of the neck is greater in the fetus than at birth it may be assumed that the normal corrective force is inoperative on the displaced femur, consequently that antetorsion is present in a much larger proportion of the cases of congenital dislocation than in normal subjects.

[1] Antetorsion of the neck is most marked at the fourth month of intra-uterine life. It is about 30 degrees at birth and from 10 to 20 degrees in adult life. In the typical Lorenz reduction the normal head points directly forward; in marked antetorsion, upward. In 124 cases of congenital dislocation the angle of torsion was from 0 to 29 degrees in 29 per cent., from 30 degrees in 54 per cent.; from 31 to 50 degrees in 14.5 per cent. and 60 to 90 degrees in 2.5 per cent.; Meyer, A.: Arch. f. orth. u. unfall. Chir., December, 1923.

MEDICAL LIBRARY BOSTON CITY HOSPITAL

It has been claimed that it is corrected in part during the period of treatment, therefore that it has but little influence on the result. Since, however, operative correction is practically always required in later childhood to assure stability, it may be assumed that the prospect of success may be improved by its correction in infancy.

From this standpoint a notable advance has been made by Dr. Krida of my staff by the routine correction of the distortion, as demonstrated by his illustrations.

FIG. 517.—The characteristic appearance of antetorsion of a degree to require operative correction.

The diagnosis of anterior torsion of a degree to warrant correction can usually be made by the peculiar twisted appearance of the neck in the roentgen-ray picture and by the relatively normal appearance in a second picture with the limb rotated inward (Fig. 521).

In a typical case of this type the dislocation is reduced in the usual manner, in order to thoroughly stretch the capsule (Figs. 518 and 519). Two weeks later the plaster splint is removed and reapplied with the limb rotated inward so that the head may be apposed to the center of the acetabulum (Figs. 520, 522 and 523). At the end of three months, the femur is fractured by manual force just above the knee. The upper part of the thigh being firmly grasped and fixed in inward rotation, the lower fragment is rotated outward to the desired degree. Manual fracture is easily accomplished since the bone will have been weakened by the period of disuse. The plaster support is applied in extension and in the degree of abduction that assures stability and usually is retained from three to four months. The after-treatment is

FIG. 518.—Bilateral dislocation after reduction and fixation in the typical Lorenz position. A larger opening in the genital region is usually required.

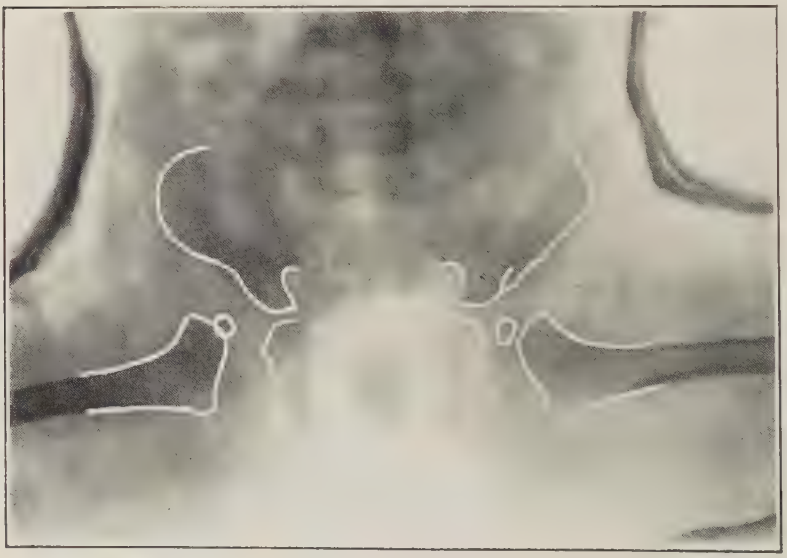

FIG. 519.—Roentgen-ray picture after the first operation.

FIG. 520.—The second step. Two weeks after the primary reduction. The limb is rotated inward to a degree corresponding to the anteversion so that an approximately normal relation of the components of the joint may be assured. (A unilateral displacement.)

FIG. 521.—The normal relations attained by inward rotation of the limbs. (See Fig. 523.)

FIG. 522.—The attitude after the correction of the anterior torsion by manual osteoclasis.

FIG. 523.—Showing the unaltered hip-joint relations after correction of the inward rotation of the limbs, and the type of fracture produced in the supracondylar region. (See Fig. 521.)

the same as for other cases.[1] It may be noted that the originality of this procedure is not in any of the details of treatment, all of which are old but because the correction of the deformity is determined in advance, regardless of the apparent security of the immediate reduction.

Operative Treatment.—Open operations may be considered as supplementary to manipulative reduction and are rarely required in early childhood. There are however cases in which the capsule is so contracted as to prevent reposition. In this event the joint is opened by the anterior incision between the tensor fasciæ femoris and the gluteus medius muscles, the capsule thoroughly stretched, the dislocation reduced and the limb fixed in the attitude that assures stability. The further treatment is conducted as in non-operative cases.

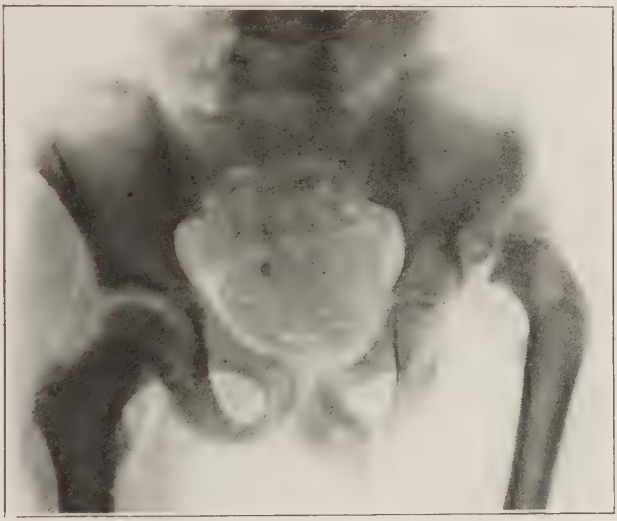

FIG. 524.—A case of neglected congenital dislocation showing the secondary acetabulum and deformity of the head.

The same procedure is usually effective in middle childhood if the resistance has been lessened by preliminary traction. The greatest obstacle to reduction is the shortened pelvi-trochanteric group of muscles, and if this is marked the trochanter should be cut through at the base and displaced upward as described in the reconstruction operation, after which it usually possible to reduce the displacement. The trochanter is then replaced.

In cases of this type the acetabulum is usually shallow and partly filled with fibroid tissue. It should be enlarged by the Doyen instruments if these are available, since a symmetrical cavity is assured. In many instances the limb must be rotated inward to assure secure reposition and at a later time the antetorsion must be corrected by

[1] Krida, A.: Am. Jour. Surg., February, 1929.

osteotomy or osteoclasis in the manner described. If the antetorsion is not extreme and if the new acetabulum is capacious subsequent correction may be unnecessary.

It must be borne in mind that the primary purpose of operative treatment is to prevent future disability by providing a stable support. In cases in which it has been necessary to reconstruct the acetabulum restricted movement to a greater or less degree is the rule, and in the after-treatment the first indication is to prevent deformity so that the range of motion shall be of the greatest service.

When the child begins to walk about there is a tendency, as in all operations on the hip-joint, toward flexion and adduction. It is advisable therefore to support the limb in extension and abduction by a plaster splint for several months, to be followed by mechanical stretching in extension and abduction for an indefinite time.

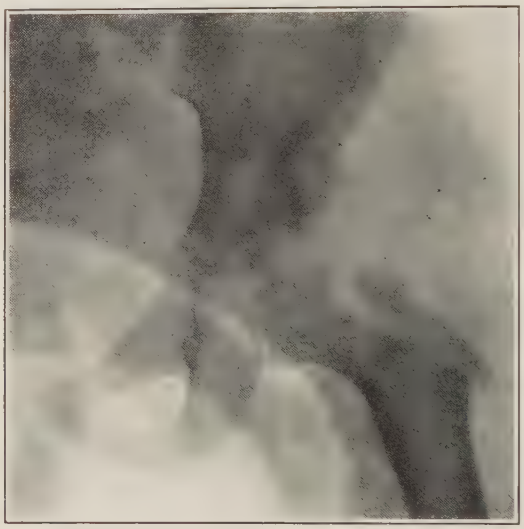

FIG. 525.—After the open operation showing the section of the trochanter and the capacity of the reformed acetabulum. (See Fig. 524.)

In cases in which the after-treatment has been efficient the results are usually satisfactory from the functional standpoint. Operative treatment of this character is indicated in unilateral dislocations and in bilateral cases in which manipulative reposition has been successful on one side.

In the treatment of bilateral dislocations the restriction of motion in the reconstructed joint must be considered and the second hip should not be operated on until the functional result of the first operation has been tested.

The Treatment of Older Subjects.—It has been stated that the final result the "bloodless operation" in a large proportion of the cases beyond the age of selection is anterior transposition or apposition, as

FIG. 526.—The Doyen instruments for enlarging the acetabulum.

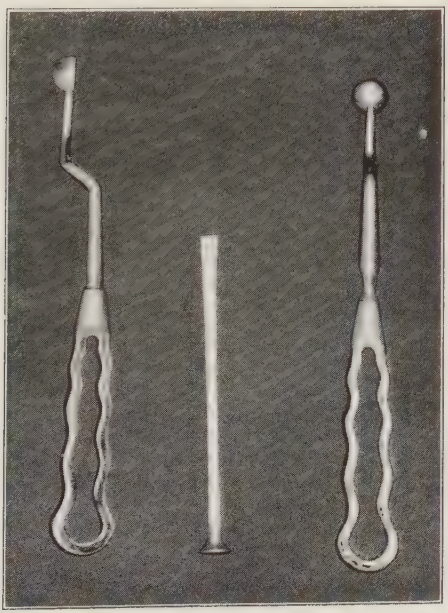

FIG. 527.—Scoops used in the treatment of congenital dislocation, also the subcutaneous osteotome.

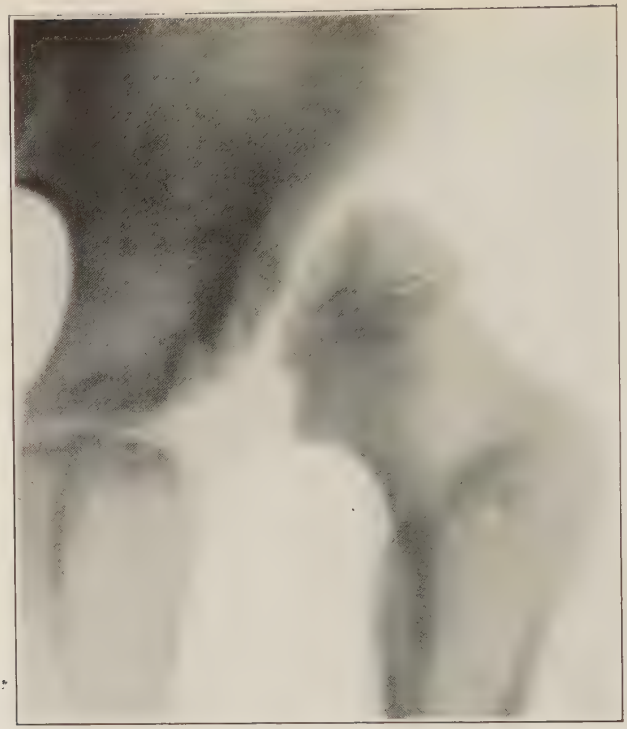

FIG. 528.—Congenital dislocation of the hip in adolescence. Shows the deformity of the head in adaptation to the secondary acetabulum. (See Fig. 529.)

FIG. 529.—After operation. Showing the reconstructed acetabulum in normal position. (See Fig. 528.)

MEDICAL LIBRARY THE BOSTON CITY HOSPITAL

Lorenz calls it, and in cases —from ten to twenty-one years of age— it may be the primary aim of the operation. After preliminary traction in bed and after subcutaneous division of the more resistant tendons if necessary, the limb is forced into moderate abduction and extreme extension, so that the head of the bone is displaced forward to the neighborhood of the anterior-inferior spinous process. In this attitude the limb is retained for many months by a plaster splint, and the attitude is assured in the after-treatment by the manipulation and exercises already described. Although even in the most successful cases a limp persists, it is far less noticeable than in untreated cases; the discomfort is relieved, the apparent shortening is overcome, and the prognosis as to future disability is much more favorable.

The Osteoplastic Buttress.—In certain cases a secondary acetabulum of fair depth is present, yet not sufficiently stable to prevent displacement, and others in which after an apparently successful reduction a subluxation follows at a later time because of deficiency of the upper border of the acetabulum. In this class an osteoplastic buttress may be constructed. This was first suggested by König,[1] and it has been employed in different forms by Clarke, Albee, Smith-Peterson and others.

Fig. 530.—The osteoplastic buttress to stabilize the secondary acetabulum. (Lance.)

Lance's[2] method is shown in Fig. 530. He exposes the joint by an incision between the sartorius and tensor fascia femoris, then with a chisel a large section of bone is separated from the ilium above the joint and forced downward. The interval thus formed is filled by sections of bone from the tibia. In operations of the type the Smith-Peterson method of stripping the muscles from the ilium gives a better exposure.

The Lorenz Bifurcation Operation.[3]—In cases of this type in which the discomfort and disability are extreme, Lorenz performs what he

[1] Ztschr. f. Chir., 1891, **17**, 146.
[2] Rev. d'orthop., October 19, 1925.
[3] Wien. klin. Wchnschr., 1919, No. 41.

calls the Bifurcation Operation. This in an oblique osteotomy of the femur opposite the acetabulum. The bone is cut from before backward on a line running downward and outward from just below the trochanter minor to a point about two inches lower on the external aspect of the femur.

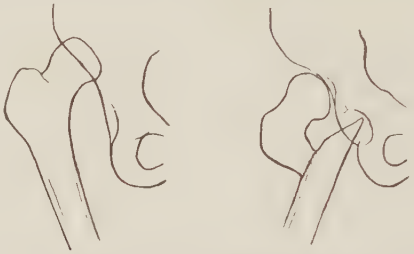

FIG. 531.—The left sketch represents an irreducible traumatic hip dislocation. The outlined roentgen-ray picture on the right side shows the anatomical results of the bifurcation. (Lorenz.)

The fragments are thoroughly separated and the pointed upper extremity of the shaft is thrust upward and inward against the capsule covering the acetabulum, the limb being abducted about 35 degrees. The upper fragment is thus apposed to the outer surface of the shaft, eventually uniting in this position. Thus security is attained while the muscles attached to the upper extremity of the femur permit a certain range of controlled motion (Fig. 531).

FIG. 532.—(Loeffler.)

FIG. 533.—(Loeffler.)

The bifurcation operation is of especial value in cases of bilateral dislocation in older subjects, accompanied by flexion and adduction contraction, particularly in those cases in which friction between the head

of the femur and pelvis is the source of discomfort. By this procedure the flexion and adduction of the limb may be corrected, security assured with a limited range of motion and pain relieved. It has the disadvantage in unilateral cases of increasing the shortening, but otherwise its mechanical effects are the same.

FIG. 534.—Unilateral dislocation. Two years after operation in 1897 by the Lorenz method. A complete cure.

FIG. 535.—Unilateral dislocation. Eighteen months after operation by the Lorenz method in 1897. A complete cure.

Review of the Treatment of Congenital Dislocation of the Hip.—The prospect of success in treatment stands in direct relation to the age of the patient, since the pathological changes that make cure difficult or impossible are proportionate, as in the acquired form, to the duration of the displacement. Consequently, treatment should be applied as soon as the dislocation is discovered, and, as has been stated, there is little excuse for not making the correct diagnosis when the child begins to walk. The treatment of selection is the functional weighting

method of Lorenz, modified somewhat in certain cases in that the limb may be placed with advantage in the position which best assures stability. In his last communication, from an experience in more than 1000 cases, Lorenz states that he has made no essential change in the operation. In general he advises against complete rupture of the adductors and against forcible increase of the capacity of the joint by rotation and pressure at the time of operation. The shortest period of fixation in the primary position should be six months, increased to eight or ten in certain instances. By this treatment a larger proportion of the cases may be cured, and in all instances the posterior may be changed into an anterior displacement, which is a great improvement. The treatment at the hands of a competent surgeon in properly selected cases is free from danger, for now that the strain that the tissues will safely withstand is better known, violent and prolonged manipulation has been discarded. In the older class, or when reduction is difficult, the resistant parts should be stretched by preliminary traction in bed, or the reduction should be accomplished at two sittings.

FIG. 536.—Shows developmental changes in the head of the femur after reduction of the dislocation in early childhood.

If manipulative reduction is difficult it should be supplemented by arthrotomy, and antetorsion of the upper extremity of the femur should be corrected by osteotomy.

Excavation of the acetabulum is often essential to anatomical success.

Anatomical reposition with fair or even very limited motion assures better function in unilateral cases than transposition, but anchylosis with deformity is certainly no improvement on the original condition.

In the treatment of adolescent cases one may attempt to obtain anterior transposition and to assure it by fixing the limb for a sufficient

time in the improved position. The bifurcation, the buttress, the reconstruction or other operation may be indicated in special cases.

It should be mentioned that in cases of congenital dislocation treated successfully there are changes preceding or subsequent to the operation in the articulation which may be classified as abnormal in possibly 50 per cent. of the cases. The head of the femur may be flattened or otherwise distorted resembling the Legg-Perthes disease. Its angle may be diminished (coxa vara) or its forward inclination may be increased (Fig. 536).

The acetabulum may be shallow or irregular in outline.

The capsule may be lax and the head of the femur may be prominent in the inguinal region and in some instances its cartilage may be eroded from injury during operative reduction.

These so-called incongruities may interfere with function and predispose to later changes resembling arthritis deformans and causing characteristic symptoms in later life. This emphasizes the importance of effective treatment in infancy or early childhood as the best assurance of normal development.

Palliative Treatment. Palliative treatment does not require extended comment. In brief, in unilateral cases a cork sole may be worn to equalize the length of the limbs, and in bilateral cases a corset suitably strengthened with steel supports may be adjusted if the lordosis is extreme. Exercise and passive manipulation with the aim of retaining, as far as possible, the ability to abduct and to extend the thighs may be of service in preventing secondary contractions. Overexertion that causes discomfort or pain should be avoided.

FIG. 537.—Putti's cushion. (Courtesy of the Jour. Bone and Joint Surg.)

CONGENITAL SUBLUXATION OF THE HIP.

There are cases of congenital displacement of the hip which are in reality subluxations and others which present abnormalities at the joint causing a slight limp and slight shortening. In such cases a roentgen-ray picture may show an enlarged acetabulum somewhat above the plane of the opposite side, or an abnormal laxity of the

capsule. True subluxations are usually of the anterior variety. They should be treated in the ordinary manner. As has been stated it is only in exceptional cases that one has an opportunity to treat congenital dislocation before the walking age when the limp or waddle attracts attention.

Putti[1] has reported results in 24 cases treated in early infancy. At this age the dislocation is often incomplete and it may be effectively treated by fixing the limbs in wide abduction on a triangular cushion (Fig. 537). This is removed twice daily for manipulation in abduction and inward rotation. Cure is usually complete before the walking age.

SNAPPING HIP.

Some individuals possess the power of slightly displacing the head of the femur, usually upon the superior or upper border of the acetabulum. This is sometimes seen in infancy, the child's thigh snapping with a jar or even audible sound upward and downward. This is usually accomplished when the child is seated in the mother's lap, the thigh being flexed and adducted, and in this class of cases it is, according to the mothers, an evidence of temper. As a displacement may be increased by habit, it is well to restrain it by applying a bandage about the hip to prevent flexion of the limb, which is apparently preliminary to its accomplishment. (See Snapping Knee.) Snapping about the hip in older subjects is usually induced by friction between the tendon of the gluteus maximus muscle or iliotibial band and the trochanter. The limb flexed at the knee is rotated inward and the tendinous attachment of the gluteus maximus springs backward on the trochanter. It is in a degree an accomplishment which is apparently increased by practise. The treatment is to divide the band and to sew each half to the underlying tissues.[2]

HYPERMOBILITY OF THE JOINTS.

This may be a congenital peculiarity apparently more common in males than females.

COXA VARA.

Synonym.—Depression of the neck of the femur.

The character of this deformity is indicated by the synonym. The term coxa vara signifies that its causes and effects are similar to those of genu valgum and varum, the more common distortions of the lower extremities.

Genu valgum and varum are common in childhood, but rarely develop in adolescence. Coxa vara is, in comparison, an infrequent deformity, and it is peculiar in that it more often attracts attention in later childhood or adolescence than at the earlier period, doubtless

[1] Jour. Bone and Joint Surg., October, 1929.
[2] Jones, F. W.: Jour. Orth. Surg., January, 1920.

because the neck of the femur is, at the age when rhachitic distortions are common, very short, and the capsule comparatively lax, so that restriction of motion due to deformity causes only slight functional disability.

FIG. 538.—Traumatic coxa vara, illustrating the normal anatomical checks of abduction on the right side and the restriction of the range caused by deformity on the left side.

The distortions at the knee are apparent, but the neck of the femur is concealed from view; thus the diagnosis of coxa vara is more difficult; and, in fact, it is only in comparatively recent years that its symptoms have been recognized. Fiorani first described the deformity as it had been observed by him in children; but E. Müller first applied the name to an acquired deformity of adolescence, which, until that time, had been mistaken for hip disease and whose true nature as an epiphyseal fracture was established by the specimens that he obtained by excision.

Etiology and Pathology.—The term coxa vara in an unqualified sense should not be applied to depression of the neck of the femur that may be secondary to local or general disease, for example, to osteomyelitis, osteitis fibrosa, osteomalacia and the like, but it should be reserved for cases of simple local deformity.

From the symptomatic and therapeutic standpoint there are three types of coxa vara:

1. Coxa vara of early childhood corresponding to the other rhachitic deformities of the lower extremity[1] in which the neck is depressed upon the shaft or in which the angle is relatively lessened by outward bowing of the upper part of the shaft. The depression may be directly downward but it is usually downward and backward.

[1] Humphrey: Jour. Anat. Phys., vol. **23**, 236.

This form of coxa vara is usually bilateral, although not always symmetrical on the two sides. (Fig. 541.)

Unilateral cervical coxa vara in childhood as distinct from the bilateral form is usually of traumatic origin—incomplete fracture. It may be in rare instances a congenital deformity and it is not infrequently a minor complication of congenital dislocation of the hip. In the typical rhachitic cervical coxa vara of childhood the head of the femur or epiphysis retains a relatively normal relation to the neck, and the obliquity of the epiphyseal junction may be even lessened, protecting it from displacement. (Fig. 540.)

Fig. 539.—Section of the upper extremity of a normal femur at eight years of age; angle formed by the neck with the shaft 140 degrees. In the normal subject the neck of the femur projects slightly forward (12 degrees) and upward to form an angle with the shaft of about 125 degrees. In childhood this angle is usually somewhat greater, and in later years it may be somewhat less than 125 degrees; in fact, a variation between 110 and 140 degrees may be within the normal limit.[1] Both anterior torsion and upward inclination are much greater at birth than in adult life. The length of the neck varies from 5.9 to 8.17 per cent. of the length of the shaft.

Bilateral cervical coxa vara in adolescence is often a further development of a preëxisting rhachitic deformity of childhood induced by the instability of rapid growth and the disproportionate strain of a laborious occupation.

In the more extreme degrees of the adolescent type of cervical coxa vara, the increased pressure upon the femoral head usually lessens its elevation and may eventually force it below the line of the upper border of the neck. In such cases there are usually also accommodative changes in the acetabulum. Cervical coxa vara in adolescence may be unilateral or bilateral and, as in childhood, the unilateral form may be caused directly by injury.

2. The second type of coxa vara is what is called the epiphyseal form, in which the head of the femur is displaced in a direction downward and backward upon a neck which retains its normal angle. This type is found only in later childhood and adolescence and is in reality a form of fracture. Epiphyseal displacement is far more common at the hip-joint than elsewhere because the epiphysis is joined to the projecting neck on an oblique plane and is therefore relatively unstable. This type of deformity is essentially one of adolescence because this is the period of rapid growth, therefore, of instability of tissue, when the protecting covering of cartilage has become thin in preparation for final union of the epiphysis and diaphysis. This mechanical predisposition to deformity is supplemented by structural weakness in rapidly

MEDICAL LIBRARY OF THE BOSTON CITY HOSPITAL

growing adolescents some of whom present the evidence of endocrine disturbance (Fig. 553). Thus, unilateral epiphyseal coxa vara in normal individuals is usually a direct effect of injury, while in bilateral epiphyseal coxa vara there is usually what may be called a constitutional predisposition to displacement (Fig. 556).

3. The third form of coxa vara is the combination of the cervical and epiphyseal forms—the epiphyseal displacement in adolescence complicating a previously existing rhachitic cervical coxa vara or, as in some instances, the two forms progressing simultaneously. In this type of deformity constitutional predisposition is almost always present.

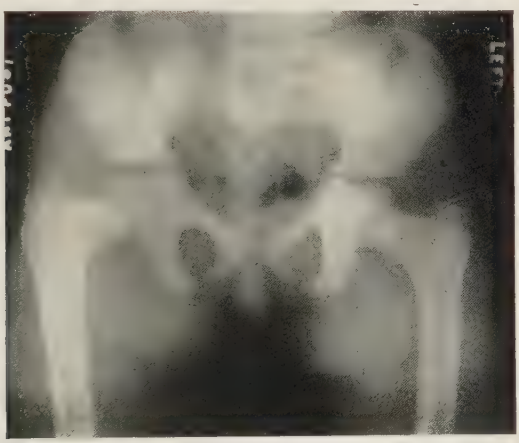

FIG. 540.—Typical rhachitic coxa vara, showing the relation of the head and neck which lessens the tendency to displacement of the epiphysis.

Thus it will appear that in the etiology of all forms of coxa vara considered as apart from actual disease of which deformity is simply an incident, constitutional predisposition, overweight or strain and direct injury are the important factors.

Excluding coxa vara as one of the distortions of general rhachitis in early life, the deformity is distinctly one of later childhood and adolescence. It is much more common in males than in females, and in at least three-fourths of the cases unilateral, indicating apparently the relative importance of injury in the etiology.

Symptoms.—1. **Mechanical Effects.**—The character of the symptoms may be explained by a description of the distortion and of its direct effects upon the function of the joint. When the neck of the femur is depressed, for example, to a right angle with the shaft, the trochanter is elevated to a corresponding degree above Nélaton's line,[1]

[1] Nélaton's line (Elément de Path. Chir., Paris, 1847): Patient lies upon the side with the limb flexed to 90 degrees, and slightly adducted. In this attitude a line drawn from the anterior-superior spine to the most prominent part of the tuberosity of the ischium passes across the tip of the trochanter and approximately the center of the acetabulum. According to Preiser (Berlin, 1911) the trochanter is usually slightly above the line (40 per cent. on the line). In extreme adduction it is about 3 cm. below, and in extreme abduction 6 cm. above the line. In the extreme of extension the trochanter is below, in flexion above the line. In inward rotation below and in outward rotation above the line.

FIG. 541.—Rhachitic coxa vara. In cases of this type the most significant diagnostic sign is limitation of abduction.

and forms a noticeable projection as contrasted with the normal contour (Fig. 547), a projection that becomes more marked when the thigh is flexed and adducted (Fig. 546). In most instances the neck is twisted backward following the line of least resistance in its downward course, and as the head of the bone remains in the acetabulum the trochanter is thrown forward and the limb is rotated outward. The ability to abduct the thigh is dependent upon the upward inclination of the femoral neck (Fig. 538); when, therefore, this inclination is diminished the range of abduction is lessened, in part by the greater tension that is exerted upon the lower portion of the capsule, in part by the direct contact of the rim of the acetabulum with the neck (Fig. 542), and in part by the adaptive muscular retractions that always accompany

Fig. 542.—Skiagram of coxa vara; deformity most marked at the epiphyseal junction. This illustrates the mechanical limitation of abduction caused by the deformity, and the compensatory tilting of the pelvis. The patient is shown in Fig. 547.

distortions of this character. The distortion of the neck in a direction backward and downward changes its relation of the acetabulum, so that abduction or flexion tends to displace the head of the femur from its socket. Thus the range of abduction, of inward rotation, and of flexion is limited, while that of adduction, outward rotation, and extension may be increased.

There is an actual shortening of the limb proportionate to the depression of the neck of the femur. This is not often more than an inch in the ordinary type of adolescent deformity, but the apparent shortening, caused by the adduction and the accommodative upward tilting of the pelvis, may be extreme; from two to three inches is not uncommon (Fig. 547).

2. **Physical Effects.** The symptoms of coxa vara of the ordinary type are *discomfort, awkwardness, limp, shortening, atrophy, limitation of motion, deformity.*

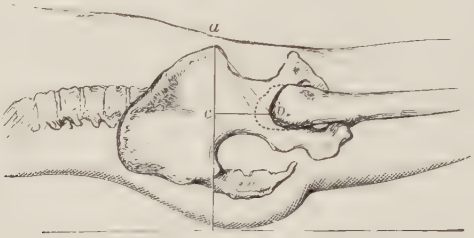

FIG. 543.—Bryant's triangle.

Bryant's drawing and description of his triangle: This triangle when drawn on each side shows clearly by contrast an elevation of the trochanter and its relation to the anterior-superior spine. Its chief value in Bryant's opinion was to demonstrate an impacted fracture of the hip. The triangle is formed as follows, and is a right-angled triangle. It is figured above (Fig. 543). One side of the triangle is represented by a line, *a b*, drawn from the anterior-superior spinous process of the ilium to the top of the trochanter major. The second, *a c*, is drawn from the anterior-superior spinous process of the ilium directly downward to the horizontal plane of the recumbent body. And the third, *c b*, which is the base of the triangle, is drawn at right angles to *a c* and falls upon the line, *a b*, where it touches the great trochanter.

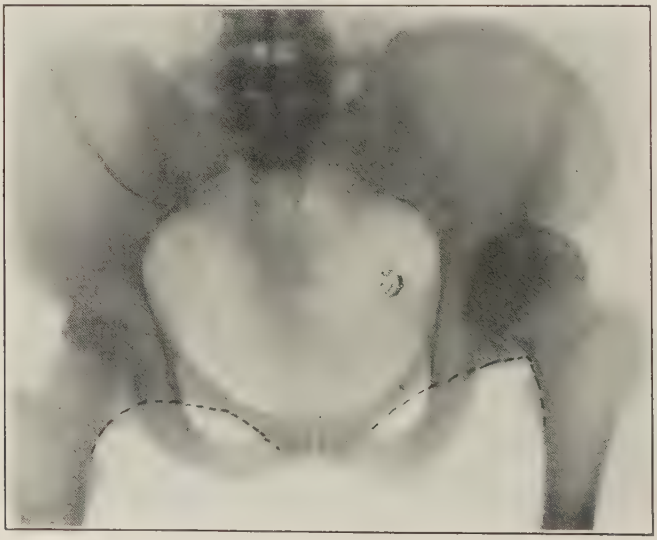

FIG. 544.—Shenton's line.

Shenton's Line.—E. W. H. Shenton (*Diseases in Bone, etc.*, London, 1911) first called attention to the unbroken arch formed by the upper border of the obturator foramen and the femoral neck, irrespective of the attitude of the limb. The contrast in contour in a case of arthritis deformans is shown in this figure.

Coxa vara is a more disabling deformity than genu varum or valgum, and its attendant symptoms of discomfort, weakness, and pain are, as a rule, more marked. This is explained by the fact that in coxa vara the anatomical relations of the articulation are disturbed (Fig. 545), while in the deformities at the knee the joint surfaces remain in practically normal relation to one another.

The symptoms of *unilateral coxa vara* vary with the degree and with the duration of the deformity and particularly whether it is progressive or stationary. The patient usually complains of sensations of stiffness and weakness, referred to the thigh. These are more noticeable on changing from a position to rest to one of activity, and at times, par-

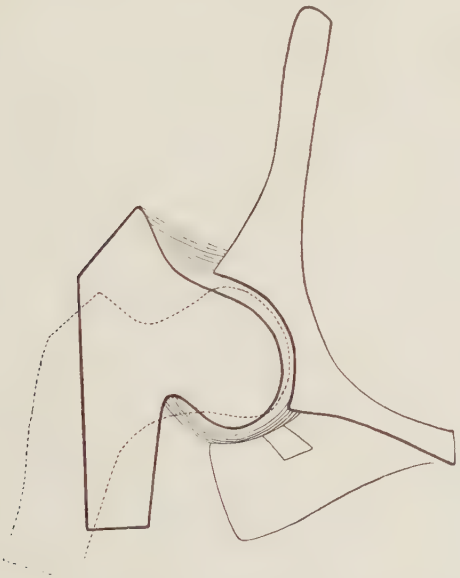

Fig. 545.—Cross-section of the pelvis and the deformed femur. A scheme to show the effect of the deformity of the combination type in limiting abduction of the limb. The dotted outline shows the normal relation.

ticularly after over-exertion, there may be actual pain. By far the most important symptom, since it is the one that usually brings the patient under observation is the limp. This limp, accompanied, as it usually is, by outward rotation of the limb, resembles that caused by united fracture of the neck of the femur. On physical examination the actual shortening, explained by the elevated and prominent trochanter and the peculiar unequal limitation of motion, will make the diagnosis clear. In some instances there may be a marked degree of muscular spasm, and there is usually moderate atrophy of the muscles of the thigh.

Bilateral Coxa Vara.—If the deformity is bilateral its effect upon the gait and attitude is more marked. The gait is extremely awkward,

resembling somewhat that of knock-knees, for the limitation of abduction forces the patient to sway the body from side to side in order that the knees may not interfere; and if the deformity is extreme the limbs may be crossed over one another, so that locomotion may be difficult. In the ordinary form of bilateral coxa vara the femoral neck on each side is displaced backward as well as downward, and as the head of the femur remains in the acetabulum the shaft is thrown forward, so that the trochanter is nearer the anterior-superior spine than is normal. This displacement of the support lessens the inclination of the pelvis and consequently the normal lumbar lordosis. Bilateral coxa vara is not infrequently accompanied by other deformities, as, for example, knock-knee and flat-foot (Fig. 548), and it is usually an indirect result of former rhachitis or of constitutional weakness while in unilateral coxa vara injury (fracture) is the most frequent cause.

Other Varieties of Coxa Vara.—Far less often, the neck of the femur may be depressed directly downward or even downward and forward. In the latter instance, the effect of the deformity upon the function of the joint is somewhat different from that of the ordinary type. Abduction is limited, as in the common form, but inward rotation replaces outward rotation, and extension is limited in place of flexion. This type of deformity is almost always bilateral. It is accompanied, usually, by slight permanent flexion of the thighs; thus the lumbar lordosis is exaggerated; whereas in the ordinary form it is usually lessened.

This description applies to the ordinary types of the deformity as it is seen in later childhood and in adolescence. It is not uncommon in early life as one of the rhachitic deformities but it is masked by the more noticeable distortions of other parts (see Fig. 541). It is usually bilateral and it may be suspected whenever abduction is markedly limited. This form is rarely presented for treatment but it is important as a predisposing cause of the progressive deformity of later years. In some cases of the rhachitic type, however, the deformity may cause discomfort and awkwardness during the earlier years, the disability becoming more noticeable in later childhood, indicating a continuity of symptoms.

In the majority of cases of the ordinary type the symptoms begin insidiously, in the unilateral form often as the result of injury or overexertion. (See Epiphyseal Displacement.) If the affection begins in adolescence and is untreated, the period of discomfort, during which the depression of the neck may be assumed to be progressive, is from two to four years; but if the deformity appears at an early age, the symptoms, though remittent in character, may continue indefinitely. When the resistance of the compressed bone becomes sufficient to ensure stability the discomfort ceases, and the disability becomes less marked, as Nature accommodates the mechanism to the new conditions.

Diagnosis.—In most instances diagnosis may be easily made, and yet coxa vara is very often mistaken for *hip disease;* in fact, we are indebted

to this mistake for the specimens of the deformity that have been described. The essential differences between the two are as follows: In tuberculous disease of the hip the movements of the joint are limited in every direction by reflex muscular spasm, and, as a rule, other evidences of the character

Fig 546.—Coxa vara, showing the prominent trochanter.

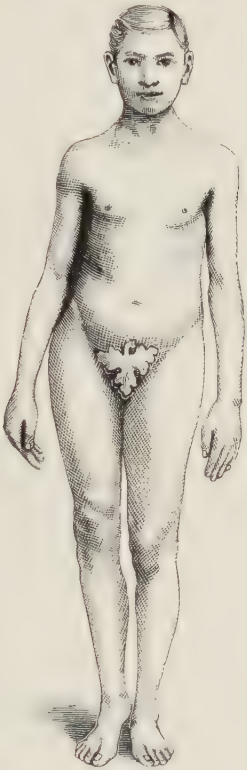

Fig. 547.—Illustrating the tilting of the pelvis and the apparent shortenl ing of the limb in unilatera-coxa vara. Actual shortening, three-fourths of an inch; apparent shortening two and a half inches. The deformity of the epiphyseal type was apparently induced by overexertion. (Fig. 542.)

of the disease are apparent. Coxa vara is a simple deformity; reflex muscular spasm is absent, except during exacerbations due to injury or overstrain, and movement is not limited in all directions, but only in abduction, flexion, and inward rotation when the deformity is of the ordinary type. Actual shortening is a late symptom of hip disease, while it is present from the very onset of coxa vara. It is a shortening explained by the elevation of the trochanter above Nélaton's line, while such elevation in hip disease is a sign of destruction either of the head of the bone or of a part of the acetabulum.

The deformity in young subjects might be readily mistaken for *congenital dislocation of the hip*, particularly of the anterior variety, but this would be excluded by the history, since coxa vara is essentially an acquired deformity. The diagnosis between the two affections may be easily made on the physical signs alone. In congenital dislocation, if the thigh be flexed and adducted to its extreme limit, the head and neck of the displaced bone can be outlined beneath the distended tissues of the buttock. In coxa vara nothing but the prominent trochanter can be made out on similar manipulation, while the abnormal mobility, characteristic of the dislocation, is absent. There is, however, a form of anterior dislocation in which the head of the femur has a secure support beneath the anterior-superior spine in which diagnosis from the physical signs alone may be somewhat more difficult. A roentgen-ray picture will always make the distinction clear, however.

FIG. 548.—Bilateral coxa vara of an extreme degree, showing the involuntary crossing of the limbs in flexion which increases the adduction.

Treatment of Cervical Coxa Vara.—If the deformity were detected in a very early stage one might hope to check its progress by lessening the strain upon the weakened bone by restricting the activities and in the stage of active rhachitis by appropriate constitutional and local treatment.

Forcible Abduction.—In certain instances, particularly those cases in adolescence in which the symptoms have advanced rapidly, it may be inferred that the bony structure of the affected neck is congested and softened. And during the active stage of rhachitis in early childhood the neck of the femur may be sufficiently yielding to permit a certain degree of correction by forcible abduction of the femur. In this man-

MEDICAL LIBRARY BOSTON

cuver the head is fixed by the lower portion of the capsule, and the deformed neck is forced against the upper border of the acetabulum as illustrated in the diagrams (Fig. 552). If the normal range of abduction and inward rotation can be attained, one may infer that the deformity has been corrected. The limb or limbs should then be fixed by a plaster spica bandage in this attitude of extreme abduction and inward rotation until consolidation in the new position is apparently complete. Afterward protection and reconstructive treatment should be continued until repair is complete.

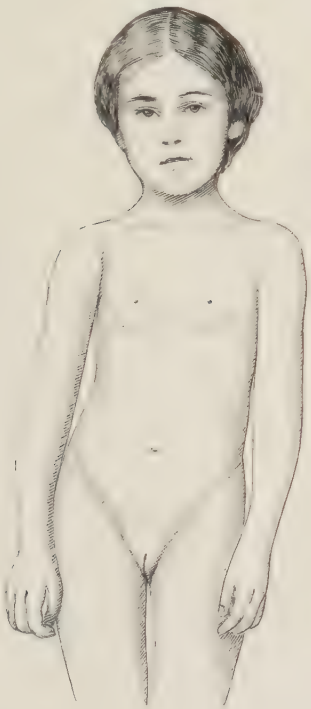

Fig. 549.—Unilateral coxa vara, showing the effect of slight depression of the neck of the left femur upon the attitude. (See Fig. 550.)

Fig. 550.—The patient, Fig. 549, eight months after cuneiform osteotomy. An absolute cure, both as regards symptoms and deformity.

Linear Osteotomy.—The most practicable means of overcoming the deformity in older subjects in which extreme outward rotation indicates backward distortion of the neck is linear or curved osteotomy of the shaft of the femur just below the trochanter minor. This may be performed by the subcutaneous method, as in the correction of the deformity of hip disease or by open division. When the bone

has been divided the shaft is rotated inward to the proper degree, and it is then under traction abducted to the normal limit; in this attitude a plaster spica bandage is applied, reaching from the axilla to the toes.

If the deformity is bilateral it is often sufficient to operate on the limb which is most affected. When the fracture is consolidated, massage, exercises, and manipulation are employed, as has been described. It may be assumed that the increased blood supply necessitated by the repair of the injury will affect favorably the weakened bone as well.

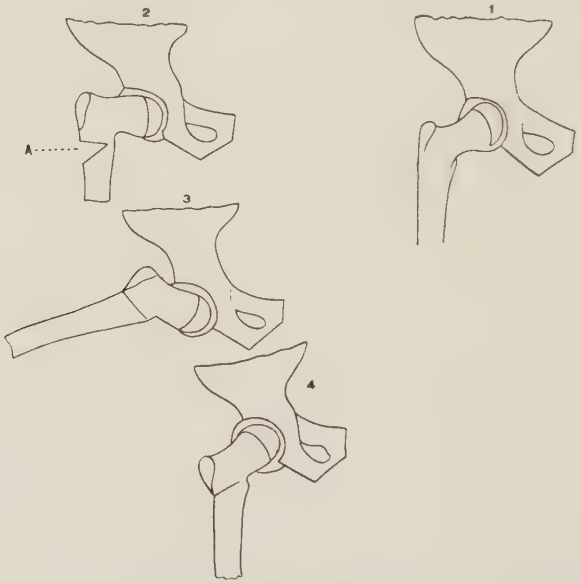

FIG. 551.—*1*, the normal femur; *2*, depression of the neck of the femur—coxa vara; *A*, a wedge of bone has been removed; *3*, abduction of the limb first fixes the upper segment by contact with the rim of the acetabulum, then closes the opening in the bone; *4*, replacement of the limb after union is completed elevates the neck to its former position.

Cuneiform Osteotomy.—If outward rotation is not marked the deformity should be remedied by removal of a cuneiform section of bone from the upper extremity of the shaft at the level of the trochanter minor (Fig. 551). In childhood the neck of the femur is short and the strain to which it is likely to be subjected slight; thus operative treatment may be indicated as a prophylactic measure. In fact, one should treat this deformity at the hip on the same principles as the similar distortions at the knee. Coxa vara cannot be rectified by mechanical treatment; therefore, unless it is directly contraindicated, operative intervention should be advised.

In the technic of this procedure there are several points of importance. First, the secondary restriction of abduction, of ligamentous or muscular region, must be overcome by vigorous stretching and

massage of the shortened tissues before the operation on the bone. An incision is made from a point about one inch below the apex of the trochanter directly downward about three inches in length. The bone is thoroughly exposed by separating the periosteum from the site of operation. The base of the wedge should be about three-quarters of an inch in breadth, directly opposite the trochanter minor; the upper section should be practically at a right angle with the shaft, the lower being more oblique (Fig. 551, *2*). The situation and size of the wedge-shaped resection necessary to restore the normal angle of the neck may be determined by making a paper model from a roentgen-ray

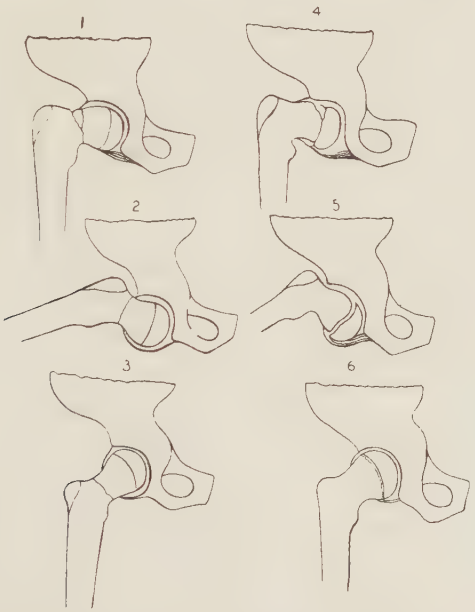

Fig. 552.—*1*, fracture of the neck of the femur; *2*, restoration of the normal angle by forcible abduction; *3*, the limb in normal position; *4*, *5*, and *6* illustrate separation of the epiphysis of the head of the femur treated by the same method.

picture. The cortical substance on the inner aspect of the bone should not be divided, but, reinforced by the cartilaginous trochanter minor, should serve as a hinge on which the shaft of the femur is gently forced outward, until the opening is closed by the apposition of the fragments after the upper segment has been fixed by contact with the margin of the acetabulum (Fig. 551, *3*); thus the continuity of the bone is preserved. The limb is then fixed in the attitude of normal abduction by means of a plaster spica bandage, which should include the foot also, for about eight weeks, or until the union is firm. When the limb is brought to the line of the body the neck of the femur is restored to its proper position (Fig. 551, *4*). This mechanical method of apposing the fragments is absolutely effective. This method in which the exact section of bone required to correct the deformity may be determined

by a roentgen-ray picture and in which the continuity of the bone is preserved has a manifest advantage over a simple osteotomy in which there is danger of displacement of the fragments.

The opportunity for treatment of coxa vara in earliest childhood is rarely offered. It is usually the direct result of rhachitis and it is probably always accompanied by other rhachitic distortions. It would be well, therefore, to examine the hip-joints of rhachitic children, especially those who present the deformity of genu valgum with reference to this distortion.

As has been stated, unilateral cervical coxa vara in otherwise normal subjects is usually of traumatic origin, a fracture unrecognized at the time of the injury.

FRACTURE OF THE NECK OF THE FEMUR IN CHILDHOOD.

"Traumatic Coxa Vara."—Fracture of the neck of the femur in childhood, contrary to established teaching, is by no means uncommon. A large number of cases have come under my observation since 1890, when I first called attention to the subject.[1] It is seen in two forms: Fracture of the neck proper usually caused by direct violence, and fracture at the epiphyseal junction with the head. This form is practically limited to adolescence.

Simple Fracture.—Fracture of the neck of the femur in childhood differs somewhat in its symptoms and in its effects from that in later life. Although it may be complete, it is often what may be termed the "green stick" variety. Thus, the immediate effects of the injury are far less disabling, and the patient is often able to walk about within a few days or weeks after the accident. During the period of repair the limp and attendant discomfort are usually mistaken for symptoms of hip disease and at a later time it is classed as coxa vara.

Diagnosis.—The diagnosis is not difficult even without roentgen-ray examination. There is a history of injury, usually a fall from a height which confined the patient to the bed for several days or weeks. On physical examination shortening of half an inch to an inch is found, explained by the corresponding elevation of the trochanter. Motion in the joint is more or less restrained by voluntary and involuntary contraction of the muscles, but this restriction is much more marked in flexion, abduction, and inward rotation than in other directions; a limitation explained by the nature of the displacement, the neck of the bone having been forced downward and backward.

The immediate effect of the injury is, as has been stated, less marked than in the adult, but the deformity tends to increase in later years, because the right-angled relation of the neck to the shaft exposes it to greater strain. In a number of the patients examined several years after the injury there was an increase of the actual shortening combined with permanent adduction. At this time the deformity could not have

[1] New York Med. Jour., February 7, 1891; New York Med. Rec., February 25, 1893.

been distinguished, except for the history, from the ordinary coxa vara of a rather extreme degree.

Treatment.—If the diagnosis is made immediately or before consolidation is complete, one should attempt to replace the neck in its proper relation with the shaft in order to restore normal function and to prevent subsequent disability. The patient having been anesthetized, the limb, under manual traction, should by gentle force be rotated inward and then gradually abducted, the upper border of the acetabulum serving as a fulcrum for leverage by means of which even resistant deformity may be corrected. In this position of complete abduction and extension a plaster spica, reaching from the axilla to the toes, should be applied (Fig. 552).[1] After consolidation of the fracture a Lorenz spica may be used for several months or until complete repair has taken place. Massage and passive movements, if limitation of motion persists, should restore function if the deformity has been overcome.

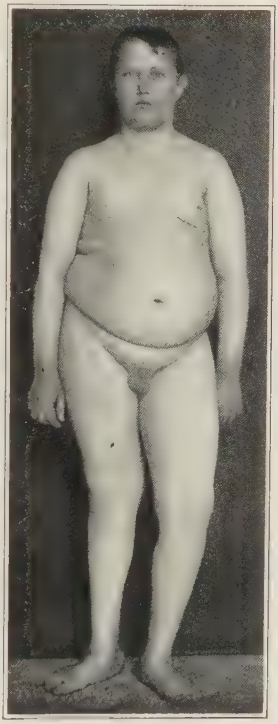

FIG. 553. — Epiphyseal fracture of the neck of the right femur, illustrating the type of patient (adipositas hypogenitalis) especially predisposed to such injury and the characteristic attitude of the limb, also the knock knee and flat feet. In cases of this so-called endocrine group thyroid extract may be of service to reduce weight and possibly to hasten repair.

In the cases in which the fracture has united, the neck of the femur should be replaced in its normal position by the removal of a sufficient wedge of bone from the base of the trochanter as described under the treatment of simple coxa vara (Fig. 551). The same treatment applies also to congenital coxa vara or other forms of fixed deformity, in which there is but slight backward displacement linear osteotomy will be indicated in order to correct the outward rotation of the limb.

Epiphyseal Fracture or Coxa Vara.[2]—As has been stated, epiphyseal coxa vara, the type originally described by Müller, is in reality an incomplete fracture of the neck of the femur. The exciting cause of displacement is apparently a superficial fracture at the superior portion of the junction of the head and neck, or possibly a less direct injury that weakens the immature bony structure on the diaphyseal side of

[1] The abduction treatment for this class of cases was first described in the Annals of Surgery, June, 1897.

[2] A. Schmidt (Ztschr. f. Orthop. Chir., **2,** 1927) considers both types of adipositas, hyper- and hypo-genitalis, as predisposing factors in the Legg-Perthes disease as well as of Coxa Vara, the precocious genital development being more common in girls.

the cartilage. Then follows gradual downward and backward displacement of the head upon the neck, the rate of progress being determined by the strain or injury to which the weakened tissues are subjected. Thus, under favorable conditions the process of repair may check further deformity, or the weakened junction may give way completely and the lame patient become suddenly disabled.

The clinical history and physical signs in a typical case are as follows: The patient, usually after injury which, however, may pass unnoticed, begins to limp, to complain of occasional stiffness and discomfort at the hip or knee on changing from rest to activity, and of pain after exertion.

These symptoms, usually passing as "rheumatism," persist and increase, often for months, even to the point of practical disability, before the patient comes under observation.

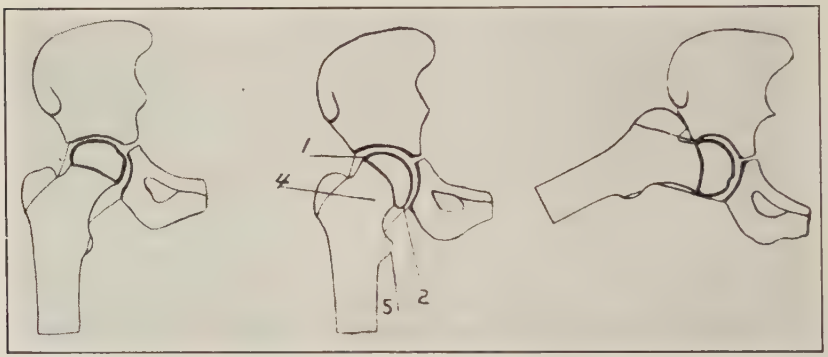

A B C

FIG. 554.—A scheme (Nicola) to illustrate the progression and correction of the deformity. A. The normal joint. B. The changes observed in the roentgen-ray picture in the early stage of epiphyseal displacement. 1. The upper border of the head and neck form an unbroken line in the same plane. 2. The lower border of the epiphysis projects downward in its relation to the neck. 3. The neck appears, because of the outward rotation, shorter and thicker than the normal and the trochanter minor more prominent. 4. The trochanter minor. C. Shows that in complete abduction pressure is removed from the epiphyseal junction (see Fig. 555).

If any treatment is instituted it is usually for "hip disease," the pain, the limitation of motion and the blurred outline about the cartilage in the roentgen-ray picture seeming to establish such a diagnosis. Yet to one familiar with this type of injury the diagnosis is almost self-evident.

The patient is an adolescent, and although he limps, the weight is borne on the entire foot rather than on the toes. There is persistent outward rotation of the limb, which is increased by flexing the thigh; actual shortening is present, but rarely exceeds half an inch; passive movements are restricted to a greater or less degree in flexion, abduction, and inward rotation, while extension, the movement first limited in disease, is actually increased in range.

In other words, the muscular tension symptomatic of disease, checks all the movements of the joint in fairly equal degree, while in this form of injury they are mechanically accommodated to a head displaced downward and backward upon the neck. In the rapidly progressive stage of deformity, or of secondary fracture, there may be practical fixation by muscular spasm, but in such instances the history and the attitude of the limb should make the diagnosis clear.

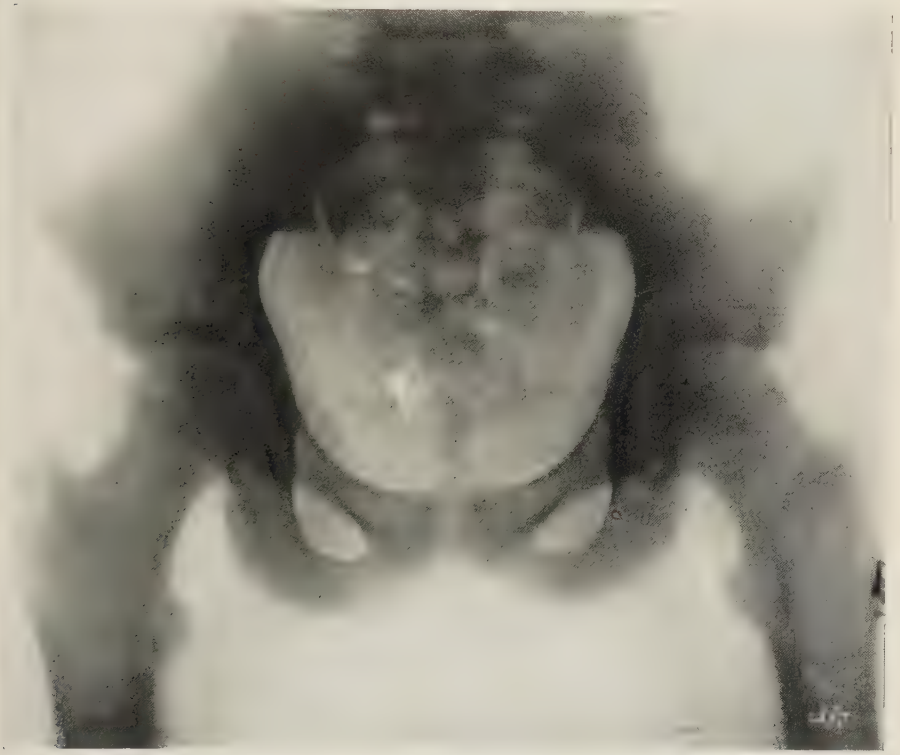

FIG. 555.—The changes indicated in Fig. 554 are shown in the roentgen-ray picture of the left hip illustrating an early stage of the progressive deformity.

The roentgen-ray picture is distinctive. Under normal conditions the head rises sharply above the upper border of the neck; in these cases the elevation is lessened and the outline of the head and neck may form an unbroken line.

The epiphysis, as compared with its fellow, seems shallow, and indication of backward displacement; the epiphyseal junction seems wider, and an actual separation may be present at its upper border.

The increase in width of the epiphyseal area is on the diaphyseal side and apparently indicates softened bone. This is sometimes discovered before the deformity is present, or at least apparent, and the subsequent displacement is attributed to a preëxisting local disease;

but since this disease never progresses, and since it disappears after the correction of deformity, it seems more reasonable to ascribe the softening to injury which, although it may precede displacement, is usually coincident with it.

Treatment.—As has been stated, in typical cases the characteristics are those of a progressive deformity, the character of which is indicated by the symptoms and by the restriction of the range of motion. Thus, downward displacement of the head limits abduction, backward displacement limits flexion and inward rotation. Consequently restora-

FIG. 556.—Epiphyseal displacement in a boy, aged fourteen years, illustrating the progression of the deformity, see Fig. 557.

tion of the normal range in these directions implies the reduction of deformity. The primary indication for treatment, therefore, is to utilize the natural leverage, on which the abduction method is based, to overcome the restriction of motion.

Thus, in cases in which the progression of the deformity has been rapid or in which there has been a fracture of the weakened junction, manipulative correction may be attempted. The pelvis having been fixed by abduction of the sound limb, the limb on the injured side is abducted to the degree permitted by the deformity. At this point the

BOSTON CITY HOSPITAL

upper rim of the acetabulum coming into contact with the neck serves as a fulcrum, and the head being fixed by the tense capsule, further abduction tends to force the extremity of the neck downward into normal relation with the head.

In cases in which the displacement is too great, or the consolidation too advanced for correction by indirect force, open reduction will be necessary, as described in a former paper.[1]

Fig. 557.—After reduction. Taken through the plaster spica. Contrast with Fig. 556.

The joint is opened by an incision between the tensor fasciæ femoris and sartorius muscles exposing the neck, which, in cases of advanced deformity, practically conceals the head. From its extremity a sufficient section of bone is removed to permit the insertion of a thin chisel between the two fragments, then by rotation of the limb and leverage on the instrument the head is replaced in normal position.

The removal of bone is of little consequence since the epiphyseal cartilage is always adherent to the head fragment. In fact as the patients are usually well developed adolescents one may with advan-

[1] Whitman: New York Med. Record, January, 1909.

tage perforate and cut away parts of it in order to hasten the bony union that assures stability.

Thus, from the therapeutic stand-point, these patients may be divided into three classes:

1. Cases of incipient deformity in which it is only necessary to fix the limb in the attitude of abduction and inward rotation for a time sufficient to permit consolidation of the weakened junction.
2. Cases in which the deformity may be corrected by forcible manipulation.
3. Cases in which the open operation is necessary.

FIG. 558.—Ambulation may be permitted in suitable cases of fracture of the neck of the femur in childhood during the stage of repair because weight is borne upon the outer border of the neck and trochanter. (See Fig. 554–C.) Figure reproduced from an early paper. (Medical Record, March 19, 1904.)

In all cases the limb is fixed in abduction and inward rotation for a period long enough to permit consolidation, or about three months, during which locomotion may be permitted in suitable cases, since weight is supported by the trochanteric region of the femur. This is followed by exercises to restore muscular power and control, and naturally by general and special supervision and treatment, constitutional and local, as may be indicated.

Bilateral cases are treated on the same principles, but, as a rule, the

constitutional predisposing weakness is far more important than in unilateral cases. In cases of the combined type in which the angle of the neck and shaft is lessened and in which the head is still further forced downward it may be necessary, after replacing the head, to perform an osteotomy of the shaft, as already described. Cure in advanced cases of the endocrine type can be attained only when the epiphyseal junction has been consolidated and in certain cases of the type the insertion of a bone graft through the neck into the head may be advisable to assure stability. In cases of irremediable deformity the reconstruction operation may be indirect.

The abduction treatment for fracture of the neck of the femur in adults is fully described in Chapter XXIV.

FIG. 559.—Coxa valga in an adult. An extremely rare deformity.

COXA VALGA.

Coxa valga is a term used to signify an abnormal elevation of the neck of the femur in its relation to the shaft, in contrast to coxa vara, an abnormal depression. It is usually congenital. It is sometimes observed in limbs which have never supported weight, and it is a possible result of injury also. The symptoms in extreme cases are an awkward gait, the limb being rotated outward and abducted. The deformity is very uncommon and is of slight importance. Sixteen cases have been collected by Maullaire and Oliver.[1]

Treatment should be directed to lessening the limitation of adduction. This may be manipulative or by force under anesthesia followed by retention in the attitude of adduction. In rare instances osteotomy to reduce the angle of the neck may be indicated.[2]

[1] Arch. gén. de chir., vol. 4, 15, 1.
[2] Young: Univ. Penna. Bull., January, 1907.

CHAPTER XVI.

DEFORMITIES OF THE BONES OF THE LOWER EXTREMITY.

Of the distortions of the lower extremity, bow-leg and knock-knee are by far the most common. Of the two, bow-leg is the more frequent in all tables of statistics, and it is probable that the proportion of bow-leg to knock-knee is much larger than would appear from the hospital records; for genu valgum is generally recognized as a serious deformity, while bow-leg is thought to be of little consequence except from the esthetic stand-point, so that its rectification is more often trusted to the power of natural outgrowth.

Both deformities appear to be more common in male than in female children—a fact explained, perhaps, by the greater weight and the greater susceptibility of the former. But here, again, statistics may be influenced somewhat by the fact that bow-leg is considered to be of more consequence to the boy than to the girl, because of the concealment that the skirts may ensure if the distortion is not outgrown in childhood.

Statistics.—The relative frequency of the two deformities may be indicated by the statistics of the Hospital for Ruptured and Crippled for a period of fifteen years. During this time 8760 cases were recorded, 5741 cases of bow-leg (65.5 per cent.), 3019 knock-knee (34.5 per cent.). Of the 5741 cases of bow-leg 3401 were in males (59 per cent.) and 2340 were in females (41 per cent.). The 3019 cases of knock-knee were more evenly divided between the sexes, 1610 being in males (50.04 per cent.) and 1409 in females (49.06 per cent.).

It will be noted that 94 of the cases of knock-knee were in patients over fourteen years of age, as compared with 78 cases of adolescent or adult bow-leg. It may be noted that a large proportion of the cases of genu valgum actually developed or increased to an extent demanding treatment during adolescence, while most of the cases of bow-leg deformity in patients more than fourteen years of age had existed since early childhood or were the result of injury or disease.

The Etiology of Genu Valgum, Genu Varum, and of Other Distortions of the Bones of the Lower Extremity.—The common predisposing cause of primary deformities and disabilities of the lower extremities—in other words, those not caused by local disease—is the erect posture, when for any reason the bones and the joints are unequal to the strain of locomotion and to the task of sustaining the weight of the body.

Time of Onset.—At two periods of life the deformities under consideration most often develop. The first is in early childhood, when

the upright posture is first assumed; the second is in adolescence, when the rapid growth and other changes incident to this period may lessen the stability of the supporting structures, and when the strain of laborious occupation may be added to that of the increasing weight of the body.

The deformities of adolescence are, however, relatively insignificant in number compared with those of early childhood, for in childhood weakness, whether inherited or acquired, at once develops into deformity under the strain of the erect posture. Thus, as a rule, the deformities under consideration first attract attention soon after the child begins to walk. If they are marked the body usually presents the evidences of general rhachitis; in other instances the distortion of the legs is almost the only sign of its presence, and in a certain number there may be no evidence whatever of malnutrition or disease.

Predisposition to Deformity.—It is not always easy to explain why weak legs bend in one way rather than in another. In many instances it may be assumed that a slight degree of deformity is present before the child begins to walk. For example, a slight outward bowing of the legs is not uncommon in early infancy, and the use of heavy diapers might favor an increase of the distortion. Knock-knee may be induced, apparently, by holding the infant on the arm with the knees pressed against the chest, and certain cases of knock-knee and bow-leg combined appear to be caused directly by this manner of carrying the infant habitually upon one arm.

The legs of rhachitic children who may have never walked are often somewhat distorted and in many instances this may be explained by the habitual postures (Fig. 560).

A moderate degree of bow-leg is not infrequently seen in vigorous infants who stand and walk at an early age. Aside from the determining curve in the bone that may be present before the child begins to walk, this predisposition toward bow-leg may be explained, perhaps, by the fact that young infants often separate the feet widely in walking, and the swaying of the body from side to side may tend to bend the legs outward. In weaker or less vigorous children a slight degree of knock-knee is not uncommon, induced more directly by weakness or inactivity of the muscles, as a result of which the child stands with the knees somewhat flexed and pressed together, while the feet are separated and everted, an exaggeration of the so-called attitude of rest.

Bow-leg is not uncommon in adult life, and it is popularly associated with strength and activity. Undoubtedly the attitudes of activity would tend to induce bow-leg rather than knock-knee, so that this tradition may have a foundation of truth. It is said to be common among those who ride constantly, and it may be a direct result of injury or disease of the knee-joint, but it may be stated that well-marked bow-leg in an adult has almost always existed since childhood. This statement cannot be made of genu valgum, since it may develop or increase during adolescence or even in adult life. The predisposing

cause is weakness or overstrain, and, as has been stated, in the popular mind the deformity is characteristic of weakness.

The Attitude of Rest.—Genu valgum is an exaggeration of what is known as the attitude of rest or relaxation, in which the weight of the body is thrown in great part upon the ligaments of the three joints of the lower extremity. In the attitude of rest the pelvis is tilted forward, the femora are rotated inward upon the tibiæ, and the feet are separated and everted, so that the greatest strain falls upon the inner side of the knees and of the feet. Thus, what is known as flat-foot is in childhood often combined with knock-knee. Knock-knee may cause flat-foot,

Fig. 560.—Habitual posture as a factor in the etiology of rhachitic bow-leg.

but more often the flat-foot may induce knock-knee, or both may be the effect of the same general cause. Genu valgum, in the slighter degree at least, may be induced directly by improper attitudes; but the attitudes are, as a rule, the result of overwork to which the mechanism is subjected; thus the knock-knee of adolescence is so common among the bakers of Vienna that "baker's knee" is there synonymous with genu valgum.

Genu valgum may be secondary to distortion elsewhere. For example, compensatory knock-knee is usually combined with fixed adduction of the thigh; it may be the result of the inactivity neces-

sitated by the treatment of hip disease; it may be a direct result of injury, and it is sometimes an accompaniment of osteomyelitis or osteoperiostitis of the tibia, which causes an overgrowth and abnormal lengthening of the leg. These are, however, exceptional cases that should not be classed with the ordinary deformity.

The Outgrowth of Deformity.—In considering the treatment of the simple static deformities of the lower extremity, which are usually the result of a temporary weakness of structure, one must first answer the question, "Will not the child outgrow it?" This belief in the spontaneous cure of deformity is very strong, not only among the laity, but among physicians as well; and it rests upon the common observation that crooked legs may become straight, or at least less deformed, with the growth of the child. In fact, if one were to judge from the general observation of the effect of growth upon the deformities of this class, or even from the tracings of the legs of rhachitic children taken from year to year, one might conclude that all deformities of this class might be safely left to themselves. As an illustration of positive evidence on the subject, the observations of Kamps[1] on 32 cases of rhachitic distortion of the lower extremity may be cited. Four and one-half years after the cases were first seen and recorded examination showed that 75 per cent. were cured, 15.3 per cent. improved, while 9.7 per cent. were unimproved. His conclusions are that such deformities do not, as a rule, require special treatment in early childhood, but that after the age of six years the prognosis for spontaneous cure is unfavorable.

Veit[2] photographed a number of rhachitic children seen in the surgical clinic of the University of Berlin, and after a lapse of two or three years made another series of photographs of the same patients, who had meanwhile received no treatment. His conclusions are similar to those of Kamps, namely, that surgical treatment is not required for deformity of this character in children less than six years of age. In two classes of cases, however, the prognosis for spontaneous cure is not favorable, those in which the growth has been checked by the rhachitic process, and in certain cases of extreme bow-leg, "O" legs (Fig. 561).

The rectifying force of Nature acts in two ways. Assuming that the deformity reached its limit during the period of original weakness, it must, of course, become relatively less as the body increases in length and size. In fact, the outgrowth of deformity has a direct relation to the rapidity of growth during the early years of childhood. It must be borne in mind also that not infrequently rhachitic bones are bent in two or more directions, so that knock-knee and bow-leg may be combined in the same person. Thus the bow-leg may be outgrown while the knock-knee persists or even becomes less noticeable. The second manifestation of the power of Nature is more positive. It may be assumed that when the deformity is progressive all the tissues are

[1] Beitr. z. klin. Chir., Band **14**, Heft 1.

[2] Arch. f. Chir., B. **1**, S. 130.

affected by the weakness; consequently the attitudes of the child are those that can be most easily assumed under the abnormal conditions. But when the primary cause of the weakness, in most instances rhachitis, is no longer operative, the muscles take on new activity and vigor, and the actions and attitudes, in spite of the deformity, become approximately normal. Then, according to Wolff's law of transformation, the internal structure of the affected bones begins to change in accommodation to the new conditions of weight and strain induced by the change in action and attitude; and to this rearrangement of the internal structure the external shape of the bones must conform in a gradual growth toward the normal contour.

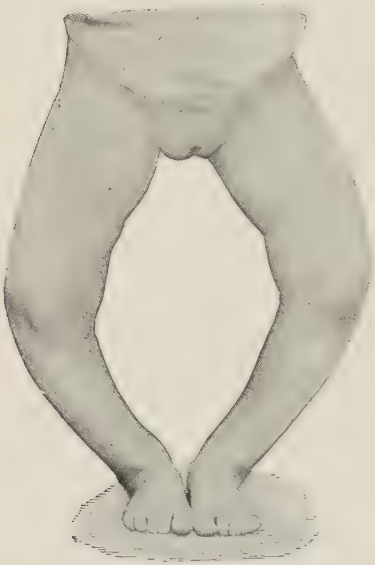

FIG. 561.—A type of deformity in which the prognosis as regards outgrowth is bad.

On this theory it is easily explained how the natural outdoor life of the country has long been celebrated as an effective treatment for this class of deformity. It by no means follows, however, that deformity is always outgrown even under favorable conditions. Improper attitudes that favor and cause deformity are often observed among those who are free from weakness and disability and from the influences of unfavorable surroundings; and such attitudes are, of course, more likely to persist in those who were once obliged to assume them because of weakness and deformity. Again the weakness of structure or function may be an inherited peculiarity, or it may be induced by disease or by improper surroundings, influences that may continue for many years and thus serve to check the natural tendency toward cure.

The observations on the outgrowth of deformity have been confined, as a rule, to the period of childhood, and most often they have been made with reference to the more serious grades of distortion, which are the direct result of rhachitis. It must be borne in mind, however, that the true significance of these deformities in the adult must be judged from the esthetic rather than from the medical point of view, and although the extreme degrees of bow-leg and knock-knee are relatively rare, yet in the minor grade both deformities are very common in adult males and in all probability in adult females also.

In 1887 the writer[1] noted among 2000 adult males observed on the streets of Boston 400 cases of bow-leg and 32 cases of knock-knee.

[1] New York Med. Rec., July 30, 1887.

MEDICAL LIBRARY BOSTON CITY HOSPITAL

One may assume, then, that the legs of about one adult male in five deviate more or less from the line of symmetry—a conclusion that has been confirmed by many subsequent observations.[1] It may be admitted that a certain number of the distortions under consideration are acquired during adolescence, but it is probable that the greater number of those that may be noted in walkers upon the streets represent the incomplete outgrowth of a deformity of childhood.

FIG. 562.—Extreme deformities, the result of infantile rhachitis. The left leg forms practically a right angle with the thigh. (See Fig. 566.)

The statement is often made that these distortions of the legs are common in childhood, but rare in adult life. Just what the proportion may be in childhood it is impossible to say, but it is not likely to be greater than one in five. One must conclude that statistics, on which such statements are based, have been made up from the records of hospitals where it is unusual for an adult to apply for the treatment of bow-leg, to which he has become accustomed since childhood, unless the deformity is extreme or causes discomfort.

Granting that the power of Nature is quite sufficient to modify or to cure even the more extreme distortions of childhood, still it is

[1] The original observations were necessarily confined to males, but the change of costume in recent years has furnished evidence that the conclusions apply equally to feminine limbs.

evident that this natural force is often ineffective in completing the cure. Therefore, in doubtful cases at least, one should lend assistance in that class of patients likely to appreciate the advantage of symmetry over deformity, even though it be unattended by discomfort or disability.

GENU VALGUM.

Synonyms.—Knock-knee, in-knee.

In the erect posture the thighs, whose upper extremities are separated by the pelvis and by the projecting femoral necks, incline slightly inward to the knees, forming an angle at the knee, opening outward, of about 172 degrees. The inward inclination varies with the breadth of the pelvis, and it is therefore more marked in adult females than in males (Figs. 563 and 564). The internal condyle of the femur is slightly longer than the external; thus the inclination of the femur is compensated and the plane of the knee-joint is horizontal.

Fig. 563.—Female.

Fig. 564.—Male.

Figs. 563 and 564.—The normal inclination of the femora. (Pfeiffer.)

Symptoms.—When the inward projection of the knees is increased to a noticeable degree the tibiæ are no longer perpendicular; their upper extremities incline inward so that in the erect posture the feet are separated when the knees are in contact (Fig. 565). In the slighter grades of knock-knee, which are due in great degree to laxity of the ligaments, the deformity is apparent only when the weight of the body is borne, but in more marked cases, although the distortion is increased by the weight of the body, it cannot be overcome when this is removed, because it depends upon actual changes in the shape of the bones themselves.

As has been stated, the normal inward inclination of the femur is compensated by the greater length of the internal condyle, and in the deformity of knock-knee the plane of the knee-joint is still preserved by an apparent elongation of the inner condyle. Formerly it was

supposed that there was an actual overgrowth of this part of the epiphysis which caused the deformity, but this apparent lengthening is in reality, due in great part to a deformity of the lower extremity of the shaft of the femur, which is so bent that the epiphyseal line has an increased obliquity. And the hypothesis that bone grows more rapidly when relieved from weight and strain has been disproved by Wolff, who has demonstrated that changes in the bones are the result of accommodation to altered function and attitude. The deformity is not limited to the femur; in most instances there is a similar, although

Fig. 565.—Adolescent knock-knee. Deformity most marked in the tibiæ. (See Fig. 569.)

usually slighter, irregularity in the epiphyseal line of the upper extremity of the tibia, the shaft being so bent that when it is placed in the perpendicular position its internal condylar surface is higher than the external. In some instances the primary and principal deformity is of the shaft of the tibia, the distortion being most marked in its upper third (Fig. 565).

Changed Relation of the Femur and Tibia.—In addition to the direct deformities of the bones there is a change in the relation of the femur to the tibia. The former is rotated inward and the latter is rotated outward. In some instances there is also a certain degree of overextension

at the knee. This is more often observed in the adolescent type, in which there is laxity of the ligaments (Fig. 565). In the ordinary form of rhachitic knock-knee in childhood the habitual attitude is one of slight flexion at the knees, and in extreme cases there may be actual limitation of the range of extension at the knee, and at the hip as well.

The Accommodative Attitude.—When the limb is fully extended the deformity is most marked, because the shortened ligaments and tissues on the outer aspect of the joint become tense, and because the outward rotation of the tibia is increased. As the leg is flexed the deformity

Fig. 566.—Skiagram of Fig. 562, showing the deformity to be due to distortions of the diaphyses of the bones, while the epiphyses are practically normal.

lessens, and in the attitude of complete flexion it disappears (Fig. 569). This is explained by the fact that the posterior surface of the condyle is not affected by the deformity of the shaft, while the relaxation of the ligaments and the outward rotation of the femora allow the tibiæ to become parallel with one another. This accounts for the habitual attitude of slight flexion which is so often assumed by patients who thus unconsciously accommodate themselves to the deformity.

Secondary Deformities.—The outward inclination of the leg throws more weight upon the inner border of the foot and tends to depress it

into the attitude of valgus. Thus knock-knee in weak children is often accompanied by flat-foot, but in the more extreme grades of deformity the efforts of the patient to compensate for the abnormal separation of the feet may result in habitual inversion (Fig. 565); in fact, confirmed and extreme knock-knee in older subjects is usually accompanied by a slight degree of varus that become very evident after the correction of the deformity by operation. Even in the mildest type of knock-knee this compensatory and conservative effort of Nature is shown by the so-called pigeon-toed walk, which is often the first symptom that attracts attention.

Fig. 567.—Deformity of the femur in genu valgum. (Mikulicz.)

Gait.—The gait of the patient with well-marked genu valgum is peculiarly awkward and shambling. The knees "interfere" and must be assisted, as it were, in the effort to pass one another in walking. In the slighter cases the thigh is abducted and rotated outward at the moment of passing its fellow, the movement being then reversed as it, in its turn, supports the weight; but in the more severe type this voluntary effort of the muscles of the leg is not sufficient, and, in addition, the body is swayed from side to side and the legs are alternately swung outward and lifted around one another.

The deformity and the effects of the deformity on the gait and attitude are the most important symptoms, as of other distortions of similar origin. The patient is, as a rule, easily fatigued, and pain during the progressive stage, referred to the inner side of the knee, where the ligaments are subjected to continuous strain, is a common symptom, particularly in the adolescent type of genu valgum.

Unilateral Knock-knee.—This description refers particularly to the cases in which the deformity is bilateral. Not infrequently it is unilateral, the limb being so shortened by the distortion that a well-marked limp replaces the swaying gait. The pelvis is tilted toward the short limb, while the body is inclined in the opposite direction, thus in cases of long standing a permanent curvature of the lumbar spine may be present.

Knock-knee Combined with Bow-leg and with General Rhachitic Distortions.—Occasionally the unilateral knock-knee may be accompanied by an outward bowing of its fellow; and in the marked distortions of the lower extremity, induced by rhachitis, the bones may be twisted and bent in various directions, although the outward expression of the deformity may be genu valgum. For example, the femora may be bent forward and outward above and inward and backward below, while the tibiæ may be bent inward above and outward and forward below.

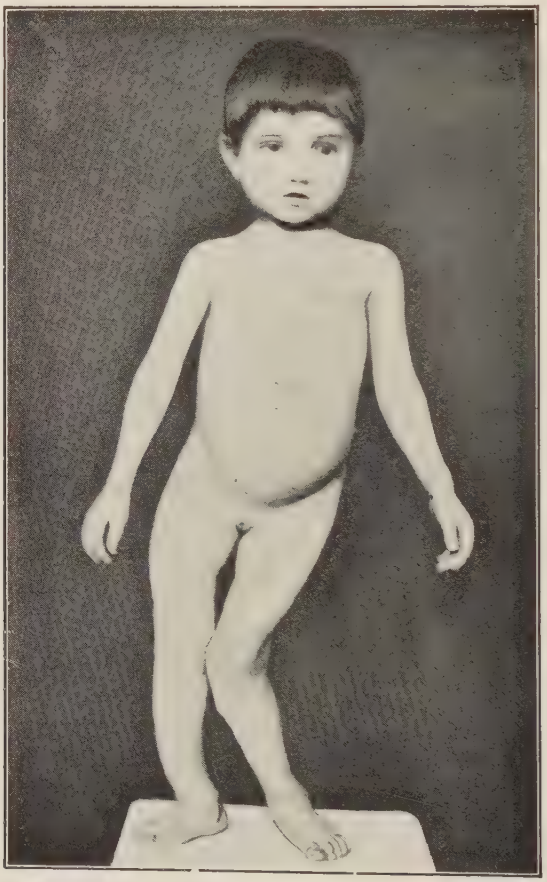

FIG. 568.—Knock-knee and bow-leg.

This type is noted particularly in Italian children and is caused apparently by carrying the child on one arm.

In other instances, especially in the slighter rhachitic deformities, an outward bowing of the leg may accompany a slight degree of knock-knee, so that it may be difficult to classify the deformity.

In the more extreme deformities of the rhachitic type the shape as well as the contour of the bones is markedly modified, for example,

the internal border of the tibia may become very prominent at its upper extremity, and may project beneath the skin like an exostosis (Fig. 568). A change in the contour of the fibula accompanies and corresponds to that of the tibia, although it is, as a rule, much less pronounced. As has been stated, the internal structure or architecture of the affected bones is changed to accommodate the new static conditions, and according to Wolff the internal change precedes the external deformity.

Measurements.—There are various methods of measuring the deformity. One of the simplest and most practical is to trace the outlines on paper, while the child is seated with the limbs fully extended, the knees being sufficiently separated to allow the pencil to pass between them. The increase of the deformity, depending upon the laxity of the ligaments and upon the outward rotation of the tibiæ, may be estimated by measuring the distance between the two internal malleoli when the patient stands, the knees being slightly separated as before, and comparing this measurement with that between the similar points in the tracing.

Pathology.—In knock-knee due directly to rhachitis the changes in the bones and in the epiphyseal cartilages are characteristic of that affection, but in the milder grades of deformity, aside from the change in the contour of the bones, the transformation of the internal structure, and in some instances slight thickening or irregularity of the epiphyseal cartilages, there is little noteworthy change from the normal (Fig. 566). The tissues on the internal aspect of the joint are relaxed; those on the outer side, the lateral ligaments, the capsule, and the biceps muscle, are contracted and resist the reduction of the deformity. In the interior of the joint slight changes in the articulating surfaces of the bones and evidences of chronic irritation to the synovial membrane have been described.

In the early stages of progressive knock-knee, particularly in the type not caused directly by rhachitis, laxity of ligaments and the habitual assumption of the attitude of rest will account for the deformity, which the patient may be able to overcome, in great degree at least, by voluntary effort. This voluntary control of the deformity is very suggestive, as indicating certain factors in its etiology, and the principles that should be followed in its treatment.

Treatment.—The treatment of the deformity under consideration may be classified as expectant, mechanical, and operative.

Expectant Treatment.—This should not be expectant in the sense that nothing is done to correct the deformity, but expectant in that more positive treatment by braces or by operation is delayed or avoided if it proves to be unnecessary.

During this period the predisposing cause of the deformity, if it is constitutional, should receive proper dietetic or medicinal treatment, as already described in the chapter on Rhachitis. And, if possible, the direct exciting causes of the deformity must be removed—that is to say, the improper attitudes, or, in the adolescent, the predisposing

occupations, should be discontinued. General massage of the limbs may be employed with advantage; in older children special exercises may be practised, and in all cases, whether braces are used or not, direct manipulation of the distorted limbs is of the first importance.

Manipulation.—The limbs should be vigorously massaged at morning and night, and forcibly straightened. The latter procedure is conducted as follows: The patient is seated in a chair, the limb being fully extended so that the deformity is made as extreme as possible. One hand then clasps the knee, the palm lying against its inner aspect; with the other the calf is grasped firmly and the leg is then gently straightened over the fulcrum formed by the palm of the hand, and is held in the corrected position for a moment. This manipulation should be continued with gradually increasing force, although not to the extent of causing actual pain, for ten minutes at least twice in the day and oftener if possible.

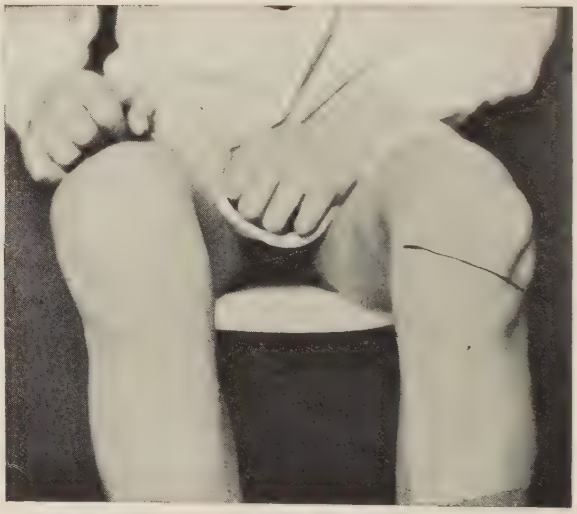

Fig. 569.—Adolescent knock-knee, showing the disappearance of the deformity when legs are flexed. (See Fig. 565.)

Posture and Exercise.—It has been stated that genu valgum is often accompanied, especially in the rhachitic cases, by flat-foot, while in another type the inversion of the feet, or in the more severe the actual fixed attitude of varus, indicates the effort of Nature to withstand and to compensate for the deformity at the knee. This serves as an indication to thicken the soles of the shoes on the inner border or to apply direct support as in the treatment of flat-foot, in order to throw the strain upon the outer border of the foot, or if the feet are weak, supports should be applied as in the treatment of flat-foot. The patient should be instructed to walk with the feet parallel with one another, and for older children the tip-toe exercises, in which the body is raised upon the toes as many times as the strength permits, or games or exercises

MEDICAL LIBRARY OF THE BOSTON CITY HOSPITAL

in which the legs are extended should be encouraged. Such exercises are often efficacious in the early stage of adolescent knock-knee, for, as has been mentioned, genu valgum is an exaggeration of the attitude of rest; therefore its progress should be checked by the assumption of the attitudes proper to activity. Bicycle riding, and particularly horseback riding, may be recommended also in this class of cases. A record of the deformity should be kept during this tentative treatment, and if it improves somewhat one is justified in delaying the more radical measures. This question may be decided, as a rule, in three months if instructions are faithfully followed.

FIG. 570.—The Thomas knock-knee brace.



FIG. 571.—Thomas knock-knee brace with pelvic band. The pelvic band may be divided also, the two parts being joined by straps (Fig. 572).

Treatment by Braces. The most efficient brace for the treatment of genu valgum is the simple straight steel bar or splint extending from the trochanter to the heel of the shoe, without joint at the knee. The greater efficacy of the rigid bar as compared with the jointed brace is explained by the fact that the rectifying force acts constantly when the joint is fixed, and because, in many instances, the patient

habitually flexes the knees so that direct pressure cannot be made upon the deformity by a brace that permits this attitude.

The Thomas Brace.—The simplest and cheapest brace is that of Thomas, which consists of a light steel bar provided with a pad at its upper end for pressure against the trochanter, while the lower, rounded extremity is turned inward at a right angle, to pass through the heel of the shoe. The knee is fixed by a posterior bar attached to a thigh and calf band, as illustrated in the figure. When the brace is applied the knee is drawn backward and outward and is attached firmly to the brace by a roller bandage (Fig. 570).

Fig. 572.—Modified Thomas knock-knee braces applied.

In the more extreme cases in which the knees and thighs are habitually flexed, the addition of a pelvic band attached to the uprights by a free joint at the hips adds to the comfort and efficiency of the apparatus, as the attitude of outward or inward rotation can be regulated by twisting the uprights slightly. Or preferably the pelvic band may be divided and attached by means of straps on the front and back. The uprights may be bent somewhat inward at first, and as the legs become straighter

they are straightened and finally bent slightly outward to allow for the overcorrection of the deformity (Fig. 572). Twice a day the braces should be removed for massage, manipulation, and for voluntary exercises of the limbs. In most cases the braces are not employed at night, although the rectification of the deformity may be hastened by their constant use.

If the deformity is unilateral so that a brace is required for one limb only, the other shoe should be raised by a cork sole about three-quarters of an inch in thickness, to make walking easier. Children soon become accustomed to the braces and walk easily in spite of the absence of joints at the knees.

Another simple and efficient brace is that used at the Children's Hospital at Boston (Fig. 573). The upper part of the brace is turned backward and upward to lie against the buttock, and the feet may be rotated in or out by lengthening or shortening straps passing before and behind the body. Braces jointed at the knee are sometimes employed, but they are, as a rule, ineffective, except in the slighter cases in which the deformity depends upon laxity of ligaments rather than distortion of bone.

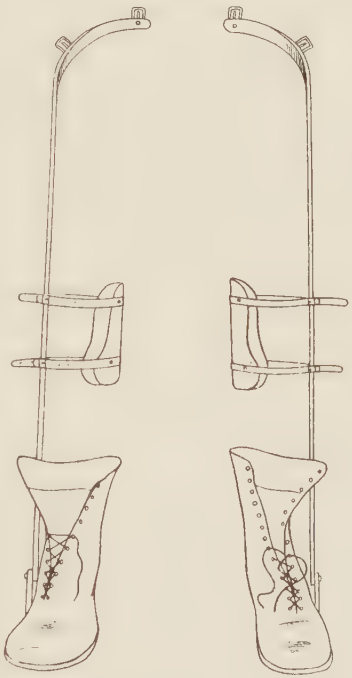

Fig. 573.—Long braces for genu valgum. (Bradford and Lovett.)

Duration of Treatment by Braces.—The duration of the brace treatment depends, of course, upon the degree of deformity, the age of the child, and upon the efficiency of the apparatus. From six months to one year of treatment by this means is usually required. The cure is assured by the gradual adaptation of the parts to the new static conditions. The contracted tissues of the outer aspect of the joint become lengthened; the lax ligaments on the inner side contract; the internal structure of the condyles and of the adjoining diaphysis is gradually transformed and at the external contour of the bone becomes correspondingly straighter. When the braces are discarded attention should be paid to the attitudes, and the exercises that have been mentioned should be continued in order that relapse may be prevented.

The Plaster Bandage.—When the bones are yielding, as in young children, the deformity may be corrected by the repeated applications of plaster bandages, the limbs being straightened as far as possible without causing discomfort at each sitting, or it may be corrected at once by manual force under anesthesia, which is the better method.

Operative Treatment.—Immediate correction of the deformity, when it is at all marked, is, as a rule, indicated after the age of four or five years, and is a satisfactory treatment at any age except during the period of active rhachitis. It is perhaps needless to remark that the necessity for operation implies neglect of proper preventive treatment or the failure of the manipulative and mechanical methods, because of their improper application. While it is possible to correct deformity of the bones by mechanical treatment in cases far beyond this limit of age, the time required and the discomforts of the treatment exclude it in all but very exceptional cases.

Osteotomy.—In a single year 146 cases of knock-knee were operated on at the Hospital for Ruptured and Crippled. The routine operation was supracondylar osteotomy of the femur (95 cases) by means of the small Vance osteotome, the so-called "subcutaneous osteotomy." In a certain proportion of the cases the bones of the thigh and leg are equally involved in the deformity. In others the tibia is the more distorted, requiring primary or secondary osteotomy, but in the ordinary case the correction of the deformity of the femur will practically restore the normal contour (Fig. 567).

The limb having been prepared in the usual manner is semiflexed, and the inner surface of the knee is placed on a firm sandbag. With the fingers the femur is firmly grasped just above the condyles, so that its size and position may be accurately determined, and the sharp osteotome about the size of a lead-pencil is forced with its cutting edge parallel to the axis of the thigh down to the bone, at a point about one inch above the external tuberosity. While it is held firmly in position against the bone it is turned in the transverse direction and is then driven through the cortex. When it enters the medullary canal, as is made evident by the lessened resistance, it is partly withdrawn and moved slightly to one side and the other, and driven through the cortical substance until by gentle force the bone may be fractured. The osteotome is then withdrawn; the minute wound is closed with a catgut suture. The deformity is then overcorrected sufficiently to simulate well-marked genu varum, and a plaster spica bandage is applied. If the deformity is bilateral both limbs are operated upon at the same sitting.

The plaster support is continued for from four to six weeks, and it is then usually supplemented by a brace, which may be worn with advantage for several months, because of the laxity of the ligaments of the knee-joint, which usually accompanies extreme deformity of rhachitic origin. In less marked cases and in older subjects the support is unnecessary. Massage and exercises during the stage of recovery should be employed if possible.

Incomplete osteotomy and fracture in the manner described have been employed at the Hospital for Ruptured and Crippled in a very large number of cases without an unfavorable result. The discomfort is insignificant, and confinement to bed after the third day is unnecessary. For one unexperienced in this type of operation and in

older subjects the exposure of the bone by a sufficient incision is advisable.

Cuneiform Osteotomy.—In the more extreme cases of general rhachitic deformity of the lower extremity in which the tibia is implicated, it is sometimes necessary, in addition to the osteotomy of the femur, to fracture the tibia also in order to distribute, as it were, the correction. In such cases it may be advisable to remove a cuneiform section of bone from the inner side of the tibia just below the epiphysis for more symmetrical adjustment of the fracture. In cases of this type it is better to perform the second operation at a later time in order that the effect of the femoral osteotomy may be observed. In exceptional cases the deformity may be practically confined to the tibia; in such instances it should be corrected by a primary cuneiform or linear osteotomy.

The linear osteotomy has the advantage that it lengthens the bone on the shorter side. The opening formed by correcting the deformity may be closed in part by sections of bone cut from the extremity of either fragment, or very satisfactorily by the insertion of a wedge of beef bone which assures the alignment.

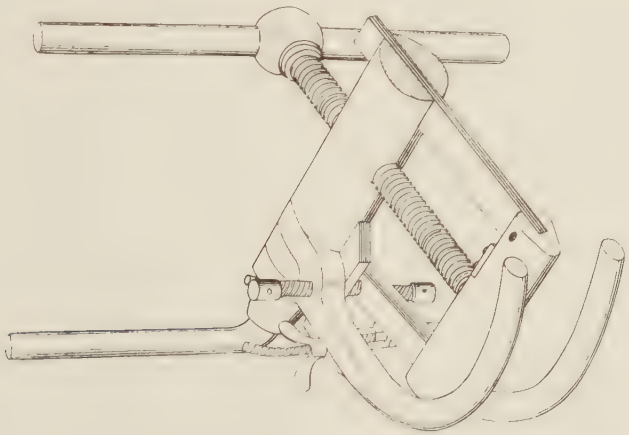

Fig. 574.—The Grattan osteoclast.

Osteoclasis.—Osteoclasis, by means of the Grattan osteoclast, is an effective operation. With this instrument the bone may be broken above the condyles at the point of election. The lower resistant bar is applied over the external condyle, the upper about 4 inches higher. The limb is then firmly fixed by the hands of an assistant, and the bar is screwed rapidly home, breaking or bending the bone at the point of pressure. The deformity is then overcorrected in the manner described. Not infrequently in rhachitic cases the principal or primary distortion is of the tibia. In such cases the correction is made at this point. If it is necessary to operate upon both the femur and the tibia the osteoclast, which bends and breaks, is to be preferred to osteotomy.

The adolescent type of genu valgum is not often extreme. As a rule the deformity of the bone is of comparatively short duration, and it is accompanied by considerable laxity of ligaments. In the well-marked cases osteotomy above the condyles may be performed in the manner described.

Wolff's treatment of gradual correction by plaster-of-Paris bandages ("Etappen Verband") and Lorenz's method of epiphyseal separation described in former editions have been omitted as offering no advantage over osteotomy or osteoclasis.

It may be noted that paralysis due to injury of the peroneal nerve may follow the correction of knock-knee. In a total of 1863 operations by osteoclasis reported by Codivilla there were 34 instances of the paralysis, 2 of which were permanent.

FIG. 575.—The genu varum type of bow-leg, showing the outward rotation of the femora.

FIG. 576.—The same patient, showing the separation of the malleoli when the knees are in contact.

GENU VARUM.

Synonym.—Bow-leg.

The term bow-leg includes, in its popular sense, all the distortions that cause a separation of the knees when the ankles are in contact

with one another. But, strictly speaking, genu varum is the reverse of genu valgum—that is, the principal distortion is at or near the knee-joint—while bow-leg, as the name implies, is a simple bowing of the tibia and fibula, as a rule, near the ankle-joint (Fig. 572). In true genu varum a line dropped from the head of the femur falls inside the knee (Fig. 561); the inner condyle of the femur and the inner tuberosity of the tibia bear the greater part of the weight; the outer condyle is on the same level or somewhat lower than the internal, and the outer tuberosity of the tibia may be somewhat higher than the internal. The femur is abducted and rotated outward; the tibia is

Fig. 577.—Genu varum of rhachitic origin in an adult, the primary deformity being of the femora.

rotated inward. These changes, it will be noted, are the reverse of those found in genu valgum. As has been stated, the deformity of genu valgum disappears on flexion, and in genu varum, if the limbs are flexed and the knees are placed in contact with one another, the malleoli may be actually separated, simulating the deformity of knock-knee (Fig. 576). This is explained by the inward rotation of the femora, necessitated by placing the knees in contact with one another.

In genu varum the distortion of the bones is not as strictly confined to the neighborhood of the knee-joint as in genu valgum, and in simple bow-leg there is almost always a certain degree of distortion at the knee, dependent, in part, upon laxity of the ligaments. It is proper, there-

fore, to use the two terms synonymously, although one must recognize a decided difference between the genu varum type, in which the deformity is greatest at the knee, and which is accompanied, as a rule, by marked laxity of the ligaments (Fig. 577) and the bow-leg type, in which the deformity may be limited to the lower third of the leg.

Symptoms.—As was said of genu valgum, the deformity is the principal symptom. The gait is somewhat rolling, because each foot must describe a part of the arc of a circle before reaching the ground; and because of the inward rotation of the tibiæ, or because of the inward spiral twist of the bone that is sometimes present, patients often toe-in in walking.

Except in extreme cases, the weakness and awkwardness characteristic of genu valgum are absent. This may be explained by the fact that the relation of the bones is such that the general attitude is one of activity, the weight falling on the outer side of the feet; thus the weak foot is uncommon as an accompaniment of bow-leg, except in the early or rhachitic type or as a compensatory deformity in older subjects.

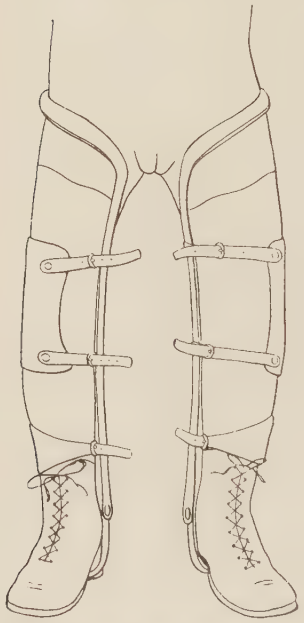

FIG. 578. -Long braces for genu varum. (Bradford and Lovett.)

Measurements. — The full effect of the deformity appears only when the weight of the body is borne, but for practical purposes the tracing of the extended legs is the best method of recording the fixed deformity. In true genu varum the deformity is greatest at the knee, and in the distortion the apposed surfaces of the femur and of the tibia participate.

In simple bow-leg the deformity may be confined to the tibia, which in addition to the outward bowing, may be twisted inward somewhat upon its long axis.

Genu varum may be unilateral or it may be combined with genu valgum of its fellow (Fig. 568), and occasionally slight knock-knee and slight bow-leg may be present in the same limb.

Treatment. — Expectant Treatment. — The slighter cases of bow-leg in early childhood and particularly in infancy may be treated by manipulation. The leg, grasped firmly at the ankle and at the knee, is straightened with a certain amount of force over and over again. Gradual correction by this means may be hastened by making the sole of the shoe slightly thicker on the outer border. This aids also in correcting the secondary pigeon-toe, but if the foot is weak, as it usually is in rhachitic cases, this method should not be employed, as it might induce flat-foot.

MEDICAL LIBRARY BOSTON

Treatment by Braces.—If the deformity is more extreme, or if improvement does not follow expectant treatment, apparatus should be employed. If the distortion is confined to the lower third of the tibia a Knight brace may be used. It consists of two uprights attached to a foot plate; the inner bar is provided with a pad at its upper end for pressure on the internal condyle of the femur. The outer bar reaches to the head of the fibula, and the two are joined by a calf band (Fig. 579). When applied the leg is drawn toward the inner upright by means of a lacing, which passes about it within the outer bar. When the lacing is made fast, the outer bar is adjusted to the contour of the leg, and thus it aids somewhat in supporting it in an improved position. The foot plate may be dispensed with, and the brace may be attached

Fig. 579.—The long (Napier) and short (Knight) bow-leg brace.

to the shoe, and even the outer bar may be removed, leaving only the upright, which is held in position by the lacing. The apparatus, then, has the appearance of a gaiter, and has the advantage of being inconspicuous, although somewhat less effective than the Knight brace. If the support is supplemented by vigorous manipulation the deformity may be corrected, in young children, in about six months.

If the outward bowing of the knee is marked another form of apparatus will be necessary, and its effectiveness will be much increased if there is no joint at the knee. The inner bar reaches to the upper third of the thigh. An inner straight bar extends to the upper third of the

thigh, and is attached to the outer bar by a thigh band. This inner upright is provided with a lacing of leather or canvas, similar to that of the short brace, which surrounds the knee and upper part of the leg, and thus draws it toward an improved position (Fig. 579).

Another form of brace is used at the Boston Children's Hospital, in which the upper part of the upright is curved upward and outward just below the groin, to a point on a level with and behind the trochanter, and is attached to its fellow by means of a strap passing across the buttocks so that the feet may be somewhat rotated outward if necessary (Fig. 578).

Operative Treatment.—In children over four years of age, and in cases of the more extreme type at an earlier age, or when the opportunity for mechanical treatment is lacking, or if rapid cure is desired, operative correction of the deformity is indicated. Either osteoclasis or osteotomy may be employed, and in some instances manual force is sufficient for the correction of the deformity. There is but little choice between the methods. Osteoclasis is somewhat safer possibly, and is to be preferred for the younger patients.

At the Hospital for Ruptured and Crippled in a single year, 160 patients, were operated on for the correction of deformity. Of the 160 operations 104 were linear osteotomies and 16 were cuneiform osteotomies. Osteoclasis was performed in 21 cases and the deformity was corrected by manual force in 15 cases. Osteotomy of the tibia is usually performed. The small osteotome is inserted on the inner aspect of the tibia at the point of greatest deformity, and when the bone has been sufficiently weakened the fracture is completed by manual force. The fibula may be broken at the same time, or, as is usually the case, it may be simply bent outward. The deformity is overcorrected and a well-fitting plaster splint, including the foot and extending to the trochanter, is applied.

The patient usually remains in bed for a few days; he is then dressed, and if he so desires is allowed to stand. Almost no pain or discomfort follows the operation, and in fact, in properly selected cases, it is not only free from danger, but it has a very decided advantage over the ordinary mechanical treatment. If the child is in good condition, and if the deformity is overcorrected at the time of operation, apparatus will not be required in the after-treatment; but in many instances some form of support is indicated, usually because slight deformity, due to laxity of ligaments or to deformity of the femur, appears when the weight of the body falls upon the legs.

It has been stated that the deformity of bow-leg depends in part upon a distortion of the femur as well as of the tibia. As a rule the correction of the greater deformity of the tibia will be sufficient, but in more extreme cases a secondary osteotomy above the condyles will be necessary. This may be performed simultaneously with that on the tibia, but it is better to defer it until the effect of the primary operation has been observed.

ANTERIOR BOW-LEG.

Synonym.—Anterior curvature of the tibia.

Both bow-leg and knock-knee are often seen in children who present no signs of general rhachitis, but anterior bowing of the legs is almost

FIG. 580.—Anterior bow-leg.

FIG. 581.—Extreme anterior curvature of the tibia and flat-foot.

always combined with general rhachitic distortions of the lower extremity, most often with knock-knees. These in turn are caused by marked distortion of the femora, which may be bent forward and outward above, and inward at their lower extremities "corkscrew deformity."

In anterior bow-leg the tibiæ are usually flattened from side to side, curved inward or outward and bent forward, the projecting crests presenting sharply beneath the skin.

Symptoms.—The effect of the anterior bowing is to throw the weight forward upon the foot; thus the heels appear abnormally long and prominent, and the patient seems to sink forward at each step (Fig. 580). The knees are usually somewhat flexed, partly as the effect of knock-knee, with which the deformity is usually combined, and the feet are, as a rule, flat. As had been stated, anterior bowing is almost never seen as an independent deformity unless it is a relic of the more general distortion which has been "outgrown."

Fig. 582.—Rhachitic anterior bow-leg.

Treatment.—Anterior curvature of the tibia must, as a rule, be treated by operation, preferably osteotomy. After complete fracture of the tibia and fibula the deformity may be overcome by forcing the bones directly backward. In many instances tenotomy of the tendo Achillis may be required. Cuneiform osteotomy of the tibia permits more perfect correction, but the final result is equally good after simple osteotomy or osteoclasis, and if one succeeds in separating the posterior

part of the tibia so that it may conform to the straightened anterior border an actual elongation may be obtained in place of the shortening that results from removal of bone.

CONGENITAL ANTERIOR CURVATURE OF THE TIBIA AND PSEUDO-ARTHROSIS.

In cases of this type there is a sharp angulation of the tibia usually at the junction of the middle and lower third . In many instances there is evident non-union at this point which may be congenital or the result of an attempt to correct the deformity. In these cases there is atrophy and loss of growth. The extremities of the fragments are pointed and the medullary canal is closed. The fibula is usually intact and it must be broken in order to permit contact of the fragments.

Treatment.—The medullary canal must be completely exposed and a massive bone graft extending several inches above and below the point of contact must be firmly fixed to each fragment preferably by bone screws. Firm union is usually long delayed.

GENERAL RHACHITIC DISTORTIONS.

General rhachitic distortions of the lower limbs have been mentioned in connection with knock-knee and with anterior bow-leg. A more extended description is hardly necessary. The deformities are usually of the knock-knee type, and they may be treated on the same general plan that has been outlined in the description of the less extreme distortions.

CHAPTER XVII.

DISEASES OF THE NERVOUS SYSTEM.

From the orthopaedic stand-point only those diseases of the nervous system that directly interfere with locomotive function or that cause deformity for which local treatment is of benefit are of special interest. Even this limited class is not often seen in the early or progressive stage, and it is rather with the effects of a disease that is no longer present than with the disease itself that the orthopaedic surgeon is especially concerned.

The relative importance of this branch of orthopaedic work under normal conditions may be illustrated by the statistics of the Hospital for Ruptured and Crippled. In a typical year, 9964 new patients were examined in the out-patient department. In 709 of these the nervous system was involved.

Anterior poliomyelitis furnished 371, about 52 per cent. of the total number. In 144, or 20 per cent., the cerebrum was involved.

ACUTE ANTERIOR POLIOMYELITIS.

Anterior poliomyelitis is an acute infectious disease that involves the nervous system, especially the spinal cord. It is caused by a minute filtrable germ or virus, apparently introduced at the upper respiratory passages.

The infection reaches the spinal cord through the bloodvessels, and probably by the lymph channels of the nerves, and induces primarily an interstitial meningitis accompanied by an increase of the spinal fluid.

The changes in the cord are most marked in its anterior portion, at the lumbar and cervical enlargements, although the medulla, pons and other parts of the brain are frequently involved and also the posterior root ganglia. There is an initial hyperemia, an accumulation of small round cells about the bloodvessels in the lymph spaces, minute hemorrhages and edema. These changes are most marked in the anterior horns of gray matter, but are not confined to it.

The nerve cells are injured or destroyed in part by the mechanical effects of the disease and in part by the toxic action of the virus, and later are replaced by scar tissue. Primarily, the paralysis is often widespread because of interference with function caused by congestion and edema.

The most constant changes in the viscera are hyperplasia of the mesenteric lymph nodes. These are often enlarged, red in color, sometimes hemorrhagic and edematous. In the gastro-intestinal canal the solitary lymph nodes and Peyer's patches are similarly affected.

The disease is somewhat more common among males than females and those in perfect health are as susceptible as those whose resistance is enfeebled. It is endemic in New York and at intervals becomes epidemic, as in 1907 and 1916.

Age.—Acute anterior poliomyelitis is essentially a disease of early childhood, as is indicated by the popular name, infantile paralysis, although it is not uncommon in adolescence or even adult life. This is illustrated by the statistics of the 1916 epidemic in New York:

	Totals.
Under 1 year	751
1 and over, but under 2	1,541
2 and over, but under 3	1,714
3 and over, but under 4	1,278
4 and over, but under 5	618
5 and over, but under 6	511
6 and over, but under 7	304
7 and over, but under 8	184
8 and over, but under 9	130
9 and over, but under 10	126
10 and over, but under 11	68
11–15, but under 16	142
16 and over	129
	7,496

Summary.

Under 1 year	10.0 per cent.
Under 3 years	53.9 "
1 year and over, but under 6 years	75.0 "
6 years and over, but under 11 years	10.8 "
11 years and over, but under 16 years	1.9 "
16 years and over	1.7 "

In both endemic and epidemic forms it is far more common during the warm months than at other seasons, as is illustrated by the following tables.[1, 2]

Endemic.

NEW YORK CITY, 1921–1923.

	Cases.	Deaths.
January	7	2
February	11	5
March	3	1
April	7	3
May	11	2
June	24	3
July	237	13
August	265	36
September	357	68
	922	133

Death-rate, 18+ per cent.

Epidemic.

STATE OF NEW YORK, 1916.

	Cases.	Deaths.	Fatality rate per 100 cases
June	367	64	17.4
July	4,011	895	22.3
August	5,987	1,466	24.5
September	1,992	628	31.5
October	645	215	33.3
November	135	40	29.6
December	40	22	50.6
Total	13,177	3,330	25.1

[1] Bull. Department of Health, October, 1923.
[2] Nicoll: New York State Jour. of Med., June, 1917.

In epidemics the mortality is usually much higher than under ordinary conditions. In five years, 1905–1909, 7103 cases were reported in New York City with 538 deaths, 7.4 per cent. In the 1916 epidemic there were 2444 deaths in a total of 8991 cases, 27.2 per cent. In the remainder of the State there were 866 deaths in 4186 cases, 21.1 per cent. In 1924 866 cases were reported in New York, of the largest number in any year since 1916. There were 91 deaths, a mortality of 10.5 per cent. In the epidemic in Massachusetts, 1927, 1189 cases, the mortality was 14.2 per cent. The mortality rate rises with age, being as high as 50 per cent. in patients of middle age and is estimated to be 50 per cent. higher among males than females. In epidemics there are many abortive cases in the sense that paralysis does not follow, as in 14 per cent. of the cases reported by Wickman,[1] and there are others in which the paralysis is transitory, as in about 20 per cent. of the cases in the New York epidemic. It is probable that even in the abortive cases there are slight but characteristic lesions in the cord, as they have been found at autopsy in all patients who died before the paralysis appeared.

Distribution of the Paralysis.—The lower extremities are far more often paralyzed than the upper. In 1765 of 2418 cases reported by various writers the persistent paralysis was limited to the lower extremities, as compared with 195 cases in which the upper extremities were alone involved.

The general distribution was as follows:

One leg	1120
Both legs	645
One arm	162
Both arms	33
Leg and arm	222
Three extremities	42
All extremities	194
	2418

In general it may be stated of persistent paralysis that the upper arm muscles are more often involved than the lower; the anterior thigh muscles far more often than the posterior; the anterior leg group far more often than the posterior and the adductor muscles of the foot than the abductor. The tensor vaginæ femoris muscle and the short flexors of the toes most often retain power when the paralysis is extensive. The spinal and abdominal groups are often weakened or paralyzed at the onset of the disease, but recovery in the cases of ordinary severity is the rule.

In a total of 500 personal cases examined from two to three months after the onset of the disease the abdominal muscles were partially or completely paralyzed in 50. It is probable that in a large proportion of the cases of a severe type, the trunk muscles particularly those of the abdomen are involved but that complete and permanent paralysis is far less common than in the extremities.

[1] Ztschr. f. klin. Med., 1907, No. 63.

MEDICAL LIBRARY
THE
BOSTON CITY HOSPITAL

Tabulations are only approximately correct, since complete paralysis of one extremity is often accompanied by temporary or persistent weakness of the other.

The Committee on Poliomyelitis of the Conference of State and Provincial Boards of Health (April 30, 1917), from an examination of the reports of various epidemics, concludes that the incubation period varies from four to fourteen days, but is commonly seven days, that poliomyelitis is widely prevalent, but is generally of the non-paralytic type, and that the disease is transmitted chiefly by contact with a patient or carrier. The committee suggested certain minimum requirements for the control of the disease, as follows:

1. That an isolation period for a patient of not less than two weeks nor more than three weeks from onset be required unless the temperature has not returned to normal in the meantime.

2. That children of the same household in contact with a patient be excluded from places of public assembly for a period of fourteen days from the last date of contact as determined by the health officer.

3. That an adult of the household, if the patient is properly isolated, may continue his vocation, provided it does not bring him into contact with children at any time.

Disinfection.—(1) The discharges from the nose, throat and bowels of the patient should be disinfected promptly; (2) the caretaker shall wash her hands with soap and hot water promptly after handling said discharges; (3) the caretaker shall wash her hands similarly before leaving the room occupied by the patient; (4) isolation shall be terminated by a thorough washing of entire body and hair of the patient and the room cleaned with soap and hot water, aired and sunned; (5) sick-room precautions should include the usual attention to cleaning and disinfection of eating utensils, personal and bedclothing, rugs, door-knobs and other things handled by the patient or caretaker.

One thousand families from which patients had been received at the Hospital for Ruptured and Crippled were investigated with reference to contagion by contact.

In the 1000 families there were but 1055 cases, the 55 cases being about 3 per cent. of those exposed to possible contagion. In 32 of 755 families investigated by Legg there was more than one case, 4.2 per cent.[1]

Symptoms.—The disease and its effects may be divided into several stages:

1. The stage of onset: In some instances there appears to be a period of incubation, indicated by fatigue, loss of appetite, sore throat or "rheumatic" pain. More often there are evident constitutional symptoms, fever, headache and drowsiness, vomiting, intestinal disturbance, polyuria, sweating and stiffness or contraction of the neck muscles, this being apparently the most constant symptom. Occa-

[1] Jour. Am. Med. Assn., January 5, 1928.

sionally there is severe pain in the back or limbs and local sensitiveness, often to touch or movement is present in about one-half the cases. This is ascribed to involvement of the intervertebral ganglia. In many instances the elevation of the temperature is not extreme, nor is the constitutional disturbance severe, and but for the paralysis the symptoms might be mistaken for those of one of the transitory illnesses of childhood. In some cases, however, the fever is high, and there may be convulsions, delirium and prolonged unconsciousness, while in others there may be no premonitory symptoms whatever; the child, apparently well at night, wakes in the morning paralyzed in one of the extremities. The reflexes in the affected limb are usually diminished or lost, although an increase may be noted in the preparalytic stage or in those in which the disease is confined to the upper neurones.

In many instances the weakness or paralysis caused by anterior poliomyelitis of a mild type in infancy is not discovered until the child begins to walk, when the awkward gait or limp, or the distortion of a foot, may make it evident.

In a few hours or a few days after the first symptoms of the disease, the paralysis appears or is detected. Its area, corresponding in some degree to the severity of the symptoms, may extend for several days, or its extreme limit may be reached at once. The primary paralysis is always greater than that which finally persists. The duration of the acute stage of the disease is about a week. The direct cause of death in most instances is respiratory paralysis.

There are several types of the disease corresponding to the symptoms or the distribution of the paralysis.

(*a*) The abortive form, in which the constitutional symptoms are not followed by paralysis.

(*b*) The ordinary spinal type.

(*c*) An ascending or descending form that extends gradually, often involving the muscles of respiration.

(*d*) The bulbar type, in which the muscles of respiration or of deglutition may be weakened or paralyzed or in which the cranial nerves may be involved. The most common isolated paralysis is of the facial nerve. In a total of 88 cases the seventh nerve was involved in 38: the sixth in 16; the twelfth in 10.[1] In rare instances both sight and hearing may be affected.

(*e*) The cerebral type, affecting the cerebral cortex and inducing increased reflexes.

(*f*) The meningeal form, involving chiefly the pia mater and in which the symptoms resemble those of cerebrospinal meningitis.

2. Then follows a stationary period, lasting from a week to a month; the constitutional symptoms cease but the paralysis persists.

3. This is succeeded by the stage of partial recovery, usually noticeably progressive during the first six months and which may be prolonged indefinitely. The muscles which were paralyzed because of

[1] Perkens: New York State Jour. Med., October 15, 1928.

the secondary congestion and exudation about the local myelitis recover their power in whole or in part, while those muscles supplied from the area in the cord in which the nerve cells have been destroyed waste away. At this time the contractions and distortions in the paralyzed limbs develop.

4. The chronic stage. This may be considered from the therapeutic stand-point, to last to adult age or until the ultimate effect on the individual, due to the retardation of the growth and unbalancing of the mechanical equilibrium of the body may be complete.

The sensation of the paralyzed part is not affected except in the extreme cases. The temperature is lower from the first. In many instances the limb is not only cold, but it is congested and "blue." These circulatory disturbances are caused primarily by the interference with the vasomotor function, but they are confirmed later by the atrophy of the muscles and by the permanent contraction of the bloodvessels. Thus, in general, the impairment of the circulation corresponds to the degree of the paralysis, but not absolutely so. In certain cases the paralysis may be limited in extent, and yet the limb may be cold and congested, while in others in which the loss of power is much greater the temperature is but slightly lowered and the color remains normal. The same is true of retardation of growth. In most instances the ultimate shortening of the limb corresponds to the degree of the paralysis and consequent loss of function; but occasionally cases are seen in which the growth is markedly retarded, although but few of the muscles are paralyzed.

Diagnosis.—The diagnosis of acute anterior poliomyelitis is not usually made, except in epidemics, before the stage of paralysis. An increase of intraspinal pressure and an increase in the number of cells in the fluid being the most specific of the early signs. According to Menninger, the cell count may be increased from a normal of 10 to 2500 cells per c.mm. The first increase is of the polymorphonuclear leukocytes, but within twenty-four hours there may be 80 per cent. mononuclear lymphocytes. After the paralysis has appeared there should be little difficulty in interpreting the symptoms. It is a disease usually of acute onset, followed by paralysis of certain muscular groups or of entire members. It is a flaccid paralysis, the reflexes are lost, the muscles no longer contract under faradism and the reaction of degeneration soon appears; the tissues waste and the circulation is impaired in the affected parts. At the stage of onset it might be mistaken for acute encephalitis, of which the symptoms are fever, vomiting, headache, drowsiness or delirium; but in this disease the later symptoms resemble those of meningitis rather than of poliomyelitis, viz.: nystagmus, strabismus and paralysis of the cranial nerves and the like, which are rarely seen in anterior poliomyelitis. Encephalitis lethargica is essentially, as contrasted with anterior poliomyelitis, a disease of adult life. In a total of 268 cases reported in New York City between January 1 and February 27, 1923, but 12 were under five years of age.

It is usual to consider first in differential diagnosis of cases of long standing the paralyses of cerebral origin, but this is more for the purpose of calling attention to the essential differences between the two than because they are likely to be confounded by one acquainted with the ordinary characteristics of cerebral and spinal disease.

Paralysis of Cerebral Origin in Childhood.—The common form is hemiplegia. It is often congenital, the result of injury at birth, and the intelligence may be impaired. The paralysis is not complete, nor is it limited to groups of muscles; it is rather powerlessness or impairment of function, due to loss of cerebral control. The reflexes are increased and limbs are stiffened, not flaccid. The electrical reactions are not lost or changed in quality. Paralysis of cerebral origin may be also paraplegic or diplegic in its distribution, but in these cases the general characteristics are the same as in the hemiplegic form, except that the intelligence is more markedly affected.

Other Forms of Spinal Paralysis.—Transverse myelitis is very uncommon in childhood. In this disease the distribution is equal, the reflexes are at first increased, and sensation as well as motion is lost.

Pott's Paraplegia.—In this form of paralysis, also, the distribution is equal, the reflexes are increased, and the signs of the disease of the spine are always present.

Spastic Spinal Paraplegia.—In this as in the preceding form the distribution is equal, and the reflexes are exaggerated.

Rheumatism and Joint Disease.—In orthopaedic clinics anterior poliomyelitis is not often seen in the stage of onset unless pain is a prominent symptom, when the disease may be mistaken for rheumatism or for some form of joint disease. Cases of this type are not uncommon. The tissues are sensitive to pressure and the movements of the joints cause discomfort. In certain instances the paralysis may not be apparent on the first examination; when it does appear the diagnosis is, of course, established; therefore the characteristics of diseases of the joints need not be detailed.

Multiple Neuritis.—Multiple neuritis is usually a sequel of infectious diseases, or of metallic poisoning. In the cases due to metallic poisoning with lead or arsenic the paralysis usually begins in the extensors of the hands and feet, and is symmetrical in its distribution. This is true, also, of the localized forms of paralysis following contagious diseases in which the dorsal flexors of the feet are most often involved. In multiple neuritis there is usually local sensitiveness lasting a longer time than in poliomyelitis; the paralysis is gradual in its onset, and sensation as well as motion is affected.

Diphtheritic Paralysis.—Diphtheria is the most common cause of general weakness terminating in paralysis in childhood, but in these cases there is usually a history of the preceding disease. The paralysis usually appears first in the muscles of the throat and neck, and a general and increasing weakness precedes by a considerable interval the complete loss of power.

Weakness. Pseudoparalysis.—Weakness caused by rhachitis, the so-called pseudoparalysis, due to this or to other affections, is readily distinguished from actual paralysis by pricking the part with a pin, when muscular contraction and movement of the limb will be evident. This test of function is of value in showing the distribution of actual paralysis. Loss of power in the tibialis anticus muscle, for example, causes valgus resembling closely the ordinary valgus due to simple weakness. In simple weakness the child withdraws the foot from the point of the pin, and the ability to move it in all directions is very evident; but if the tibialis anticus muscle is paralyzed the foot is always flexed in the abducted attitude. The same test may be made for paralysis of other muscles or muscular groups. It is a test that is easily applied and that is especially useful in the examination of young children.

Fig. 583.—Anterior poliomyelitis. Extreme flexion deformity at the hips, inducing quadrupedal locomotion.

Amyotonia Congenita.—This is a form of weakness characterized by flaccidity of the muscles and general atony.

Obstetrical Paralysis.—Paralysis of the arm due to anterior poliomyelitis is infrequent as compared with that of the lower extremity. This form might be mistaken for obstetrical paralysis, but the history of the disability and its distribution should make the diagnosis clear.

Prognosis.—The prognosis as to function depends primarily upon the area of the destructive disease of the cord, secondarily upon the treatment of the weakened or disabled part. As has been stated, the extent of the primary paralysis is very much greater than that which ultimately persists.

The Electrical Test.—During the early stages of the disease the extent of the residual paralysis may be estimated with some degree of accuracy by the electrical reaction. Within a week after the initial paralysis the reaction to the faradic current in the muscles and nerves in direct connection with the diseased area is lessened and is soon

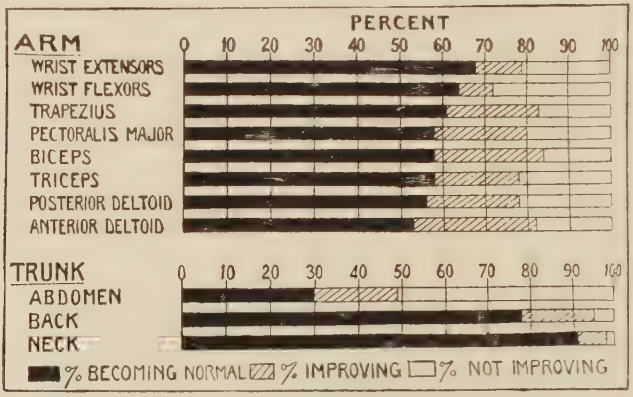

Fig. 584.—Percentage of gain in three years. (Lovett.)

lost. If the faradic irritability is retained in the paralyzed muscles, or if it is merely diminished, recovery may be predicted. The muscles which no longer react to the faradic stimulation may still be made to contract by the galvanic current. In normal muscles the reaction is greatest at the closing of the negative pole. In the paralyzed muscles the reaction is slower, it requires stronger stimulation, and the con-

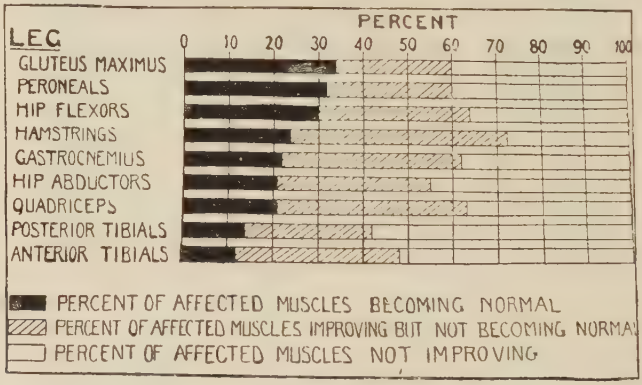

Fig. 585.—Percentage of gain in three years. (Lovett.)

traction is greater at the closing of the positive pole. This is known as the reaction of degeneration. The loss of faradic reaction and the change in the galvanic reaction indicate that the function of the affected muscle will be seriously impaired, although certain of its fibers may in time regain their power.

It must be borne in mind that the paralysis of anterior poliomyelitis is in general incomplete, that a certain proportion of the contractile substance of an apparently paralyzed muscle may remain active

indicating similar activity of the nerve cells, capable possibly of further development. Also, that the number of nerve cells in adult life is double that at birth, indicating a possibility of further regeneration.

In general the prognosis for partial or complete recovery is far more favorable for paralysis of the upper extremities and trunk than for the lower extremities.

FIG. 586.—The effect of extreme flexion contraction of the thighs on the contour of the spine.

FIG. 587.—The effect of extreme flexion contraction of the thighs in exaggerating the lordosis.

The charts (Figs. 584 and 585) prepared by Lovett show the comparative gain in muscular power in a period of three years in a series of cases under his observation.

The Effects of Paralysis of Different Muscles and Groups of Muscles upon Function.—From the orthopaedic stand-point the chief interest in anterior poliomyelitis lies in its immediate and ultimate effects upon

the functional ability of the individual. These effects may be classified as *deformity of the part directly involved and the influence of weakness, deformity, and loss of growth upon the body as a whole.*

Causes of Deformity.—The deformities of anterior poliomyelitis are caused:

1. By force of gravity.
2. By the unopposed action of the active muscles.
3. By habitual posture.
4. By functional use.

All these and other less important causes of deformity are, of course, combined in most instances. The relative importance of each factor varies, according to the muscular group that is involved, with the age of the patient, and with the strain to which the part is subjected. The influence of the different factors can be studied best in the foot.

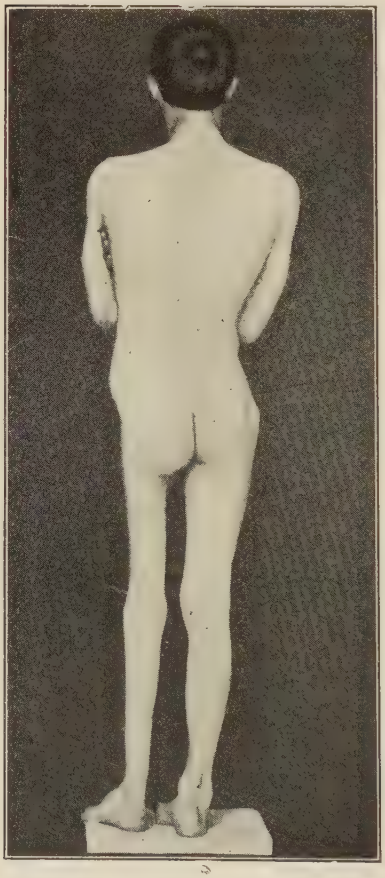

FIG. 588.—Anterior poliomyelitis. After seven years. Showing atrophy and slight lateral curvature of the spine; two and a quarter inches of shortening.

Muscular Action and Gravity.—In by far the larger number of cases one or more of the dorsal flexors of the foot are involved. This is illustrated by the statistics of acquired talipes, tabulated elsewhere, the equinus type of deformity being three times as common as the calcaneus form.

If the anterior muscles are paralyzed before the walking age, the foot drops under the influence of the force of gravity into the attitude of equinus. If this attitude is allowed to persist, the muscles on the posterior aspect of the limb, accommodating themselves to the habitual attitude become structurally shortened. In such cases the equinus deformity is caused by the force of gravity; it is increased by unopposed muscular action and it is fixed by muscular shortening in adaptation to the persistent attitude. That deformity is not caused directly by muscular action is shown by the fact that it may be prevented by systematic passive movements to the limit of dorsal flexion. Deformity is thus prevented, not by opposing muscular action, but by stretching the active

MEDICAL LIBRARY
BOSTON CITY HOSPITAL

muscles to the full limit and thus preventing muscular adaptation and structural change. In the instance cited, gravity and muscular activity are combined in the production of deformity, but in other instances gravity and muscular power may be opposed to one another. If, for example, the calf muscle is paralyzed while the anterior group retains its power, the characteristic deformity of calcaneus, opposed by the force of gravity does not usually appear until the child begins to use the foot, when the peculiar helplessness calls attention to the disability, if the diagnosis has not been made before. Thus it is that equinus may be present when the child is still in arms, while the opposite deformity develops much more slowly.

FIG. 589.—Paralytic dislocation of the hip.

Habitual Posture.—There are other cases in which every vestige of muscular power is lost and the foot "dangles" on the leg. In this class there is no functional activity or tonic contraction of the muscles; consequently deformity develops slowly and is not often extreme, since it is confirmed only by the structural shortening of inactive tissues, the ligaments, fasciæ, and the atrophied muscles. There are, of course, other causes for habitual posture than the force of gravity and muscular action, such as, for example, the position of convenience in which a weak, or disabled or sensitive part might be placed. For example, in extensive paralysis of the lower extremities the habitual sitting posture requires flexion at the hips and knees, and contractions

at these joints soon appear unless they are prevented, especially in those cases in which the residual muscular activity favors the deformity. It is in cases of this type that lateral curvature of the spine is most common, particularly if the oblique abdominal muscles are paralyzed.

Functional Use as a Cause of Deformity.—Thus far the force of gravity, habitual posture, unbalanced muscular power, and the structural changes in the tissues have been considered in the etiology of

FIG. 590.—Anterior poliomyelitis, causing genu recurvatum. (See Fig. 591.)

deformity as it might develop in infancy. When, however, the patient stands and walks, existing deformities are exaggerated and confirmed by the weight of the body falling on the unbalanced part, and by the action of the muscles in the attempt to supply the function of those that are paralyzed. Thus it is that deformity develops far more rapidly when a fair amount of muscular power remains than when it is completely lost. (See Talipes.)

Subluxation.—Aside from the distortions due to the causes that have been mentioned, there are others induced simply by weakness; for example, laxity of ligaments and the loss of muscular support may permit distortion of a limb and subluxation or even dislocation of a joint (Figs. 589 and 591). The most common of these secondary distortions is subluxation of the tibia upon the femur, often combined with outward rotation. Complete displacement is uncommon, and occurs practically only at the hip. In such cases there is usually flexion deformity of the limb, the femur being suspended by the contracted tissues attached to the anterior-superior spine. This unyielding band forms a fulcrum by means of which force applied at the knee may cause sudden displacement of the head of the femur forward or upward and backward (Fig. 589.)

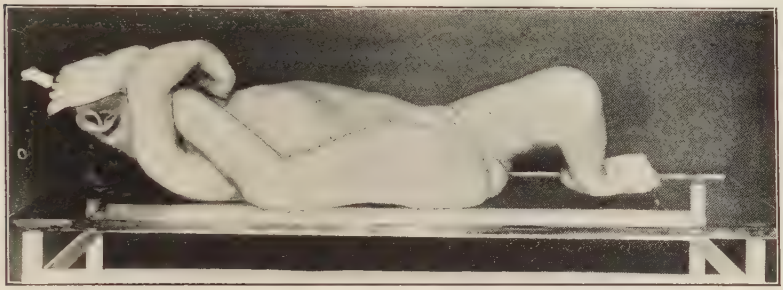

Fig. 591.—Anterior poliomyelitis. Paralysis of muscles at the hip permits subluxation of the femur. The same patient as in Fig 590.

Deformities of the Upper Extremity.—Deformities caused by paralysis of the muscles of the shoulder are usually slight because the part is not subjected to the strain of weight-bearing, and because the force of gravity is opposed to muscular contraction. In these cases the loss of muscular support and the resulting tension on the capsule permit a considerable separation of the joint surfaces so that the atrophied head of the humerus may be displaced forward or backward; but there is not often fixed displacement, and consequently persistent distortion due to this cause is unusual. Abduction and rotation are sometimes limited by muscular resistance or by accommodation to habitual posture.

Paralysis of the muscles of the forearm and of the hand is followed after a time by deformity of the fingers, caused primarily by unopposed muscular action, secondarily by accommodation and atrophy.

Deformities of the Neck.—Paralysis of one or more of the muscles of the neck may induce a paralytic torticollis. This is, however, uncommon.

Deformities of the Trunk.—Distortions of the trunk are usually induced by habitual posture during the early stages of the disease when the paralysis is widespread, particularly when the abdominal muscles are involved, and persist even though the muscles recover

their strength in whole or part. The direct effect of paralysis of the trunk muscles in inducing lateral curvature in the thoracic region is not usually as might at first appear, the unopposed action of the active muscles and thus a bending of the trunk with a convexity toward the weaker side. As a rule the curvature is, as a whole, in the opposite direction. This is explained by the fact that if the paralysis is limited to one side and is extensive enough to cause distortion of the trunk, the muscles of respiration being involved, the chest wall becomes inactive and collapses. In compensation the opposite side of the thorax increases in size and lung capacity and the weak, atrophied, and sunken side is drawn toward it. The same effect is observed when the arm and the shoulder muscles are paralyzed, the spine bending toward the side that is still active. The convexity of primary lumbar curvature, however, is usually toward the weak or paralyzed muscles and is induced more directly by activity of the stronger trunk or abdominal groups.

Fig. 592.—The preventable deformities of anterior poliomyelitis.

Paralysis of the posterior group of muscles, if extreme, may induce kyphosis. Paralysis of the muscles of the abdomen causes lordosis when the erect posture is resumed, but in this group of cases the lower extremities are usually involved, and the secondary distortions due to posture and to functional use mask the direct effect of the paralysis of the muscles of the trunk. And, again, the overuse of the arm muscles in patients whose lower extremities are paralyzed, and the suspension of the body on crutches in walking, modify the ultimate effects in those cases in which the paralysis is widespread in its area (See Lateral Curvature.)

Retardation of Growth and Secondary Deformities.—The effects of anterior poliomyelitis are not limited to the paralysis and to atrophy of the muscles, but all the component tissues of the affected limb are involved as well. The bones become relatively atrophied, and their growth is retarded to a degree fairly proportionate to the extent of the paralysis and to the functional disability that has resulted. As has been stated, retardation of growth does not always correspond to the degree of paralysis. In some instances paralysis of a single muscle, which does not seriously compromise the function of the part, is accompanied by greater shortening of the limb than in other cases in which the paralysis is far more extensive. Thus it may be inferred

that certain cells in the spinal cord are especially concerned in the growth and nutrition of the bones and that interference with the function of these cells may not correspond absolutely to the extent of the destructive process. However this may be, it is certain that atrophy and retardation of growth are much greater when a limb is not used than when by the aid of apparatus it has been enabled to

FIG. 593.—Resistant contractions at the hips, knees and ankles eight weeks after the onset of the disease. (See Fig. 594.)

carry out, in part at least, its proper function. It is evident, also, that retardation of growth will be more marked during the period of rapid development; thus the younger the patient the greater should be the ultimate inequality of the limbs.

FIG. 594.—Deformities corrected under anesthesia. (See Fig. 593.)

RETARDATION OF GROWTH.—The ultimate shortening varies from one to three or more inches. In the slighter degrees of paralysis affecting the leg the shortening may be less than an inch, but when the thigh muscles are paralyzed also it may be much more (Fig. 588). This inequality both in length and size is most marked in those cases in which the paralysis is confined to one limb is usually noticeable in the feet.

When both limbs are paralyzed, so that locomotion is very seriously interfered with, the retardation of growth is especially marked, and the

contrast between the trunk of the patient and the attenuated lower extremities is very striking.

Compensatory Distortions.—Secondary deformities must include, besides those already mentioned, the compensatory distortions of the trunk that may follow paralysis of the limbs. Thus a shortened limb and the weakness of the hip and thigh muscles might cause a lateral curvature of the spine, or flexion contraction of the thigh might induce persistent lordosis. In fact, the final effects of disabilities of this character are very complex, and are influenced by many factors of which only a general indication is practicable.

Treatment.—The treatment of the acute stage of anterior poliomyelitis is symptomatic. If the diagnosis has been made early, such measures as would tend to relieve the congestion about the diseased area may be employed; the first indication being free catharsis and the cleansing of the throat and nasal passages. The only drug for which any influence on the disease has been claimed is urotropin in doses of from 5 to 10 grains three times daily.



Fig. 595.—The use of plaster in a case of extensive paralysis including the trunk muscles.

Lumbar puncture[1] in the acute stage for the relief of tension repeated at intervals is of apparent value, and the injection of serum from the blood of those who have had the disease into the spinal canal may be of service if administered early. Fifteen to 20 cc. of convalescent human serum is injected, to be repeated in twenty-four hours. Flexner recommends the injection of this serum as a prophylactic, 10 cc. for child, 20 cc. for an adult. He thinks that the neutralizing antibodies persist for twenty years so that serum might be obtained from adolescents and adults.[2] During the active stage complete rest and quiet

[1] The point of election for lumbar puncture is between the fourth and fifth lumbar vertebræ opposite the highest point of the iliac crest. The spine should be bent forward and the needle inserted in the median line in a direction forward and slightly upward.

[2] Whatever benefit may be expected from convalescent serum can be realized only when it is given in the preparalytic stage. The intrathecal route would seem to be as safe, and certainly as effective, as less direct methods. The intramuscular or intravenous route is possibly as effective as the intrathecal, excepting for a certain amount of delay in reaching the spinal fluid with antibodies, but further studies on this point are desirable. The prophylactic use of convalescent serum given subcutaneously or intramuscularly in time of epidemic, as suggested by Flexner, is amply backed up in its rationality by monkey experiment and is probably a valuable preventive measure, albeit limited in application by difficulties in obtaining serum. (Kellogg, Jour. Am. Med. Assn., December 29, 1929.)

are indicated. In cases in which the paralysis is widespread, and in which movements of the limbs cause discomfort, particularly if the skin is hyperesthetic, a single or double long spica plaster splint or stretcher frame, described in the Chapter on Pott's Disease, may be used to support the spine and extremities. When the acute symptoms have subsided local treatment to maintain as far as possible the nutrition of the muscles, to prevent deformity and to relieve the strain upon the weakened tissues, is indicated. The nutrition of the parts may be improved by friction and gentle massage, by the direct application of heat to the cold extremities, by radiant light, and particularly by warm baths. In this connection it may be stated that in cases of extensive paralysis the most satisfactory exercise is swimming, or at least movements of the limbs to the degree possible while the body floats or is supported by the attendant. This exercise is particularly effective during the stage of recovery. Galvanism may be of direct service as long as it will induce contraction of the paralyzed muscles and indirectly as a stimulant of the nutrition.

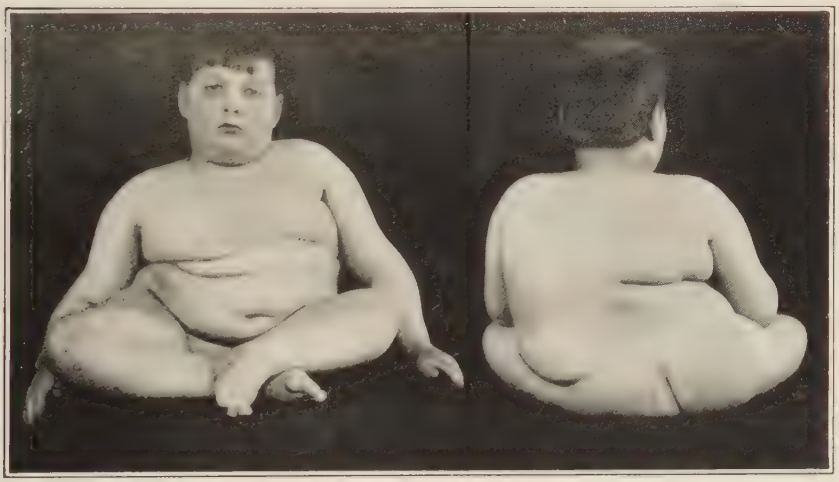

Fig. 596.—Postural deformities. Lateral curvature of the spine and contractures of the lower extremities.

The most important part of the treatment is the prevention of deformity, which is otherwise an inevitable consequence of the disease. In all cases, in which the muscles of the trunk are involved prolonged rest on the back is indicated, preferably on the stretcher frame. The sitting posture permitted while the muscles are weak is the direct cause of the great majority of distortions of the spine. The child may be removed from the frame at intervals for baths and massage, and finally the spine should be methodically stretched to its normal limit in all directions as soon as such manipulations cause no discomfort. By this means and by efficient support when the erect posture is resumed lateral curvature, the most disastrous of all paralytic deformities, may be prevented.

In the same manner deformities of the limbs may be prevented by moving each joint to the limit of the range of motion in all directions several times a day, and by supporting the limb with simple apparatus. Deformity in those parts in which it is favored by muscular action and by the force of gravity appears much more rapidly than is generally supposed. Equinus, for example, is often apparent within a few weeks after paralysis of the anterior muscles of the leg. The first indication of such deformity in this class is the discomfort caused by passively moving the foot toward dorsal flexion. This limitation of the range of motion rapidly increases, and as it increases it is confirmed by muscular adaptation and finally by structural shortening. This is equally true of other parts and much of the pain supposed to be hyperesthesia following disease is actually caused by tension on contracted tissues. As a rule the period of rest during the stage of recovery should be prolonged and locomotion should be deferred as long as possible.

The Principles of Mechanical Treatment.—The object of a brace is to prevent the deformity due to weakness and to utilize the muscular power that remains, so that the disabled member may carry out its function. As each muscle has an essential function the paralysis of any one must be followed by a certain proportionate disability. Muscles vary in importance as they do in strength, and the ultimate disability caused by paralysis may be predicted with accuracy by one who is familiar with this function.

Paralysis of the Anterior Muscles of the Leg.—Paralysis of the anterior leg group causes the so-called steppage gait; the toes drag on the floor when the limb is swung forward, and this necessitates an awkward lifting of the knee. The natural result of such paralysis is equinus. Slight equinus has a tendency to throw the knee backward, "recurvatum," in order that the patient may place the entire sole on the ground. More marked equinus obliges the patient to bear the weight entirely on the front of the foot, and unless the limb is short, usually induces flexion both at the knee and hip. If but one of the dorsal flexors is paralyzed the tendency to equinus is in so far lessened, but there is an inclination to lateral distortion. Paralysis of the anterior muscles causes an awkward gait and often deformity, but the propelling force of the limb remains. The indication for support is simple, to prevent the foot from dropping to the extent that inconveniences the patient.

Paralysis of the Posterior Muscles of the Leg.—If, on the other hand, the calf muscle is paralyzed the resistance of the foot is lost and it is simply dorsiflexed when weight is thrown upon it. The gait is inelastic and awkward. In most instances other muscles are paralyzed also, so that the foot is inclined laterally. Thus the brace must be arranged to prevent dorsal flexion, and it must be strong enough to support the strain which is transmitted from the foot plate of the brace to the front of the leg. The various weaknesses and deformities of the foot and the means of treating them are described at length elsewhere. (See Talipes.)

MEDICAL LIBRARY BOSTON CITY HOSPITAL

Paralysis of the calf muscle not only affects the foot, but it weakens the knee as well and hyperextension or genu recurvatum is often a secondary effect. In many instances, therefore, it will be necessary to support the knee as well as the ankle during the earlier stages of the treatment.

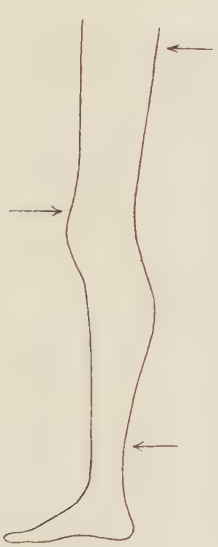

Fig. 597

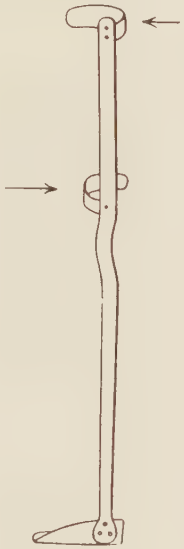

Fig. 598

Figs. 597 and 598.—The Judson brace for paralysis of the quadriceps extensor muscle in connection with deformity of the foot.

Paralysis of the Thigh Muscles.—Paralysis of the quadriceps extensor muscle causes primarily a peculiar gait. The patient, unable to extend the leg upon the thigh, throws or swings it forward, then locks the joint by direct contact of the bones and by the resistance of the posterior tissues, by inclining the body somewhat forward as the weight falls upon it. In this manner, again, the knee may be overextended. Or if extension is checked by shortening of the tissues, induced, for example, by habitual assumption of the sitting posture, the patient being unable to lock the joint effectively by complete contact of the bones, often trips and falls because of the insecurity of the support. When in the normal subject the weight is borne upon one limb in the attitude of rest, in which the muscles are thrown out of action, the knee-joint is locked, but the insecurity of this support is illustrated by the school-boy's trick of striking the back of the knee with the hand, when, the muscles being taken unawares, the person falls to the ground. This insecurity is constant when the extensor of the leg is paralyzed. For this reason the patient inclines the body forward and places the hand on the front of the thigh in locomotion.

Paralysis limited to the quadriceps extensor muscle is, however, unusual. In almost all cases some of the leg muscles are involved

also, and the brace usually must serve to support the foot as well as the knee. In its ordinary form such a brace is constructed of two lateral upright bars, reaching nearly to the pubes on the inner and to the trochanter on the outer side, joined to one another by bands passing beneath the thigh and the calf, and attached to a light steel



Fig. 599.—A brace for complete paralysis of the limb, showing a form of lock at the knee and a limited joint at the ankle.

Fig. 600. — Anterior poliomyelitis. Paralysis of the anterior and posterior muscles. Recurvation of the right knee.

foot plate. If the dorsal flexors of the foot are paralyzed the ankle-joint is arranged to permit dorsal flexion, but to prevent extension beyond the right angle. If the calf muscle is paralyzed a reverse catch is used, or the uprights are attached directly to the foot plate without a joint (Fig. 598), or the so-called limited joint, allowing only a few degrees of motion in either direction, is used (Fig. 599).

(See Talipes.) In the treatment of young children the joint is also omitted at the knee, the limb being firmly held in the extended position during the period of activity (Figs. 598 and 601). This is of advantage because the joint is the weakest part of the brace and it soon becomes loose under the severe strain to which it is subjected. In older subjects a joint is arranged with a spring catch, the brace being held in the straight position when the patient is walking about, but allowing flexion when the sitting posture is assumed. This is, of course, a great convenience (Fig. 599). In fitting the brace the lateral bars should be adjusted to support the limb without uncom-



Fig. 601.—Brace for complete paralysis of the anterior muscles of the limb; before and after covering.

fortable pressure, and the joints should be exactly opposite the normal centers of motion. The thigh and leg bands should be properly fitted to the contour of the soft parts so that half the limb is contained within them. These are smoothly covered with leather, and the limb is held in position by leather bands that complete the circumference. Other bands are applied across the front or back of the limb, either to support it or to fix it firmly in place. In the ordinary brace without the joint at the knee there are three anterior bands, one across the front of the thigh, another across the leg, and the third, a wide knee-cap, supports the greater part of the strain (Fig. 601). The Thomas caliper

knee brace is a light and effective appliance if no joints are required. (See Fig. 401.)

Paralysis of the Muscles of the Hip.—The functional effect of paralysis of the muscles about the hip is difficult to describe, as in these cases many other muscles are usually involved. If all the muscles are paralyzed the thigh dangles. This is, however, rather unusual, for the tensor vaginæ femoris almost always retains its power, and this is one of the causes of flexion deformity which is so often present in cases of this character.



Fig. 602.—Leg brace, with pelvic band. Double uprights. No joint at knee. For paralysis of the anterior thigh and leg muscles.

Paralysis of the iliopsoas muscle makes it impossible for the patient to flex the thigh directly, and in the upright posture the body is usually inclined somewhat backward. The gluteus maximus is the most important of the hip muscles since complete extension at the hip and knee are essential to normal locomotion. When this muscle is paralyzed the trunk usually sways backward in compensation. If the gluteus medius is paralyzed the limb cannot be abducted. In walking the body sways toward the paralyzed limb and the pelvis is tilted upward on the affected side when weight is borne (the Trendelenburg sign).

The distribution of the paralysis of the muscles of the hip may be ascertained by placing the patient in the recumbent posture; the leg is then lifted from the table, and by placing the thigh in different positions the ability of the patient to move it may be tested, in older subjects by voluntary effort, in younger ones by pricking the parts lightly with a pin.

General weakness of the muscles of the hip causes an awkward, insecure gait, accompanied usually by outward rotation of the limb which is swung forward by a rotation of the pelvis. In such cases as has been stated, there is almost always extensive paralysis of other muscles of the extremity and a pelvic band must be attached to guide

the limb. The pelvic band is made of sheet steel of about 18 gauge, two inches wide, fitted to the pelvis, which it encircles midway between the crest of the ilium and the trochanter. At this point it is attached to the brace by a free joint (Fig. 602). When the band is accurately adjusted and strapped firmly about the pelvis the necessary security is assured and the attitude of the limb in walking can be regulated. If greater security is desired a perineal band may be applied as described in the chapter on Disease of the Hip-joint.

If both limbs are paralyzed double braces must be used. If the muscles of the lower part of the back are much weakened the pelvic band may be replaced by a corset or some form of back brace.

Paralysis of the abdominal muscles if complete causes bulging of the abdomen and loss of the ability to raise the trunk to the sitting posture when the patient lies on the back. The paralysis may be complete or unilateral or partial, as shown by a limited bulging under strain. Abdominal paralysis is the most constant cause of scoliosis, especially if unilateral, and this should be borne in mind in considering preventive treatment. The abdomen should be supported by a binder, and any tendency to lateral distortion should be resisted by methodical bending of the trunk in the opposite direction.

Paralysis of the extensor muscles of the spine causes a general forward droop of the trunk. In cases of this class persistent recumbency on a frame is advisable because partial as well as complete recovery is the rule. Later support is indicated to preserve the erect posture.

Paralytic Scoliosis.—Paralytic scoliosis requires the support of corsets or braces as a rule, such as are used in the treatment of other forms of distortion of the back. Operations to induce anchylosis are indicated in suitable cases. (See Lateral Curvature.[1])

Paralysis of the Arm.—Paralysis limited to the arm is comparatively uncommon, and mechanical treatment is rarely indicated except during the stage of recovery.

If the shoulder muscles are paralyzed the arm should be supported at the limit of normal abduction (Fig. 603), and the other joints in the attitudes that remove all strain on the weak muscles (Fig. 604). Any tendency to contraction should be corrected by methodical stretching.

Muscle Training.—Lovett[2] has called particular attention to the fact that paralysis is often partial rather than complete, and that weak muscles may be developed by appropriate exercises.

These exercises are adapted to the weakness of the muscles and are carried out in attitudes in which they are not antagonized by the force of gravity. No resistance is used until the full range of motion has been regained.

If possible, the relative strength of the weak muscles is tested by a spring balance pulling against a fixed position assumed by the patient, and upon this basis the muscle training is regulated and its

[1] Hibbs: Jour. Am. Med. Assn., September 8, 1917.
[2] Treatment of Infantile Paralysis, 1916.

effects are judged. Particular attention is called to avoidance of overfatigue both in exercise and in functional use, and upon mental concentration as an aid in muscular control.

FIG. 603.—A splint for paralysis of the shoulder and arm muscles. (Gocht.)

As the great majority of cases are in young children, the field for accurate muscle testing is somewhat limited, but functional training

FIG. 604.—A splint for paralysis of the arm and hand muscles. (Biesalski.)

in some form is possible in most instances[1] and is of great importance. It must be borne in mind, however, that the most effective training is

[1] W. G. Wright: Muscle Training in the Treatment of Infantile Paralysis, Boston, 1916.

normal functional use provided the part may be properly supported, and if it be limited to the point of fatigue; for weight bearing is as essential to the development of the bones as exercise is to that of the muscles.

In discussing treatment the relative importance of the different agencies must be considered. In the great majority of cases the patients are the children of the poor, and the benefit that may be derived from electrical stimulation and muscle training will hardly compensate for the time, effort and exposure involved in frequent visits to orthopaedic clinics.

FIG. 605.—The secondary changes in the bones after complete paralysis of long duration. Extreme atrophy, subluxation at the knee, change in the upper surface of the tibia and distortion of the epiphysis of the femur.

Operative Treatment.—THE REDUCTION OF DEFORMITY.—In a large proportion of the cases of anterior poliomyelitis the patients are not seen by the orthopaedic surgeon until months or years after its onset. They are then brought for treatment because of secondary deformity, often of an extreme degree. At least half of the cases of talipes are due to this cause, and with the deformity of the foot are often com-

bined, other distortions varying in degree with the extent of the paralysis. Many of the patients hobble about on a distorted foot, others use crutches, and in a smaller number the only method of locomotion is creeping on all-fours. In the cases in which the patient has habitually used crutches, allowing the paralyzed limb to "dangle," there is usually marked flexion at the three joints. The thigh is flexed upon the pelvis, the leg is flexed upon the thigh, and the foot hangs downward and inward (plantar flexed) in an attitude of equinovarus.

However extreme the paralysis of a lower extremity may be, the limb may be made useful as a prop when properly braced; this prop may enable the patient to dispense with the use of crutches and thus free the arms from unnecessary work. Even if both limbs are paralyzed they may at least serve as supports to enable the patient to stand erect and to propel himself with the aid of crutches. If a limb has been disused for a long time, the atrophy is usually extreme, the bones are fragile, and the growth has been greatly retarded as compared with those limbs in which deformity has been prevented and in which the weight of the body has been sustained in functional use. In this class of cases the first step must be the reduction of deformity; the foot must be brought to a right angle with the leg, the limb must be extended at the knee, and the flexion at the hip must be overcome in order to enable the patient to stand erect without compensatory lordosis.

Acquired deformity of the foot is far less resistant than is the congenital form, and by tenotomy and the proper application of manual force it may be readily straightened, usually at one sitting.

The flexion contraction at the knee may be overcome also by careful and persistent manual stretching combined, if necessary, with division of the contracted tissues on the posterior aspect of the joint. (See Reverse Leverage and Posterior Capsulotomy.)

The flexion deformity at the hip is usually fixed by the contraction of the tissues about the anterior-superior spine of the ilium, including the tensor vaginæ femoris muscle, which is rarely paralyzed. Although it has been demonstrated by Dunn that resistant deformity may be reduced by splinting and traction, in confirmed cases operative treatment is usually indicated. The contracted tissues, together with the fascia, may be divided subcutaneously, or by open incision if necessary, after which the deformity may be reduced by gradual forcible extension of the thigh while the pelvis is fixed by flexing the other limb upon the body. In cases of marked contraction, *Soutter's operation* is most effective.[1] An incision is made just behind the anterior-superior spine, extending directly downward about 3 inches. The fascia is then incised transversely from the anterior-superior spine to the trochanter. With an osteotome contracted muscles and fascia attached to or about the anterior and inferior spines are separated from the underlying bone inside and outside the iliac crest and its anterior margin, including in some instances the spines themselves so that the attachments of the

[1] Boston Med. and Surg. Jour., March 12, 1914.

MEDICAL LIBRARY
OF THE
BOSTON CITY HOSPITAL

contracted tissues are actually displaced downward when the limb is hyperextended. When the contractions are overcome lateral deviation at the knee is corrected, if it is present, either by force supplemented by division of the lateral tissues or by osteotomy, and the bony points having been carefully protected by padding a long spica plaster bandage is applied to fix the limb in hyperextension at the hip.

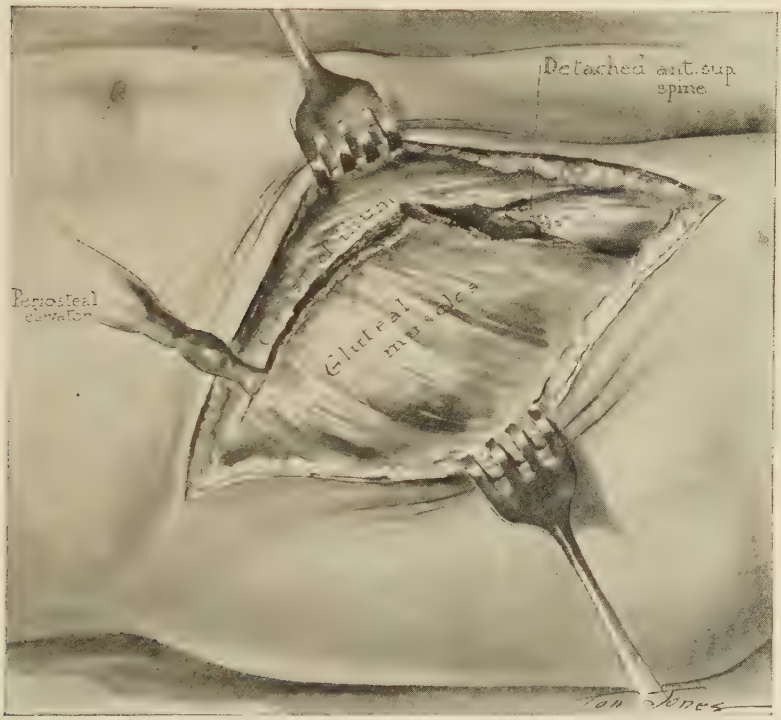

Fig. 606.—Gluteal muscles with small portion of crest of the ilium being detached. (Campbell.)

It may be noted that in cases of extreme bilateral contraction it is not advisable to correct both sides at the first operation, nor in very resistant cases to force the limbs to complete extension.

Campbell[1] has enlarged the scope of the Soutter operation by extending the incision backward for one-half or three-quarters of the extent of the crest of the ilium and downward anteriorly to the inferior spine. He not only cuts away the anterior-superior spine, but a part of the crest of the ilium throughout the incision as well and displaces it with its attached tissues downward after the Smith-Peterson method, as illustrated in Figs. 606 and 607. The deformity having been corrected the separated tissues form a new attachment lower down on the ilium. The extensive exposure enables one to divide other possible contractions

such as of the capsule of the hip-joint. Campbell has employed the operation for hemiplegic and inflammatory contractions, also for those secondary to congenital dislocation of the hip.

In some instances particularly those of extensive paralysis and disuse the limb may be persistently abducted. In extreme cases the deformity may be reduced by cutting, through the trochanter at the base and displacing it upward. This exposure will permit the division of the upper part of the capsule of the hip-joint.

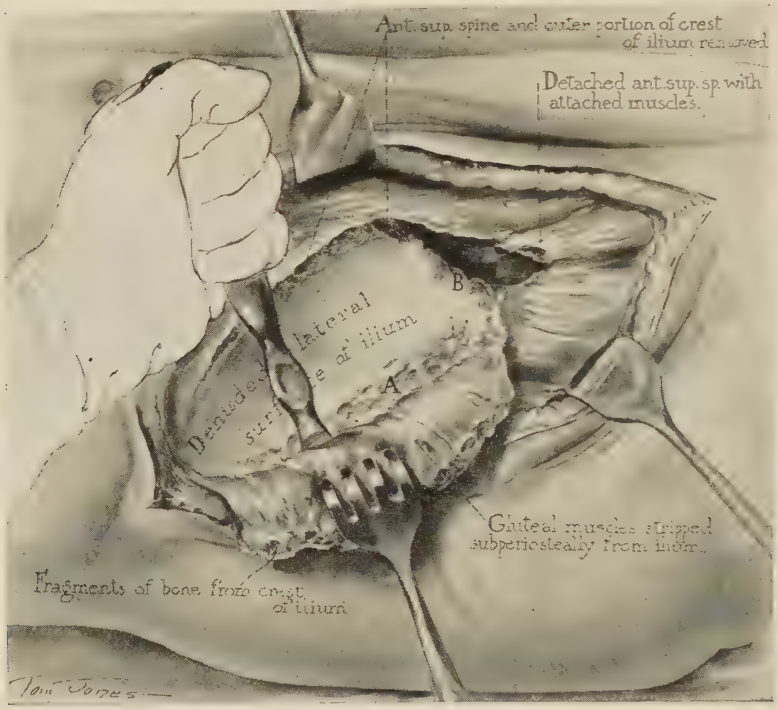
Ant. sup. spine and outer portion of crest of ilium removed
Detached ant. sup. sp. with attached muscles.
B
A
Gluteal muscles stripped subperiosteally from ilium
Fragments of bone from crest of ilium

FIG. 607.—*A*, surface of bone roughened to facilitate new attachment; *B*, surface of bone between antero-superior and inferior spines roughened for new attachment of flexor muscles. (Campbell.)

Epileptiform convulsions may follow forcible correction of deformity of any type, usually after a period of two or more days. The attack is often slight and transitory but if severe and repeated, the constraining support must be removed[1] to relieve the tension which is apparently its exciting cause.

FAT EMBOLISM.—It may be noted in this connection, that fat embolism is a complication to be considered in operations on atrophied bones which contain an abnormal proportion of fat. In 1000 operations

[1] In Lange's clinic, 1907–1924, convulsions followed operations in 26 cases: 8 for anterior poliomyelitis; 4 cerebral paralysis, 8 dislocations; 3 club-feet; 2 knock-knee; 1 flexion contraction at knee.

of this class collected by Renier[1] there were 10 cases of fat embolism with 4 deaths. It is particularly common after the forcible correction of paralytic deformity. The symptoms[2] which are often mistaken for those of shock or as a result of anesthesia may follow immediately or may be delayed for a day or more. These are usually vomiting, rapid respiration, anxious expression and fluttering pulse. In severe cases there may be high temperature, coma and convulsions. As the fat is absorbed during operations on the bones it would appear that the Esmarch bandage should always be employed in cases of this character.

Postoperative "pneumonia" is often pulmonary embolism. It commonly occurs on the eighth or ninth day. It differs from pneumonia in that pain precedes fever. Unless death is immediate, recovery is the rule.

The lesser degrees of deformity may be reduced by non-operative means, for example, by traction, by repeated applications of plaster bandages under slight corrective force, or by manipulation, or by braces and bandaging.

Paralytic knock-knee may be corrected by the Thomas knock-knee brace, and this brace when attached to a pelvic band is a useful form of support in the routine treatment of paralysis of the leg (Fig. 572).

The Thomas caliper knee brace is another cheap and useful support. It is of special service when there is flexion or lateral deformity of the limb (Fig. 401).

A very common deformity often secondary to flexion contraction at the hip is outward rotation of the leg on the thigh. In suitable cases this may be corrected. Transplantation of the biceps muscle, osteotomy of the femur or tibia, the correction of knock-knee or other deformities that may interfere with the adjustment of a brace, may be indicated in neglected cases.

Yount[3] has called attention to shortening of the tibial band of the fascia femoris as an important factor in flexion at the hip—outward rotation of the tibia and knock-knee. This and other lateral tissues should be divided if they resist the correction of deformity.

When distortion has been overcome and when functional use has been made possible by proper support, the development of muscles atrophied from disuse, and of those in which part of the muscular substance has been retained, is often surprising. In many of these cases the distortions which have developed during the temporary paralysis have alone prevented recovery, and this latent power may be revived even after years of disuse. Thus in many instances a definite prognosis is impossible until the deformities have been corrected and until the limb, properly supported, has been enabled to resume its function. Aside from the correction of deformity, operative treatment is undertaken when the area of final paralysis can be defin-

[1] München. med. Wchnschr., November, 1907; Timmer: Lect. f. orth. Chir., 1920, Bd. 40, Heft 3.

[2] Caldwell and Shuber: Surg., Gynec. and Obst., December, 1917.

[3] Jour. Bone and Joint Surg., January, 1926.

itely determined, for the purpose of rebalancing the residual power and assuring stability.

It is of most service for the deformities of the feet and it is described more at length in the chapter on Talipes.

Of these operations the most effective in cases of extensive paralysis is astragalectomy and backward displacement of the foot, since by this means the center of uncontrolled movement is removed and the malleoli implanted on the basic structure of the foot near its bearing center and the grip or resistance of the forefoot is restored. It is the most dependable of all operations because the structural conditions are changed in adaptation to the disability. (See Talipes.)

Fig. 608.—Paralysis of the left deltoid muscle, showing the elevation of the shoulder when the patient attempts to abduct the arm. (See Fig. 609.)

Muscle and Tendon Transplantation.—The object of this operation is to utilize the residual muscular power to best advantage, transferring, if possible, an agent of deformity, to a point where it may be functionally useful. (See Talipes.)

Transplantation of the Trapezius for Paralysis of the Deltoid Muscle.—In cases of this class there is disabling laxity or even subluxation at the articulation, and the exaggerated elevation of the shoulder when the patient attempts to raise the arm makes the disability very noticeable (Fig. 608). In exceptional cases, particularly when the other muscles of the scapulo-humeral group retain their power, transplantation of the trapezius muscle may be of service.

A broad flap of skin, its convexity over the upper quarter of the deltoid muscle, is raised, exposing the trapezius. This is thoroughly separated from its attachment to the acromion and sufficiently from the spine of the scapula and clavicle. The capsule is incised and made tense by overlapping the edges. The arm being fully abducted and the flap of muscle is sewed with numerous sutures to the atrophied deltoid or preferably a flap of fascia from the thigh may be quilted to the trapezius and attached to the bone and periosteum at the inser-

Fig. 609.—Illustrating the improvement in the range of abduction obtained by transplantation of the trapezius muscle. The line of the incision is shown.

tion of the deltoid. The limb is fixed in complete abduction by means of a plaster splint. This attitude should be retained for several months. Afterward massage and exercises should be employed. The humerus is usually held more securely, a certain power of abduction is restored and the functional ability often greatly increased (Figs. 608 and 609).

The upper portion of the pectoralis major muscle may be transplanted in place of the trapezius. A part of the sternal and half of the clavicular attachments of the muscle are separated as far as possible

without injuring the nerve supply, turned over the shoulder and attached to the spine of the scapula. Spitzy has divided the humerus above the insertion of the pectoralis major and rotated it outward so that the tension on its upper fibers of the muscle enables it to serve as an abductor. (See Arthrodesis).

Persistent paralysis of the muscles of the arm and hand is comparatively unusual. The operation of tendon shortening or implantation combined with transplantation of the tendons of one or more active muscles may be of service in the treatment of wrist-drop and persistent pronation and opportunities may suggest themselves in other situations whenever it is possible to utilize the muscular power to better advantage.

The relative strength of the flexors and extensors of the wrist, according to Frohse and Fränkel, is as follows:

		Weight, gr.	Fiber length, cm.
Flexors	Flexor carpi radialis	17.8	5.8
	Flexor carpi ulnaris	21.4	4.8
	Extensor carpi radialis longior	25.9	7.6
	" " " brevior	24.2	5.3
	Extensor longus hallucis	13.5	4.7
	Extensor proprius indicis	5.7	5.1

The preponderance of power in the extensors of the wrist indicates the importance of this attitude on the function of the hand.

Transplantation of the Hamstring Muscles (Figs. 611–614).—One of the most satisfactory operations is transplantation of the biceps for paralysis of the quadriceps extensor muscle. An incision is made over the muscle from the upper third of the thigh to the head of the fibula. The tendon of insertion together with a section of bone or cartilage is separated from the head of the fibula and is dissected back with the short attachment of the biceps to the femur to a point where the muscle may pull in a direct line from the tuberosity to the patella. An incision is then made over the patella, exposing the tendon of the quadriceps. With a thin chisel the incision over the patella is deepened and the two sides together with a thin section of underlying bone are separated to form a bed for the terminal end of the biceps. A sufficiently capacious tunnel between the deep fascia and the skin in the direct line of traction is made with long strong forceps through which the transplanted muscle is drawn. It is then inserted through the quadriceps tendon and its extremity of bone and cartilage is buried in the patella to which it is attached and to the quadriceps tendon with heavy kangaroo sutures. The wounds are closed and the limb is supported in the extended position by a plaster spica. This is replaced in a few weeks by a support which is removed from time to time from muscular reëducation and until the strength of the transplanted muscle has been developed by exercises.

If the biceps is weak, the semimembranosus and tendinosus may be transplanted in the same manner, the openings being made on the inner side. The result is not as satisfactory, because the muscular

pull is less direct. In some instances all the hamstrings may be transplanted, but unless the calf muscle is active there is danger of recurvation at the knee. If the calf muscle retains its power, or if the resistance to dorsal flexion is restored by astragalectomy and backward displacement of the foot, the patient may discard apparatus at the end of several months.[1] The gain in power, however, is not often sufficient to enable the patient to completely extend the limb, as in the accompanying figure (Fig. 610), but when the limb is thrown forward in walking the leg may be extended on the thigh and stability assured by the tension on the transplanted muscle.

FIG. 610.—Showing restoration of the power of extension by transplantation of the biceps muscle. A very unusual result.

There are two essentials for success: (1) that flexion at the knee be entirely corrected. If it be resistant as in cases of long standing an osteotomy of the femur may be required; (2) that there shall be resistance of the foot to dorsiflexion. Thus in many instances astragalectomy and backward displacement of the foot must be considered as an essential preliminary to the success of the operation.

The sartorius and tensor vaginæ muscles have been transplanted for the same purpose, but the results are not satisfactory because the posterior muscles are made tense when the limb is thrown forward, while these muscles are relaxed by the same movement.

TRANSPLANTATION OF THE SEMIMEMBRANOSUS MUSCLE FOR GLUTEAL PARALYSIS.[2]—An incision is made in the median line extending from

[1] The functional results in a large number of these cases have been analyzed by Kleinberg, Am. Jour. Orthop. Surg., July, 1917.

[2] Yergason: Am. Jour. Orthop. Surg., May, 1918.

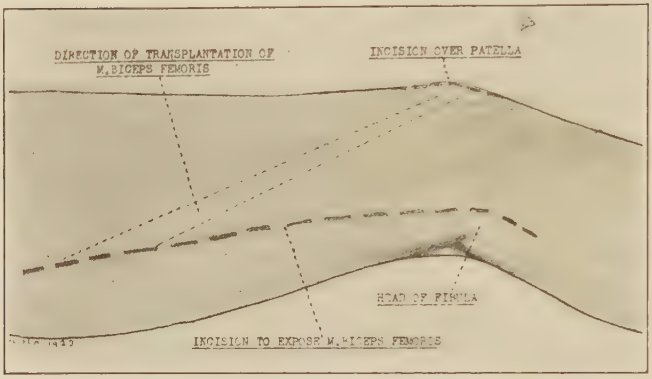
DIRECTION OF TRANSPLANTATION OF M.BICEPS FEMORIS
INCISION OVER PATELLA
HEAD OF FIBULA
INCISION TO EXPOSE M.BICEPS FEMORIS

FIG. 611.—Transplantation of biceps femoris muscle into patella.

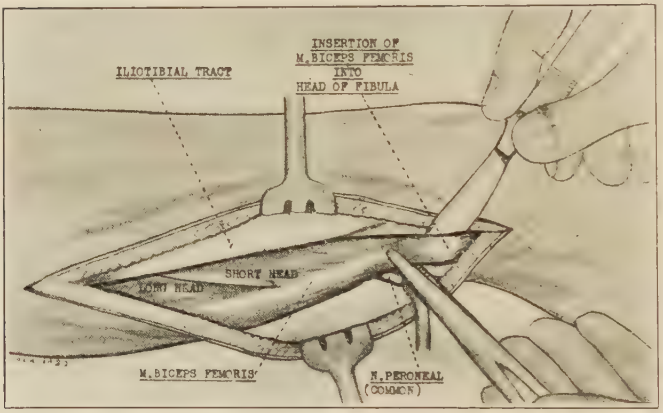

FIG. 612.—Transplantation of biceps femoris muscle into the patella. A section of bone is removed from the insertion of the biceps to the fibula.

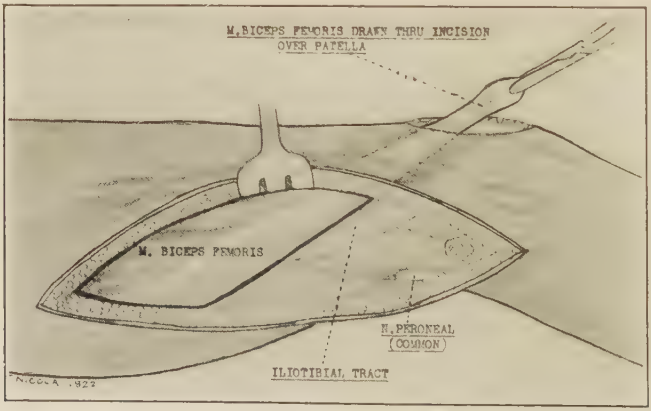

FIG. 613.—Transplantation of biceps femoris muscle into patella.

MEDICAL LIBRARY BOSTON CITY

just above the gluteal fold downward for three or four inches, exposing the tendon of the muscle. This is freed by blunt dissection and is cut across at its junction with the muscular belly. A second incision is then made from a point two inches below the posterior border of the trochanter downward, exposing the lower border of the insertion of the gluteus maximus. At this point a hole is bored through the bone and enlarged sufficiently to permit the insertion of the transplanted tendon which is drawn through, turned back, and sutured to itself. The belly of the muscle is then sutured to the semitendinosus and the wounds are closed. A plaster spica or brace is used to support the limb in extension until the resistance of the transplanted tendon is sufficient.

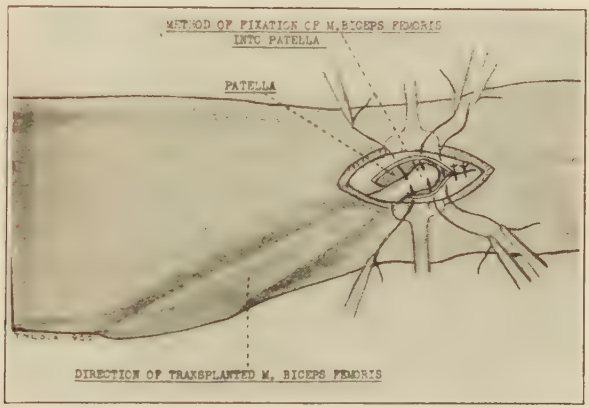

Fig. 614.—Transplantation of biceps femoris muscle into patella. (Diagrams drawn by Dr. T. Nicola.)

Ober's Operation for Gluteal Paralysis.—Lange first suggested using the erector spinæ muscle to replace the paralyzed gluteal extensor. The procedure has since been much improved by Ober, who has substituted fascia for silk ligaments. The operation is conducted as follows: The attachment of the erector spinæ muscle is exposed by an incision of sufficient length, and it is dissected upward from its origin for a distance of about 4 inches. An incision on the outer aspect of the thigh is extended downward from the trochanter to about the upper border of the knee-joint and a band of fascia $1\frac{1}{2}$ inches in width is separated below and freed up to the trochanter. At this point a hole is bored in the femur, the fascia is passed through it and firmly attached at this point. It is then passed through a subcutaneous channel over the gluteus muscle and is sewed to the under surface of the quadriceps extensor at a tension. The limb is afterward supported in the extended attitude for several months. The object of the operation is to assure sufficient support to assist whatever active powers persist in the weakened gluteal extension. The operation details are shown in Figs. 615 and 616, furnished by Dr. Ober.

Transplantation of the Tensor Vaginæ Femoris for Paralysis of the Gluteus Medius.—Paralysis of the gluteus medius causes an awkward swaying of the body toward the affected side and insecurity.

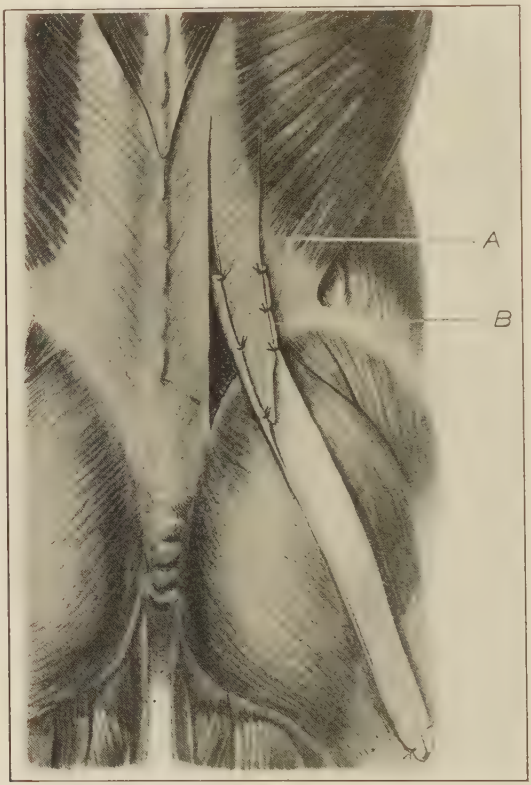

Fig. 615.—*A*, outer half of erector spinæ group split off and dissected free from its attachment; *B*, showing method of suturing fascia lata to inferior surface of freed spinal muscles. (Ober.)

Legg[1] has in a number of cases transplanted the tensor vaginæ femoris muscle with satisfactory results. The operation is described by him as follows:

The incision starts at the anterior-superior spine, and extends backward and downward over the great trochanter, and then downward along the course of the femur for about three inches.

The skin with the subcutaneous fat is reflected forward, exposing the fascia lata.

Anteriorly, running downward from the anterior-superior spine, the fascia lata is seen to become thin before extending over Scarpa's

[1] Jour. Am. Med. Assn., January 27, 1923.

triangle. Along this line the fascia is incised downward from the anterior-superior spine to three inches below the great trochanter, where it is divided transversely backward for about one and a half inches.

At about one and a half inches below the great trochanter, the fibers of the tensor fasciæ femoris are seen becoming inserted into the fascia lata.

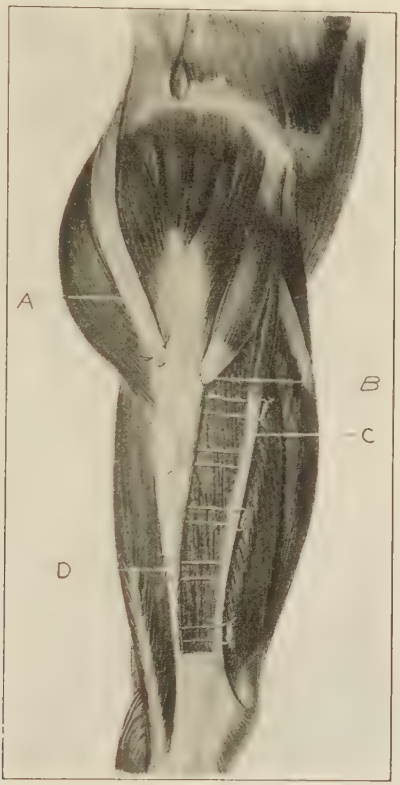

FIG. 616.—Long flap of tensor fascia, 1¼ inches wide, dissected free from the thigh up toto and including some muscle fibers of the tensor fasciæ latæ. *A*, flap of fascia extending up to spinal muscles; *B*, hole drilled through femur at level of insertion of gluteus maximus tendon; *C*, edge of fascia—space closed with mattress sutures. (Ober in a later communication states that he no longer drills a hole in the femur.)

The outer surface of the femur is next exposed, about two and a half inches below the trochanter, by dividing the fibers of the vastus externus. A periosteal flap is turned downward at this point, and a groove, going into the marrow, is made about one inch long and one-half inch wide.

At this point the extremity of the transplanted muscle is sutured as illustrated in the diagram, the limb being held in about 30 degrees of abduction. This attitude is maintained either by a plaster spica or abduction splint for six months. The gain in power is not usually sufficient to enable the patient to abduct the limb directly while

lying on the other side, but in locomotion the limb may be thrown forward in the abducted attitude, so that the lunge of the body toward that side is much lessened.

The most effective of the operations for abductor paralysis from a mechanical standpoint is that of Dickson.[1] His description follows:

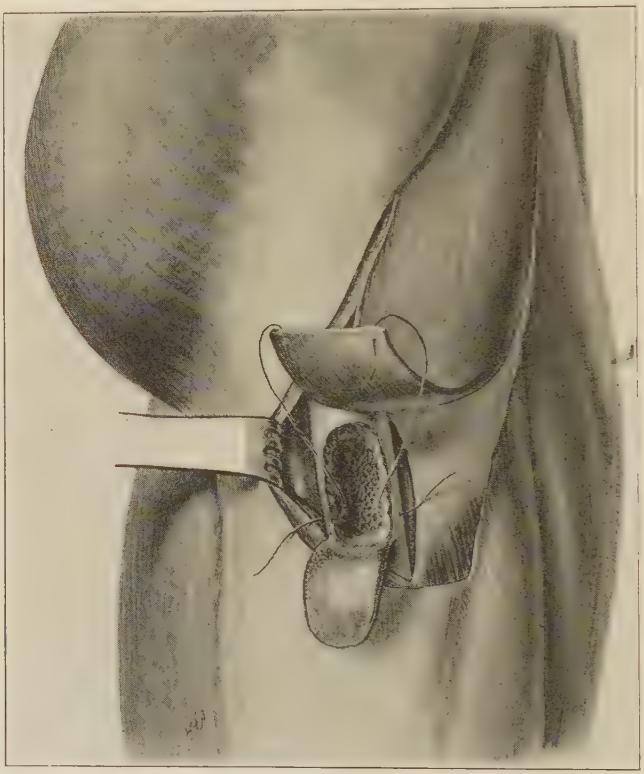

Fig. 617.—Legg's operation. Groove in femur and freed tensor fasciæ femoris with silk suture before insertion into the femur.

"1. With the patient lying well over on the side, the skin incision is made. This starts at the anterior-superior spine and runs posteriorly along the crest of the ilium to the posterior-superior spine. Anteriorly, it is prolonged downward from the anterior-superior spine onto the thigh for a distance of about 4 inches, passing along the inner border of the tensor fasciæ femoris (lata). The skin and subcutaneous fat are reflected back, exposing the fascia covering the tensor fasciæ femoris (lata), the gluteus medius and the gluteus maximus (Fig. 619—Insert).

"2. The tensor fasciæ femoris is next separated from the sartorius and rectus femoris anteriorly for a distance of about 4 or 5 inches, and

[1] Bone and Joint Surg., January, 1927.

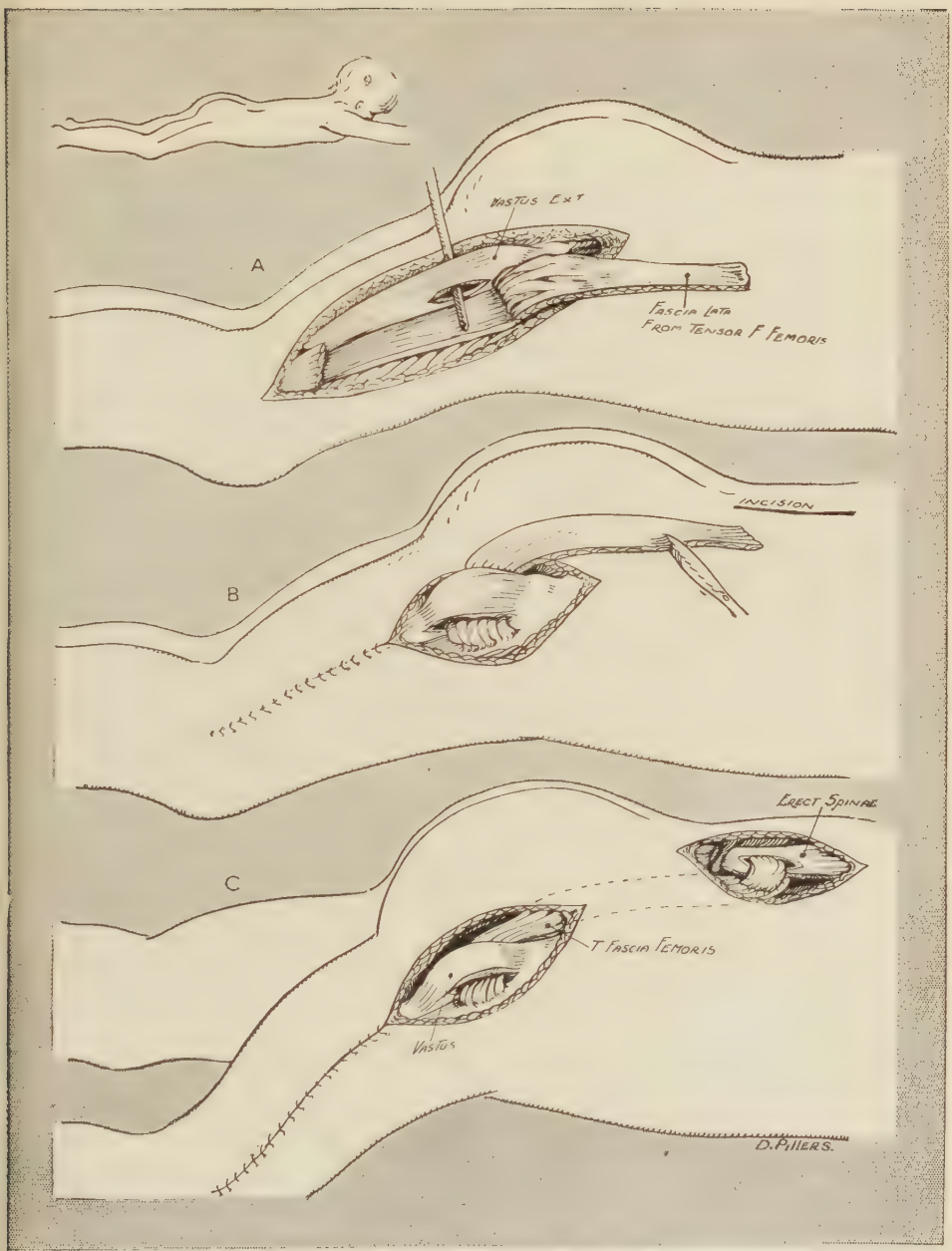

FIG. 618.—Hey Groves combination of the Legg-Lange operation. The tensor fasciæ femoris muscle by its attachment to the erector spinæ forms a loop like a digastric muscle and thus may serve as an abductor and also as a flexor and extensor of the limb. *A*, Thigh operation; the iliotibial band is isolated and divided at its lower end. A tunnel is prepared for the new tendon at the base of the great trochanter under the upper part of the origin of the vastus externus. *B*, A great part of the incision is closed; the iliotibial band has been brought through the tunnel at the base of the trochanter. *C*, The superficial part of the erector spinæ has been exposed and isolated; the iliotibial band has been drawn upward and backward under the skin and attached to the erector muscle. (British Journal of Surgery, January, 1927).

from the gluteus medius for about 3 inches posteriorly; care should be taken in this dissection not to interfere with the nerve supply to the

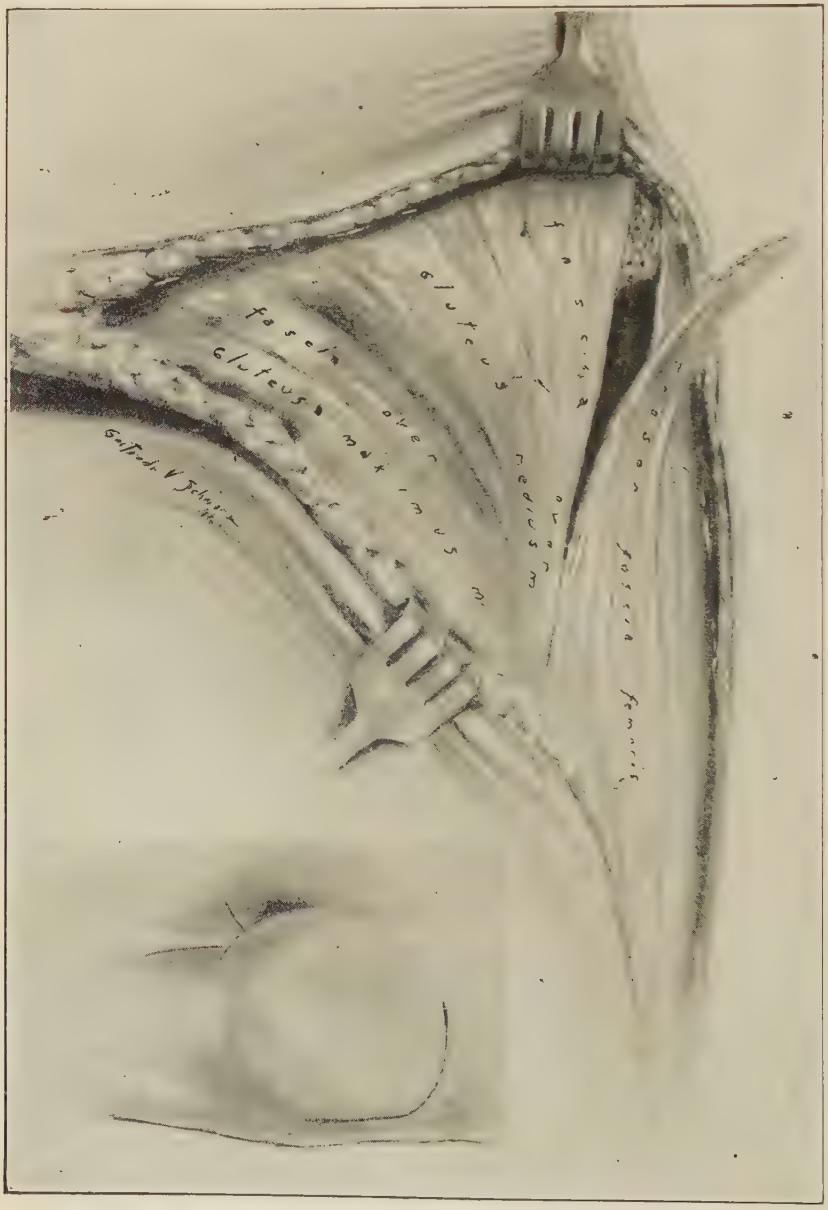

FIG. 619.—Dickson's operation for abductor paralysis. Tensor fascia femoris partly dissected free and turned back with a shell of bone from the crest of the ilium; fascia covering gluteus medius and gluteus maximus shown intact. (Insert—Skin incision.) (Jour. Bone and Joint Surg.)

muscle. The nerves to the tensor fasciæ femoris, coming from the superior gluteal nerve, emerges from beneath the gluteus medius at about its lower third and passes into the under surface of the muscle.

"3. The tensor fasciæ femoris (lata), having been freed well down toward the knee, is separated from its origin at the crest of the ilium

Fig. 620.—Dickson's operation for abductor paralysis. Tensor fascia femoris passed through the tunnel made by lifting up the gluteus medius. The muscle emerges through a slit made in the fascia at the anterior border of the gluteus maximus. (Jour. Bone and Joint Surg.)

by chiselling off a shell of bone. As large a shell as possible is taken; usually a good substantial piece about 2 inches long can be secured (Fig. 619).

"4. The atrophied gluteus medius is now carefully lifted up and through the tunnel thus formed beneath it the severed insertion of the

FIG. 621.—Dickson's operation for abductor paralysis. Tensor fascia femoris has been made fast to the groove cut in the crest of the ilium in the region of the posterior superior spine; stitches attaching its posterior edge to the under surface of the gluteus maximus also shown. (Jour. Bone and Joint Surg.)

tensor fasciæ femoris (lata) is passed, to emerge through an incision in the fascia made at the anterior border of the gluteus maximus (Fig. 620). This tunnel beneath the gluteus medius should be made close

MEDICAL LIBRARY
OF THE
BOSTON CITY

to its insertion into the greater trochanter to allow the transplanted muscle to pass as far as posteriorly as possible.

"5. The thigh is now strongly abducted to allow the insertion of the tensor fasciæ femoris (lata) to pass well posteriorly and reach the posterior-superior spine if possible. It will almost invariably reach this position if the abduction is carried far enough. At this point a groove is made in the crest of the ilium into which the shell of the bone adherent to the origin of the tensor fasciæ femoris (lata) is securely fastened with No. 3 chromicized catgut or silk suture (Fig. 621). If, even with extreme abduction, the tensor fasciæ femoris (lata) is too short to reach the posterior-superior spine, a strong band of fascia attached to the crest of the ilium can be turned up, and by suturing the tensor to this a firm attachment for the transplanted muscle can be secured. Occasionally, when unable to bring the muscle as far posterior as was desired, we have raised a flap from the side of the ilium below the crest and attached the muscle at this point. It is usually only in the older cases that we have found it necessary to resort to fixation below and slightly anterior to the posterior-superior spine.

FIG. 622.—Dickson's operation for abductor paralysis, showing limb fixed in extreme abduction. (Jour. Bone and Joint Surg.)

"6. The posterior edge of the transplanted tensor fasciæ femoris is then firmly sutured to the under surface of the gluteus maximus, the sutures through the gluteus maximus being placed as far posteriorly as possible, thus drawing the transplanted muscle back and anchoring it (Fig. 621). If the muscle has been displaced as far posteriorly as it should be, it will, in its new position, pass over the anterior half of the greater trochanter.

"7. The wound is closed, all dead spaces being carefully obliterated and the limb put up in plaster in extreme abduction (Fig. 622).

"8. At the end of three or four weeks the splint is cut down and daily exercises given. The exercises consist in placing the patient in a prone position and teaching him to extend the hip on the pelvis with the thigh abducted. The cast is removed and the extremity allowed gradually to come down from the abducted position at the end of six to eight weeks and the patient allowed to use the extremity."

Silk Tendons and Ligaments.—The use of silk to elongate tendons of active muscles in order to transplant them at a point of election was popularized by Lange, who demonstrated that silk tendons were in some instances eventually transformed by penetration and absorption into fibrous cords.

Silk ligaments are used, as the name implies, as direct internal stays to hold a part in normal position. For this purpose, however, they have been practically supplanted by the use of strips of fascia. It is assumed by those who employ them that they are later transformed to fibrous ligaments and thus to permanent supports. This, however, is very doubtful. They are of service as internal splints, as adjuncts to apparatus, to tendon transplantation, or arthrodesis, or even, it may be, during the stage of recovery as a protection to weakened muscles, but as permanent and independent supports they are usually disappointing.

Silk ligaments have been employed chiefly in the treatment of paralytic talipes, but Bartow has employed them for insecurity at the larger joints.[1]

A typical operation is that for laxity at the shoulder-joint following paralysis of the supporting muscles. A short incision is made over the acromion and a drill with an eye at the point is pushed through the acromion and the head of the humerus emerging through an incision in the skin near the base of the greater tuberosity. A looped cord of silk is attached to the drill which is withdrawn. A second similar incision is made with the drill through the acromion and humerus emerging about three-fourths of an inch from the first. The lower end of the silk cord is then passed beneath the muscle, attached to the drill and drawn upward through the opening in the acromion. The two ends are then tied to one another, holding the humerus firmly in the socket. The arm is afterward supported for four or more weeks.

Bartow uses strands of 14 to 16 Corticelli silk, doubled or quadrupled, according to the strength required, paraffined according to the Lange method.

Loeffler's Operation for Outward Rotation of the Limb.—In cases of excessive outward rotation of the lower extremity, Loeffler[2] splits the deep fascia as in the diagram (Fig. 623) from above downward about one and a half inches anterior to the trochanter. The limb is then rotated inward and the posterior margin of the fascia is drawn behind the trochanter and sewed in a groove cut in its posterior surface. The fascia is then united, the wounds are closed and a plaster support is applied, holding the limb in inward rotation for a time.

Arthrodesis.—Arthrodesis is most often employed at the ankle-joint, to fix the foot at a right angle with the leg and at the subastragaloid and medio-tarsal joints for lateral deformity. (See Talipes.) In exceptional cases arthrodesis or excision at the knee may be advisable in the older patients, but in young subjects the strain upon the long,

[1] Am. Jour. Orthop. Surg., May, 1913.
[2] Ztschr. f. Chir., 1922, vol. xlvi.

weak lever formed by the two bones will almost always induce deformity. A preferable procedure is *patellapexy* (Stern[1]). A vertical incision about 4 inches in length is made over the patella. Its surface is denuded of cartilage which is included in the lateral flaps. Vertical incisions are made on either side of the patella to separate it from the lateral fascia and capsule. It is then drawn to one side and a bed prepared for it in the femur, into which when turned upon its vertical axis its dorsal surface may be embedded. It is then screwed to the femur, the tissues sewed over it and a splint is applied to be worn until fixation is assured. Patellapexy permits about 10 degrees of motion which lessens the strain and yet assures stability. Arthrodesis at the hip may be of service in cases of complete paralysis of the pelvic

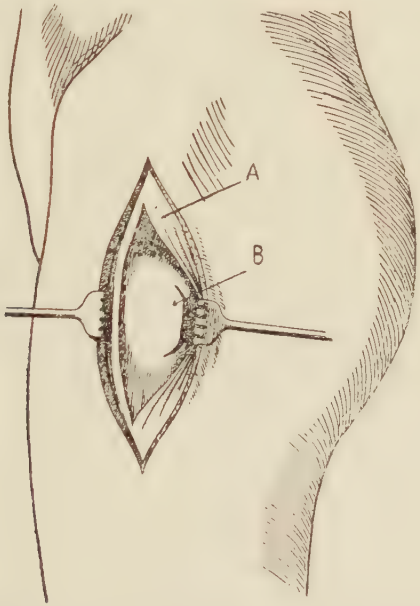

FIG. 623.—The Loeffler operation for outward rotation of the limb shows the groove into which the posterior margin of the fascia is to be sewed.

muscles. The operation is performed as for arthrotomy in the treatment of congenital displacement of the hip, except that the cartilage is thoroughly removed from the head of the femur and from the acetabulum and the interval closed by wedges of bone cut from the tibia or elsewhere. A short spica plaster support should be worn until union is firm.

Athrodesis at the shoulder is of service when the supporting muscles are paralyzed, while the trapezius and other muscles are active. An incision is made directly over the acromion downward through the deltoid muscle about 3 inches in length; all the tissues are divided

[1] Jour. Bone and Joint Surg., April, 1924.

and dissected laterally, so that the head of the humerus may be exposed.

The cartilage should be completely removed and the apposed bones deeply scored and closely apposed by sutures or by a bone screw. The arm should be fixed at the limit of abduction and inclined forward about 25 degrees and rotated outward. If fixation is attained in abduction, the scapular muscles, especially the trapezius and the serratus, serve as elevators and abductors of the arm.

Personally I prefer to lay bare the under surface of the acromion, and to cut away the upper margin of the glenoid. The superior surface of the head of the humerus is then cut flat and a groove made in its antero-lateral aspect into which the acromion is fitted when the arm is abducted to a right angle and inclined forward to the desired degree. Security is assured by a bone screw passed through the acromion into the head or by heavy sutures. The capsule and other tissues are then sewed over the junction and a plaster splint is applied, to be worn until consolidation is complete.

As it is often difficult to secure anchylosis in the younger class of cases, bone grafts are sometimes used to insure eventual security.

Bassie Operation.—One of the most effective of the anchylosing operations is that of Bassie. The upper third of the humerus is exposed by the usual incision and the outer third of the head and shaft is split and separated with a wide chisel forming a flap attached at its lower border. The under surface of the acromion having been laid bare of cartilage, is then apposed to the shaft of the abducted humerus and the outer bone flap sewed to its superior margin.

Kapis[1] suggests as a supplemental operation to a successful arthrodesis at the shoulder a resection of about 6 cm. of the center of the clavicle, and pseudoarthrosis at this point in order to increase the range of movement of the arm.

Arthrodesis[2] at the elbow and wrist may assure an improved attitude. Whenever possible these operations should be reinforced by tendon or muscle transplantation. Anchylosis or even satisfactory fixation cannot be attained by this means until the bones are sufficiently developed. The operation should not be performed therefore until the child is at least eight years of age.

In cases of paralysis of the upper arm muscles in which those of the forearm retain their power, flexion may be restored in some degree by separating the muscles which are attached about the internal condyle and displacing them upward with the purpose of so increasing the leverage as to enable them to flex the elbow. Steindler[3] describes the operation as follows:

Steindler Operation.—"An incision is made on the side of the humerus, beginning three inches above the internal epicondyle between the brachialis internus and triceps muscles down to the internal epi-

[1] Ztschr. f. Chir., September 22, 1923.
[2] Bucholz: Am. Jour. Orthop. Surg., June, 1918.
[3] Interstate Med. Jour., 1918, No. 3.

condyle and from there over the anterior aspect of the forearm obliquely downward and outward in the direction of the pronator teres muscle. Then, beginning from the lower half of the incision the superficial and deep fasciæ of the forearm are cut and the superficial layer of the flexor muscles of the forearm is carefully dissected. These muscles are the pronator teres, flexor carpi radialis, palmaris longus and flexor carpi ulnaris. This superficial layer of muscles is carefully prepared and dissected off its insertion at the epicondyle, taking with it the periosteum. At this step it is very advantageous to look up the ulnar nerve and protect it from possible injury. After this superficial muscle layer has been dissected off its insertion, it is followed and carefully freed for two or three inches downward, care being taken not to injure the median nerve as it descends between the two heads of the pronator radii teres.

"Then this common muscle bundle is drawn upward under strong flexion of the elbow-joint. The inner surface of the humerus is approached, by blunt dissection, through the intermuscular septum between the brachialis anticus and triceps. The periosteal covering of the humerus is split longitudinally, the freed muscle ends are then pulled upward two or three inches above the epicondyle, and fastened over the denuded bone by sutures to the edges of the periosteum. The fasciæ are then sutured and the skin closed.

"The arm is put up in splint in extreme flexion and held there for six or eight weeks. After-treatment is begun after three weeks, and consists in careful active flexion movement of the elbow and massage."

Osteotomy.—In some instances, particularly in the extreme deformities in the adult, osteotomy of the femur at the hip or knee may be necessary in order to overcome resistant distortion.

Simon[1] suggests in cases of paralysis of the gluteal muscles a cuneiform osteotomy at the level of the trochanter minor on the posterior aspect of the femur so that, the shaft having been displaced backward in its relation to the trunk, there would be less of the compensatory lunge of the body forward in walking.

Nerve Grafting.—A number of operations have been performed with the aim of restoring muscular power in paralyzed muscles by uniting the inactive nerve with one which is still in communication with the nerve centers practically without success. The operations for paralytic deformities of the feet are described in Chapter XXIII.[2]

Review of Treatment.—This consists in absolute rest during the acute or sensitive stage, supplemented by suitable support to hold the part in the best possible position for usefulness when the final extent of the paralysis has become evident. During the stage of recovery any treatment that will improve the nutrition of the part is of service; methodical movements of the joints and muscle training being of special value. The limb in which the circulation is deficient should be protected from the cold by proper covering and its nutrition may be improved by the direct application of heat, the hot-air or hot-water

[1] Ztschr. f. Chir., November 22, 1924.
[2] Steindler: Am. Orthop. Assn., December, 1916.

bath both being useful. The swimming pool which permits exercise without weight-bearing is a very valuable means for the development of weak muscles in cases of extensive paralysis. Eventually functional use, which is made possible even in extreme cases by apparatus, is of the most effective means of preserving and stimulating whatever muscular power remains, and special gymnastic exercises to this end should be employed whenever practicable. The prevention of deformity during the growing period is of the first importance. Every morning and night the joints of the partly paralyzed member should be passively moved through normal range in all directions in order to prevent the gradual limitation of the range of motion which is the first indication of deformity. Lateral deviation of the limb or foot may be prevented by passive manipulation and by careful adjustment or modification of the support. Braces should be strong and as simple as may be in construction. Elastic bands and springs, applied with the design of replacing paralyzed muscles, are of little practical use, since they are ineffective in action, difficult to adjust and easily disarranged. The parent, when treatment is begun, must be impressed with the fact that a brace must be strong enough to serve its purpose; that its period of usefulness is limited and that it must be replaced when it is outgrown; that the breaking of a brace from time to time is unavoidable, and that such accidents, in so far as they are evidences of the functional activity of the patient are favorable indications.

When the area of persistent paralysis can be definitely determined, operative treatment with the aim of relieving the patient from braces or for the purpose of making them less burdensome is often of great value.

At the present time many operations are required to correct unnecessary deformity, especially in cases in which the paralysis is extensive.

Whenever possible, patients should be forced to stand and to walk with crutches, and this is always possible even when the paralysis of the lower extremities is complete, unless the trunk and arm muscles are also involved.

In cases of this type in which the limbs are of service only when braced, the two operations that are of greatest service are the Soutter operation to overcome contraction at the hips and astragalectomy and backward displacement at the ankles to restore the bearing capacity of the foot.

Careful supervision of the patient, even though the weakness is not great, will be necessary during the period of growth. The contrast between the development and symmetry, the muscular power and practical utility of a limb that has received this care and supervision, and one that has been neglected, is sufficiently striking to impress anyone with the necessity for this tedious and apparently never-ending treatment.

Thus, in this as in other chronic diseases and disabilities the character and the duration of the treatment, its object, and the final results that one may expect to attain by it, should be explained to the parents when the care of the patient is undertaken.

CHAPTER XVIII.

DISEASES OF THE NERVOUS SYSTEM (Continued).

CEREBRAL PARALYSIS OF CHILDHOOD—SPASTIC PARALYSIS.

Cerebral paralysis or palsy is in orthopaedic practice second only in frequency and importance to anterior poliomyelitis. It is, however, quite different in its distribution and in its effects. It is a form of disability that is characterized by motor weakness, by stiffness and loss of control, rather than by paralysis. It affects entire members and it results in atrophy, contractions, and deformity.

It may involve half the body—hemiplegia.

It may be limited to the lower extremities—paraplegia.

It may involve both the upper and lower extremities—diplegia.

In rare instances but one extremity is affected—monoplegia.

Distribution.—In 451 cases of cerebral paralysis analyzed by Peterson,[1] 332 were or the hemiplegic type, 73 were of the diplegic type, and 46 were of the paraplegic type. Of 121 consecutive cases observed at the Hospital for Ruptured and Crippled, 63 were paraplegic or diplegic and 58 were hemiplegic.

Of 132 cases of hemiplegia analyzed by Thomas but 36 were of congenital origin, a large proportion of the remainder followed acute infectious disease, the paralysis resulting from hemorrhage, thrombosis, embolism, or encephalitis.[2]

Etiology and Pathology.—Cerebral paralysis may be divided into two classes—the congenital and the acquired. The diplegic and paraplegic forms are usually congenital, the hemiplegic form is more often acquired.

Congenital Paralysis.—Paralysis of intra-uterine origin may be the result of maldevelopment or injury or a secondary effect of intercurrent disease of the mother. Injury at birth either from prolonged labor or instrumental delivery is apparently the most common cause.

Acquired Paralysis.—Acquired paralysis may be due to hemorrhage, embolism, thrombosis, or to disease. Sachs[3] presents the following classification of causes and effects:

Paralysis of Intra-uterine Origin.

Large cerebral defects—true porencephaly.

Hemorrhages of intra-uterine origin—softening.

Agenesis corticalis.

[1] American Text-book of Diseases of Children.
[2] Bull. Johns Hopkins Hosp., June, 1909.
[3] Nervous Diseases of Children.

Paralysis Acquired after Birth.

1. Meningeal hemorrhage—very seldom intracerebral. Embolism: thrombosis in marantic conditions, and occasionally from syphilitic endoarteritis. Results of these vascular lesions: cysts; softening; atrophy; sclerosis, diffuse and lobar.

2. Chronis meningitis.

Paralysis Occurring during Labor.

Meningeal hemorrhage—very seldom intracerebral. Resulting conditions: meningo-encephalitis chronica; sclerosis; cysts; atrophies; porencephalies.

3. Hydrocephalus.

4. Primary encephalitis (Strümpell).

General Symptoms.—Motor.—The effect of the lesion of the brain and of the secondary changes in the anterior pyramidal tracts of the cord is to impair the voluntary control of the limbs supplied from the affected area, and at the same time the inhibition of the higher centers is impaired or lost. Thus, together with the loss of power, there is a corresponding exaggeration of the reflexes causing a spastic rigidity of the limbs varying with the degree of voluntary control. This induces distortion, which finally becomes fixed by the adaptive changes in the tissues. As the centers for the nutrition of the paralyzed parts are not involved, the muscles do not waste and the circulation is but little affected. Thus the atrophy as compared with paralysis of spinal origin (anterior poliomyelitis) is comparatively slight, and this, together with the retardation of growth, is due rather to the general effects of the disease and to the loss of function than to the direct influence of the nervous lesion.

Mental.—In this form of paralysis the lesion is of the brain, and the direct injury of its structure and the interference with its development is likely to cause mental impairment. This mental impairment is usually more marked in the paraplegic or diplegic than in the hemiplegic form, because in the latter but half the brain is involved, and because the injury or disease occurs at a later period of its development. So, also, the mental development is usually less interfered with in the paraplegic than in the diplegic type. For, although both hemispheres were involved, yet the recovery of power in the arms indicates that the injury was less extensive than when the weakness persists in one or both of the upper extremities.

It is estimated that in 50 per cent. of the hemiplegic cases the patients are feeble-minded, although comparatively few (13 per cent.) are idiotic. In the paraplegic and diplegic forms of paralysis about 70 per cent. of the patients are feeble-minded, and from 40 to 50 per cent. are idiotic. (Sachs.)

Epilepsy is an accompaniment of about 45 per cent. of all forms of cerebral paralysis, and in 20 per cent. of the cases athetoid or associated movements in the paralyzed parts persist. (Peterson.)

Congenital Weakness and Paralysis.—The congenital form of cerebral paralysis is often seen in orthopaedic clinics, because the effect

MEDICAL LIBRARY
BOSTON CITY

of the lesion of the brain in retarding physical development first attracts the attention of the mother. Thus infants are brought for examination because they are unable to sit or stand at the usual time. In certain instances the cause of the physical weakness is simple idiocy. In such cases the vacant expression, the inability of the child to recognize even its mother, the extreme weakness, and the absence of the spastic rigidity of the limbs will make the diagnosis clear.

In another class of cases the weakness appears to be caused simply by retarded cerebral development. The patient is apathetic and weak, but there is no evidence of paralysis, and the comparative intelligence of the patient distinguishes this type from the idiotic class.

FIG. 624.—Congenital cerebral diplegia (idiocy).

In the characteristic form of cerebral paralysis as seen in early life the child may be idiotic, or simply apathetic, or fairly normal in intelligence, but it is always weak, and in the sitting posture the spine is usually bent backward into a long, more or less rigid curve. It makes no effort to stand, and when placed in the erect posture it will be noticed that the thighs are usually pressed closely against one another and that the feet are extended. The limbs are "stiff." There is a peculiar resistance to flexion at the extended joints, which slowly gives

way under steady pressure. This is the characteristic spastic rigidity (Fig. 625).

Deformities.—These children usually begin to stand at about the third year and later to walk with an awkward, shuffling gait; the limbs are usually flexed, adducted, and rotated inward; the knees touch one another or the legs may be crossed, while the feet turn inward in a persistent attitude of slight equinovarus. The equilibrium is very easily disturbed, partly because of the deformities and partly because of the direct lesion of the brain. In the majority of the congenital cases the

FIG. 625.—Spastic paraplegia, illustrating the adduction of the thighs and the equinus deformity.

paralysis is paraplegic in its distribution; perhaps 15 per cent. are of the hemiplegic variety, and in a somewhat larger number the paralysis is diplegic in distribution (Fig. 624).

The typical deformity of the foot is equinovarus, but in older subjects who have walked about in the attitude of flexion at the hips and knees there may be an accommodative distortion of the foot toward valgus, or even to an extreme degree of calcaneovalgus.

Mentality.—As has been stated, in a certain number of cases the intelligence is not impaired, but more often the patients are distinctly

feeble-minded. They are very nervous, easily startled, emotional, and are often unable to speak distinctly, yet it is interesting to note that this peculiar emotional excitability often passes for quickness of perception. In fact, parents often remain unconvinced that the child is lacking in mental power until it reaches an age when comparison with other children makes this conclusion inevitable.

Acquired Paralysis.—As in adult life, the common form of acquired cerebral paralysis in childhood is hemiplegia. About two-thirds of all the cases occur in the first three years of life; and in about 20 per cent. of these the affection of the brain is a complication of infectious disease. The onset is usually sudden, and is accompanied in the majority of cases by fever, convulsions, and loss of consciousness. When the child regains consciousness the paralysis of the arm and leg is at once evident, and in about 20 per cent. of the cases the face is paralyzed also.

Deformities.—At first the paralysis is a simple powerlessness, but soon the exaggeration of the reflexes is evident. As has been stated, there is a loss of voluntary power and an increase of the reflexes or "stiffness" of the paralyzed members. They are no longer competent to assume the more difficult attitudes and functions, and these are replaced by those that are simpler; thus flexion becomes habitual.

Fig. 626.—Acquired cerebral hemiplegia.

In typical hemiplegia the foot is plantar flexed and adducted. The leg is flexed on the thigh and the thigh on the trunk, and with the flexion, adduction is usually combined. The arm is held against the thorax, the forearm is flexed upon the arm in an attitude midway between pronation and supination. The hand is flexed upon the arm and inclined toward the ulnar side and the fingers are clasped over the adducted thumb (Fig. 626).

Disability.—The loss of power is not absolute; in most instances the patient is able to walk with a noticeable limp, dragging the stiffened and distorted limb, which serves as a prop rather than as an active support. So, also, the control of the upper extremities is in part retained; the patient is able to abduct the arm, to partly extend the forearm, sometimes to extend the fingers and to abduct the thumb, but the power to dorsiflex the hand and at the same time to extend the fingers is not usually retained in a case of this character.

Loss of Growth.—The growth of the patient as a whole is usually retarded to a certain extent by the lesion of the brain. There is also an inequality in the growth of the two halves of the body. This inequality is more marked in the upper than in the lower extremity. Shortening to the extent of an inch in the lower extremity is not usually exceeded, but the growth of the arm and hand may be very decidedly retarded. This disproportionate loss of growth in the upper over the lower extremity depends primarily upon the interference with function. The lower extremity is rarely disabled to an extent that prevents its use in locomotion, consequently its nutrition is preserved; whereas the same degree of paralysis of the arm utterly unfits it for its more complex functions. With the disuse there is a corresponding diminution of nutrition and a consequent atrophy and loss of growth.

Extreme deformity and disability, as in the type described, are rather unusual. In many instances there is almost complete recovery from the paralysis, only an awkwardness and slowness of movement, combined with an increase of reflexes persists usually accompanied by a slight hemiatrophy of the body. In some cases a slight degree of equinus is the only deformity; in others weakness of the arm may persist, although complete control of the lower extremity has been regained.

The final effect of the paralysis is almost always more marked in the upper than in the lower extremity; thus, when contractions and deformities of the lower extremity are present the arm and hand are often practically disabled.

Treatment.—1. **Hemiplegia.**—The treatment from the orthopaedic stand-point consists in stimulating the nutrition of the paralyzed parts, in preventing deformity, and in improving the functional ability. The results of treatment are, of course, very greatly influenced by the mental condition of the patient. If the mental power is not impaired one may count upon the efforts of the patient for aid; whereas, if the patient is idiotic there is but little encouragement for active treatment. If the patient is seen before the secondary contractions have appeared, deformity may be prevented in great degree by regular massage and by passive movements in the directions opposed to the habitual positions. If the spastic contraction is slight a light jointed leg brace attached to a pelvic band may be used. By this means the movements are controlled and the excessive expenditure of nervous energy necessary to guide the limb may be lessened. If the support is supplemented by massage and regular exercises the control of the limb may be greatly improved.

In many instances the patients are not seen until late childhood, when the deformities have become fixed. The foot is usually turned inward and downward (equinovarus); there is flexion at the knee and often flexion and adduction at the hip, the resistance of the contractions being dependent upon the duration of the deformity. In such cases the distortions must be corrected by force and by division

of more resistant tissues, including often the tendo Achillis, the plantar fascia, and in many instances the hamstrings and the adductors of the hip. The limb is then fixed in a plaster-of-Paris splint for a sufficient time to overcome the more direct tendency to deformity. In correcting hemiplegic or paraplegic deformity one should be particular to overcome resistant contraction at the knee before dividing the tendo Achillis, for if the patient is permitted to walk afterward with a flexed knee, calcaneus deformity may be induced. Lengthening of the hamstring tendons through an open incision is therefore indicated in all resistant cases of this class. As additional precaution the foot at the time of an operation should be fixed at a right angle with the limb; not overcorrected as is usual. When the splint is removed a brace is of service in guiding the limb, and regular massage and forcible passive movements together with proper exercises should be employed whenever practicable. In this class of cases the deformities may be overcome in most instances, but there is a tendency toward flexion at the knee, and stiffness and awkwardness in movement usually persist.

Muscle Transplantation.—Muscle transplantation is often of service in lessening the tendency to deformity and restoring balance and is the procedure of selection in the majority of confirmed cases.

At the knee the transplantation of the biceps to the front of the limb is of service in cases of persistent flexion, and in the more extreme cases transplantation of all the hamstring muscles is indicated. At the foot the transplantation of the tibialis anticus to the outer border and if necessary, the tibialis posticus to the peroneus brevis will prevent recurrence of varus. If the deformity of the foot is marked and resistant the astragalus may be removed. In cases of resistant adduction of the thigh the division of the obturator nerve is indicated. The operations are described elsewhere. (See Talipes.)

In many of the milder hemiplegic cases the only deformity is of the foot. This should be treated by division of the tendo Achillis and by support for a time until the deformity habit has disappeared.

If the arm is but slightly affected persistent exercise will greatly improve its ability. In the more extreme cases, in which the fingers are clasped over one another, treatment is of little avail. In another class, in which the patient has the power of extending the fingers only when the wrist is flexed, the power of dorsiflexion may be restored or improved by transplanting the flexors of the carpus on the radial and ulnar border to the extensors, which have been overlapped and shortened to the proper extent. These tendons may be exposed by lateral incisions, and may be attached to the dorsal tendons by passing them about the border of the radius and of the ulna, or directly through an opening in the interosseous ligament. The transplantation of the pronator radii teres is of value in cases in which the forearm is persistently pronated. An incision is made over its insertion to the radius and its tendon is separated, together with a strip of periosteum. This is passed beneath the radius and is attached under tension to the

upper external border, a hole being bored through the bone to assure security. The arm is then fixed in full supination by a plaster support for a sufficient period followed by mechanical stretching and muscle training. The transplantation of other tendons may be of service, but the operation is limited in usefulness, because power in the extensors is rarely sufficient to enable the patient to straighten the fingers. Athetoid movements of the hand and arm may be relieved somewhat by prolonged fixation in a plaster bandage, by arthrodesis at the wrist-joint or by division of the motor nerves.

Hemiplegia in Older Subjects.—Acquired hemiplegia in adult life often causes the same general type of deformity as that described, namely, contraction of the wrist and fingers and equinovarus. These distortions should be prevented by proper support or corrected when they are present. Supplemental treatment by massage and muscular reëducation will then greatly improve function.

2. **Paraplegia.**—The treatment of spastic paraplegia is more difficult than that of hemiplegia, because the disability is very much greater and because the mental impairment is usually more marked.

In general, the treatment in infancy is by massage and by manipulation. When the child shows a desire to walk an attempt should be made to relieve the spastic contractions. In certain instances complete correction of all deformities, followed by prolonged fixation of each joint in the overcorrected attitude, may be of service (Fig. 608). This may be combined with multiple tenotomies if the contractions are more resistant. The advantage of tenotomy, aside from the simple correction of deformity, is that by elongation of the tendon the response to the exaggerated motor impulses is lessened and an opportunity for more effective control is afforded. The beneficial effect of complete division of contracted parts in checking spasmodic contractions is very marked in older patients. The indications for muscle transplantation are the same as in hemiplegia. In cases of this type division of the obturator nerve in order to relieve the adductor spasm is of great advantage.

Section of the Obturator Nerve.—The thigh being somewhat abducted, an incision about four inches in length is made from the pubis downward along the upper border of the adductor longus. The deep fascia is divided, exposing the tendon of the adductor longus and above it the border of the pectineus muscle, beneath which lies the anterior division of the nerve. This is exposed by drawing the pectineus upward and outward. In most instances the resection of the anterior branch is sufficient. The posterior branch lies beneath the adductor brevis and may be exposed by retraction or division of the adductor longus. After resection the contracted tissues are stretched and divided and the limb is fixed for a time in full abduction. Later manual stretching and muscular training are employed as usual.

Except in the very mild cases of paraplegia, and as a temporary support to retain the limbs in the improved position after operative

treatment, braces are of little value. The trunk is not, as a rule, deformed except in the diplegic cases in which the mental impairment is great. Manipulation, massage, and educational gymnastics are of service in correcting and preventing this distortion.

FIG. 627.—Cerebral paraplegia, second stage in treatment, the long replaced by the short spica. This patient, at the age of eight years, was unable to stand without assistance. The spastic contractions and deformities were overcome by tenotomies and by force, and a double long spica bandage was applied. This was worn for eight months. It was then replaced by the support shown in the illustration. Six months later this was removed. There is at present no deformity, and the child walks fairly well.

FOERSTER'S OPERATION.—Foerster's operation is division of the posterior nerve roots, dorsal to their ganglia.

The purpose of the operation is to check the impulses from the periphery that excite involuntary muscular contraction, and thus to assure better control.

In spastic paraplegia the nerves involved are the four lower lumbar and two upper sacral, and according to Foerster's latest teaching, all the roots are divided, except that of the supply of the anterior thigh group from the first or third lumbar nerves as determined by direct electrical tests.

In the upper extremity the nerves involved are the four lower cervical and first dorsal.

It is hardly necessary to describe the steps of the operation, or its modifications, since it has been practically abandoned in the class of cases of orthopaedic interest.[1]

Sympathetic Ramisectomy (Royle's Operation).—According to Royle and Hunter, there are two elements in muscular tonus, the contractile and the plastic, and two groups of muscle fibers to correspond. The contractile or voluntary impulse determines the attitude and the plastic or sympathetic impulse maintains it. Thus the abnormal retention of an attitude—"stiffness"—in spastic paralysis is explained by lessened voluntary control due to cerebral impairment and a consequent preponderance of what is called plastic tone, as indicated by prolonged maintenance of a position as, for example, when the limb is extended at the knee.

In selected cases of this type Royle, when operating for paralysis of the lower extremity divides the communications of the paravertebral sympathetic chain to the second, third and fourth lumbar nerves, and at the last level divides the chain completely through an incision in the loin, and in the operation on the upper extremity those to the three lower cervical and two upper dorsal nerves. The immediate effect of the operation is to increase blood supply of the part, with consequent increase of heat production and radiation. As the result, an improvement in control may be noted particularly of the upper extremity. The operation is still in the experimental stage. The theory on which it is based has not been established and the later results of the operation in other hands have not been encouraging. For the operative details, Royle's description should be consulted.[2,3]

Operations on Motor Nerves.—These operations have been conducted for the purpose of weakening the power of the spastic muscle and thereby lessening the disparity between the overactive and the inactive groups.

One method is to induce temporary paralysis by injecting alcohol about the nerve trunk supplying overactive muscles, in order that the weaker groups may be trained to better advantage.

Another, is to induce permanent paralysis in parts of the muscle. This is Stoffel's operation.[4]

Stoffel has called attention to the fact that a nerve trunk is composed of numerous distinct fibers establishing a direct communication from the nerve cells to the individual bundles, of which the muscle is composed.

The power of the overactive muscles may be reduced by dividing certain of the branches of distribution to the muscle itself, or by

[1] T. Gumbel: Berl. klin. Wchnschr., vol. 51, 29.

[2] Med. Jour. Australia, January 26, 1924. See Sympathetic Ganglionectomy.

[3] Herz: Zent. f. Chir., January 11, 1930, from a later examination of 32 patients operated on by Royle concludes that there was no essential improvement in any case.

[4] München. med. Wchnschr., 1911, No. 47; Am. Jour. Orthop. Surg., May, 1913.

MEDICAL LIBRARY
THE
BOSTON CITY HOSPITAL

cutting these in the main trunk after identification by electrical tests. The degree of weakening must be tentative and determined therefore by the experience of the operator. (Figs. 628, 629.)

Stoffel's operation may be of service in the treatment of spastic contraction of the upper extremity, particularly of the athetoid type, because even slight improvement in control may be of value.[1]

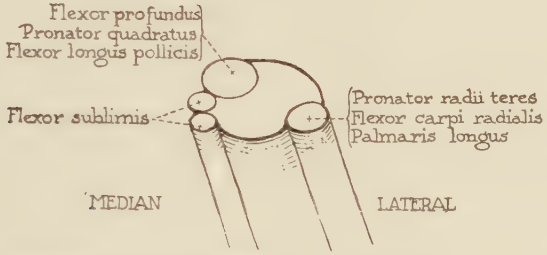

FIG. 628.—Topography of the cross-section of the median nerve. Diagrammatic. (Heyman.)

In the lower extremity, however, the conditions are different. Spastic muscles are not actually stronger than normal muscles, nor is the chief disability of the inactive muscles caused by overaction of the opposing groups, but there is rather a loss of control, paresis or paralysis, due to the impairment of the cortical centers.

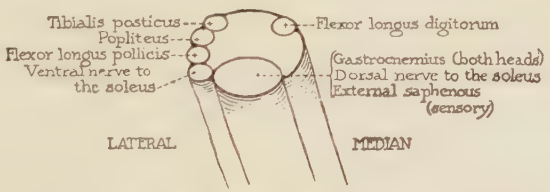

FIG. 629.—Topography of the cross-section of the internal popliteal nerve. Diagrammatic. (Heyman.)

Unfortunately temporary complete paralysis or mechanical weakening of the stronger group is not necessarily followed by sufficient gain in the weaker muscles to improve function. Temporary paralysis by means of alcohol injections as an aid in correcting deformity and in muscle training is to be preferred to operations designed to induce permanent partial paralysis, except to relieve pronation in the upper, or for adduction deformity, in the lower extremity, but both have a very limited application in orthopaedic practice as compared to direct operation on the muscles either by transplantation or by elongation of tendons, except in a class of cases under complete educational control.[4]

[1] Gill: Jour. of Orthop. Surg., February, 1921; Heyman: Surg., Gynec. and Obst., May, 1923.

Decompression of the Brain.—In a large proportion of the cases of spastic paralysis the disability is caused by injury at birth and subdural hemorrhage. In some instances the effused blood has been removed soon after birth by opening the skull with complete relief of symptoms. The symptoms of brain compression or injury during the first week of life are stupor, muscular twitchings of the orbital muscles and fingers or general convulsions.

William Sharpe[1] has made a series of lumbar punctures in 500 newborn infants and has found blood in 9 per cent., indicating that injury is more common in apparently normal deliveries than has been believed. When blood is found, the lumbar punctures are repeated at intervals, thus relieving the intracranial pressure. He is also an advocate of cranial decompression in later childhood when intracranial pressure can be established by the ophthalmoscope and by lumbar puncture, as in about 12 per cent. of the cases. He has operated on 235 cases: 80 diplegic, 117 hemiplegic and 38 paraplegic, with a mortality of 8 per cent. In all but 13 cases improvement was noted. In this class the evidence of injury at birth was striking: 81 per cent. first children, 95 per cent. full term, 90 per cent. difficult labor, 76 per cent. forceps and 17 per cent. breech deliveries.[2]

In a summary of operative treatment it will appear that with the exception of that of Sharpe all are directed to effect rather than to cause.

Foerster would improve voluntary control by lessening the reflex response; Royle, by lessening plastic tone; Stoffel, by lessening the nerve supply to overactive muscles. Each of these procedures may be of value in selected cases, but all should be considered merely as adjuncts to comprehensive orthopaedic treatment.

Prognosis.—It is stated by Peterson[3] that the patients in whom the paralysis is paraplegic or diplegic in distribution usually die before the twentieth year, and that but few of those in whom it is hemiplegic reach the age of forty. This prognosis applies, it may be assumed, rather to the extreme cases accompanied by mental impairment than to the milder forms. In almost all cases the patient, even if idiotic, is finally able to stand and to walk. As a rule there is for a time a gradual improvement in motor power and in mental control as well. It is evident that in a class in which mental enfeeblement is so common and in which epilepsy is present in so large a proportion of cases, moral and mental training is of great importance.

Orthopaedic treatment, although it has no direct action upon the lesion in the brain, certainly has an indirect effect upon the mental as well as upon the physical condition of the patient.

When deformity has been corrected and when contractions have been overcome, functional use requires less mental effort; and motor

[1] Jour. Am. Med. Assn., January 30, 1926.
[2] Sharpe: Ann. Surg., November, 1925.
[3] Tr. Am. Orthop. Assn., 1900, vol. 13.

control may be still further improved by drilling the patient constantly in simple movements. Such exercises improve the motor communications and the ability of the paralyzed part as well.[1]

SPASTIC SPINAL PARALYSIS.

Occasionally cases of spastic paraplegia are seen in which there is no cerebral impairment. In such cases the lesion appears to be confined to the spinal cord and to be a degeneration of the distal portions of the pyramidal tracts due to imperfect development.[2] The treatment is similar to the ordinary form of spastic paraplegia, but the prognosis is far more encouraging.

DYSTONIA LENTICULARIS, DYSTONIA MUSCULORUM DEFORMANS.

This affection is characterized by spasmodic contractions and athetoid movements of one or more limbs, eventually generalized in character but usually beginning in one of the lower extremities. The spasmodic action of the muscles is increased by attempted voluntary action. The reflexes are not increased. The affection is caused by defect or gradual degeneration of the corpus striatum apparently of congenital origin. It usually begins in early childhood. In characteristic cases the thigh is flexed on the pelvis and in walking the body is in accommodation, drawn forward and toward the distorted limb. Fixation of the limb in a plaster support may give at least temporary service and in advanced cases division of the nerves may be indicated to check exhausting contortions.

AMYTONIA CONGENITA.

This is a congenital affection apparently due to developmental defect of the lower motor neuron and of the voluntary muscles.

At birth, extreme weakness is noted often mistaken for paralysis. The weakness persists and later postural deformities usually appear. The condition is of chief interest from the standpoint of diagnosis.

PROGRESSIVE MUSCULAR ATROPHY.

Progressive muscular atrophy, as the term implies, is a progressive wasting of the muscles, with corresponding loss of power, terminating finally in paralysis and deformity. Its cause is apparently a developmental defect.

Under this title are included two varieties of disease:

1. The myelopathic form, in which the primary disease is apparently of the spinal cord.

[1] According to von Baeyer (München. med. Wchnschr., vol. **62**, No. 4), an inelastic band about 3 cm. wide buckled about the thigh, not tight enough to affect the circulation reinforces the inhibiting power and lessens the spastic contractions.

[2] Spiller: Phila. Med. Jour., June 21, 1902.

2. The myopathic form, in which the disease appears to be primarily of the nerve terminals and the muscular fibers.

The second variety is usually designated as muscular dystrophy to distinguish it from the spinal form.

Myelopathic Paralysis or Atrophy.—The myelopathic form of muscular atrophy, the Aran-Duchenne type, usually begins in the small muscles of the hands and spreads from the periphery to the trunk. Fibrillary twitching of the affected and unaffected muscles is fairly constant, and the reaction of degeneration may be present. The disease is practically limited to adults, and from the orthopaedic standpoint it is of little interest. In another form, the Charcot-Marie-Tooth type, usually classed with the muscular atrophies, the paralysis may begin in the muscles of the legs, causing deformity of the equinus or equinovarus variety. The lesion of the cord is of the anterior cornua, and resembles closely that of the subacute form of anterior poliomyelitis.

Myopathic Paralysis or Muscular Dystrophy.—The myopathic form of muscular atrophy may be preceded by apparent hypertrophy (pseudohypertrophic muscular paralysis), it may be primarily atrophic, or the two forms may be combined.

It differs from the myelopathic form in several particulars. It is a disease of childhood. It is often hereditary and its distribution is different.

The affection is divided according to the distribution into two main varieties:

1. The facio-scapulo-humeral type (Landouzy-Dejerine), in which the muscles of the face and shoulder-girdle are primarily affected (Fig. 630).

2. The juvenile form of Erb, in which the muscles of the back and of the upper arms are first involved.

The etiology, pathology, and clinical course of the atrophic do not differ essentially from the pseudohypertrophic form.

Pseudohypertrophic Muscular Paralysis.—Pseudohypertrophic paralysis is characterized by progressive weakness of the muscles of the trunk and of the legs, associated with apparent hypertrophy of the calves due in great part to a deposit of fat in the wasting muscles (Fig. 631).

The symptoms are caused by a degenerative atrophy of the nerve terminals and of the muscular fibers and an increase of the connective tissue and replacement of the muscular substance by fat. It is in at least 50 per cent. of the cases an inherited defect and several members of a family may be affected. It may be transmitted through either parent, but usually through the mother, and it is far more common in boys than girls. In a family of 12 children, 8 boys and 4 girls, all of the boys were affected and none of the girls.

Recently it has been stated that syphilis is a common factor in the etiology of progressive muscular atrophy, particularly of the Aran-Duchenne type and that the primary lesion is a diffuse vascular

meningomyelitis; consequently that specific treatment is of great value.

Diagnosis.—The interest in this latter affection from the orthopaedic stand-point lies in the diagnosis in the early stage of the affection. At this time the patient is evidently weak; he walks with an awk-

FIG. 630.—Progressive muscular dystrophy, facio-scapulo-humeral type. Extreme lordosis and flexion contractions at the hips.

FIG. 631.—Progressive muscular dystrophy, showing the enlargement of the calves and the atrophy of the shoulder muscles.

ward, shambling gait, and climbing stairs is especially difficult. There is usually an increased lordosis and a peculiar swaying or waddle, a disinclination to stoop, and an evident difficulty in regaining the erect posture, and there may be discomfort or pain referred to the lumbar region. If the disease is advanced, the peculiar hard, resistant enlargement of the calves, combined, it may be, with atrophy of the muscular

groups of the upper extremity, and weakness of the muscles of the back, makes the diagnosis evident, but in young children the disease may be mistaken for *Pott's disease, simple weakness,* or *postural deformity.* Although there is a superficial resemblance to the general symptoms of Pott's disease, yet the specific signs of disease of the vertebræ, pain, and muscular spasm are absent.

Weakness, a result of malnutrition or disease, is general in character and its cause is usually apparent; it is, of course, not accompanied by local hypertrophy. Retarded cerebral development causes general weakness as far as inability to stand is concerned, but the cause is in this class also usually apparent.

Postural deformities in childhood always have a cause, and as one is not content to treat a deformity without ascertaining its cause, this search will bring to light the peculiar symptoms of the disease.

The disability is usually progressive. The patient in ordinary cases loses the ability to walk at about the age of twelve years and dies within a few years, often from some intercurrent disease. Treatment, therefore, must be symptomatic.

Treatment.—In certain instances the discomfort referred to the back, due in part to the lordosis, may be relieved by a light spinal support. Massage and muscle-training will enable the patient to utilize the remaining power to best advantage.

In the later stages of the disease there may be secondary deformities, most marked in the feet, which may be fixed in the equinus or equinovarus attitude. This is usually the first deformity that appears and it may be corrected by tenotomy or otherwise, if the disability is not progressing rapidly. As a rule, however, operative intervention is contraindicated in progressive cases because the patient cannot reaccommodate himself to the new static conditions.

PERONEAL ATROPHY.

There is a type of dystrophy often hereditary in which the atrophy is practically limited to the distribution of the peroneal nerves, inducing varus deformity or involving other muscles below the knees.[1]

HEREDITARY ATAXIA. FRIEDREICH'S DISEASE.

Hereditary ataxia is an ataxic paraplegia caused by sclerosis of the posterior and lateral columns of the spinal cord. The early symptoms are incoördination and weakness of the lower limbs; later similar symptoms appear in the upper extremities, and speech is affected. In well-marked cases there is usually distortion of the feet toward equinus or equinovarus, and frequently a posterior or lateral curvature of the spine.

MULTIPLE NEURITIS.

Multiple neuritis may be a sequel of infectious disease such as pneumonia, typhoid fever and the like. Its onset is often attended by fever,

[1] Macklin and Bowman: Jour. Am. Med. Assn., February 27, 1926.

by pain in the affected limbs and by advancing paralysis usually beginning in the lower extremities. The paralysis may be progressive and cause death, but in most instances recovery takes place after a long interval.

NEURITIS.

Localized neuritis also follows contagious disease, rheumatism, alcoholism, and the like, or begins without apparent cause. The pain is of an aching throbbing character with occasional shooting pain along the nerve, sensitiveness to pressure, usually accompanied by a sensation of heaviness and weakness. The deep reflexes are diminished, the muscles atrophy and there may be temporary paralysis, as of the dorsal flexors of the foot, causing toe-drop and, finally, deformity. In establishing a diagnosis of neuritis care must be taken to exclude pain referred from the spine or cord or neighboring joint, of which so-called sciatica is the most notable example. If the muscles are weak the affected part, particularly the "drop foot," should be supported by a brace or plaster splint in normal position. This not only prevents deformity, but it hastens the cure by preventing tension upon and structural lengthening of the weakened muscles. The same treatment may be applied for wrist-drop from metallic poisoning. The hand should be supported by a suitable brace in the attitude of dorsiflexion until the muscles have recovered their power. Obstetrical paralysis has been considered under affections of the shoulder.

SUBACUTE COMBINED SCLEROSIS.

In cases of pernicious anemia, Addison's disease and the like, weakness and paralysis may eventually appear. The early symptoms are partial loss of sensation in the hands and feet (the so-called glove and stocking regions), with areas of numbness and tingling. Later there may be flaccid or spastic paralysis of the lower extremities and deformity.

HYSTERICAL JOINT AFFECTIONS AND DEFORMITIES. FUNCTIONAL AFFECTIONS OF THE JOINTS.

So-called hysterical and functional affections may be divided into two groups:

1. Those in which there is no actual disease or weakness.
2. Those in which the symptoms of disease or injury, or of their effects, are exaggerated or persist unduly.

The first class of cases is small, the second is large.

Simulation, whether voluntary or involuntary, of organic disease can deceive only those who are not familiar with the characteristics of the disability that is simulated. Every disease has certain well-defined symptoms which can no more be imitated by a well person than a disabled part can suddenly take on the normal appearance and function.

THE NEUROTIC SPINE.

The "neurotic" spine is much more common in adolescence and in adult life than in childhood, and the subjects, usually females, are often of a nervous or neurasthenic type. In certain instances the symptoms appear to have been induced by injury, and in others by worry or overwork.

FIG. 632.—The neurotic spine. Characteristic attitude.

Symptoms.—The patient usually complains of a dull pain in the back of the neck or in the lumbar or sacral region, of a constant tired feeling, and, not infrequently, of sharp neuralgic pain localized about a certain point in the spine, often the vertebra prominens. The contour of the spine may be normal, but most often there is a lessening of the lumbar lordosis, a backward inclination of the body and a forward droop of the head, an attitude that signifies muscular weakness and strain upon the ligaments. One of the common symptoms of the neurotic spine is *extreme local sensitiveness*, or hyperesthesia, of the skin at certain points along the spinous processes. Thus, if one passes the finger gently along the spine the patient will often shrink or cry out

MEDICAL LIBRARY BOSTON CITY HOSPITAL

because of the pain. As a rule there is no limitation of motion or muscular spasm. The pain is local, not referred to the terminations of the nerves; in fact, the symptoms are in great part subjective and irregular in character, as contrasted with those of actual disease or injury, which are objective and well-defined.

Treatment.—The treatment of the neurotic spine must be general in character, as indicated by the condition of the patient. Locally, a light back brace or a long corset, reinforced if necessary by light steel back bars, adds greatly to the comfort of the patient. The application of the cautery is particularly efficacious in relieving the local sensitiveness. Massage and light exercises may be employed in the later treatment. Weak feet are often associated with this condition. In such instances appropriate treatment often induces a marked improvement in the general condition.

Camptocormia, Bent Back.—This is a condition in which the trunk is inclined forward without lateral distortion. The symptoms aside from the inability to stand erect are weakness and pain. The deformity may be induced by injury, by shell shock and the like. The treatment aside from that of the neurotic element is essentially rest, support and physiotherapy.

THE HYSTERICAL SPINE.

The hysterical spine is considered usually as synonymous with the neurotic spine, but as there are many individuals who suffer from sensitive spines who are not hysterical, it would seem proper to limit the latter term to the hysterical class.

Symptoms.—The local symptoms do not differ particularly from those of the neurotic spine except that in certain instances actual deformity may be present. This is usually an exaggerated lateral distortion, most marked in the lumbar region. Like hysterical distortions elsewhere, it may follow injury, and it may be claimed that this injury was the direct cause of the deformity. Except, however, as a possible cause of the appearance of a particular manifestation of the mental condition, it is evident that no form of injury could explain the symptoms or the deformity.

"Hysterical Scoliosis."—A case was at one time under the writer's observation in which distortion of the trunk persisted for more than a year, and until a suit for damages was finally decided. In this case there was a most exaggerated lateral twist of the spine, so that the shoulder approached the pelvis. The deformity, however, was not fixed, but it could be completely reduced when the patient was in the recumbent posture. There was no paralysis, no persistent spasm, no evidence of disease or injury. The deformity was of a nature that could not be explained by any conceivable lesion, and other signs of hysteria were present. Spontaneous cure then followed to be succeeded several years later by hysterical "club-feet" (Fig. 633).

"Hysterical Hip."—The hysterical hip is supposed to simulate actual tuberculous disease.

Diagnosis.—The symptoms of actual disease of this joint are pain, limp, limitation of motion due to reflex muscular spasm, muscular atrophy, distortion, and later the local signs of a destructive process; for example, heat, swelling, abscess, displacement, shortening of the limb, and the like. As these later symptoms could not be simulated, they need not be considered.

FIG. 633.—Hysterical scoliosis. (Schuster.)

In actual disease symptoms and effects follow one another in regular sequence and correspond closely to the pathological conditions that cause them. Pain is not a pronounced symptom; it is more likely to be concealed than exaggerated and it is usually referred to the knee. Local sensitiveness is not marked, and it is often absent. Distortion of the limb if present before the destructive changes are advanced is caused by involuntary muscular contraction, and whenever this distortion is great the reflex muscular spasm, which involves every muscle about the joint, is also great; so that the range of motion is restricted. With the distortion there is always a corresponding atrophy of the muscles of the limb. If pain is present it is usually worse at night than during the day.

The simulation of hip disease is characterized by an exaggeration of the symptoms and by absence of the physical signs of disease. There is usually an extreme limp, great distortion, marked local sensitiveness and pain, but absence of muscular spasm, atrophy, or other signs of disease.

The age of the patient, the history of the supposed disease, and the

other evidences of hysteria that are usually present will confirm the diagnosis.

The same principle applies, of course, to the differential diagnosis of simulated disease at other joints. The knee and the hip-joint are those that are most often involved.

"**Hysterical Talipes.**"—Local deformity distinct from simulated joint disease is sometimes seen. The differential diagnosis is simple.

Talipes is either congenital or acquired. Congenital talipes and all the acquired varieties, other than those of paralytic origin, may be at once excluded from consideration. Paralytic talipes in the great majority of cases begins in early childhood, when it is either caused by anterior poliomyelitis or by cerebral hemiplegia or paraplegia. When these are excluded the remaining causes of deformity are very limited. Each variety of nervous disease has well-defined symptoms. If actual paralysis is present the muscles atrophy and the electrical reactions are changed. In hysterical contractions the muscles are not atrophied except to the degree explained by disuse of the limb, and the electrical reactions are unchanged.

Treatment.—The principles of the treatment of pronounced hysteria, of which simulated joint disease and deformity are but unusual manifestations, need not be considered at length. It is evident, of course, that an unequivocal diagnosis must be the first and essential step toward cure. In this class of cases apparatus is not often indicated unless the deformity has persisted for so long a time that the disused muscles have become incapable of performing their proper functions.

"**Neurotic Joints.**"—In this class, although there is no absolute distinction between it and the preceding variety, there is usually a physical basis for the symptoms, however much they may be exaggerated.

The patients are not usually hysterical; in fact, hysteria in the ordinarily accepted sense is uncommon, and although the larger proportion of patients are women, yet men and children are by no means exempt from the so-called functional affections.

It must be borne in mind, also, that many of these cases are classed as neurotic simply because the cause of the symptoms is not apparent. It may be inferred that as diagnosis becomes more accurate the more restricted will become the class of cases of purely imaginary disability, insofar at least as the locomotive apparatus is concerned.

Etiology.—A "neurotic joint" is often caused by injury. A sprain of the ankle, for example, may have been treated by prolonged fixation, either because the patient had originally impressed the physician with the severity of the symptoms or because of persistent discomfort. When the dressing is removed there may be congestion due to impaired circulation, weakness and atrophy of the muscles due simply to disuse, and a certain degree of infiltration and stiffness caused by the original injury. In cases of this character the disability may be prolonged because the patient or the physician mistakes the effects of disuse for

the symptoms of serious injury or disease. The treatment therefore should be directed to increasing the activity of the circulation and thus the nutrition of the part, by counter-irritation, by massage, by passive movements, by voluntary exercises and the like, but cure can only be completed by functional use. If the disability is of long standing a brace may be required for a time, to protect the part from injury, and to increase the patient's confidence. In milder cases it is possible that without support or treatment, other than an assurance of the absence of serious weakness, cure may be accomplished, but this is certainly unusual.

Symptoms.—The knee-joint is very often the seat of so-called neurosis. Injury in nervous children is sometimes followed by a persistent flexion contraction that may continue for weeks after all local signs have disappeared. When the attempt is made to straighten the knee the patient screams with pain and the muscular resistance is very great. In such cases the immediate rectification of deformity under anesthesia and the application of a plaster support to hold the limb in the corrected position is indicated. It must be borne in mind that the persistent assumption of a deformed position for weeks or months must induce structural changes in the contracted muscles and weakness in the opposing groups. Thus some assistance may be required in the treatment even of the purely hysterical deformities because of this weakness.

In all forms of traumatic neurosis, so-called, the possibility of a physical basis for the symptoms should be considered, the location of the pain or discomfort, and its connection with certain movements or attitudes should be investigated. If such discomfort is induced by, or is aggravated by a certain motion or attitude it is reasonable to infer that this has a definite cause. In such cases limitation of the movements for a time to the painless range of motion by some form of support may be indicated.

Thus far injury has been considered as the starting-point of the symptoms, but in many cases there is no history of injury. In this class the symptoms may have been induced by some form of arthritis, or by neuritis, and such possible causes should be investigated and excluded before the diagnosis of simple neurosis is made. In neurasthenic patients or those who are anemic, or overworked, the pain and discomfort is often localized in the spine, the "neurotic spine" which has already been considered.

Treatment.—In the treatment of all cases of this group, the general condition of the patient should receive consideration, and in connection with the local treatment a change of occupation and of scene is often of advantage.

It is hardly necessary to insist again that an accurate diagnosis is the first essential of successful treatment. If this is impossible at least one may by the exclusion of those injuries and disabilities and diseases that are evidently not present arrive at a general conclusion as to the character of the ailment and shape his treatment accordingly.

CHAPTER XIX.

CONGENITAL AND ACQUIRED TORTICOLLIS.

Synonym.—Wry-neck.

Torticollis is, as the name implies, a twisted neck, a distortion caused in most instances by active contraction or by shortening of one or more of the lateral muscles that control the head.

Similar distortion may be due to disease of the spine, so-called false torticollis, but this should be classed as a symptom of the underlying disease, not as simple torticollis, of which the distortion itself is the important disability that demands treatment.

Torticollis may be divided primarily into two classes: The congenital and the acquired.

Congenital torticollis is a painless shortening of the tissues on one side of the neck of intra-uterine origin.

Acquired torticollis is, in most instances, accompanied in its early stages by local pain and sensitiveness, and by active contraction of the affected muscles. After a time these acute symptoms disappear, leaving simply the deformity. Thus, from the therapeutic standpoint, torticollis may be classified as *acute* and *chronic*, the latter class including the congenital form.

The sternomastoid is the muscle that is usually involved primarily, both in the congenital and acquired forms; thus, in typical torticollis the head is drawn somewhat forward and is inclined toward the contracted muscle, while the neck is pushed, as it were, away from the contraction (Fig. 634); the chin is slightly elevated, and turned toward the opposite shoulder—an attitude explained by the normal action of the affected muscle. Irregular distortions of the head, as posterior or anterior torticollis due to contraction of muscles other than the sternomastoid, are, however, not infrequent. These will be mentioned in the consideration of the forms of acquired torticollis.

Statistics.—Torticollis is one of the less common deformities.

Acquired torticollis is by far the more frequent, as is shown by the fact that of 507 cases but 87 were supposed to be of congenital origin.

Of the 87 congenital cases 46 were in females. The contraction was of the left side in 38 of the 58 cases in which the affected side was specified. Of the entire number of cases available for comparison 246 were in females and 198 in males; in 236 instances the contraction was on the left and in 196 on the right side of the neck. From these statistics it would appear that the deformity is somewhat more common in females than in males, and that the left side is more often affected than the right.

Congenital Torticollis.—In most instances the deformity of congenital torticollis is slight at birth, and it may not attract attention

until the child is able to support the head or even walks. Thus it is often difficult to distinguish the congenital form from the deformity that may have been acquired in infancy, especially as the patient may not be brought for treatment until the distortion has persisted for several years.

In early infancy slight torticollis may be demonstrated by fixing the shoulder on the affected side and drawing the head forcibly in the opposite direction, when the shortened muscle becomes prominent beneath the skin, evidently restricting the range of motion. In most instances the sternal division of the muscle appears to be more shortened than the clavicular portion.

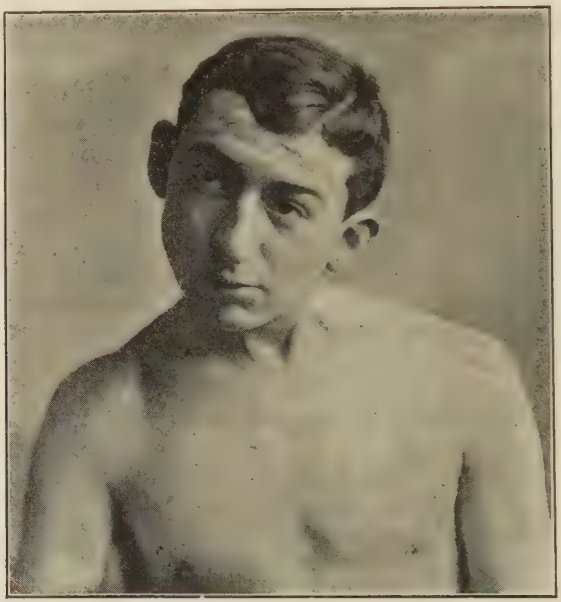

FIG. 634.—Left torticollis, apparently of congenital origin, showing the secondary distortions of head and face.

In exceptional cases the deformity even in infancy may be extreme, and it may be accompanied by well-marked asymmetry of the face and even by distortion of the skull. In this class the shortening may involve all the lateral tissues, both anterior and posterior and is often complicated by malformation of the cervical vertebræ. If asymmetry is present at birth it increases somewhat with growth. Even in the acquired form it often appears soon after the onset of the deformity, becoming more marked with its continuance. Its cause is the constrained attitude, the restriction of normal use, and consequently of the blood supply, combined with the tension upon the tissues of the face, as is evidenced by the fact that it becomes less noticeable after the deformity has been corrected.

In the well-marked cases of long standing, whether congenital or acquired, the face on the affected side is shorter and flatter, the nose and the corner of the mouth and the eyelids even are drawn downward, and the skull shows evidence of atrophy and deformity.

Secondary distortions also appear in the trunk in chronic cases. These are rotation of the spine to compensate for the lateral distortion of the head and an increase in the dorsal kyphosis, "round shoulders." Among the minor secondary deformities upward bowing of the clavicle caused by the tension of the contracted muscle may be mentioned (Fig. 636).

Fig. 635.—Right torticollis, showing the displacement of the head toward the opposite side.

When the deformity is marked or of long standing the head and neck following the compensatory convexity of the cervical spine are displaced toward the opposite shoulder (Fig. 635). This displacement relaxes in some degree the contracted tissues, consequently the lateral distortion of the head is lessened.

The compensatory deformities that have been indicated are slight in infancy, but become more noticeable in later childhood, for in many instances the growth of the affected muscle is checked; thus, an original shortening of half an inch, as compared to its fellow, may be increased to two or more inches in later years. This fact emphasizes the importance of treatment as soon as may be possible after the distortion is discovered.

As has been stated, the important contraction is usually of the sternomastoid muscle, but if the deformity is uncorrected all the lateral tissues become shortened.

Typical wry-neck caused by shortening of the sternomastoid muscle is by far the most common form of congenital torticollis, but occasionally cases are seen in which the head is but slightly inclined to one side and in which the shortening appears to involve the lateral tissues in general rather than a particular muscle. In rare instances, although the deformity resembles that of typical torticollis, the greatest shortening will be found to be of the posterior muscles on one side, particularly of the trapezius and the levator anguli scapulæ, Sprengel's deformity. Thus the scapula may be elevated and tilted forward. Torticollis due to defective development of the upper extremity of the spine is a rare deformity that does not require special description.



FIG. 636.—Upward bowing of the clavicle in compensation for the shortened sternocleidomastoid muscle.

Etiology.—It may be assumed, disregarding the possible influence of hereditary predisposition, that congenital torticollis is, in most instances, caused by a constrained or fixed position in the uterus for a longer or shorter time before birth. It is, in fact, a simple distortion, and that it has, in the majority of cases, no deeper significance is proved by the fact that it may be easily and completely cured by simple division or elongation of the contracted tissues.

Hematoma of the Sternomastoid Muscle as a Possible Cause of Torticollis.—During difficult delivery, fibers of the muscle are ruptured, usually in the upper or middle third of the anterior border, hemorrhage follows, which in turn is surrounded by an encapsulating area of inflammatory material. This forms a firm, cylindrical tumor in the substance of the muscle, which becomes noticeable about two weeks after birth, or at least this is the time when it is usually discovered by the mother. As a rule the tumor is not sensitive to pressure; it may or may not be accompanied by restriction of motion in the direction causing tension on the muscle. The tumor remains for from

LIBRARY OF THE BOSTON CITY

three to six months, when it usually disappears, leaving no trace of its presence.

The theory of Stromeyer, at one time generally accepted, is that congenital torticollis is usually caused by rupture of the muscle and by myositis about the hematoma that may involve and ultimately destroy a large part of the substance of the muscle, replacing it with fibrous tissue, which, contracting, causes deformity.

This theory is extremely improbable for the following reasons:

1. Rupture of muscle elsewhere is practically never followed by myositis and contraction.

2. It has been demonstrated by Heller[1] that it is impossible to cause myositis and contraction by any form of injury to the muscles of animals unless it be combined with actual infection with pyogenic germs.

3. The majority of the cases of congenital torticollis seen soon after birth present no evidence of hematoma or injury, viz.: In 7 of 55 cases of supposed congenital torticollis, investigated by the writer, there was a history of injury at birth. In 48 cases no mention was made of injury. In the 7 cases referred to, the deformity was accompanied by hematoma or there was a history of a swelling, apparently of this nature; but in 2 of these the hematoma was coincident with intra-uterine shortening of the muscle.

4. Cases of hematoma of the sternomastoid muscle are not, as a rule, followed by torticollis. Seven consecutive cases of hematoma were examined by the writer with special reference to this point. In all the evidence of violence in delivery was clear. Two were delivered by forceps, 3 were breech presentations, and in 2 version was performed. In 1 case an arm was broken and in another paralysis resulted from injury to the brachial plexus. Six of the children lived until the swelling had nearly or entirely disappeared, and in none did torticollis accompany or follow hematoma.

5. In certain cases a congenitally shortened muscle may be ruptured at delivery; thus the hematoma is simply a complication of torticollis, not its cause. Bruns[2] has reported such a case, and 2 others have been observed by the writer, in 1 of which club-foot was present also.

6. Hard tumors of the sternomastoid muscle are not always the result of injury; myositis may be of syphilitic origin apparently occurring in intra-uterine life. In other instances tumors of fibrous or sarcomatous nature have been removed from the substance of the muscle. Sixteen cases in which cartilaginous nodules, apparently of congenital origin, were found in the muscle have been reported.[3]

One may conclude, then, that congenital torticollis in the majority of cases is of intra-uterine origin. If it follows injury at birth it is probably an indirect result of local pain, discomfort and irritation

[1] Deutsch. Ztschr. f. Chir., Band **49**, Heft 2 and 3, 234.
[2] Zent. f. Chir., 1891, No. 26.
[3] Leugemann: Beitr. z. klin. Chir., Band **30**, Heft 1.

of the nerves or of an actual infectious inflammation of the injured part rather than an effect of the absorption of effused blood.

Pathology.—In the ordinary type of congenital torticollis, as demonstrated at operations on children, the substance of the affected muscle or muscles is simply lessened in amount, and there is a disproportionate area of tendinous substance as compared to the contractile tissue. In other instances the muscle may be almost entirely replaced by fibrous tissue or it may be traversed by fibrous bands, or patches of scar-like tissue may be distributed throughout its substance. These degenerative changes, considered to be evidences of preëxisting myositis, are more common among the acquired than the congenital forms, and, as a rule, they are found only in cases of long standing. Eventually all the lateral tissues of the neck are shortened to correspond to the habitual attitude, and the compensatory curvatures of the spine in time become fixed, so that torticollis may be classed as one of the causes of scoliosis.

Acquired Torticollis.—Acquired torticollis is an affection of early life, at least 80 per cent. of the cases beginning in the first ten years of life.

As has been stated, congenital torticollis is usually a painless shortening of the muscles, while acquired torticollis is, as a rule, a painful affection secondary to injury or disease of some of the structures of the neck, which causes irritation of the peripheral nerves and active contraction of the neighboring muscles. Thus, as a rule, the number of muscles involved in the deformity is greater than in the congenital form; for example, in the ordinary form of acquired wry-neck both the trapezius and the sternomastoid are contracted; and irregular forms of distortion caused by spasm of other muscular groups are not uncommon.

Varieties.—The varieties of acquired torticollis may be classified conveniently as follows:

1. The *simple* or *mechanical form* due to scar contraction following destruction of the skin or deeper tissues, as from burns or disease.
2. *Acute torticollis* caused by direct irritation of the muscle, by injury, by inflammatory affections of the surrounding parts, combined in most instances with irritation of the peripheral nerves, which causes reflex contraction of certain muscles or muscular groups.
3. *Spasmodic Torticollis.*—A form of convulsive spasm, "a disorder of the cortical centers for rotation of the head." (Walton.)
4. *Irregular Forms of Torticollis.*—Paralytic, ocular, psychical and the like.

The first class, that due to scar contraction, needs only to be mentioned.

Etiology of Acute Torticollis.—The second class is the most important form of torticollis, both as to frequency and as to its effect in causing permanent distortion. Of this group, one of the most common and at the same time the least important form is the simple stiff neck, supposed to be due to cold or to muscular rheumatism. Its onset is, in childhood, sometimes accompanied by slight fever and general discomfort;

the affected muscle is somewhat sensitive to pressure and motion or tension causes discomfort. The distortion, in great part voluntary and accommodative, is of short duration as a rule. Strains and direct injury of the muscles of the neck may cause deformity, which usually disappears when the local sensitiveness has subsided. Traumatic hematomata, similar to those caused by injury at birth, are sometimes observed in older subjects. These usually disappear after a time, leaving no trace of their presence. Another form of torticollis is secondary to cellulitis and to infiltration following the breaking down of tuberculous cervical glands. This may become a permanent distortion if the deformity is allowed to persist or if the tissues of the neck are injured by the suppurative process.

By far the most important variety of this class is the *acute spastic torticollis* due to active tonic contraction of one or more of the muscles of the neck. The exciting cause of the spasm appears to be irritation of the peripheral nerves in the nasopharynx or in its neighborhood, and the muscles most often affected are those supplied in part by the spinal accessory nerve. Thus torticollis of this form may follow tonsillitis, pharyngitis, measles, diphtheria and the like. It may be preceded by "toothache" or "earache," or it may be an accompaniment of what appears to be the ordinary form of stiff neck or of enlarged or suppurating cervical glands. In this form the torticollis is caused directly by tonic contraction of the muscles. Reflex spasm of this character is, however, often associated with distortion, due primarily to injury of the neck or to some local inflammatory process, so that a sharp distinction between the divisions of this second class is impossible. Many of the patients are known to be of a nervous temperament, and overstudy, anxiety, sudden shock, and the like are considered to be predisposing causes.

Enlarged cervical glands	14	"Cold in the neck"	5
Supporting cervical glands	41	Rheumatism	18
Scarlet fever	14	Vaccinia	1
Diphtheria	7	Fever	6
Mumps	6	Malaria	5
Measles	2	Injury of the neck	35
Sore throat	8	Rhachitis	3
Suppurative otitis	3	Syphilis	1
Toothache	6	Cicatricial contraction	3
Cellulitis of the neck	2		
Furuncle of the neck	1	Total	181
Torticollis associated with chorea			4
Torticollis associated with epilepsy			1
Torticollis associated with cortical irritation			5
Torticollis associated with hysteria			1
Torticollis associated with meningitis			1
Torticollis associated with hemiplegia			3
Spasmodic torticollis			8
"Functional torticollis"			8
Total			31

The numerical importance of this variety of acquired torticollis is indicated by the statistics of 212 cases treated at the Hospital for Ruptured and Crippled, in which the cause seemed to be apparent. Of the 212 cases 181 may be fairly assigned to this class.

Symptoms of Acute Torticollis.—As a rule the distortion of the neck, slight at first, is more noticeable at night than in the morning; it then gradually increases and becomes persistent. In other instances the onset is sudden, sometimes accompanied by fever.

As has been stated, in most instances several muscles are more or less involved in the contraction, particularly the sternomastoid and the trapezius, and in such cases the deformity is more marked and persistent than when the sternomastoid is alone affected. Less often the contraction is of the posterior group, "posterior torticollis" (Fig. 637), the head being tilted backward and the chin turned more toward the opposite side than in the typical lateral form. In other cases the contraction appears to affect the small muscles that control the joints at the upper extremity of the spine, when the head may be tilted forward with but slight lateral inclination, resembling closely except in the history, the symptomatic wry-neck of Pott's disease. In rare instances the muscles on both sides of the neck may be contracted simultaneously (Fig. 638). The affected muscles are usually sensitive to manipulation and attempted correction of the deformity causes extreme pain and is resisted by the patient. The child is, as a rule, nervous and irritable; it often complains of neuralgic pain about the contracted parts, which is increased by sudden or unguarded movements or strain; thus "getting the patient to bed" is often a tedious proceeding, because of the difficulty of supporting the head comfortably with the pillows.

Fig. 637.—Posterior torticollis. Duration one week.

In many instances the affection is of short duration; in others, particularly those in which the reflex spasm is aggravated by local inflammatory processes, there appears to be but little tendency toward recovery. In such cases, after several weeks or months, the local pain and sensitiveness may subside, together with the active spasm, but the deformity, caused by adaptive shortening of the muscles and

fascia, aggravated in some instances by actual myositis, persists. The muscles atrophy and degenerate and present at a later stage the same pathological appearances that are found in the congenital form.

Diagnosis.—Torticollis is most often confounded with *Pott's disease* and in its acute form there may be some difficulty in distinguishing between the two. The main points have been mentioned already in connection with Pott's disease. In acute torticollis the affection is of sudden onset, not preceded by the stiffness and neuralgic pain that characterize tuberculous disease. The deformity of torticollis is almost always of the regular type—that is, the head is tilted toward the contracted muscles while the chin is rotated in the opposite direction. The spasm and contraction of the affected muscles are apparent, and

FIG. 638.—Bilateral contraction of the sternomastoid and trapezius muscles. (See Fig. 639.)

FIG. 639. -Bilateral torticollis after treatment. (See Fig. 638.)

direct tension upon them is painful. If, however, the tension is relaxed by inclining the head toward the contraction, movement of the head in other directions will be found to be practically unrestricted.

In Pott's disease the spasm of muscles is general, the deformity is not of a regular type, since the chin often points to the side toward which the head is inclined. Steady tension with the aim of reducing the deformity is not, as a rule, painful; in fact, it is often agreeable to the patient. Finally, the limitation of motion cannot be lessened by inclining the head toward the muscle that seems to be most contracted, for the reflex spasm of Pott's disease limits motion in every direction. As a rule the diagnosis is easily made, but in cases complicated by suppuration of the cervical glands it is sometimes impos-

sible to exclude Pott's disease until after the effect of treatment has been observed.

Injury of the neck of the nature of a strain of the muscles or articulations or fracture may cause lateral distortion as mentioned in the differential diagnosis of Pott's disease.

Disease of the cervical spine, other than tuberculous, is comparatively rare, and resembles in its symptoms Pott's disease rather than torticollis. *Arthritis* of the suboccipital articulations may be a manifestation of general arthritis; it may follow infectious disease, or it may occur as an isolated infection. It is of sudden onset, and it resembles acute spastic torticollis, except that all the surrounding muscles are affected rather than a particular group; in fact, but for the history it could not be distinguished from tuberculous disease of this region.

Although the diagnosis of torticollis is simple, it is not always easy to determine the muscle or muscles involved in the contraction. The effect of unilateral contraction of the different muscles is as follows:

The sternomastoid inclines the head toward the contraction, displaces it toward the opposite shoulder, elevates the chin, and turns it away from the contracted muscle.

The trapezius has much the same action, but the backward inclination and rotation are more marked.

The action of the complexus resembles that of the trapezius, but the rotation is less.

The splenius inclines the head backward and toward the contracted muscle, but does not turn the chin in the opposite direction.

The scaleni have the same action, except that the head is inclined forward.

As has been stated, in acute torticollis several muscles are often involved, but the spasm is usually greater in one or in one group than in another. The seat of greatest contraction may be determined by the deformity, by the evident spasm that resists reposition, and by the local sensitiveness on palpation. As a rule, when the primary contraction is of the posterior group the deformity is more marked than in other forms. Bilateral contraction of the muscles is rare, but it is occasionally seen (Fig. 637).

Treatment.—The treatment varies according to the cause and with the duration of the deformity. Excluding, for the present, the rare and irregular forms of wry-neck, there are, from the remedial standpoint, two forms of torticollis:

1. The chronic form, in which the local pain and sensitiveness are absent, but in which there is resistant deformity. As has been stated, congenital torticollis is included in this class.

2. The acute form, in which the distortion is of short duration and in which permanent contraction may be prevented.

The Treatment of Chronic Torticollis.—By Manipulation.—Congenital torticollis, if of moderate degree, may be treated effectively in early infancy by methodical stretching of the contracted parts. One person fixes the arm and another draws the head gently but firmly in the direc-

tion opposed to the contraction, over and over again, meanwhile massaging the tissues of the neck. The procedure should be repeated several times a day; it causes slight momentary discomfort if properly performed, but this ceases when the stretching is discontinued. Care should be taken also that posture may, as far as possible, favor the reduction of the deformity; thus while the child is in the mother's arms the head should be supported, and when asleep the pillow may be arranged in a manner to prevent the improper position. In this way the torticollis may be entirely corrected or its progress may be checked until more effective treatment is indicated.

Hematoma.—This should be treated by massage with some bland ointment; if it is accompanied by deformity the manipulation already described should be employed.

In the great majority of cases of congenital torticollis the patient is not brought for treatment until the deformity has become an eyesore to the parents. The contracted muscle is then usually an inch shorter than its fellow, the disparity increasing, as a rule, with the growth of the child. In such cases the immediate correction of the deformity is indicated, and this implies in most instances division of the contracted parts by subcutaneous tenotomy or by open incision.

Subcutaneous Tenotomy.—If the deformity is comparatively slight and if the contraction seems to be limited to the sternomastoid muscle, and particularly to its sternal portion, one may hope to overcome the most resistant part of the contraction by the subcutaneous operation. Aside from the possibility of wound infection, which at the present time is an argument of very little weight, subcutaneous tenotomy has the advantages of simplicity, apparent freedom from the danger which parents associate with an operation, and it leaves no scar. It is inadequate, however, for the correction of advanced cases.

The patient and the instruments having been prepared as for an ordinary operation, a sand-bag is placed beneath the shoulders and the head is inclined so that the contracted muscle is thrown into relief beneath the skin. The sternal insertion of the tendon is seized with two fingers and the tenotome is inserted beside it and passed beneath it at a point about an inch above the sternum. It is then divided by a sawing motion of the knife. Division of the tendon in this situation is practically free from danger, and in the slighter degrees of deformity one can by vigorous manipulation and forcible traction overcome the resistance offered by the other tissues. If bands of fascia resist the correction, they may be divided by superficial nicking with the tenotome in the lateral region of the neck. As a rule, however, in cases of this type the open incision is to be preferred, as the contracted parts may be divided without danger of injury to the bloodvessels and nerves in this neighborhood.

The Open Method.—The skin should be made tense by drawing it upward so that the scar may fall below the clavicle. The incision should begin about half an inch above the clavicle, midway between the clavicular and sternal insertions of the muscle, and pass downward

and forward, following the natural folds of the skin to the clavicle. In the milder cases in childhood it need be little more than an inch in length. A director may be passed beneath the sternal tendon, and on this it may be divided. The clavicular insertion and the more resistant bands of fascia may be divided as they appear. The fascia and skin are then carefully united with fine catgut.

No functional disability follows division of the sternocleidomastoid muscle and for esthetic reasons the relative prominence of the unaffected muscle may be reduced by dividing its sternal insertion if absolute symmetry is desired.

In cases of very great deformity in the adult some of the posterior as well as the lateral muscles are involved. In such instances the contracted parts may be divided at the upper border of the neck through an incision from the mastoid process backward along the lower border of the scalp, the scar being concealed by the hair.

Overcorrection of the Deformity.—The object of treatment is not only to correct the deformity, but also to overcome all restriction of motion that may remain after the division of the more resistant parts, and the operation, whether open or subcutaneous, must be supplemented by a vigorous, methodical stretching of underlying resistant tissues. Finally, the head should be rotated in the opposite direction, the aim being to completely overcome the secondary curvature of the cervical spine.

It may be stated that Lorenz considers it possible to correct torticollis, even of long standing, by systematic kneading and stretching without previous division of the contracted tissues, but the use of so much force appears to be undesirable if by so slight an operation it may be avoided.

After all resistance to passive motion has been overcome by vigorous manipulation the head should be fixed during the process of repair in the overcorrected position. Thus in the treatment of typical torticollis the chin should be turned to a point over the middle of the clavicle on the operated side, and the head should be inclined toward the opposite shoulder, while the neck is held in the median line. In this attitude a plaster bandage should be applied surrounding the head and the thorax. It should remain until all local sensitiveness has disappeared, and until the tendency toward deformity has been checked. Fixation in the overcorrected position is very important in childhood, as an aid in overcoming the deformity habit, but it may be dispensed with in the treatment of adults (Fig. 640).

The plaster support is usually retained from four to eight weeks. When it is removed, massage, manipulation, and gymnastic training are indicated. Twice a day the head should be forced to the extreme limit of overcorrection. Traction on the neck in self-suspension by means of the sling used in the application of the plaster jacket, a regular system of exercises for the muscles of the neck and back, and supervision of the habitual postures will usually assure a complete cure. If, however, the deformity habit is strong so that the head has

MEDICAL LIBRARY
THE
BOSTON CITY

a marked tendency to resume the former attitude, some support is indicated. A simple and effective support is the jury-mast as used in the treatment of Pott's disease with the plaster jacket or attached to a brace.

As has been stated, the indications for support, provided the deformity has been thoroughly overcorrected, depend upon the care that is to be exercised in the after-treatment. When exercises and training in posture can be efficiently employed, the support is not essential. In other cases it may be worn for several months with advantage.

The principles of the treatment of the chronic or painless form of torticollis that have been outlined apply to the acquired as well as to the congenital form, when adaptive shortening has replaced

Fig. 640.—Torticollis, left, showing the method of fixing the head in the overcorrected position after operation.

active contraction. Acquired torticollis is, in most instances, however, a preventable deformity; thus operative treatment would be rarely required had the patient received proper treatment.

The Treatment of Acute Torticollis.—The insignificant form of torticollis called stiff neck may be treated by hot applications; a firm, wide, thick collar of flexible cotton stiffened by several layers of adhesive plaster is an agreeable support in the more painful cases.

In acute spastic torticollis the cramp-like contraction of the muscles is secondary to irritation elsewhere. This, if possible, should be removed, and, as has been stated, the general condition of the patient

often requires treatment as well. But the important indication is to support the head in order to relieve the pain and to correct the distortion. In the early stage the support of the collar that has been described may be sufficient, but, as a rule, patients of this class are not seen until the distortion has persisted for weeks or months even, so that a more efficient form of support is required—such as the plaster jacket and jury-mast. The elastic tension of this appliance overcomes the spasm and relieves the discomfort and apprehension which have lowered the vitality of the patient (Fig. 47). If the spasm is the result of the irritation of enlarged or suppurating cervical glands, as is often the case, the rest afforded by the brace is an effective treatment of the cause as well as of its effect, and if suppuration is present this support is most convenient for the dressing that may be required. When the acute symptoms and the deformity have been relieved, manipulation and exercises may be employed in the manner already described.

In cases of longer standing, particularly when the posterior muscles are involved, the deformity may be forcibly corrected under anesthesia, and the head may then be fixed in a plaster dressing in the manner already described. This treatment may be employed at an earlier stage in selected cases. As a rule, when deformity has been allowed to persist for six months or more, its rectification will require division of the more resistant tissues.

Spasmodic Torticollis.—Spasmodic torticollis, a form of convulsive spasm of the muscles of the neck that is somewhat similar in its general characteristics to writer's cramp, must not be confounded with the acute torticollis of childhood, in which tonic spasm of the affected muscles, due usually to some well-defined irritation of the peripheral nerves, is the characteristic. Spasmodic torticollis is an affection of adult life. Of 32 cases collected by Richardson and Walton,[1] but 2 were in patients less than twenty years of age. The sexes are equally liable to the affection, and the contraction is as frequent on one side as on the other.

The onset of the affection is usually gradual. The first symptoms are most often stiffness and discomfort in the muscles of the neck; a "drawing sensation" and a momentary twitching or slight contraction which draws the head to one side. These symptoms increase slowly until the head is habitually inclined in the attitude of torticollis. For a time the patient can correct the position voluntarily, or by supporting the head with the hand can restrain the twitching of the muscles, but in well-established cases the head is persistently inclined to one side and the convulsive spasm is uncontrollable. This latter symptom is the most marked peculiarity of the affection; at intervals the muscles begin to twitch, and the head finally drawn by the convulsive contraction into an attitude of extreme deformity. As the muscles most often affected are the sternomastoid and trapezius the attitude is usually one of typical torticollis. The spasmodic clonic contrac-

[1] Am. Jour. Med. Sci., January, 1895.

tions may involve the muscles of the face or of the chest even. They are more marked when the patient is excited or when sudden movements are necessary. As a rule patients complain of neuralgic pain in the head and neck, aggravated by the cramp-like contractions.

Etiology and Pathology.—The etiology is obscure. Many of the patients present a neurotic family or personal history, and overwork, shock to the nervous system and the like are cited as predisposing causes. The affection has been compared to writer's cramp, as in certain instances the spasm appeared to be caused by constrained positions of the head necessitated by certain occupations, aggravated, it may be, by the strain of defective eyesight.

The affected muscles may be hypertrophied from constant activity, and in the later stages of the affection they are, as a rule, permanently shortened. No characteristic changes in the nerves or in the central nervous system have been recorded.

Prognosis.—There is little tendency toward spontaneous recovery. As a rule the spasm becomes more constant and other muscles become involved.

Treatment.—It is perhaps unnecessary to state that the general condition of the patient and the possible local and general causes of the spasm should receive consideration. As a rule, however, the patient will have exhausted both constitutional and local treatment before coming under observation.

In the mild and early cases the avoidance of predisposing causes combined with massage, systematic muscle training, and in exceptional instances mechanical support may be of service; but in the chronic, severe, and persistent cases of this class the resection of nerves supplying the affected muscles has alone proved to be efficient. If the spasm is limited to the sternomastoid and trapezius muscles, resection of the spinal accessory nerve may be sufficient; but if other muscles are involved or if the spasm recurs after the original operation, the removal of the posterior branches of the upper cervical nerves, together with extensive division of the contracted muscles upon the same side and sometimes upon the opposite side, also, may be required.

Resection of the spinal accessory nerve was first performed by Campbell de Morgan, of London, in 1866, and since then the operation has been repeated many times by other surgeons, with temporary or permanent benefit to the patients. According to Pétit, of 26 patients so treated 13 were cured and 7 were permanently improved. In 5 others the benefit was but temporary, and 1 died from erysipelas following the operation.[1]

Division of Spinal Accessory Nerve.—The spinal accessory nerve passes downward and backward from the jugular foramen and enters the anterior border of the sternomastoid muscle at a point about one and a half inches below the tip of the mastoid process. At this point it should be exposed. Dr. E. Eliot, Jr., from a special study of the course and relations of the nerve, suggests the following method:[2]

[1] L'Union Méd., July 9, 1897.

[2] Ann. Surg., May, 1895.

"The incision should extend from the mastoid process above downward to one or two inches beyond the angle of the jaw. The anterior edge of the sternomastoid should then be exposed. In the upper part of the wound the posterior and inferior portion of the parotid gland may have to be drawn forward, although usually it does not overlap the muscle. When this is done it is comparatively easy to expose by blunt dissection the transverse process of the atlas, as it lies directly below the mastoid process above, while immediately in front of this bony prominence, and running downward and forward from the mastoid process toward the angle of the jaw is the posterior belly of the digastric. Behind this lie the main vessels of the neck, with the spinal accessory nerve emerging from the jugular foramen, and the operator is certain that no harm can be done to these structures as long as he remains superficial to the digastric belly, which in its turn lies at a considerable depth—in fact, at about the level of the transverse process of the atlas.

"Owen and Pétit have drawn attention to the fact that the nerve usually enters the mastoid muscle at a point opposite the angle of the jaw. I have found, however, in a large majority of cases, that on leaving the internal jugular it assumes a definite relationship with the transverse process of the atlas. Never above it, sometimes directly over it, usually a fraction of an inch in front of its most prominent part, the nerve may easily be detected in the small amount of connective tissue that envelops it, and from this point to its entrance into the belly of the muscle it may be isolated with safety, and treated by any suitable procedure. If, exceptionally, it should escape detection the anterior border of the muscle should be drawn sharply backward at a point opposite the angle of the jaw, the nerve in this way put on the stretch, and by blunt dissection in the adipose tissue that separates the under surface of the muscle from the sheath of the vessels the nerve may be readily exposed. Usually the nerve passes from under the posterior belly of the digastric, at a point just in front of the transverse process of the atlas, to a point on the deep surface of the muscle just behind its anterior margin opposite the angle of the inferior maxilla. It is sometimes accompanied by a small artery and vein, the latter easily visible, the former a branch of the occipital. Rarely the nerve lies at a considerable distance from the transverse process of the atlas; in 1 case as much as half an inch anteriorly. Here the nerve could be found at its entrance into the muscle, the landmark of the transverse process having failed to localize its situation."

Richardson suggests that if the nerve is not readily found its position may be ascertained by drawing the finger-nail firmly across the bottom of the wound, a sharp contraction following pressure upon it. The nerve having been isolated, a section of an inch should be removed. Richardson advises in addition vigorous stretching of both extremities. After division of the nerve the spasmodic contraction relaxes and the muscles become flaccid, permitting the normal position of the head, or if the deformity has become permanent the contracted parts may

be divided as in the ordinary form. Fixation of the head is not, as a rule, required. The operation should be supplemented by massage and by muscle-training. If the spasm has been confined to the muscles supplied by the spinal accessory nerve, the treatment may be permanently successful, but in many instances the spasm may recur in other muscles. Of these, the posterior group of the opposite side is more often affected, and a similar operation for resection of the posterior branches of the upper cervical nerves may be indicated. This has been performed with success by Smith, of London; Keen, Richardson and others. According to Smith,[1] the operation should be conducted as follows: An incision is carried downward from the occiput about three inches in length, parallel to and one inch from the spinous processes. It is continued through the trapezius to the edge of the splenius.

The complexus is then divided and the posterior branches of the nerves are exposed; those of the three upper nerves which supply the posterior rotators are then resected.

The most radical and apparently the most successful operation is that by Finney and Hughson,[2] which they describe as follows:

"In planning the operation we have endeavored to make it sufficiently comprehensive to include all the offending structures on both sides instead of only one, as experience has taught us that in the majority of cases sooner or later both sides become involved. The operation about to be described is based upon the anatomical relations as observed in operations performed upon our series of 32 cases and in the dissecting room findings in approximately 50 cadavers. After having tried various positions, we now employ that known as the cerebellar position, the patient lying prone with the shoulders elevated, the head slightly flexed and projecting over the end of the operating table and supported on a rest. The usual aseptic technique is employed.

"The incision should be made along the posterior border of the sterno-cleido-mastoid muscle (Fig. 641), beginning at a point two finger's breadth below the level of the angle of the jaw and continuing upward along the edge of the muscle to a point about the level of the lobe of the ear, then curving over toward the midline to a point about two finger's breadth below the occipital protuberance, thence carried across the midline, following the same general direction as just described, in reverse order. When completed, the incision is in the form of an inverted "U." Reflect back a flap of skin and subcutaneous tissue, taking care to identify and avoid the lesser occipital nerve, which is quite superficial and lies along the posterior border of the sterno-cleido-mastoid muscle, in its upper half. Having exposed and identified this nerve, follow it down to the point where it emerges from behind the posterior border of the sterno-cleido-mastoid muscle (Fig. 642). By retracting the sterno-cleido-mastoid muscle, the anterior divisions of the second, third and fourth cervical nerves now come into view, together

[1] Spasmodic Wry-neck, London, 1891.

[2] Ann. Surg., January, 1925.

with the chain of deep cervical lymph nodes. A little further in front of the plexus, and consequently a little deeper in the wound, will be found the trunk of the spinal accessory nerve where it emerges from the body of the muscle. The nerve having now been definitely identified (and here as with all other nerve trunks involved, direct stimulation with a bipolar electrode makes the identification absolute) can be resected at any point desired. No effort should be made to save the sensory branches of these nerves as, in Thomas' opinion, both efferent and afferent pathways should be interrupted. Search should next be

Fig. 641.—Incision. Lower limit, level of angle of jaw; upper, 1½ cm. below occipital protuberance. (Finney and Hughson.)

made for the great occipital nerve, where it emerges through the fibers of the splenius, about 1 cm. from the midline and just beneath the skin incision. Having identified this nerve, divide transversely at this point the trapezius and splenius muscles (Fig. 643), exposing the fibers of the complexus, which is easily recognized. The fibers of this muscle are divided in turn throughout its whole thickness in the same plane as the skin incision, and it is then reflected backward in the same way, care being taken all the while to preserve the great occipital nerve which lies immediately below it. This exposes the two recti muscles,

major and minor, and the superior and inferior oblique (Fig. 644), each of which can be distinguished by the direction of its fibers and their common point of origin. The trunk of the great occipital nerve should then be traced down to the point where it emerges from the vertebral foramen at the lower border of the inferior oblique muscle. At this point will be found its anastomosis with suboccipital nerve running across the body of the muscle to the point where it is given off from the first cervical nerve in the suboccipital triangle.

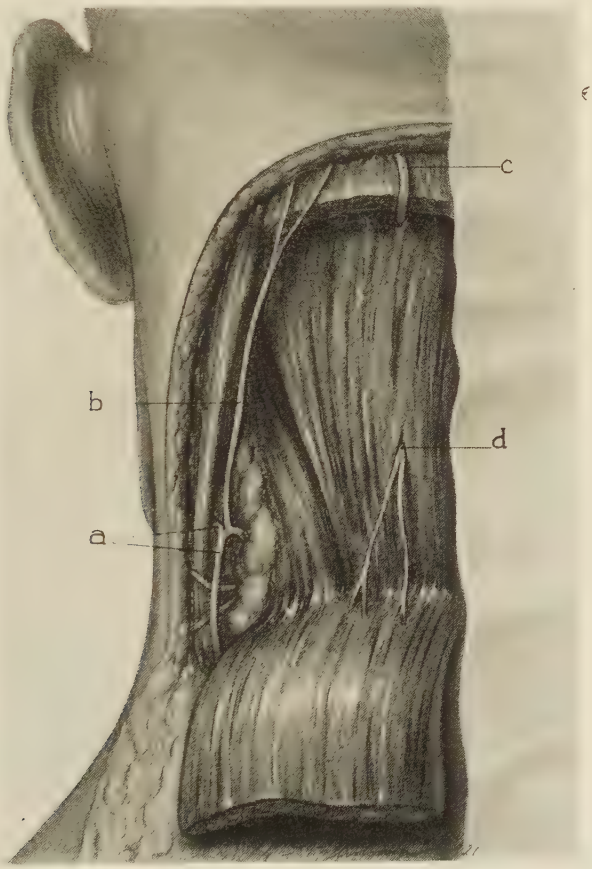

FIG. 642.—*a*, spinal accessory nerve; *b*, lesser occipital nerve; *c*, greater occipital nerve; *d*, third cervical nerve. Splenius and trapezius muscles have been divided and turned back. (Finney and Hughson.)

"The great occipital nerve should be resected below the point of anastomosis with the suboccipital. The latter can then be traced out in the suboccipital triangle as it emerges between the vertebral artery lying deeply in the triangle and the upper border of the inferior oblique muscle. Its branches to the recti muscles and the superior and inferior oblique muscles are given off here, and the main trunk of the

nerve can be readily resected at this point. Care should be taken not to injure the vertebral artery, which may be identified as it lies on the floor of the triangle. The splenius and complexus muscles should be reflected sufficiently to allow the exposure of the third cervical nerve, where it emerges a finger breadth below the great occipital. At the level of the second and third cervical nerves is located a venous plexus of considerable size which may give rise to troublesome bleeding

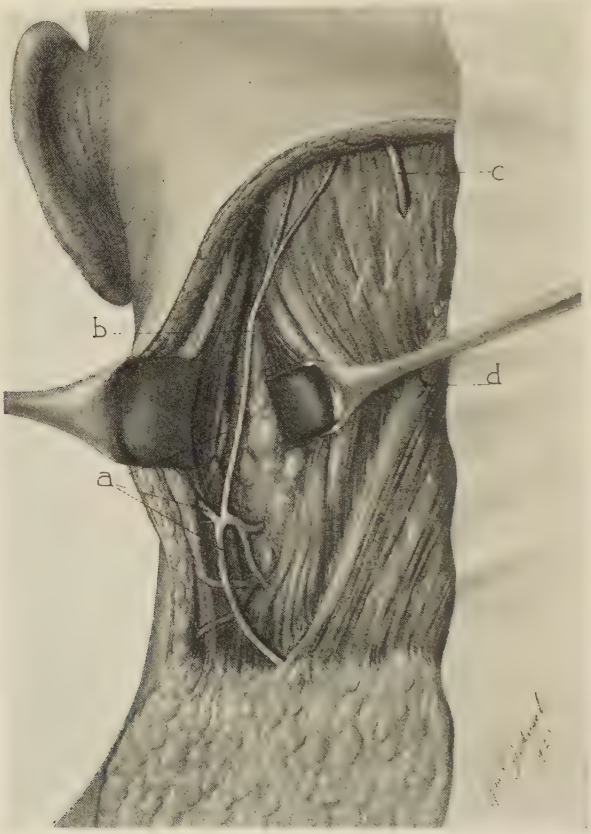

FIG. 643.—*a*, spinal accessory nerve; *b*, lesser occipital nerve; *c*, greater occipital nerve; *d*, third cervical nerve. View after skin and subcutaneous tissues have been turned back. (Finney and Hughson.)

if care is not taken to avoid or control it, which, however, can be readily done. The third cervical nerve should be resected where it emerges from the vertebral foramen, as it supplies fibers to the overlying muscles (splenius, trapezius and complexus). After the trunks of the three upper cervical nerves have been resected as described, the muscles may be replaced, layer by layer, and held in place by a few stitches, and the wound closed in the usual manner. In our earlier operations we excised portions of these muscles, but subsequent experi-

MEDICAL LIBRARY OF THE BOSTON CITY HOSPITAL

ence has shown that with complete resection of the nerve supply this rather mutilating procedure may be omitted. Until recently we have always inserted a drain consisting of a small piece of protective at each corner of the incision, but with adequate hemostasis this will probably be unnecessary.

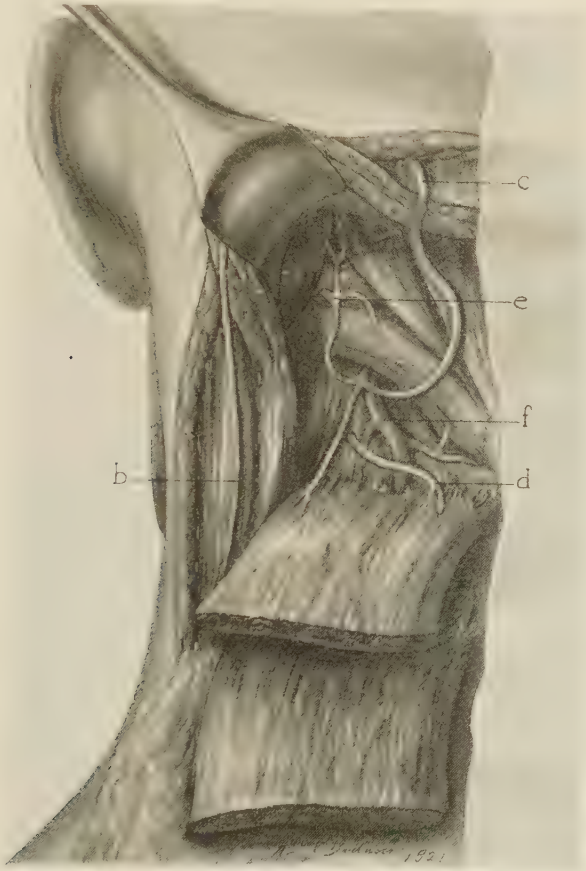

FIG. 644.—*b*, lesser occipital nerve; *c*, greater occipital nerve; *d*, third cervical nerve; *e*, first occipital nerve; *f*, branch of venous plexus. All posterior muscles have been divided and turned back, exposing the suboccipital triangle. (Finney and Hughson.)

"Formerly we applied a plaster-of-Paris bandage reinforced with wooden splints, with the head in an overcorrected position; but this added greatly to the patient's discomfort and appeared to be rather a source of irritation than a help, and so was discontinued in favor of the ordinary gauze dressing and soft bandage, reinforced with light wooden coaptation splints if desired. Notwithstanding the great extent of the wound, the healing has been uniformly satisfactory and the resulting disability surprisingly slight.

"The average time of the operation, doing two sides at one sitting, is one and a half hours. We would emphasize the fact that this operation should not be undertaken by any but an experienced surgeon, and only after thoroughly familiarizing himself with the anatomy of the part, as the success of the operation is dependent largely upon careful dissection and recognition of the different structures sought for. Careful hemostasis, in order to insure a clean, dry wound, is essential for the easy recognition of the different structures, which facilitates greatly the performance of the operation.

"From our experience with our group of 32 cases, we are convinced that the probable reason for failure to obtain cures is failure to identify and resect the nerves. We feel convinced too that it is impossible to secure satisfactory exposure and identification of the nerves sought by any less extensive incision than that described.

"Of our series of 32 operated cases, 1 has not been heard from recently. Of the remaining 31, 3 are unimproved, 16 have been improved but not entirely relieved, while 12 have been completely cured. It should be borne in mind that these operations cover a period of more than twenty years, that the earlier operations were very incomplete and that the operation just described has been developed comparatively recently. It has been used in only a few cases, too few and too recent to enable us to pass final judgment on its merits, but in a sufficient number we believe, as compared with previously used and less radical methods, to justify its more extended use."

Irregular and Exceptional Forms of Torticollis.—Paralytic Torticollis.—One or more of the muscles of the neck may be paralyzed, as from anterior poliomyelitis, and thus a deformity, due at first to simple weakness and later to the permanent effects of the disability, may be the result.

Diphtheritic Paralysis and Torticollis.—The muscles of the neck may be involved in paralysis following diphtheria. In this form the trapezii muscles are, as a rule, affected, so that the head droops forward, but occasionally the paralysis may be accompanied by contraction of one of the sternomastoids. The history, the evident weakness, and the paralysis of the soft palate or other parts, which is often present, usually make the diagnosis clear.

Cervical Opisthotonos.—In the course of certain forms of disease of the nervous system, for example, cerebrospinal or basilar meningitis, the head may be drawn backward by spasm of the posterior muscles. A slight degree of the same deformity is sometimes seen in ill-nourished infants not suffering from serious disease. This and the preceding distortion are of some importance, because they may be mistaken for symptoms of Pott's disease and they have been described in that connection.

Rhachitic Torticollis.—During the course of acute rhachitis, particularly when the characteristic deformity of the lower part of the spine is well-marked, the head may be tilted backward usually as a compen-

satory attitude, but occasionally slight spasm of the posterior muscles may increase the distortion; so, also, when lateral deviation of the spine is present due to rhachitis the neck may participate in the deformity as in other forms of rotary lateral curvature. This is not torticollis, however, in the proper sense.

Ocular Torticollis.—The head may be habitually held in a distorted attitude because of defective vision or irregularity in the action of the muscles of the eyes. This is, however, rather an improper attitude than a variety of true torticollis and is of greater importance as a predisposing factor to deformity of the spine[1] (Fig. 232).

Fig. 645.—Cervical opisthotonos.

Psychical Torticollis.—A distortion of the head, apparently due to the inability of the patient to control the muscles of the neck, has been described by Brissaud.[2] The deformity is not due to muscular spasm, since it can be corrected by the pressure of a finger on the head. The condition is called by Brissaud a local paralysis of the will—a form of neurosis allied to neurasthenia, epilepsy, and functional spasm.

[1] White: Am. Jour. Surg., January, 1928.

[2] Thèse de Paris, 1894.

CHAPTER XX.

DISABILITIES AND DEFORMITIES OF THE FOOT.

GENERAL DESCRIPTION OF THE FOOT AND OF ITS FUNCTIONS.

The function of the foot is twofold: to serve as a passive support of the weight of the body, and as an active lever to raise and propel it. For the proper performance of these functions it is constructed to permit elasticity under pressure, and an alternation of attitudes under strain, that protect it from injury.

The Arches.—The most noticeable peculiarity of the foot is the arrangement of its arches. As has been suggested by Ellis and others, the construction and shape of the arched part of the foot may be better understood by considering it as half of the arch formed by the two feet. This complete arch may be demonstrated by making an imprint of the apposed feet in plaster of Paris. The plaster cast

Fig. 646.—Longitudinal section of the cast of the arch at the point *A* in Fig. 647. *A*, the astragalo-navicular junction; *B*, the internal tuberosity of the os calcis; *C*, the head of the first metatarsal bone.

which represents it will appear in shape somewhat like an inverted saucer, the part of each foot that rests upon the ground forming half of an irregular ring. If the plaster cast is sawed into equal sections it will be seen that the highest or thickest part of each division is at the astragalo-navicular junction; from this point the arch descends sharply to the tuberosities of the os calcis, and gradually to the outer border, beneath the cuboid bone, and to the metatarso-phalangeal joints (Fig. 646). A cross-section of the cast will show the contour of what is sometimes called the *transverse arch* (Fig. 647), while the section through the long diameter will demonstrate the shape of the *longitudinal arch*. In descriptions of the longitudinal arch it is often divided into two parts, of which the outer division is formed by the os calcis, the cuboid, and the two outer metatarsal bones. Of this outer arch, the highest point is at the calcaneo-cuboid articulation (Fig. 648), and although it is normally a permanent arch, yet the soft tissues are

forced downward beneath it when weight is borne, so that the outer border of the foot makes an imprint throughout its entire length,

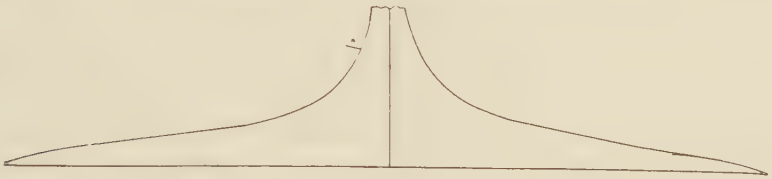

FIG. 647.—Cross-section of the cast of the arches of the apposed feet. *A*, the internal and inferior surface of the astragalo-navicular junction.

as contrasted with the inner and deeper arch formed by the os calcis, the astragalus, the navicular, the cuneiform, and the three inner meta-

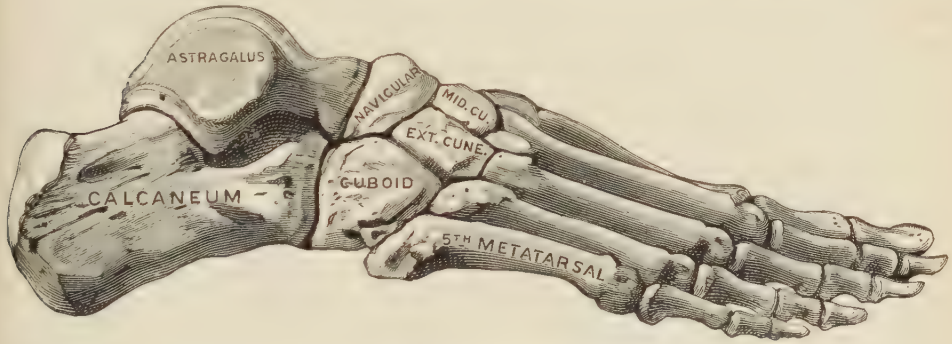

FIG. 648.—The bones of the right foot, viewed from the outer side. (Gerrish's Anatomy.)

tarsal bones (Fig. 649). This division, although an artificial one, serves to call attention to the fact that the outer or lower arch is more solidly

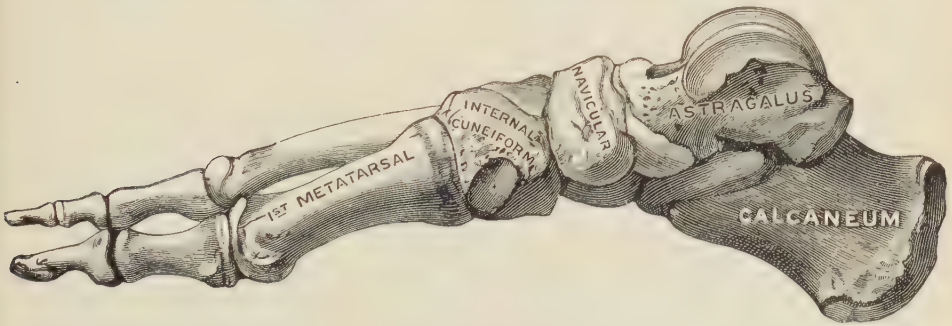

FIG. 649.—The bones of the right foot, viewed from the inner side. (Gerrish's Anatomy.)

braced, and, therefore, better adapted for continuous weight-bearing than is the higher and more elastic inner arch.

The diagram of the longitudinal arch, showing its sharp descent

from the highest point to the center of the heel, indicates that the heel is well adapted for weight-bearing, while the long anterior pillar composed of several bones is less strong but more elastic; thus one instinctively extends the foot in descending stairs, for example, to avoid the unpleasant jar of direct shock received upon the heel. Of this anterior pillar, the third metatarsal bone is the most direct support, while the more movable first and fifth metatarsals, more under muscular control, aid in balancing the weight and sustaining it in the different attitudes.

FIG. 650.—Illustrating the automatic adduction of the forefoot on the right side, due to the obliquity of the bearing surface of the metatarsus, in the proper attitude for walking.

FIG. 651.—The improper attitude of outward rotation of the limbs usually accompanied by eversion of the feet, in which there is disuse of the leverage function.

Both divisions of the longitudinal arch are permanent arches, but there are two others which are obliterated under weight—one of these is that formed by the heads of the metatarsal bones, the *anterior metatarsal arch*. In the unweighted foot the second and third metatarsophalangeal articulations occupy a higher plane than their fellows, but when the erect posture is assumed the anterior arch is depressed to allow the metatarsal heads to bear their share of the weight. The other arch is formed by the internal border of the foot, which curves slightly outward, so that when the two feet are placed side by side an interval remains between them, widest at the highest point of the longitudinal arch, as is shown in the diagram by the upright section which divides the cast of the two soles from one another, the *internal*

arch (Fig. 647). When the weight is borne this curved contour of the foot becomes straighter, or is obliterated, or is even transformed to an arch whose convexity is internal (Fig. 651).

The Foot as a Passive Support.—The foot is supported by the muscles, by ligaments, and by the strong plantar fascia that covers in the sole. When the foot is actively used it is in great part supported by the muscles, but when it serves as a passive support, as in standing; the ligaments bear the greater part of the strain, and its normal elasticity allows the bearing surface to expand as the arches are slightly depressed. If this elasticity is diminished as in the contracted foot the supports of the arch are subjected to abnormal pressure and the individual may suffer from sensitive corns or calloused skin. Or if the ligaments permit abnormal expansion the arches may become permanently depressed, and, as a result, the range of motion required for the proper functional use of the foot may be permanently restricted.

It has been stated that the foot broadens and that the arches are slightly depressed under weight; it must not be understood, however, that the longitudinal arch is simply flattened by direct pressure and by elongation of elastic ligaments and fascia. Ligaments and fascia are not elastic in this sense, and they are not, in the normal foot, overstretched. The change in contour is the effect of normal motion in the joints of the foot, by which it is placed in the most favorable attitude for weight-bearing without muscular exertion—the so-called attitude of rest.

Of the changes of contour that distinguish the foot used as a passive support from one that bears no weight, the most significant is the obliteration of the outward curve of its internal border. This change is due to the fact that the astragalus, bearing the leg, rotates inward and downward on the os calcis until it is checked by the resistance of the ligaments and by the interlocking of the bones. The head of the astragalus thus becomes slightly prominent, the inner border of the foot is depressed, and an attitude is attained in which the weight of the body may be supported with but slight muscular exertion. In this attitude of rest, as von Meyer has explained, there is general fixation of joints of the lower extremity which makes support possible with the least muscular exertion. The pelvis tilts slightly backward until tension is brought upon the anterior part of the capsule of the hip-joint; the femur rotates slightly inward on the tibia, which in turn falls slightly inward upon the everted foot. To unlock the joints the pelvis must be tilted forward or the hip must be flexed.

The Foot in Activity.—The second function of the foot is as a lever to raise and to propel the body. The calf muscles supply the power and the heads of the metatarsal bones serve as the fulcrum on which the weight is to be lifted. When the foot is used as a lever, it should be held in such relation to the leg that the line of weight, passing downward through the center of the knee and ankle-joints, is continued over the second toe or practically the center of the foot. As the body

is lifted over the fulcrum the leg is turned outward in its relation to the forefoot, because the inner side of the fulcrum, formed by the first metatarsal bone, is longer than its outer side; thus the strain is directed toward the outer and stronger side of the foot (Fig. 650).

In the proper walk, which is the best illustration of the leverage function, the feet should be placed practically in the line of progression. As one foot is advanced it first bears weight momentarily on the heel, then upon its outer border; the heel is then raised, and the body is lifted over the toes, the great toe giving the final impulse to the step, so that if the walker is looked at from behind he appears to be in-toeing at the termination of each step.

Improper Postures.—The alternation of postures and the leverage action of the foot are by no means necessary to simple progression; for example, both feet might be fixed in plaster splints, yet walking would be possible, just as it is possible on two wooden legs. Indeed, an approximation to such a manner of walking is often seen, in which the feet are used in the passive attitude, the weight being borne in great part upon the heels. Such a walk is necessarily jarring and ungraceful, and it predisposes to weakness and deformity because of the disuse of proper function.

The custom of turning the feet outward embarrasses the leverage function. Outward rotation of the limbs is normal in the passive attitude because it enlarges the base of support and thus relieves the muscles. On this very account it is the improper attitude for activity because the strain falls upon the inner border of the foot, or to the inner side of the fulcrum, and makes the proper exercise of muscular power and alternation of postures impossible.

The Movements of the Foot.—The junction between the foot and the leg is made by means of the astragalus, a bone which is not intimately connected with either part, since it moves upon the leg and upon the foot, and to it no muscles are attached.

The primary movements of the foot are four in number—dorsal flexion, plantar flexion, adduction, abduction.

Simple dorsal and plantar flexion are confined to the ankle-joint, but extreme plantar flexion is combined with slight adduction, and dorsal flexion with abduction, because the external facet of the astragalus permits a greater range of motion on the external malleolus than that about the internal malleolus, and because the forefoot in plantar flexion turns downward and inward on the head of the astragalus and in the reverse direction in dorsal flexion.

The range of motion at the ankle-joint is from 60 to 80 degrees; thus dorsal flexion to 10 to 20 degrees less than the right angle, and plantar flexion to 50 to 60 degrees more than the right angle (Figs. 653 and 654).

Adduction and abduction of the foot are carried out in the mediotarsal and subastragaloid joints.

Adduction, the turning of the foot inward in its relation to the leg,

MEDICAL LIBRARY
BOSTON CITY HOSPITAL

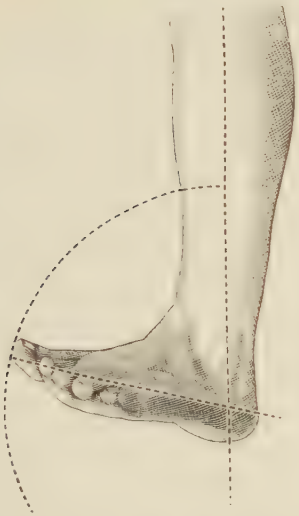

FIG. 652.—Voluntary dorsal flexion.

FIG. 653.—Voluntary plantar flexion.

FIGS. 652 and 653.—In these attitudes the astragalus moves with the foot upon the leg bones, as contrasted with adduction and abduction, in which the center of motion is below the astragalus.

FIG. 654.—Voluntary adduction.

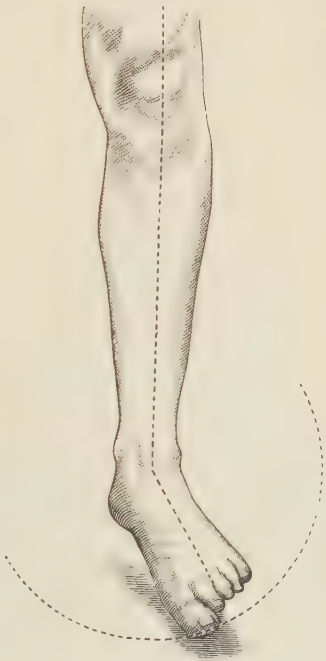

FIG. 655.—Voluntary abduction.

FIGS. 654 and 655.—In these postures the foot moves beneath the astragalus, which is practically fixed between the malleoli. Adduction, the turning of the foot inward in its relation to the leg, is always accompanied by elevation of its inner and depression of its outer border. This is known as supination or inversion of the foot. The reverse of this attitude—pronation or eversion—is an accompaniment of abduction, as is illustrated in the figures. The three terms therefore are practically synonymous.

is always accompanied by inversion of the sole because of the shape of the joint surfaces between the astragalus and os calcis, where the greater part of the motion takes place. Simple adduction and abduction without inversion or eversion is possible to a very limited extent in the mediotarsal joint. Its range may be tested by fixing the heel, when the forefoot may be moved slightly from side to side upon the astragalus and os calcis. The range of motion in the subastragaloid joint is twice as free as in the mediotarsal joint. The character of the motion between the astragalus and os calcis is rotation on an axis passing through the upper and inner part of the head of the astragalus, downward and outward to the outer tuberosity of the os calcis. Thus for all practical purposes adduction, inversion, and supination are synonymous terms, as are abduction, eversion, and pronation.

Fig. 656.—Tibialis anterior of right side; outline and attachment areas.

Fig. 657.—Peroneus tertius of right side; outline and attachment areas.

Figs. 656 and 657.—The direct dorsal flexors.[1]

In the movement of inversion the astragalus is practically fixed by the malleoli, and upon it the os calcis glides forward, its anterior extremity turning slightly inward; its inner superior surface is elevated, and its external surface is depressed. Meanwhile the forefoot, attached to the os calcis, is carried inward and downward about the head of the astragalus; its inner border is elevated, and its outer border is repressed, so that the sole looks inward and downward. In this attitude all the arches are increased in depth (Fig. 654).

In eversion the bones move upon one another in the reverse direc-

[1] Figs. 656–666 modified from Gerrish's Anatomy.

tion, the curves are lessened, and that of the inner border is obliterated (Fig. 665).

Simple inversion and eversion may be carried out to the full extent with the foot at a right angle to the leg. Complete adduction, however, may be attained only in the position of plantar flexion. In this position the forefoot is flexed over the head of the astragalus, increasing the depth of the arch and the adduction permitted at the ankle-joint when the narrow posterior border of the astragalus is alone in contact with the malleoli, is added to the adduction which the joints of the foot permit.

FIG. 658.—The gastrocnemius of right side; outline and attachment areas.

FIG. 659.—The soleus of right side; outline and attachment areas.

FIGS. 658 and 659.—The combined soleus and gastrocnemius is called the calf muscle.

Extreme abduction is attained in the attitude of dorsal flexion, its extent being about one-half that of adduction; the entire range of motion between the two extremes being about 45 degrees.

In this description the foot is considered as moving on the leg, but in the attitude of rest the foot becomes the fixed point and the astragalus moves upon the os calcis in the manner and to the position already mentioned in the description of abduction—*i. e.*, it slips downward and forward and turns inward; at the same time the anterior extremity of the os calcis turns slightly inward and downward, and its inner border is depressed. Corresponding to this movement, as the inner border of the foot becomes straight or bulges inward,

the navicular is forced forward and downward and the longitudinal arch is depressed. As has been mentioned, the turning of the leg inward and the corresponding turning of the foot outward in its relation to it locks, in a manner, the ankle-joint, and at the same time throws the strain upon the ligaments, so that standing in the erect posture is possible with but little muscular exertion (Fig. 667).

To put in a simpler manner, the leg supporting the weight of the body has a tendency to tilt the foot over toward the inner side and to evert the sole; thus, under increasing weight, the point of greatest pressure on the sole shifts from its center and outer border toward the inner border. If, on the other hand, the body is raised upon the toes, the arch is relieved from strain and the weight falls upon the front

FIG. 660.—Peroneus longus of right side; outline and attachment areas.

FIG. 661.—Peroneus brevis of right side; outline and attachment areas.

FIGS. 660 and 661.—The direct abductors.

and outer part of the foot. Plantar flexion and adduction represent, as contrasted with the passive attitude of supporting weight, the attitude of activity in which the foot is supported and controlled by the muscles.

The Function of the Muscles.—The most important function of the dorsal flexors is to raise the foot as it is swung forward; of the plantar flexors to lift and propel the body. The difference in function is shown by the relative strength of the two groups, the plantar flexors being five times the stronger; in fact, the calf muscle (gastrocnemius and soleus) alone is three times as powerful as all the other muscles of the foot combined. It is practically the leverage muscle, the others serving more especially to balance the foot and hold it in its proper

relation to the leg. It is also a powerful adductor and inverter of the foot in the attitude of plantar flexion (Figs. 658 and 659).

The muscles that more directly support the inner arch of the foot are the tibialis posticus and tibialis anticus, whose tendons approach to their attachments in front of the astragalus. The tibialis anticus supports the internal border of the foot from above, and is the direct inverter of the foot in dorsal flexion—that is, if unopposed it elevates the inner border of the foot, when it acts as a dorsiflexor. The tibialis posticus is the most powerful adductor (Figs. 656 and 662). The extensor longus hallucis is an adjunct of the tibialis anticus in its action on the foot as a whole. The extensor longus digitorum, including the peroneus tertius, is a dorsal flexor and abductor.

The flexor longus hallucis, passing directly beneath the sustentaculum tali, aids in supporting the weak part of the foot, and its position indicates the importance of the proper functional use of the great toe (Fig. 666).

The peroneus longus and brevis support the outer arch, and the former binds the foot together and holds the great toe firmly against the ground; thus it indirectly supports the longitudinal arch against direct pressure (Figs. 660 and 661).

The peroneus longus is an abductor, the brevis a more direct evertor of the foot.

Fig. 662.—The most important adductor. Tibialis posterior of right side; outline and attachment areas. The most of the muscle is represented as if seen through the bones.

The relative strength of the muscles and their functions is indicated in the following tables:[1]

Dorsal Flexors of the Foot; Strength Reckoned in Kilogrammeters.

	Tibialis anticus	0.871
	Extensor longus digitorum	0.280
	Extensor longus pollicis	0.155
	Peroneus tertius	0.087
		1.393

Plantar Flexors.

The calf muscle.	Soleus	3.256
	Gastrocnemius	2.831
	Flexor longus pollicis	0.218
	Peroneus longus	0.118
	Tibialis posticus	0.094
	Flexor longus digitorum	0.078
	Peroneus brevis	0.055
		6.650

[1] R. Fick: Ueber die Arbeitsleistung der auf die Fussgelenke Wirkenden Muskeln, Leipzig.

FIG. 663.—Extensor proprius hallucis of right side; outline and attachment areas.

FIG. 664.—Extensor longus digitorum of right side; outline and attachment areas.

FIG. 665.—Flexor longus digitorum of right side; outline and attachment areas. The muscle is represented as seen from in front through the bones.

FIG. 666.—Flexor longus hallucis of right side; outline and attachment areas. The muscle is represented as seen from the front through the bones.

The Foot Considered as a Mechanism.—In the study of the deformities, and particularly of the functional weaknesses of the foot, one must consider it is a mechanism of which deformities and disabilities and relative strength or weakness can be appreciated only by comparing it with the normal standard. Marked deformity or distortion is evident at a glance, even though the apparatus is not in use, but functional ability can be estimated only by the manner in which active work is performed.

As has been stated, the foot is, in activity, a lever, by means of which the weight of the body is lifted and propelled. If it is loosely constructed or insufficiently supported by the ligaments, it cannot be properly controlled by the muscles. If, on the other hand, the muscular power is insufficient, the weight of the body cannot be lifted and properly balanced upon it. The structure of the foot may be normal, and its muscles may be of normal strength, yet the strain placed upon it may be disproportionately great. The strain may be overweight of body, or that of a laborious occupation, but more often the foot is overworked because it is weakened by compression and consequent distortions and because it is subjected to mechanical disadvantages in the performance of its functions, by the assumption of improper attitudes.

One of the most common of such attitudes is, as has been mentioned, that of turning the feet outward in walking; for as the fulcrum is displaced outward, the strain falls through the inner and weaker side of the foot. As a consequence there is, to a greater or less degree, disuse of the active leverage function, the foot being used somewhat as if it were a movable pedestal (Fig. 651). This posture is usually associated with abduction of the foot, the passive attitude that predisposes to pain and weakness.

The disuse of the active function may be unnecessary, just as the outward rotation of the limbs with which it is associated is a conventional attitude. On the other hand, the habitual assumption of the passive attitude may be induced by injury or disease of the foot, or by corns or bunions, or by improper shoes. For under such conditions the strain of the leverage function increases the discomfort; consequently it is discontinued. It must not be inferred that such improper attitudes lead inevitably to weakness and discomfort, for in most instances an ungraceful carriage and gait are the only ill effects. The improper attitudes must, however, lessen the power and resistance of the foot, and they must be reckoned, therefore, among the important predisposing causes of disability.

The passive attitude, it will be remembered, is the attitude of abduction or rest, in which the ligaments bear the greater part of the strain and in which the arches of the foot are depressed or obliterated.

THE WEAK FOOT.

Synonyms.—Splay-foot, flat-foot, pronated foot.

The introductory pages of this chapter lead naturally to the con-

sideration of the most important and the most neglected of the acquired disabilities of the foot,[1] a disability characterized in the mildest aswell as in the most advanced type by the *persistence of the passive attitude of abduction,* or an approximation to it, in place of normal alternation of posture. Disuse of function is followed by restriction of motion, particularly in the range of adduction and plantar flexion, and finally by deformity, a deformity that is simply an exaggeration of the normal posture assumed when the foot supports weight (Fig. 667). This is the so-called flat-foot (Fig. 668). At first glance it may seem that the

FIG. 667.—An attitude that simulates the flat-foot. (See Fig. 668.)

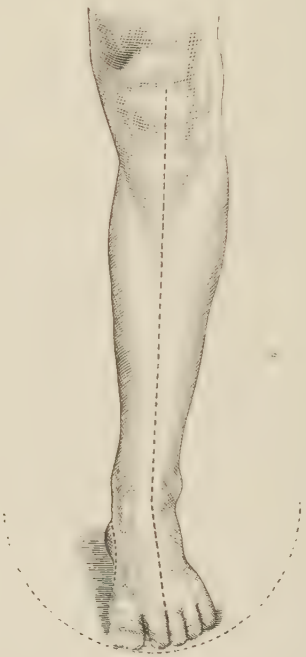

FIG. 668.—Compared with Fig. 667 illustrates the voluntary protection of the foot from overstrain.

depression of the arch is the most noticeable peculiarity in a characteristic case of flat-foot and that the popular name is, therefore, an appropriate one. On closer examination, however, it will appear that the foot is not flat because its "keystone has sunk," but that the lowered arch is caused by lateral displacement (abduction). This fact may be demonstrated by adducting the foot sufficiently to restore

[1] In 1925, 3759 new cases of weak foot were registered at the Hospital for Ruptured and Crippled in a total of 10,758 new patients (35 per cent.). R. J. Cook examined 1400 college students, three-fourths of whom presented recognizable weakness of the foot (Jour. Bone and Joint Surg., April, 1922).

MEDICAL LIBRARY
OF THE
BOSTON CITY HOSPITAL

approximately the normal relation between it and the leg, a movement which will restore its normal contour.

The deformity of the so called flat foot may be analyzed as follows: (1) The leg is displaced inward, so that the weight falls upon the inner side of the foot. (2) The leg is rotated inward so that a line drawn through its center, prolonged from the crest of the tibia, instead of falling over the second toe, now points inside the great toe, or even over the center of the internal border of the foot (Figs. 669 and 672).

Fig. 669.—Typical "flat-foot" of moderate degree, illustrating the component elements of abduction and depression of the arch.

It has been stated that under normal conditions, in the act of passive weight-bearing, the astragalus rotates downward and inward upon the os calcis, depressing its anterior and internal border until the movement is checked by the strong ligaments connecting the bones, the calcaneo-navicular, the deltoid, and the interosseus; in other words, in the passive attitude the leg has a tendency to slip downward and inward from off the foot. In the weak foot of advanced grade this simulating attitude has become an actual deformity, for the normal movement has become so exaggerated by the distention of the ligaments and by the weakness of the supporting muscles that an actual subluxation is present. The astragalus has rotated and slipped far to the inner side of its normal position, to an attitude of exaggerated rotation and plantar flexion, so that its head can be plainly felt on the internal border of the foot. The

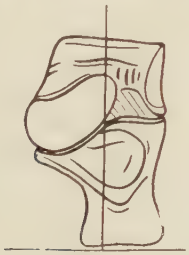

Fig. 670.—The relation of the astragalus to the os calcis.

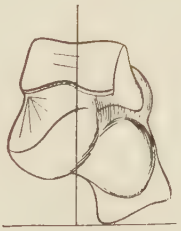

Fig. 671.—The relation of the astragalus and os calcis in flat-foot.

anterior extremity of the os calcis is depressed and is turned slightly inward and its internal border is lowered (Fig. 671).

The navicular has been depressed with the head of the astragalus, although to a less degree, it has been forced farther away from the os calcis, and the entire inner border of the foot is lowered. Thus the depression of the arch is always accompanied and preceded by a bulging inward of the inner side of the foot.

The typical flat-foot is, as it were, broken in the center (Fig. 669), the posterior division having turned inward and downward, while the forefoot is forced downward and outward. The dislocation may be so extreme that the entire sole of the foot rests upon the ground, and a callus even may be found at the point that usually represents the highest point of the arch, which now supports the greatest burden.

In this change of relation between the bones the arched part of the foot or waist appears much broader than normal, even broader than the front of the foot; the heel projects, the external malleolus is depressed and carried forward by the rotation of the leg, and is much less prominent than normal; the internal malleolus is more prominent, and with the astragalus it overhangs the bearing surface of the sole. The entire mechanism is out of gear; its motion is therefore much restricted. It is manifestly impossible for the patient to adduct the forefoot—that is, to turn it inward about the head of the displaced astragalus. Plantar flexion is also much limited, because of the persistent adduction and plantar flexion of the astragalus. Dorsal flexion, on the other hand, even if actually restricted, may appear to be abnormally free, because the forefoot is abducted and slightly dorsiflexed upon the head of the astragalus (Fig. 669).

The disability and its accompanying deformity are found in every grade of severity. Discomfort usually begins when the strain upon the muscles is disproportionate to their strength, and it is increased when the ligaments begin to give way under strain, permitting the bones to occupy an abnormal relation to one another. It is evident, therefore, that the individual whose foot is well-formed and whose ligaments are firm, will suffer from the symptoms of strain long before the arch has been noticeably depressed, also, that the lateral inward bulging, characteristic of abduction, must be very great before the arch is completely flattened. In this type the prominent deformity is lateral displacement (valgus). On the other hand, if the individual has inherited a low arch, or if, as the result of weakness in early life, the arch has been depressed or has never formed, accommodative changes in the joints will have taken place during growth, so that the flat-foot of this type will not entail such disturbance of function, as the typical case that has been described. This latter class of cases exemplifies the popular type of flat-foot which may entail no disability other than an awkward gait. (Contrast Figs. 673 and 676.)

In certain instances abnormal laxity of ligaments permits deformity of the valgus type when weight is borne, yet the foot, controlled by efficient muscles, may be apparently normal in functional ability, while in other cases, subjected by insufficient muscular protection to overstrain, disability and pain may precede noticeable deformity.

It is evident that the lowering of the arch is of secondary importance in the deformity, and that the popular conception of flat-foot, as an inherited or irremediable weakness, is most misleading. Yet it seems to have governed the treatment of the disability until very recently. On the one hand, the early cases were overlooked because

the foot was not flat, while those in which the deformity was more advanced were either neglected or were treated by simple supports beneath the arch or by operation, without regard to restoration of function, and, therefore, without hope of ultimate cure.

As has been stated, there is one feature common to every grade of the so-called flat-foot: the foot regarded as a mechanism is weak as compared to the normal standard—weak because of the persistence of the attitude of rest and relaxation, as contrasted with that of activity and strength, and weak

FIG. 672.—Weak feet, showing the inward rotation of the legs when the feet are placed side by side, indicating an attitude of persistent abduction.

FIG. 673.—Weak feet, illustrating lateral bulging due to persistent abduction without flatness.

because the proper relation between the power and the fulcrum is changed. Even the inherited flat-foot or the flat-foot which has never caused symptoms is weak in the sense that, in use, it lacks the symmetry and elasticity characteristic of the perfect machine. The term weak foot may be used, then, to include all types of the disability.

In one weak foot the arch has disappeared (Fig. 669); in another it is lowered; in a third the arch is of normal depth (Fig. 673). In one case the deformity appears only under weight-bearing; in another the foot is held rigidly in the deformed position by muscular spasm. In one instance there may be great deformity without pain; and in another disabling weakness and pain without noticeable deformity. In one case the foot is unable to perform its functions because of its inherent weakness; in another the disability may be due simply to

the improper use of a normal structure but there is one characteristic common to all, a persistence of the passive attitude of abduction.

Etiology.—The early symptoms are caused by fatigue and strain of the muscles working at a disadvantage, and the later symptoms are explained by the injury to which the overstrain has subjected the mechanism.

This theory accounts for the fact that the weak foot, although very common in childhood, does not, as a rule, cause disability until adolescence, when the weight and strain put upon it are increased. It explains why the foot, which may be fairly normal in structure, breaks down often in later adolescence or early adult life when the continuous strain of regular occupation is undertaken. It is evident, also, that an occupation that induces a persistence of the passive attitude, that of waiters, cooks, and bartenders, for example, exposes the feet to greater strain than one which encourages alternation of postures. And that the symptoms are likely to be more severe and the deformity to be greater among those who are obliged to labor than among those who are not. Overwork or strain, of occupation or otherwise, may be temporarily disproportionate because of general weakness, as, for example, during pregnancy or after recovery from exhausting disease; or because of local injury or disease of the foot itself, which weakens it directly or indirectly by inducing improper attitudes. This theory explains why there is no constant relation between the degree of deformity and the severity of the symptoms, for, although all weak feet are mechanically weak, yet all weak feet are not necessarily painful or deformed. Pain is not caused because the foot is flat or because it is improperly used; it is a symptom of strain and injury and of progressive deformity. The progress of the deformity may be temporarily or permanently checked at any stage, either by removal of the exciting causes or because of the increased resistance of the tissues; then the pain intermits or ceases.

This conception of the foot as a mechanism, of which grades of efficiency may be recognized, has a great advantage, since it enables one to perceive wherein a foot is weak, even though the weakness causes no symptoms whatever, and thus to prevent discomfort and deformity by the recognition and treatment of its predisposing causes.

Statistics.—A brief analysis of 1000 cases of so-called flat-foot treated at the Hospital for Ruptured and Crippled will represent fairly the points of general interest in this class of cases:

THE AGE AND SEX OF THE PATIENTS.

	Males.	Females.	Total.
Ten years or less	68	30	98
Ten to fifteen	112	87	199
Fifteen to twenty	144	83	227
Twenty to twenty-five	94	53	147
Twenty-five to thirty	68	41	109
More than thirty	132	88	220
	618	382	1000

Foot affected: right, 133; left, 138; both, 729.

In 58 cases the cause of the disability appeared to be injury, and in 65 instances it was, apparently, due to the so-called rheumatoid diseases. The symptoms usually appear first in one foot, and, as a rule, they are at all times more marked on one side. Of 569 instances, in which the duration of symptoms was recorded, it was six months or less in 409.

Hospital statistics cannot adequately represent the subject, for, as a rule, it is because of disability and pain that these patients apply for treatment. In a large proportion of the cases recorded muscular spasm and stiffness were present, in 234 instances to such a degree that forcible overcorrection was advised—an operation rarely necessary in private practice.

It is in childhood that the prevention of subsequent weakness and deformity is of the first importance, yet but 98 children of ten years of age or less are recorded, and many of these were brought, not for weakness or deformity, but for treatment of the symptomatic in-toeing.

It may be noted that in more recent statistics than the above, which were compiled for the first edition of this book, the relation of sex to disability has changed, for example, of 3739 new cases treated in 1925, 1565 were males and 2174 were females.

The age of the patients in this latter group is of interest as bearing on the question of prognosis: 23 per cent. were less than sixteen years of age and nearly 50 per cent. were less than thirty.

Pathology.—Assuming the foot to have been normal before it began to break down, it is evident that extreme deformity could not have been acquired without adaptive changes in its internal structure. In a general way these changes have been indicated already. The ligaments on the internal aspect of the foot and of the ankle-joint are weak and distended; the unused portions of the articular surfaces of the joints may be denuded of cartilage, while new facets may have formed to accommodate the changed relations of the bones. For example, the external malleolus may be in direct contact with the os calcis; evidences of injury and of abnormal pressure may be found in the thickened periosteum, in formation of osteophytes, while the internal structure of the bones has been changed in adaptation to the new conditions. The disused muscles, particularly the plantar flexors and adductors, have become atrophied, as evidenced by the shrunken calf. The muscles on the inner border of the foot have been overstretched, while the abductors and in some instances the calf muscles have become shortened and contracted in accommodation to the habitual posture. Such a foot represents an extreme, it may be an irremediable degree of deformity; but in by far the greater proportion of the cases the pathological changes have not advanced to a stage that precludes successful treatment.

Symptoms.—As has been stated, the symptoms of the weak foot, although similar in type, vary in severity according to the local condition and the disturbance of function, the work to be performed, and the susceptibility of the individual. The earliest symptom is usually

a sensation of weakness; the patient begins to recognize as familiar a feeling of discomfort, of tire and strain about the inner side of the foot and ankle; sometimes after long standing a dull ache in the calf of the leg or pain at the knee, hip, and particularly in the lumbar region, symptoms more common in women than in men; or after overexertion a momentary sharp pain radiating from the point of weakness; thus the patient often dates the history of his trouble from a long walk or other form of overwork. After a time the patient may become aware that he is accommodating his habits to his feet; he rides when he once walked; he sits when he once stood; he no longer runs up or down stairs or jumps off the street-car. His feet have lost their spring, as he expresses it, which means that the foot is no longer supported and controlled by muscular activity and is no longer used as a lever. Not infrequently early symptoms are pain and sensitiveness at the center of the heel, explained in part by the jarring heel walk, which is always assumed when the foot is weak, and in part by the strain upon the attachments of the deep plantar ligaments. The patient may complain that he cannot buy comfortable shoes; the reason is that the weak foot under use is changed in shape, so that the shoe that was comfortable in the morning compresses the foot painfully at night; thus increasing discomfort from corns, bunions, enlarged great toe-joints and deformities of the toes is experienced. Coldness and numbness, congestion and increased perspiration, caused by the impaired circulation and weakness, are common symptoms in this class of cases. Actual pain is, as a rule, felt only when the foot is in use; it ceases under temporary rest or relief from disproportionate work, and it is this remittance of symptoms, together with the fact that the discomfort is usually more marked in damp weather that leads so often to the mistaken diagnosis of rheumatism.

The foot is weak and vulnerable; the patient now recognizes that he has what he speaks of as a weak ankle, or sprain, or gout, or rheumatism, but if he has accommodated himself to the weakness but little discomfort is experienced. In many instances such relief or accommodation is impossible, and it is therefore among the working class that one oftener sees rapid development of the disability and deformity. The range of motion becomes more and more restricted; the habitual attitude, at first exaggerated to deformity only under the influence of the weight of the body, remains as a persistent displacement. The weak and dislocated foot is subjected to constant injury, to what may be likened to a succession of slight sprains, so that local congestion, sensitiveness, and swelling may appear, together with muscular spasm, rigidity, and pain on passive motion. Because of this stiffness of the foot, which cannot accommodate itself to inequalities of the surface, the patient dreads to cross a rough pavement, for every misstep causes discomfort.

Another symptom, the discomfort felt in changing from a position of rest to activity, which is usually present in slight degree at every stage, now becomes more prominent. The patient, after sitting or

on rising in the morning, is unable to walk, but staggers or limps for several minutes, a symptom explained by the fact that when the foot is at rest there is a certain relaxation of the tension that has become habitual. The local sensitiveness and muscular spasm are increased by use, so that the patient may have difficulty in removing the shoe at night, and the symptoms relieved by the rest of Sunday become progressively worse during the week. The pain and discomfort are more general in character, and are often referred to the dorsum of the foot, representing muscular tension and contraction and to the ankle where the external malleolus is grinding out a facet in the projecting os calcis. The patient may now complain of discomfort in the feet and cramps in the legs, even when in bed, and the weakness, awkwardness, and even mental depression may be so noticeable that the case is sometimes mistaken for serious disease of the nervous system.

The appearance of such a foot has already been described, and the effect of the deformity on its functions should be evident. The gait is slouchy, what has been spoken of as the pedestal walk; the feet are simply pushed by one another, in the attitude of eversion, the knees are slightly flexed, and the weight is borne entirely upon the posterior segment of the foot. The muscles have atrophied, the foot is cold and congested from its continued inactivity, and it is usually bathed in perspiration. A certain range of motion remains at the ankle-joint, but adduction is absolutely restricted by the shortened and spasmodically contracted muscles on the outer and upper surface. This type represents, of course, only the severe variety that is more likely to be seen in hospital than in private practice; and it would seem, were it not for the evidence to the contrary, which the histories of the patients present, that the nature of the trouble must be recognized at a glance. But in the milder and earlier cases the diagnosis is not always so easily made.

Diagnosis.—In all cases of suspected weakness of the foot a thorough and orderly examination should be made, not only of its appearance, but also of its functional ability. Such an examination is not merely for the purpose of diagnosis, but in order that the degree and character of the temporary or permanent changes in structure and function may be properly estimated.

Attitudes.—One begins the examination by noting the manner of standing and walking. The heel walk, the exaggerated turning out of the feet, the slouchy gait in which the leg is never completely extended, in which the power of the calf muscle is not applied, and in which the essential postures of the foot are disused, are all elements of weakness that should be corrected whether they cause symptoms or not.

Distribution of Weight and Strain.—The distribution of the weight of the body and the habitual use of the foot are often made evident by examining the worn shoe. If it is bulged inward at the arch or worn away on the inner side of the sole it shows weakness (Fig. 678). The same observations are then made on the bare feet, particular

attention being paid to the line of strain or leverage; thus a line drawn down the crest of the tibia from the center of the patella, continued over the foot, should meet the interval between the second and third toes; if it falls over or inside the great toe, it shows that the foot is working at a disadvantage (Fig. 672).

Contour.—The contour of the foot should then be examined; its internal border should curve slightly outward, so that if the feet are placed side by side with the toes and heels in apposition a slight interval remains between them; if this slight concavity is replaced by a noticeable convexity when weight is borne the foot is weak (Fig. 673).

FIG. 674.—The ordinary type of weak foot in a child. The degree of abduction is indicated by the relation of the patellæ to the feet. (See Fig. 675.)

This change in contour is the earliest and sometimes the only evidence of deformity. The arch of the foot properly protected by the muscles and by proper attitude sinks but little under weight; there is a slight elasticity only, as the strain is thrown more to the inner side of the median line, and if the depression is marked it shows weakness.

Bearing Surface.—The exact amount of bearing surface may be shown by an imprint upon carbon paper or by smearing the sole with vaseline; then, as the patient stands upon a sheet of white paper, the outline of the foot should be traced so that the relative size of the imprint to that of the foot may be shown and compared with the normal standard (Fig. 680).

MEDICAL LIBRARY
BOSTON

Of all the tests this, so often used to confirm a diagnosis of weak foot, is of the least importance. As has been stated the symptoms are the result of strain and not of deformity. Thus the true flat-foot (pes planus) may be and often is entirely competent for its function.

The Range of Motion.—The balance of the foot, as shown by the range of motion, is next to be tested, for its limitation is one of the earliest signs of improper attitudes and of weakness. This range of motion varies somewhat within normal limits; it is usually greater in childhood than in adult life, greater in the slender than in the massive foot, and greater in the foot used properly than in one that is

Fig. 675.—Voluntary correction of the deformity, illustrating particularly the restoration of the arch and the normal line of strain. (See Fig. 674.)

not. The first test is applied to simple dorsal and plantar flexion; the leg must be fully extended at the knee; the line of strain must be in its normal relation, so that the foot may be neither adducted nor abducted, and the observation must be made on its outer border.

In this position the patient should be able to reflex the foot from 10 to 20 degrees less than the right angle, and to extend it from 40 to 50 degrees beyond the right angle, the range of motion being from 50 to 60 degrees (Figs. 672 and 673).

By far the most important test is that of the power of adduction or inversion of the foot, the test of the mediotarsal and subastragaloid joints, a motion in which the os calcis is drawn forward and inward

under the astragalus, while the forefoot is flexed about its head. With the leg extended and the patella in the median line the foot is turned inward as far as possible; the elevation of its inner border or inversion and the turning in of the heel are well illustrated in Fig. 655; the actual range of adduction is somewhat difficult to measure, but it is about 30 degrees. Even the mild and early cases of weak foot usually show some limitation of this most important motion, and in many instances it is completely lost, the patient turning the entire limb in the effort to adduct the foot. The less important motion of abduction may be tested also (Fig. 656); its range is about half that of adduction, so, also, the range of inversion of the sole is nearly twice as great as that of eversion of the sole. In other words, the internal border of the foot can be raised twice as far from the floor as can the external border. The range of passive motion is then tested by pushing the foot in all directions. The range of dorsal flexion is from 5 to 10 degrees beyond that of voluntary motion, while passive extension, so far as it applies to the ankle-joint, is about the same as the voluntary, although the forefoot may be bent downward still farther at the mediotarsal joint. It must be borne in mind that dorsal flexion, especially in women, is a comparatively disused movement. Consequently the inability to dorsiflex the foot beyond a right angle at command might be mistaken for structural shortening, because if forced it causes discomfort in the calf. This limitation, however, will in most instances disappear under instruction and practice and operative elongation is very rarely indicated except in cases of advanced deformity. The limit of passive adduction is considerably beyond that of the voluntary range.[1]

Passive motion serves several purposes; contrasted with the range of voluntary motion it shows the habitual use of the foot, since the motion least used is most limited. It also makes evident the slight restriction of motion and the presence of local sensitiveness, which, even in early cases, are usually present. Thus, if pressure is made just in front of and below the internal malleolus at the astragalonavicular junction, and if at the same time the foot is forcibly adducted, the patient will complain of pain at the point of pressure and of a feeling of constriction and tension about the dorsum of the foot before the normal limit of motion is reached. When the foot is dorsiflexed the plantar fascia is put upon the stretch, and its condition may be noted,

[1] As adduction and inversion and abduction and eversion are always combined, one term is used to signify the movement inward or outward; thus, inversion means adduction; abduction implies eversion; strictly speaking, however, adduction and abduction signify the relation of the foot to the middle line of the limb, while inversion and eversion refer primarily to the relation of the sole to the base. A fixed attitude of adduction and inversion is called varus; a fixed attitude of abduction and eversion is called valgus. Varus and valgus signify, therefore, deformity. Thus the term valgus, although it may be properly applied to designate the deformity of weak foot, is usually reserved for the more extreme and persistent distortion of talipes. The term supination and pronation are sometimes used for inversion and eversion and the terms pronated foot to designate the weak or flat-foot. As pronation in its general sense signifies an attitude of activity it cannot as correctly describe a deformity which is essentially one of inactivity as either eversion or abduction.

for a contracted and sensitive plantar fascia may cause sufficient discomfort to induce improper attitudes and thus it may predispose to further disability.

Varieties.—This method of examination will demonstrate the disability, and the secondary changes in the mechanism, which must be overcome before a cure can be accomplished. By it one may recognize several grades of weak foot:

1. The normal foot improperly used, as shown by the manner of standing and walking (Fig. 651).

2. The foot which because of laxity of ligaments or insufficient muscular support is forced by the weight of the body into an attitude of deformity; that is, in which the foot under weight falls into an abnormal attitude of abduction in its relation to the leg, as evidenced by the inward projection of its inner border and by the over-hanging internal malleolus. As a rule there is sufficient laxity of ligaments to permit depression of the arch, as shown by an imprint, but in other instances, although the arch seems lower because of the characteristic attitude of abduction, in which the leg, as it were, overhangs the foot, yet the imprint shows that there is no increase in the area of bearing surface. Indeed, if the eversion is sufficient to raise the outer border of the foot, this may be even smaller than normal; thus an individual may be disabled by so-called flat-foot whose arch is actually exaggerated (Fig. 673).

3. The weak foot, which shows typical deformity under use and in which the range of voluntary motion is somewhat limited, particularly in the direction of plantar flexion and adduction. Forced motion causes discomfort and pain, indicating certain accommodative changes in structure, which are not apparent when the foot is not in use (Fig. 674).

4. The foot which presents typical and persistent deformity, whether it is in use or not, and in which the range of both voluntary and passive motion is much restricted. In all of these varieties the improper functional use of the foot, particularly the loss of active leverage, is very evident when the patient walks (Fig. 678).

Limitation of Motion and Muscular Spasm.—Limitation of motion is caused by the changes in structure in accommodation to functional use. These are first evident in the muscles, then in the ligaments, and, finally, in the articular surfaces of the bones. Added to this underlying limitation of motion there is usually a certain degree of muscular spasm, which varies in grade with the local congestion, irritation, and inflammation of the joints and tissues. In the quiescent flat-foot it may be absent, but on renewed injury or overwork of the weak structure it again appears. It depends also upon the irritable condition of the overworked and contracted abductor muscles, practically the only group which retains functional power; thus the spasm, as has been stated in describing the severe and painful type of weak foot, is greater after the day's use and relaxes somewhat during the night. The degree of muscular spasm or stiffness corre-

sponds with the intensity of the symptoms, but by no means with the depression of the arch or with the duration of the deformity.

Extreme Types of Weak Foot.—1. **Persistent Abduction.**—In one type of deformity the foot is turned outward and upward. It may be everted to such an extent that practically the weight is borne upon the heel and the ball of the great toe. The entire foot is simply fixed in an attitude of extreme abduction and dorsal flexion by the spasm and contraction of the dorsal flexors and abductors, so that the leg must be bent at the knee and inclined forward to bring the sole to the ground. Such extreme cases are uncommon. They are often the direct result of injury, so-called chronic sprain. Less extreme examples of this class are very common. The foot is simply turned to one side (valgus) and the arch appears to be depressed because of the attitude, whereas it may be in reality exaggerated in depth.

2. **Pes Planus.**—As has been stated already, and as is well known, there is a type of true painless flat-foot sometimes called pes planus, in which the flatness of the foot is more noticeable than the other components of the deformity that have been described. This is probably the result of inherited laxity of ligaments or of rhachitis or other form of acquired weakness in early life, so that a normal arch was never present. Such a foot controlled by normal muscles may be strong and efficient, but it is, nevertheless, deformed, and it is doubtful if its possessor ever could attain the grace and elasticity of gait possible under normal conditions. It is said, also, that a low arch is normal in certain races, for example, the negro, but the American negro is certainly not exempt from the pain and disability incidental to the broken-down foot.

It is evident, of course, that the breaking down of a properly shaped foot, supported by normal ligaments, will be attended by greater pain and greater disability than of one in which the arch was originally low and of which the ligaments were weak, because it is during the progression of the deformity and particularly in its early stages, that such symptoms are most prominent. When the bones of the arch rest upon the ground or when final stability has become assured, pain may cease, and permanent accommodation to the new conditions may increase the ability of the deformed member. Such an outcome might be quickly accomplished in the foot originally flat, while in the other instance the symptoms, although remitting from time to time, might continue indefinitely.

The abducted foot, in which there is no depression of the arch, and the simple flat-foot, in which the element of abduction is less prominent, represent the two extremes of weak foot. In the majority of cases the two are combined in varying degree.

One may recognize, then, three types of weak foot which may be classified according to the more noticeable deformity as

1. Valgus, or abduction.
2. Valgoplanus, or abduction and depression.
3. Planovalgus, or depression and abduction.

This distinction is of some importance from the stand-point of prognosis, at least in the adolescent and adult cases, as the prospect of anatomical cure corresponds to the order of classification.

Weak Foot in Childhood.—There can be no doubt that in many instances the origin of the weak foot may be traced to early childhood. Certainly, deformities and improper attitudes are very common at this period, and it is much more likely that they are ingrown than outgrown. Actual pain from the weak foot is unusual at this age. The child may complain of fatigue and may be weak and awkward, but it is usually because of the very evident deformity rather than because of symptoms that advice is asked. In these cases, as in every case, the habitual attitudes and use of the feet are of the first importance.

Fig. 676.—Weak feet and slight knock-knees often associated in childhood.

Out-toeing and In-toeing as Symptoms.—One of the most common of the improper postures of civilization is that of exaggerated outward rotation of the limbs (turning outward of the feet), which is not only an ungraceful attitude, but a direct cause of weakness as well. The opposite attitude of inward rotation, the so-called "pigeon-toed" walk, is most offensive to relatives and friends, and it is for correction of the attitude that the child may be brought for treatment. The attitude is, in many instances, a sign of the weak foot, for on examination the bulging on the inner side, the inward rotation of the leg in its relation to the foot, and the depressed arch show very plainly that it is the foot and not the attitude that requires treatment; in fact, the attitude is, in this class of cases, really a safeguard against increasing

deformity, which will correct itself when its cause is removed.[1] Particular emphasis is laid upon this point, which is very generally overlooked, because the routine treatment of the "pigeon-toes" in these cases might be the cause of direct harm.

Weak Ankles.—"Weak ankle" is a term popularly applied to the weak foot of childhood, in which the foot is in a position of valgus when in use, so that the sole of the shoe is worn away on its inner side. Weak ankles are very common in young children and are often one of the effects of general weakness due to defective assimilation. At this age the foot is, in addition, usually flat (Fig. 676), but in the valgus or weak ankle of later years the arch is often found to be of normal height when the foot is placed in proper relation to the leg.

Outgrown Joints.—In older children "outgrown" joints often attract the mother's attention; the internal malleoli appear prominent because of the position of valgus, or because of the turning out of the feet the malleoli may strike against one another, "interfere," and thus there may be an actual hypertrophy of the tissues over the projecting bones from local irritation.

Another type is the long, slender abducted foot, in which the inward bulging at the mediotarsal joint is indicated by the point of wear in the leather of the shoe (Fig. 673).

In the weak foot of childhood, although restriction of voluntary and passive motion may be present, there are, as a rule, but little local sensitiveness and muscular spasm, and, as has been said, but little actual pain, for the reason that the weak foot in childhood is not subjected to the strain of constant occupation or to the burden of an overweighted body. There is also another important difference: the foot of the adult is obliged to bear greater strain than any other part, and although normal in structure it may be overworked, so that in many instances the weakness of the foot is the only disability. But in childhood, when such exciting causes are absent, a weak foot is very often a local indication of general weakness and loss of tone.

Irregular Forms of Weak Feet.—Occasionally the apex of the inward bulging and deformity is not at the mediotarsal joint, but anterior to it in the cuneiform region. In such cases the internal cuneiform bone may be enlarged and sensitive to pressure.

Another form is the combination of a plantar flexed toe with a depressed arch (Fig. 679). Extreme deformity of this class is usually congenital. A milder type is not uncommon. (See Hallux Rigidus.) A third variety is eversion at the mediotarsal region combined with marked adduction of the metatarsus. This is a congenital deformity. (See Metatarsus Varus.)

Weak Feet and Deformity of the Legs.—In childhood weak feet are often seen in combination with slight knock-knees (Fig. 676), while in later life knock-knee usually induces in compensation the opposite

[1] Inward rotation of the limb, an attitude controlled by the muscles at the hip, and inversion of the foot are usually confounded, as are eversion and outward rotation. Inward rotation of the limb (pigeon-toe) and eversion of the foot (weak foot) are often combined in childhood.

attitude of adduction. (See Knock-knee.) Bow-leg in childhood is often accompanied by slight adduction of the feet, but later there is usually a certain degree of compensatory eversion, although it does not, as a rule, cause discomfort.

FIG. 677.—Congenital flat-foot. Rigid deformity of an extreme type, illustrating the component abduction and eversion.

FIG. 678.—Flat-foot, illustrating extreme deformity in childhood.

FIG. 679.—Hammer-toe flat-foot.

General Weakness.—The direct effects of the weak and painful foot have been described in detail. It must be borne in mind that the feet support the body, and that an insecure support affects the entire mechanism. General functional weakness and awkwardness, the flat

chest, round shoulders, or other curvatures of the spine, are often observed as accompaniments of effects of weak feet. Thus, as a rule, the systematic treatment of any form of postural weakness must include the treatment of the feet as well.

Review.—The disability and deformity of the weak or so-called flat-foot are caused by disproportion between the resistance of the foot and the weight and strain to which it is subjected.

The foot may be weakened by injury or disease; it may be overburdened by the body weight, or overstrained by laborious occupation, or the broken-down foot may be simply one indication of general bodily weakness. It is unnecessary to enumerate all the various factors that singly or combined lead to this disability. It may be stated, however, that in adult life the weak foot is in many or most instances the only disability that demands treatment. Its most constant predisposing causes are the direct injury caused by improper shoes and the mechanical disadvantages to which it is subjected by the assumption of improper attitudes.

All weak or flat feet are mechanically weak, but all weak feet are by no means painful feet. Pain, the symptom of overstrain or injury, bears no definite relation to the degree of deformity.

In certain instances persistent abduction of the foot may be accompanied by exaggeration of the arch; in others, the flattening of the arch may be the most noticeable deformity, but in most cases the two are combined in varying degree. And as each deformity is an evidence of weakness, it seems hardly necessary to make a radical distinction between the two, except as regards prognosis. For the abducted foot in which the arch is intact is almost always an acquired deformity of short duration, whereas in the case of the foot in which the arch is obliterated the deformity usually dates from early childhood, and it is therefore less amenable to treatment as far as perfect cure is concerned.

Treatment.—The principles of the treatment which lead to the permanent cure of the weak and deformed foot are very simple, but the application varies somewhat according to the grade and duration of the deformity. The object of treatment is to so change the weak foot that it may conform not only in contour but in habitual attitudes and in power of voluntary motion to the normal foot, because complete cure is impossible unless normal function is regained. The first step must be, therefore, to make passive motion free and painless to the normal limit. In other words, the obstructions to the motion of the mechanism must be removed before the power can be properly applied; for the increase of muscular strength and ability, on which ultimate cure depends, is not possible while motion is restrained by deformity or by pain or by adhesions or contractions.

The weak foot, because of inefficient ligaments and muscles unable to hold itself in proper position, must be supported until regenerative changes have taken place in its structure. Such support is necessary to retain the joints in normal position, and to hold the weight in

MEDICAL LIBRARY OF THE BOSTON CITY HOSPITAL

proper relation to the foot, otherwise normal function is impossible. When these essentials are provided the patient may cure himself by the proper functional use of the foot and by the avoidance of attitudes that place it at a disadvantage.

It may be well to describe, first, the treatment that must be applied to all classes of weak foot in which a cure is to be attempted and which by itself is sufficient in the milder types, before calling attention to the modifications that may be necessary in more advanced cases.

The Shoe.—In all cases it will be necessary to provide the patient with a proper shoe, for the shoe is usually the direct cause of the minor deformities, and indirectly, in many instances, of more serious disability. Indeed, most of the deformities and disabilities of the foot are incidental to civilization, and are therefore confined to the shoe-wearing people. The direct effect of the ordinary shoe is to lessen the area and the adjustability of the fulcrum by cramping the toes. Indirectly it causes deformities — corns, bunions and the like — which serve to make active movement or leverage painful, so that it is replaced by the massive attitude.

FIG. 680.—The proper relation of the sole of the shoe to the shape of the foot: *A*, outline of sole; *B*, outline of foot; *C*, imprint of foot. This figure appeared in the first edition of this book in 1901 and the type has now been generally adopted.

The proper shoe should contain sufficient space for the independent movements of the toes. This motion is illustrated in the walk of the barefoot child. As the weight falls on the foot the toes spread, and as the body is raised on the foot they contract. The important leverage action of the great toe and support afforded by it to the arch of the foot have been mentioned already. The shape of the sole should correspond to the shape of the foot and the heel should be broad and low. It will be noted that the front of the sole of the shoe in Fig. 680 appears to be adducted. Such a shoe aids in preventing abduction, and it is therefore an important adjunct to the brace in restraining deformity.

Raising the Inner Border of the Shoe.—A simple expedient in the treatment of the weak foot and an aid in balancing it properly is to make the inner border of the sole and heel of the shoe slightly thicker, one-quarter of an inch, in order to throw the weight toward the outer side of the foot. This is of special importance in the treatment of the

slighter degrees of what is known as weak ankle, and it is always of service in the treatment of any grade of weak foot.

Attitudes.—The patient's attention is called to the significance of the bulging on the inner side of the foot (Fig. 674) and how this may be prevented by throwing the weight on the outer side of the foot (Fig. 654) and by holding the feet parallel with one another in standing and by crossing the feet in the sitting posture and by the assumption of the proper attitude in walking (Fig. 650). The importance of leverage is shown him, that he must try to press down the sole of the shoe

FIG. 681.—The tip-toe exercise, raising the body on the adducted feet. (See Fig. 682.)

FIG. 682.—The tip-toe exercise resting on the outer borders of the feet. (See Fig. 681.)

with his toes, particularly with the great toe, and employ the active lift to the calf muscles by fully extending the limb and raising the body on the foot from time to time (Fig. 650). Finally, in standing, he must avoid long continuance in one position, especially the passive posture, which, even in the normal subject, simulates the attitude and deformity of weak foot. In short, he must be instructed in the mechanics of the foot and taught how the weak foot may be protected as well as strengthened.

Exercises.—It is important, also, to demonstrate to the patient the normal range of motion of the foot, motion which, if restricted, must

be regained by voluntary and passive exercises. Voluntary exercise should be devoted to strengthening the adductors and plantar flexors; thus the foot should be adducted and inverted, then dorsiflexed in the attitude of slight adduction (Fig. 652) over and over again at every opportunity. Tip-toe exercises are especially useful; the patient, placing the feet side by side in an attitude of slight adduction, raises the body on the toes to the extreme limit, the limbs being fully extended at the knees, then sinking slowly, resting the weight on the outer borders of the feet, in the attitude of marked varus, twenty to one hundred times. This exercise is somewhat difficult, and it cannot be carried out properly if there is any limitation of motion or sensitiveness at the mediotarsal joints. Another is to place the feet side by side and to increase the interval between them, *i. e.*, to make their internal borders concave by rotating the legs outward without raising the sole from the floor. Crossing the feet throws them into adduction and this posture should be assumed when the patient is sitting. The best of all exercises is, however, the proper walk, in which the leverage power of the foot is employed and in which it passes through the proper alternation of postures (Fig. 650). Treatment by massage and special gymnastic exercises is, of course, of benefit if the patient can command it, although by no means essential to the cure.

Support.—In many instances the simple treatment that has been outlined is all that is required, but in the majority of cases the patient is not able to prevent deformity voluntarily; consequently a support is necessary to hold the foot in proper position and to relieve discomfort. It is usually necessary in the treatment of the weak foot of childhood because one cannot command the aid of the patient.

In selecting a support for the weak foot the nature of the deformity should be borne in mind; that the acquired flat-foot, for example, is not a direct breaking down of the arch, as is usually taught, but a lateral deviation and sinking—a compound deformity, as has been already described (Fig. 669). Thus a brace to be efficient must hold the foot laterally as well as support the arch. But it must not prevent the normal motions of the foot, and thus interfere with the increase of muscular strength and ability, on which ultimate cure depends.

The supports that are ordinarily used for flat-foot do not fulfil the conditions; the pads, springs, and plates placed beneath the arch are intended to support it by direct pressure without regard to the abduction; they are usually ill-fitting, and are often of such length and shape as to splint the foot and thus to restrict its motion. Leg braces which control the valgus do not often hold the foot accurately, and their weight and unsightliness are fatal objections to their use, especially in the early cases, in which prevention of subsequent deformity is of such importance.

A brace should never be applied to a deformed and rigid foot because it cannot adapt itself to the support; the spasm and rigidity should be first relieved by the preliminary treatment which will be described in the consideration of this class of cases.

The Construction of the Brace.—To properly construct a brace to meet these conditions it is necessary to provide the mechanic with a plaster cast of the foot, taken in the attitude in which one wishes to support it. Such a model may be easily and quickly made in the following manner:

FIG. 683.—The attitude in which the plaster cast should be taken. This attitude, in which the weight rests upon the outer border, is important, because in it the foot assumes the best possible contour. If the sole is simply pressed downward into the plaster cream, the ordinary method of making the model, the shape will be found to be quite different from that taken in the manner illustrated.

The Plaster Cast.—Seat the patient in a chair; in front of him place another, preferably a rocking chair, somewhat less in height; on it lay a thick pad of cotton-batting and cover it with a square of cotton cloth. Put about a pint of cold water into a basin and sprinkle

FIG 684.—A cast marked for the mechanic. The internal flange rises slightly above the astragalo-navicular joint. See Fig. 687.

plaster of Paris on the surface until it does not readily sink to the bottom; then stir. When the mixture is of the consistency of very thick cream pour it upon the cloth. The patient's knee is then flexed, and the outer side of the foot, previously rubbed with talcum powder,

is allowed to sink into the plaster, and, the borders of the cloth being raised, the plaster is pressed against the foot until rather more than half is covered. The forefoot should be placed on the higher side of the

FIG. 685.—The lower half of the plaster mould.

FIG. 686.—The plaster mould completed.

chair seat, the object of the inclined plane and the lower surface being to utilize the force of gravity and thus to hold the foot in slight adduction. The foot should be at an angle with the leg, corresponding to its usual position in the shoe, that is, slightly plantar flexed, and the sole should be in the plane perpendicular to the seat of the chair; the toes need not be included (Fig. 685). As soon as the plaster is hard its upper surface is coated with vaseline or talcum powder and the remainder of the foot is covered with plaster; the two halves are then removed, dusted with talcum powder, bound together, and filled with the plaster cream. In a few moments the outer shell may be removed, and one has a reproduction of the foot, which, when properly made, should stand upright without inclination to one side or the other (Fig. 684).

In most instances it will be of advantage to deepen in the plaster model the inner and outer segments of the arch, in order that the arch of the brace may be slightly exaggerated, especially at the heel, so that the depression of the anterior extremity of the os calcis may be

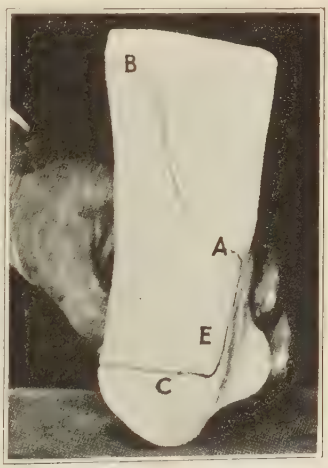

FIG. 587.—The outline of the sole part of the brace. *B*, The anterior extremity behind the bearing surface of the great toe; *C*, the posterior border just in front of the bearing surface of the heel; *D*, the anterior extremity of the outer flange just behind the tuberosity of the fifth metatarsal bone; *E*, the calcaneo-cuboid joint.

prevented. If the outer border of the case is flattened by pressure a little plaster should be added to approximate its normal rounded contour.

The Brace.—Upon the model the outline of the brace is drawn as illustrated in the diagrams. The best sheet steel, 18- to 20-gauge, cut after the pattern is molded upon it and tempered, so that as it is applied for the purpose of preventing deformity, it may be practically unyielding to the weight of the body.

It will be noticed that the brace clasps the weak part of the foot and holds it together; the broad internal upright portion (Fig. 684) covers and protects the astragalo-navicular junction, rising well above the navicular; the external arm covers the calcaneocuboid junction and the outer aspect of the foot to a height sufficient to hold the foot securely (Fig. 687). The sole part provides a firm, comfortable support, yet, reaching only from the center of the heel to just behind the ball of the great toe, it does not restrain the normal motions of the foot. The brace may be nickel-plated, or preferably galvanized, which makes a more durable covering. As it is modeled

Fig. 688.—The brace showing the contour and leverage.

on the foot, it finds and holds its own place in the shoe, so that no attachment is required; thus it may be changed from one shoe to another. Not only does it hold the foot laterally and from beneath, but there is an element of suggestiveness in the slight leverage action which is very important, and which is a distinctive feature of this brace as contrasted with other supports (Fig. 688).

The Positive Action of a Proper Brace.—The patient, instructed to throw his weight upon the outer side of the foot and wearing the shoe which has been tilted in the same direction by thickening the inner border of the sole and heel, presses down the external arm and thus lifts the internal flange against the inner side of the foot, which is instinctively drawn away from the pressure and thus toward the normal contour. He no longer turns the feet outward in walking, because this causes positive discomfort, and he is not likely to assume the passive attitude because of the suggestive lateral pressure of the support. With the foot held in the normal attitude the patient may again walk with the proper spring; thus the brace itself becomes a positive aid in the phy-

siological cure as contrasted with sole-plates and stiffened shoes. It is important, also, that a shoe of proper shape, as shown in the diagram (Fig. 680), be worn, as it aids the brace in holding the foot in an attitude of slight adduction.

The shape of the brace, in general like that of the diagram, is modified in certain cases; for instance, the entire internal aspect of the foot may be weak and must be covered by the internal flange. In very heavy subjects the sole portion must be made larger, although this is a disadvantage, as it lessens the leverage action; other slight modifications may be necessary in special cases. If any portion of the rim of the brace causes discomfort, the edge may be turned away slightly at the point of pressure by a wrench. After a few days the patient no longer notices the constraint of the brace, and as its presence in the shoe is not evident, it may be worn indefinitely. Steel is the lightest and strongest, and, on the whole, the most satisfactory material for the brace. In hospital practice heavier material is used and the braces are galvanized. This will prevent rusting if the braces are removed from the shoe and wiped dry at night.[1]

FIG. 689.—The combination foot brace, providing support for the metatarsal as well as the longitudinal arch.

Support is usually necessary for from three months to a year or longer, according to the condition of the patient and the strain to which the feet are subjected. The brace, accurately made and adjusted under suitable conditions, causes no more pressure or discomfort than a well-made shoe, for its principle is quite different from that of the ordinary supports that are in common use, to which this objection has been made. This brace supports the arch primarily by preventing abduction, consequently its pressure is first felt upon the lateral aspect of the foot, a pressure that the patient can relieve by improving his attitude. The brace should afford support when necessary, and at all times suggest and enforce a proper attitude; it is, however, but one of the essential factors in the general scheme of treatment. The ordinary form of brace in all its modifications conforms to the shape of an inner sole (Fig. 690). As it supports the sole of the foot, and by the

[1] In many instances there is a rapid improvement in the shape of the foot under treatment, and it is often advisable to make a second cast within a few months, in order that the brace may conform to the improved contour.

elevation of its inner border tends to throw the weight more toward the outer side, it is a useful aid in treatment; but, providing no lateral support, it cannot prevent the inward bulging of the foot, which is the most important element of the deformity, and as compared to a positive brace which prevents its primary deformity it is therefore an ineffective apparatus.

In the treatment of children the nurse should push the feet inward and upward to the normal limit of adduction and dorsal flexion at morning and at night, until the child has regained the normal muscular power and ability. Special gymnastics and massage are always desirable, and they may be necessary in certain cases. Bicycling may be cited as one of the best, and roller-skating as one of the worst exercises for the weak foot. A year is about the time required for a cure of the weak foot in childhood, although attention to the shoes and to the attitudes must be continued indefinitely.



FIG. 690.—The typical or negative sole plate ordinarily used in the treatment of weak foot. (After Bradford and Lovett.)

THE RIGID WEAK FOOT.

One may now contrast with the mild types of weakness that have been described the cases of extreme deformity in which the symptoms are disabling and in which the foot is fixed in the deformed position by muscular spasm and by secondary changes in its structure. Such cases, often considered hopeless as regards a cure or even relief, are in reality the most satisfactory from the remedial stand-point, and in no other type of painful deformity can so much be accomplished by rational treatment as in this class. The deformity must be considered as a dislocation in which the astragalus has slipped downward and inward from off the os calcis, which, in turn, is tipped downward and inward and into a position of valgus. The remainder of the foot is turned outward, so that the relation of the leg and the forefoot is entirely changed; in fact, the forefoot is almost entirely disused (Fig. 678).

Corresponding to the duration of the disability, one finds accommodative changes in the soft parts and in the bones, but such changes are by no means as marked as those recorded in the reports of autopsies which have been made in cases of advanced and irremediable deformity. In fact, by far the greater number of patients are young adults in whom the extreme deformity is of comparatively short duration, and in whom complete cure is possible.

Treatment.—In the treatment of such a condition one must first reduce the dislocation and overcome the obstacles that contracted muscles and ligaments may offer to free and normal motion; then

MEDICAL LIBRARY
BOSTON CITY HOSPITAL

rest must be assured to the injured and congested parts in order to relieve the patient from the pain from which he has suffered so long.

Forcible Overcorrection.—By far the most effective treatment is forcible overcorrection of the deformity, under anesthesia. When the patient is under the influence of the anesthetic the muscular spasm relaxes, and it will be seen that this accounts for about half of the restriction of motion, the remainder being caused by the adaptive changes that have been mentioned. The object of the operation is to overcome the residual obstruction, and to assure the patient against a relapse, by fixing the foot for a sufficient time in the position of extreme adduction and supination, the attitude directly opposed to that which has become habitual.

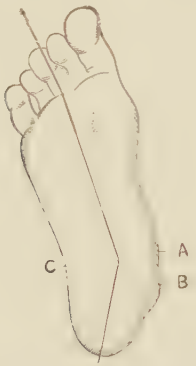

FIG. 691.—The deformed foot before operation. *A*, the projection of the displaced astragalus and navicular; *B*, the inner malleolus; *C*, the mediotarsal joint, showing the outward displacement before, the inward rotation behind, this point.

FIG. 692.—The overcorrected foot, showing the reversal of the lines of displacement. (See Fig. 691.)

This is the object of forcible overcorrection as the first step in the systematic repair of the disabled mechanism; its principle must not be confounded with forcible correction carried out with the object of simply remolding the arch of the foot, or in which the correction of the deformity is the only object in view.

One first extends the foot forcibly, then flexes it to the normal limit, then abducts and adducts, the different motions being carried out over and over until the rigid foot has become perfectly flexible. In cases of long standing it is often necessary to draw the patient to the end of the table, so that the foot may be taken between the knees, in order to supply the required force by the thigh muscles. This forcible manipulation is accompanied by the audible breaking of adhesions, and in favorable cases by complete disappearance of the deformity. In certain instances it will be necessary to divide the tendo Achillis, when, for example, the range of dorsal flexion is limited by resistant accommodative shortening of the calf muscles, or when

there has been very great pain and sensitiveness at the mediotarsal joint, and it is desired to remove the strain of leverage completely; traumatic cases come especially under this head. Occasionally also in resistant cases division of the peroneal tendons may be advisable. Tenotomy has one great advantage: it necessitates longer fixation in the plaster support, and gives the patient the benefit of rest, and the opportunity for prolonged after-treatment. When the passive range of motion has been regained, the foot is turned downward, then inward and upward into the position of extreme varus. By this manipulation the os calcis is drawn under the astragalus and thrown into the supinated position, and the navicular is flexed about and under the head of the astragalus, which is then lifted to the limit of normal flexion. The attempt is always made to bring the extreme outer border of the inverted foot up to a right angle with the leg, which is the limit of normal flexion in this attitude. The foot, very thickly padded with cotton, especially between and about the toes, is then fixed in this posture of varus by a firm plaster-of-Paris bandage extending to the knee (Fig. 693). Surprisingly little discomfort, considering the force that it is sometimes necessary to apply, is experienced after the operation. The familiar and often intense pain, from which the patient has suffered so long, is entirely relieved by the correction of the deformity; there is often a sense of tension about the outer side of the ankle and dorsum of the foot, but this is not, as a rule, of long duration.

Fig. 693.—The forcible overcorrection of flat-foot. The proper position in the plaster bandage.

Functional Use in the Overcorrected Attitude.—As soon as possible, often on the following day, the patient is encouraged to stand and walk, bearing his weight on the foot. Weight-bearing serves to still further overcorrect the deformity and to accustom the patient to a posture entirely different from that so long assumed. Meanwhile the contracted tissues on the outer side become thoroughly outstretched; the weakened ligaments and muscles on the inner side are relaxed, and the local irritation rapidly subsides under the rest from the constant injury to which the foot has been subjected.

The patient is not confined to the bed or house, although if both feet are in plaster bandages, crutches are, of course, necessary. The time that the foot should remain in the overcorrected position depends

upon the duration of the deformity and the severity of the symptoms, from two to six weeks, the usual time being about four weeks. At the end of about three weeks, or whenever the patient can support the weight on the plaster support, without a sensation of discomfort, it is removed; the foot is placed in the normal attitude and a cast is taken for the brace (Fig. 683). Immediately after, the foot is returned to the former position and the plaster bandage is reapplied. When the brace is ready the plaster support is finally removed; the foot is now in good position, and in many instances the arch is exaggerated in depth. For the first few days prolonged soaking in hot water or the use of the hot-air bath, with subsequent massage at intervals during the day, will be found useful in overcoming the swelling and sensitiveness that may remain. It is always insisted that a new shoe of the proper pattern shall be obtained, the sole and heel of which are raised a quarter of an inch on the inner border to aid in the balancing of the weak foot. The brace is then applied, and the patient is never allowed to walk without its support. When the shoe is removed at night, he is instructed to turn the toes in and to bear the weight on the outer side of the foot until it has regained its strength; in other words, the deformity is never allowed to recur.

Systematic Manipulation.—Systematic treatment is then begun by the surgeon and the patient, with the object of restoring free and painless passive movement in all directions. This movement, which has been so long restrained by deformity, cannot be regained without effort, and during this critical stage, treatment must be supervised by the surgeon himself; if he trusts to the patient or to his friends a cure is out of the question. At least once a day the full range of motion must be carried out to the normal limit. Three motions—abduction, flexion, and extension—are usually free and painless; but the fourth, that of adduction, is almost invariably resisted by the same quality of muscular resistance that was present before the operation. The most effective method of overcoming this resistance is as follows: The patient being seated in a chair, the surgeon sits or stands before him. Let us suppose that the right foot is to be adducted, or, as the patient expresses it, twisted. The surgeon places the foot between his knees; his right hand encircles the heel, the fingers grasping the projecting os calcis and tendo Achillis; the base of the palm lies against the mediotarsal joint on the inner and inferior aspect of the foot; the left hand grasps the outer side of the forefoot and toes; then, by steady pressure of the high muscles, the forefoot is forced downward and inward (adducted and inverted) (Fig. 694) over the fulcrum formed by the projecting palm, which lies upon the right knee, the fingers holding the heel steadily in place. This inward twisting is at first resisted by voluntary and involuntary muscular spasm, which gradually gives way under steady pressure. When the limit of adduction has been reached, the foot is held firmly until all pain has subsided; then the patient is instructed to attempt voluntary movements while the foot is guided by the hands; in other words, the patient attempts to adduct the foot

while the surgeon supplies the power, which in all cases of this type has been lost. This passive manipulation to the extreme limit of normal adduction, plantar and dorsal flexion, is continued from day to day until there is no longer a sensation of pain or tension. For as long as there is the slightest spasm or painful restriction of passive motion, the voluntary assumption of proper attitudes is checked, and

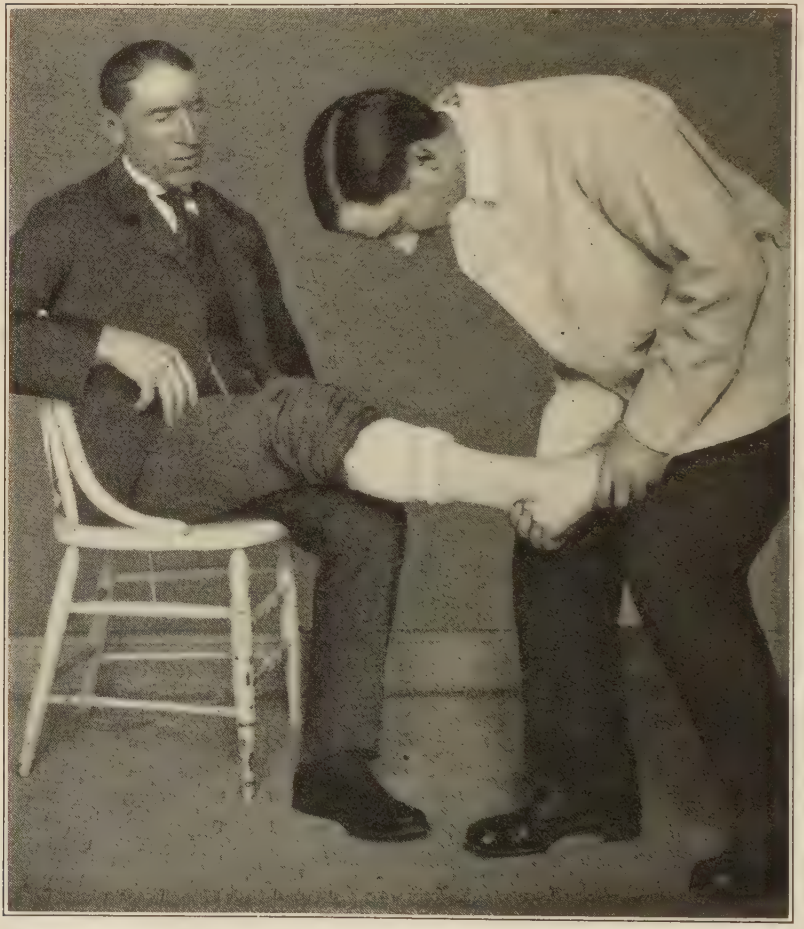

FIG. 694.—"Twisting" the foot. In these ambulatory cases plaster strapping is usually applied after the manipulation. See Fig. 696.

until this power is regained there is danger of relapse. During active treatment, therefore, the patient, by means of massage and active and passive exercises, must constantly work to one end, namely, to regain the lost power of voluntary adduction.

The time necessary to rest the feet, to overcome the local irritation and muscular spasm, to regain, in part at least, the range of passive motion, and to place the patient in the same position, as

regards a cure, as in the milder types of deformity, is from three to six weeks. Usually the patients are told that a month will be necessary, and that at the end of that time they may return to work, free from pain and from the danger of relapse, and that the feet will constantly grow stronger under the work which was before too great for their strength. The time necessary to reëducate the adductor muscles in their proper function depends, in great degree, upon the intelligence and persistence of the patient. Although in after-treatment massage and special exercises are of benefit, the essentials are very simple; they are an effective brace, a proper shoe, the passive manipulation that has been described until its object has been attained, and the proper walk, the best and easiest of exercises. Finally, one must force into the patient's understanding the method of protecting the weak foot by the alternation of strain, and by proper postures.

Other Varieties of Rigid Weak Foot.—The foot which is fixed in the abducted position without depression of the longitudinal arch is simply one variety of the rigid weak foot, which should be treated in the same manner. It may be stated, also, that a very large proportion of the so-called chronic sprains of the ankle are of this type, and that the disability will yield very readily to treatment, conducted with the purpose of restoring impaired function, in the manner that has been indicated.

In certain instances the apex of the deformity lies in front of the astragalo-navicular joint, in the navicular-cuneiform region, and the internal cuneiform bone may be enlarged and sensitive to pressure. Such cases should be treated on the same general principles as the ordinary variety.

In rare instances marked depression of the arch is accompanied by flexion contraction of the great toe, as if the result of an attempt to support the weak arch. This was described by Nicoladoni as hammer-toe flat-foot (Fig. 679). The association of painful great toe (hallux rigidus) and weak foot is mentioned elsewhere.

There are other cases in which the deformity of weak foot is complicated by chronic rheumatism, gonorrheal arthritis, or similar affections of which the evidence is seen in various joints, but in which the pain and discomfort seem to be concentrated in the feet, which are absolutely stiff and deformed. In such cases one can hardly expect a complete cure; but although the function of leverage may not be regained, still one may hope, by overcoming the deformity, to hold the weight of the body in its proper relation to the foot, so that the pain of a progressive dislocation may not be added to the pain of disease.

Between the two classes of cases, the mild and the severe, one finds every grade of deformity. All cases in which there is marked muscular spasm, local sensitiveness, and swelling require temporary rest; in many instances simply rest from functional use combined with massage; in others, rest in a plaster bandage in the adducted attitude. In the milder and ordinary class of cases the use of a brace and shoe will relieve spasm and pain, and the range of motion can usually be regained by manipulation, passive motion, and by the proper use of the foot.

Occasionally, even in childhood, one may encounter marked limitation of normal motion, particularly in dorsal flexion, caused by actual shortening of the calf muscle. This may be the accommodative adaptation to long-standing deformity; in other instances it would appear to be the result of a slight and unnoticed neuritis or anterior poliomyelitis, which has resulted in muscular inequality or even to the habitual use of high heels, and disuse of the normal range of dorsal flexion. If the contraction does not yield readily to manipulation or to mechanical stretching, forcible correction and, if necessary, tenotomy should be employed in the manner already described; for whatever may be the cause, it is again emphasized that obstruction to motion in every direction must be overcome before a complete cure is possible.

In this connection attention may be called to a theory that a very important factor in the etiology of flat-foot is primary shortening of the calf muscle. This is based apparently on the observation that, as paralysis of the calf muscles induces a hollow foot, overaction or resistance must have the opposite effect. A low arch, however, as has been explained, is not the essential feature of the weak foot, and functional cure is attained by stimulating the action of the calf and adductor muscles, not by weakening the propelling power.

Adjuncts in Treatment.—It must be apparent that in many instances the anatomical cure of the weak foot is impracticable, either because of the want of energy or opportunity on the part of the patient, or because of the local or general conditions, types familiar in outpatient practice.

FIG. 695.—The Thomas method. The shoe is tilted toward the outer side and the shank is supported. The disadvantages are the stiffening of the entire sole and the unsightly appearance.

The Thomas Treatment.—In such cases raising and strengthening the inner side of the shoe by the wedge-shaped leather sole, as used by Thomas, splints the painful foot and aids in relieving the strain. A diagonal heel of which the inner border extends forward beneath the arch is a less offensive if less effective support of the same class.

Plaster Strapping.—If the symptoms are more acute the adhesive-plaster strapping, as advocated by Cottrell and Gibney for the treatment of sprains, is often of service, although it is applied in a different manner, and with a different object in view. One end of a strip of adhesive plaster, about fifteen inches long and three inches wide, is applied to the outer side of the ankle just below the external malleolus; the foot is then adducted as far as possible, and the band is drawn tightly beneath the sole up the inner side of the arch and leg, and is stayed in this position by one or two plaster strips about the calf (Fig. 696). Narrow plaster straps are then applied about the arch and ankle, in the figure-of-eight manner, and a bandage is applied.

FIG. 696.—Method of applying the plaster strapping to hold the foot in the adducted attitude.

The object of the dressing is to aid in holding the foot in the improved position by the support and suggestiveness of the plaster, and to provide the firm compression about the arch that is always agreeable to the sufferer from weak foot. This treatment, combined with the tilted shoe, is often very effective in overcoming the acute and disabling symptoms of the weak and injured foot, which are, as has been stated, often the result of extra strain or injury; in other words, a sprain of a weak foot. Consequently, when these symptoms are relieved, the patient who has become habituated to the weakness and deformity considers himself cured. By persistent manipulation and subsequent support with the adhesive plaster one may overcome the

deformity in the majority of cases. When this is accomplished the brace is applied and the further treatment that has been described is continued. Forcible correction under anesthesia is, however, preferable in cases of the more resistant type.

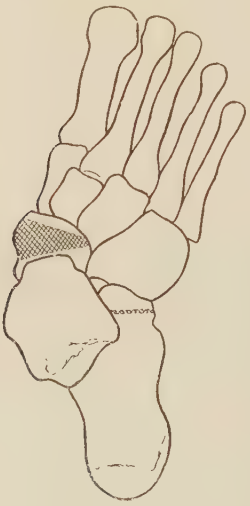

FIG. 697

FIG. 698

FIG. 699.—Shape of wedge.

FIG. 700

FIGS. 697–700.—Wedge removed from the scaphoid and inserted into the os calcis. (Perth.)

Operative Treatment.—The various cutting operations for the relief of flat-foot do not call for extended comment. Jones advises resection of a portion of the two peroneal tendons at a point of one and a half inches above the malleolus in cases of resistant abduction, and in some instances tendon transplantation as for paralytic valgus may be indicated. Fixation in the normal attitude has been attempted

MEDICAL LIBRARY
BOSTON CITY HOSPITAL

by arthrodesis of the astragalo-scaphoid articulation or in combination with arthrodesis of the subastragaloid articulation and the greater security that may be assured by the insertion of the bone peg through the navicular into the head of the astragalus. The typical operation, the removal of a wedge from the astragalo-navicular region, aims simply at removal of the deformity. It should be restricted to those cases in which the adaptive changes are so marked that functional cure is impossible. A more conservative form of operation is that of Perth[1] as illustrated in Figs. 697–700. A wedge of bone is removed from the scaphoid and inserted into the anterior-external extremity of the os calcis.

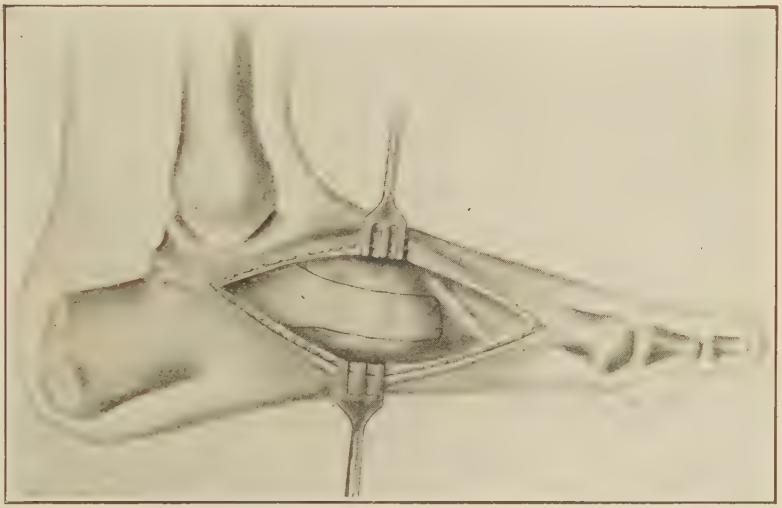

FIG. 701.—Marking out the figure in the fascia to be lifted up with slab of bone beneath. (Miller, Jour. Bone and Joint Surg., January, 1927.)

Miller's Operation.—A flap of ligament and bone is cut from the inner side the foot, including the three adjoining joints; sections are removed from each articulation and the deformity, having been corrected, the flap is replaced, as illustrated in Figs. 701 703.

The operation of advancement of the posterior extremity of the os calcis, as proposed by Gleich, in order that it may be placed in relation to the leg somewhat like that of Pirogoff amputation, offers little hope of ultimate cure; for since the disability is not due to primary depression of the arch, it can hardly be cured by exaggerating its depth in this manner. Supramalleolar osteotomy, in which the bones of the leg are divided above the ankle, and the distal extremity turned inward, with the aim of directing the weight toward the outer border of the foot, has been advocated by Trendelenburg. In practice the operation is by no means always successful, while the bow-leg that results if the object is attained is an unfortunate accompaniment of the treatment.

[1] Deutsch. Ztschr. f. Chir., April 12, 1913.

In operative treatment the prolonged rest must be taken into consideration, as explaining in part the immediate favorable effect of whatever procedure is adopted.

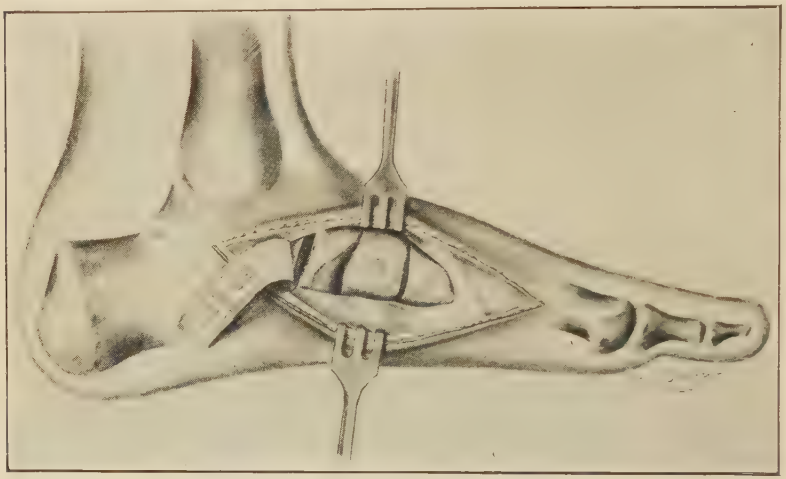

FIG. 702.—Showing section from neck of astragalus. This can be done through the incision when necessary. (Miller, Jour. Bone and Joint Surg.)

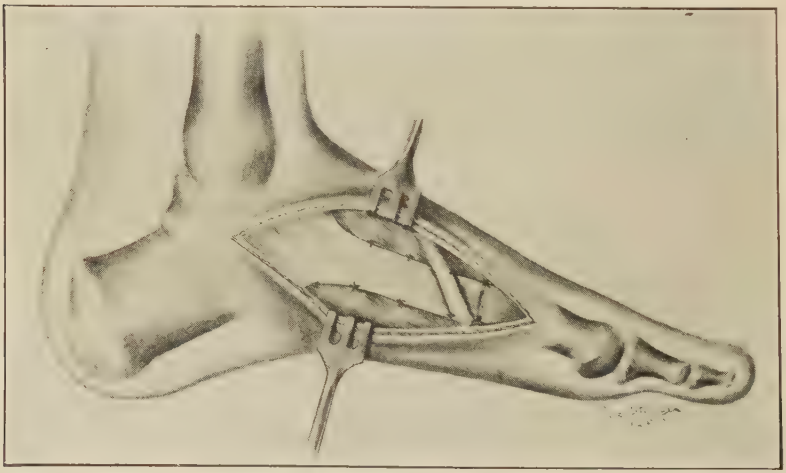

FIG. 703.—Showing the fascia sutured in place maintaining a normal arch line. (Miller, Jour. Bone and Joint Surg.)

In conclusion, the following points are again emphasized: The weak foot in all its grades is characterized by the persistent attitude of abduction, an attitude that must be corrected if cure is to be accomplished. The depth of the arch is of minor importance and for this reason the term flat-foot which has attracted attention to this element of deformity rather than to functional disability should be discarded.

CHAPTER XXI.

DISABILITIES AND DEFORMITIES OF THE FOOT (Continued).

THE HOLLOW OR CONTRACTED FOOT.

Synonyms.—Talipes plantaris, talipes cavus.

The depth of the arch and the corresponding area of the bearing surface of the sole vary greatly in different individuals, and, although marked differences in contour and function are included within a normal range, yet, as a rule, the low arch is characterized by relaxation and weakness of structure, while the high arch implies a corresponding contraction and loss of normal elasticity.

The hollow or contracted foot may be divided into two classes—the primary and the secondary. In the first class the simple exaggeration of the arch (talipes arcuatus) is the only change from the normal condition. In the second the high arch is combined with limitation of the range of dorsal flexion at the ankle-joint (talipes plantaris—Fisher).

Etiology.—The simple hollow foot may be an inherited peculiarity. The depth of the arch may be exaggerated by the habitual use of high heels (postural equinus), or by excessive use of the calf muscles, as by professional dancers.

The secondary variety, in which the hollow foot is combined with slight equinus, may be induced by habitual use of high heels and consequent habitual disuse of dorsal flexion, but if it is marked its origin may be traced in many instances to a mild and transient form of anterior poliomyelitis or neuritis in early childhood. This causes temporary weakness of the anterior group of muscles of the leg, and thus a slight toe-drop, followed by secondary contraction of the tissues of the sole and of the muscles of the calf. In the history of many of these patients it will appear that after recovery from scarlatina or other contagious or infectious disease the child seemed weak or awkward. These symptoms became less marked or practically disappeared; yet a trace remained, although not of sufficient importance to call for treatment, until adolescence or adult life, when the greater strain and weight put upon the feet brought to light the latent disability. The affection may undoubtedly develop in later years as the result of neuritis, or of gout or rheumatism. It may be caused by a sprain or fracture of the ankle, and it may be a result of habitual posture in compensation for a limb shortened by injury or disease.

The exaggerated arch which is a part of a more important deformity, as of equinovarus or calcaneus, or that which is simply one of many

distortions caused by disease of the nervous apparatus, does not belong to the class of disability under consideration.

Symptoms.—The simple hollow foot often exists without symptoms; in fact, it may be considered a particularly well-formed foot rather than a deformity. The common complaint in these cases is that one is unable to buy comfortable shoes because the ordinary shoe does not conform to the arch, or because the leather presses on the dorsum of the foot. The convexity of the dorsum, of course, corresponds to the depth of the arch; in many instances the cuneiform bones project sharply beneath the skin, and painful pressure points or even inflamed bursæ in this locality may cause discomfort.

Fig. 704.—The contracted foot of slight degree.

In the well-marked cases in which the weight is borne entirely on the heel and the front of the foot, calluses and corns usually form at the center of the heel and beneath the heads of the metatarsal bones. The patient may complain of neuralgic pain about the great toe, the metatarsal arch, or in the sole of the foot. The gait is often ungraceful, as the patient walks heavily upon the heels with the feet turned outward. In such cases "the ankles may be weak and turn easily." In the more advanced cases of this type the foot may assume the position of valgus when weight is borne, so that the more noticeable symptoms are those of the weak foot or so-called flat-foot.

Contracted foot, of the more severe grade, is almost always accompanied by a certain limitation of dorsal flexion; and as the shortening of the plantar fascia is often more marked at its inner border, a slight inversion of the forefoot or varus may be present also.

When the exaggerated arch is combined with limitation of dorsal flexion the deformity is usually greater. This limitation may be very slight, or it may be well-marked; and a slight degree of permanent equinus even may be present, but so slight that it does not, as a rule, attract attention.

This type of the contracted foot was first clearly described by Shaffer, in 1885, under the title of "non-deforming club-foot,"[1] and later by Fisher, of London, as "talipes plantaris."

The symptoms are similar to those of the simple hollow foot, but they are almost always more marked. The gait is awkward and jarring, the feet being turned outward to an exaggerated degree. The patient is easily fatigued, and often complains of the weakness about the ankle and inner side of the arch, characteristic of the weak foot, and of sensations of tire and strain in the calf of the leg. The discomfort from corns, the pain referred to the metatarsal region, the great toe, and to the sole of the foot have been described already.

FIG. 705.—The hollow foot, showing contraction of the toes.

On examination, the exaggeration of the arch is evident, and an imprint of the sole shows that the weight is borne entirely on the heel and on the heads of the metatarsal bones, which may be very prominent beneath the thickened skin, as if the subcutaneous fat had been absorbed. The anterior metatarsal arch is often obliterated, and the toes are usually habitually dorsiflexed at the first phalanges, the permanent flexion, with the resulting pressure against the leather of the shoe being indicated by a row of corns upon their dorsal surfaces (Fig. 705).

[1] New York Med. Record, May 23, 1885.

The contracted plantar fascia may be demonstrated by forcible dorsal flexion of the foot, when the tense bands, in many instances very sensitive to pressure, may be felt beneath the skin.

On testing the movements of the foot, the limitation of dorsal flexion, both of the voluntary and the passive range, will be evident. In voluntary flexion the toes are drawn up and the tendons are plainly seen on the dorsum, showing the effort made by the accessory muscles to overcome the abnormal resistance.

In this connection it may be noted that the action of the lumbricales and both dorsal and plantar interoseii muscles is to fix the first and to extend the second phalanges. Thus the characteristic contracted toe indicates disuse of this action (Fig. 705) and the possibility of temporary or permanent paralysis of these intrinsic muscles as the cause.

The limitation of dorsal flexion may be demonstrated in the manner suggested by Shaffer, by asking the patient to flex the feet while standing erect with the back to the wall, when, in spite of the effort made, "the feet remain glued to the floor."

Treatment.—In the ordinary form of contracted foot, as has been stated, the disability is much more marked than the deformity; and the disability is due to secondary changes in the structure of the foot, by which its elasticity is impaired. If this can be restored in some degree, permanent relief will follow. If the simple hollow foot (cavus), or the secondary type (plantaris), were discovered in early childhood, massage, and methodical stretching would, in all probability, be sufficient to relieve the contractions; but, as a rule, no symptoms are noticed until later life. Even then, especially in the simple form, they are often slight and may be relieved by a shoe with a broad heel and a high (Spanish) arch or by a foot plate that equalizes the pressure on the sole.

In the more advanced cases of the milder type methodical forcible manual stretching may elongate the tissues sufficiently to relieve the symptoms. The Shaffer[1] "traction shoe" may be used with advantage for the same purpose. In the more resistant cases, however, division of the contracted parts and forcible correction of deformity are indicated.

Operative Treatment.—The patient having been anesthetized a tenotome is inserted beneath the skin to the inner side of the central band of fascia. This is divided by a sawing motion, and if on forced dorsal flexion other tense bands appear they are divided also. Forcible massage, with the aim of making the foot flexible and reducing the depth of the arch, is then employed. If more force is required the Thomas wrench may be used as in the treatment of club-foot; the object to elongate the foot, to remove the contraction, and thus by increasing the area of bearing surface to relieve the painful pressure on the heads of the metatarsal bones. In cases of this type the operation called by *Steindler*[2] stripping of the os calcis is more effective. His description is as follows:

"A horseshoe incision is laid around the heel beginning from the inner tubercle of the os calcis on the inner side, and ending about

[1] New York Med. Jour., March 5, 1887.
[2] Surg., Gynec. and Obst., May, 1917.

three-quarters of an inch behind the calcaneocuboid joint. The lower surface of the os calcis is stripped entirely to its anterior edge where the short flexors of the toes and the abductors of the first and fifth toes are inserted together with plantar fascia. Underneath these structures a grooved director is passed and they are severed or stripped closely to the bone. Thereupon, the cavity of the foot at once yields to extension up to the point where the contraction of the accessory flexor and of the long plantar ligament is responsible for the cavus deformity. In one or two cases, I have gone further and resected these muscles and also incised the long plantar ligament at the calcaneocuboid junction and resected this latter joint, but the flap necessary is so long that its nutrient condition becomes very unsatisfactory and the ends slough off. Therefore, I have contented myself in most of the cases with the procedure as outlined above. I have found that a half horseshoe gives all the exposure necessary and, with this incision, there is no danger of sloughing." A straight incision preferably on the outer border of the heel in order to avoid the posterior tibial artery has the advantage of a lessened scar and permits sufficient exposure. Forcible correction by the Thomas wrench as a supplementary procedure is usually required in resistant cases.

Fig. 706.—The plaster splint as applied after forcible correction of contracted toes, holding them in plantar flexion. The plaster pad beneath the joints aids correction when weight is borne.

If the contraction of the tendo Achillis cannot be overcome by forcible manipulation it may be divided subcutaneously or elongated by open operation. In nearly all cases of this type the toes are contracted often to a degree of hammer-toe deformity and the metatarsal arch is replaced by a convexity downward. This deformity should be corrected by manipulation and if necessary by subcutaneous division of the extensor tendons. The toes are then vigorously stretched and are then forced downward, while the metatarsal extremities are pushed upward. A plaster bandage is then applied to hold the extended toes in plantar flexion and the foot in dorsal flexion. (See Fig. 706.) As

soon as possible, often on the following day, the patient is encouraged to walk about, in order that the pressure of the body weight may be utilized to flatten the foot still more, while its tissues are in a yielding condition.

The plaster support may be continued for six weeks, or, if the tendo Achillis has been divided, until its repair is complete. A well-fitting shoe should be worn, and methodical massage and stretching of the tissues should be persistently employed, particularly with the aim of restoring the normal flexion of the toes. A long metal foot plate extending to the extremity of the sole presenting a convexity beneath the metatarsophalangeal articulations is an essential aid in restoring the normal contour. (See Fig. 707.)

Fig. 707.—The foot plate for metatarsalgia and contracted toes extending to the extremity of the sole and supporting the entire metatarsal arch is far more effective in a curative sense than the pads ordinarily used, because the weight of the body is utilized as a corrective agent.

By this treatment the symptoms may be relieved and in many instances restoration of approximately normal shape and function can be assured.

For the contracted toes, Jones suggests transplantation of the extensor tendons into the heads of the metatarsal bones while Hibbs transplants them into the external cuneiform bone, the aim being to remove an active deforming force.

This operation has been somewhat modified recently. The toe tendons are fixed in openings made in a cuneiform bone. An arthrodesis operation is made at interphalangeal joints, especially that of the great toe, and a digitated splint to hold the toes in the corrected attitude is applied. In this class of cases equinus or cavus is corrected as a preliminary measure.

In cases of an extreme type an effective operation is to turn back a horseshoe flap from the front of the sole to expose the articulations. The tendons are drawn laterally, the capsule is opened and, with a narrow chisel, the prominent lower half of the head of the metatarsal bone is removed. The operation is repeated at all the joints. The bearing surface is thus made flat and the sole protected from unequal pressure. The operation is supplemented by the support and manipulation, as already described.

WEAKNESS AND DEPRESSION OF THE ANTERIOR METATARSAL ARCH.

Anterior Metatarsalgia and Morton's Neuralgia.—A peculiar spasmodic pain about the fourth toe was described by Morton, of Phila-

MEDICAL LIBRARY
BOSTON CITY HOSPITAL

delphia, long before its predisposing and exciting causes were understood. For this reason a description of the symptoms may with advantage precede a consideration of the weakness of which they are usually the result.

Typical cases of Morton's[1] painful affection of the foot are characterized by a sudden cramp-like pain in the region of the fourth metatarso-phalangeal articulation.

The pain may begin as a burning sensation beneath the toe, as a numb or tingling feeling, as a sudden cramp, or as a peculiar feeling of discomfort about the articulation that increases in severity until it becomes almost unbearable. At first the pain is confined to the neighborhood of the affected joint, but unless it is relieved it radiates to the extremity of the toe, to the dorsum of the foot, or up the leg. In many instances the onset of the pain is preceded by the sensation of something moving or slipping in the foot; in some cases the pain may be induced by sudden movements, missteps, or by long standing, and in practically all the cases the pain is felt only when the shoes are worn. The frequency of the recurrent cramp varies; in some cases it appears only at infrequent intervals; in others it practically disables the patient. When the "cramp" habit has been acquired, very slight causes may induce the pain—for example, a thin-soled shoe, a hot pavement, "the sticking of the sock to the foot." and the like—but, as has been stated, except in the very advanced and chronic cases, the pain is never felt except when the shoe is worn.

To relieve the pain the patient removes the shoe, rubs and compresses the front of the foot, flexes and extends the toes and the like. After the cramp is relieved a sensation of soreness remains, and occasionally slight swelling may appear, but in most instances there are no external signs, although the affected articulation is usually sensitive to deep pressure at all times.

The more comprehensive term, anterior metatarsalgia, suggested by Poulosson, of Lyons, in 1889, may include Morton's neuralgia, and similar symptoms of pain and discomfort about the anterior metatarsal arch. For in many instances the cramp-like pain is referred to other points, for example, to several adjoining joints, or the discomfort caused apparently by direct pressure on the bones of the weakened arch may be more disabling than the irregular attacks of neuralgic pain characteristic of Morton's affection.

Etiology and Pathology.—In 78 cases of anterior metatarsalgia in which the location of the pain was noted, it was referred to the fourth metatarso-phalangeal articulation in 60; to the third and fourth articulation in 6; to the second, third, and fourth in 6, and in but 6 was the fourth articulation free from pain. The pain is most often unilateral, or, if the other foot is affected, it is usually after a considerable interval.

The affection is more common in females than in males. Of 84 cases, 64 were in women and 20 were in men.

[1] T. G. Morton: Am. Jour. Med. Sci., August, 1876.

Anterior metatarsalgia is not an affection of early life, the average age in the reported cases being more than thirty years. It is far more common in private than in hospital practice, and not infrequently the patients are of a distinctly nervous type. In many instances it is supposed to be a family inheritance. The affection is usually extremely chronic. Occasionally the symptoms may cease spontaneously, and in such instances a particular pattern of shoe usually receives the credit of the cure.

Morton considered the disability to be a painful affection of the plantar nerves due to compression or pinching by the adjoining fourth and fifth metatarso-phalangeal articulations. This compression was explained by the anatomical construction of the foot—*i. e.*, the mobility of the fifth metatarsal bone which allowed it to roll above and under the fourth, its relative shortness which allowed the head and base of the adjoining phalanx to be brought against the adjoining head and neck of the fourth bone, and, finally, by the peculiar distribution of the external plantar nerve between these bones that made it or its fibers more liable to injury. This natural mobility and thus the predisposition to compression might be exaggerated by a sprain, or possibly by rupture of the transverse metatarsal ligament, or the pain might be induced by wearing tight shoes, but in many instances no cause could be assigned. On this theory Morton advocated excision of the head of the fourth metatarsal bone to remove the point of counter-pressure. This operation has been performed many times, but practically no pathological changes in the resected bone or in the surrounding parts have ever been discovered.

In more recent years the true significance of Morton's neuralgia and of similar pains in the front of the foot has been made more clear by the study of the relation of weakness of the anterior transverse metatarsal arch to the symptoms. Attention was first called to this point by Poulosson, and again by Roughton, Woodruff, and others, and more definitely by Goldthwait,[1] in 1894.

The Anterior Metatarsal Arch.—In the normal foot the two central metatarsal bones, the second and third, are slightly longer and on a higher plane than their fellows. When weight is borne all the metatarsal bones are on the same plane and the arch is obliterated, but when the weight is removed the arch is restored by a certain natural resiliency. In walking and standing the weight falls in the neighborhood of the head of the third metatarsal bone, as shown by a thickening of the skin beneath it, but the strain on the metatarsal arch is relieved somewhat by the balancing action of the muscles about the first and fifth metatarsal bones, the inner and outer supports of the arch, and by the active assistance of the toes themselves. When the arch is weak or broken down this natural resiliency is lost, and, in some instances, the center of the forefoot is not only depressed but it is fixed in this abnormal attitude.

[1] Boston Med. and Surg. Jour., vol. **131**, 233.

In the ordinary type of depressed anterior arch the deformity may be shown by an imprint of the foot, in which the flabby tissues of the depressed arch encroach upon the clear space representing the longitudinal arch. In many instances, however, the imprint of the foot subject to Morton's neuralgia may be to all intents normal, and, on the other hand, depression of the metatarsal arch, one of the very common results of improper shoes, may be present, yet unaccompanied by pain or discomfort.

Depression of the anterior arch induces discomfort because of abnormal pressure upon the persistently depressed articulations from beneath and it predisposes to pain, as the writer[1] has explained, because the metatarso-phalangeal joints of an habitually depressed arch are exposed to the direct lateral compression of a narrow or ill-shaped shoe.



FIG. 708.—Position of the fingers corresponding to dorsiflexion of the toes, an attitude in which lateral pressure causes pain.

This point may be illustrated in the hand. When lateral pressure is applied, the hand is folded together and the anterior metacarpal arch is increased in depth, but if the fingers are dorsiflexed so that it is fixed in a depressed position, then lateral compression causes great pain at all the articulations (Fig. 708); or if one finger is dorsiflexed and the corresponding metacarpal bone is thus forced below the level of its fellows, lateral compression causes pain at the compressed joint. Or if the metacarpal bone of the little finger is made to override the fourth, lateral pressure causes pain usually of a more acute character than at the other joints, because the opportunity for direct pressure is more favorable.[2] Finally, if firm pressure is made upon one or the other side of the head of the depressed metacarpal bone of the dorsiflexed finger in the palm of the hand, a point of sensitiveness, representing apparently the digital nerve, can be made out. The same experiments may be tried upon the foot with the same results, and it would seem to make clear the mechanism of the pain

[1] New York Med. Record, August 6, 1898.

[2] This anatomical peculiarity is well known to school-boys.

of Morton's neuralgia and the allied forms of discomfort at the front of the foot.

Anterior metatarsalgia is in most instances the result of weakness or depression of the anterior metatarsal arch as a whole or in part, and the quality of the pain corresponds fairly to the form of weakness or deformity. If, for example, the entire arch is rigidly depressed, as after certain inflammatory affections of the joints, the discomfort is likely to be caused, in great degree, by the direct pressure on the prominent metatarso-phalangeal joints by the sole of the shoe; or, if lateral pressure is exerted as well, the discomfort or pain may be referred to the metatarsal arch in general. If the metatarsal arch is weakened, depressed, and broadened, but not rigid, the discomfort is often referred, as in the preceding instance, to the center of the arch, and this discomfort is increased, in some instances, by a painful callus representing abnormal pressure at this point. "Burning pain" at night after overuse is a common symptom of this class of cases. If one of the metatarsal bones falls below its fellows, the lateral pressure of a narrow shoe may cause neuralgic pain at this joint, but in many cases in which the anterior arch is depressed the patient makes but little complaint of pain. In certain instances, more particularly those of Morton's typical neuralgia, the foot may appear normal; in such cases it may be inferred that the sharp and characteristic pain is caused by pressure applied to the overriding fifth metatarsal bone, just as similar pain is felt if the hand is suddenly compressed while the fifth metacarpal bone is in the same position. The theory is the more satisfactory because it explains the symptoms and indicates the principles of treatment: for example, the sensation of something slipping or moving, the necessity for the removal of the shoe to flex and extend the toes and to compress the foot, apparently with the instinctive aim of replacing a depressed arch, or a misplaced bone in the arch. It would also explain how the shoe may be the most direct of the exciting causes of the deformity, in that it compresses the forefoot and throws more weight upon it by elevating the heel. If the arch is depressed or becomes depressed, or if a bone in the arch overrides another, this compression causes the symptoms.

Classical Morton's neuralgia is then but one of the symptoms of weakness of the anterior arch of the foot.

The Influence of the Shoe in Causing Disability and Pain.—In the etiology of pain and discomfort about the anterior arch one must recognize the shoe not only as the direct cause of the pain, but also as the most important of the predisposing causes of weakness of the anterior arch, of which the pain is a symptom, since it compresses the toes, lifts them off the ground by its "rocker sole," and thus throws additional strain and pressure upon the arch. In fact, in a very large proportion of feet that are supposed to be normal in appearance and functional ability, the toes are habitually dorsiflexed in a claw-like attitude that shows entire disuse of their function both as to support and progression. Women wear shoes with narrower soles and higher

heels than men, and this seems the most reasonable explanation of the fact that they are more subject to the affection.

The shoe also predisposes to habitual elevation of the fifth metatarsal bone, because this bone almost invariably overhangs the narrow sole. The fourth metatarsal bone becomes, therefore, the outer support of the arch, and is almost always found to be on a lower level than the adjoining bones. This relation, together with a laxity of muscular and ligamentous support induced by injury or otherwise, may account for the location of the pain at this point in the majority of cases. Although in certain instances local neuritis may result from repeated injury, it is a rather unusual complication. Nor is it likely that the peculiar distribution of the nerves at the fourth joint has any direct influence on the location of the pain, for the nerve supply of all the joints and all the toes is practically identical.

Other Factors in the Etiology.—Besides the general effect of the shoe, and the influence of an inherited predisposition to the affection, which seems evident in certain cases, or of weakness or direct injury of the anterior arch, one recognizes among the causes or complications of anterior metatarsalgia weakness of the longitudinal arch, which may be combined with a depression of the anterior arch. Less often the longitudinal arch may be exaggerated in depth and the dorsal flexion of the foot may be limited by a shortened tendo Achillis; thus more pressure is brought upon the front of the foot. In these cases the pain may be increased by corns or calloused skin beneath the depressed bones, and in many instances the discomfort of the depressed arch of the ordinary type, is, in great part, caused by a sensitive corn or fibroma at the point of greatest depression, and the patient may be entirely relieved by its removal. (See Contracted Foot.)

Although the symptoms of anterior metatarsalgia may be explained in most instances by the primary effect of improper shoes, by weakness and abnormality of the foot itself, and by the local sensitiveness of the parts that are continually subjected to strain, pressure, and injury, yet in some instances the symptoms can be accounted for only by local neuritis; in others they are aggravated by gout or rheumatism or general debility, and as has been mentioned in a large proportion of the cases, the patients are of a distinctly nervous type.

It may be stated, in conclusion, that anterior metatarsalgia in its milder form is a very common affection and one rarely treats a patient who does not know of other cases similar to his own.

Treatment.—The most important local treatment is to provide the patient with a suitable shoe. This shoe must be of proper shape with a thick sole, so broad that no lateral compression of the toes is possible, with a high arch and narrow counter, so that the leather fitting closely about and beneath the arch may hold the foot securely.

As an immediate treatment a firm bandage about the metatarsal region, as suggested by Morton, may aid in supporting the metatarsal arch, or, better, adhesive-plaster strapping may be applied about the entire metatarsus, with the object of compressing the forefoot some-

what as a tight glove compresses the hand. Beneath or slightly behind the affected joint or the depressed arch, a pad, preferably an oval piece of sole leather, about one inch by three-quarters of an inch in size and one-quarter of an inch in thickness with bevelled edges, may be fixed to the sole of the foot with adhesive plaster so that depression of the arch or overriding of the adjoining bones may be prevented. This pad, suggested by Poulosson and Goldthwait, usually relieves the pain, and when the exact place has been ascertianed it may be fixed to the sole of the shoe. Supports of this character are palliative rather than curative, as a rule, a metal support will be found to be more comfortable and far more efficient. This may be constructed of light steel (19 gauge) upon a plaster cast of the sole of the foot suitably modelled. The anterior extremity of the brace is made nearly as wide as the foot and extends forward to the extremity of the sole, splinting the sensitive metatarso-phalangeal articulations, thus differing entirely in its action from pads or other supports in which the pressure is upon

Fig. 709.—Exercise for the weakened metatarsal arch.

the soft parts behind the joints. As a rule a slight general convexity is efficient, but in certain instances this must be greatest behind the sensitive joint to relieve the pain. The brace should also support the longitudinal arch to hold the foot securely and to relieve some of the pressure on the metatarsal region. If there is slight depression of the longitudinal arch it may be further corrected by raising the inner border of the heel and sole of the shoe; but if it is more pronounced a flat-foot brace (Fig. 689) may be employed, of which the anterior extremity is modified to support the metatarsal arch. If, on the other hand, the arch is exaggerated and if dorsal flexion is limited, treatment with the aim of relieving this deformity will be necessary, as described under Contracted Foot. When the immediate symptoms of pain and local discomfort have been relieved, the patient should endeavor to strengthen the natural supports of the arch by proper functional use of the foot, and by regular exercises of the muscles, more especially by methodical forced flexion of the toes, as this motion elevates the anterior metatarsal

arch (Fig. 709). Massage of the foot and forcible manipulation of the toes for the purpose of overcoming restriction of motion are of special value.

If the depressed anterior arch is rigid, as in some instances, its flexibility must be restored by manipulation or by forcible correction under anesthesia before a brace can be applied. If the symptoms are very acute, and particularly if they have followed direct injury, the parts should be placed at rest and the anterior arch should be elevated and supported by a properly applied plaster bandage.

In chronic and resistant cases or when conservative treatment is impracticable, resection of the head of the metatarsal bone at the seat of pain may be performed as suggested by Morton. The operation is very simple: An incision is made over the dorsal surface of the joint, and the articulating extremity of the metatarsal bone is divided by bone forceps or Gigli saw. The toe should not be removed. After the operation it slowly recedes between the adjoining metatarso-phalangeal joints, becoming somewhat shorter. The operation is, as a rule, successful, but in the majority of cases it is unnecessary.

FIG. 710.—Fixed depression of the anterior metatarsal arches, showing the prominence of the depressed joints in the sole, also extreme hallux valgus.

The general condition of the patient should, of course, receive attention, and local applications, electricity and the like may be of benefit in special cases.

Woodruff[1] described a case of what he called "incomplete luxation of the metatarso-phalangeal articulation," in which the symptoms, practically identical with those of Morton's neuralgia, are ascribed to an upward displacement of the proximal phalanx at the fourth metatarso-phalangeal joint. These cases of complete or incomplete luxation are not infrequent particularly as sequelæ of gonorrheal or other form of infectious arthritis, and unless the deformity can be overcome by manipulation the head of the depressed metatarsal bone should be resected.

[1] New York Med. Record, January 18, 1887.

In this connection it may be stated that in the ordinary forms of metatarsalgia, patients often refer the pain and local sensitiveness to the anterior extremity of the metatarsal bone rather than to its lateral aspect. Persistent dorsal flexion of the toes so commonly associated with depression of the arch by subjecting this portion of the joint to abnormal pressure, may explain the location of the pain.

A *sensitive callus* beneath the arch may require treatment, and in certain cases its removal may be the only treatment required other than an improved shoe. But, as a rule, the cause of the callus is habitual depression of one or more of the metatarso-phalangeal articulations, so that cure can only be assured by supporting the arch and by strengthening its natural supports. If as in certain instances the depressed joints cannot be replaced in normal position operative treatment is indicated, as described elsewhere. (See Contracted Foot.)

PAINFUL WARTS.

Not infrequently an area of callus in the anterior metatarsal region presents one or more wart-like growths which have resisted treatment by the chiropodist and complete excision is indicated. In these cases there is usually depression of the anterior arch which should be treated in the manner already described.

ACHILLOBURSITIS.

Synonyms.—Achillodynia, achillobursitis anterior, retrocalcaneobursitis.

Under the title of Achillodynia, Albert,[1] in 1893, called particular attention to an affection characterized by pain and sensitiveness about the insertion of the tendo Achillis, symptoms usually caused by irritation or inflammation of the bursa lying between the insertion of the tendon and the bone (Fig. 711).

Etiology.—In the acute cases the cause of the bursitis often appears to be a strain of the tendon or direct injury, as the symptoms appear immediately after running or jumping or after a fall, sometimes after a long walk or bicycle ride. Sever[2] has described several cases in childhood in which the symptoms were caused by injury or displacement of the posterior epiphysis of the os calcis. (See Apophysitis.)

In the subacute cases the symptoms may begin almost imperceptibly, so that it may be impossible to assign a direct cause other than strain or the pressure of the shoe, aggravated, it may be, by an exostosis of the os calcis beneath the insertion of the tendon or by concretions within the bursa. In many instances rheumatism, gout, gonorrhea, or one of the infectious diseases appear to be associated, directly or indirectly, with the onset of the symptoms. In such cases the

[1] Wiener med. Presse, January 8, 1893.
[2] New York Med. Jour., May 18, 1912.

MEDICAL LIBRARY
BOSTON CITY HOSPITAL

bearing surface of the heel may be sensitive and the metatarso-phalangeal joints may be involved.

Symptoms.—In a typical case pain is referred to the back of the heel at the insertion of the tendon; and is increased by use of the foot, particularly by the attitudes in which the strain on the part is increased, as, for example, in descending stairs. There is also sensitiveness to pressure about the back of the heel on either side of the insertion of the tendon. In most cases a slight swelling, often more prominent on the inner than on the outer side of the tendon, indicates the situation of the bursa.

In the chronic cases the enlargement of the bursa is very noticeable, and, in addition, the entire posterior aspect of the heel often appears to be thickened. This is due probably to the secondary irritation about the fibrous expansion of the tendon and the adjoining periosteum. In many cases the symptoms are pronounced; pain is often felt in the bottom of the heel or it radiates up the back of the leg. The patient everts the foot in walking, to avoid tension on the sensitive part, thus subjecting the arch to overstrain, so that the symptoms of the weak foot are often added to those of the original trouble. Not infrequently, however, the two affections may be associated from the beginning in one or the other foot. The patient complaints much of stiffness and weakness at the ankle and metatarsal joints. In acute cases, or in acute exacerbations, there is usually burning and throbbing pain characteristic of inflammation, but in the subacute form the pain is slight, and is troublesome only after overexertion.

FIG. 711.—Bursa between the tendo Achillis and the os calcis.

Pathology.—The pathological changes do not differ from those found in and about other bursæ under similar conditions. In the mild cases the lining membrane is simply congested, and the cavity contains serous fluid. In the chronic cases the walls are much thickened,[1] the lining membrane is fringed and reduplicated; the contents are semisolid, and sometimes calcareous masses are present. Similar changes are found, however, in the bursæ of apparently normal subjects, so that the condition of the bursa may not always correspond to the character of the symptoms. Suppuration of the sac occasionally occurs, and it may be the seat of tuberculous or syphilitic disease. In cases of long standing the parts adjoining the bursa, the expansion of the tendon, and the periosteum become thickened, so that the bone appears to be increased in breadth and may actually become so.

Treatment.—When once established the affection is usually of a very chronic nature, as is explained by constant irritation to which

[1] Rössler: Deutsch. Ztschr. f. Chir., Band 62, Heft 1 and 3.

the sensitive part is subjected by the use of the foot. It is, therefore, important to apply efficient treatment at the beginning of the affection if an opportunity is afforded. Efficient treatment implies absolute rest, and in all cases of any severity, particularly those of acute onset, a well-fitting plaster support should be applied to hold the foot slightly inverted and at a right angle to the leg. This should be worn until all symptoms have subsided. In very mild cases, following immediately on a strain or overuse, simple rest with the application of heat, massage, and pressure may be efficient. And in the subacute cases the symptoms may be relieved by the application of a long, broad band of adhesive plaster, from the toes over the back of the heel to the upper third of the calf, the foot being slightly plantar flexed. This is firmly fixed by narrow strips of plaster about the metatarsus, the heel, and the calf. By this means pressure is exerted upon the bursa, and much of the strain is removed from the tendon.

In persistent cases a brace may be used with advantage for the purpose of preventing strain upon the tendon. Two lateral uprights with a calf band and padded strap that crosses the upper third of the leg are attached to the shoe, provided with a stop joint at the ankle as used in the treatment of paralytic calcaneus to prevent dorsal flexion. (See Talipes.) As the patient is usually sensitive to jar, the heel of the shoe should be replaced by one of thick rubber. In connection with the brace the stimulation of the cautery and the pressure of the adhesive-plaster strapping seem to hasten the absorption of the effusion in and about the bursa. If weakness or depression of the arch is present, as a result of the disability or combined with it, a foot plate should be applied, and systemic affections, with which the disability is oftentimes associated, should, of course, receive attention, gonorrhea being one of the most important.

Operative Treatment.—In persistent cases, in which the symptoms are not relieved by treatment, the enlarged bursa should be removed, together with the periosteum about its margin, by an incision on the inner side of the tendon, as the swelling is usually most prominent here. A plaster support is then applied and is continued until the symptoms have subsided. If the case is a chronic one it may be advisable to divide the tendo Achillis in order to completely remove for a time the strain upon the sensitive part. A brace of the character already described may be used with advantage for a time after the plaster support has been removed. Operative treatment is, of course, indicated in acute suppurative inflammation, in tuberculous disease, or if an exostosis beneath the bursa or concretions within the sac are present, as shown by a roentgen-ray negative.

Apophysitis.—Symptoms and appearances similar to those of achillobursitis are sometimes observed in young subjects induced by inflammation or irritation about the epiphyseal cartilage on the posterior extremity of the os calcis. It is most common in boys from ten to fifteen years of age. The exciting cause is ascribed to strain or pressure. The affection is similar, apparently to the so-called Osgood-

Schlätter disease at the insertion of the ligamentum patellæ. The roughened surface of the tuberosity of the os calcis and the segmentation of the epiphysis are shown in Fig. 712. It may be noted that similar changes are sometimes observed in the roentgen-ray picture of apparently normal subjects and apart from the symptoms are of slight importance. The treatment should be directed to the relief of strain and pressure by the application of a plaster support or brace.[1]

Fig. 712.—Apophysitis showing the irregularity of the posterior surface of the diaphysis and the segmentation of the epiphysis of the os calcis.

Achillobursitis Posterior.—Sensitiveness, pain and swelling at the back of the heel may be due to irritation of the small superficial bursa that lies between the tendon and the skin. The cause is usually pressure of the shoe. The symptoms resemble somewhat those of achillobursitis anterior, but the swelling is more superficial, and the pain is caused by friction rather than by tension on the tendo Achillis. In the ordinary case removal of the pressure will at once relieve the symptoms, but if the discomfort is considerable a plaster bandage may be worn for a week or more.

Sensitive points at the back of the heel are usually caused by the

[1] Lewin: Surg., Gynec. and Obst., November, 1925.

pressure of the shoe. In rare instances prominent points or exostoses of the os calcis are present, that may require special protection or removal.

STRAIN OF THE TENDO ACHILLIS. PERITENDINITIS.

Not infrequently, and usually as the result of strain or overuse of the foot, patients complain of symptoms similar to those of achillobursitis, but on examination one notes that the pain and sensitiveness are referred to the tendon itself, which is often enlarged (peritendinitis). The sensitive area may be as high up as the junction of the tendon with the muscle, but usually the midpoint of the tendon is most painful.

In some instances the predisposing cause of peritendinitis may be infection of the so-called rheumatic type, and it may be relieved by the removal of a focus of infection or by internal medication; but most often it is induced by strain of the tendon or of the muscular fibers near its origin, or inflammation of its fibrous covering due probably to the same cause. The treatment is similar to that of the milder type of achillobursitis, by the adhesive-plaster strapping, by rest, and latter by massage. Recovery is usually rapid.

TENDINITIS OSSIFICANS.

In rare instances a more or less extensive ossification occurs. It is apparently induced by injury and resembles myositis ossificans.

RUPTURE OF THE TENDO ACHILLIS.

The tendo Achillis may be broken by sudden strain, the rupture being partial or complete. The most common site is at the junction of the tendon and muscle. If the opportunity is offered, immediate operative repair is indicated, otherwise fixation by a plaster support in slight plantar flexion. In neglected cases the tendon is usually long and weak and function is consequently impaired. In such cases it may be shortened by overlapping and reinforced by binding it with a strip of fascia.

Rupture of the plantaris tendon is comparatively common. The sensation is of a sharp blow on the calf. There is often swelling of the calf and extensive discoloration of the skin. Rest, strapping and bandaging usually relieve the symptoms.

PAINFUL HEEL.

Pain referred to the bearing surface of the heel and sensitiveness to pressure on standing are common symptoms of the weak or flat-foot. Pain at this point may be one of the symptoms of achillobursitis also. In rare instances the painful point is clearly localized, and is confined to a small area in the neighborhood of the inner tuberosity of the os

calcis. The cause of the symptoms in such cases may be an inflamed bursa lying between the periosteum and the fatty tissue of the heel. Painful heels are a not uncommon complication of gonorrhea, and in cases of long standing the local inflammation apparently beginning in the musculo-periosteal attachment of the flexor brevis digitorum may result in ossification (exostosis). Projections of bone in this locality are often seen in *x*-ray pictures of normal feet and in many instances a weakened or depressed arch is the exciting cause of pain which an exostosis merely aggravates.[1] Exostoses of this type were first described by Pletner in 1900. They were found in 9 of 100 consecutive autopsies.[2]

More general pain and sensitiveness referred to the heel are often the result of direct pressure and bruising of the tissues incidental to overuse of the feet.

Treatment.—Treatment must be directed to the condition of which the pain is a symptom, and, as has been stated, it is most often one of the symptoms of the weak or broken-down arch. If the sensitive point is localized, and if the pain is increased by jars, a thick rubber heel combined with an inner sole, so cut out as to remove the direct pressure on the sensitive point, will often relieve the symptoms. In persistent cases, in which the sensitive point is distinctly localized, operative intervention is indicated. An incision is made along the outer border of the heel of sufficient length to completely expose the attachment of the plantar fascia. This is divided and reflected forward and beneath it, usually in the substance of the flexor brevis digitorum the exostosis or ossified tissue appears. This should be completely excised together with its periosteum, care being taken to make the new bearing surfaces smooth and flat.

It may be noted that the most common cause of this complication is infection, usually gonorrheal, consequently stiff and painful metatarso-phalangeal joints are often present. The removal of the exostosis is therefore often only the first step in treatment.

Sensitiveness due to direct contusion, or bruising of the tissues caused by overuse, must be treated by rest and by change of occupation, unless reduction of the body weight or improvement in attitudes and local support relieve the symptoms.

PLANTAR NEURALGIA.

Synonym.—Plantalgia.

Pain referred to the sole of the foot and sensitiveness to pressure on the plantar fascia are usually symptomatic of the contracted foot (cavus); less often such symptoms accompany the weak or broken-down arch.

Pain, sensitiveness, and thickening of the fascia sometimes follow injury (rupture of the fascia),[3] and a similar condition has been

[1] Baer: Surg., Gynec. and Obst., July 2, 1906.
[2] Sarrazin: Ergeb. d. Chir. u. Orth., Bd. 7.
[3] Lederhose: Verhandl. d. Deutsch. Gesellsch. f. Chir., XXIII Kong., 1894.

described by Franke as one of the sequelæ of influenza.[1] It may be present, also, in patients who suffer from gout or rheumatism.

Treatment.—Pain in the sole of the foot, symptomatic of the contracted or of the weak foot, may be relieved by the treatment of the conditions of which it is a symptom. In the rare instances in which the fascia is itself injured or diseased, local rest, as afforded by the plaster support, is indicated until the acute symptoms have subsided. If a persistent thickening causes discomfort it should be removed.

VASOMOTOR TROPHIC NEUROSES.

Under this title may be included angioneurotic edema, acroparesthesia, erythromelalgia, Raynaud's disease, and the like affections, functional rather than organic in character, and due apparently to disturbance of the sympathetic system.

Angioneurotic Edema.—Angioneurotic edema is characterized by a sudden localized swelling of the tissues, of a waxy appearance or sometimes of a dark red color. Usually it does not pit on pressure. It is not painful and it disappears in a few days.

Acroparesthesia.—Acroparesthesia is a sensation of numbness and weakness in one or both of the upper or lower extremities usually of a passing character. It is classed as a functional neurosis and is usually induced by overwork.

Acrocyanosis.—Cold cyanotic moist hands and feet, seen most often in adolescents.

Erythromelalgia.—Erythromelalgia[2] is characterized by pain in a defined area usually of the legs and feet, attended by heat, redness, and often by swelling, lasting a few hours. It has a tendency to recur at intervals.

Raynaud's Disease.—Raynaud's disease[3] is a temporary local ischemia caused apparently by spasmodic contraction of the terminal arteries, the "dead finger" being the most familiar example. It may involve any part, even the nose and ears. The affected part is white or cyanotic or red in color, with a lowering of the temperature, although occasionally heat and pain are present. The attacks occur at intervals lasting for a few hours, induced sometimes by exposure to cold. In progressive cases a permanent change in the color and a lowering of the temperature are apparent. Later dry gangrene appears in the tips of the fingers or toes. In this type periarterial sympathectomy is indicated or the more radical ganglionotomy. Adson[4] has performed 162 of these operations on 73 patients with but 2 deaths.

Trench Foot.—This condition is induced by prolonged exposure to cold and wet combined with pressure of the shoes and leggings that further impede the circulation. The symptoms are coldness and

[1] Arch. f. klin. Chir., 1895, vol. **49.**
[2] Weir Mitchell: Philadelphia Med. Times, 1872.
[3] Arch. Gén. de Méd., 1874.
[4] Surg., Gyn. and Obst., Jan., 1930.

numbness and later swelling and pain as the circulation is reëstablished. The physical effects are similar to those of Raynaud's disease—a white or blue appearance corresponding to spasm or paralysis of the vasomotor nerves. The milder cases present eventually simply congestion or edema, discoloration, sensitiveness to pressure and pain most marked at night. In those of the more severe type gangrene may result.

The principles of prevention are self-evident. The first essential in treatment is early diagnosis, when measures to reëstablish vasomotor control—such as rest, massage and the like —are usually effective in a few weeks. In the more severe cases, discoloration, edema, and pain persist indefinitely.

DYSBASIA ANGIOSCLEROTICA AND THROMBO-ANGIITIS OBLITERANS.

Dysbasia Angiosclerotica[1] (*Intermittent Limp*).—The name implies a sclerotic change in the bloodvessels that lessens their capacity. Consequently the blood supply is insufficient for active use. The patient after walking for a time, complains of pain in the calf of the affected leg, "cramps," limps and must rest for a time before resuming activity.

This affection in a mild form is not uncommon in elderly subjects and is relieved usually by accommodating the activities to the diminished nutrition. A more progressive type of the disease sometimes complicates diabetes, resulting in diabetic gangrene.

Thrombo-angiitis Obliterans.[2]—This disease is usually closely allied in symptoms to the preceding, but it is of a much more serious character. It affects young or middle-aged adult males, usually Russian Jews. In a total of 500 cases tabulated by Buerger[3] there were but 3 in females, and all but 4 of the patients were of the Semitic race. It is said, however, to be common in China. It is a thrombotic process involving the veins as well as the arteries, apparently of an inflammatory nature, chronic and irregular in its character, sometimes intermittent as regards symptoms; in some instances becoming quiescent and in others progressing to the extent of causing necrosis in a year or less. According to Buerger, the lesions are in chronological order: (1) An acute inflammatory process with occlusive thrombosis and formation of miliary giant-cell foci; (2) the stage of organization or healing, with the disappearance of the miliary giant-cell foci, the organization and canalization of the clot, the disappearance of the inflammatory products; (3) the development of fibrotic tissue in the adventitia that binds together the artery, vein and nerves. The symptoms are pain on walking rather than standing, cramps in the limbs, numbness and pain at night when the feet are on the horizontal plane.

[1] Charcot: Gaz. de Paris, 1850.
[2] Leo Buerger: Am. Jour. Med. Sci., January, 1910.
[3] Meleny and Miller: Ann. Surg., May, 1924.

The disease is usually confined to the lower limbs below the knees, and in the beginning it is usually unilateral.

Blood tests show nothing distinctive, although Buerger states that a considerable increase of the leukocytes is sometimes noted in the early or inflammatory stage. No specific organisms have been discovered.[1]

The diagnosis is easily made from the symptoms and from the appearance of the foot which is cyanotic or of a dusky red color when dependent, the pulsation of the arteries being weak or imperceptible. In typical cases the pain and disability are progressive. Dry gangrene follows, as in 77 per cent of 155 cases observed by Silbert,[2] and amputation is required. The etiology is obscure. Excessive smoking, has by some been considered a factor and hyperactivity of the suprarenal glands has also been suggested as a possible cause. The treatment is unsatisfactory. It would seem that prolonged rest at an early stage of the disease might be the most efficacious remedy for an inflammatory process. In the advanced stage hypodermoclysis with Ringer's solution, 500 cc., every second or third day, has been employed with apparent relief of pain. Bier's treatment and the Klapp suction appliances have been used to induce venous congestion.



FIG. 713.—The anterior tibial artery showing the thrombosis in the upper end which has become organized below.

Ligation of the femoral vein or anastomosis of the femoral artery and vein, and sympathetic ganglionectomy[3] with the aim of increasing the blood supply by developing the collateral circulation have apparently been of service. Extirpation of the suprarenal glands has also been suggested as a remedy by Oppel.[4]

Recently favorable results have been reported by exposure of the lower part of the trunk, front and back alternately, at weekly intervals, to the roentgen-ray for about fifteen minutes (5 ma., 1000,000 volts, 5-mm. aluminum filter, 15-inch distance). The favorable results are ascribed to increased phagocytosis, the development of collateral circulation and to biochemical changes.[5]

Periarterial Sympathectomy.—This operation, first advocated by Leriche,[6] is designed to increase the blood supply of the limb by cut-

[1] Surg., Gynec. and Obst., February, 1923.
[2] Jour. Am. Med. Assn., September 27, 1927.
[3] Adson and Rowntree, Surg., Gynec. and Obst., January, 1930.
[4] Zeit. f. Chir., 1923, No. 2.
[5] Phillips and Fennick, Jour. Am. Med. Assn., June 16, 1925.
[6] Lyon's Chir., 1913, **5**, 10.

MEDICAL LIBRARY
OF THE
BOSTON CITY HOSPITAL

ting off the contracting influence of the sympathetic system from the main artery. In the class of cases under consideration it would be especially indicated for Raynaud's disease, caused by spasmodic contraction of the arteries, and by contrast should be of little service for thrombo-angiitis obliterans, in which the vessels themselves are diseased.

In the lower extremity the femoral artery is exposed in Scarpa's space. Just below its division the sheath of the superficial femoral is opened and the underlying adventitia is completely separated by blunt dissection from the artery, exposing a smooth, glistening surface for a distance of 2 to 3 inches, and is removed.[1] The immediate effect of the operation is to cause contraction of the artery to be followed by dilatation, a perceptible reddening of the part below and rise in local temperature that persists for several weeks. The operation has proved of service in a variety of conditions, particularly for trophic disturbances after injury involving the nerves or as the result of anterior poliomyelitis, for painful ulcerated stumps, for chronic, ulcers and for scleroderma.

Sympathetic Ganglionectomy. Adson performs a more radical operation than that of Leriche or Royle. He removes completely the second, third and fourth lumbar ganglia on one or both sides, together with the sympathetic trunk, thus interrupting all of the gray rami below the first lumbar ganglion.

For the upper extremity the lower cervical and first and second thoracic ganglia are removed through a posterior thoracic incision with rib resection. The increase in the blood supply appears to be permanent and the operation has proved to be of benefit in cases of chronic arthritis.

THE INJECTION TREATMENT OF VARICOSE VEINS.[2]

The Hospital for Ruptured and Crippled has always provided stockings and bandages for varicose veins, and in recent years since the color and contour of the limbs are no longer concealed by the skirts, there has been a very general interest in treatment by the injection method.

Its purpose is to set up a local irritation and thrombosis, and eventually the transformation of the vein to a fibrous cord. The essentials of the procedure are to distend the vein sufficiently by pressure from above so that a small needle may be readily inserted into its lumen. Three to 5 cc. of a 20 per cent solution of sodium salicylate are injected and a pad is applied. One or several injections are made and the subsequent treatment as to the amount and strength of the solution are determined by the effect on the patient, particularly by the momentary

[1] According to Camera, the injection of a solution of sodium citrate between the superficial and muscular coats simplifies the dissection. McClintic (Jour. Am. Med. Assn., March 23, 1929) cuts off the nerve supply by injecting 2 cc. of 95 per cent. alcohol between the coats in a manner to form a ring about the artery.

[2] For literature see McPheaters and Rice: Jour. Am. Med. Assn., October 13, 1928.

cramp-like pain in the leg. Great care must be taken that the fluid does not escape into the subcutaneous tissues. There is some local sensitiveness attendant on the subsequent "venitis."

Dr. Kahle, who has been in charge of the treatment in my service, prefers a solution of quinine hydrochloride for treatment of the smaller veins, 0.266 gram, and urethran, 0.133 gram, in 22 cc. of water. This is prepared for use in ampoules. It is practically painless and a wider area may be injected at each sitting, beginning with the lower branches.

HALLUX RIGIDUS.

Synonyms.—Hallux flexus, painful great toe.

Hallux rigidus is a painful affection of the great toe-joint, characterized by restriction of motion, particularly of the range of dorsal flexion. In advanced cases the first phalanx may be slightly plantar flexed, together with its metatarsal bone; hence, the name hallux flexus, applied by Davies-Colley, who first described the affection.

The restriction of motion may be complete, as implied by the term rigidus; the joint appears unduly prominent or enlarged, usually slightly congested, and pressure or forced movement causes pain.

Fig. 714.—The dotted outline shows the shape of the steel splint that may be inserted in the sole of the shoe for hallux rigidus.

The symptoms of which the patient complains are a burning or throbbing pain in the joint, increased by standing, and particularly by walking, because of the enforced movement of the stiff and painful articulation. There are many cases in which there is no actual deformity of the joint or other noticeable change; the restriction of motion is much less, and the symptoms are correspondingly slight.

Etiology.—Typical hallux rigidus is most common in adolescence, and it is very often associated with the weak or broken-down foot. In such cases the toe is forced into the narrow part of the shoe, and is thus subjected to lateral and to longitudinal pressure, as well as to the additional strain that the attitude, characteristic of the weak foot, throws upon it. In some cases the habitual plantar flexion of the toe may be the result of an instinctive effort to support the weak arch (hammer-toe flat-foot). In other instances hallux rigidus is caused directly by traumatism, as by stubbing the toe, by kicking a hard object, or by other form of strain or injury. The affection appears to be, primarily, a form of periarthritis. The restriction of motion is in part due to muscular spasm, and in part to the irritative and accommodative changes in the ligaments and tendons. In more advanced cases changes in the cartilage and shape of the articulating surfaces, due to disuse of function and to pressure and friction, may be present.

Treatment.—If the stiff and painful joint is not associated with a weak arch, it may be relieved by providing the patient with a proper shoe which exerts no pressure on the sensitive part. Motion of the joint may be lessened by increasing the thickness of the sole, or, if necessary, it may be entirely restricted by the insertion of a brace of tempered steel between the two layers of the sole, as shown in the diagram or by a sole plate within the shoe. If, as in some instances, the flexed and painful toe is associated with rigid flat-foot, both deformities may be overcorrected, under anesthesia, and retained in proper position by a plaster bandage, as a preliminary treatment.

FIG. 715.—Hallux rigidus and flat-foot, showing the persistent flexion of the toe on the metatarsal bone.

If the milder type of painful joint is associated with the ordinary weak foot, the treatment of the latter condition will usually relieve the symptoms. In this class, particularly among the poorer patients, the shoe may be raised on the inner side and the sole stiffened by means of the wedge-shaped sole, as already described in the treatment of the weak and flat-foot. If motion is restricted, and if the exciting causes of the disability are removed, relief of the symptoms is usually immediate. In the chronic cases, in which the pathological changes are more advanced, excision of the head of the metatarsal bone may be necessary.

Painful Great Toe-joint in Older Subjects.—A similar condition of the joint is sometimes found in older subjects. In many instances the foot is well-formed, and the restriction of motion in the joint is very slight; yet forced dorsal flexion causes pain, and long standing or

walking induces discomfort, particularly a dull ache in the joint and sharp neuralgic pain referred to the terminal phalanx. In some cases the onset of the symptoms may be ascribed to a long walk or "mountain climb," in others to wearing tight shoes, and in some instances no definite cause can be assigned by the patient. In cases of this type the symptoms are often supposed to be evidences of gout or rheumatism and in certain instances there is a distinct hypertrophic change corresponding to Heberden's nodes on the fingers. In such cases the local treatment that has been described in the preceding section should be combined with appropriate medication. In those cases in which the joint is enlarged by actual overgrowth of cartilage or bone with discomfort on movement and pressure, operative treatment is indicated. (Fig. 716). The joint is exposed by a lateral incision. A wide flap of capsule is separated from the base of the phalanx and turned backward,

Fig. 716.—Local arthritis deformans of the great toe-joint.

exposing the joint. The hypertrophied articulating surface of the metatarsal bone is then removed with a Gigli saw or chisel and the extremity made smooth with a file; the flap of capsule is turned in between the bones and the wound is closed. If on examination the joint cartilage appears to be in fair condition, it may be sufficient to remove the marginal projections, thus reducing the head of the metatarsal bone to less than the normal size and preserving the articulation.

As has been mentioned, pain referred to this joint is a common symptom of the weak foot and of the contracted foot as well. It is also caused by simple pressure on the joint, and by the use of improper shoes which force the toes into the abducted position.

INJURY OF THE SESAMOID BONES.

Sensitiveness to pressure and discomfort on dorsal flexion of the great toe referred to the plantar surface of the joint may be due to fracture

of a sesamoid bone or to inflammation of the tendon sheath or neighboring tissues. The medial bone is usually involved. The *x*-ray demonstration of fracture may not be conclusive as congenital separation into two or more parts is not uncommon.[1] Cases of osteitis fibrosa of the sesamoid bones have been reported apparently of the nature of Köhler's disease.[2]

If relief of pressure by the use of an arched foot plate is not effective the affected bone should be removed.

HALLUX VARUS.

Adduction of the great toe is not infrequent in infancy, and it may be associated with a slight degree of varus deformity (Fig. 717). The peculiarity attracts the mother's attention because of the difficulty of drawing on the socks. In many instances the adductor muscles seem abnormally developed, and the toe appears to be somewhat prehensile in its movements.

FIG. 717.—Simple congenital varus, adduction without inversion—a form of pigeon-toe.

Treatment.—The abnormal mobility may be checked by enclosing the toes with a narrow strip of adhesive plaster; in any event the ordinary shoe may be depended upon to correct any residual deformity of this character. If the adducted toe is combined with varus, the deformity must be corrected in the ordinary manner. (See Talipes.)

Pigeon-toe.—Congenital hallux varus forms one variety of what is known as pigeon-toe or the habitual turning in of the feet in walking. The inward rotation may be due also to bow-legs, or it may be an effect

[1] Freiberg: Am. Jour. Orthop. Surg., August, 1920.
[2] Grief: Zentralbl. f. Chir., December, 1927.

of congenital talipes that persists after the cure of the deformity, or of the exceptional variety of coxa vara in which the depressed necks of the femora are turned forward. In most instances, however, pigeon-toe in childhood is symptomatic of weakness either of the arch of the foot or of the knees (genu valgum). In such cases it is a conservative effort of Nature to check further deformity, and it needs no treatment other than that which may be applied to the weakness or deformity of which it is a symptom.

Fig. 718.—An appliance constructed of leather bands and elastic webbing for the correction of in-toeing.

In the exceptional cases, in which the posture is not symptomatic of weakness or the effect of deformity, the sole of the shoe may be raised slightly on the outer border. This will correct the attitude in the milder type, if combined with instruction and training. In rare instances the in-toeing seems to be caused by limitation of the range of outward rotation at the hip-joints, a restriction that must be overcome by systematic stretching of the contracted parts. In these and in the more

Fig. 719.—Metatarsus varus.

obstinate cases of the simple type apparatus may be applied, similar to that used in the after-treatment of congenital club-foot, to hold the feet in the proper attitude (Fig. 718). It must be borne in mind that the proper attitude of the feet is one of parallelism, not of outward rotation, and that slight pigeon-toe will, as a rule, correct itself as the child grows older.

METATARSUS VARUS.

This is a deformity in which the metatarsus is adducted on the tarsal bones. It may be congenital, a variety of talipes varus, but in its typical form it is combined with valgus deformity of the posterior division of the foot. The most effective treatment, if the deformity is well marked, is forcible correction under anesthesia, thus converting a compound deformity into a simple flat-foot. The corrected foot is fixed for a sufficient time in a walking plaster support and later the flat-foot is treated in the usual manner (Fig. 719).

HALLUX VALGUS.

Hallux valgus is a deformity in which the great toe is turned outward to an exaggerated degree. Outward deviation of the toe induced by the shoe is so common that it is not recognized as a deformity, at least from the popular stand-point, unless the joint appears to be much "enlarged," forming a so-called bunion.

Hallux valgus is practically a subluxation. In well-marked cases the metatarsal bone is adducted or turned inward, so that an abnormal interval separates its head from its fellows, while the phalanx is displaced outward and articulates only with the outer condyle. The angle thus formed, or, more properly, the inner condyle of the adducted metatarsal bone, makes the prominent or "outgrown" joint (Fig. 737). This projects sharply beneath the skin, and being exposed to injury and to the pressure of the shoe, a bursa often develops beneath the skin, while a corn or callus forms on its superficial surface. The projecting bone, the bursa and the thickened tissues make up the typical bunion.

In many instances the other toes are displaced outward, all the metatarsal bones being somewhat adducted, and in extreme cases the great toe may be rotated on its long axis and lie above or beneath its fellows. As a secondary effect the forefoot is broadened and the metatarsal arch is depressed. The deformity is often combined with weak foot, although in many instances the arch is of normal height.

Etiology.—Hallux valgus is the direct effect of shoes that are too narrow, too pointed, and in some instances too short for the foot, so that the great toe is subjected to lateral and longitudinal pressure. The deforming effect of the shoe is increased if the foot is weak, so that the toe is forced forward into the narrower part of the shoe when weight is borne. The deformity may be induced or aggravated by injury or by the changes that follow gout, rheumatism, infectious arthritis, diseases of the nervous system and the like. In rare instances the distortion may be the direct result of such diseases, or there may be a congenital predisposition to the deformity, since it is sometimes seen in young children, but all other factors are of slight importance when compared to the influence of the ordinary shoe. The deformity begins at a very early age; it advances more rapidly during adoles-

cence, but the symptoms do not often become troublesome until later years. Both great toes are affected, as a rule, although the deformity and its accompanying symptoms are usually more marked on one side.

Pathology.—The pathological changes are such as usually follow deformity, disuse of function, and injury. The cartilage on the exposed condyle atrophies, the sesamoid bones, together with the tendon, are displaced outward, the tissues on the outer side undergo accommodative shortening, while those on the inner side are correspondingly lengthened and attenuated. The surface of the bone beneath the irritated periosteum is often roughened and irregular, and exostoses may form about the condyle, and thus aggravate the effects of the lateral pressure.

Symptoms.—As has been stated, the slighter grades of deformity are not recognized as such, and it is usually because of the pain due to the irritated corn or bursa, and incidently because of the outgrown joint, that the patients apply for treatment.

Treatment.—The symptoms in the ordinary cases may be relieved by providing a proper shoe, by which pressure on the joint is completely removed (Figs. 679 and 734). The shank should be narrow so that the upper leather may hold the arch securely. The sole should be strong, and it should be slightly thicker along the inner border, so that the sensitive joint may be inclined away from the upper leather. In cases in which the deformity is slight the use of a suitable shoe that allows space for an improved position of the great toe, combined with methodical manual correction of the deformity and exercise of the disused muscles while the toe is guided in the proper direction by the fingers, will relieve the symptoms promptly and lessen the distortion. If the longitudinal or the metatarsal arches are depressed they should be properly supported (Fig. 689). Several forms of corrective braces have been devised, to be worn during the day, a digitated stocking and special shoe being, of course, necessary.

A simple device for holding the toe in an improved position is the Holden toe-post, recommended by Walsham and Hughes. This is a thin piece of metal so fixed in the front and inner side of the sole of the shoe that it separates the first and second toes from one another and holds the former in an improved position. It, of course, necessitates a special shoe and a special shoemaker to fit it in its proper place.

Sampson[1] makes the toe-post of tin and places it in a cardboard inner sole, as illustrated in the diagrams (Figs. 720 to 723).

The use of a splint at night is also of some service. For this purpose a piece of celluloid about one-eighth inch in thickness, one inch in width, and about six inches in length may be used. This, having been molded to the proper contour by placing it in hot water, is secured by tapes to the inner side of the toe and foot.

It may be stated that in the class of cases that can be successfully treated by mechanical correction very few patients will be found who

[1] Johns Hopkins Bulletin, January, 1902.

MEDICAL LIBRARY OF THE BOSTON CITY HOSPITAL

are sufficiently interested in the cure of the deformity to submit to the slight discomfort that the wearing of even a carefully adjusted brace entails.

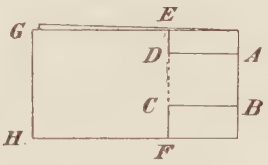

FIG. 720.—Making the pattern for a toe-post. A heavy piece of paper folded once along the line *AB*, *ADE* and *BCF* are cut away, leaving the tongue *ADCB*. *AD* should equal the depth of the shoe at that point, and *AB* should be as wide as the length of the slit in the cardboard inner sole. The tongue is inserted in the slit, and the bases folded back and cut away to conform to the front of the inner sole. When removed and straightened out this forms the pattern, Fig. 721.

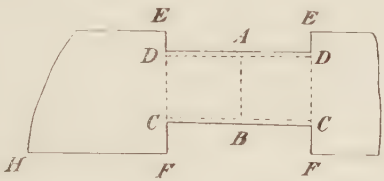

FIG. 721.—Pattern of paper from which the tin is cut. The edges *DD* and *CC* are to be turned in. Tin is folded along the dotted lines *AB*—*DC* and *DC* forming the toe-post in Fig. 722.

FIG. 722.—Shows the toe-post ready to be inserted into the cardboard inner sole. Rough points on the upper and under surfaces of the base, which are made by punching holes with an awl, hold the toe-post to both the inner sole of the shoe and the cardboard inner sole.

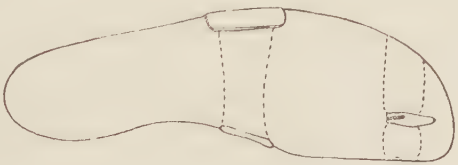

FIG. 723.—Cardboard inner sole with toe-post and foot adductor attached. (Sampson.)

Operative Treatment.—In cases in which the deformity is noticeable or in which the projecting condyle or the exostoses make protection of the sensitive joint difficult, an operation is indicated. The primary object of the operation is to remove the projecting bone. This may be accomplished by a slightly curved incision about the inner aspect of the condyle, the center being below the joint, so that the scar will not be subjected to pressure. The flap of skin is raised, the capsule is split

and separated, exposing the head of the metatarsal bone. With a sharp chisel the disused projecting portion of the articulating extremity of the metatarsal bone is split off in the axis of the shaft, so that the entire internal surface is flat and smooth. Contracted tissues that resist a corrected position of the toe are stretched or divided, and the capsule and skin having been closed with catgut, a plaster bandage is applied about the foot and toe. This may be worn with advantage for several weeks. The after-treatment consists in the use of a proper shoe and daily manual adduction of the toe, in order to retain the improved position. In some instances it may be advisable to lengthen the extensor tendon of the toe or even to transplant it to the internal surface of the phalanx. It should be borne in mind, however, that in most instances the patient wishes to be relieved of discomfort and of a noticeable projection. The abducted toe is not considered as a deformity but merely an adaptation to the shoe and its complete correction which would necessitate a shoe with a wide front in this class of cases would be considered an undesirable result. The use of a flat-foot brace for a time is of service in relieving pressure on the joint.

Resection with chisel or Gigli saw of the head of the metatarsal bone is the most effective operation if the deformity is extreme. It should not be employed in ordinary cases, as the removal of the head of the bone lessens the direct support of the inner border of the foot and limits effective flexion of the toe. In such cases a long flap of the capsule, the base of which is attached to the metatarsal bone or the bursa, should be interposed between the extremity of the metatarsal bone and the phalanx to lessen the danger of anchylosis.

As has been stated, hallux valgus is often combined with the weak or broken-down arch and practically always by a depression of the metatarsal arch. In such cases the foot should be supported by a properly fitted brace. This is of special importance after treatment by operation.

Not infrequently in association with hallux valgus and depression of the anterior arch the projecting external condyle of the fifth metatarsal bone causes symptoms similar to those of hallux valgus, and requires similar resection.

Bunion.—The discomfort of hallux valgus is caused in great part by the irritated bursa and the overlying callus. These symptoms may be relieved by rest and by hot applications. Afterward the callus or corn may be removed, and the sensitive bursa may be protected by a bunion plaster. Operative treatment should be deferred until after the acute symptoms have subsided.

HAMMER-TOE.

Hammer-toe is a contraction of one of the toes, usually of the second, in which the first phalanx is dorsiflexed, the second plantar flexed, while the third may be flexed or extended. The contracted toe is overlapped by its fellows; its projecting dorsal surface is sub-

jected to the pressure of the upper leather of the shoe, and the terminal phalanx, forced against the sole of the shoe and compressed by the adjoining toes, becomes flattened into a club or hammer-like form. The nail is distorted and often "ingrown;" in most cases a corn or callus forms upon the extremity of the toe, and a small bursa and corn over the projecting knuckle on the dorsal surface. A third corn or callus is often found beneath the head of the metatarsal bone which has been forced downward by the flexion of the toe.

Fig. 724.—Hammer-toe, hallux valgus, and flat-foot.

Hammer-toe is usually bilateral; it may be congenital and even hereditary, but it is usually caused by shoes that are too short and too narrow. The second toe is deformed most often, because it is the longest and because it suffers most from the lateral compression as well. The deformity begins, as a rule, in early childhood, when, the growth of the foot being rapid, it is more likely to suffer from the effects of outgrown shoes, and socks also.

Symptoms.—The symptoms are practically those of the corns or blisters caused by the pressure of the shoe, but they are often sufficiently troublesome to interfere seriously not only with the comfort, but with the ability of the patient.

Treatment.– The resistance to the rectification of the deformity is caused by the accommodative changes that follow habitual malposition. In cases of long standing all the tissues may be involved in the contraction, of which the most resistant are the shortened capsular and lateral ligaments of the first interphalangeal joint.

The congenital hammer-toe of the infant may be treated by daily manipulation, the toe being held in proper position by narrow strips of adhesive plaster passed over and under it and about its fellows or a thin strip of lead may be molded about the toes for the same purpose. In older children a digitation in the stocking will often hold the toe in place if the deformity is slight and if a wide shoe is worn. In adult cases, in addition to the manipulation and shoe, a retention apparatus, in the form of a light plantar splint, or stiffened inner sole to which the toe can be attached, should be worn. If the deformity is more resistant the toe may be straightened by force, aided, if necessary,

by the subcutaneous division of the contracted ligaments; but in ordinary cases the only effective treatment is resection of the joint for the purpose of inducing anchylosis. Sufficient bone in the form of a wedge, base upward, together with the thickened skin, should be removed to permit the correction of the deformity. The two bare surfaces are then sutured in apposition. A splint of celluloid or other material may be worn for a time until union is complete.[1] By this operation permanent relief may be assured, and it is to be preferred to the mutilation of amputation.

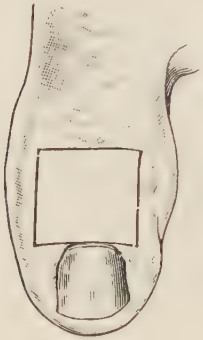

FIG. 725

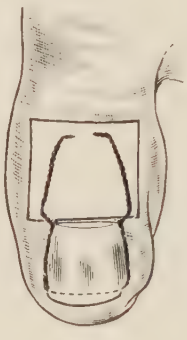

FIG. 726

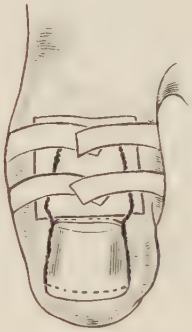

FIG. 727

INGROWN TOE-NAIL.

Ingrown toe-nail is a direct result of improper shoes. The most important predisposing cause is weak foot. Both factors must be considered in treatment, operative or otherwise.

The figures (Webb) illustrate an effective treatment of the milder type of this affection. A square of adhesive plaster is placed at the base of the nail. Twisted silver wire, No. 26, is drawn beneath the nail and is fixed in position by adhesive strips. If all pressure is removed the normal relation of the nail to the lateral tissue is gradually resorted.

Operative treatment consists in the removal of a sufficient section of the nail and its matrix together with the soft parts that have overlapped it.

OVERLAPPING TOES.

Overlapping toes are very common among adults, owing to the pressure of the narrow shoe; and not infrequently such deformity is seen in infancy of apparently congenital origin. Deflected or deformed toes may be treated in infancy by manipulation and by support in the manner described.

In childhood persistent manual correction and proper shoes will usually overcome acquired deformity. In older subjects an inner sole

[1] Laming Evans removes the head of the proximal phalanx, hollows out the base of the distal phalanx and apposes the two bare surfaces.

somewhat like a sandal, to which the toes may be attached by bands of tape, may be employed if the deformity is considered of sufficient importance by the patient to demand treatment.

EXOSTOSES OF THE FOOT.

Simple exostoses of the foot, as distinct from those that are congenital or incidental to disease, are, in most instances, induced by pressure upon a projecting bone of a somewhat deformed foot. The common examples are the hypertrophy of the navicular (often seen in weak foot of young children), the projection of the cuneiform bones on the dorsum of the hollow or contracted foot, the hypertrophy of the internal condyle of the first metatarsal bone complicating hallux valgus. Exostoses on the posterior aspect of the os calcis often accompanying achillobursitis, or those on its under surface are often the result of infectious diseases, particularly gonorrhea.

As a rule the treatment of the deformity of the foot and the removal of pressure will relieve the symptoms without other treatment. Operative removal is indicated when such treatment is not effective.

Subungual Exostoses.—In some instances the "exostosis" is a duplication of a terminal phalanx, causing elevation of the nail and discomfort. Operative removal is indicated.

FRACTURE OF THE METATARSAL BONES.

Fracture of a metatarsal bone, most often near the anterior extremity of the second or base of the fifth, may occur without apparent cause other than walking. The pain and the subsequent swelling in such cases may be inexplicable until the diagnosis is made clear by a roentgen-ray picture. The accident is well known in military practice as an incident of marching. The symptoms may be relieved in most instances by plaster strapping and by a steel sole plate that supports the metatarsal arch. Fracture near the base of the fifth metatarsal usually occurs when the heel is off the ground and the foot is inverted.

KÖHLER'S DISEASE OF A METATARSAL HEAD.

Köhler's disease, so-called because of its similarity to the similar affection of the scaphoid resembles fracture in its symptoms of sensitiveness to pressure and to forced motion. It presents in the roentgen-ray picture a flattening or other irregularity of the articulating extremity of the affected bone, usually the second metatarsal (arthritis deformans). It was first described by Freiberg, under the title of infraction of the metatarsal head. It is apparently caused by disturbance of the circulation and limited necrosis. The symptoms and treatment are similar to those of fracture. Resection may be indicated if the symptoms persist. (See Fig. 426.)

SUPERNUMERARY BONES.

Supernumerary bones are of interest because they may be mistaken in roentgen-ray pictures for small fragments broken from the adjoining bone, particularly as they are often unilateral. In order of importance they are:

1. The os trigonum, at the base of the posterior surface of the astragalus, behind the internal or external tubercle (Fig. 729).

2. Os tibiale externum, behind and below the tubercle of the scaphoid (Fig. 730).

3. Os peroneale, apparently a sesamoid bone in the tendon of the peroneus longus at the anterior outer extremity of the os calcis.

4. Os Vesalii, at the base of the fifth metatarsal bone.

5. Secondary os calcis, at the superior-anterior extremity of the os calcis. This bone may cause fusion between the os calcis and scaphoid and thus limit lateral motion.[1]

FIG. 728.—Congenital exostosis of the fifth metatarsal bone.

6. Intercuneiform, between the external and middle cuneiform bones.

7. Intermetatarsum, between the bases of the first and second metatarsal bones.

The group 1 to 4 is fairly common, 5 to 7 rare.[2]

In 100 consecutive roentgen-ray pictures of normal feet, supernumerary bones were present in 30.

Of these the most important are the first and second. The os trigonum may be injured by sudden, forced plantar flexion of the foot, or it may be a factor in fracture of the posterior margin of the tibia. The posterior tubercle of the astragalus which is closely allied to the os trigonum may be either fractured itself or cause injury to the tibia by forced contact.

The os tibiale externum broadens the foot and irritation or pressure

[1] Badgley: Arch. Surg., July, 1927.
[2] Geist: Am. Jour. Orthop. Surgery, 1914.

FIG. 729.—Showing os trigonum and os tibiale externum (Fig. 706) in the same individual (bilateral).

FIG. 730.—Showing os trigonum (Fig. 729) and os tibiale externum in the same individual (bilateral).

FIG. 731.—Os peroneale and projecting posterior tubercle of the astragalus resembling os trigonum.

FIG. 732.—Showing the projecting process of the astragalus and fracture of the tibia.[1]

[1] Simon: Arch. f. orthop. u. unfall. Chir., August, 1925.

MEDICAL LIBRARY
BOSTON HOSPITAL

at this point as incidental to the treatment of flat-foot may cause a sensitive swelling. In persistent cases the removal of the bone and the underlying articulating surface is indicated (Geist[1]).

DISPLACEMENT OF THE PERONEAL TENDONS.

Permanent displacement of these tendons forward of the malleolus is not uncommon as a result of paralytic deformity, particularly talipes calcaneus, and in such instances it gives rise to no symptoms. Displacement of one or both of the tendons, or rather a laxity of their attachments that allows an occasional displacement or slipping from the groove behind the malleolus, may cause serious disability, because of the pain that follows the displacement and because of the weakness and insecurity of which the patient usually complains.

The cause of the laxity of the tissues that allows displacement in feet otherwise normal may have been injury, but as the affection is often bilateral, the predisposition may be congenital.

Treatment.—If the displacement is recent, as when it follows injury, the tendons should be replaced, and the foot should be fixed in a plaster support until repair has taken place. If, as in certain instances, dorsal flexion is limited, the restriction should be overcome before the support is applied. If the displacement is habitual, a brace may be applied to restrain those motions at the ankle that induce it. In cases of the milder type a tentative treatment by adhesive-plaster strapping so applied as to prevent dorsal flexion and abduction may be effective. In chronic cases an operation with the aim of fixing the tendons by suturing the displaced sheath in its normal position by deepening the groove in the fibula or forming a covering by a flap taken from the bone may be indicated.[2] If on examination the cause of the displacement appears to be a shortening of a tendon it may be divided and lengthened in the ordinary manner.

SHOES.

The shoe as a factor in the etiology of deformity and disability has been mentioned several times in the preceding pages, but it is a subject of such importance that it deserves especial consideration.

The object of the shoe is to cover and to protect the foot; therefore the one should correspond to the shape of the other. If the feet are placed side by side the outline and the imprint of the soles will correspond to the accompanying diagram (Fig. 733). The outline demonstrates the actual size and shape of the apposed feet, emphasized by enclosing them in straight lines. Thus, each foot appears to be somewhat triangular, being broad at the front and narrow at the heel. The imprint shows the area of bearing surface, and owing to the fact that but a small portion of the arched part of the foot rests upon the

[1] Jour. Bone and Joint Surg., July, 1925.
[2] Neimersheim: Deutsch. Ztschr. f. Chir., 1925, **190**, 96.

ground it appears to be twisted inward. The sole of the shoe, if it is to enclose and support the bearing surface, must conform to this inward turn. It must be straight along the inner border to follow the normal line of the great toe, and a wide outward sweep will be necessary in order to include the outline and thus avoid compression of the outer border of the foot (Fig. 734).

Fig. 733.—Normal feet

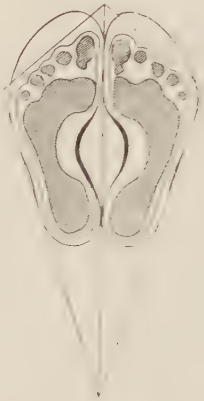

Fig. 734.—Proper soles for normal feet.

This demonstration of the true form of the foot is almost an indispensable preliminary to an intelligent discussion of the relative merits of shoes, and, indeed, it is somewhat of a revelation to those who have

Fig. 735.—Shoemaker's feet.

Fig. 736.—Shoemaker's soles.

thought of the foot only as it has been subordinated to the arbitrary and conventional standard of the shoemaker. The shoemaker's foot, to which lasts conform, is much narrower than the actual foot; the great toe is not a powerful movable member, provided with active

muscles, but is small and turns outward, so that the forefoot is somewhat pyramidal in form and turns upward as if to avoid contact with the ground. This imaginary foot, drawn after the shape of the ordinary last, appears in the diagrams (Figs. 735 and 736). Upon it the sole of the shoe has been indicated, to contrast it with the shape of that necessary to include the outline of the normal foot. The actual foot is thus compressed laterally by the shoe until the stretching of the

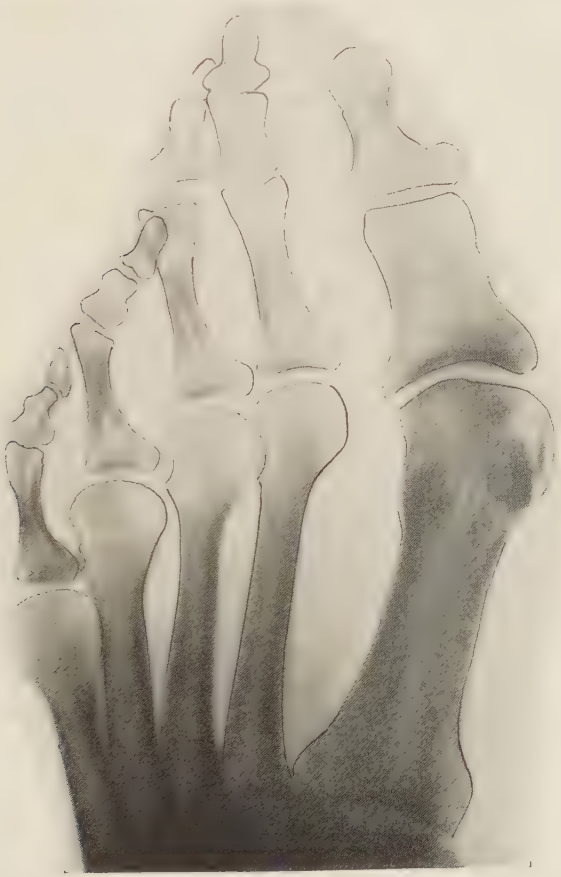

Fig. 737.—Skiagram of a foot remodelled by the shoe, illustrating the etiology of hallux valgus and depression of the metatarsal arch.

leather, during the "breaking-in" process, allows it to overhang the sole. The great toe is forced outward, and, with its fellows, is compressed, distorted, and lifted off the ground by the rocker-shaped sole (Fig. 738). Finally, although in the foot there is a well-marked metatarsal arch (convexity upward), the sole is made with a convexity downward. Thus the foot, according to the age at which the reshaping process is begun and the constancy of the application, is gradually

changed in shape and altered in function (Fig. 737). The high heel often causes an unsightly projection on the dorsum and Wright[1] has reported a number of cases of what he calls "French heel fracture" of the scaphoid. Small fragments are broken from its dorsal surface and form exostoses.

This remodelling, however, is often accompanied by such discomfort that the individual rebels and wears a shoe with a square toe, which, from the conventional stand-point, is supposed to show a meritorious effort to follow Nature. But the demonstration of the actual foot makes it evident that it is a properly shaped sole which serves as a support, not the part which projects beyond the foot, that is of importance. If the shoe with the square toe is wider, and straighter on the inner side than another with a pointed toe, it is insofar an improvement. But, as a matter of fact, one of the worst types of shoe owes its popularity to the square toe.

The object of the heel is to make walking easier by inclining the body somewhat forward. The high, narrow heel is an insecure support, which induces deformity by throwing more strain upon the forefoot and pushing it forward into the narrowest part of the shoe. The

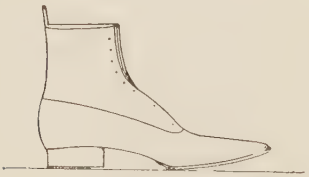

FIG. 738.—The rocker sole.

FIG. 739.—The flat sole.

heel is, of course, unnecessary in childhood, and should not be worn, since it limits the necessity for and therefore the use of the normal range of motion of the ankle-joint. The ordinary shoe, with its stiff shank, by restricting the functional use of the foot, favors awkwardness and improper attitudes. It compresses the toes, and is directly responsible for corns, bunions, ingrown toe-nails, and deformities, and indirectly causes or aggravates nearly every weakness to which the foot is liable. This assertion does not need support of argument, since in some degree it has been proved by the personal experience of every shoe wearer.

The shape of the proper shoe corresponding to the undistorted foot has already been demonstrated (Fig. 734). The sole should be thick enough for protection, but not so rigid as to limit normal motion; it should follow the imprint of the foot, projecting somewhat beyond the outline of the toes; it should be flat from end to end and from side to side (Fig. 739), and the upper leather should be capacious. In other words, the front of the shoe should be designed to permit and to

[1] Ann. Surg., April, 1927.

encourage normal functional activity, the slight adduction of the great toe, and the alternate expansion and contraction of its fellows, as may be observed in the barefoot child. The heel should be broad and low and the shank should be narrow so that the upper leather may be properly fitted to the arch. It should not be braced or stiffened but flexible in order to conform to the sole and to permit free movement. Most adult feet are more or less deformed, and therefore better suited by an improved than by a perfect shoe. In selecting shoes, the breadth of sole, the angle of outward deviation of the soles when the two are placed side by side, and the capacity of the upper leather must be the determining points.

Rubber heels should not be worn by young and vigorous individuals. Elasticity in gait which lessens the shock of impact is assured by the action of the calf muscles, not by a yielding substance beneath the heels.

The most effective reform is to provide proper shoes for children and thus prevent deformity. The inspection of children's feet shows that atrophy and compression begin at a very early age, and if protection could be assured during the period of rapid growth, serious distortion might be prevented.

Socks.—Although of far less importance than the shoes, the socks worn by children deserve special mention as a factor in deformity, since they are often too short and too narrow and are made of unyielding material, so that the proper action of the toes is restrained. The socks, like the shoes, should be rights and lefts, but as these are not in common use one must select those sufficiently large and of a yielding texture.

CHAPTER XXII.

DEFORMITIES OF THE FOOT.

TALIPES.

In the preceding chapters the disabilities of the foot, of which the symptoms were of greater significance than the actual deformity, have been described. One now passes to the consideration of the congenital and acquired disabilities, of which the deformity is the most important feature.

Fig. 740.—Paralytic equinus. Recovery from paralysis, but deformity persists.

Distortions of the foot are, practically, fixed positions in normal attitudes or what are exaggerations of normal attitudes; in other words, the ordinary deformities may be simulated, and the centers of motion, at which the foot is deformed, are the centers of normal motion. If the foot has been fixed in the abnormal attitude during the period of formation and rapid growth, or if it has been used for any length of time in the abnormal position, the deformity becomes exaggerated beyond the possibility of imitation, and secondary variations in its shape, size, and nutrition follow.

The deformities of the foot are grouped under the generic name of talipes, derived from talus (ankle) and pes (foot), signifying, therefore, a form of deformity in which the patient walks upon his ankles. Talipes was thus originally synonymous with the popular term club-foot, but at the present time it is used simply as a prefix to the descriptive titles of the different distortions, while club-foot is usually applied only to the most common of the congenital deformities, equinovarus, in which the distorted foot eventually becomes club-like in form.

Varieties.—There are four *simple* varieties of the distorted foot or talipes.

1. **Talipes Equinus**, the extended or plantar flexed foot. In well-marked cases the patient walks upon the heads of the metatarsal bones, thus equinus (horse-like).

2. **Talipes Calcaneus**, the dorsiflexed foot, in which the heel is prominent, and which alone bears the weight in walking; hence calcaneus, from calcaneum, the heel bone.

In these forms the center of motion is at the ankle-joint. Under the terms equinus and calcaneus are included usually cases of what may be termed potential deformity, in which the range of dorsal or plantar flexion is sufficiently limited to interfere with function, even though the change in the contour of the foot is slight.

3. **Talipes Varus**, the inverted foot. In this deformity the foot is turned in or adducted, and combined with the inward twist there is practically always a corresponding degree of inversion; that is, the inner border of the sole is elevated and the outer border is depressed, so that the weight falls to the outer side of the center of the foot.

4. **Talipes Valgus**, the everted foot. This deformity is the reverse of varus. The foot is abducted and the sole is everted, so that in use the weight falls on the inner border.

In these forms of lateral deformity the centers of motion are at the mediotarsal and subastragaloid joints.

Compound Deformities.—Simple deformities, in which the foot is persistently extended or flexed, or turned in or out, are comparatively uncommon. More often they are combined in varying degree; thus the overextended or the overflexed foot is usually turned inward or outward, making four varieties of compound deformity:

1. **Talipes Equinovarus**, the extended and inverted foot.
2. **Talipes Equinovalgus**, the extended and everted foot.
3. **Talipes Calcaneovarus**, the flexed and inverted foot.
4. **Talipes Calcaneovalgus**, the flexed and everted foot.

In the various forms of talipes the arch may be increased or diminished in depth. It is, for example, usually increased in calcaneus and equinus, and it is usually diminished in valgus; but this secondary or subordinate deformity is not recognized in the ordinary classification. If the arch of the foot is simply exaggerated, the condition is sometimes called pes cavus; if it is lessened or lost, it is called pes planus. These slight degrees of distortion, in which the functional disability is usually more important than the deformity, are rarely

classed as forms of talipes. Simple cavus, the hollow or contracted foot, and pes planus, one of the forms of the common weak or flat-foot, have been described. (Chapters XXI and XX.)

Etiology.—From the remedial stand-point, the cause of the deformity is of far greater importance than its form. Thus, one divides the distortions of the foot into two groups:

1. **The Congenital Form**, in which the foot, in process of formation has become deformed before birth.

2. **The Acquired Form**, in which the foot, normal at birth, has subsequently become distorted.

FIG. 741.—Congenital calcaneus. In this form (simple calcaneus) the arch is obliterated. In the acquired form (calcaneocavus) it is increased.

Congenital talipes may be considered simply as a deformed foot, of which the component parts, although distorted to a greater or less degree, are capable of regaining normal form and function. This is practically true, although slight asymmetry, particularly shortening of the great toe, is not uncommon. There are also exceptional cases complicated by defective formation of the foot or leg, or by paralysis; as, for example, in certain forms of spina bifida or other congenital defect or disease of the nervous system.

The acquired deformity is nearly always a sequel of disease of the spinal cord (anterior poliomyelitis). The motive power is unbalanced by the paralysis of certain muscles and distortion is induced by the contraction of the unopposed muscles and by the influence of gravity.

MEDICAL LIBRARY
OF THE
BOSTON CITY
849

This distortion is confirmed and increased by the accommodative changes in structure that accompany functional use and growth in the abnormal attitude.

Far less often acquired talipes is the result of paralysis of cerebral origin, of other forms of disease of the spinal cord, or of local paralysis following neuritis or injury to a nerve trunk. It may be induced by scar contraction, as after a severe burn, or by direct injury, or by disease that may interfere with subsequent growth. Such are, however, extremely uncommon causes. Thus it is evident that while congenital talipes is in most instances a simple distortion capable of functional cure, acquired talipes, though easily corrected, cannot be cured unless recovery from the original disease, of which it is a result, has taken place.

Etiology of Congenital Talipes.—As of other congenital deformities, the etiology of talipes is conjectural. Occasionally the influence of inheritance is apparent, and, again, two or more children with club-foot may be born of the same mother; but, as a rule, nothing bearing upon the deformity appears in the family or personal history. The most

Fig. 742.—Congenital valgus.

reasonable explanation as applied to the majority of cases is the mechanical. This is, in brief, the theory that the foot has from some cause remained for a longer or shorter time in a constrained or fixed position, and has thus grown into deformity.

It has been claimed by Eschricht[1] and also by Berg[2] that about the third month of intra-uterine life the thighs of the embryo are abducted, flexed, and rotated outward, the legs are crossed, and the feet are plantar flexed and adducted, so that the inner surfaces of the thighs, the tibial borders of the legs, and the plantar surfaces of the feet are held in close apposition to the abdomen and to the pelvis of the fetus. Later there is an inward rotation of the limbs, the feet turning gradually outward until the soles are brought into contact with the uterine wall, the feet then being in the attitude of abduction

[1] Deutsch. Klinik, 1851, No. 44.
[2] Arch. Med., New York, December 1, 1882.

and dorsal flexion. According to this theory, there is a regular succession of attitudes during intra-uterine life. If the inward rotation of the lower extremity is prevented or if it is incomplete, the foot, remaining in the original position, becomes deformed. Thus equinovarus, being the normal attitude of the early and middle period of intra-uterine life is the most common, and the most intractable of the congenital deformities. If the constraint or pressure is not exerted until after rotation has taken place, when the foot has attained or

FIG. 743.—Congenital club-hands and feet, combined with fibrous fixation of many of the larger joints (arthrogryposis multiplex congenita). (Compare with Fig. 744.)

nearly attained its normal size and shape, it will then induce the rarer and comparatively slight grades of deformity, such as calcaneus or valgus.

This theory, which seems interesting and reasonable, appears to rest on a very insecure basis. Bessel Hagen[1] states that in embryos of 30 mm. in length the foot is in extreme plantar flexion; in those of 90 to 100 mm. the foot is at a right angle to the leg; and from this size to that at full term the foot may be found in any position—

[1] Die Pathologie und Therapie des Klumpfusses, Heidelberg, 1899.

abducted, adducted, or dorsiflexed. He states, also, that inversion is not the usual attitude at an early period, but is more common near the termination of intra-uterine life, and when it is present it is more often combined with dorsiflexion. In other words, there is no definite period of intra-uterine life in which the attitude of adduction is constant. Scudder,[1] after similar investigations, arrived at practically the same conclusions. He states that there is no essential relation between the age, the rotation of the limbs, and the position of the feet.

FIG. 744.—The etiology of congenital club-hands, club-foot and fibrous fixation of the joints is indicated by the attitude at birth. In cases of this type the actual deformity may be gradually corrected by splints or by plaster and the range of motion in the joints may be increased by methodical manipulation. Division of contracted parts or plastic operations may be indicated at a later period. Photograph at age of three months. (See Fig. 743.)

Whether or not there may be a more or less regular change in posture during fetal life it is evident that constraint favors deformity. If the constraint is slight, and if its influence is exerted at a late period, the deformity will be slight; if it persists from an early period, the deformity will be extreme and resistant.

One of the causes of constraint, and thus of ultimate deformity, appears to be the interlocking of the feet. Many museum specimens show this, and in some of the cases of talipes seen during the first weeks of life the feet may be replaced in the attitude in which they had

[1] Boston Med. and Surg. Jour., October 27, 1887.

been fixed before birth (Fig. 742). Intra-uterine pressure, although not usually the direct cause of club-foot, undoubtedly has an influence in aggravating the deformity. The effect of pressure is not infrequently shown in atrophic areas of skin, and bursæ even are sometimes found over prominent bones.

Entanglement in the umbilical cord, the direct pressure of intra-uterine or extra-uterine tumors and the like may be mentioned also as possible causes.

Evidence of restraint and of abnormal attitudes of the limbs is seen not infrequently in connection with club-foot; for example, in hyper-extension or fixed flexion of the knees, and in extreme deformity, the foot is often smaller than normal and otherwise asymmetrical.

Fig. 745.—Intra-uterine "amputations." The patient is a tailor.

The distorted foot may be imperfect in structure; toes may be absent, "spontaneous amputation" (Fig. 745) or constricting bands about the leg or foot may be present. Such abnormalities are usually ascribed to amniotic adhesions. Talipes may be combined with evidences of impaired or arrested development; with hare-lip, exstrophy of the bladder, spina bifida, and absence of patellæ; or with other deformities, such as club-hand and wry-neck, fixed flexion at the knees, and the like; or there may be evidence of intra-uterine disease, as in anchylosis of joints (Fig. 743) or so-called fetal rickets. Finally, deformities of the foot may be accompanied by other deformities and malformations, showing evidently an abnormality in the original make-up of the germ. This latter group, which includes the complica-

tions of club-foot and imperfection of structure, is comparatively small, for, as has been already stated, in the great majority of cases congenital club-foot is a deformity capable of practical cure.

Statistics.—The most accurate statistics are those compiled from the records of the Hospital for Ruptured and Crippled, of 4718 individual cases of talipes. Of these 2103 were congenital and 2615 were acquired. The relative frequency of the congenital and acquired forms of talipes has given rise to much discussion in the past, and statistics on this point are at considerable variance with one another. This may be explained by the fact that acquired talipes is, as a rule, a preventable deformity. At the present time the extreme degrees of acquired talipes are comparatively rare, and the deformity is usually of a much slighter grade than the corresponding form of congenital distortion.

	Males.	Females.	Total.
Sex of congenital talipes	1355	748	2103
Percentage	64.4	35.6	
Sex of acquired talipes	1416	1199	2615
Percentage	54.1	45.9	

In a total of 1206 cases from various sources tabulated by Isigkeit,[1] there were 790 males, 66.1 per cent, and 416 females.

Congenital talipes is much more common among males than among females. All statistics are in accord upon this point. Acquired talipes is more equally divided between the sexes.

	Right.	Left.	Both.	Total.
Foot affected in congenital talipes	643	552	908	2103
Percentage	30.4	26.1	43.5	
Unilateral 1195 = 57.5 per cent.	Bilateral 918 = 43.5 per cent.			

	Right.	Left.	Both.	Total.
Foot affected in acquired talipes	1126	1102	387	2615
Percentage	43	42.1	14.9	
Unilateral 2228 = 85.1 per cent.	Bilateral 387 = 14.9 per cent.			

In congenital talipes the deformity is nearly as often of both as of one foot, while in the acquired form unilateral deformity is far more common. In each variety the right foot appears to be more often affected than the left.

The Relative Frequency of the Different Forms of Congenital Talipes.

	Cases.	Percentage
Equinovarus	1629	77.4
Valgus	144	6.8
Varus	89	4.2
Calcaneovalgus	87	4.1
Equinus	49	2.3
Calcaneus	47	2.2
Equinovalgus	35	1.6
Calcaneovarus	10	
Cavus	5	
Valgocavus	1	
Equinocavus	1	
Different deformity in each foot	54	

[1] Arch. f. Orthop. Chir., October, 1927.

Relative Frequency of the Different Forms of Acquired Talipes Together with the Etiology.

	Spinal.	Cerebral.		Other forms of paralysis.	Traumatic.	Total.	Per cent.
	Anterior poliomyelitis.	Hemiplegia.	Paraplegia.				
Equinovarus	610	59	41	18	56	784	30.0
Equinus	469	102	50	14	43	678	25.9
Calcaneus	313	7	3	9	20	352	13.4
Valgus	205	6	10	1	37	259	9.9
Equinovalgus	163	1	5	1	7	177	6.7
Calcaneovalgus	123	1	1	1	15	141	5.4
Varus	68	8	3	1	10	90	3.1
Calcaneovarus	13	0	1	1	0	15	0.5
Equinocavus	38	0	0	0	2	40	1.5
Calcaneovarus	15	0	0	1	1	17	0.6
Cavus	48	1	1	0	4	54	0.2
Varocavus	2	1	1	0	0	4	
	2067	186	116	47	195	2611	
Deformity different on each side	387	—	—	—	—	—	

Anterior poliomyelitis . . . . . 2067 = 79.9 per cent.
Cerebral . . . . . 302 = 11.5 "
Traumatic . . . . . 195 = 7.0 "

Comparative Frequency of the Different Forms of Talipes, Congenital and Acquired.

	Congenital	Acquired
Equinovarus	77.4 per cent.	32.5 per cent.
Valgus	6.8 "	9.7 "
Varus	4.2 "	2.7 "
Calcaneovalgus	4.1 "	4.4 "
Equinus	2.3 "	26.1 "
Calcaneus	1.6 "	12.6 "

It will be noted that in three-fourths of the congenital cases the deformity is equinovarus, and that equinus and calcaneus, rare as congenital deformities, comprise more than one-third of the acquired forms.

Occasionally the deformity is different in each foot, far more often in the acquired than in the congenital form (147 of the former, or 38 per cent., of the 387 acquired bilateral deformities as compared with 54, or less than 6 per cent., of the bilateral congenital). In 7 of 18 of the congenital cases the deformity was equinovarus on one side, calcaneus on the other; in 3 equinovarus and calcaneovalgus, and in 3 simple varus and valgus. In congenital cases the most common combination is equinovarus on one side and calcaneus on the other. Next equinovarus and calcaneovalgus.

In 31, or 4 per cent., of 735 cases of congenital talipes the distortion was combined with other congenital defects or deformities, viz., in 12 cases with double club-hands; in 6 cases with defective development of the hands, webbed fingers and the like; in 7 cases with spina

bifida; in 3 cases with absence of one or more bones of the leg; in 1 case with torticollis, in 1 case with hare-lip; in 1 case with dislocation of the knee and anchylosis of an elbow; in 2 cases with general rigidity and deformity of the joints.

The Anatomy of Congenital Club-foot.—Talipes Equinovarus.—Congenital talipes is, in the great majority of cases, the form in which the foot is turned inward and downward, so that in extreme cases it resembles the club-like extremity that has received the popular name of club-foot. The ordinary congenital club-foot in early infancy is simply a foot fixed in an exaggerated attitude of plantar flexion, adduction, and inversion. The dorsum of the foot looks forward and slightly outward and upward, the plantar surface is abnormally con-

FIG. 746.—Typical congenital equinovarus (club-foot).

cave, and looks backward, inward, and downward. The foot often seems somewhat smaller than normal, and the heel appears to be ill-formed. Upon the outer dorsal surface the body of the displaced astragalus projects; the external malleolus is prominent, while the internal malleolus lies deep beneath the redundant tissues of the internal aspect of the foot.

In many instances the turning inward of the foot is so extreme that it conceals the equinus element of the deformity (Fig. 746). Thus equinovarus is often classified as varus, especially by English authors.

The internal structure of the foot corresponds to the external contour; thus the relation of the bones to one another, and even the shape of the individual bones, are more or less altered as the deformity is

more or less of an exaggeration of the attitudes that the normal foot is capable of assuming. These changes are most marked in the astragalus and os calcis. The astragalus is thicker at its external than at its internal border, or somewhat wedge-shaped from without inward; it is plantar flexed, so that a large part of its body protrudes from between the malleoli. Its neck is often somewhat longer than normal, and is depressed and deflected inward (Fig. 747, *B*). The os calcis is also in an attitude of plantar flexion; the internal tuberosity is drawn upward to the vicinity of the internal malleolus, its anterior extremity looks downward and inward, and it is often bent inward, corresponding to the deformity of the neck of the astragalus. Its external surface looks downward and forward, and it lies directly beneath the astragalus instead of to its outer side, as in the normal relation.

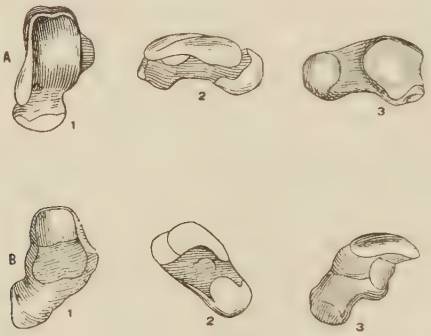

FIG. 747.—The deformities of the astragalus in club-foot: *A*, astragalus of a normal infant; *1*, from above; *2*, from within; *3*, from without. *B*, the astragalus in club-foot in the same position. (Adams)

The navicular is drawn inward and upward, and articulates with the inner part of the deflected head of the astragalus; it lies in close proximity to and is often in contact with the internal malleolus; the cuboid is displaced upward and inward, and lies to the inner side of the anterior extremity of the os calcis. The remaining bones are changed in position, but not materially in shape. In many instances the tibia is rotated inward upon the femur, and this inward rotation of the leg may persist after the deformity of the foot has been corrected. Less often the tibia is slightly twisted inward on its long axis. In other cases there is often a moderate degree of knock-knee and laxity of the ligaments at the knee. As a rule, however, these are secondary or compensatory effects of club-foot that do not appear until the child begins to walk.

The ligaments and muscles correspond to the changed relations of the bones. The muscles are normal as to their structure and their origin and insertion, but those attached to the inner side, the extensor and adductor group, are shortened and are relatively stronger than the opposing muscles which are lengthened and atrophied from disuse.

MEDICAL LIBRARY OF THE BOSTON CITY HOSPITAL

To sum up: all the component parts of the foot participate in the deformity. The most resistant structures of the deformed foot are the plantar fascia and the ligaments that bind the navicular, the os calcis, and the internal malleolus to one another. The muscles that are most active in retaining and increasing the deformity are the tibialis anticus, the tibialis posticus, and the combined gastrocnemius and soleus.

The changes that have been outlined, which are comparatively slight and which may be easily rectified soon after birth, become more marked as the part develops; and when the child begins to walk the weight of the body, combined with growth and functional use in the abnormal position, increases and fixes the deformity.

In the adolescent or adult type of club-foot that has never been treated, the deformity is so extreme that the patient actually appears to walk on the outside of his ankles, as the term talipes implies. The feet turn directly inward, or even inward, upward, and backward, and the peculiar walk, by which interference of inverted feet is avoided, has given another name (reel foot) to the deformity.

In such cases knock-knee is usually well marked. This, although it may be present at birth is, as has been stated, usually a secondary distortion caused in great part by the accommodation to the deformity; that is, by the diminution of the base of support and by the interference of the feet (Fig. 751).

FIG. 748.—Acquired talipes equinovarus in adolescence, showing the displacement of the astragalus and its relation to the scaphoid also the atrophy and distortion of the bones of the leg.

The legs are shrunken from disuse. Over the outer border of the foot, in the neighborhood of the calcaneo-cuboid articulation, there is a large callus with an underlying bursa. The foot itself is atrophied and is smaller than the normal. The changes in the bones are much more marked; only a small part of the articulating surface of the astragalus lies between the malleoli, and this posterior extremity is flattened out to the shape of a wedge. Thus, the leg bones appear to be displaced backward in relation to the foot, a change most

apparent in the position of the external malleolus. The bones of the foot are more or less atrophied, and the cartilage has in great part disappeared from the articular surfaces of the disused joints.

In these neglected cases the foot is practically a simple rigid support, to which the patient has been so long accustomed that he may walk with comparative ease and with no discomfort other than that caused by the callosities and bursæ at the pressure points.

Fig. 749.—The tendons on the front of the foot in acquired talipes equinovarus.

Fig. 750.—The tendons in the sole of the foot and the extreme displacement of the os calcis.

Symptoms.—The symptoms of congenital club-foot have been, to all intents, included in the description of the deformity. The functional disability is, of course, considerable, although some patients are surprisingly active and are able to walk long distances. As the discomfort from club-foot is due almost entirely to the corns or inflamed bursæ over the bony prominences, its degree depends, of course, upon the use to which the foot is subjected.

Treatment.—In considering the treatment of congenital club-foot it is customary to divide it into several classes corresponding to the degree of resistant deformity.

The first class would include the very slight or non-resistant cases in which the deformity may be almost entirely corrected by slight manual force.

The second class comprises those cases in which a certain degree of varus and equinus persist, which it is impossible to overcome by manipulation.

The first and second classes include the forms of infantile club-foot.

The third class comprises the cases of more extreme deformity and those in which the resistance to the correction is great, as in many of the cases in early childhood or those of later years that have been inefficiently treated.

A fourth class would include the untreated cases in the adolescent or adult.

FIG. 751.—Neglected club-foot, showing the secondary knock-knee.

Congenital club-foot (talipes equinovarus) treated at the proper time—that is to say, in early infancy and in a proper manner in a great majority of cases—may be cured both as to form and function.

The club-foot in childhood, in which treatment has been delayed or in which it has been ineffective, may be practically cured, but a certain limitation of motion and more or less atrophy of the foot and leg persists as a consequence of the disuse of normal function.

Club-foot in the adult may be made straight, but restoration of perfect function, is of course impossible.

Although congenital club-foot is an eminently curable deformity, yet complete and permanent cure requires minute attention to details

during active treatment, supplemented by careful supervision long after the cure is supposed to be complete. No other deformity presents such a record of failures and incomplete cures, of relapses after apparent cure, of tedious and ineffective treatment by braces, and of unnecessary and mutilating operations. Some of the failures may be explained by neglect or by lack of opportunity. A few are due to the unusual obstacles in the deformity itself, but by far the greater number must be accounted for by failure of the physician to apprehend the true nature of the deformity or by his inexperience in the practical details of treatment.

Principles of Treatment of Infantile Club-foot.—The infantile club-foot is, as has been stated, simply a deformed foot. It is true that there are slight changes in the bones; but the bones of an infant's foot are represented by yielding cartilage, which will rapidly reform under changed conditions. The shortened tissues may be easily stretched and when the proper relation of the bones to one another has been restored the joints will undergo an accommodative transformation which will permit normal movement.

The treatment of club-foot may be divided into three stages:

1. The rectification of the external deformity.

2. The support of the foot in proper position during the process of transformation of its internal structure and until the normal muscular balance has been regained.

3. The period of supervision. This would include the treatment of possible complicating deformities at the knee, the laxity of ligaments and the like, as well as the oversight of the functional use of the foot and the limb during the early years of life.

The normal infant moves the foot in various directions, in a more or less regular alternation of postures, but the motion of the club-foot is in one direction only, that toward which the foot is turned. The muscles on the back and inner side of the leg, which are alone active, become relatively irritable and hypertrophied as compared with those on the front and outer side that are disused. Thus movement of the deformed foot is in reality harmful, because it increases deformity and still further disturbs the muscular balance. For this reason the temporary restraint of motion, required for the correction of the deformity, may be considered rather of advantage than otherwise. When movement is again permitted it must be in the directions opposed to the deformity.

The First Stage of Treatment.—Rectification of Deformity.—"Rectification of deformity" must not be mistaken for restoration of symmetry, a misapprehension to which the majority of failures in treatment may be ascribed. It means that when deformity is really rectified all contracted and resistant parts must have been so elongated that every passive motion and attitude possible for the normal foot is equally possible and as easily attained in that which was deformed. This is functional rectification as contrasted with the simple correction of deformity.

The most important part of the deformity is varus. The foot that is rolled over and twisted inward to the attitude of extreme inversion (Fig. 746) must be untwisted and placed in an attitude of extreme abduction or valgus, the so-called overcorrection (Fig. 742). Until this is accomplished no attention whatever need be paid to the residual equinus. There are two reasons for this: First, that the attention of the surgeon may be concentrated on one and the most important part of the deformity; second, because by this preliminary untwisting the os calcis is brought into the upright position, into its proper relation to the astragalus, to the bones of the leg, and to the tendo Achillis, so that the true degrees of equinus may be appreciated.

Preliminary Manipulation.—As a rule the second or third week of life is as early as mechanical treatment can be undertaken. Until then preliminary manipulation by the nurse, more particularly manual straightening of the deformity by gently drawing the foot toward abduction and retaining it in the improved position for a few minutes, as often as is possible, may be of service in overcoming its resistance. As a treatment by itself, however, simple manual correction is tedious and ineffective, although partial cures have been attained by perseverance in this means alone.

Mechanical Treatment.—This is the treatment of choice and routine for infantile club-foot, and two methods may be described:

1. By the plaster bandage.
2. By some form of simple splint.

The principle of the two is essentially the same. The foot is drawn toward an improved position and retained there by the plaster bandage, or it may be fixed to some form of metal splint or brace the shape of which is gradually changed from week to week, as the resistance lessens.

Gradual Rectification of Deformity by Means of the Plaster Bandage.—In this treatment care should be taken to avoid undue pressure, irritation of the skin, or insecurity of the bandage. One should place shreds of cotton between the toes; and the outer aspect of the ankle, where the skin is thrown into folds when the foot is straightened, should be powdered or smeared with vaseline. A thin layer of cotton is wound about the leg, just below the knee, in order to protect the skin from the hard margin of the plaster bandage, and a similar strip is carried about the toes. The foot is then drawn gently toward the abducted position as far as may be without causing discomfort. While it is held in this attitude a narrow bandage, preferably flannel or cotton flannel, is smoothly applied to the leg and foot.

A very light plaster bandage is then applied from the extremities of the toes nearly to the knee (Fig. 752). The turns of both the plaster and the flannel bandage should be made from within, downward and outward, so that the tension aids in retaining the foot. When the plaster bandage, which during the hardening process has been constantly rubbed and manipulated so that it may fit the part perfectly, and which need not be thicker than blotting paper, has become firm, a long stocking is drawn over it and is attached to the

body clothing. At the end of a week the bandage is removed. The leg and foot are gently bathed with alcohol, thoroughly dried, powdered, and protected as before, and the bandage is again applied. At this second dressing the irritable adductor muscles, after the interval of complete rest, will be much less active and the contracted tissues will be less resistant, so that the foot may be in many instances easily turned somewhat outward or beyond the line of the leg. If for any reason the support does not hold its position a narrow strip of adhesive plaster is applied to the outer or inner surface of the leg, its lower end being turned back and incorporated in the plaster bandage, which is then fixed in position by direct adhesion to the skin.

FIG. 752.—The first application of the plaster bandage, showing the improved position. (Compare with Fig. 746.)

After four or five applications of the bandage, at weekly intervals, the foot, in ordinary cases, may be held without resistance in the attitude of extreme eversion. The sole, which at first looked backward, inward, and upward, will be turned in the opposite direction, forward, outward, and downward, and the inner border of the foot, which was concave, is now convex (Fig. 742). When the varus has thus been overcorrected, treatment is directed to the secondary equinus which has been already partly reduced. At first one carries the foot upward (toward dorsal flexion), while it is still retained in the abducted position, but after one or two treatments, when the right-angled attitude has been attained, it is brought nearer to the axis of the leg. The everted position, or the attitude opposed to varus, is retained, however,

until correction is completed. In correcting the equinus a certain degree of force may be required, sufficient to cause some discomfort during the application of the plaster, but not sufficient to occasion suffering afterward. The force is applied to the entire foot, so that the posterior extremity of the os calcis may be drawn downward by actual lengthening of the tendo Achillis, and not, as is often the case, by an overcorrection of the forefoot, while the heel remains in its original position of plantar flexion. By the proper application of force the equinus is gradually overcome; the sharp indentation or fold at the insertion of the tendo Achillis is lessened, and the heel becomes more prominent.

The reduction of the equinus may be somewhat more difficult than that of the varus, but it should be entirely corrected in three or four months from the time of beginning the treatment. As has been stated, correction of the deformity implies overcorrection (Fig. 741); and it is well, when this has been attained, to hold the foot for several weeks, by means of the plaster bandage, in an attitude of extreme eversion and dorsal flexion (calcaneovalgus) in order to impress, as it were, the new position upon its structure. This concludes the first stage of the treatment, the simple rectification of deformity.

Correction by the plaster bandage has the great advantage of placing the treatment entirely under the control of the surgeon. The application even in resistant cases should at most cause but temporary discomfort and usually none whatever. The support fits perfectly; it is light and clean, and it holds the foot in the desired attitude without undue pressure.

The disadvantages of the treatment are due almost entirely to its improper application. For instance, too much force may be used in correction or the bandage may be too tight or too heavy, or the padding may be so thick that it does not retain its position. Excoriations are usually due to carelessness in the application of the bandage, or because it is not removed in proper season. The fear of compression or of atrophy of muscles or of stunting the growth is groundless. At the end of the treatment the corrected foot is, as a rule, larger than one that has remained untreated. The stunted foot is the result of non-treatment, or of ineffective treatment by braces or otherwise, not of the temporary inactivity necessitated by the reduction of deformity.

The Rectification of Deformity by Splints and Braces.—Of mechanical supports there are many varieties. Complicated appliances should be avoided because they are unnecessary and because they serve to distract attention from the rapid and systematic correction of deformity. Of the simpler braces, that used by Judson is one of the best and will serve as a type to illustrate this form of treatment. The method of application may be described in Judson's own words: "The apparatus which I have conveniently used to effect this reduction before the child learns to stand is a simple retentive brace which acts as a lever, making pressure on the outer side of the foot and ankle

at *A*, in Figs. 754 to 756, inclusive, and counter-pressure at two points, one on the inner side of the leg at *B*, and the other at the inner border of the foot at *C*. It is advisable to keep in mind that this simple instrument is a lever, because if we know that we are using a lever with its three well-defined points of pressure we can make the apparatus more efficient than if we view it, in a more general way, as an apparatus for giving a better shape to the foot.

"I use a little brace made of sheet brass, doing the work with a few simple tools. An advantage of doing the work one's self is that there is no room for doubt as to where the blame lies if the apparatus does not work well. Two curved disks, *B* and *C*, Figs. 755 and 756, are riveted to a shank, *D*, and thus is formed that part of the brace

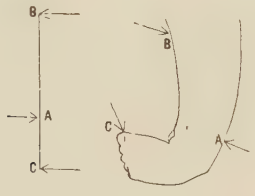

Fig. 753

Fig. 754

Fig. 755

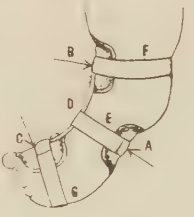

Fig. 756

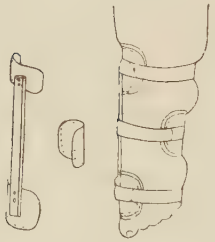

Fig. 757 Fig. 758

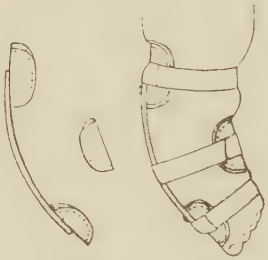

Fig. 759 Fig. 760

Figs. 753 to 760.—The Judson club-foot splint and its application.

which applies the two points of counter-pressure; while, on the other hand, the point of pressure is brought into action by a third disk or shield, *A*, which is drawn tightly against the outer side of the foot and ankle and held in place by a strip of adhesive plaster, *E*, which includes the leg and the piece which connects the two disks, *B* and *C*. The disks are lined with two or three thicknesses of blanket, easily renewed, when necessary, with a needle and thread. These braces are so cheap and easily knocked together that it is nothing to apply new and larger ones, using heavier material for the shank as the child grows. In general, three sizes will be enough, the shanks being 12-gauge, $\frac{3}{8}$ in. wide; 14-gauge, $\frac{1}{2}$ in. wide; and 16-gauge, $\frac{5}{8}$ in. wide. The disks are conveniently made from 22-gauge, $1\frac{1}{4}$ in. wide. The rivets are copper belt-rivets, No. 13. A lip turned on the edges of the

disks, with the flat pliers, gives stiffness to the thin brass and protects the skin from the rough edge. If more easily obtained, tin disks, light bars of iron or steel, and ordinary iron rivets would doubtless answer.

"The brace is applied with three strips of adhesive plaster. The upper and lower pieces, *E* and *G*, Fig. 756, are simply to keep the apparatus in place, which they do effectively if ordinary gum plaster is used; while by drawing the middle strip, *E*, tightly over the shield, and straightening the brace from time to time, the deformity is gradually and gently reduced. At each reapplication the brace is made a little straighter than the foot at that stage. This may readily be done by the hands, and then the adhesive strip is to be tightened over the shield until the shape of the foot agrees with that of the brace. After a few days the brace is to be made still straighter and again reapplied, and made tight until another point of improvement is gained. The brace is applied very crooked at the beginning of treatment, as in Figs. 755 and 756, and is straightened from time to time, and a longer brace applied as the deformity is reduced and the patient grows.

"By this simple and prosy treatment, carried out systematically and without haste, or violence or pain, the foot, unless it is a frightful exception, may with certainty be changed from varus to valgus. At the same time the tendo Achillis is lengthened until the position of the foot is near the normal, or at right angles with the leg, as the result of manipulation and giving the brace from time to time a partly anterior-posterior action. Figs. 755 and 756 show approximately the shape of the brace at the beginning of treatment; Figs. 757 and 758 when the varus is reduced, and Figs. 759 and 760 when valgus has taken the place of varus. The foot, in this latter stage, may not hold itself when left to itself, but with almost no force and with one finger it may be pushed into valgus."

When the varus deformity is reduced the equinus is gradually corrected by carrying the splint behind the internal malleolus; and finally, if necessary, direct upward pressure may be applied by lengthening the brace and applying it to the posterior aspect of the foot and leg. It may be noted that manipulation and stretching the contracted parts when the brace is removed is of much importance in the correction of deformity by this or other means. Splints of wood, tin, felt, and the like may be employed, but they present no particular advantage over that which has been described.

Tenotomy.—The equinus has been spoken as of secondary importance, although its complete correction by mechanical means may be more difficult than that of varus. When this deformity is especially resistant, time will be gained, after the foot has been forced into the position of equinovalgus, by the division of the tendo Achillis. It may then be necessary to use considerable force to stretch the other contracted parts that limit extreme dorsal flexion. The chief obstacle in such cases is the posterior ligament connecting the tibia with the base of the astragalus, and it is often advisable to divide this structure,

in part at least, so that it will give way under manipulation. The tenotome is inserted on the inner side of the tendo Achillis on a plane with the extremity of the inner malleolus, passed directly downward to the bone and the resistant tissues are cut across from within outward, care being taken to avoid the posterior tibial artery.

It may be noted in this connection that there are two contrasting types of deformity seen in early infancy: one in which the foot is well modelled and another in which there is apparently no heel because the posterior extremity of the os calcis is closely apposed to the posterior surface of the tibia. In such cases early tenotomy and division of the ligaments are indicated.[1] When the foot has been forced into the position of overcorrection it is fixed by a plaster support for several weeks, until the interval between the separated ends of the tendon is filled in with the new tissue.

FIG. 761.—The adhesive-plaster support as used after correction of the deformity.

In some instances the leg is rotated inward upon the thigh, and the habitual attitude is accompanied by accommodative changes in the ligaments of the knee-joint. During the treatment of the club-foot this secondary distortion may be, in part at least, corrected by forcible manual rotation of the leg outward on the thigh several times daily. If the leg is slightly bowed it may be corrected in the same manner.

The Second Stage of Treatment.—Support and Restoration of Function.—When the deformed foot has been corrected, in the sense that normal movement is no longer restricted, the first and most difficult part of the treatment will have been completed. But although the foot may be normal in appearance, its muscular balance has not been restored. This is shown by the fact that when support is removed the foot usually hangs downward and inward, and there is little apparent power in the dorsiflexors and abductors to draw it upward and outward. If at this stage treatment were abandoned, the deformity would inevitably recur, at least in part. For this reason the foot must be

[1] Zadeck and Barnet: Jour. Am. Med. Assn., September 29, 1917.

MEDICAL LIBRARY OF THE BOSTON CITY HOSPITAL

supported in proper position until the slack of the lengthened tissues has been taken up by development in the normal attitude, a development that may be aided by massage and other forms of stimulation of the muscles. Practically, support is always necessary until the child has begun to walk.

Retention by Adhesive Plaster.—In cases of the milder type, in which the deformity has been easily and quickly corrected, temporary support only is indicated, and for this purpose adhesive plaster will often serve. A narrow strip is first carried about the forefoot, to it a longer band is fixed and is carried up the outer side of the leg to the knee, where it is held in place by an encircling band. This is applied with sufficient tension to hold the foot in abduction and dorsal flexion. A thin foot plate of splint wood is also of service in supporting and flattening the sole. The nurse is then instructed to push the foot up to the extreme limit many times during the day. She is taught also to apply the dressing properly. This support is used until normal motion has been regained.

The Retention Brace.—The form of retention brace will vary somewhat according to the indications of the individual case. Its object is to hold the foot in what is called the overcorrected attitude—that is, dorsiflexion and eversion. This may consist of a calf pad and foot plate with an internal flange (Fig. 762) of aluminum joined to one another by a thin steel bar shaped to the heel. The brace is held in place by adhesive plaster and may be removed at intervals for massage and exercise by the mother. One of the most efficient supports for older children is the Taylor brace (Fig. 763). This consists essentially of a light upright that extends along the inner side of the leg to the knee, and a thin steel foot plate of the exact size of the sole, with an upright flange on the inner side, rising to a point just above the dorsal surface of the foot, against which the foot is pressed closely, so that recurrence of the varus deformity is prevented. The joint at the ankle is provided with a catch that prevents plantar flexion, but permits dorsiflexion. By bending the upright and the sole plate the foot may be held in slight eversion. The apparatus is applied with straps, as illustrated, and if necessary it is made more secure by a band of adhesive plaster, applied on the inner side of the leg to hold the heel firmly against the foot plate. The foot is thus held constantly at a right angle to the leg, or, better, in the early stage of treatment, in an attitude of dorsiflexion and valgus.

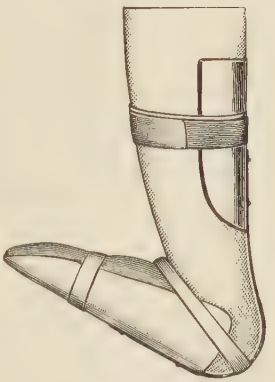

FIG. 762.—A retention brace used in infancy.

Occasionally, after complete rectification of the deformity, the foot still turns in. In most instances this is due to an inward rotation of the tibia on the femur at the knee-joint, but in some cases it

is caused by a spiral twist of the tibia itself. In order to correct this secondary deformity an extension of the upright of the brace is carried beneath the leg, provided with a joint at the knee, and is extended up the outer side of the thigh. At the hip it is attached by a free joint to a padded pelvic band of light steel (Fig. 774). The band holds the upright in the proper relation to the thigh; thus, by twisting the part below the knee the foot can be rotated outward to the desired degree. In less marked cases the retention bands used for pigeon-toe may be employed (Fig. 718).



Fig. 763.—The Taylor club-foot brace.

Methodical Manual Correction.—At least once during the day the brace should be removed in order that the foot may be thoroughly massaged and forcibly turned, first toward valgus—that is, outward at the mediotarsal joint—so that the inner border is made convex, and then to the extreme limit of dorsiflexion and abduction. If the leg is rotated inward it is forcibly rotated outward on the femur. If the tibia is bowed it is methodically straightened. Even if the tibia is actually twisted on its long axis, the influence of the brace and forcible manipulation will usually correct the deformity. Active contractions of the weak muscles may be induced by tickling the sole of the foot or by the use of electricity, and, finally, the entire limb should be thoroughly massaged before the brace is reapplied.

When the deformity shows no tendency to recur the brace may be removed for a part of a day; later it is used only at night; and, finally, it may be discarded if the child walks normally. But it is best to continue the daily manipulation, more particularly the systematic

stretching or overcorrection of the foot, for a long time. Thus one may assure one's self that there is no tendency toward deformity,

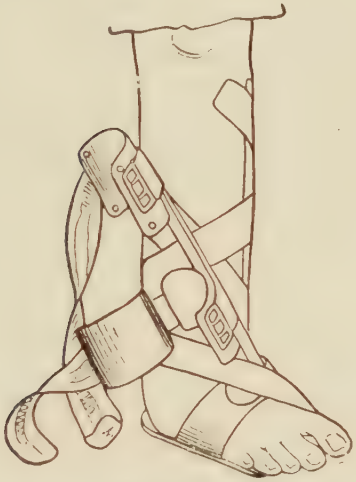

Fig. 764

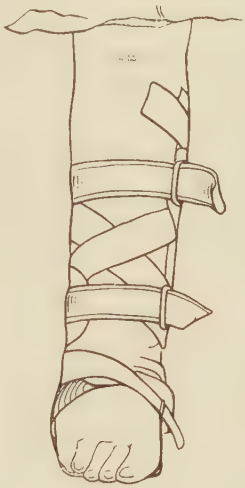

Fig. 765

Figs. 764 and 765.—Taylor club-foot brace as used for the gradual correction of deformity, showing the method of application and attachment.

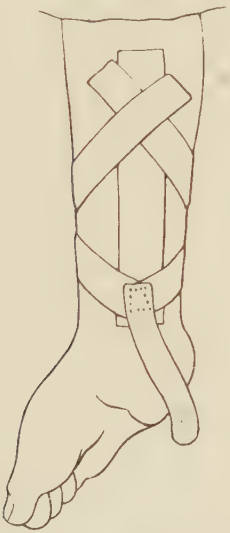

Fig. 766



Fig. 767

Figs. 766 and 767.—The Taylor club-foot brace, showing the adhesive plaster, by means of which the heel is held down, and the method of attachment. This brace was used by Taylor to correct deformity as well as to retain the foot in proper position, as is illustrated by these figures. As a retention apparatus the foot plate should be held at a right angle to the upright by the stop-joint shown in Fig. 764.

of which the first symptom is always a slight limitation of dorsal flexion and of abduction.

In many instances the deformity may have been so thoroughly overcorrected and the after-treatment of massage and stretching may have been so efficiently applied by the nurse or parent during infancy that the retention brace may be unnecessary when the child begins to walk. On the other hand, the inclination toward deformity may be so marked that a brace may be necessary to hold the foot in slight abduction and valgus for a year or longer. In other cases the use of a light brace to hold the foot in the overcorrected position during the night is alone required. These are points to be decided by the circumstances in each case. The period of observation and supervision is included in the final stage of the treatment.

Third Stage of Treatment.—Supervision.—During this period the attitudes of the limb and foot of the walking child must be carefully watched, and particularly the signs of wear on the sole of the shoe. If it shows greater wear on the outer side than is usual it is an indication that the weight does not fall directly on the center of the foot and that there is, therefore, a tendency toward deformity. This must be counteracted by making the sole thicker on the outer side or slightly wedge-shaped, so that the weight may be deflected toward the inner border.

This third period of treatment, or, rather, of oversight of the functional use of the foot, must be continued indefinitely. In fact, it is the quality of this final supervision that decides in most instances whether the ultimate outcome is to be what is called a satisfactory result or a perfect anatomical and functional cure.

The Treatment of Neglected Club-foot.—The treatment of club-foot, under what may be called the proper conditions, as outlined in the preceding pages, applies practically to all cases before the completion of the first year of life, and mechanical rectification may be successfully employed in cases far beyond this limit of age. As a rule, however, when the patient has walked for any length of time, the resistance of the tissues has increased to such an extent that more rapid and effective treatment is indicated. The investigations of Wolff have shown that the internal structure of the bones corresponds to their external contour, and that the structure and contour are adaptations to functional use. This internal structure is not, however, permanent, but is readily transformed to conform to changes of function. If, then the external contour of the club-foot were suddenly reversed, and if the foot were used in this new attitude, a transformation of the internal structure of the bones and at the same time of their shape would begin at once. This would continue until both structure and shape had become adapted to habitual function. It is upon this natural power of transformation that one depends for the final and complete change of the distorted bones to the normal; and what is true of a resistant structure like bone is equally true of the other constituents of the deformed foot.

Age as Influencing Treatment.—There is, then, this important difference between the indications for treatment in infancy and in child-

hood. In the first instance the foot has no essential function; in the second the weight of the body and habitual use tend to confirm and to increase the deformity. If walking is permitted during the process of rectification of the foot it must necessarily retard its progress. As a general principle of treatment, functional use should not be permitted, therefore, until the weight of the body may aid rather than retard the correction of deformity. The complicated and cumbersome machines that are described in the older text-books were designed for the ambulatory treatment of club-foot. The most important function of the brace, aside from its use as a corrective appliance in early infancy, is to support the foot after deformity has been corrected and to guide it in its functional use until its normal strength has been regained.

FIG. 768.—Reduction of the varus deformity. (Lorenz.)

And while rectification of deformity, even in adolescence, by simple mechanical means alone is possible, yet only in exceptional cases would one be justified in selecting a tedious and uncertain treatment which offers practically no advantage over more rapid methods.

The Rapid Correction of Deformity.—The principles on which operative treatment should be conducted are the same that govern mechanical treatment. Thus the deformed foot must be overcorrected, and it must be fixed in the overcorrected position until the immediate tendency toward deformity has been overcome. It must then be supported until the process of transformation of its internal structure is completed and until the balance of muscular power has been regained. No surgical operation, however radical, can be, in childhood at least,

curative by itself alone. Operative procedures are undertaken simply for the purpose of accomplishing the primary overcorrection, and the operation by which this object can be attained with the least interference with the structure of the foot should be selected. Such an operation is what may be called forcible manual correction.

Forcible Manual Correction.—The patient having been anesthetized, one first attempts to correct the sharp inward twist at the mediotarsal joint. Supposing the left foot to be deformed, one grasps the heel with the right hand in such a manner that the projection or muscular part of the palm lies on the outer aspect of the foot against the most prominent part of its outer border, which is at the junction of the os calcis

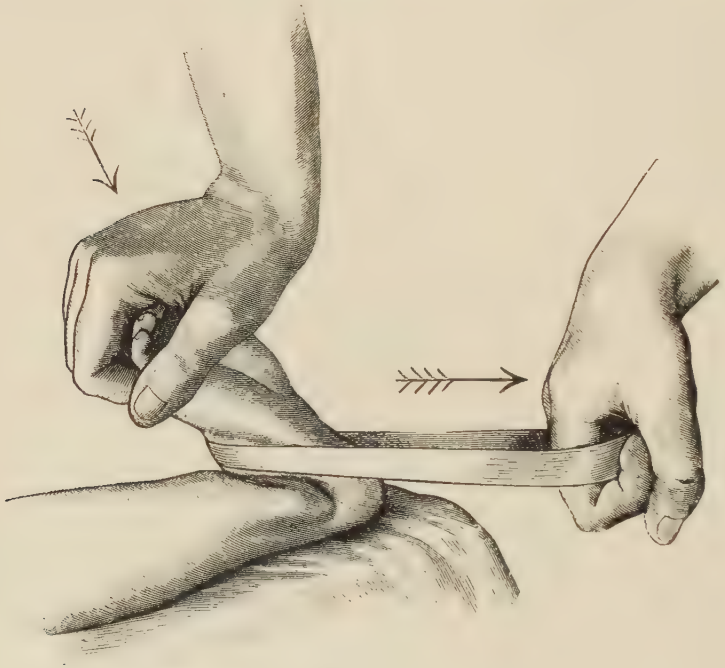

Fig. 769.—Flattening the sole. (Lorenz.)

and cuboid bones. This hand serves as a fulcrum over which the inverted foot may be bent. The forefoot is then grasped firmly by the left hand, and one begins a series of outward twists over the fulcrum of the opposing palm, gently at first, with alternate relaxation of pressure, but with gradually increasing force as the resistant tissues stretch under the tension.

If greater force is required, a triangular block of wood, well padded, may be used as the fulcrum (Fig. 768), one hand pressing on the heel and the other on the forefoot; but there is a great advantage in using nothing but the hands, because one feels that no injurious force is likely to be exerted. Under this steady manipulation the foot soon

loses its resistance and its elastic recoil toward deformity; it becomes so limp that with two fingers one cannot only hold the sole straight but can push it or bend it outward. This completes the first stage of the methodical correction.

One then turns his attention to the inversion of the sole, which makes the outer border of the foot lower than the inner border. The leg is grasped firmly near the ankle with the left hand, and with the right the foot is forcibly twisted in a direction downward, outward, and upward, over and over again, with steadily increasing force as the tissues slowly yield, until it may be forced into a position of extreme abduction, so that the sole may be made to look outward and downward—the reverse of the former attitude.

Fig. 770.—Reduction of the equinus deformity. (Lorenz.)

One next stretches the contracted plantar fascia and reduces the cavus which is usually present by forcing the forefoot toward dorsiflexion, against the resistance of the contracted tendo Achillis, until the sole is made perfectly flat (Fig. 769). Finally, the fourth, and often the most difficult part of the rectification—that of forcing the displaced astragalus into its proper position between the malleoli—is attempted. To accomplish this the tendo Achillis is first divided subcutaneously, and, if necessary, the posterior ligament of the ankle also. The patient is then turned upon his face so that with the knee resting on the table the leg is held upright. This allows one to hook the fingers about the extremity of the os calcis, while the hand and arm, lying along the sole of the foot, may be used as a lever to force

it toward dorsal flexion as the os calcis is drawn downward. In this manner forcible stretching is continued until the dorsum of the foot can be brought almost into apposition with the crest of the tibia. When the operation has been completed the foot should be perfectly limp. It is usually somewhat congested from the pressure of the fingers, but it is warm and the circulation is unimpaired.

One may assume that in the transformation of resistant deformity to yielding tissues that can be molded into the desired shape, the component parts of the deformed foot must have been subjected to considerable violence; that ligaments and muscles must have been stretched and, it may be, ruptured; that new surfaces are now apposed to one another in the articulations, and that the bones have been

FIG. 771.—Untreated club-foot, showing the secondary knock-knee. In such cases correction of the deformity should be divided into stages in order that the circulation may adjust itself to the new conditions. (See Fig. 772.)

forced into approximately normal position. This method of treatment has a great advantage over the ordinary operative treatment in that the entire foot participates in the correction instead of a limited portion, as when, for example, bone is removed by cuneiform osteotomy. It has a second and almost equally important advantage in that the immediate use of the corrected and yielding foot is possible in the place of the rest that must follow cutting operations. For these reasons it should be the operation of choice, and preliminary, at least, to more severe procedures in the treatment of resistant club-foot in childhood. The only disadvantage of the operation is the actual labor which it necessitates on the part of the surgeon, usually twenty minutes or more of rather exhausting work.

MEDICAL LIBRARY OF THE BOSTON CITY HOSPITAL

The foot must now be fixed by a plaster splint in an overcorrected position. It is first evenly covered with a layer of sheet wadding, thick bands of which are inserted between the toes, and while it is held by the assistant in the overcorrected position the plaster bandages are applied from the tips of the toes to the upper part of the thigh. It is important that the toes should not project beyond the bandage because of the swelling that sometimes follows. It is important, also, that the foot should be held in the proper position while the bandage is hardening, and that it should not be manipulated to any extent after the bandage is applied, in order that no projecting wrinkles may press against the skin. The splint often includes the

Fig. 772.—The eventual attitude after forcible correction. Compare with Fig. 773.

Fig. 773.—The attitude of overcorrection, in which the feet are fixed after the operative treatment, the plaster splint extending only to the knees.

thigh, the knee being flexed. This permits the tibia to be rotated outward on the femur and assures better fixation. When the deformity has been corrected an ambulatory plaster splint is applied in overcorrection.

It is of advantage to include the thigh in the plaster splint with sufficient flexion at the knee to assure fixation of the tibia if it is necessary to rotate it outward in order to restore the normal relation of the thigh and leg. The reaction after the operation is usually less than one would expect after such prolonged and forcible manipulation, and if the correction has been completed a walking plaster splint is applied in what is called overcorrection, the foot being dorsiflexed and abducted, as shown in Fig. 773.

Often, in cases of a milder type the patients are able to stand upon the foot in a few days and always within the first week if the support has been properly applied. The pain following this operation is far more often caused by pressure of an ill-fitting bandage than by the direct injury. Thus one should be careful to remove sections of the splint if it appears to cause undue discomfort. These points are usually the front of the ankle, the back of the heel and the inner border of the great toe.

The Importance of Functional Use.—The immediate use of the foot is encouraged, in order that the weight of the body falling on its yielding structure may still further correct the deformity and stimulate the reconstructive process. Although only the heel and inner border bear weight directly, yet the pressure of the plaster sole on the parts that do not come in contact with the floor is usually sufficient to mold the foot into its proper shape. If greater pressure is thought to be necessary, wedges of wood or cork may be attached to the sole of the plaster bandage, to equalize the bearing surface. The support is covered by a stocking; a slipper may be worn indoors and an ordinary overshoe for street wear.

Fig. 774.—The Taylor club-foot brace, with pelvic band, to prevent inward rotation of the leg. The brace is shown before the covering and straps are applied.

The first splint should be removed at the end of about four weeks, as it will have become loose. The foot will then be found to be extremely flexible, and by an enthusiast it might be considered cured; but knowledge of its previous condition should make it evident that a much longer time will be necessary for its consolidation in the new position. At this time almost no evidence of the operation remains except, it may be, slight discoloration of the skin. The foot is again held as far as possible in the overcorrected position and another plaster support is applied, usually as far as the knee only. This remains for from six weeks to six months, according to the character of the deformity and quality of the after-treatment, it being apparent, of course that the longer the foot is fixed in the overcorrected position the less danger of subsequent relapse. The patient uses the foot constantly and is drilled in the proper method of walking, so that the muscles of the limbs may become adapted to normal attitudes.

In most instances the plaster support is replaced, at the end of

about three months, by a brace to be worn inside the shoe, usually of the simplest description (Fig. 790), consisting of an upright bar with a calf band, either fixed to a sole plate or attached by a joint that will permit dorsal flexion but checks extension at a right angle. This is applied because the dorsal flexors, after years of disuse, only slowly recover sufficient power to resist the action of the opposing group and the influence of gravity.

The second stage of the treatment is now begun. This may be divided into a period of active treatment and one of supervision. The first, or treatment-stage, consists in massage of the entire leg and of the foot to stimulate the growth of the atrophied muscles, and methodical manipulation of the foot several times a day. The important point in this manipulation is to force the foot with the hand to the extreme limit of the range of motions possible immediately after the operation, viz., eversion, abduction, and dorsal flexion, in the same order as at the time of operation. At the same time the patient attempts voluntarily to carry out these motions with his own muscles, the power being supplied by the hand of the manipulator. Slowly the muscles gain in strength and ability, and when normal muscular power and balance have been regained, the patient is practically cured. But for a long period supervision of the patient's attitude, of the manner of using the foot, of the wear of the sole of the shoe and the like must be exercised if one aims to restore its normal appearance and function.

One cannot exaggerate the importance of this after-treatment, and of supervision at least on the part of the surgeon. The active treatment may often be left to the parents. But constant oversight is necessary to make this after-treatment, which seems so commonplace and simple, effective, and to assure one's self that the range of motion regained by the operation does not gradually become more and more restricted, even though the contour of the foot appears to be normal. Forcible manual correction may be employed with advantage from the second to the tenth year, although the limits may be extended in either direction in special cases. In this operation, as described, the tendo Achillis is the only structure divided. There is no particular objection to subcutaneous division of other tendons or ligaments in connection with forcible manual correction; but for such prolonged manipulation it is much better if the skin, which itself must be stretched, is unbroken and dry rather than moist from the bleeding from punctured wounds. For this reason it is well to correct the deformity as far as practicable without tenotomy.[1] In resistant cases in older subjects overcorrection may require several operations in accommodation to the shortened tissues and the impaired circulation.

[1] Forcible manual correction appears to have been described first by Delore. Lorenz employs the method supplemented in the older cases by the use of his osteoclast, to the exclusion, practically, of all other treatment. (Heilung des Klumpfusses durch das modellirende Redressement, Wiener Klinik, November, 1895.) For this reason it is sometimes called the Lorenz treatment. The method that has been described has been employed by the author for many years.

OTHER METHODS OF FORCIBLE CORRECTION.

The Correction of Confirmed Club-foot by the Method of Julius Wolff.—Wolff's treatment of club-foot, as described by Freiberg, a former assistant in his clinic, may be summarized as follows:[1] The patient is anesthetized, and with the hands and by the use of a moderate degree of force the deformity is reduced as far as possible. The foot is held in the improved position by means of strips of adhesive plaster passing from the dorsal surface of the inner border of the foot under the sole and up to the outer aspect of the leg. The leg and foot are then covered with cotton from the tuberosity of the tibia to the tips of the toes, and a plaster bandage is applied. As the plaster is hardening the position of the foot is still further improved by pressing the heel inward and the forefoot outward and upward. Two fenestra are cut in the plaster at the points of greatest pressure—one over the external surface of the ankle and the other over the internal surface of the great toe. If tenotomy is considered necessary it is usually performed as a preliminary operation several days before forcible correction.

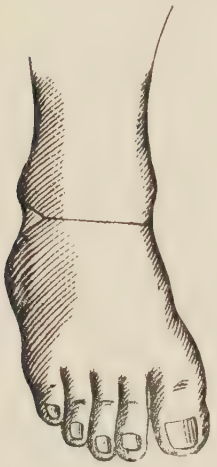

FIG. 775.—The points at which the bandage is divided and the wedge removed. (Freiberg.)

On the third or fourth day after the operation a wedge-shaped section is cut from the bandage on the outer side of the ankle-joint and a linear division is made about the ankle, so that the leg and the foot parts of the bandage are separated (Fig. 775). The leg being held firmly, the foot is forced outward and upward to the extent that the wedge-shaped opening on the plaster will allow, and the two sections are then united by a covering of plaster bandage. For the secondary correction anesthesia is not required. At intervals of several days larger wedges are removed, and the manipulation is repeated until the patient stands with the foot in a satisfactory attitude; that is, in pronation, abduction, and dorsiflexion. If the deformity is extreme the bandage may be reapplied before the correction is completed with advantage. One should take care that the toes are not compressed, but lie on the same plane in normal relation to one another.

When rectification is complete the plaster bandage is covered with strips of pine shavings, held in place by a crinoline bandage, and painted with carpenter's glue. When this is hardened the whole is covered with a thin silicate bandage; over this the shoe is fitted and the patient is encouraged to walk. This form of dressing is used until the transformation of the deformed parts may be supposed to be complete, the time varying with the case, from a few months to

[1] Med. News, October 29, 1892.

a year. The time required for the primary correction is from a week to a month. When the support is finally removed massage and exercise are to be employed.[1] Wolff's treatment is an efficient, though tedious, means of correction that may be employed when operative facilities are not at command.

Forcible Correction of Deformity by Means of Osteoclasts and Wrenches.—In place of manual correction or supplemental to it greater force may be employed by means of wrenches or osteoclasts. There is this important difference between the two procedures: Force may be applied by the hands for as long a time as is necessary without fear of injury, while force applied by a wrench must be momentary because of the pressure and strain on the parts where the leverage is exerted. Manual force continuously applied may be supposed to stretch the resistant parts, and although much less power is exerted it is really more effective than the sudden and momentary force of the wrench or osteoclast, because it may be continued until the deformity has been overcorrected, while complete correction by means of instruments may necessitate several operations.

The Thomas Method.—Of instrumental correction that by means of the Thomas wrench is one of the simplest and most effective. The wrenching may or may not be preceded by tenotomy, a point to be decided by the resistance of the parts. As a rule division of the tendo Achillis alone is necessary. The instrument is a simple heavy "monkey-wrench," of which the jaws have been replaced by two strong pins slightly bulbous at the ends to keep the covers of rubber tubing from slipping off.

The wrench is applied to the inner side of the foot and screwed down so that it may "bite" and hold its place firmly, for if it slips it is likely to abrade or tear the skin; then with considerable force the foot is twisted outward and upward (Fig. 776). The "keynote" of the operation is to so wrench the foot that it loses its elasticity and shows no tendency to recoil toward deformity. The foot is then placed in the best possible position, and is retained there by the Thomas foot splint or by a plaster support. In certain instances one may complete the correction at one operation, but this is not usually attempted, the procedure being repeated at intervals of a few days until the deformity has been overcorrected. In very resistant cases eight to ten applications of force may be necessary. When the deformity has been rectified the foot is held in the overcorrected position for several weeks by the splint or by the plaster bandage.

As a walking appliance a simple upright of iron with a calf band is applied to the inner side of the leg, from a point just below the knee to the heel of the shoe into which it is inserted, as is the Thomas knock-knee brace (Fig. 570). By bending the upright the foot may be held in slight valgus, and this position is still further assured by making the outer side of the sole of the shoe thicker than the inner,

[1] Julius Wolff: Ueber die Ursachen, das Wesen und die Behandlung des Klumpfusses, Berlin, 1905.

so that the weight falls upon the inner border of the foot. In many instances the walking brace may be dispensed with in the after-treatment, but a light brace is usually worn to hold the foot in the corrected position during the night, until the power of the abductors and dorsal flexors has been regained. Massage and manipulation are used in the after-treatment in the manner already described.

When properly applied the treatment is satisfactory and free from danger. Sloughing of the tissues caused by the pressure of the instrument has been reported, but such accidents have not occurred in the extensive practice of Thomas and Jones.

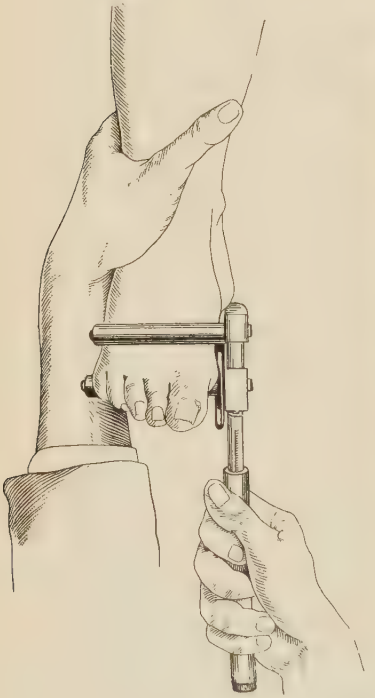

Fig. 776.—The Thomas wrench as used in correction of club-foot.

Fig. 777.—Resistant club-foot in later childhood. (See Fig. 779.)

Correction by Means of the Osteoclast.—Grattan, of Cork, used the osteoclast that goes by his name (Fig. 574) to crush and to overcorrect resistant club-foot. The operation may include besides the correction of the deformity of the foot itself, fracture of the leg above the malleolus, to turn the foot toward valgus, and a second fracture half-way up the leg, to overcome the inward rotation or twist of the tibia. Grattan's results were very satisfactory. Other appliances constructed on somewhat similar principles may be employed.

Of these the Lorenz osteoclast[1] and the Bradford[2] lever apparatus are the most effective.

SUPPLEMENTAL OPERATIONS.

If forcible manipulation is not sufficient for the complete overcorrection of the deformity, division of the resistant tissues is indicated. Of these the most important are the posterior calcaneo-tibial, the deltoid and the superior and inferior calcaneo-scaphoid ligaments. All of these tissues may be divided through an incision from a point above and behind the internal malleolus carried forward below its extremity to the navicular. Through this incision all resistant parts may be divided including, in addition to the ligaments specified, the tendo Achillis and the plantar fascia if necessary, so that the astragalus and os calcis may be placed in the attitude of valgus.

Ober's Operation.—Ober's[3] incision extends from behind the internal malleolus forward to the scaphoid. The deep fascia, annular ligament and anterior part of the deltoid ligament are divided about three-fourths of an inch above the extremity of the malleolus and are dissected in a flap from above downward. The astragalo-navicular ligament is separated from the navicular and if necessary the anterior tarsal ligament from the astragalus. Through the same incision the tendo Achillis may be divided, the tibialis posticus lengthened and the plantar fascia cut. The object of the operation is to completely remove all resistance to the correction of deformity and by displacing the ligaments from above by the so-called periosteal method to cover in the wide gap caused by the correction of the deformity. Operations of this type are rarely indicated and never as a primary procedure.

Malleotomy.—In confirmed club-foot, of the type under consideration, the chief obstacle to perfect correction is often the astragalus. This is displaced forward, downward, and inward, only the posterior portion of its articulating surface being contained between the malleoli. Thus the space between the two bones may have become insufficient for the anterior and wider part of the body of the astragalus. In such cases, even after division of the tendo Achillis and the ligaments of the ankle, dorsal flexion still remains restricted, and examination shows that the astragalus still projects as before, even though the foot has been forced into a position of apparent dorsiflexion and abduction. This apparent correction is the result of overcorrection at the mediotarsal joint, of outward rotation of the tibia upon the femur, and of backward displacement of the fibula.

In such instances the malleoli may be separated from one another by dividing the ligaments that hold them in apposition. An incision is made about the lower border of the external malleolus and sufficiently forward to expose the astragalus. The ligaments binding

[1] Wien. Klinik, November and December, 1895.
[2] Bradford and Lovett: 2d ed., p. 414.
[3] Am. Jour. Orth. Surg., October, 1920.

the tibia and fibula to one another are separated and they are pried apart to provide sufficient space. In many instances a complete division of the attachment of the fibula to the astragalus will be necessary before the proper relation can be restored. Other resistant tissues are divided if necessary, and if the neck of the astragalus is deformed it may be corrected by a linear or cuneiform osteotomy. The wound is then closed and the foot held in the overcorrected position by a plaster bandage. This should be extended to the thigh, the knee being flexed to assure better fixation.

Secondary Deformities.—In cases such as have been described secondary distortions of the limb are often present. Knock-knee rarely requires other treatment than daily manual correction in connection with the massage of the foot and leg. Hyperextension at the knee will correct itself during the treatment of the foot, which, being fixed in an attitude of dorsal flexion, obliges the patient to bend the knee habitually in walking. Inward rotation of the leg upon the thigh is often present. This may be overcome by methodical manipulation and by the use of a brace attached to a pelvic band (Fig. 774).

In many instances, particularly in childhood and adolescence, the exaggerated outward rotation of the femur has become habitual, so that after correction of the deformity the relation of the foot to the limb seems normal even though inward rotation of the tibia be present. In other cases the inward rotation of the foot is caused by a failure to completely replace the astragalus between the malleoli. Occasionally the tibia is actually twisted on its long axis, so that an osteotomy may be required in order to overcome the deformity.

It might seem on first consideration that if immediate correction of deformity may be accomplished so easily in the confirmed cases it should be employed even in infancy. There are, however, practical reasons against it: First, because the foot is so small that it cannot be easily manipulated; second, because even after it is corrected it must be supported until the child begins to walk; and third, because the foot can be so readily straightened without operation, which, even of so slight a character, is sometimes the cause of much anxiety to the parents. For these reasons, although immediate reduction of deformity is a practicable operation, unless especially indicated it is usually postponed until a later time.

Subcutaneous Tenotomy.—The division of tendons and other tissues by the subcutaneous method has been mentioned incidentally, but as it has so long occupied an important and even at one time the most important place in the treatment of club-foot, the operation and its effects may be described somewhat in detail.

Tenotomy, as has been stated, is performed for the purpose of removing an obstacle to the overcorrection of deformity. In the acquired or paralytic form of talipes one or more shortened tendons may be the chief obstacles, but in the congenital form, in which all the tissues have grown into deformity, the shortened tendons are by

MEDICAL LIBRARY OF THE BOSTON CITY HOSPITAL

no means the only resistant parts, and tenotomy should be considered, therefore, merely as an incident in correction. In the ordinary treatment of infantile club-foot tenotomy is usually unnecessary and in the great majority of cases division of the tendo Achillis is alone required.

When the tendon has been divided the deformity is immediately overcorrected; thus the two extremities are separated to the extent necessary for the improved position. At the end of three weeks or more, or at the time when the first plaster bandage is removed, the space will be filled with new material, and in another month the splice, which will be somewhat larger and thicker than the normal, should be strong enough for use. The slight thickening at the site of the operation may persist a year or more, but practically the new and lengthened tendon is perfectly normal, as is the function of the muscle of which it is a part.

The process of repair is somewhat as follows: Immediately after the operation the space between the divided ends of the tendon is filled or partially filled with blood; then leukocytes appear, which, with those in the blood clot, serve as a support for the plasma cells which migrate from between the fasciculi of the tendon and from the tendon sheath. The fibrin and red corpuscles of the clot are absorbed; the extremities of the divided tendon soften and become fused with the new material, which begins to take on the form and consistency of true tendon and to separate itself from the adherent sheath. This new tendon differs from the normal structure in that the fibrous fasciculi are more irregular and its substance is more like scar tissue, but practically it is normal in its appearance and function.[1]

Since the tendon sheath serves an important purpose in repair, it should be disturbed as little as possible. For this, as well as for other obvious reasons, subcutaneous tenotomy of the tendo Achillis, which is so prominent and so distinct from other important parts, is to be preferred; but if more extensive division of other tendons is required the open operation is often indicated.

Division of the Tendo Achillis.—For this operation anesthesia is usually required, and it is hardly necessary to state that surgical cleanliness, even in so slight a procedure, is essential.

The instrument should be small and very sharp, so that no force is required in the operation; the blade should be as long as the tendon is wide. The patient is turned upon the side or to the prone position, so that the foot may be held with the heel upward by the left hand. The position and size of the tendon is ascertained by careful palpation, and the knife is then inserted to its inner side, at about the level of the extremity of the internal malleolus. The flat surface of the blade is held parallel to the tendon, and it is passed beneath it until its point can be left beneath the skin on the opposite side. The edge is then turned upward and the tendon, being made tense, is divided by a sawing motion of the knife. When the division is complete, as indicated

[1] R. Seggel: Beitr. z. klin. Chir., 1903, **37**, 342.

by the separation of the divided ends, the knife is withdrawn, and the minute opening in the skin, from which there is usually slight bleeding, is covered with a pledget of aseptic cotton. The foot is forced into dorsal flexion and is securely fixed by a plaster bandage. In applying the dressing one should take care that no pressure is brought upon the seat of operation, as this might interfere with the effusion of plastic material. As soon as the discomfort attending the operation has subsided the patient is encouraged to stand and to walk. Functional use stimulates the circulation, and, far from retarding repair, it is in my experience an important agent in assuring firm and rapid union.

The Open Method.—The tendon having been exposed by a vertical incision is split for a sufficient distance and the division completed above and below. The two halves are then allowed to slide by one another until the necessary elongation has been obtained. The same operation may be performed subcutaneously, half of the tendon being divided with the tenotome at the usual point; the instrument is again entered 2 inches higher up and a half section made on the opposite side. Under gentle, persistent tension the two segments slide to the desired length. This result is somewhat uncertain, as the tendon may break across instead of sliding. Preferably the division of the tendon may be made from side to side, the knife being inserted high up and splitting the tendon into a long antero-posterior flap. This has the advantage in preserving its width and causing less injury to the meso-tendon. The extremities are then sutured and the tendon sheath carefully closed.

Theoretically, an open operation, which assures union at a point of selection, is safer than the subcutaneous method, in which the ends of the tendon are separated from one another; practically, when the tenotomy is an incident in the treatment of club-foot the subcutaneous method is preferable.

Division of the *plantar fascia* is often necessary. The tenotome is inserted beneath the skin at about the center of the concavity to one or the other side of the central band of the fascia, which is divided by a sawing motion of the knife. The part is put upon the stretch, and other resisting bands to the outer and inner side are divided in the same manner; the cavus is then corrected by manual or instrumental force. The open division has been described (see Contracted Foot).

Division of the *tibialis anticus* is not often necessary, as this tendon offers little resistance to the rectification of deformity of the ordinary type.

The tendon of the *tibialis posticus* may be divided together with that of the tibialis anticus near the points of attachment. If the operation is required it may be combined with simultaneous section of the *calcaneo-navicular ligament*, with which are blended the anterior part of the deltoid and fibers of the anterior ligament of the ankle. The foot should be strongly abducted to make the parts tense. The tenotome is inserted directly in front of the anterior border of the internal malleolus, its cutting edge being turned forward between

the skin and the ligament. It is then turned toward the ligament, and the tissues are divided to the bone. The blade is then made to enter the interval between the astragalus and the scaphoid, and is carried downward and forward to divide the inferior part of the ligament and at the same time the tendons of the tibialis anticus and posticus.

In some instances in which unbalanced muscular action seems to be the chief agent in the distortion—transplantation, instead of division of the muscular attachments may be indicated, as in the treatment of paralytic talipes.

The posterior ligament of the ankle-joint may be divided or sufficiently weakened so that it may be ruptured after section of the tendo Achillis by passing the knife directly downward in the middle line upon the upper border of the astragalus. As has been stated in resistant cases the open operation is to be preferred.

FIG. 778.—Illustrating the correction of varus deformity of the left foot by Phelps operation.

The Open Incision Combined with Forcible Rectification of Deformity.—Phelps' Operation.—The Phelps' operation, although now rarely performed, is of historical interest because it originally represented correction of advanced deformity by the combination of force and division of resistant parts as contrasted with extensive resection of the bones in accommodation to the contracted tissues.

The steps of the Phelps operation are as follows: After proper surgical preparation the Esmarch bandage is applied. The tendo Achillis and usually the posterior ligaments of the ankle are divided subcutaneously, and by manual or instrumental force one attempts

to correct the plantar flexion. An incision is then made on the inner border of the foot, just below and in front of the internal malleolus, which is extended directly downward over the head of the astragalus to include the inner quarter of the sole. Through the incision all resistant parts are divided in order, as stated by Phelps.

1. The tibialis posticus and the anticus if it offers resistance.
2. The abductor hallucis.
3. The plantar fascia.
4. The flexor brevis digitorum.
5. The long flexor of the toes.
6. The deltoid ligament in all its branches.

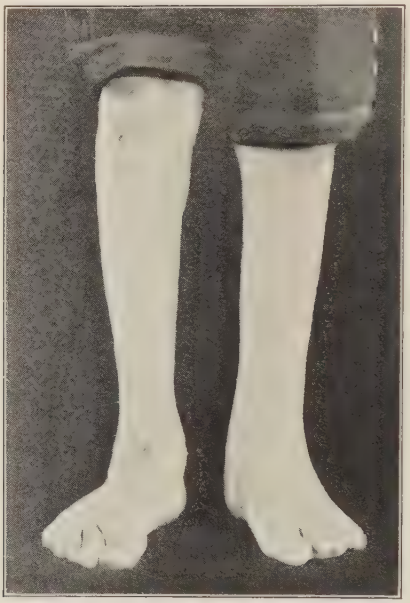

Fig. 779.—The left foot (Fig. 777) corrected by the Phelps operation and by cuneiform osteotomy of the os calcis.

During the successive division of the tissues repeated attempts are made to correct the foot, and only those structures are divided that present themselves as tense and resistant tissues when the foot is forcibly abducted.

In the adult type of club-foot no particular effort is made to recognize the different structures, but all the tissues on the inner side of the foot, including bloodvessels and nerves, the deep ligaments, and occasionally the tendon of the peroneus longus muscle, are divided. Even then it is necessary to apply considerable force to correct the deformity. In certain instances the rectification of deformity necessitates osteotomy of the neck of the astragalus or the removal of a cuneiform section from the os calcis. The object of the Phelps opera-

tion is, by division of resistant tissues and by the use of force, to overcorrect the deformed foot at one sitting, and as much force and as extensive division of tissues as are required to accomplish this object should be employed by the operator.

When the foot can be held in the desired position without resistance the wound is covered with Lister protective, the foot and leg are thickly covered with gauze and cotton, a plaster bandage is applied, and the limb is elevated. The large, gaping wound closes by granulation in from one to three months. The first bandage is usually changed at the end of one or two weeks, and the patient then begins to bear weight on the foot.

By this operation the foot, even in severe cases in adult life, may be made straight in appearance. It is evident, however, that in such cases the correction of the deformity of the bones is by no means perfect, for the forefoot is simply twisted outward and upward while the astragalus and os calcis may remain in an approximation to their original deformity. The operation is most satisfactory in those cases of resistant varus in which the equinus deformity has been overcome. After thorough overcorrection by the Phelps operation the danger of recurrence of deformity in the adult and adolescent type of club-foot is not great, and in many instances support other than that of the plaster bandage for several months after the operation may be unnecessary; but in childhood the ordinary precautions in after-treatment to prevent relapse will be necessary.

Operations on the Bones.—Osteotomy of the neck of the astragalus, as a supplementary part of the operation of forcible correction, has been mentioned. In certain instances, particularly in the adolescent or adult type of deformity, the displaced and distorted astragalus may offer such an obstacle to correction that its removal is indicated.

Astragalectomy.—The astragalus, which in club-foot is displaced forward, may be removed easily by means of an incision passing over its most prominent part, in a direction forward and downward from the tip of the external malleolus, between the tendons of the peroneus brevis and tertius. The soft parts are drawn aside, the ankle and astragalo-navicular joint are opened, and the attachments to the navicular, and, as far as possible, those at the inner and outer border, are divided. The foot is then adducted so that the head of the bone may be seized with forceps and drawn upward, the interosseous ligament and the internal lateral ligament having been divided with curved scissors, it is removed. If after removal of the astragalus the varus persists, it should be supplemented by cuneiform osteotomy of the os calcis and if necessary by the remodelling of the tarsus to assure external symmetry. The foot is then displaced backward, sufficient to restore the prominence of the heel. A useful movable foot may be obtained by this operation. Astragalectomy is never indicated as a primary operation, in childhood at least. The varus should be thoroughly corrected as a preliminary procedure, for until then the resistance that the astragalus offers to dorsal flexion cannot be accurately estimated (Fig. 781).

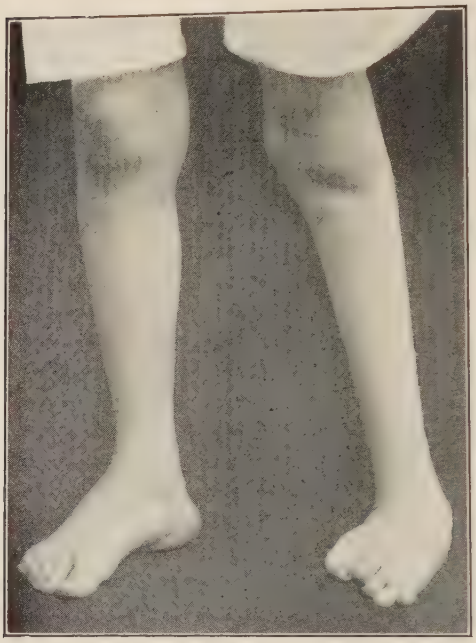

Fig. 780.—Resistant club-foot in later childhood; a type in which the displaced astragalus prevents reduction of deformity. (See Fig. 781.)

Fig. 781.—After forcible correction and astragalectomy. (See Fig. 780.)

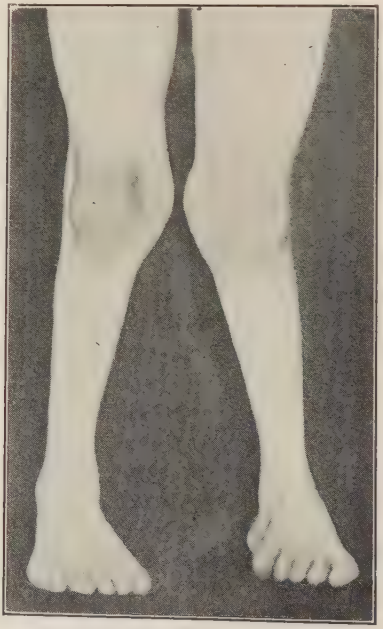

Fig. 782.—Partially corrected club-foot, showing secondary knock-knee.

Cuneiform Osteotomy.—The removal of cuneiform sections of bone from the outer border of the foot is sometimes indicated when the deformity is of long standing, but the operation should be secondary

FIG. 783.—Showing the effect of the ordinary cuneiform osteotomy, the wedge having been taken from the body of the astragalus and the anterior part of the os calcis. The astragalus is displaced forward in its relation to the malleoli.

FIG. 784

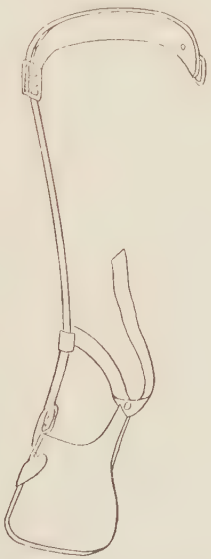

FIG. 785

FIGS. 784 and 785.—The Judson brace. Fig. 784 shows the construction of the brace; the foot plate, with internal flange or "riser," the upright riveted to it and the calf band. Fig. 785 shows the brace adjusted to fit the deformed foot.

to other methods of correction. The aim should be to lengthen the contracted and shortened tissues on the inner border of the foot to the extent required for reposition, not to remove bone to accommodate these shortened tissues. If this has been shown to be impossible by ordinary means, then removal of bone may be indicated; but it is not often necessary in childhood or even in adolescence. If sufficient bone is cut away from the adult foot to permit complete correction of the deformity, relapse is not usual; but in childhood, as has been stated, no operation will take the place of after-treatment.

The treatment by cuneiform osteotomy as it is ordinarily carried out is sufficiently simple. A wedge-shaped section of bone of sufficient size to permit correction of deformity is taken from the astragalus, the os calcis, cuboid, and, if necessary, it may include the navicular also. The external malleolus may be removed if it interferes with reposition. Preliminary fasciotomies and tenotomies are usually performed, but those who favor this method of treatment rarely use force in reposition. The foot is retained in proper position until the wounds are closed; then plaster bandages are employed for several months. Braces are seldom used in the after-treatment.

Hoke's Multiple Osteotomy.—Hoke[1] corrects confirmed deformity by a series of osteotomies supplemented by division of contracted tissues. In a typical resistant case this would include osteotomy of the metatarsal bones near their bases; cuneiform osteotomy, base upward, of the internal cuneiform bone, cuneiform osteotomy of the cuboid, base outward; cuneiform osteotomy of the os calcis, base outward to correct its twist; cuneiform osteotomy of the outer border of the neck of the astragalus, and if the body of the astragalus cannot be forced between the malleoli the ligaments that bind it to the astragalus and os calcis are divided. An osteotomy of the fibula above the ankle permits the lower end of the fibula to be displaced forward into normal relation to the astragalus. The foot is finally fixed in normal relation to the leg.

The Hoke operation differs from the ordinary procedures, in that it represents an attempt to correct immediately all the components of the deformity, as contrasted with the gradual or functional change of structure that follows what may be called a gross correction. It has proved effective in Dr. Hoke's hands and doubtless shortens the period of after-treatment.

Secondary Osteotomy.—In certain cases of relapsed or ineffectively treated club-foot, even in childhood, deformity of the os calcis interferes with correction of the foot. In such instances the removal of a cuneiform section of bone from the anterior extremity may be of service, and in cases of extreme inward twist a cuneiform osteotomy and lateral displacement of the lower segment. Osteotomy of the tibia may be required in cases of persistent inward rotation.

Simple Mechanical Rectification of Deformity in Walking Children and in Later Years.—It has been demonstrated in the past that simple mechanical rectification of deformity is possible even in adolescence.

[1] Am. Jour. Orthop. Surg., 1911, vol. 9.

MEDICAL LIBRARY
THE
BOSTON CITY HOSPITAL

At the present time, however, operative methods have supplanted mechanical treatment, except in infancy. The principles of this method of treatment are illustrated in Judson's figures (Figs. 786 to 790).

Fig. 786

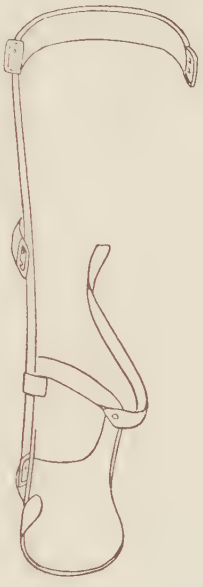

Fig. 787

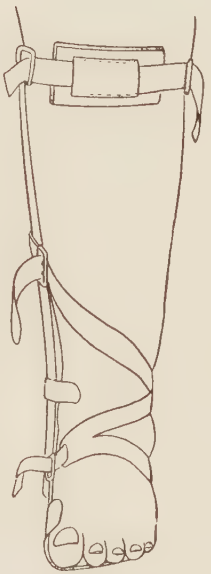

Fig. 788

Figs. 786, 787 and 788.—Showing the progressive reduction of deformity. Fig. 786 shows the ordinary attitude of the neglected club-foot in childhood with the adjustment of the brace, it being bent to accommodate the deformity. Fig. 787 shows additional details—an upright spur, useful in holding the heel and for the attachment of straps; the spur of sheet brass that may be bent over the great toe to hold it in position, Fig. 788 shows other details in the method of attachment, a strip of adhesive plaster, with two tails in the place of the band of webbing. This aids in fixing the heel. (See Figs. 789 and 790.)

The Treatment of Club Foot in the Adult.—In this class of cases the object of the operation is to change a deformed support into an approximately symmetrical one, the range of motion being a secondary consideration. The ordinary routine in a case of this character would be one or more forcible corrections by manipulation or wrenchings supplemented by subcutaneous division of the more obvious contractions, the foot being fixed in the interval in the improved position in order that the circulation may become adapted to the new conditions. At the final operation the astragalus which is simply a distorted bone wedged between the tibia and tarsus is removed. The space thus acquired usually permits the foot to be brought to a right angle with the leg without excessive tension. Then sufficient bone is removed from the os calcis and from the tarsus to correct the varus and the projection of the dorsal surface. The superfluous skin and the underlying bursa having been removed, the wound is closed and a plaster support

is applied. As soon as practicable this is replaced by a walking plaster splint which is used until consolidation is assured.

Review of the Principles of Treatment of Congenital Talipes Equinovarus.—The object of treatment is to overcome and to overcorrect the deformity at as early a period of life as is possible, and as quickly as possible. The object of overcorrection is to overcome all the resistance of the tissues that may even in the slightest degree limit the normal range of motion in any direction. The foot must be fixed in the overcorrected position until the tendency toward deformity is overcome.

Fig. 789 Fig. 790

Figs. 789 and 790.—Showing the progressive reduction of deformity and illustrating the process of changing the shape of the brace from time to time until it holds the foot in valgus. (See Fig. 786.)

It must be supported in the proper relation to the leg until the muscular balance has been reëstablished by stimulation of the weaker and by limitation of the activity of the stronger muscles, and until transformation of the internal structure has been completed.

If efficient mechanical treatment is applied at the proper time—that is to say, in earliest infancy—no operation other than division of the tendo Achillis or posterior ligaments should be required.

If the deformity is not corrected or is but partially corrected when the child begins to walk, some form of operation is, as a rule, indicated; but division of the resistant tissues must always be combined with the employment of sufficient force to accomplish the desired result,

viz., overcorrection of the deformity. Forcible manual correction, applied in the manner described, is the most efficient means of attaining this object. No instrument can equal the hand. The force that can be applied by the hand is sufficient for the correction of all the ordinary cases in early childhood, and, in combination with subcutaneous or open division of the more resistant tendons and ligaments, even in later childhood and adolescence.

Forcible correction by the Thomas wrench under the same conditions is an efficient treatment, and the instrument may be used to supplement manual correction in resistant cases, but there is a manifest disadvantage in submitting a patient to a succession of wrenchings, as was the Thomas practice, if immediate overcorrection can be attained at one operation.

The open operation, combining thorough division of the resistant parts with the application of sufficient force to overcorrect the foot, is indicated for the ordinary types of deformity in adolescence, in adult life, and in extremely resistant cases in childhood.

Astragalectomy and cuneiform osteotomy are never indicated as primary operations, but one or the other or both may be necessary for the complete rectification of the deformity when other means have failed.

Rectification of deformity, even in the later years of childhood, is possible by means of braces alone, but such treatment is very tedious. It requires the continuous supervision of the skilled orthopaedist, as well as the intelligent and persistent coöperation of the parents. The results are in no way superior to those attained by more rapid methods, while the disadvantages of long-continued use of braces are sufficiently obvious. To the popular faith in braces as a cure-all of deformity, and to the unintelligent use of braces, may be ascribed now, as in former times, the greater number of failures in treatment of this eminently curable deformity. On the other hand, the belief so prevalent among physicians that a radical operation, if it does not absolutely assure a cure, is, at least, the essential part of the treatment is equally fallacious.

Rectification of deformity, by whatever means, simply completes the first stage of treatment. Perfect cure can be assured only by attention to the small details of after-treatment, by checking the slightest impulse toward deformity, and by guiding the unbalanced foot toward normal functional use.

OTHER VARIETIES OF CONGENITAL TALIPES.

Forms of congenital distortion of the foot other than equinovarus are not uncommon; but, as a rule, these deformities are so slight, and, as compared to equinovarus, so easily remedied that they are relatively of little importance.

Congenital Talipes Varus.—Eighty-nine cases of simple varus are recorded in the table of statistics in a total of 2103 congenital deformities of the foot.

This deformity often appears to be an incomplete form of equinovarus, but in some instances there is simply an inward twist of the forefoot without inversion (Fig. 717). In some cases of this character, the forefoot is apparently drawn inward by the active movement of the great toe, which, in such cases, seems almost prehensible. (See Pigeon-toe.) In the more marked form the foot is adducted and inverted, and the tissues are very resistant.

The slight grades of deformity may be treated by simple manipulation, and if distortion persists after the first year the shoe will, as a rule, correct it. The more marked varieties must be treated like the varus deformity of ordinary club-foot, by braces or by the plaster bandage, until the varus has been transformed into valgus. The after-varus deformity of ordinary club-foot.

Congenital Talipes Equinus.—This is a rare congenital deformity, about half as common, according to the statistics, as varus (49 cases in 2103). The term equinus implies that dorsal flexion is limited, but that the foot is not deviated to one or the other side (toward valgus or varus). In congenital equinus the deformity is, as a rule, slight, and in many instances it may be overcome by gentle manual force applied frequently. In the more resistant type mechanical correction or tenotomy, followed by overcorrection and support, may be necessary.

Fig. 791.—Congenital calcaneovalgus.

Congenital Talipes Calcaneus.—Congenital calcaneus is comparatively rare (47 cases in 2103). As a rule the heel projects downward, the foot is habitually dorsiflexed, and the dorsum can be easily brought into contact with the crest of the tibia (Fig. 791). The exaggerated

cavus that is usually present in acquired calcaneus is absent. Occasionally the deformity is accompanied by hyperextension of the knee; and if, in many instances, there is a history of breech presentation, it may be inferred that the attitude before birth was one of extreme flexion of the thighs upon the abdomen, the anterior surfaces of the extended legs being pressed closely to the ventral surface of the body, the feet being fixed in an attitude of dorsiflexion. As a rule the deformity is slight, and the resistance of the tissues on the anterior aspect of the leg can be easily overcome by massage and manipulation. The foot should be gently forced toward plantar flexion several times in the day, and the weak muscles of the calf should be stimulated by massage.

Cure may be hastened by the use of some simple form of retention splint to hold the foot in plantar flexion until the posterior group of muscles has recovered its power. Tenotomy or other operative treatment is not often required.

In rare instances the tibia may be bent slightly backward, thus increasing the deformity. In such cases the distortion of the bone may be overcome by manipulation and by apparatus.

Fig. 792.—Congenital equinovarus with deformity of the great toes.

Congenital Talipes Valgus.—Congenital valgus (Fig 742) is somewhat more common than the preceding varieties (144 in 2103). Not infrequently it is combined with a slight degree of calcaneus or equinus. The resistance of the contracted tissues is not great, and the deformity

may be overcome, in most cases, by persistent manipulation. If the muscular power is sufficiently unbalanced to warrant it the foot should be fixed in the overcorrected position (varus) for a time.

Congenital valgus is one form of what is known as weak ankle, and it frequently passes unnoticed until the child begins to walk. If at that time, in spite of massage, the muscles appear weak or if the foot inclines outward when weight is borne it is well to make the sole of the shoe wedge-shaped, the thicker part (one-quarter of an inch) on the inner side. In more persistent cases a brace may be necessary, as described in the treatment of the acquired variety. (See Weak Foot.)

Talipes Equinovalgus is less common (35 in 2103). This must be treated as the other varieties by complete overcorrection of deformity, manual or otherwise, and by subsequent massage and support if necessary.

Calcaneovalgus (87 in 2103), **Calcaneovarus** (10 in 2103), **Equinocavus** (1 in 2103), **Valgocavus** (1 in 2103), **Cavus** (5 in 2103), are extremely rare, as indicated by the statistics. If treated early by persistent massage supplemented by retention apparatus, these, as well as nearly all slighter grades of congenital deformity, may be corrected and cured even before the child begins to walk.

CONGENITAL DEFORMITIES OF THE FOOT ASSOCIATED WITH DEFECTIVE DEVELOPMENT.

Talipes Equinovalgus Associated with Congenital Absence of the Fibula.—This is a rare deformity, but the most common of this class. The foot at birth is usually in an attitude of well-marked and resistant equinovalgus. The leg is somewhat shorter than its fellow, and the tibia is often bent sharply forward, sometimes to an acute angle, at a point somewhat below the center, as if it had been broken. At the most prominent point the skin may be adherent or it may present a dimpled appearance. In some instances the formation of the foot is perfect, but more often one or more of the outer toes, with the corresponding metatarsal bones are absent (Fig. 793).

Statistics.—Haudek collected from the literature 97 cases. Of these 46 were in males, 21 were in females, and in 30 the sex was not recorded. In 67 (69 per cent.) there was total absence of the fibula. In 30 the defect was partial; of the lower extremity of the fibula in 17, of the upper extremity in 9, and of the middle in 2 cases. In 27 cases both fibulæ were absent or defective, in 68 only one—the right in 31, the left in 25, and in the others the side was not recorded. In 61 cases toes were lacking, and in these cases it may be inferred that the corresponding metatarsal bones were absent also. The fourth and fifth toes were absent in 27 cases; the little toe alone was missing in 15. In many instances, as is usual in cases of defective development, deformity of other parts was present; for example, in 17 instances

the patella was absent or undeveloped and in 11 the upper extremities were defective.[1]

Etiology.—The cause of deformity, associated with absence of bone, may be either an original defect in the germ plasm or it may be due to

FIG. 793.—Defective formation of the lower limb, with absence of fibula. At the age of five years the difference in the length of the limbs was 4¾ inches. At fourteen years the defective limb was 7 inches shorter, the deficiency being equally divided between the tibia and the femur.

interference with its development. In some instances amniotic adhesions may be one of the predisposing causes; the sharp bend in the tibia,

[1] Cotton and Chute: Boston Med. and Surg. Jour., 1898, Nos. 8 and 9 (128 cases). Mazzitelli: Arch. Ortopedia, 1898, F. 5. Boinet: Rev. d'Orthop., November, 1899. Vide also Emil Hain (113 cases): Arch. Orthop. Mechanicotherapie und Unfal Chir., 1903, Band 1, Heft 1.

so often present, may be due to the lessened resistance of the defective part.

Treatment.—The indications for treatment are to correct the deformity of the foot in the usual manner. The bend in the tibia may be straightened by manipulation and splinting, or by osteotomy if neces-

Fig. 794.—Congenital absence of the fibula.

sary. When the patient begins to walk the foot must be supported. A light steel upright on the outer side of the leg, provided with a T-strap to hold the leg against it, will supply the place of the missing fibula. As the growth of the tibia, and in less degree that of the femur, is retarded a final shortening of three or more inches may be expected.

MEDICAL LIBRARY
OF THE
BOSTON CITY HOSPITAL

Talipes Varus or Equinovarus Associated with Congenital Absence of the Tibia.—Defective formation of the tibia is much less common than that of the fibula. Myers[1] has collected 46 cases. Of the 38 cases in which the sex was recorded, 25 were in males and 13 in females. In 31 instances the defect was of one side; in 17 both tibiæ were defective. In most of the cases the femur was somewhat shortened and its lower extremity was imperfectly developed. In a third of the cases the patella was absent, and in many instances other

FIG. 795.—Congenital deficiency of the femur.

FIG. 796.—Congenital hypertrophy of the feet, indicating apparently lymphatic obstruction.

malformations were present. In nearly all the cases there was flexion contraction at the knee and the fibula was dislocated backward. The foot is practically always in an attitude of varus. The toes may be normal, but in a number of instances the great toe is lacking. In possibly a third of the cases a portion of the tibia, usually the upper extremity, is present.[2]

[1] Med. Record, July 15, 1905.
[2] Lanois and Kuss report 40 cases: Rev. d'Orthop., November, 1901.

The prognosis as regards a useful limb is extremely bad. The growth of both the thigh and the leg is much retarded, and it is almost impossible to balance the foot upon the fibula by any form of brace.

The ordinary treatment, after the correction of the deformity of the foot, has been to resect the extremities of the femur and the fibula to induce anchylosis. No final results have been reported, but it may be assumed that an artificial limb would provide a more useful support than the short and distorted extremity.

Congenital Deficiency and Hypertrophy.—The leg bones may be perfectly formed, but one or more bones of the foot itself may be absent. In these cases, after the reduction of the deformity, a support to hold the defective foot in its proper relation to the leg must be used.

The foot may be divided into two parts, so that it resembles a lobster claw. Supernumerary toes, or deficiency of toes, or hypertrophy of one or more of the toes, with or without corresponding overgrowth of the foot or leg, are not extremely uncommon.

These deformities must be treated on ordinary surgical principles.[1]

Constricting Bands.—Tightly constricting bands of scar-like tissue, accompanied by deep indentations in the flesh of the foot or leg, are sometimes seen. These are supposed to be caused by amniotic adhesions. "Spontaneous amputations" of toes or of the foot itself are due to the same cause (Fig. 745).

In ordinary cases the bands require no treatment, but if they interfere with the nutrition of the foot they may be removed.

Congenital Hypertrophy of the Feet.—In rare instances, sometimes in combination with deformity, the tissues of the feet are thickened and resistant. The condition is apparently due to obstruction of the lymphatic circulation (Fig. 796).

It should be treated by massage and by compression.

Congenital Edema (Milray's Disease).—This is a persistent edema of one or both feet, rarely extending above the knees. It is painless and causes but little disability.

Spina Bifida and Talipes.—Talipes with spina bifida should be treated as are other forms of club-foot. If paralysis of the lower extremities be present, as is often the case, the corrected feet must be supported as in the ordinary forms of paralytic deformity. Later operative treatment to assure stability may be indicated, particularly astragalectomy and backward displacement of the foot.

[1] Klausner: Ueber Missbildungen der menschlichen Gliedmassen und ihre Entstehungsweise, 1900.

CHAPTER XXIII.

DEFORMITIES OF THE FOOT (Continued).

ACQUIRED TALIPES.

In the account of the congenital deformities of the foot it was stated that equinovarus was by far the most common, and that as compared with it the other deformities were of slight importance.

In the acquired varieties of talipes the equinovarus deformity is much less common, the proportion in the congenital form being 77.4 per cent. and in the acquired 30 per cent. of the total number. Acquired equinus comes next in frequency, 25.9 per cent. as compared with 2.3 per cent. of the congenital deformity; and every variety and combination of distortion finds its representative in acquired talipes, as may be seen in the tables. (See page 854.)

Etiology.—The cause of acquired talipes is usually paralysis. In the table of statistics it will be seen that in 79.9 per cent. the paralysis was of spinal origin (anterior poliomyelitis). In 11.5 per cent. it was cerebral, the talipes being a part of the deformity of hemiplegia or paraplegia. In a few cases the deformity was caused by local disease or by local paralysis, and the remainder, or 7 per cent., were of traumatic origin.

The distinction between the two varieties of talipes, congenital and acquired, has been emphasized already. In the congenital form the deformity is the essential disability, for when deformity has been corrected the most difficult part of the treatment has been accomplished and perfect cure may be expected. In the acquired form the straightening of the foot is but a preliminary part of the treatment, for cure is out of the question except in that small proportion of cases in which the disease of the spinal cord has caused no permanent injury to its structure, or in which the deformity was the result of some slight or passing disability or of local disease or injury. Congenital talipes cannot be anticipated or prevented. Acquired talipes is evidence that protective treatment has been neglected. It is a result, therefore, that may be foreseen, and thus prevented.

Development of Deformity.—The characteristics of anterior poliomyelitis are described elsewhere. (See Chapter XVII.) In its effect upon the foot the usual sequence is somewhat as follows: At the onset the paralysis is often widespread, affecting an entire limb, for example; then follows a period of partial recovery, after which the amount of damage that the spinal cord has sustained may be estimated. It is during the period of partial recovery, the six months or more following the attack, that deformity develops. If, for example,

the anterior leg muscles are paralyzed, the foot habitually hangs downward, an attitude induced by the force of gravity and by the contraction of the active posterior group. If the attitude persists the tissues accommodate themselves to the new position; the active muscles which are never extended to their normal limit become structurally shortened, while the weakened or paralyzed muscles are correspondingly lengthened. Often within a few weeks after the onset of the paralysis the evidences of progressive deformity are apparent. The contracted tissues resist passive motion in the directions opposed to the habitual attitude, and the child shows evidence of pain if force is used to increase the limited range of motion. As has been stated already, acquired talipes is an unnecessary deformity. It may be prevented by supporting the paralyzed foot in a right-angled relation to the limb, or by systematic passive movements throughout the entire range of normal motion.

Anterior poliomyelitis is most common during the second and third years of life, or when the child has already begun to walk. When the first or more general effect of the disease has passed the child again uses the disabled limb as best it may; thus the distortion of the foot is increased and confirmed by the weight of the body and by functional use in the abnormal attitude.

The final deformity, in a particular case, may be predicted from knowledge of the function of the muscles which have been disabled. For example, paralysis of the tibialis anticus, the most powerful dorsiflexor and invertor of the anterior group, must result in equinovalgus. Paralysis of the tibialis posticus, the chief adductor, causes valgus. If the peroneal group is affected varus will follow. Paralysis of the calf muscle will cause calcaneus. Paresis or paralysis of the entire anterior group will cause equinus. If all the muscles are paralyzed, what is called a dangle-foot is the result; the atrophied member dangles with but little tendency to deformity other than equinus unless it is capable of use, when it is usually forced into an attitude of varus or valgus.

A slight or transient paralysis may cause no immediate disability and yet it may induce deformity in later years. This fact has been mentioned in the etiology of the contracted foot.

Differential Diagnosis between Congenital and Acquired Deformity.—The history itself usually indicates the etiology, for deformity of the foot at birth is never overlooked by the mother. Acquired talipes is of slow development, and it is practically always preceded by disease, weakness, or injury.

In paralytic talipes (anterior poliomyelitis) there is evidence of paralysis in loss of function of certain muscles, as shown by voluntary movements or by pricking the foot with a pin; by atrophy, and loss of growth.

Only in neglected and extreme cases of talipes in the adolescent or adult could there be difficulty in distinguishing between the acquired and the congenital deformity. In rare instances, it is true, paralysis

may be present at birth, due to intra-uterine disease or to defect in the nervous system. In such cases the cause of the paralysis is usually apparent (spina bifida or spastic paralysis associated with defective cerebral development), and the treatment does not differ from that of the acquired form.

ACQUIRED TALIPES EQUINUS.

In well-marked equinus the foot is plantar flexed to its full limit, and it is fixed in this attitude by the shortened structures of which the tendo Achillis is the most important. The patient walks upon the heads of the metatarsal bones, the toes being dorsiflexed to accommodate the deformity. The arch of the foot is increased in depth and the tissues of the sole, particularly the plantar fascia, are contracted. The

Fig. 797.—Acquired talipes equinus, showing the limitation of dorsal flexion.

foot is broadened and shortened, the breadth being especially increased at the anterior metatarsal region (Fig. 740). Corresponding to the exaggerated depth of the arch, the dorsum projects, the cuneiform bones are prominent, and the head and body of the displaced astragalus may be felt beneath the skin on the anterior surface of the foot. In the slighter degrees of the deformity, when the patient still walks upon the sole of the foot, the toes are usually dorsiflexed—an attitude due apparently to the overaction of the extensor longus digitorum and proprius hallucis, as aids in dorsiflexion (Fig. 797). In rare instances, and only in those cases in which all the anterior muscles are paralyzed, the toes may be plantar flexed, the patient walking upon their dorsal surfaces.

The cavus or increased depth of the arch is due primarily to the plantar flexion of the forefoot at the mediotarsal joint, and in many

instances this dropping of the forefoot is in great degree responsible for the equinus; in fact, the os calcis is rarely plantar flexed to the degree commonly found in the ordinary congenital equinus.

The cases of slight equinus combined with cavus have been described already under the title of the Contracted Foot (page 803).

Etiology.—Equinus is the most common of the forms of talipes acquired in later life. Anterior poliomyelitis, although the usual cause, is by no means as important in the etiology of this as of other varieties of deformity. The nerve supply of the anterior muscles of the foot seems to be particularly susceptible, and toe-drop, from neuritis of various types, is not uncommon.

Equinus may be a result of disease or injury of the brain, or even, in rare instances, of progressive muscular dystrophy, locomotor ataxia and the like. It may be induced by habitual posture, as by long confinement in bed for the treatment of fracture or during the treatment of hip disease by apparatus. Or the contraction may be an effect of voluntary posture in compensation for a shorten limb. It is a very common sequel of neglected disease at the ankle-joint, and it may be a result of direct injury, as for example Pott's fracture.

The changes in the internal structure of the foot are similar to those that follow other forms of deformity; the tissues on the long side are lengthened and attenuated, while those on the short side become contracted. The bones themselves are but little changed in gross appearance, but the articulating surfaces are in abnormal relation to one another; for example, only the posterior part of the astragalus may be contained within the malleoli in relation to the tibia, while only the lower part of its anterior surface articulates with the navicular. In all cases of equinus there is a strong tendency toward varus or valgus. This is especially noticeable in those of paralytic origin.

Symptoms.—The effects of the deformity vary. If the limb is actually shorter than its fellow, so that the lengthening caused by the extension of the foot is no more than a sufficient compensation, and if the foot is firmly fixed in the deformed position, there is but little disability, and the chief discomfort is from corns or calluses beneath the metatarsal bones.

If the limb is not shorter, the additional length caused by the equinus must be compensated by a tilting of the pelvis and lateral deviation of the spine. This often causes discomfort in the lumbar region. The gait in this class of cases is always awkward, giving the impression as of stepping over an obstacle.

If the foot is not fixed in the attitude of equinus—that is, if it hangs downward during progression—the gait is very awkward, because of the insecurity and because of the exaggerated flexion at the knee necessary to lift the pendent foot.

If the equinus is extreme the limb is usually flexed at the knee when in use. If it is so slight that the foot may be used in the plantigrade position, the strain resulting from the limitation of dorsal flexion is felt at the knee; and in childhood especially there is often a well-

marked tendency to overextension or recurvation, caused by the effort to place the heel upon the ground.

In the slight degrees of equinus, discomfort about the calf is experienced; the limitation of dorsal flexion causes a shortened stride and awkward gait, while an unguarded step that throws a sudden strain upon the resistant heel cord is felt as a shock and strain through the limb. Very often the patient complains of pain about the metatarsal bones (anterior metatarsalgia), and if the equinus is accompanied by a slight degree of valgus, as is not uncommon, symptoms of the weak foot may be present.

The prognosis depends, of course, upon the cause of the deformity. When it is simply the result of posture or of the ordinary form of neuritis and the like complete cure may be expected. In many of the cases caused by anterior poliomyelitis there has been recovery, complete or partial, of the original injury to the spinal centers. But although the power has been regained, it cannot be exercised because the foot is held in the distorted position by the contracted tissues. In such instances practical cure may be predicted if, after the overcorrection of deformity, sufficient time is allowed for the overstretched and atrophied muscles to regain their proper length and volume.

Treatment.—In the cases of fixed equinus with a shortened limb in which the patient suffers no discomfort a shoe should be so built as to equalize the pressure on the bearing surface. In the more extreme cases in which the limb is short and the foot is atrophied, an "extension" shoe may be worn with comfort and with but little evidence of deformity.

In the ordinary cases, whether cure is expected or not, the rule holds good that the heel should bear weight, and that the range of dorsal flexion should not be limited when the calf muscle retains its power. If the paralysis is permanent the foot must be supported after the deformity has been corrected; but even in this class the gait may be improved and the discomfort may be relieved by removing the restrictions to normal motion.

The slight degrees of equinus in young subjects may be overcome by simple manipulation or by elastic tension, or by retention in a splint or in a plaster bandage. If the foot is fixed by a plaster splint at a right angle to the leg it will be found after a few weeks that the range of dorsal flexion has been increased by functional use. Manual stretching of the contracted tissues is also of service; for example, the patient being seated extends the limb; the surgeon stands in front of him, one hand holds the leg firmly at the ankle, and the other grasps the foot, which is then dorsiflexed over and over again with as much force as is consistent with the comfort of the patient.

Certain forms of apparatus, for example, the Shaffer extension shoe, may be employed with advantage in cases of slight deformity.

Immediate Correction of Deformity.—Attention has been called to the cavus as a secondary deformity that usually accompanies equinus, and in operative correction the exaggerated arch should first be

reduced to its normal depth, otherwise the foot will appear stunted and deformed.

One of the most effective procedures is forcible reduction by means of the Thomas wrench (Fig. 776). The contracted bands of the plantar fascia are first divided subcutaneously, the wrench is then fixed to the foot, and by sudden force exerted against the resistant tendo Achillis the foot is straightened, the shortened tissues being ruptured or stretched to the proper degree. If, however, the cavus is marked, the Steindler method of "stripping" the os calcis is preferable. The resistance to normal dorsal flexion is then overcome by manual force, or, if necessary, by supplemented division of the tendo Achillis, and the



Fig. 798.—A brace with a "limited" joint, permitting slight motion at the ankle.

Fig. 799.—A brace with "stop" joint to prevent foot-drop. One upright is often sufficient.

foot is fixed by a plaster splint in an attitude of dorsiflexion. If as is usual the toes are contracted, the deformity should be reduced in the manner already described. (See Contracted Foot.)

As the patient is encouraged to walk upon the foot as soon as possible, the weight of the body forcing the relaxed tissues against the plaster sole, reinforced, if necessary, by a wooden foot plate completes the flattening of the arch. In many of these cases the knee has been overextended by use in the deformed attitude, so that the habitual flexion necessary to bring the dorsiflexed foot upon the ground during the two months required for the complete union of the divided tendon is of benefit, as it serves to correct this secondary weakness and deformity.

MEDICAL LIBRARY OF THE BOSTON CITY HOSPITAL

The Tonic Effect of Immediate Correction.—The importance of the tonic effect of immediate relief of the strain of the deformed position upon the weak anterior group of muscles, together with the complete relaxation of the overstretched tissues, during the long rest in the overcorrected position is not generally appreciated. Whenever the weakened muscles after paralysis show by tests, electrical or otherwise, that they have recovered their power in part, overcorrection of the deformity is indicated. The application of electricity or other form of stimulation to muscles that are unable to exercise their func-

Fig. 800.—An effective and inconspicuous support for paralytic toe-drop. An upright of light tempered steel, carefully adjusted to the inner side of the leg and ankle, provided with a light calf band. This is strengthened by a posterior support attached to the upright. The lower end of the brace is arranged as a caliper and is fitted to the metal disk, of which two views are shown. A depression is cut in the heel of the shoe for the disk, as is shown in the diagram. Two strong elastic tapes are sewed to the leather of the shoe. These are attached to the studs on the front of the calf band, and thus the toe-drop is prevented. (See Fig. 801.)

tion because of contraction of the opposing tissues is useless; nor is any other form of artificial stimulation equal to functional use, which is made possible by the reduction of the deformity and support in the proper attitude. Equinus, more often than any other deformity, is the result of slight or temporary disability of the anterior group of muscles, and not infrequently perfect cure seems to have been attained when the plaster splint is finally removed, usually at the end of two months or more; but even in such cases the application of a simple support to hold the foot at a right angle with the leg for several months is advisable, while a lighter brace to hold the foot during the night in

the original attitude of overcorrection is an effective means of preventing relapse. The after-treatment by massage, muscle-training, electricity and the like, combined with methodical passive movements to the limit of dorsal flexion to guard against recontraction of the calf muscle, should be continued for a long time or until the muscular balance has been regained.

Support is, usually, necessary, in cases of permanent paralysis, to hold the foot at right angle with the leg. The common form is a simple steel sole plate of sufficient size to support the sole and the toes, also, if their muscles are paralyzed, attached to a light upright, provided with a calf band. The upright is usually applied on the inner side of the leg, where it is least noticeable. At the ankle there is a "stop joint," which permits dorsiflexion but prevents the toe-drop. This, when properly fitted, can be placed inside the ordinary shoe, as the paralyzed foot is usually somewhat smaller than its fellow (Fig. 798). If the toes do not need support, the upright can be attached to the outside of the shoe and the foot plate may be dispensed with; or, the upright may be concealed by introducing it inside the shoe to a joint sunk in the heel, the toe-drop being prevented by straps passing from the front of the upper leather of the shoe to the calf band (Fig. 800).

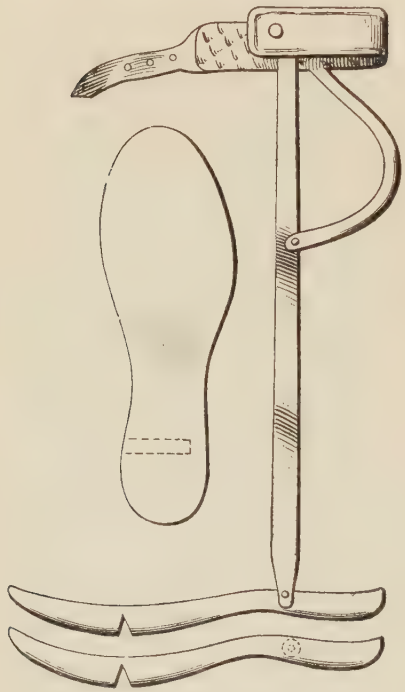

Fig. 801.—The same appliance (Fig. 800) provided with a foot-plate of metal or of wood as shown in the diagram. This modification is useful if the paralysis is complete or if the foot is much atrophied.

In some instances a steel spring placed in a padded tongue will serve to prevent for drop. The spring is made of the material used for clocks and cameras, about 1 inch in width and $\frac{1}{36}$ inch in thickness.

Operative Treatment.—The operative treatment of drop-foot is from the stand-point of complete relief rather disappointing.

Silk Ligaments.—These are of temporary value, but when support is removed the deformity usually recurs (Fig. 804).

Tendon Implantation.—This is at a mechanical disadvantage because there is no tendon on the outer border of the foot available to balance the tibialis anticus. Gallie displaces the peroneus longus forward and inserts its tendon through a hole bored in the fibula in an antero-

posterior direction. This is, however, only practicable if the muscle is paralyzed. Peckham[1] has used strips of fascia lata for the same purpose.

Tendon Displacement.—The tendons of the peroneus brevis and the tibialis posticus muscles are of normal power, and may be separated from their attachments behind the malleoli to a point about 3 inches above the malleoli, displaced forward and attached to one another by a loop of fascia at a sufficient tension forward to restrain plantar flexion.



FIG. 802.—Support and elevation after arthrodesis.

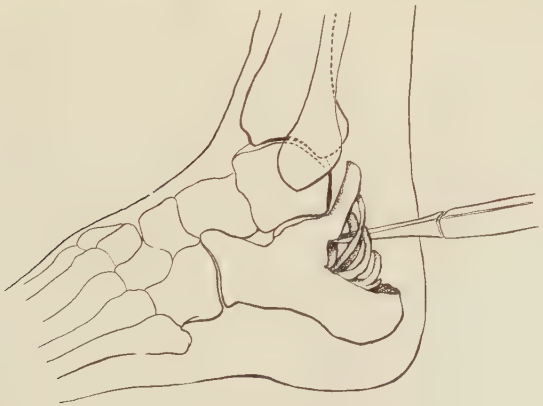

FIG. 803.—Diagram, side view, showing bone block in position approximate to and within ankle-joint. (Campbell.)

The Campbell Operation.—Campbell[2] advocates the formation of a posterior bone block similar in principle to the anterior blocking produced by displacing the foot backward after astragalectomy. The

[1] Am. Jour. Orthop. Surg., January, 1918.
[2] Jour. of the Am. Med. Assn., December 19, 1925.

astragalus is exposed from behind through an incision by the side of the tendo Achillis which, if equinus is present, is divided. The posterior inner half of the astragalus is cut with a chisel to form a flat perpendicular surface and a section of bone is turned upward from the os calcis, as shown in Fig. 803, so that when consolidated it shall by contact with the posterior surface provide a mechanical block to plantar flexion. The operation may be combined to best advantage with other procedures to stabilize the foot at the subastragaloid and mediotarsal joints, the fragments removed being utilized to reënforce the posterior bone block

Astragalectomy and Backward Displacement.—This is useful in cases of extensive or complete paralysis, especially if accompanied by lateral deformity, and if the limb is shorter than its fellow, so that a stable extended foot may be substituted for the so-called dangling extremity, but it is rarely indicated for simple equinus.

ACQUIRED TALIPES EQUINOVARUS.

Talipes equinovarus is, in the acquired as in the congenital form the most common of the deformities of the foot.

The tendency of simple equinus is usually toward varus, because in plantar flexion the foot is slightly adducted and because the outer side of the foot is shorter than the inner side, so that in walking with the foot extended the tendency of the foot is to turn somewhat inward. Equinovarus is usually preceded by equinus, and the etiology of the one will serve for the other.

In certain cases the varus is more marked than the equinus, as, for example, when the abductors of the foot are paralyzed while the adductors retain their power; or in cases of direct injury, as in fracture at the ankle; or when the growth of the tibia has been arrested, as the result of injury or disease.

A detailed account of the appearance and effect of the deformity is unnecessary.

Treatment.—If the deformity is resistant it should be reduced and overcorrected by forcible manipulation under anesthesia. Division of resistant parts is less often necessary than in the congenital form, but it may be required in neglected cases. The overcorrected position should be retained until sufficient time has been allowed for the reconstruction of the lengthened tissues; for, as has been mentioned in the treatment of equinus, fixation in the overcorrected position is by far the most effective treatment that can be applied to a weak or paralyzed part. The foot must then be supported by a brace, of which the Taylor club-foot apparatus is the type (Fig. 767). Tendon implantation, after the Gallie method, of the two peronei into grooves cut in the fibula is effective in restraining deformity, at least for a time (Fig. 811), and silk ligaments may serve temporary for the same purpose.

Transplantation of the tendon of the tibialis anticus muscle to the periosteum or bone at the outer border of the foot near the base of the

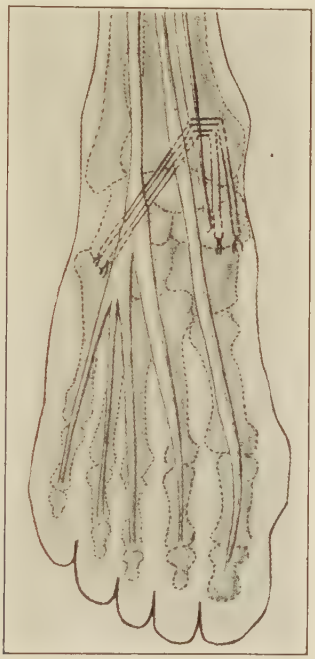

FIG. 804.—Silk ligaments applied to restrain plantar flexion. (Lovett.)

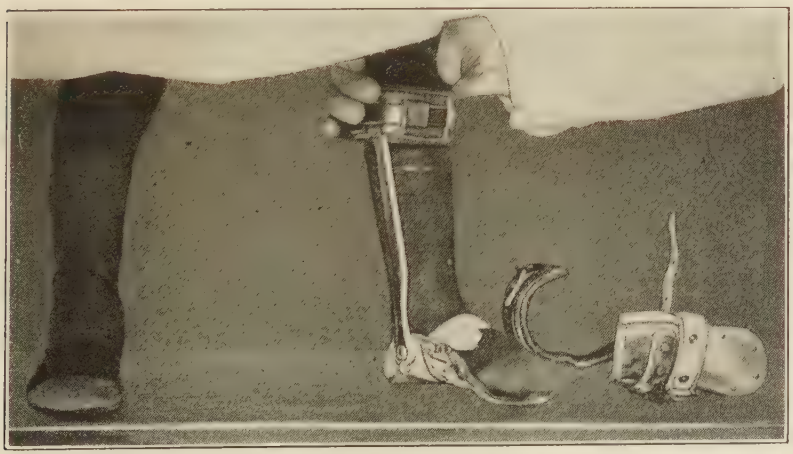

FIG. 805.—A brace for equinovalgus deformity. The author's brace for weak foot combined with an upright with a stop joint to prevent plantar flexion.

fifth metatarsal in the more persistent cases may be combined with arthrodesis of the mediotarsal and of the subastragaloid articulations.

Transplantation of the tibialis posticus to the attachment of the peroneus brevis, or to its tendon behind the external malleolus, is also of value in certain instances. (See Tendon Transplantation.) If the deformity is of long-standing the removal of a sufficient wedge of bone from the outer border of the tarsus to permit overcorrection may be indicated. This should be combined with tendon implantation or transplantation. Astragalectomy and backward displacement of the foot is most effective in the cases in which the paralysis is complete, or in those cases in which the varus is accompanied by cavus.

ACQUIRED TALIPES EQUINOVALGUS.

Acquired talipes equinovalgus is much less common than the preceding deformity. Simple equinovalgus is usually the result of primary paralysis of the tibialis anticus, the most powerful of the dorsal flexors; thus the foot is drawn somewhat outward when dorsiflexed, while the metatarsal bone of the great toe, having lost its support falls downward and is drawn outward by the peroneus longus. In this type one's attention is often attracted to the peculiar appearance of the great toe, which is deformed somewhat like a hammer-toe by the overaction of the extensor longus hallucis in its attempt to take the place of the tibialis anticus. The equinus is usually slight and is secondary to the valgus. Treatment may be begun by placing the foot in a plaster bandage in an attitude of varus and allowing the patient to walk upon it until the tendency toward deformity has been overcome. A support with the catch, as for toe-drop, is applied to the shoe, and the tendency toward valgus is checked by raising the inner border of the sole or by the use of a sole plate, as in the treatment of the simple weak foot. In this class of cases tendon transplantation, particularly the implantation of the tendon of the extensor longus hallucis or longus digitorium or both in the region of the navicular, or combined with arthrodesis of the astragalo-navicular articulation to fix the foot in the attitude of adduction is of service. If the tibialis anticus muscle is completely paralyzed its tendon may be implanted in the tibia after the Gallie method.

The Loop Operation.—The most common of the minor paralytic deformities of the foot is valgus due to paralysis of the tibialis anticus or in combination with the tibialis posticus. As the tibialis anticus is the most direct and powerful of the dorsal flexors, its loss results usually in equino-valgus deformity, and the deforming influence of the unbalanced dorsal muscles is increased by the displacement of their tendons toward the outer side.

The problem of lessening the muscular traction toward abduction and reinforcing the power of dorsal flexion has been met by what has been called the loop operation.

The deformity having been previously overcorrected, an incision is made over the fibula from about the middle of the leg downward to

the malleolus (Fig. 807). The fibrous covering and sheath of the peroneal tendons is divided and the peroneus brevis muscle carefully separated from the bone to about the junction of the upper and middle third. A short incision is then made over the base of the fifth metatarsal bone and the tendon is cut at its attachment and drawn backward from out its sheath. A long incision is made over the center of the dorsum of the foot from a point about two inches above the annular ligament to the base of the metatarsal bones, exposing the dorsal tendons. The annular ligament is divided. The tendon of the peroneus tertius is cut at its insertion and with its muscular belly is separated from the other tendons and drawn upward. The paralyzed tibialis tendon is then cut above the annular ligament. A quilted suture is securely attached to the combined tendons of the peroneus brevis and tertius, which are usually sewed lightly to one another and is passed

FIG. 806.—Tendon implantation or tenodesis (Gallie). All the structures have been removed from the skeleton, except the tibialis anticus muscle and tendon which has been buried in the tibia to prevent foot-drop.

through the cut upper end of the tibialis anticus. An opening having been made in the lower end of its sheath the tendon is withdrawn, its place in the sheath being occupied by the two transplanted tendons, whose extremities are then firmly attached to the insertion of the tibialis anticus tendon at its base. The sheath of the proprius hallucis tendon is opened at this point, the tendon divided; the distal extremity is sewed to the underlying tissues to prevent toe-drop and the proximal end is drawn down and sewed in the neighborhood of the other transplanted tendons. The final step of the operation is to pass the tendon of the tibialis anticus beneath all the dorsal tendons and finally to implant its upper end in a groove cut obliquely upward and inward across the anterior surface of the base of the internal malleolus, to which it is attached after the Gallie method, forming a loop which supports all the tendons in the center of the foot, so that all act as

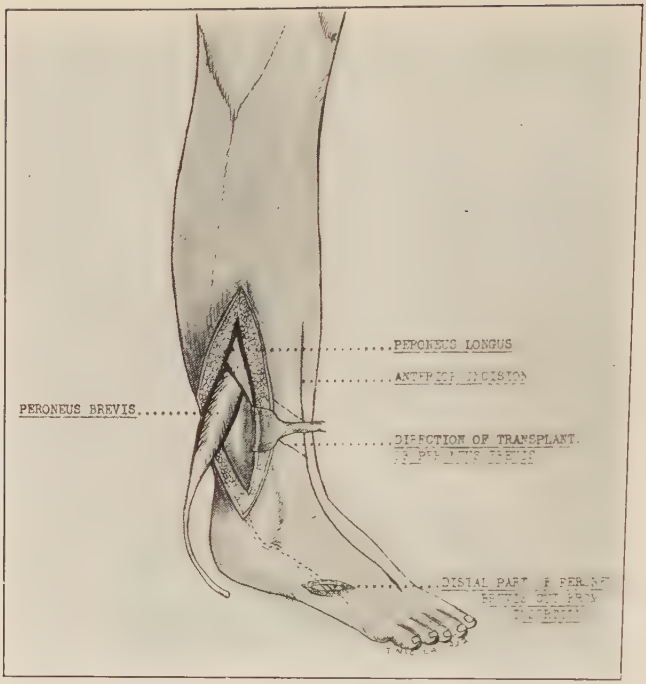

FIG. 807.—The peroneus brevis has been dissected from the fibula.

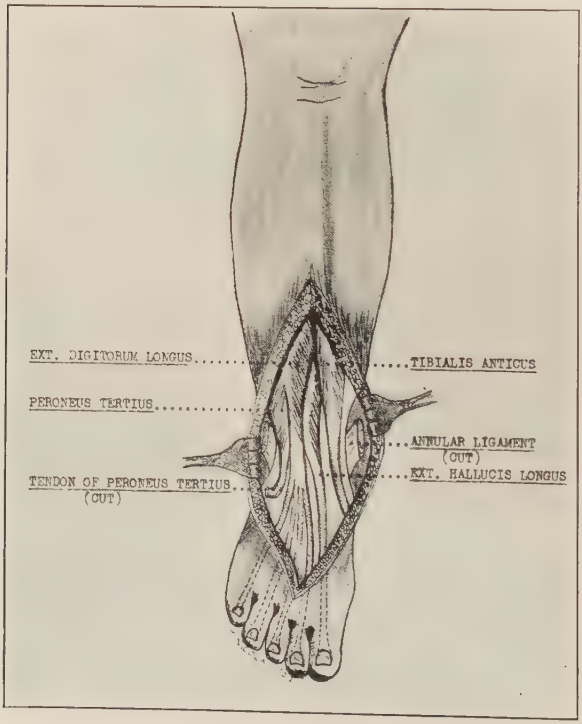

FIG. 808.—The tendon of the peroneus tertius has been separated.

direct dorsi flexors. The cut tissues are then repaired with fine catgut, particularly the peroneal tendon sheath. The fatty tissue is sewed over the transplanted tendons in addition to prevent adhesions, and the wounds are closed.

Great care is taken to avoid constriction by the dressing and the foot is suspended for several days. As soon as repair is complete a brace is applied to support the foot and to permit exercise of the transplanted muscles. The peroneus brevis is transplanted rather than the longus because it is the more direct abductor and because the latter has an important function of binding the foot together and fixing its inner border in locomotion.

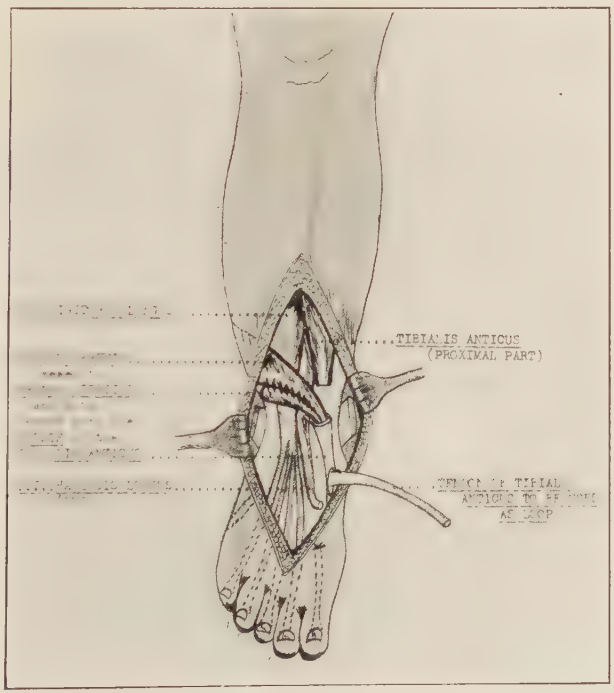

FIG. 809.—The Whitman loop operation. The tendons of the peroneus brevis and tertius sewed to one another have been passed through the sheath of the tibialis anticus from which its tendon has been withdrawn and are implanted on the inner border of the foot.

The brace is discarded in two or three months. In the after-treatment particular attention is paid to daily stretching in order to assure the full range of dorsal flexion and to prevent a lateral inclination of the foot. This operation has proved very effective; in fact, the valgus may be in some instances transformed into varus. In such cases it must be supplemented by subastragalar arthrodesis.

The most important factor in the operation is the separation of the peroneus tertius from its attachment to the outer border of the foot.

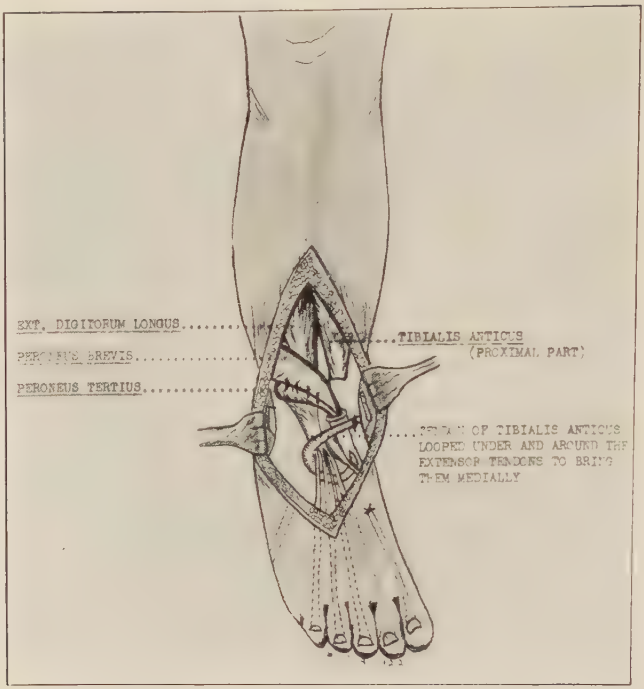

FIG. 810.—The tendon of the tibialis anticus has been looped about the toe tendons and has been fixed in a groove cut in the base of the internal malleolus. The tendon of the extensor proprius hallucis has been cut at the point indicated and has been transplanted to the inner border of the foot. (Diagrams drawn for me by Dr. T. Nicola.)

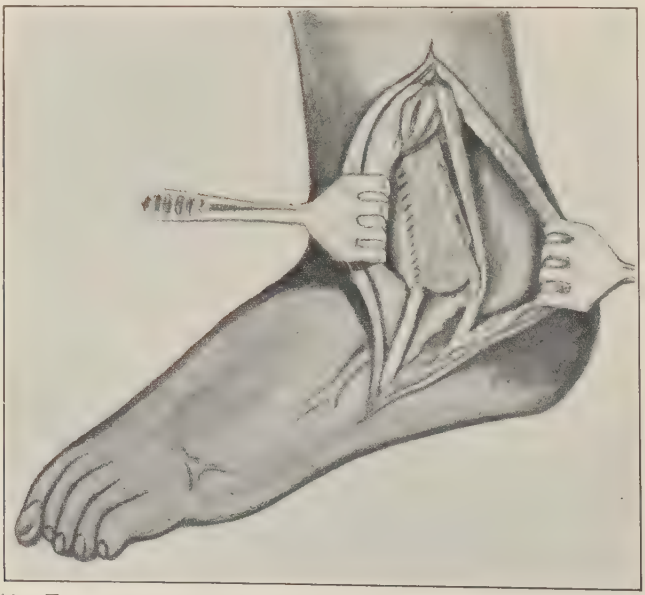

FIG. 811.—Tenodesis for varus. (Gallie.) The tendon of the peroneus longus has been fixed in the anterior border of the external malleolus and the tendon of the peroneus brevis is ready to be laid in a trough prepared for it behind the malleolus.

MEDICAL LIBRARY OF THE BOSTON CITY HOSPITAL

This permits the shifting of the dorsal tendons from the outer to the inner side of the foot and in milder types of deformity the transplantation of the peroneus brevis is unnecessary. The loop operation may be combined with subastragular arthodesis, or the Miller flap operation. (See page 801.)

FIG. 812.—Tenodesis for calcaneus. (Gallie.) The drawing shows the flexor longus hallucis retracted so as to expose the posterior surface of the tibia. The anterior half of the tendo Achillis has been sewn into the groove in the bone. The incision in the sheath of the tendo Achillis has been closed and the two peronei tendons have been transplanted into the os calcis.

ACQUIRED SIMPLE TALIPES VALGUS.

Acquired simple talipes valgus from paralysis of the tibialis posticus is rare. The deformity may be controlled usually by a flat-foot support and proper shoe. Talipes valgus, in combination with cavus, caused by complete paralysis of the leg muscles, is an occasional variety of dangle-foot.

Talipes valgus, sometimes called spurious valgus, the simple weak or flat-foot, has been described elsewhere. (See Chapter XX.)

Talipes caused by cerebral disease, whether of the paraplegic or the hemiplegic type, is in early childhood almost always of the form of equinovarus. In adolescence the deformity may be equinovalgus or even calcaneovalgus if there is extreme flexion at the knee. The hemiplegic form of talipes is much more rigid and unyielding than the paraplegic type. The treatment of spastic paralysis, of which the deformity is a part, is discussed elsewhere. (See Chapter XVIII.) The deformity must be corrected by the ordinary methods. In many

instances when the contractions are not marked mechanical treatment is unnecessary.

Traumatic valgus and equinovalgus caused by fracture at the ankle (Pott's fracture) may be treated by osteotomy of the tibia above the ankle, or if the displacement is more marked by direct division of the bones at the seat of fracture. By this means the proper relation of the leg to the foot may be restored in many instances. Equinovalgus of slight degree is not uncommon after tuberculosis or rheumatoid disease at the ankle or at the astragalo-navicular joints. This is practically one variety of weak foot.

Hysterical equinovarus or other form of deformity is not especially rare. The diagnosis may be made from the other symptoms of hysteria, from the history of the onset and duration of the distortion, and from the appearance of the deformity, which is evidently merely an assumed posture.

ACQUIRED TALIPES CALCANEUS.

Talipes calcaneus is much less common than equinus and it is practically always of paralytic origin, although it occasionally follows rupture or division of the tendo Achillis, or injury or disease about the ankle-joint.

Etiology.—There are several varieties or grades of the deformity. If all the muscles of the posterior group have been paralyzed, the foot soon assumes an attitude of slight dorsiflexion, and the range of plantar flexion is gradually lessened by secondary contractions. This variety resembles closely the congenital form (simple calcaneus) (Fig. 741). In the ordinary and typical form of calcaneus only the calf muscle is paralyzed and when fully developed the patient walks, as the name implies, on an elongated heel. The arch of the foot is much increased in depth and the forefoot is atrophied and useless (calcaneo-cavus) (Fig. 818).

Development of Deformity.—The development of the deformity is somewhat as follows: The tension and support of the calf muscle having been lost, the position of the os calcis changes and eventually it tends to stand on end, so that its posterior surface becomes inferior. The projection of the heel is first lessened and finally lost. The change in the position of the os calcis increases the distance from the malleoli to the base, deepens the longitudinal arch, and shortens the foot; thus cavus is a later complication of all cases of paralytic calcaneus. If the entire posterior group of muscles is paralyzed, while the anterior muscles are unaffected, the foot will be somewhat dorsiflexed and the cavus will be less marked. If the calf muscle only (gastrocnemius and soleus) is paralyzed, the remaining muscles of the posterior group will counter-balance the dorsiflexors and at the same time increase the cavus. In all cases the range of plantar flexion is lessened. In many instances one or more of the lateral muscles is paralyzed, in which case the foot is usually turned toward valgus. The changes primarily

caused by the paralysis and by unopposed muscular action become fixed by habitual use and by secondary adaptation of the tissues. The heel only is used in walking, and the area of callus indicating its weight-bearing surface becomes much enlarged, and to it forefoot and toes become a mere appendage, a striking illustration of the atrophy that follows disuse (Fig. 817).

Symptoms.—The gait is shambling, the patient, who is, as it were, "hamstrung," stamps along upon the insecure heel in a manner which is easily recognizable by one familiar with the deformity. The changes in the internal structure of the foot, the inevitable adaptations to the deformity, do not call for special description.

FIG. 813.—Talipes calcaneus in the developmental stage, showing the elongated heel, the cavus and the atrophy of the forefoot.

Treatment.—When the diagnosis of paralysis of the calf muscle is made one may predict, unless recovery takes place, a deformity such as has been described. This deformity may be lessened or even prevented by proper support, by massage and methodical stretching of the tissues that have a tendency to contract. The form of brace used for walking and support should be provided with a sole plate, upright, and calf band, as already described in the treatment of paralytic equinus. If motion is permitted at the ankle it should be in plantar flexion only, the stop being the reverse of that used in equinus; or, as this form of check entails much strain upon the joint, it may be omitted (Fig. 815). A still stronger and more effective brace is that shown in Fig. 816, by which the strain, removed from the weakened tissues, is borne by the anterior surface of the leg. Other forms of braces are sometimes employed, provided with elastic bands to supply the place of the calf muscle; but, as a rule, the improvement in gait hardly compensates for the difficulty in adjustment or the conspicuousness of the appliance.

The most important part of the actual deformity of calcaneus is the cavus, and in confirmed cases it is practically impossible to reduce this directly, because the loss of resistance of the tendo Achillis takes

Fig. 814.—Talipes calcaneus, showing the change in the static conditions that causes the instability, particularly the adverse leverage.

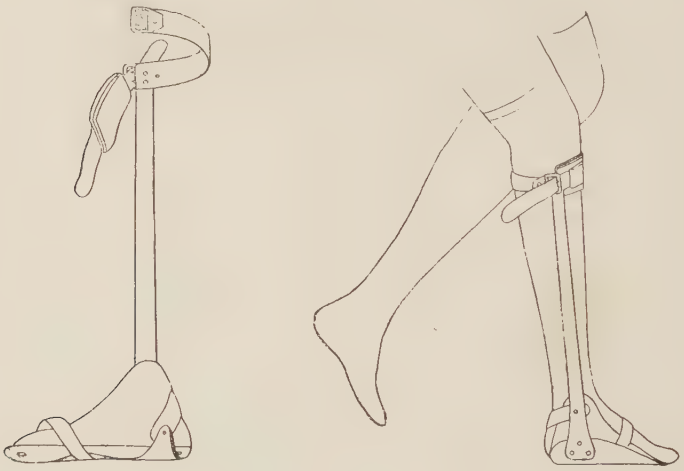

Fig. 815.—Judson's brace for calcaneus deformity.

away the point of fixation against which effective force can be exerted. If this is not marked the foot may be drawn as far as possible toward equinus and fixed in a plaster bandage, of which the sole part is made strong and unyielding. Upon this the patient may walk, the heel being

built up with cork wedges to make the sole level. When the contraction of the anterior tissues has been overcome the brace is applied and the usual treatment of manipulation and massage is continued (Fig. 816).

Prolonged fixation in the attitude of equinus by means of the plaster splint may be of value in early childhood, if the paralysis is not complete, and cures of apparently confirmed cases by this means have been reported[1] (Fig. 827).

FIG. 816.—The author's brace for calcaneus and lateral distortions of the foot. It consists of two light lateral steel bars joined in front above by a padded band of steel which crosses the upper third of the tibia, and below expanded to a narrow anterior sole plate, supplemented by a leather support for the sole. The brace is made on a plaster cast in the attitude of slight plantar flexion. The shoe is adjusted to the inclination of the brace by a cork wedge in the heel.

Operative Treatment.—In more extreme cases immediate reduction of the deformity under anesthesia may be attempted. The contracted tissues, more particularly the plantar fascia, may be divided subcutaneously or by open incision; then by forcible manipulation on wrenching, the sole may be somewhat lengthened and the heel pushed upward and backward to permit of slight plantar flexion. In this attitude the foot should be fixed by means of a plaster splint. In the reduction of the deformity one must not merely force the forefoot downward, as this would simply increase the cavus, but whatever correction is

[1] Gibney: Tr. Am. Orthop. Assn., 1900, vol. 13.

accomplished should be by means of elevation of the os calcis and elongation of the tissues of the sole of the foot. In cases of extreme deformity the contracted tissues in the anterior aspect of the ankle must be divided also.

In some instances the improved position of the os calcis may be assured for a time by shortening the tendo Achillis, as first performed by Willett, of London.[1]

Willett's Operation for Calcaneus.—A Y-shaped incision about two inches in length is made through the tissues down to the tendon. At the lower vertical part of the incision, which is continued down to the tuberosity of the os calcis, the tendon is dissected from the surrounding

Fig. 817.—Paralytic calcaneus showing secondary changes in contour, particularly the entire disuse of the forefoot.

parts. It is then divided in an oblique direction from within outward and downward, and the heel having been pushed upward as far as possible the divided ends are overlapped and sutured; the flap of skin is drawn downward at the same time, so that the Y-incision is converted into the shape of a V. According to Mr. Willett's original directions, deep sutures are passed through the skin flaps and through the tendon on either side, so that all the tissues are united. The foot is then fixed in a plaster support in an attitude of equinus. As soon as practicable the patient begins to use the foot, wearing a high heel to compensate for the elevation of the sole.

[1] St. Bartholomew's Hosp. Reports, 1880, **16**, 309.

Palliative operations of this class aside from lessening deformity may be of service in those cases in which some power remains in the calf muscle. In cases of complete paralysis the shortened tendon offers some resistance to deformity, but unless support is used afterward the tissues will stretch under the strain of use; thus the treatment should always be supplemented by a brace of the character already described.

Silk Ligaments.—This operation has been generally abandoned as useless.

Tendon Transplantation.—The original operation of Nicoladoni of transplanting the peroneal tendons to the tendo Achillis, or any of its modifications, are of little value except perhaps as adjuncts to mechanical support, since the power of the transplanted muscles is insignificant in comparison to that of the calf muscle, which is three times greater than that of all the other leg muscles combined.

FIG. 818.—Talipes calcaneus in early childhood.

Tendon Fixation and Transplantation.—Gallie[1] combines tendon fixation and transplantation. In cases in which the paralysis of the calf is not complete, the tendo Achillis is split from side to side and the anterior half is embedded in the tibia. The two peroneal tendons are passed through a hole bored in the os calcis in opposite directions and sutured. The field of the operation is very limited and it would appear that the removal of the peronei in conjunction with limited dorsal flexon should predispose to varus unless constant supervision is assured (Fig. 812).

Arthrodesis.—The method of Jones is the most effective of the operations of this class. It is divided into two stages. The cavus is first corrected by the removal of a wedge-shaped section of bone from the dorsum of the foot at the mediotarsal joint which is closed by forcing the forefoot into dorsal flexion. Later, an arthrodesis operation is performed at the ankle-joint in the usual manner.

Arthrodesis operations have the disadvantage that they are not effective in inducing anchylosis until the development of the bones is fairly advanced and consequently are not available at an early age, that the foot is fixed at a right angle to the leg so that shortening of the limb cannot be compensated by an elevation of the heel, but requires an unsightly cork sole, and finally, because it enforces disuse of muscles that are still active. These procedures have not been described in detail because they have been in great degree supplanted by the opera-

[1] Ann. Surg., January, 1915.

tion of astragalectomy and backward displacement of the foot, which has in comparison very great mechanical and practical advantages. The removal of the astragalus by relieving the contraction of the tissues on the front of the leg permits backward displacement and thus automatically reducing the cavus and restoring the prominence of the heel without violence. Lateral security is assured by the implantation of the malleoli upon the basic structure of the foot and dorsal flexion is checked by contact of the tibia and the scaphoid. This impact assures the resistance or grip of the foot, restores a fairly normal gait and stimulates the nutrition and development of the limb. Thus security is assured while movement is retained, a compound, uncontrolled joint having been transformed to a simple one. Tendon transplantation in suitable cases may supplement the operation. The operative details are as follows:

FIG. 819.—Shows the incision. The peroneal sheath has been opened and the tendons drawn back exposing the lateral ligament.

Astragalectomy, Backward Displacement of the Foot and Tendon Transplantation (the Author's Operation[1]).—The line of incision begins at a point about an inch above the extremity of the external malleolus midway between it and the tendo Achillis, and is continued downward and forward about three-quarters of an inch below the malleolus over the dorsum of the foot to the external surface of the head of the astragalus.

The sheaths of the peroneii tendons are opened and the tendons are drawn backward (Fig. 819). The bands of the external lateral and interosseous ligaments are divided and the head of the astragalus is freed from its attachments to the tibia and scaphoid. An elevator is

[1] Am. Jour. Med. Sci., November, 1901, and Ann. Surg., February, 1908; Am. Jour. Orthop. Surg., August, 1910; Med. Record, January, 1914.

MEDICAL LIBRARY
OF THE
925
BOSTON CITY HOSPITAL

then inserted between it and the os calcis, and foot being forcibly inverted, the head of the astragalus is extruded, and the attachments



FIG. 820.—The attachments of the astragalus having been divided it is extruded by adducting the foot and by inserting a periosteal elevator beneath it.

on the inner and posterior borders having been cut or ruptured, it is removed (Fig. 820).

FIG. 821.—The foot is completely turned over toward the inner side exposing the articulating surface of the tibia preparatory to laying bare the malleoli.

The foot is then turned completely to the inside exposing the articular surfaces of the leg bones. The attachment of the ligaments to the internal malleolus are dissected upward, and with a chisel the inner surface of the external malleolus is cut to an even plane (Fig. 821).

One, then, prepares the new articulations. A thin section of bone is cut from the adjoining surfaces of the cuboid and os calcis and,

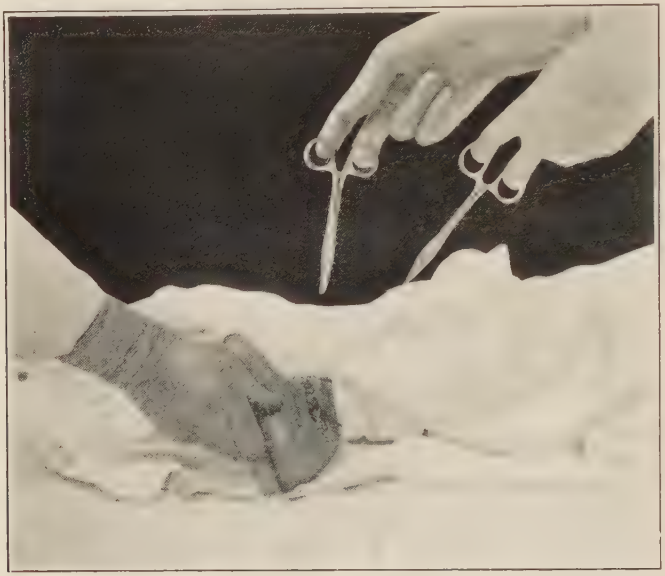

Fig. 822.—Shows the suture apposing the external malleolus and the calcaneo-cuboid articulation.

together with the overlying muscles, is displaced outward to form a bed for the external malleolus. On the inner side a knife is passed

Fig. 823.—The line of suture and the new relation of the leg and foot.

about the superior and internal surface of the scaphoid and the tissues are separated with an elevator.

The foot is now displaced backward so that the external malleolus may cover the calcaneo-cuboid articulation and the internal overlap

FIG. 824.—The plaster splint and elevation of the limb.

the navicular, and in order to assure security, the bone and tissue flap cut from the cuboid is attached by strong kangaroo tendon to the

FIG. 825.—Talipes calcaneus before operation, illustrating mechanical instability, particularly the elevation of the malleoli from the base. (See Fig. 826.)

external malleolus (Fig. 822). The wound is then closed with catgut or silk sutures, and the foot is fixed by a plaster splint in an attitude of moderate plantar flexion and abduction.

In the routine of hospital practice the operation is performed under the Esmarch bandage. The wound, having been cleansed with warm saline solution, is closed without drainage. The foot and limb are bandaged with sterilized sheet wadding, over which a light plaster is applied, holding the foot in the attitude described, with the leg flexed on the thigh. The limb is afterward suspended between tapes running from the head to the foot of the bed. Great care is taken to avoid constriction. To this, to the rest assured by the plaster splint, and to suspension, are ascribed the very slight discomfort following the operation and the absence of complications (Fig. 824).

Fig. 826.—Talipes calcaneus immediately after operation, taken through the plaster. (Compare with Fig. 825.) Showing the backward displacement of the foot and the contact of the tibia and the navicular, which checks dorsal flexion. The cavus is reduced by the removal of its apex and the weight of the body transferred forward will automatically reduce the residual deformity when locomotion is resumed.

At the end of about three weeks the first support is removed, and the walking plaster splint is substituted, extending to the knee, and fixing the foot in the same attitude of moderate equinovalgus, the sole being equalized by the incorporation of a wedge of cork. The patient is encouraged to walk with equal steps, and to bear weight on the forward part of the foot. At the end of from two to four months the new joint will have become stable, and the fixed support may be discarded for a shoe arranged with a cork wedge beneath the heel, of sufficient thickness, is compensated for slight equinus, and

if necessary the outer border of the sole is thickened somewhat to prevent a tendency to inversion (Fig. 827[1]).

FIG. 827.—The plaster walking support with cork wedge holding the foot in equinus.

Even in the cases in which after-treatment has been neglected, the nutrition of the limb and the appearance of the foot improve with the

FIG. 828.—The foot after the author's operation for calcaneovalgus, showing the restoration of symmetry. Also a simple brace that may be worn temporarily within the shoe in place of the plaster support during the period of repair.

gain in functional ability, and some of the patients walk so well as almost to merit the term "cure," as applied to cases of this class.

As originally described and as performed for many years the

[1] In the treatment of young children the plaster support is continued for a much longer time.

peroneal tendons were divided below the external malleolus, passed through a slit in the tendo Achillis, sewed there and then reunited to their distal extremities. This step has been discontinued in all but extreme cases of calcaneovalgus because the transplantation is of no functional value in locomotion and because in some instances it appears to favor subsequent inversion of the foot.

It may be noted that in all cases of calcaneus the foot is fixed in plantar flexion in order to force the disused forefoot to bear weight during the period of repair. In other types of deformity for which the operation is performed, if the limb is shorter the attitude of plantar flexion to which the shoe is adjusted is of advantage in equalizing the length of the limbs. If, however, the operation is designed simply to restore symmetry and stability as in cases of extensive paralysis in which braces must be worn, the right angular relation of the foot and limb must be maintained.

This operation, based on a mechanical readjustment of the leg with the foot, as contrasted with alternative procedures, is independent of the supplementary processes of natural adjustment and repair and is, therefore, by far the most dependable of the operations of its class.

It has the great advantage that since only a single bone is involved the operation may be performed at a much earlier age than arthrodesis and as soon as the permanency of the paralysis is established. Thus by restoring the resistance of the foot a more normal development of the limb, as well as improved function may be assured.

Unsatisfactory results, in the great majority of cases may be explained by defective operative technique or by misapprehension of the character of the paralytic disability for which the treatment is undertaken.

In perhaps 10 per cent. of the cases in which the essential requirements have been fulfilled, supplementary treatment will be required. If, for example, the tibialis anticus muscle is strong and active it may invert the foot. This may be remedied by transplanting the muscle to the outer border, and if the varus is pronounced it may be corrected by a cuneiform osteotomy.

In some instances the calcaneus may be transformed into a resistant equinus. This may be easily remedied by the removal of the upper border of the scaphoid at the point of impact with the tibia.

Very rarely there may be recurrence of calcaneus, due apparently to a slipping upward of the scaphoid on the rounded border of the tibia. This should be treated according to the condition found at operation. In some instances the anterior surface of the tibia is split and pried forward to meet a section of the tarsus displaced backward, but in most cases after the surfaces have been scarified a wedge is cut from the tibia to fill the interval between the tibia and tarsus.

ACQUIRED CALCANEOVALGUS AND CALCANEOVARUS.

In many cases the foot, deformed as a result of paralysis of the calf muscle, is in addition turned in a lateral direction, so that the weight of the body falls to the inner or outer side of its center (Fig. 829).

Calcaneovalgus, in which the foot is turned outward and upward, so that the patient walks on the inner side of the heel or even on the

Fig. 829.—Talipes calcaneovalgus, showing the characteristic distortion and atrophy of the foot and leg.

inner ankle, is by far the most common. It is usually a result of more extensive paralysis than simple calcaneus. For example, all the muscles about the foot may be disabled except the peronei, or in cases of a milder type the tibialis anticus may be the only muscle of the front of the foot that is paralyzed.

Treatment. — When the foot inclines toward calcaneovalgus it is difficult to hold it in proper position by the ordinary braces. More efficient supports are shown in Figs. 816 and 830. A plaster cast of the leg with the foot in a moderate degree of plantar flexion is made and on it the lines for the brace are drawn. Occasionally a metal sole plate is used, rising on the outer border to a somewhat less degree than on the inside. The uprights are riveted to the foot plate and are joined by a padded metal band just below the tibial tubercle, the circumference being completed by a strap. The shoe is adjusted to the brace by means of a cork wedge in the heel. (See Fig. 830.)

Fig. 830.—A brace for calcaneovalgus or varus.

Calcaneovarus is a much less serious affection, since the foot may be more easily

supported. A brace, such as is used in the treatment of ordinary varus, without motion at the ankle or provided with a reverse stop, is ordinarily employed. The operation of astragalectomy and backward displacement of the foot has practically displaced both mechanical and other operative methods in all cases of confirmed deformity of the calcaneous type.

In cases of calcaneovarus or valgus, in which the unapposed active lateral muscles cause distortion tendon transplantation may be indicated usually as a supplemental procedure to astragalectomy. The transplantation of either the tibialis anticus to the outer border of the foot or the tibialis posticus to the peroneal tendons or both being sometimes required for persistent varus deformity.

Tendon Transplantation.—When one or more of the muscles are paralyzed the action of the unapposed group distorts the foot. The object of tendon transplantation is to restore the muscular balance. Tendon transplantation was first performed by Nicoladoni in 1882[1] for the relief of paralytic calcaneus. The tendons of the peroneus longus and brevis were divided behind the external malleolus and the proximal ends united to the distal extremity of the divided tendo Achillis. This proved to be of no lasting value and the operation was not repeated by him.

The first operation on the front of the foot was performed by Parish,[2] of New York, for the relief of paralytic valgus, by sewing the tendon of the extensor proprius hallucis to that of the paralyzed tibialis anticus, without division of either tendon. The field of the operation has since been extended to include almost every possible combination of tendons and muscles.

The relative strength of a muscle may be fairly estimated by its weight.

Weight of the Muscular Substance of the Long Muscles of the Lower Extremity in the Adult. (Stoffel.)

Tibialis anticus	80 grams	
Extensor hallucis longus	18 "	
Extensor digitorum longus	30 "	
Peroneus longus	62 "	
Peroneus brevis	25 "	
Tibialis posticus	56 "	
Flexor hallucis longus	34 "	
Flexor digitorum longus	10 "	
Soleus	260 "	
Gastrocnemii	200 "	
Quadriceps	1650 grams	
Biceps	280 "	
Semimembranosus	300 "	760 "
Semitendinosus	180 "	
Gastrocnemius	200 "	
Soleus	260 "	460 "
Flexor hallucis longus	34 "	
Flexor digitorum longus	10 "	106 "
Peroneus longus	62 "	

[1] Arch. f. klin. Chir., 1882, **3**, **27**, S. 660.
[2] New York Med. Jour., October 8, 1892.

MEDICAL LIBRARY OF THE BOSTON CITY HOSPITAL

The functions of the muscles and their relative order of importance in the execution of each movement have been described. (Chapter XX.) They are indicated in the following table, modified somewhat from that of Codivilla:

	Dorsal flexion.	Plantar flexion.	Adduction.	Abduction.	Eversion.	Inversion.
Tibialis anticus	1	—	—	—	—	1
Extensor proprius hallucis	3	—	—	—	—	6
" longus digitorum[1]	2	—	—	3	3	
Peroneus brevis	—	6	—	2	2	
" longus	—	3	—	1	1	
Gastrocnemius and soleus	—	1	2	—	—	2
Tibialis posticus	—	4	1	—	—	3
Flexor longus hallucis	—	2	3	—	—	4
" " digitorum	—	5	4	—	—	5

Time for Operation.—The operation should not be undertaken until the degree of final paralysis has been definitely determined. This stationary stage may be reached in a comparatively short time, but in the ordinary cases in which, for want of protection, distortion has developed, it is practically impossible to estimate the latent muscular power until the deformity has been corrected and until the enfeebled muscles have been stimulated by functional use. In general, a period of several years at least should intervene between the onset of the paralysis and the operation.

The first essential for success by this means is a clear understanding of the mechanism of the disabled part and of the relative importance of its functions. As regards the foot, for example, plantar flexion is far more important than dorsal flexion, because the inability to plantar flex implies the loss of the principal lifting and propelling power of the body. Dorsal flexion is more important than adduction or abduction, because the drop-foot, so-called, interferes seriously with locomotion. Adduction is more important than abduction, because the loss of power to turn the foot inward induces the attitude of valgus, which is more difficult to control than the opposite deformity. To the importance of these movements the power of the muscles corresponds.[2]

Selection of Muscles.—In selecting muscles for transplantation one attempts usually to reduce the distorting power as well as to replace lost function. For example, if the tibialis anticus were paralyzed one would naturally replace it in part by its adjunct, the extensor hallucis. This might complete the operation, or the tendon of the peroneus tertius, the most direct abductor on the dorsal surface of the foot, might be divided and attached to the periosteum on the inner side of the foot, or the peroneus brevis may be changed from a direct to an indirect abductor by dividing it and sewing it to the longus to further assure the success of the operation.

If, on the other hand, the dorsal abductors were reduced in strength so that the foot turned inward in dorsiflexion, the tibialis anticus tendon should be divided at its insertion, transplanted to the outer

[1] Including peroneus tertius.

[2] See tables on pages 932 and 933.



FIG. 831.—The muscles and tendons on the front of the leg. (Gerrish.)

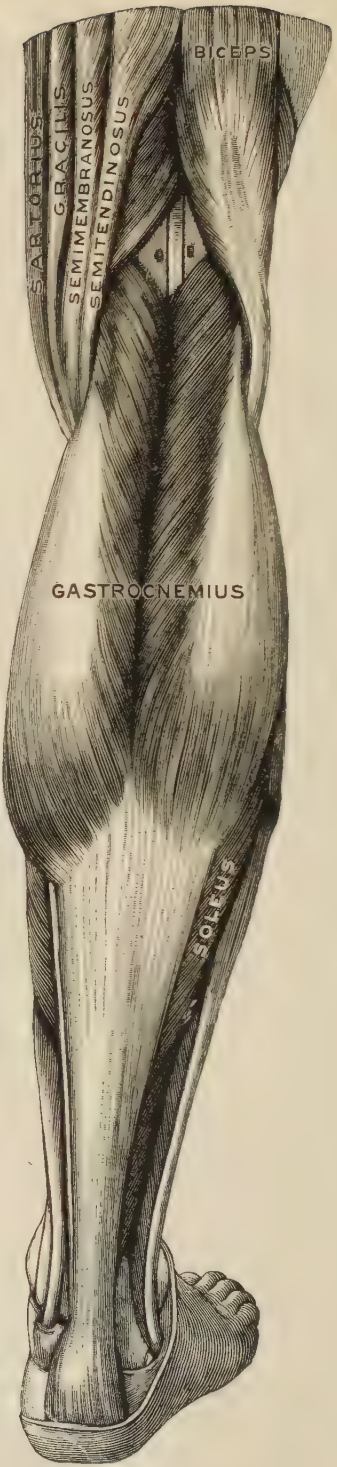

FIG. 832.—The muscles and tendons on the back of the leg. (Gerrish.)

border and fastened securely at or near the insertion of the peroneus tertius as well as to that tendon; thus the power of adduction would be weakened and that of abduction increased.

In other instances the peroneus longus is carried across the front of the leg and is implanted on the inner border of the foot; or the peroneus brevis transplanted in the same manner or carried behind the internal malleolus to serve as an adductor. It must be borne in mind that lessening the deforming power of the muscles is as important in reëstablishing balance as restoring in some degree that of the paralyzed muscles. Other procedures may be combined with tendon transplantation to assure stability, as described elsewhere.

If the calf muscle is weak, and if the foot is inclined toward valgus because of weakness of the adductor group, the two peroneii tendons may be attached at the insertion of the tendo Achillis, not, of course, with the aim of replacing its propelling function by two such feeble muscles, but to remove a distorting force and to transfer it to a point where it may aid in preventing lateral deformity and be of some functional service, even if slight. (See Talipes Calcaneus.)

Valgus due to paralysis of the tibialis posticus muscle may be treated by dividing the peroneus brevis at or near its insertion, passing it beneath the tendo Achillis and attaching it to the tendon of the paralyzed muscle. It may be mentioned, also, that sections of the tendo Achillis have been used to strengthen either the posterior adductors and abductors and even those of the anterior group. As has been stated, one must plan the operation according to the function that is lost and the power that remains and combine this procedure if possible with other methods of assuring stability. As a rule the most successful operations are those in which a muscle of similar function to that of the paralyzed one is transplanted. It is apparent, also, that it will be of little use to transfer a muscle unless its origin is such that it can work at a mechanical advantage at its new point of attachment. For example, an anterior adductor may be changed to an abductor, and the function of a posterior adductor or abductor can be similarly transferred; but

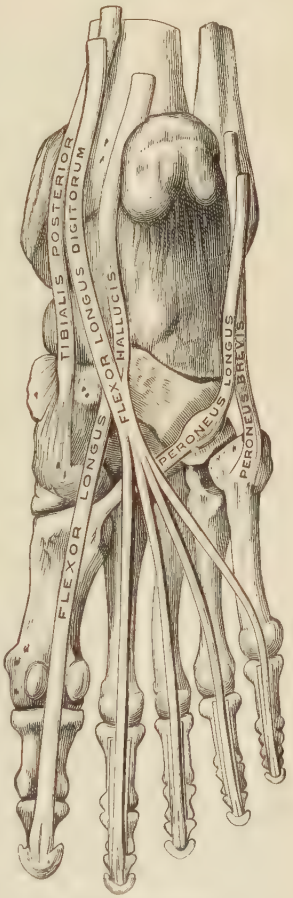

FIG. 833.—Tendons in the right sole. (Gerrish's Anatomy.)

a posterior plantar flexor can never be equally efficient as a dorsal flexor, nor can one muscle act as an extensor and as a flexor at the same time, as would appear to be the belief of certain contributors to the literature of the subject. The variety of combinations of this character that have been advocated is very large, but it is hardly necessary to describe them. As has been mentioned, one may always sacrifice a less important to a more important function, and as a weak muscle can hardly carry out its original function and a more important one as well, it is advisable in most instances to relieve it completely of the first in making the transfer.



FIG. 834.—The relative size and structure of the muscles as indicative of strength: *a*, tibialis anticus; *b*, extensor longus hallucis; *c*, extensor longus digitorum and peroneus tertius; *d*, peroneus brevis; *e*, peroneus longus. (Stoffel.)

The Operation.—The technic of the operation is simple. All restriction to normal motion should be overcome by preliminary treatment in order that the degree and extent of functional impairment may be accurately determined. The incision either continuous or divided should expose the muscular substance of the muscles and the point at which the transplanted tendon is to be attached. By such direct examination one may verify the diagnosis. A completely paralyzed muscle is atrophied and of a dull, reddish-yellow color, and its tendon

often of a yellowish-white tinge. A partially paralyzed muscle is atrophied, its tendon is small, but it retains the silvery glisten of the normal structure. The tendon sheaths having been opened, the tendon is divided near its insertion, and having been freed from any restraint that might impair its direct action, it is placed in apposition to the tendon of the paralyzed muscle, whose surface has been freshened with the knife, or better, it is passed directly through it and its extremity is sewed to the periosteum of the neighboring bone. The two tendons are then attached to one another by several sutures of silk or other material, and the graft is covered by uniting the tendon sheath or

FIG. 835.—The relative size and structure of the muscles as indicative of strength: *a*, gastrocnemius; *b*, soleus; *c*, flexor longus digitorium; *d*, flexor longus hallucis; *e*, tibialis posticus. (Stoffel.)

fatty tissue over it with fine catgut. In many instances the transplanted tendon is attached elsewhere than at the site of the paralyzed tendon and is not, therefore, sewed to it, and whenever practicable it is passed through the tendon sheath of the paralyzed muscle to lessen the danger of adhesions.[1] The skin incision is closed with a continuous catgut suture. The graft should be applied under a certain tension, all the slack being drawn in, as it were, so that the foot may be held if

[1] Biesalski: Verhand. d. Orth. Gesells., 1915.



Fig. 836.—Cross-section of the leg muscles: *a*, flexor longus hallucis; *b*, tibialis posticus; *c*, flexor longus digitorum; *d*, soleus; *e*, tibialis anticus; *f*, extensor longus hallucis; *g*, extensor longus digitorum; *h*, peroneus longus; *i*, peroneus brevis; *k*, gastrocnemius. (Stoffel.)

Fig. 837.—Paralytic equinovarus before operation. (See Fig. 838.)

possible in the normal attitude. Stability may be further assured in some instances by implantation of the tendon of the paralyzed muscle in the bone or by arthrodesis operations. A plaster support is then applied in the overcorrected position, and in this attitude the foot should be used for several months until a change in its shape and structure may further assure stability. For stability in weight-bearing is ordinarily of far greater importance than complete restoration of a range of motion.

FIG. 838.—Paralytic equinovarus cured by operation, showing power of dorsal flexion (one-half of the tendon of the tibialis anticus attached to the periosteum of the outer border of the foot). Operation, July 19, 1898. The direct union of tendons to periosteum at the most advantageous point was introduced by Lange. (Ueber Periostale Schnenverpflanzung bei Lähmung, München. med. Wochnschr., 1900, No. 15.)

Modifications of the Operation.—As has been stated since its introduction, the operation of tendon transplantation has been modified in several particulars. It has been demonstrated by experience that there is a strong tendency toward relapse to the original deformity, because of weakness of the transposed muscle, adhesions about the tendon, the mechanical disadvantage at which it acts and in some degree because of the insecurity of its attachment.

Lange was the first to urge that the tendon of the living muscle should not be attached to that of the paralyzed one, but should be fixed directly to the periosteum or bone at the point of greatest mechanical efficiency. This procedure has now been generally adopted or at least the tendinous attachment has become supplemental to the periosteal. If the tendon is not long enough for this purpose it may be lengthened by means of a silk cord quilted into its substance. By this means the scope of the operation has been greatly extended both in applicability to the foot and to other parts of the body. Lange uses strong silk ligatures previously boiled in a solution of corrosive

sublimate (1 to 1000). These are dried and are preserved in paraffin, which lessens the danger of adhesion with the surrounding tissues. The muscle to be transferred, for example the peroneus longus or brevis, to replace the tibialis anticus is exposed by a long incision over the fibula. It is separated in the greater part of its area from its attachments, its extremity is passed across the front of the leg beneath the skin and is drawn through an incision in the line of the tibialis anticus. To it the silk cord is attached by quilting it through its sub-

Fig. 839.—The peroneus longus transplanted to the front of the limb to serve as a dorsal flexor.

Fig. 840.—The peroneus brevis carried behind the leg and the internal malleolus to the tendon of the tibialis posticus to serve as an adductor.

Fig. 841. — The tendon of the tibialis posticus displaced forward to serve as a dorsal flexor.

stance. A free channel is then made directly beneath the skin to an incision over the scaphoid. Through this the silk tendon is drawn and is firmly attached to the periosteum of the navicular. The foot is then fixed in the inverted position by a plaster support. In most instances, however, if the tendon to be transplanted is divided at its insertion the use of silk prolongation may be avoided.

Leo Mayer, in connection with Biesalski,[1] has made a special study of the physiology of the tendons and has emphasized the importance

[1] Die Physiologische Sehnenverplanzung, Berlin, 1916.

MEDICAL LIBRARY OF THE

of utilizing the tendon sheaths in transplantations in order to lessen the danger of adhesions, and this procedure has been generally adopted. If, for example, the peroneus longus is transplanted to the inner side of the foot, it is drawn through the sheath of the tibialis anticus. If the tibialis anticus is transferred to the outer side it is inserted into the common sheath of the extensor tendons and finally brought to the outside through the sheath of the peroneus tertius. As far as possible the mesotendon should be preserved to assure nutrition and the gliding function favored, as illustrated in Figs. 845 and 846.

Fig. 842. — Transplantation of the tibialis anticus to the outer border of the foot. In some instances the tendon is split to the muscular substance and the outer half transplanted.

Fig. 843. — Extensor proprius hallucis transplanted to the scaphoid region.

Fig. 844.—The tendon of the peroneus brevis displaced forward to serve as a dorsal flexor.

Tendon Transplantation in Combination with Other Procedures.—As the object of operative treatment is to prevent deformity and to increase the stability of the foot, tendon transplantation may be of greater service when combined with other operations. For valgus deformity arthrodesis of the astragalo-navicular articulation is a valuable adjunct of tendon transplantation. An incision about three inches in length, long enough to expose the muscular substance of the extensor longus hallucis and the astragalo-navicular articulation is made. This joint is then opened and the cartilage is thoroughly removed from the adjoining bones. The paralyzed tibialis anticus may be implanted in the lower end of the tibia to serve as a passive support for the inner border of the foot. The tendon of the proprius hallucis is then divided and is sewed to the inner border of the navicu-

lar to become an active if weak supinator. The ligament covering the denuded bones is then shortened and sewed with silk or kangaroo sutures, the wound is closed and the foot is fixed in extreme inversion and slight dorsal flexion by a plaster bandage. A similar procedure is employed if the deformity is of the varus type. A thin wedge of bone, including the calcaneo-cuboid and the outer half of the astragalo-navicular articulation, is removed from the dorsal aspect of the foot.

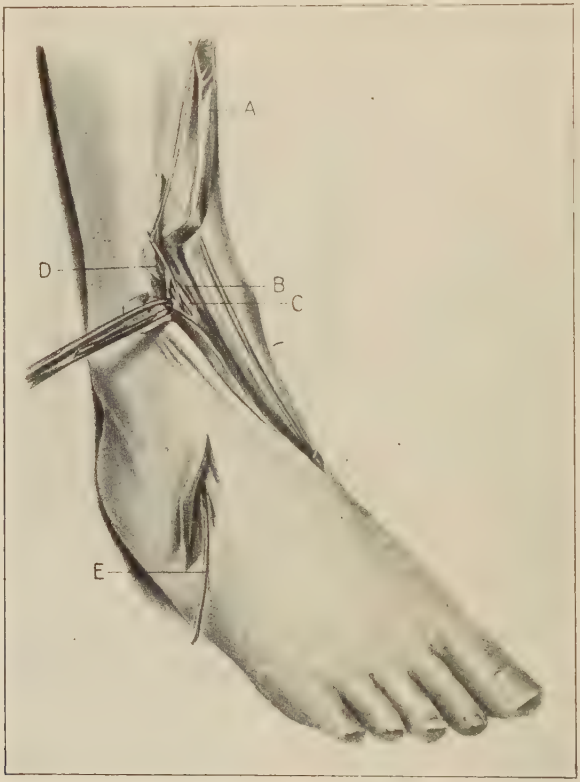

Fig. 845.—The tibialis anticus transplanted to the outer border of the foot, showing the probe passed through the sheath of the extensors of the toes by the side of the peroneus tertius. *A*, the tendon of the tibialis anticus muscle provided with strings for tying; *B*, extensor hallucis longus muscle; *C*, medial tendon of the extensor digitorum longus; *D*, fascia drawn aside; *E*, the probe passes through the sheath of the extensor digitorum and is pushed out at the termination of the sheath of the peroneus tertius. (Biesalski and Mayer.)

Forced abduction closes the opening and continued contact is assured by several heavy silk sutures. The tibialis anticus tendon is then transplanted, passing through the sheath of the peroneus tertius and is attached as low as possible on the outer border of the foot. In most distances, however, arthrodesis at the subastragaloid in addition to that at the astragalo-scaphoid articulation, as suggested by Codivilla and Davis, is advisable if the deformity is of long standing. The

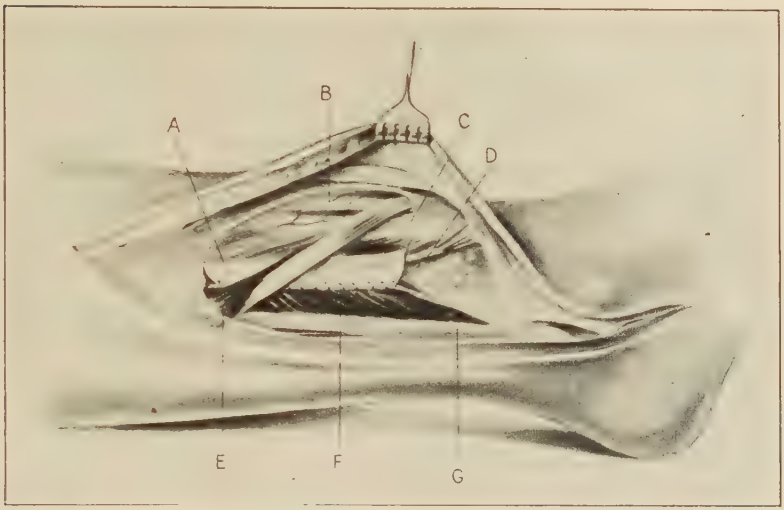

FIG. 846.—Transplantation of the peroneus longus to replace the tibialis anticus The tendon is passed through the sheath of the tibialis anticus. *A*, the deep fascia turned back and sewed to the peroneus brevis; *B*, tibialis anticus muscle; *C*, extensor digitorum longus muscle; *D*, peroneus tertius muscle; *E*, peroneus longus muscle; *F*, suture of fascia; *G*, peroneus brevis muscle. (Biesalski and Mayer.)

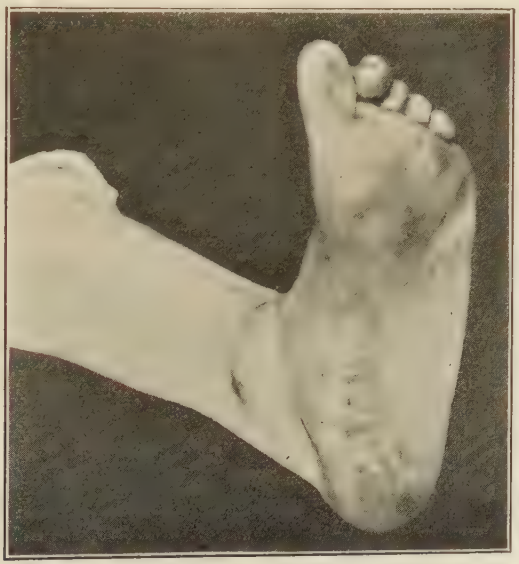

FIG. 847.—Talipes equinovalgus after treatment by tendon transplantation. The tendon of the peroneus tertius was attached to the overlapped and shortened tendon of the tibialis anticus. All the tendons on the front of the foot were then united, so that all might serve as dorsal flexors.

posterior articulation is reached by a longitudinal incision below the external malleolus. The adjoining surfaces are thoroughly "dug out" and all bone chips are left.[1]

The foot should be retained for several months in the corrected attitude by a plaster support, on which the patient walks about until the parts have thoroughly conformed to the new position, the aim being to supplement muscular weakness by a fixed attitude slightly opposed to that for which the operation was performed. In many instances further support is unnecessary, but a brace should be used if there is a tendency toward deformity. Massage, passive and active exercises in the direction opposed to deformity are of great importance in after-treatment and may be begun early in those cases which are under careful supervision.

The prognosis depends upon the degree of permanent paralysis and its distribution. It is, of course, evident that tendon transplantation is essentially a palliative rather than a curative operation. In selected cases in which the attachment is directly to the bone, and especially when lateral motion is checked by arthrodesis, the results are very satisfactory. The improvement in functional ability is immediately shown in the nutrition of the limb. In selected cases of this class the transferred muscle is efficient in the new function, but in all cases deformity must be prevented by manipulative exercises and by balancing the shoe.

Silk Ligaments.—As has been mentioned elsewhere, silk ligaments were originally designed as permanent internal stays to support the foot in the desired position on the assumption that they might be transformed to unyielding fibrous tissue. They may be of some service in connection with braces as an additional means of security or in combination with arthrodesis or tendon transplantation, but it is now generally admitted that their usefulness is very limited. Lovett[2] describes the operation as follows (Fig. 804):

"In the technic one or two matters are of much importance. The crest of the tibia above the ankle is exposed, periosteum incised and turned back, and a hole drilled in the bone. One of the bones in the tarsus at the inner or outer side of the foot, or both, as the indication for support determines, is drilled in the same way, and one or two strands of heavy silk are passed through the tibial hole under the annular ligament, through the tarsal hole, and tied. The knot must come in the upper wound, as otherwise it is likely to chafe through from pressure of the boot. At least three months' support is necessary, and probably more."

Tendon Implantation or Tenodesis.—Although operations for the conversion of the tendons of paralyzed muscles into ligaments have in past years been performed by several surgeons, Gallie has perfected and popularized the procedure which has in great degree supplanted the use of silk ligaments. The operation in brief consists of separating

[1] Davis: Am. Jour. Orthop. Surg., November, 1916.
[2] Jour. Am. Med. Assn., January 24, 1914.

the periosteum from the bone and gouging a trough of sufficient depth to contain the tendon which is placed within it at sufficient tension to hold the foot in proper position, and fixed by kangaroo-tendon sutures passed from the periosteum and cartilaginous covering of the bone through the tendon which is thus embedded in the bone. In the earlier operations the tendon was not separated from the muscular substances but such division does not affect the result. The tendon sheath must be thoroughly removed, the tendon bruised, and it is well to leave the bone chips in the groove in order to assure fixation. The operation is sometimes useful as an adjunct to tendon transplantation in the treatment of lateral distortions. The tendon of the tibialis anticus may be implanted on the internal aspect of the tibia for valgus; or the two peroneii into the fibula for varus, as shown in the illustrations (Figs. 806 and 811), but as an independent procedure, at least in childhood, it is of doubtful value as a permanent support.

Arthrodesis.—The removal of the cartilaginous surfaces of articulating bones to induce anchylosis for the relief of paralytic deformities of the foot was first performed by Albert, of Vienna, in 1878. As applied to the foot, it is of special service as the mediotarsal and subastragaloid joints in connection with tendon transplantation to prevent lateral deformity. It is of little value in the younger class of patients, as the bones are not sufficiently developed to assure firm adhesion. An age limit of eight years has been suggested.

Formerly it was employed to fix the ankle-joint but far less often at the present time. The operation consists in opening the joint and removing the cartilage from the apposed surfaces of the bones, then fixing them in contact by nails, bone pegs, sutures or bone grafts until union has taken place. The usual incision is about two inches in length over the front of the ankle-joint. The foot is then plantar flexed and the cartilage is thoroughly removed from the articulating surfaces with a thin chisel or knife. The lateral incision as used for the removal of the astragalus with inward displacement of the foot permits a more thorough inspection of the joint and in many instances it is to be preferred. As the removal of the cartilage at the ankle-joint increases its capacity and thus prevents accurate apposition, Farrabeuf and Goldthwait divide the fibula above the articulation so that it may be forced against the astragalus. If lateral deformity is present the subastragaloid joint is destroyed. By prolonging the lateral incision over the dorsum of the foot the mediotarsal may be reached and by an incision below the external malleolus that between the astragalus and os calcis. As a rule in cases of complete paralysis of the anterior group simple anchylosis at the ankle-joint is not sufficient to prevent the toe-drop, and it is well to include the mediotarsal joint also. A convenient method is to remove the cartilaginous surface of the astragalonavicular and calcaneocuboid articulations, including a thin wedge of bone, base uppermost. In some instances the tendons of the paralyzed muscles are implanted after the Gallie method to aid

in retaining the foot in the improved position. This, however, is of minor importance. The operation should be performed under the Esmarch bandage, and the limb should be elevated for a time to prevent the subsequent bleeding from the bones (Fig. 802).

The improvement in the gait, obtained by the rectification of deformity, and by fixation of the foot, after arthrodesis, is often very marked. In many instances, though bony anchylosis is not attained, the limitation of movement is sufficient to restrain deformity and to permit the patient to discard apparatus, although discomfort on overuse or strain is often experienced. Anchylosis at the ankle-joint has the disadvantage of hampering the function of all the active muscles, and fixation at a right angle prevents the adjustment of an inoffensive shoe to compensate for a shortened leg. For these reasons it has been in great degree supplanted by astragalectomy and backward displacement of the foot which assures security and yet permits the attitude of plantar flexion and the adjustment of an extension shoe.

Subastragaloid Arthrodesis.—The most useful of the arthrodesis operations is that of the joints below and in front of the astragalus for lateral instability of the foot, an operation introduced by Davis, of Philadelphia. The steps are very simple. An antero-posterior incision, about 2 inches in length, is made directly below the external malleolus, the peroneal tendons are displaced backward, exposing the posterior articulation between the astragalus and os calcis. With a chisel the cartilage and sufficient bone is removed to form a flat surface, although, according to Dr. Davis, gouging and consequent irregularity favors more solid union. The anterior extremity of the incision exposes the joint between the os calcis and cuboid from which the cartilage is removed. A similar incision is then made on the inner border of the foot, extending backward from the navicular, exposing the anterior and inferior surface of the astragalus and the sustentaculum tali. The cartilage is removed from the apposing bones or, according to Davis, gouged into a rough surface which is probably more effective in young subjects. The wounds are closed without drainage, support applied and, as soon as possible weight-bearing is resumed. Support is retained for several months, until fixation is assured. This type of operation is often combined with tendon transplantation.

Transverse Section of the Foot.—Davis attempted to indirectly stabilize the ankle-joint by dividing the foot into two parts in the plane of the joint between the os calcis and astragalus, the division being carried forward to emerge in the cuneiform region. The separation was accomplished with a chisel through the same incisions as for the arthrodesis and the lower fragment was forced backward from the upper, the aim being to displace the leg forward, more toward the center of the foot, as in the operation of astragalectomy.

Dunn's Operation.—The same object, namely, to secure lateral stability and to force the foot backward, is more definitely attained by the operation of Naughton Dunn. The fixation is more effective because the bones are brought into close contact after the resection, by the

backward displacement. In this operation an incision is made below the external malleolus and is carried forward to the base of the fifth metatarsal bone, the origin of the extensor brevis digitorum muscle is separated from the bone and with the other tendons is displaced inward, exposing the dorsum of the foot. Sections of the adjoining bones are then cut away with a chisel. The scaphoid is entirely removed, an oval depression corresponding to the neck of the astragalus is cut from the cuneiform bones and the lower segment is forced backward sufficiently to close the openings.

A similar, although less radical, operation is the routine at the New York Orthopaedic Hospital.[1] The joints are exposed by incisions of the Davis type the attachments of astragalus and os calcis are completely separated and sections of bone and cartilage are removed from the junctions of the astragalus and scaphoid and the os calcis and cuboid. Apposition is then assured by forcing the foot backward beneath the astragalus. This type of operation is an improvement on that of Davis because a larger surface of bone on either side of the joints is brought into contact. A simpler and more effective method of approach is that similar to astragalectomy (MacAusland.) The peroneal tendons are divided and the attachments of the os calcis and navicular having been cut, the foot is displaced inward beneath the astragalus, thus exposing all the joints which are involved in the procedure. It is evident, however, that this type of operation, although it reduces the adverse leverage, does not prevent dorsal flexion of the foot, and therefore it cannot restore the resistance or grip of the forefoot that is the first essential in the treatment of paralytic calcaneus.

REVIEW OF THE OPERATIVE PROCEDURES FOR THE RELIEF OF PARALYTIC DEFORMITIES OF THE FOOT.

The primary object of operative treatment is to assure security in weight-bearing and thus to relieve the patient from the burden of mechanical support. The chief source of insecurity when the foot is unbalanced is the astragalus and the compound joint of which it is a part. Consequently its removal and the implantation of the leg bones near the center of the foot, with the limited movement that the new and simple joint permits, assures from the mechanical standpoint the greatest security consistent with the retention of motion. This operation is, therefore, the most useful and the most comprehensive of its class for the more extreme types of paralytic disability. It is the only effective operation for calcaneus because it assures a mechanical check to dorsal flexion and thus restores the weight-bearing capacity of the forefoot, and thus the complete extension at the hip and the knee essential to stability in locomotion. This restoration of what may be called the grip of the foot is of great importance in increasing stability in cases of extensive paralysis of the limb, and

[1] Smith and Von Lackum: Surg., Gynec. and Obst., June, 1925.

the operation is sometimes performed for this purpose, irrespective of the type of local deformity, as, for example, an essential preliminary to transplantation of the biceps muscle.

Finally, the operation, as compared to that of Dunn's and other procedures of this type, when performed during the growing period has the great advantage that but a single bone, practically independent of the basic structure of the foot, is removed. Therefore, development will be less affected.

Considered as an independent operation, tendon transplantation is of limited value. The transplantation of any or all the posterior muscles with the purpose of restoring the propelling force of the calf muscle is futile. The operation is of greatest service in the cases of lateral distortion of the foot and as a subsidiary to other procedures.

Arthrodesis is of most service at the subastragaloid and mediotarsal joints in combination with tendon transplantation to assure lateral stability. It is rarely indicated at the ankle-joint.

Tendon implantation as an independent operation has a limited field, but it may be combined in many instances with stabilizing operations to the mutual advantage of both procedures.

MEDICAL LIBRARY
OF THE
TON CITY

CHAPTER XXIV.

COLLATERAL ORTHOPAEDIC SURGERY.

This chapter, originally entitled Military Orthopaedics, has been retained and expanded because it seemed to contain material of collateral or incidental interest to the readers of a treatise of this character.

As has been stated already it is impossible even if it were desirable to set definite limits to orthopaedic surgery, but under certain conditions, as in Military Service, an arbitrary division of patients must be made.

The American Medical Department adopted the following classification:

1. All amputations.
2. Deformities of the extremities due to or associated with contractures of muscles, ligaments and tendons.
3. Derangements and disabilities of joints, including articular fractures.
4. Deformities and disabilities of the feet.
5. Cases requiring tendon transplantation.

The British classification was more comprehensive and the service was conducted on a much larger scale. It included:

1. Bone lesions, ununited and malunited fractures, and contracted scars.
2. Nerve injuries complicated by fractures and contracted scars.
3. Acute and chronic disabilities of the joints.
4. Injuries of muscles, ligaments and tendons.
5. Deformities and disabilities of the feet of all types.
6. Cases requiring tendon transplantation and similar measures.
7. Cases requiring surgical appliances.
8. Amputation, repair of stumps and adjustment of artificial limbs.

It has been estimated that 20 per cent. of all military casualties are of an orthopaedic nature—that 70 per cent. of returned surgical cases are of this class, and that in 20 per cent. of these operations are required.[1]

Military orthopaedics includes upbuilding as well as repair, and this phase has been perhaps more developed in this country than elsewhere. Formerly only the physically fit were accepted for military service, but under the system of universal conscription a large proportion of those who might have been rejected were retained with the expectation that they might be brought into condition by preliminary training in the camps.

The following rules of the selective service indicate the relative importance of physical defects in prospective recruits, and to these is appended a similar estimation of the degree of disability for injuries received in the service from the stand-point of compensation. These schedules are presented because they may serve equally well in the industrial field, for since compensation is now paid for both direct

[1] Starr: Am. Jour. Orthop. Surg., July, 1918.

and indirect disability from injury it would seem that a physical examination should be made as a preliminary to employment.

1. Registrants who on examination are found to present the following conditions, who are otherwise mentally and physically fit, shall be unconditionally accepted for general military service.

SPINE.

(*a*) Normal spine.

(*b*) Lateral curvature of the spine of two inches or less from the normal midline if the mobility and weight-bearing power are good.

(*c*) Fracture of the coccyx.

(*d*) Temporary defects in the form of recent contusions or sprains of the spinal column.

(*e*) Pilonidal sinus (this usually presents itself in the region between the coccyx and anus) if unattended with disease of the bone as shown by a roentgen-ray plate.

2. Registrants who on examination are found to present the following defects, who are otherwise mentally and physically fit, may be accepted for special and limited military service:

(*a*) Lateral deviation of the spine from the normal midline of more than two inches and less than three inches.

(*b*) Non-tuberculous diseases of the spine which are unassociated with such rigidity that the registrant has been incapacitated from following a useful vocation in civil life.

(*c*) Fracture of the spine or pelvic bones which have healed without defects and which have not interfered with their following a useful vocation in civil life.

3. Registrants who on examination are found to present the following defects shall be *unconditionally rejected* for all military service:

(*a*) Extensive disease of the vertebræ.

(*b*) Tuberculosis of any portion of the vertebral column.

(*c*) Abscess of the spinal column.

(*d*) Osteoarthritis, partial or complete, of the spinal column.

(*e*) Healed fractures of the vertebræ or pelvic bones with associated disqualifying rigidity.

(*f*) Lateral deviation of the spine from the normal midline of more than three inches.

SACRO-ILIAC AND LUMBO-SACRAL JOINTS.

4. Registrants who on examination are found to present the following conditions, if otherwise mentally and physically fit, shall be *unconditionally accepted* for general military service:

(*a*) Normal sacro-iliac and lumbo-sacral joints.

(*b*) Complaint of disease of the sacro-iliac and lumbo-sacral joints which is unassociated with objective signs and symptoms at the first examination and which, on reëxamination, after a reasonable period of time, is again found negative.

5. Registrants who on examination are found to present the following defect, if otherwise mentally and physically fit, may be accepted for *special and limited* military service:

(*a*) Disease of the sacro-iliac and lumbo-sacral joints of a degree which disqualifies for general military service, if otherwise mentally and physically fit and if the registrants have followed a useful vocation in civil life.

6. Registrants who on examination are found to suffer from the following defects shall be *unconditionally rejected* for all military service:

(*a*) Disease of the sacro-iliac and lumbo-sacral joints which is of a chronic type and is obviously associated with pain referred to the lower extremities, muscular spasm, postural deformities and limitation of motion in the lumbar region of the spine.

SCAPULÆ.

7. Registrants who on examination are found to present the following conditions, if otherwise mentally and physically fit, shall be *unconditionally accepted* for general and military service:

(*a*) Normal scapulæ.

(*b*) Prominent scapulæ due to other causes than paralysis.

8. Registrants who on examination are found to present the following defect shall be *unconditionally rejected* for all military service:

(*a*) Prominent scapulæ due to paralysis.

THE EXTREMITIES.

9. Registrants who on examination are found to present the following conditions shall be *unconditionally accepted* for general military service:

(*a*) Normal upper and lower extremities with normal function.

(*b*) Ancient or recent fractures which have healed spontaneously with no resulting impairment of function.

(*c*) Paralysis of a muscle or group of muscles that does not interfere with function.

(*d*) Benign tumors of bone, or defects due to their removal, when the condition does not interfere with the function of the extremity or the joint involved.

(*e*) Recent injury of a bone or joint with or without fracture or dislocation which in the opinion of the examiners is only temporarily incapacitating. (Registrants with these defects should be given a period of time, not less than six weeks, for recovery before the final examination is made.)

(*f*) Defects of bone or joint due to healed tuberculosis when the tuberculosis has not shown evidence of activity at any time during the period of ten years immediately preceding the examination.

(*g*) Absent left thumb.

(*h*) Loss of one finger of either hand, with the exception of the right index-finger.

(*i*) Scars and deformities of moderate degree of the hand or hands which do not interfere with normal function.

(*j*) Stiff fingers of a degree not to interfere with function.

(*k*) A low or even absent longitudinal arch, if the foot is otherwise practically normal in shape, flexibility and weight-bearing capacity.

(*l*) Slight hallux valgus which is unassociated with exostoses or bunion of any size.

(*m*) Club-foot of slight degree if the deformity has been corrected to the degree that the tarsus, metatarsus and phalanges are flexible and the condition permits the wearing of a military shoe.

(*n*) Slight claw-toes not involving obliteration of the transverse arch and which do not interfere with the wearing of a military shoe.

(*o*) Hammer-toe which is flexible and which does not interfere with the wearing of a military shoe. (Hammer-toe usually involves the second digit and unless it is rigid is not a disqualifying defect.)

(*p*) Absence of one or two of the small toes of one or both feet if the function of the foot is good.

(*q*) Ingrowing toe-nails.

10. Registrants who on examination present the following remediable defects, who are otherwise mentally and physically fit, may be *conditionally accepted* for general military service in the deferred remediable group:

(*a*) Ununited fractures, if in the judgment of the examiners they are remediable with resulting good function.

(*b*) Benign tumors of bone or joint which interfere with function and which in the judgment of the examiners are remediable.

(*c*) Other defects which, in the opinion of the examiners, are disqualifying but remediable.

11. Registrants who on examination are found to present the following defects, who are otherwise mentally and physically fit, may be accepted for *special and limited* military service unless the degree of disability is obviously disqualifying:

(*a*) Loss of thumb or index-finger of right hand.

(*b*) Loss of two fingers of either hand, including the right index-finger.

(*c*) Web-fingers.

(*d*) Ganglion and other benign tumors of the hand or fingers.

(*e*) Moderate deformities of one or both upper extremities which do not and have not interfered with function to a degree to prevent the registrant from following a useful vocation in civil life.

(*f*) Internal derangement of the knee-joint.

(*g*) Abduction and pronation (knock-ankle) when this condition is not associated with rigidity of the tarsal joints or with deformity of the foot. (This defect is remediable with proper foot exercise and with correct shoes.)

(*h*) Loss of great toe.

(*i*) Loss of dorsal flexion of great toe.

(*j*) Hammer-toe with rigidity.

(*k*) Web-toes.

(*l*) Other defects of the foot which disqualify for general military service but do not prevent the registrant from wearing a military shoe and which have not prevented him from following a useful vocation in civil life.

(*m*) Moderate deformities of one or both lower extremities which

do not and have not interfered with function to a degree to prevent the registrant from following a useful vocation in civil life.

(*n*) Adherent scars of the skin and soft tissues of an extremity.

(*o*) Paralysis of a muscle or group of muscles that interferes with function.

12. Registrants who on examination are found to present the following defects shall be *unconditionally rejected* for all military service:

(*a*) Loss of both thumbs.

(*b*) Loss of more than two entire fingers of one hand.

(*c*) Extensive disease of long duration of one or more of the large joints with or without sinuses.

(*d*) Tuberculosis of a bone or joint. (The diagnosis should be based upon the presence of swelling, tenderness, muscular spasm, restriction of joint motion, and the evidence of bone destruction shown by a roentgen-ray plate.)

(*e*) A history of tuberculosis of a bone or joint when the tuberculosis has been active at some time during the period of ten years prior to the examination.

(*f*) Old, irremediable, ununited fractures or united fractures with deformity sufficient to interfere with function.

(*g*) Malignant tumors.

(*h*) Extensive disease of long duration involving a number of joints of the upper and lower extremities.

(*i*) Old, unreduced dislocations which have interfered with the registrants following a useful vocation in civil life.

(*j*) Disease of the shoulder, elbow, or wrist with resulting limitation of motion.

(*k*) Disease of bone or joint healed with such resulting deformity that the function is disturbed to a degree that it will interfere with military service.

(*l*) Muscle paralysis or contraction which disturbs function to the degree of interference with military service.

(*m*) Excessive curvature of the bones of the leg or thigh.

(*n*) Excessive curvature of the bones of the forearm or arm which would interfere with military drill.

(*o*) Excessive knock-knee.

(*p*) Excessive bow-legs.

(*q*) Adherent scars of skin or soft tissue to a degree which seriously interferes with function.

(*r*) Excessive varicose veins.

(*s*) Varicose veins of any degree associated with edema or ulcer of the skin.

(*t*) Absent longitudinal arch of the foot associated with one or more of the following conditions:

Limitation of dorsal flexion.
Rigid metatarsal and subastragaloid joints.
Rigid toes.
Marked pronation.
Prominent scaphoid associated with other disabling foot conditions.

(*u*) Rigidity of the tarsus and metatarsus due to former infectious processes with or without flat-foot.

(*v*) Obliteration of the transverse arch associated with permanent flexion of the small toes (claw-toes).

(*w*) Prominence of the plantar surface of the transverse arch, especially when associated with large callosities.

(*x*) Hallux valgus if severe and associated with exostoses or a bunion of any considerable size, especially when there are signs of irritation about the joint.

(*aa*) Club-foot, if correction of the condition has not been sufficient to meet the standard requirements.

(*bb*) Disease of the bone or of the hip-, knee-, or ankle-joint which seriously interferes with function and weight-bearing power.

(*cc*) Deformities due to fracture or other injury which seriously interfere with function and weight-bearing power.

(*dd*) Sciatica which is apparently intractable and disabling to the degree of interference with the function of walking and weight-bearing power.

(*ee*) Amputations of extremities in excess of those already cited.

In the training camps the defective recruits and those who had broken down in service were divided into classes according to the character and degree of the disability. These classes were drilled by military officers under the supervision of the orthopaedic surgeons. As the students improved they were transferred from the lower to the higher classes and in about 80 per cent. of the cases were finally graduated as fit for full duty.

The most common disabilities were strains of the back and weak and disabled feet.

Of these, weak feet are by far the most important, since potential or slight disability, which is very common among the recruits, develops rapidly under the unusual strain of military routine. The weak foot and its treatment have been described at length in Chapter XX. It may be stated again, however, that the most important predisposing and exciting cause of the disability is an habitual lateral inclination of the foot; that the disabling symptoms are due to strain, to which the improper attitudes predispose, and that the prognosis as to future usefulness is determined by the secondary changes in accommodation to the deformity rather than by the severity of the immediate symptoms.

If in the erect posture the normal feet are placed side by side an interval remains between them due to the slight outward curve of their inner borders. In this attitude the line of strain, transmitted from the calf, passes through the center of the ankle to the middle of the forefoot. If the feet are potentially weak this interval is lost and the borders are in contact, or if the deformity is more extreme it is impossible to appose the heels and toes, because of the bulging inward where there should be a slight concavity.

The inward bulging is therefore the most positive sign of the weak foot. It is caused by the inward and downward displacement of the astragalus on the os calcis, and since the leg is supported on the astragalus it is rotated inward, carrying therefore the line of strain inward

over the arched or weak side instead of over the normal fulcrum of the forefoot. This relation of the foot to the limb, which is characteristic of the deformity, is best described as abduction, indicating the outward deviation of the foot from the axis of the leg, although eversion and pronation are alternative terms. The depression of the arch is a secondary effect of the progression of deformity. Thus in a well-formed foot the lateral distortion must be extreme before the arch is noticeably depressed, while the originally low-arched or flat-foot is stable without marked lateral distortion, and therefore is often entirely competent for weight bearing.

Weak feet may be divided from the stand-point of prognosis into three classes:

1. The well-formed foot, habitually abducted, in which the normal attitude may be voluntarily assumed.

2. The low-arched or actually flat-foot, with but slight lateral distortion.

3. The class in which the changes in structure in accommodation to the habitual attitude prevent the voluntary or passive restoration of the normal relations.

FIG. 848

FIG. 849

FIG. 848.—The army ankle strap for weak foot. A strap of leather or webbing applied about the arch and ankle proved fairly effective in relieving discomfort of strained arches. A similar strap (Fig. 849) is sometimes of service for metatarsal pain.

The treatment of the potential or actual weak foot is conducted with the purpose of enforcing proper postures and thus the avoidance of the attitudes that predispose to disability and of improving the muscular power and balance. The patient is instructed to voluntarily throw the weight on the outer rather than the inner borders, in straight forward walking, in tiptoe exercises and the like. The shoes are in all instances thickened one-quarter inch on the inner border of the heels and soles, and if actual strain is present adhesive plaster may be applied in a manner to prevent abduction, as illustrated on page 799, or the army ankle strap, Fig. 848, may be used.

When as in the recently acquired disability the deformity and resistance to reposition are due to muscular spasm, relief of pain quickly follows rest and strapping, and exercises may then be begun. It is very doubtful, however, if in cases of longer standing in which deformity is so resistant as to require forcible correction the recruits can ever be fitted for full duty, because in these and in fact all of the more persistent types, in which proper posture cannot be voluntarily retained, support is essential.

The same is true of the depression of the metatarsal arch, accompanied by contracted toes, and similar conditions of long standing in which operative treatment is required.

In the examination of industrial injuries, minor deformities and weaknesses of the feet are usually overlooked. Yet these often explain persistent disability after a fracture of the leg bones which has united satisfactorily.

SCHEDULE OF RATINGS FOR AMPUTATIONS, FRACTURES, AND THEIR SEQUELÆ.

Foreword.—In arriving at the following schedule of ratings of Amputation, Fractures, and their Sequelæ, the various opinions of leading orthopaedic surgeons in the United States, and the schedule of ratings of Belgium, France, Canada and England now in effect have been taken into consideration.

Ratings of Amputations, Fractures, and Their Sequelæ.—In general loss of muscle substance, cicatrices and atrophies, when having an effect upon functions from 10 to 25 per cent. should be added to the specific rating.

		Favorable angle, per cent.	Unfavorable angle, per cent.
Shoulder.			
Bony ankylosis	Major	36	45
	Minor	28	36
Limitation of motion from full flexion to 90° extension		Same as ankylosis	
Inability to raise arm above 90°		30	
Elbow.			
Complete bony ankylosis	Major	35	50
	Minor	30	45
Limitation of Flexion of the Forearm from:			
160°–110°	Major	25	
	Minor	20	
160°– 90°	Major	20	
	Minor	15	
180°– 70°	Major	5	
	Minor	5	
Loss of Extension of the Forearm from:			
60°–180°	Major	50	
	Minor	40	
75°–180°	Major	45	
	Minor	38	
90°–180°	Major	25	
	Minor	20	
105°–180°	Major	20	
	Minor	15	
120°–180°	Major	15	
	Minor	10	
135°–180°	Major	10	
	Minor	10	
150°–180°	Major	5	
	Minor	5	

(Extension from a position of complete flexion to the arc specified is unrestricted but wholly lost through the arc specified.)

MEDICAL LIBRARY
OF THE
BOSTON CITY HOSPITAL

		Favorable angle, per cent.	Unfavorable angle, per cent.
WRIST.			
Bony ankylosis	Major	23	35
	Minor	19	31
Limitation of Motion:			
Loss of more than 10° Dorsal extension, or *Palmar flexion*	Major	20	25
	Minor	15	20
Less than 10°	Major / Minor	10	10
Painful movement with loss of motion	Major / Minor	Full amount of bony ankylosis.	
FINGERS.			
Bony Ankylosis:			
First (thumb)		10	25
Second		5	8
Third		5	8
Fourth		3	3
Fifth		2	2
Limitation of Motion:			
First (thumb)		10	25
Second		10	25
Third		3	5
Fourth		2	2
Fifth		2	2
HIP.			
Bony ankylosis		36	45
Limitation of motion		From 5 per cent. to 25 per cent., depending upon degree.	
KNEE.			
Complete bony ankylosis		35	50
Limitation of Flexion of the Leg from:			
180° to 105°		5	
180° to 120°		10	
180° to 135°		15	
180° to 150°		20	
180° to 165°		30	
180° complete ankylosis		35	

(Flexion is unrestricted through the arc specified but wholly lost beyond the arc specified.)

Loss of Extension of the Leg from:		
90° / 105° / 120° / 135° to 180°		58
(The equivalent of an amputation of the thigh through the lower third.)		
150° to 180°		40
165° to 180°		20
170° to 180°		10
175° to 180°		5

(Extension from a position of complete flexion is unrestricted excepting through the arc specified.)

The axis of 180 degrees corresponds to the axis of the proximal long bone on which the distal long bone moves in the arc of a circle. Extreme flexion of the forearm is approximately at an angle of 45 degrees.

Extreme flexion of the leg is approximately at an angle of 75 degrees. Complete extension of either forearm or leg is at 180 degrees.

Where a partial disability results from an injury to both members, involving bilateral function, 20 per cent. of the total rating provided by the present schedule for the partial loss of bilateral function will be added to the sum of the ratings for impaired function in both members.

Peripheral Nerve Ratings.—In rating for peripheral nerve injury where there is an associated rating for surgical disability for the wound causing nerve injury the combined rating for functional loss shall not be greater than the surgical rating for amputation at the level of the injury.

Brachial Plexus:				
Upper radicular group fifth and sixth cervicals (Erb-Duchenne) syndrome	Major	Permanent	Partial	0.40 to 0.75
	Minor	"	"	0.30 to 0.70
Middle radicular group	Major	"	"	0.30 to 0.70
	Minor	"	"	0.20 to 0.60
Lower radicular group	Major	"	"	0.30 to 0.60
	Minor	"	"	0.20 to 0.60
Total radicular group	Major	"	"	0.90
	Minor	"	"	0.85
Nerves of Upper Extremity:				
Musculospiral	Major	"	"	0.75
Total paralysis	Minor	"	"	0.65
Paralysis of triceps	Major or Minor less than			0.10 to 0.10
Above supinator longus	Major	Permanent	Partial	0.40 to 0.75
	Minor	"	"	0.35 to 0.65
Below supinator longus	Major	"	"	0.30 to 0.50
	Minor	"	"	0.30 to 0.45
Below radial extensors	Major	"	"	0.30 to 0.50
	Minor	"	"	0.30 to 0.45
Dissociation of Exten. Com. Dig.	Major	"	"	0.20 to 0.30
	Minor	"	"	0.15 to 0.25
Paralysis below the Ext. Com. Dig.	Major	"	"	0.10 to 0.20
	Minor	"	"	0.10 to 0.15
Median Nerve:				
Above epitrochlear muscles	Major	"	"	0.20 to 0.40
	Minor	"	"	0.15 to 0.35
Below epitrochlear muscles	Major	"	"	0.15 to 0.25
	Minor	"	"	0.10 to 0.20
Ulnar Nerve:				
In arm of upper half of forearm	Major	"	"	0.20 to 0.40
	Minor	"	"	0.15 to 0.30
In forearm below flexor carpi ulnaris	Major	"	"	0.20 to 0.30
	Minor	"	"	0.15 to 0.25
Musculocutaneous:				
From axilla to belly of biceps	Major	"	"	0.15 to 0.25
	Minor	"	"	0.10 to 0.20
Below biceps	Below			0.10
Circumflex	Major	"	"	0.15 to 0.30
	Minor	"	"	0.10 to 0.25
Combined nerve injuries in same upper extremity. Ulnar and median catching fibers of median above epitrochlear muscles	Major	"	"	0.30 to 0.60
	Minor	"	"	0.30 to 0.55
Median above epitrochlear muscles and ulnar below flexor carpi ulnaris and flexor profundus digitorum muscles	Major	"	"	0.30 to 0.50
	Minor	"	"	0.25 to 0.45

Musculocutaneous:				
Musculospiral and median epitrochlear muscles and ulnar above upper half of forearm	Major	Permanent	Partial	0.50 to 0.80
	Minor	"	"	0.45 to 0.75
Median below epitrochlear muscles and ulnar in upper half of forearm	Major	"	"	0.35 to 0.50
	Minor	"	"	0.35 to 0.45
Median below epitrochlear muscles and ulnar below flexor carpi ulnaries and flexor profundus digitorum muscles	Major	"	"	0.30 to 0.50
	Minor	"	"	0.25 to 0.45
Musculospiral above supinator longus brachioradialis and median above epitrochlear muscles and ulnar	Major	"	"	0.50 to 0.80
	Minor	"	"	0.45 to 0.75
Nerves of Lower Extremity:				
Sciatic				
Upper half of thigh		"	"	0.40 to 0.60
Lower third		"	"	0.30 to 0.50
External popliteal		"	"	0.25 to 0.45
Anterior tibial		"	"	0.20 to 0.40
Musculocutaneous		"	"	0.20 to 0.30
Internal popliteal without flat-foot		"	"	0.15 to 0.30
" " with flat-foot		"	"	0.50
Posterior tibial (above soleus)		"	"	0.30 to 0.40
External saphenous		Less than		0.10 to 0.10
Posterior tibial (below soleus)		Permanent	Partial	0.25 to 0.35
Internal plantar		"	"	0.20
External plantar		"	"	0.20
Anterior crural		"	"	0.25 to 0.40
Internal saphenous		"	"	0.10 to 0.20
Obturator		"	"	0.10 to 0.20
External cutaneous nerve of the thigh		Less than		0.10 to 0.10
Ilioinguinal		Permanent	Partial	0.10

FRACTURES.

A relatively large number of fractures come under orthopaedic treatment (851 at the Hospital for Ruptured and Crippled in a year). Of 251 treated in the hospital wards a very large proportion were admitted for deformity and in at least two-thirds of these an open operation was required for its reduction. Thus, although fractures are of equal interest both to general and to orthopaedic surgeons the latter are more directly concerned with the disabilities resulting from ineffective treatment and with those fractures that involve joint function.

It is generally recognized that the treatment of fractures is unsatisfactory and a representative group of surgeons in 1922 prepared the following outline with the aim of simplifying and standardizing the routine of the more common forms of fracture:

Outline of Treatment of Fractures.

I. *First Aid.*—Every effort should be made to avoid any injury additional to that of the original trauma.

1. "Splint 'em where they lie!"
2. Avoid every unnecessary manipulation.
3. Transport with extreme care.
4. Treat any existing shock.

II. *Examination.*—As complete and thorough an examination as possible should be made without causing any additional injury.

1. Begin with painless procedures.

2. Search for crepitus and abnormal mobility only when these symptoms are absolutely essential. The manipulation required to elicit these cause additional injuries.

3. Rule out, if possible, other associated injuries, especially those of nerves.

4. Elicit objective symptoms, which will be painful, only under an anesthetic.

5. Roentgen-ray examination should be made as early as possible; roentgenograms should be taken in two planes, stereoscopic when necessary; should be of sufficient size and should be studied with detailed care.

III. *Diagnosis.*—The simple diagnosis that a fracture exists is not sufficient. All details of pathology of the soft parts, as well as of the bone, should be considered, so as to visualize properly the problem of obtaining and maintaining reduction as well as the problem of repair and its probable duration.

IV. *Treatment.*—Each fracture should be considered as an individual problem and the treatment directed not only to the injury of the bone but to that of the soft parts as well. The pathological changes following a fracture interfere markedly with the ease of reduction of displaced fragments. These changes begin very soon after the injury. Infiltration of the adjacent soft parts, coagulation and later organization of the blood, are the most important.

1. Obtaining Reduction.
   - (*a*) Reduction of any existing displacement should be made as soon after the injury as possible, without waiting too many hours for the roentgen-ray examination.
   - (*b*) Reduction should be as gentle as possible.
   - (*c*) Reduction should be as complete as the individual case requires.
   - (*d*) Reduction may be controlled by fluoroscopic examination in appropriate cases.
   - (*e*) Reduction should be checked by a roentgen-ray examination as soon as practical.
   - (*f*) Manipulation should be carried out under an anesthetic with but few exceptions.
   - (*g*) Further attempts at reduction should be made as soon as the need is recognized.
2. Maintaining Reduction.
   - (*a*) Decide in each case the peculiar problem presented and select apparatus accordingly, both for immediate and subsequent use.
   - (*b*) A decision should be reached as to how early such apparatus can be temporarily discarded to allow for massage and motion and how long it should be worn, in order to protect against further injury.

(*c*) Repair in cancellous is more rapid than in cortical bone.
(*d*) Rapidity of repair will depend very largely on the blood supply of the fragments.
(*e*) The atrophy of disuse must be borne in mind.
(*f*) The inherent value of any apparatus is of less importance than the skill with which it is used.

3. Plaster of Paris. Circular plaster bandages are permissible only when completely divided in at least one line.

4. Massage and Movements. If carefully and gently carried out, massage and movements can be of the greatest help. If roughly performed, they may do considerable harm. One must differentiate, under massage, between:

(*a*) Gentle stroking without deep pressure.
(*b*) Stroking with deep pressure.
(*c*) Kneading.

One differentiates between:

(*a*) Guided active motion.
(*b*) Unaided active motion.
(*c*) Passive motion.

With these differences in mind, the various forms of each may be begun as soon as there is no danger of any additional injury or any displacement of the fragments resulting. This gentle massage and movements may cause discomfort but should never cause actual pain. The pain of forced passive movements usually means harmful stretching or tearing of soft parts with additional necessary repair.

V. *Operative Treatment.*—Operative treatment is indicated when a satisfactory reduction cannot be obtained and maintained by non-operative methods, provided there is no contraindication, and when the expected result of the open method is sufficiently better than that of the closed to justify the additional risk.

Furthermore, it is generally recognized and accepted that, in certain types of fractures, it is impossible to obtain satisfactory restitution except by operative methods.

The operative method is recommended to those surgeons who have had special training and experience, who have the necessary skill and judgment, and who have the hospital facilities and surgical armamentarium with which to do this work properly. In the case of those who do not have such facilities, operation is not advised.

Internal splinting of long bones is usually best made by fixation, with steel plates and screws, having a minimum of foreign material but with maximum strength and ductility. The machine type screw only should be used. The wood, or so-called carpenter, screws are contraindicated in the cortex of bones. A scrupulous non-hand contact technic should be carried out, with strict attention to detail. The skin should be carefully covered during the operation, and there should be special care and preparation of the skin before operation. Intramedullary fixation by bone graft or splints is contraindicated if any other method is possible.

SCHEMATIC TABULATION OF TREATMENT OF FRACTURES.

Bone.	Part of bone.	Reduction.	Immobilization.	Position.	Secondary splinting (duration).	Convalescent brace (duration).	Physiotherapy (time to begin).	
							Massage.	Active motion.
Clavicle . .	Outer, mid, inner thirds	Manipulation with or without anesthesia	Clavicular cross, no sling necessary	Shoulders back, up and out	1. Same, 3 to 5 wks. 2. Recumbency in dorsal decubitus with posterior pad; 10 days to 3 weeks	None Clavicular cross, 2 wks.	None None	Immediate 3 wks.
Scapula . .	1. Body	No manipulation	Slight with or without adhesive	Arm to side	1. Same, 3 weeks	Sling, 1 to 2 wks.	1 wk.	2 to 4 wks.
	2 Neck	Manipulation with or without anesthesia	Sling and axillary pad	Arm to side	2. a. Same, 3 weeks b. or without swathe, 1 to 2 weeks c. Recumbency (for those displaced)	Sling, 1 wk.	1 to 3 wks.	4 wks.
Shoulder (humerus)	1. Anatomic neck 2. Surgical neck:							
	a. Impacted I. Without marked displacement (as for a)	a. No manipulation	Axillary pad (sweat pad only); circular bandage; cravat sling or as per d (omit for c)	a. Arm to side or abduction	a. Same, 2 to 3 days	a. Sling, 3 wks.	3 days	3 days
	II. With marked displacement (as for d)							
	b. Incomplete (children)	b. No manipulation		b. Arm to side	b. Same, 1 to 3 weeks	b. Sling, 2 to 3 wks.	Not necessary	1 to 3 wks.
	c. Epiphysis	c. Manipulation with anatomic reposition with anesthesia		c. Arm to side or abduction	c. Same, 3 to 4 weeks	c. Sling, 2 to 3 wks.	Not necessary	2 to 4 wks.
	d. Unimpacted	d. Manipulation with or without anesthesia	Abduction and traction by Thomas arm or aeroplane splints or as for a	d. Abduction or arm to side	d. Same, 4 to 6 weeks	d. Sling, 1 to 2 wks.	3 days	2 to 4 wks.
	e. Fracture dislocation	e. Careful manipulation with or without anesthesia	Traction in Thomas' arm splint	e. Abduction	Operation: plaster-of-Paris or aeroplane splint; 4 to 6 weeks	Sling, 2 to 4 wks.	2 to 5 wks.	2 to 5 wks.
	3. Greater tuberosity	No manipulation	Aeroplane splint or plaster spica	Abduction and external rotation	1. Same, 3 to 5 weeks 2. Operation if necessary	Sling, 1 to 2 wks.	1 to 5 wks.	3 to 5 wks.
Humerus	4. Shaft: a. Upper and mid thirds (above insertion of deltoid)	Manipulation with or without anesthesia	1. Hinged Thomas arm splint 2. Jones' humerus splint with or without coaptation splints, avoiding axillary pressure	Arm to side	Same, 4 to 8 weeks	Coaptation splints and sling, 2 to 4 wks.	1 to 3 wks.	4 to 8 wks. (shoulder)

	b. Lower third	Manipulation with or without anesthesia	1. Jones' humerus splint 2. Axillary pad, sling to wrist and circular with internal (anterior) angular or molded plaster splints	Suspension or arm to side	Same, 4 to 8 weeks	Coaptation splints and sling, 2 to 4 wks.	1 to 3 wks.	3 to 6 wks. (elbow)
	5. Supracondylar or lower humeral epiphysis a. Lower fragment posterior b. Lower fragment anterior	Manipulation with or without anesthesia to anatomic reposition (traction with elbow in hyperextension)	1. Adhesive strapping 2. Aluminum internal (anterior) angular splint 3. Molded plaster external or internal angular splint 4. Bandage and sling	a. Acute flexion	Same, 10 to 14 days	Sling, 1 to 2 wks.	3 days to 2 wks.	1 to 3 wks.
				b. Right angle flexion	Same, 10 to 14 days	Sling, 1 to 2 wks.	3 days to 2 wks.	1 to 3 wks.
	6. Epicondyle	Same as 5, a	Same as 5, a	Same as 5, a	1. Same as 5, a or 2. Operation if necessary	Same as 5, a	Same as 5, a	Same as 5, a.
	7. Internal condyle	Same as 5, a	Same as 5, a	Same as 5, a		Same as 5, a	Same as 5, a	Same as 5, a.
	8. External condyle	Same as 5, a	Same as 5, a	Same as 5, a		Same as 5, a	Same as 5, a	Same as 5, a
	9. T-fracture into joint	Manipulation with or without anesthesia	1. Traction by Thomas' arm splint or Jones humerus splint, or suspension with immediate active motion (rt. angle elbow)	1. Extension or right angle	1. Same, 4 to 6 weeks	Sling, 2 to 3 wks.	1 to 3 wks.	2 to 4 wks.
				2. Right angle flexion	2. Open reduction plaster, 3 weeks	Sling, 2 to 3 wks.	3 wks.	2 to 4 wks.
	10. Capitellum	Manipulation with or without anesthesia	1. Same as 5, a	Acute flexion	1. Same as 5, a, 3 to 5 weeks	Sling, 1 to 3 wks.	1 to 3 wks.	3 to 5 wks.
				Acute flexion	2. Open reduction if necessary; same as 5, a, 2 to 4 weeks	Sling, 1 to 3 wks.	1 to 3 wks.	3 to 5 wks.
Ulna	1. Olecranon	No manipulation	1. Extension with molded plaster splint from axilla to palm	1. Extension to 160 degrees	1. Same, 2 to 4 weeks	Sling, 2 wks. (gradually increasing flexion)	1 to 2 wks.	1 to 3 wks.
			2. Thomas arm splint	2. Extension or partial flexion	2. Open reduction where marked separation			
	2. Coronoid	Manipulation with or with anesthesia	Same as humerus, 5, a	Complete flexion generally	Same, 2 to 4 weeks	Sling, 2 wks.	1 wk.	2 wks.
Radius	1 Head: a. Not displaced	No manipulation	a. Right angle splinting	1. a. Right angle in 2. a. full supination	1.a. Same, 2 to 3 weeks	1.a. Sling, 2 wks.	1 wk.	Flexion, 1 wk.; pronation, supination, 2 wks
	b. Displaced	Manipulation with or without anesthesia	b. Same as humerus, 5, a	.....	1.b. Excision of fragment or head; same, 2 to 3 weeks	1.b. Sling, 2 wks.	1 wk.	Flexion, pronation, supination, 1 wk.
	2. Neck: a. Not displaced	No manipulation	a. Right angle splinting	1.b. Acute flexion 2.b.	2.a. Same, 2 to 4 weeks	2.a. Sling, 2 wks.	1 wk.	Flexion, pronation, supination, 2 to 3 wks.
	b. Displaced	Manipulation with or without anesthesia	b. Same as humerus, 5, a	....	2.b. Same as 1, b, 5 to 7 weeks	2. b. Sling, 2 wks.	1 wk	Flexion, pronation, supination, 2 to 3 wks.

SCHEMATIC TABULATION OF TREATMENT OF FRACTURES.—(*Continued.*)

Bone.	Part of bone.	Reduction.	Immobilization.	Position.	Secondary splinting (duration).	Convalescent brace (duration).	Physiotherapy (time to begin).	
							Massage.	Active motion.
Forearm. .	1. Both bones	Manipulation with or without anesthesia	1. a. Anterior and posterior wooden splints and anterior right angular splint or molded posterior plaster splint b. Molded anterior and posterior plaster splints to include palm c. Plaster axilla to palm d. Traction and suspension	1. Forearm supinated; elbow flexed at right angle	Same, 5 to 7 weeks; children, 3 to 5 weeks	Sling, 2 to 3 wks. Sling, 3 to 6 wks.	1 to 4 wks.	4 to 6 wks.
	2. Radius (alone)	Manipulation with or without anesthesia	2. Same as 1, a, b or c	2. Upper third (above insertion of pronator teres); supination with elbow at right angle; below insertion of pronator teres, pronation with elbow at right angle	Same, 4 to 6 weeks	Sling, 2 to 3 wks.	1 to 3 wks.	2 to 4 wks.
	3. Ulna (alone)	Manipulation with or without anesthesia	3. Same as 1, a, b or c	3. Midpronation	Same, 3 to 4 weeks	Sling, 2 to 3 wks.	1 to 3 wks.	2 to 4 wks.
	4. Greenstick	Manipulation with or without anesthesia	4. Same as 1, a, b or c	4. Supination with elbow at right angle	Same, 3 to 5 weeks	Sling, 2 to 4 wks.	Not necessary	2 to 4 wks.
					or 1, 2 and 3 a. Traction, 3 to 6 wks 1. Jones' humerus splint 2. Overhead suspension, 4 to 6 weeks b. Open reduction	Sling or plaster, 2 to 3 wks.	3 to 6 wks.	3 to 6 wks
Radius . .	1. Lower extremity, with Colles' displacement, epiphyseal separation	Under anesthesia; after mobilization reduce existing deformities, including torsion and ulnar luxation	a. Anterior and posterior wooden splints with cut-out for ulnar styloid, with fingers free b. Plaster	1. a. Hand adducted and pronated with palmar flexion b. In bad displacements, extreme of foregoing position	1. Same, 2 to 3 weeks	a. Wrist strap, 1 to 5 wks. b. Wrist strap, 2 to 6 wks.	2 days to 3 wks.	1 to 3 wks.
	2. Same without displacement	No manipulation	a. Wooden splint b. Plaster	2. Same as 1	2. Same, 2 to 3 weeks	Wrist strap, 2 to 6 wks.	2 to 7 days	2 to 7 days
	3. Same with displacement, not Colles'	Same as for 1	Same as for 1	3. Hand adducted and slight dorsal flexion	3. Same, 2 to 3 weeks	Wrist strap, 2 to 6 wks.	2 days to 3 wks.	1 to 3 wks.
Carpus . .	Scaphoid, semilunar, all others:							
	a. Not displaced	No manipulation	Molded plaster anterior cock-up splint from elbow to finger tips	Dorsal flexion of hand in position of grasp	Same, 4 to 6 weeks	Wrist strap, 2 to 6 wks.	1 to 3 wks.	4 to 6 wks.
	b. Displaced	Manipulation with anesthesia			or Reduction of displaced fragment by open reduction with cock-up	Wrist strap, 2 to 6 wks	1 to 3 wks.	4 to 6 wks.

Metacarpus	Bennett's	Manipulation with anesthesia	Traction in small banjo splint	Hyperextension	Same, 3 weeks	None	1 to 3 wks.	3 wks.
	Metacarpals:							
	a. Not displaced	No manipulation	Convex palmar splint	a. Position of grasp	Same, 2 to 4 weeks	None	2 days	1 to 2 wks.
	b. Displaced	Manipulation with anesthesia if necessary	Traction in small banjo splint with cock-up to palm	b. Extension	Same, 3 to 5 weeks	None	1 wk.	2 to 3 wks
Phalanges	a. Not displaced	No manipulation	Palmar splint for injured and adjacent fingers or traction	a. Partial flexion	Same, 2 weeks	None	Immediate to 1 wk.	1 wk.
	b. Displaced	Manipulation with anesthesia	Traction in small banjo splint	b. Partial flexion	Same, 2 weeks	Palmar splint, 1 wk.	1 wk.	2 wks.
Ribs . .	....	No manipulation	Adhesive strapping (two-thirds circumference) with arms dependent	Full expiration	10 days to 2 weeks	None	None	None
Pelvis . .	1. Any bone or combination	Reduction if possible with or without anesthesia	Swathe; if necessary with suspension in Balkan frame or Sinclair net bed	Supine	Same, 4 to 12 weeks	Belt	None	5 to 8 wks.
	2. Iliac crest	No manipulation	Tight swathe not advised	Supine	Same, 4 to 12 weeks	None	None	5 to 8 wks.
	3. Acetabulum with penetration of head of femur	Manipulation with anesthesia	a. Traction (Maxwell-Ruth) b. Plaster spica (in abduction)	a. b. Abduction	Same, 6 to 12 weeks	Caliper	1 wk.	6 to 12 wks.
Femur . .	1. Neck: a. Impacted, not displaced b. Unimpacted, displaced	Manipulation with or without anesthesia	Thomas splint with skin traction from knee to ankle as emergency	Full abduction, extension, internal rotation (Whitman position)	Plaster spica extending to toes with short spica to opposite thigh, or carried to opposite axilla; 12 to 15 weeks	Caliper and crutches, 6 to 9 months; no weight bearing for 6 to 9 mos.	12 to 15 wks.	12 to 15 wks.
	2. Intertrochanteric and base of neck	Manipulation with or without anesthesia	Thomas splint with skin traction from knee to ankle as emergency	Usually slight abduction	Abduction plaster spica or traction in Thomas splint, 8 wks., or Maxwell-Ruth method	Caliper and crutches, 4 to 6 mos.; patient to be up as soon as union is firm	Immediate	Hip, 8 wks.; knee, 4 to 6 wks.
	3. Shaft: a. Adult	Manipulation with or without anesthesia	Thomas splint with skin traction from knee to ankle as emergency	Hip flexion: knee flexion and abduction often necessary in fractures from trochanters to mid-thigh; maintain normal anterior convexity of femur	Traction in Thomas splint followed by 1. Skin traction (carried well above line of fracture), total traction, 5 to 9 weeks, or 2. Skeletal traction from condyles of femur (under proper conditions)	Caliper and crutches, 3 to 6 mos.	Immediate	Knee, 2 to 4 wks.
	b. Children (not more than 6 yrs.)	Manipulation with or without anesthesia	Thomas splint with skin traction from knee to ankle as emergency	1. Hip flexion; knee extension 2. Slight flexion of hip and knee	1. Overhead traction (on Bradford frame preferred), 6 weeks 2. Plaster spica (if reduction is satisfactory)	Plaster spica or long molded plaster side splint from axilla to below knee 4 to 6 wks.	Not necessary	8 to 12 wks.

MEDICAL LIBRARY
THE
BOSTON CITY HOSPITAL

SCHEMATIC TABULATION OF TREATMENT OF FRACTURES.— (*Continued.*)

Bone.	Part of bone.	Reduction.	Immobilization.	Position.	Secondary splinting (duration).	Convalescent brace (duration).	Physiotherapy (time to begin).	
							Massage.	Active motion.
Femur . .	4. Supracondylar	No manipulation; anesthesia if necessary for pain	Thomas splint with skin traction from knee to ankle as emergency	Hip flexion; knee flexion sufficient to maintain position	1. Skeletal traction from condyles of femur in Thomas splint (under proper conditions), followed by skin traction if necessary; total traction, 5 to 9 weeks 2. Plaster spica (if reduction is satisfactory) 3. Operation if necessary	Caliper and crutches, 3 to 6 mos.	Immediate, if possible	Knee, 2 to 4 wks.
	5. T-fracture into knee-joint	No manipulation	Thomas splint with skin traction from knee to ankle as emergency	Hip flexion; slight knee flexion	1. Skeletal traction from head of tibia (under proper conditions) in Thomas splint, 5 to 9 weeks 2. Plaster spica (if reduction is satisfactory)	Caliper and crutches, 3 to 6 mos.	Immediate, if possible	Early
	6. Separation of lower epiphysis	Manipulation with anesthesia (immediate)	Plaster toes to groin	Acute knee flexion	Same, 3 to 4 weeks	Plaster cylinder with gradual extension of knee	2 wks.	3 to 4 wks.
Patella . .	a. With separation	No manipulation	Cabot posterior or similar splint (prepare for operation)	Extension	Operation after 3 to 8 days 1. Cabot posterior or similar splint 2. Molded plaster, malleoli to buttock, 1 to 3 weeks	Molded plaster posterior or caliper, 4 to 10 wks.	Immediate, if possible	As soon as skin wound is healed.
	b. Without separation	No manipulation	Cabot posterior or similar splint (operation not necessary)	Same	Same, 1 to 3 weeks	Same	Same	1 to 2 wks.
Tibia	Tuberosities: a. With separation	Manipulation, if necessary, with or without anesthesia	Cabot posterior or similar splint	Extension	1. Manipulation with lateral clamp if necessary; plaster toes to groin, 4 to 6 weeks 2. Skin traction in Thomas splint, 4 to 6 weeks	Caliper, 4 to 12 wks.	Immediate, if possible	Immediate, if possible.

	b. Without separation	No manipulation	Plaster toes to groin	Extension	Same, 4 to 6 weeks	Caliper, 5 to 12 wks.	2 to 7 wks.	4 to 6 wks.
	Shaft with or without fibula	a. Manipulation with or without anesthesia b. Delbet method without anesthesia (excellent)	1. Molded plaster splint, or 2. Plaster toes to groin (with or without posterior wooden splint)	Slight knee flexion; foot at right angles; avoid rotation	Same, 6 to 8 weeks or skeletal traction in Thomas (especially in oblique fracture of lower third), 4 to 6 weeks; operation if necessary	Caliper or Delbet, 4 to 8 wks.; plaster, caliper, Delbet 4 to 10 wks.	1 to 3 wks. Immediate, if possible	4 to 6 wks Immediate.
Fibula	Shaft	Manipulation, if necessary, with or without anesthesia	1. Molded plaster splint, toes to knee or groin, depending on level of fracture 2. Cabot or similar splint	Slight knee flexion	Same, 3 to 4 weeks; in fractures near head, special attention must be paid to external popliteal (peroneal) nerve	Not necessary	3 to 4 wks.	2 to 4 wks.
Ankle . .	1. Inversion (adduction)	Manipulation with anesthesia if necessary	Plaster toes to knee	1. Eversion (abduction), moderate	Same, 4 to 6 weeks	Short caliper if necessary	1 day to 1 wk.	2 to 3 wks.
	2. Eversion (abduction), Pott's, and outward rotation			2. a and b. Dorsiflexion and inversion (adduction) of foot with reduction of displacements, especially posterior displacement	Same, 4 to 6 weeks	a. Short caliper; foot plate if necessary; Thomas heel (forward ¾ to 1 in., inner border raised ¼ in.)	1 day to 1 wk.	2 to 6 wks.
	a. Without displacement	a. No manipulation	Plaster toes to knee					
	b. With displacement	b. Manipulation, if necessary, with or without anesthesia	Plaster toes to above knee			b. Same	1 day to 1 wk.	2 to 6 wks.
Os calcis .	....	Manipulation with anesthesia when necessary	Pillow and side splints temporarily	Slight plantar flexion and inversion (adduction), or plantar and knee flexion	Plaster boot to knee or groin; operative manipulation necessary for those with displacement, 4 to 6 weeks*	Foot plate or Thomas heel	2 to 3 wks.	4 to 6 wks.
Tarsus . .	....	Manipulation with anesthesia if necessary	Pillow and side splints temporarily	Right angle flexion and inversion (adduction)	Plaster boot with molding, 4 to 6 weeks; operation if necessary	Foot plate or Thomas heel	3 to 4 wks.	4 to 6 wks.
Metatarsus .	a. Not displaced	No manipulation	Molded plaster to tibial tubercle	Right angle flexion and inversion (adduction)	Same, 4 to 6 weeks	Foot plate or Thomas heel	3 to 4 wks.	4 to 6 wks.
	b. Displaced	No manipulation	Pillow and side splints	Right angle flexion and inversion (adduction)	Traction in banjo splint, 4 to 6 weeks, or operation			

*The conference considers this fracture very serious, requiring skilful treatment; by operation, if necessary.

Bone grafting is indicated chiefly for loss of substance and pseudarthrosis. It is not indicated in the treatment of acute fractures. Every attempt to stimulate osteogenesis should be exerted before attempting to bone-graft for delayed union.

VI. *Compound Fractures.*—In all compound fractures, patients are to receive tetanus antitoxin.

Compound fractures in which it is perfectly evident that the wound of the soft parts is made by the protrusion of bone from within outward through the skin, and in which the wound is tiny, should have a thorough preparation of the skin by washing with benzine, shaving (away from the wound), drying with ether and the application of tincture of iodine to the skin and the wound itself, with sterile dressing. Immediate reduction should be undertaken when indicated.

When a roentgen-ray examination is to be made before reduction, all the steps enumerated above, except reduction, are to be completed before the patient is sent to the roentgen-ray department.

In extensive compound fractures with a large wound:

1. Apply tourniquet only when it is obvious that some large vessel has been lacerated.

2. With a sterile sponge, carefully protect the wound from contamination while the skin is being cleansed, following the foregoing routine; in addition, chlorinated soda solution 1:40 may be found of value in removing grease. If this procedure can be undertaken without too much pain and shock to the patient, it should be carried out before he is sent to the roentgen-ray department; if not, apply tincture of iodine only to the edges of the wound and put on a large sterile dressing before roentgen-ray examination, and complete the procedure when the patient is under anesthesia.

3. At operation, débridement:
   - (*a*) Thorough exposure of wound by generous incisions.
   - (*b*) Excision en bloc of traumatized and infected tissues.
   - (*c*) Excision of skin at least 0.5 cm. from the wound edges.
   - (*d*) Dead and dying fat, fascia and muscle cut away with sharp instruments until fresh bleeding occurs.
   - (*e*) Small bone fragments unattached to periosteum removed; soiled bone surfaces rongeured.
   - (*f*) Hematoma dissecting between muscle planes should be carefully evacuated.
   - (*g*) Frequent changes of gloves and instruments to ensure against carrying infection into deep portions of wound.
   - (*h*) Irrigation of the wound with salt solution to wash out particles of dirt if necessary.

4. Final dressing of the wound according to indication:
   - (*a*) Complete closure after lavage with ether or iodine.
   - (*b*) Application of Carrel tubes for immediate use of surgical solution of chlorinated soda (Dakin's solution).

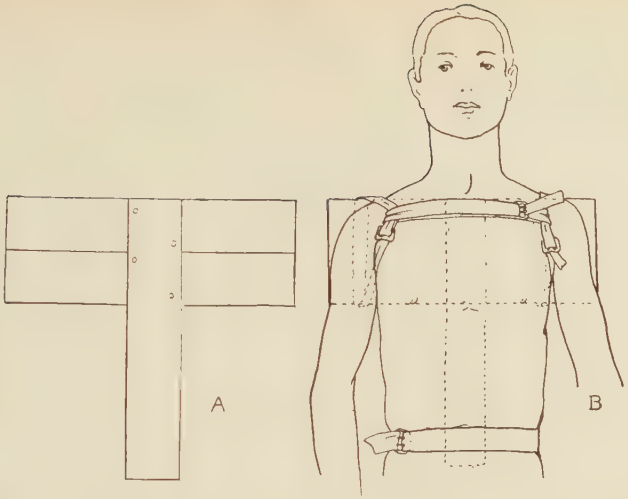

Fig. 850.—*A*, clavicular cross (made of splint board), the two pieces, the width of the shoulder, being tacked to a vertical piece reaching from the shoulder to the sacrum; *B*, method of application of clavicular cross (for purposes of simplification the padding is not shown). The surface of the splint in contact with the skin should be abundantly padded with cotton and covered with bandage. The affected shoulder is lifted up, back and out and secured to the cross arms of the splint by straps or a figure-of-eight bandage. The lower part of the vertical pieces is pushed in close to the sacrum and held by adhesive or buckle straps.

Fig. 851

Fig. 852

Fig. 851.—Thomas' traction arm splint (Murray pattern): The ring is padded with felt and covered with leather and is hinged at its points of junction with the frame.

Fig. 852.—Method of application of the Thomas traction arm splint (Murray pattern) in fracture of the upper end of the humerus: Adhesive traction strips are applied to the upper arm, traction being obtained by weight and pulley. The arm is supported on flannel or canvas strips pinned to the side bars of the splint. The elbow may be flexed, as shown, and suspended by means of additional traction strips to an overhead frame; or it may be placed in the extended position, in which case only one pair of traction strips, extending from the wrist nearly to the axilla, is used.

FIG. 853

FIG. 854

FIG. 853.—Axillary sweat pad and wrist sling, showing the narrow width of the sling.

FIG. 854.—Plaster-of-Paris jacket, with shoulder spica and forearm casing holding the arm in the abducted position.

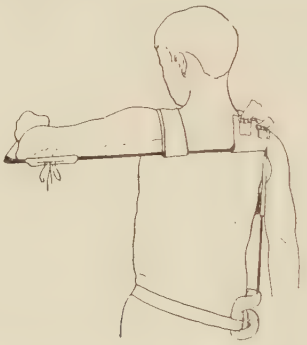

FIG. 855.—Anterior and posterior views of aëroplane splint (Cleary type), the lower support of which rests against the iliac crest.

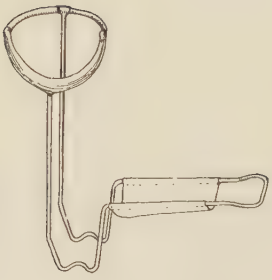

FIG. 856

FIG. 857

FIG. 856.—Jones' humerus traction splint.

FIG. 857.—Method of application of Jones' humerus traction splint: Traction may be obtained as indicated by means of a strap passing over the upper end of the forearm, in which case a thick felt pad should be interposed between it and the skin. In other cases, traction is obtained by adhesive strips applied to the mesial and lateral skin surface of the upper arm.

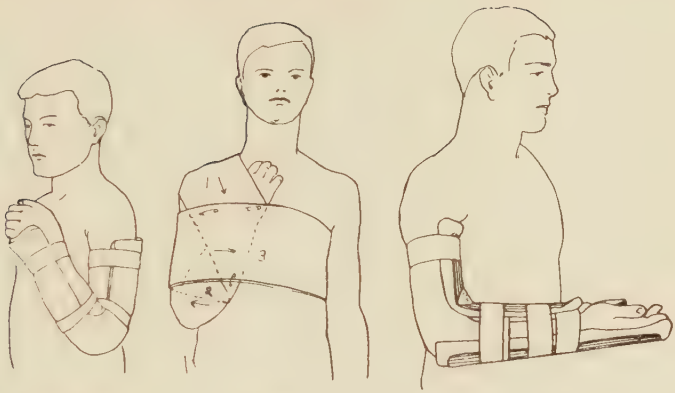

FIG. 858 FIG. 859 FIG. 860

FIG. 858.—Molded plaster posterior splint, holding the elbow in the position of acute flexion.

FIG. 859.—Lund swathe: A long muslin strip is folded to a width of 4 inches (10 cm.). One end is placed on the dorsal spine and unrolled over the affected shoulder, vertically downward across the forearm, under the elbow and then back across the elbow, and around the chest as a bandage. The free ends are fixed to adjacent folds with safety pins.

FIG. 860.—Anterior and posterior wooden splints with anterior angular aluminum splint, as used in fracture of the bones of the forearm.

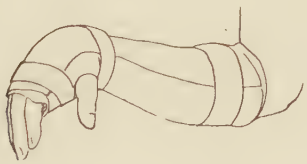

FIG. 861.—Colles' fracture plaster splint, illustrating the extreme position of pronation, adduction, and wrist flexion in which it may be necessary to place the hand after reduction of certain cases of Colles' fracture.

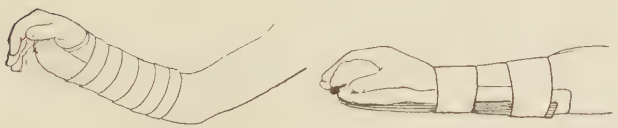

FIG. 862 FIG. 863

FIG. 862.—Plaster cock-up splint employed in certain cases of injury about the wrist.

FIG. 863.—Long plaster cock-up splint holding the hand in the position of grasp, as required in fracture of the carpal scaphoid.

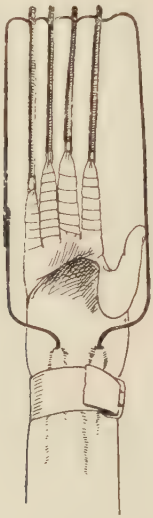

FIG. 864.—Banjo splint (indicated in fractures of the metacarpals with displacement and in certain fractures of the phalanges): The splint is made of a molded plaster strip applied to the forearm, in which is incorporated a wire frame appropriately bent to meet the indication. The traction is obtained by adhesive strips fastened to the fingers and elastic tubing connecting these with the wire frame. One or all the fingers may be included, as necessary.

FIG. 865.—Bradford frame: Canvas strips are laced across the frame, which is made of ordinary gas pipe, in such a way as to leave an appropriate interval for the buttocks, under which the bedpan may be passed.

FIG. 866.—Long plaster spica extending from the toes to the axilla, used in fractures of the neck of the femur to hold the hip in the position of abduction, extension and internal rotation. The abduction treatment is described in detail page 978.

BOSTON CITY

FIG. 867.—Thomas' traction leg splint.

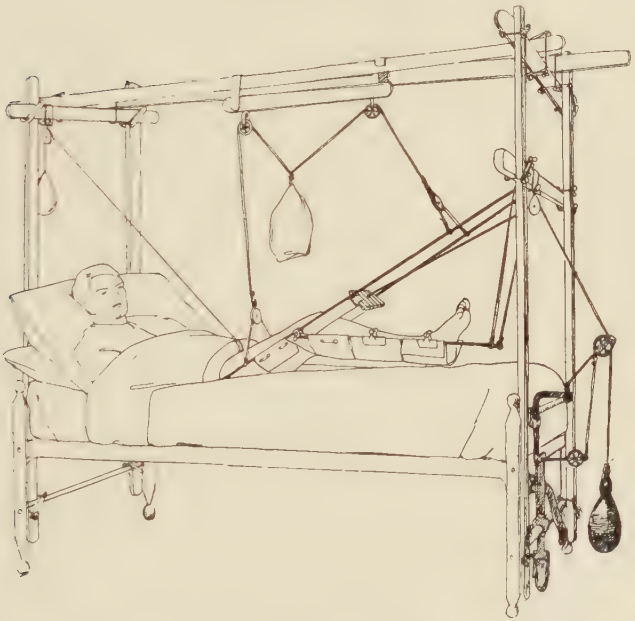

FIG. 868.—Balkan frame, illustrating the method of applying and suspending the Thomas traction leg splint with the hinged knee attachment.

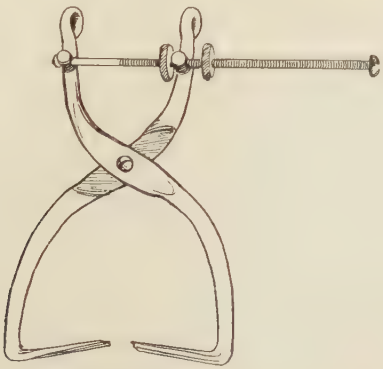

FIG. 869.—Calipers (Adams type) for direct skeletal traction on the femoral condyles.

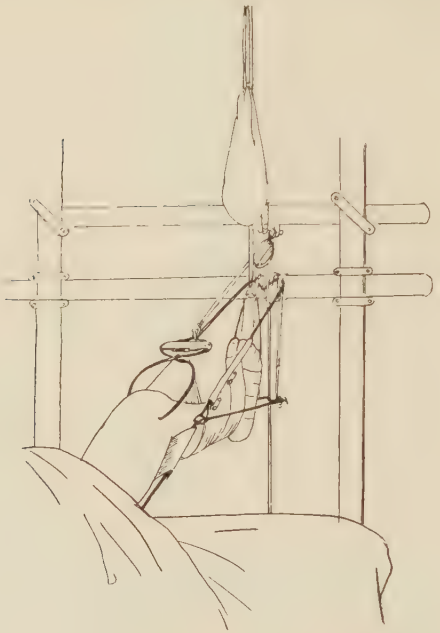

FIG. 870.—Skeletal traction in fractures of the femur: The points are introduced on a horizontal plane ½ inch (1.3 cm.) above and in front of the adductor tubercle.

FIG. 871.—Thomas' caliper splint: The lower ends of the splint fit into the heel of the shoe and part of the body weight is transmitted to the ground by the direct thrust of the rings against the tuberosity of the ischium. The opposite shoe should be slightly elevated.

FIG. 872.—Rainbow frame. The overhead traction as used in fractures of the femur in young children is illustrated. The child is lying on a Bradford frame.

FIG. 873.—Cabot posterior wire splint.

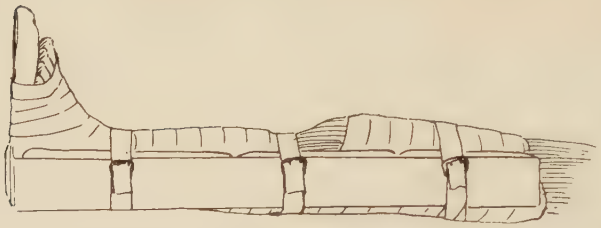

FIG. 874.—Cabot posterior wire splint applied with side splints in injuries about the knee.

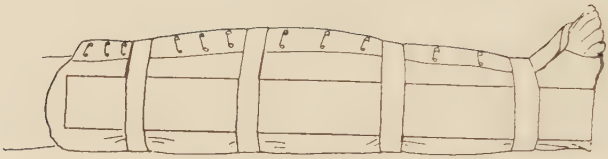

FIG. 875.—Pillow splint with lateral and posterior wooden splints, used as an emergency dressing in fractures of the leg.

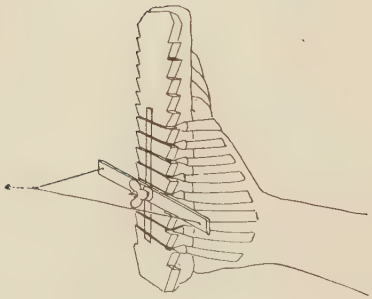

FIG. 876.—Method of application of Sinclair skate to obtain traction in certain fractures of the lower leg.

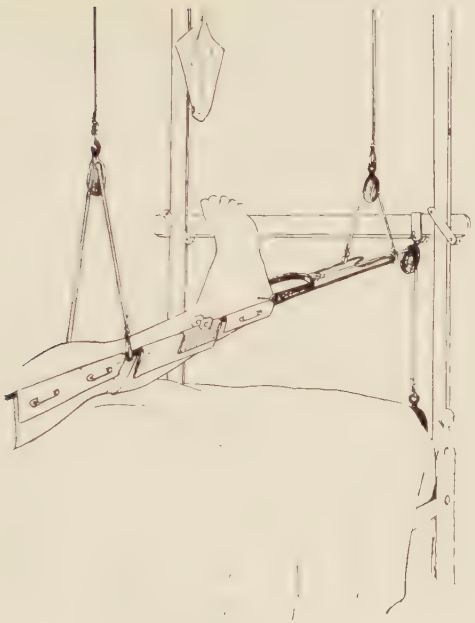

FIG. 877.—Skeletal traction on the os calcis: A Steinmann or similar steel pin is passed through the heel either over the top or through the center of the os calcis. To this pin, by means of an appropriate clamp, traction by means of weight and pulley is attached (used in connection with the Thomas traction leg splint).

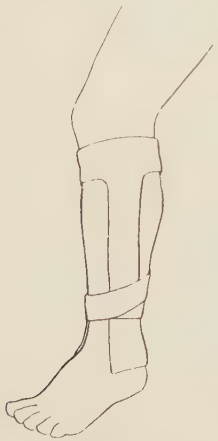

FIG. 878.—Delbet plaster splint: Plaster strips are molded snugly without padding to the leg, one encircling the upper end of the tibia, two vertical strips on the mesial and lateral aspects of the leg, and one spiral strip holding them in position. Weight is transmitted from the upper end of the tibia to the plaster strips and by them carried to the malleoli. It is used as a convalescent brace.

Russel's simple appliance carries out the principles of the Hodgen method without a splint. The adhesive traction straps extend only to the knee, which is flexed by the action of the sling.

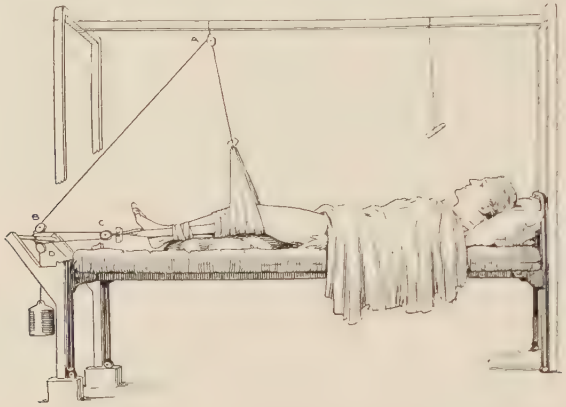

FIG. 879.—Russel's sling, as used in the treatment of fracture of the shaft of the femur.

THE ABDUCTION TREATMENT OF FRACTURE OF THE NECK OF THE FEMUR[1]

Fracture of the neck of the femur deserves special consideration since its effective treatment is an orthopaedic contribution to surgical progress.

FIG. 880.—The characteristic attitude after fracture of the neck of the femur. The patient is eighty-five years of age. The succeeding photographs (Figs. 886 and 887) illustrate the application of the abduction treatment to this patient.

This fracture is exceptional in several particulars. In a large proportion of the cases the physical condition of the patients is unfavor-

[1] This treatment as applied to the fracture in childhood and adolescence is described elsewhere (p. 628).

able and in certain forms of fracture, notably the subcapital type, the capacity for repair is somewhat doubtful.

The primary cause, however, of the extraordinarily bad results that have always distinguished this fracture from all others is mechanical. The neck of the femur projects from the shaft, consequently conventional methods of traction and splinting can at best appose the fragments only in a lateral and, therefore, insecure relation which does

ORIGINAL DIAGRAMS (1902) ILLUSTRATING THE MECHANISM OF THE ABDUCTION TREATMENT.

FIG. 881.—The range of normal abduction limited by contact of bone and by tension on the capsule.

FIG. 882.—Fracture and displacement illustrating muscular action as an agent of deformity.

FIG. 883.—Reduction by the abduction method illustrating bony contact and muscular velaxation.

not assure the essentials of repair. Conventional practice is based on inadequate mechanics, although ostensibly it is an adaptation to the quality of the patient and to the character of the injury. Thus, according to a leading treatise on fractures, "The ideal object of treatment, restoration of form and function, is rarely to be attempted or even sought." "The first indication is to save life" (by neglecting the local injury)—"the second to get union" (by protecting deformity

that might seem to assure apposition) —"the third to reduce or diminish displacements"—Thus, what is the first indication in the treatment of any other fracture is in this instance the last. Naturally treatment conducted on such indications has been what has been aptly termed a surgical ritual, futile and perfunctory from beginning to end.

The abduction treatment is based on the proposition that because of the mechanical and nutritive obstacles to repair end-to-end apposition of the fragments and secure fixation are essential to success. In only one attitude can this essential be assured—namely, in full abduction—because each fragment then lies in a horizontal plane, and since the head fragment is contained in the acetabulum tension on the capsule as the limb is abducted must align the fragments and assure direct and resistant pressure. Furthermore, in full abduction

FIG. 884.—The first step in the abduction treatment. The shortening is reduced by direct manual traction and verified by measurement, the limb having been rotated slightly inward as indicated by the position of the patella. (Annals of Surgery.)

the trochanter is brought into contact with the side of the pelvis, and the muscles, under other conditions active agents of deformity, are in this position relaxed and impotent (Figs. 881-883).

The practical application of the treatment for complete fracture is as follows:

The patient, having been anesthetized, is placed on a pelvic support with a perineal bar, the shoulders resting on a box of equal height. Two assistants make manual traction on the extended limbs, drawing the perineum firmly against the bar and completely reducing the shortening on the injured side, as verified by measurement, the surgeon meanwhile lifting the thigh upward if it is below the place of its fellow and by pressure on the trochanter guiding it to its proper position. The limb is then rotated slightly inward, as indicated by the position

MEDICAL LIBRARY
THE
BOSTON CITY HOSPITAL

of the patella thus completely apposing the fragments. Both limbs, extended and under manual traction, are then abducted to the full limit, on the sound side first, to demonstrate the normal range which varies in different individuals and to balance the pelvis. When this limit is approached on the injured side tension on the capsule assures the alignment of the fragments and forces a resistant contact. Inspection should then show an absolutely level pelvis and an exact correspondence of the anatomical landmarks on the two sides. A long plaster spica extending from the axilla to the toes is then applied, which by fixing the limb in complete abduction, full extension and slight inward rotation, assures the security of the internal splinting. The knee is slightly flexed and the foot supported at a right angle with the

FIG. 885.—The second step. The limbs are, under manual traction, abducted to the normal limit as indicated by the range on the sound side, upon a level pelvis, the surgeon verifying the exact correspondence of the two sides. (Annals of Surgery.)

leg is slightly adducted. Krenz,[1] from experiments on 23 bodies, concludes that the fragments are most securely apposed by 45 degrees of abduction, slight inward rotation and extension. This confirms Taylor's conclusions from similar investigations made in 1905.

The treatment of the incomplete fracture is practically the same. The characteristic deformity of what is called an impacted fracture is a downward and backward displacement of the neck in relation to the shaft (coxa vara). This deformity causes outward rotation and direct shortening of the limb; but what is of far greater ultimate importance is the limitation of abduction and the secondary or apparent shortening due to upward tilting of the pelvis, on the injured side. The

[1] Arch. f. klin. Chir., 1927, vol. **137**.

correction of deformity, therefore, is essential to functional repair, and it may be very easily accomplished by adjusting the position of the

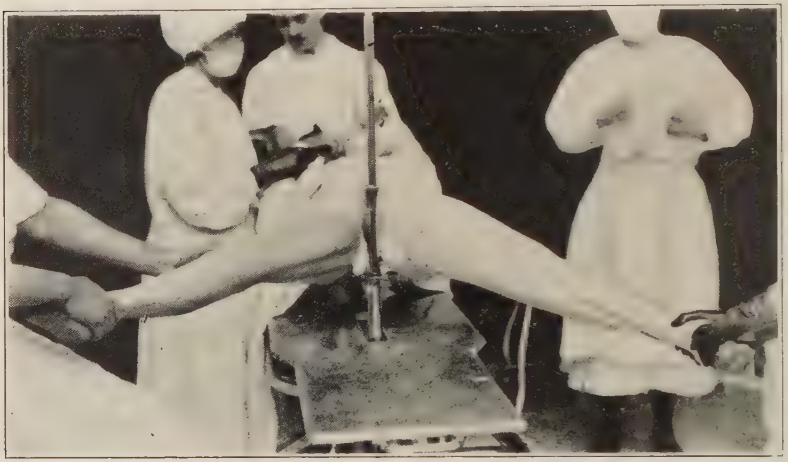

FIG. 886.—The second stage of the abduction treatment, the shortening having been reduced by direct manual traction, the limb has been abducted to the normal limit as indicated by the range on the sound side and rotated inward.

shaft which is under control to that of the neck. Thus the neck being displaced downward and backward is in a relation to the acetabulum that in an unbroken bone would require abduction and inward rota-

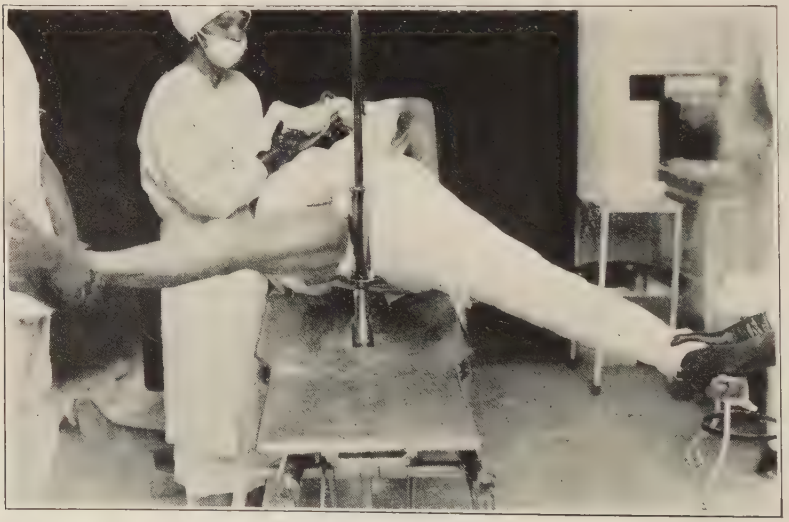

FIG. 887.—The trunk and limb have been protected by the fitted stockinette (Fig. 886) and by a thick covering of sheet wadding and bandage in preparation for the application of the plaster spica.

tion of the shaft; and to restore the normal relation of the fragments one must abduct the limb and rotate it inward.

In most instances, by the manipulation already described for complete fracture, the shortening of the so-called impaction may be

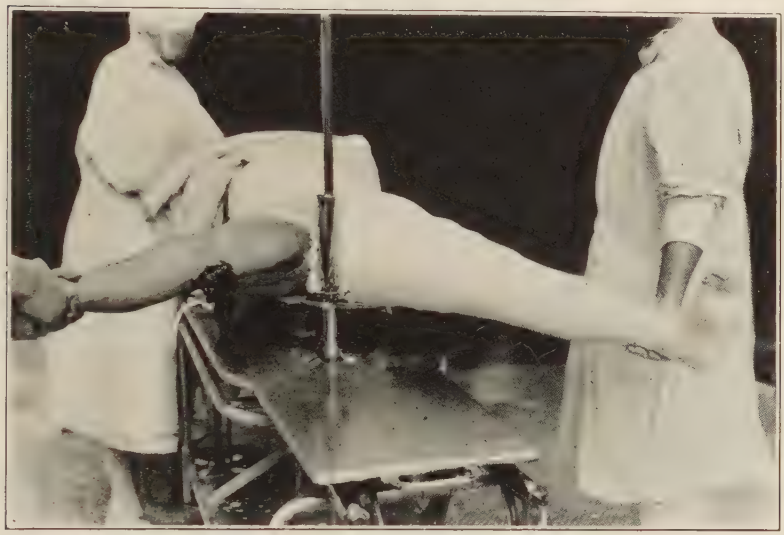

FIG. 888.—After the application of the spica. The function of the spica is merely to support the limb in the attitude that makes the anatomical splinting effective. Close adjustment is therefore unnecessary.

FIG. 889.—The elevation of the head of the bed and the ventral attitude that prevent bed-sores and hypostatic congestion. This picture illustrates fixation in full extension, abduction and inward rotation with slight flexion at the knee. Full extension at the hip joint as contrasted with flexion assures the normal lumbar lordosis. It also forces the fragments forward against the tense capsule; thus its engagement between the fractured surfaces is prevented. Flexion at the knee lessens the pressure on the articular surfaces of the joint.

as easily reduced as if the separation were manifestly complete. If, however, the resistance is greater, as in the incomplete fractures of childhood, page 627, or when treatment has been delayed, manual trac-

tion is supplemented by downward pressure on the projecting trochanter and more effectively by natural leverage. For since the range of normal abduction is dependent on the upward inclination of the neck of the femur, its depression must limit abduction by contact with the upper border of the acetabulum. This contact fixes the neck, and by the leverage of the extended limb against this fulcrum the limb may be abducted and then rotated inward to the required degree. Correction of deformity is the first essential of functional repair; and, far from endangering union, it is the most effective means of promoting it, since restoration of the normal contour apposes the fractured surfaces which were displaced by the distortion.

FIG. 890.—Turning the patient.

The subsequent treatment is the same for all forms of fracture. The head of the bed is raised one or two feet, an inclination which, as contrasted with that required for traction, is far more comfortable, and because of its influence on the blood supply more favorable to repair. The patient is turned at intervals from side to side and completely over to the ventral position, without discomfort or danger of displacement; thus, bed-sores and hypostatic congestion may be absolutely prevented. If feasible, patients may be transported daily to the open air, and fixation in the abducted attitude even permits locomotion without injury as has often been demonstrated by young and unruly subjects. The spica is retained from eight to twelve weeks, or until it may be assumed, or demonstrated by roentgen-ray examination, that union is sufficiently firm to permit movement of the limb. On its removal, the patient should remain in bed, devoting if possible several weeks to muscular reëducation and to the restoration of motion in the disused joints, the limb being drawn out to the limit of abduction at regular intervals by the attendant.

Weight-bearing is not permitted until free and painless movement and roentgen-ray examination indicate stability of repair. Thus, what may be termed the physiological treatment of fracture of the neck of the femur, at least of the central type, requires at least six months; and if early locomotion is desired, a protective hip brace should be provided (Fig. 891). Adequate protection is almost as essential to restoration of function as the correction of the deformity, and its complete neglect in the conventional routine explains much of the final disability in cases in which the fracture has united.

FIG. 891.—A caliper traction hip brace that may be used with advantage in the after-treatment to permit locomotion without direct weight-bearing. The Thomas caliper splint is equally effective (Fig. 871).

Thus it will appear that fracture of the neck of the femur, supposed to pre-



FIG. 892.—Intracapsular fracture. Roentgen-ray picture taken through the spica six weeks after its application, showing the security of the apposition. It may be emphasized again that the fixation that can only be assured by natural mechanics is essential to the repair of the transcervicalf racture, since even slight movement favors the formation of friction facets which prevent union.

sent such insuperable obstacles, both physical and mechanical, to the application of surgical principles as tojustify perfunctory treatment and neglect is actually the fracture most amenable to efficient treatment, since ligamentous and muscular resistance may be utilized to assure both apposition and fixation of the fragments. Furthermore, it has been proved that positive treatment of the fracture supposed to endanger life is actually the most conservative treatment of the patient.

And finally it has been demonstrated that neither old age nor the position of the fracture preclude repair if the fragments are fixed in apposition.

It follows, therefore, that the traditional teaching summarized in the indications quoted and the conclusions based on the results of conventional treatment must be discarded, together with the inadequate methods to which they are adapted. Thus it will appear that the most neglected of all fractures has become the most important from the therapeutic standpoint, because in proportion to the lessened capacity for repair the more essential must be favorable opportunity. This essential is now at command, as may be demonstrated by roentgen-ray examination at the time of operation and at intervals thereafter (Fig. 892). If, therefore, the treatment does not assure this primary and demonstrable opportunity for repair, the one who applies it should be held responsible for the result, not because opportunity will always assure success, but because without opportunity failure is inevitable.

Supplementary Remarks.—At the present time the tendency is to encourage early movement in the treatment of fractures in order to improve nutrition and to assure mobility. This is not practicable in the treatment of fracture of the neck of the femur, since it would prevent union in the transcervical type and might stimulate excessive callus formation about a fracture at the base of the neck and thus limit the range of motion.

The introduction of nails, screws or bone pegs is contraindicated, because they are unnecessary if the abduction method is properly applied, because they damage the cancellous tissue on which repair depends, and because in the event of the not unusual absorption of a part of the neck the fragments would be actually held apart by the means intended to assure apposition.

THE ABDUCTION TREATMENT FOR FRACTURE AT THE SHOULDER.

As has been stated, since the neck of the femur projects laterally it is only in abduction that the fragments may be directly apposed.

The upper extremity of the humerus presents a somewhat similar formation and consequently in fracture at the epiphysis in early life and in fractures near the articulation in adults the same principles may be applied. Manual traction in complete abduction at the joint supplemented by a further elevation of the arm, rotates the scapular and forces the articulation outward so that in some instances the fragments may be sufficiently exposed to permit adjustment by manipulation in the axilla aided by leverage of the shaft. The arm is then placed in complete abduction on the scapula and preferably in upward elevation with that degree of outward rotation and forward inclination of the shaft that best apposes the fragments and fixed in what is called a shoulder-plaster spica. Since abduction and outward rotation are the two movements

most restricted after injury at the shoulder, functional recovery is favored by the abduction treatment as compared to other methods.[1]

FIG. 893.—The shoulder spica applied for fracture at the shoulder-joint, fixing the limb in full abduction and outward rotation.

THE RECONSTRUCTION OPERATION FOR UNUNITED FRACTURE OF THE NECK OF THE FEMUR.

This operation is primarily designed for the treatment of ununited fracture of the neck of the femur in which direct union of the fragments by bone-grafting or other means is doubtful or impracticable.[2]

These patients in addition to functional disability usually suffer persistent discomfort, and the object of treatment is to restore the capacity for weight-bearing and to relieve pain. In the majority of cases the patients are in poor physical condition from prolonged invalidism. The neck of the femur has been in great part destroyed and the head of the bone atrophied so that from both the nutritive and mechanical standpoint restoration of an approximately normal condition is impracticable.

The reconstruction operation is so-called because it is designed to restore stability in weight-bearing with a fair range of controlled motion. For this purpose the head of the femur is removed. The trochanter is cut through at the base on the line of the neck. The surface thus obtained provides, as it were, a new neck. It is shaped somewhat and is inserted in the acetabulum, the limb being abducted about 25 degrees. A section of the cortex from the outer surface of the femur is removed and to this surface the trochanter with the attached muscles is apposed and sutured firmly. The limb is then fixed by a plaster spica for several weeks until union between the trochanter and shaft is firm when passive and active movements are begun (Fig. 891).

[1] Whitman: Ann. Surg., May, 1908.
[2] Whitman: Surg., Gynec. and Obst., June, 1921.

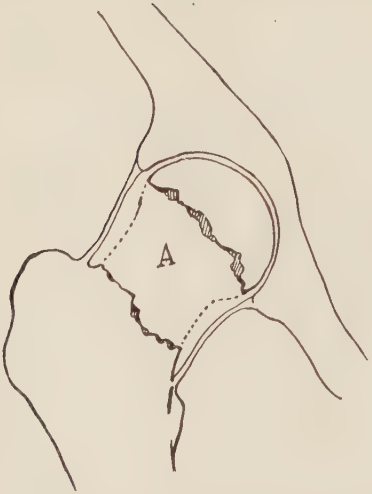

FIG. 894.—*a*. The area of the neck that is usually "absorbed" in ununited fractures of long standing.

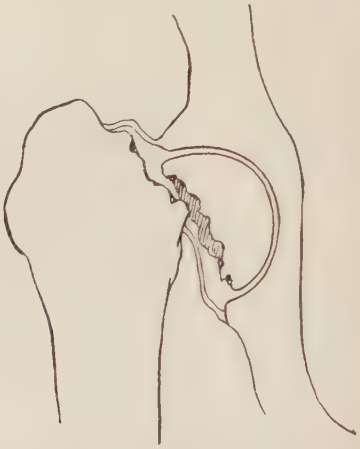

FIG. 895.—The relation of the fragments in the ordinary type of ununited fracture. The shaft of the femur is displaced upward and adducted and the head is atrophied.

FIG. 896.—The fragments are apposed for direct repair, illustrating contact of the trochanter with the rim of the acetabulum, which checks abduction of the limb and causes functional disability even when union is attained.

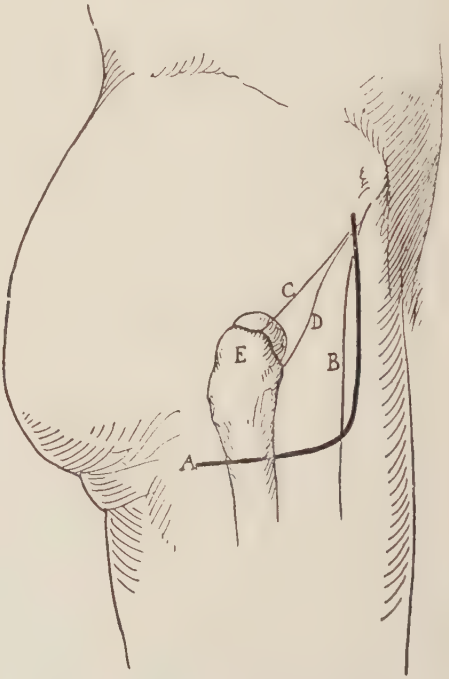

FIG. 897.—*a*, The reconstruction operation, line of incision; *b*, the tensor fasciæ femoris; *c*, the anterior margin of the gluteus medius; *d*, the anterior margin of the gluteus minimus; *e*, the trochanter.

MEDICAL LIBRARY OF THE BOSTON CITY HOSPITAL

The tension of the pelvi-trochanteric muscles supports the femur in the acetabulum. The transplanted trochanter provides leverage for the abductor muscles and the reconstructed neck assures a secure support.

FIG. 898.—The muscular attachments of the trochanter. At left the posterior and internal surface of the trochanter. *a*, gluteus medius; *d*, obturator internus, pyriformis and gemelli; *e*, obturator externus; *f*, quadratus femoris; *g*, line of section. At right, the anterior and external surface of the trochanter. *a*, gluteus medius; *b*, pyriformis-obturator internus and gemelli; *c*, gluteus minimus; *d*, vastus.

The limb is habitually used in an attitude of slight abduction and a range of motion sufficient for ordinary function is assured. The operation has proved by far the most satisfactory and practicable treatment for all cases of ununited fracture in which degenerative changes have advanced sufficiently to make direct union doubtful.

FIG. 899

FIG. 900

FIGS. 899 and 900.—The mechanics of the reconstruction operation. Fig. 899, the line of section of the trochanter and the point on the shaft to which it is to be transferred. Fig. 900, the reconstructed neck, showing the new bearing surface obtained by removal of the trochanter and the leverage obtained for the abductor muscles by its transplantation.

The steps of the operation are, in brief, an incision in the shape of a half U beginning one inch behind the anterior-superior spine extending downward then backward crossing the femur about three inches

below the apex of the trochanter (Fig. 897). This exposes the interval between the tensor vaginæ femoris and gluteus medius through which the capsule is opened and the head of the femur removed. The trochanter is then cut through at its base and with the attached muscles

FIG. 901.—Ununited fracture at the hip, showing the atrophy of the head and loss of the neck.

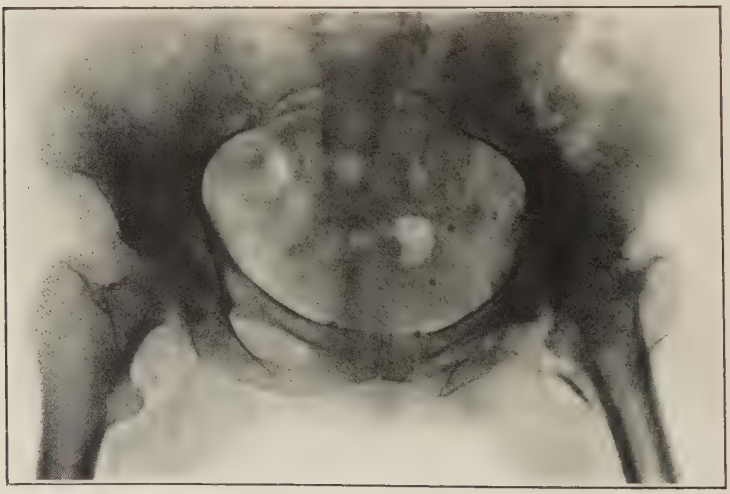

FIG. 902.—After the reconstruction operation, showing the stability of the support attained by the removal of the trochanter and the restoration of leverage.

and turned upward, and any angular projections of bone are then cut away from the upper extremity of the bone. In some instances the trochanter is removed first, but usually it is the last step because with the capsule opened the line for its removal is more clearly defined.



FIG. 903.—Molded plaster splint to support the suspended limb for exercise after the reconstruction operation.

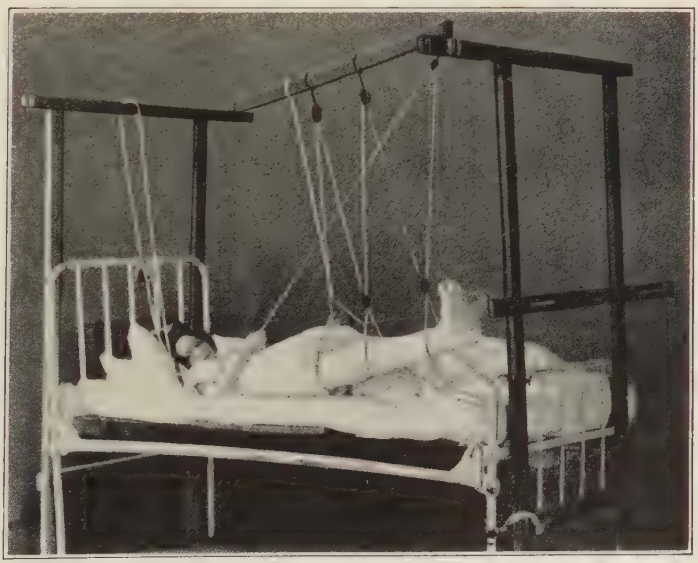

FIG. 904.—Frame used for mechanical exercises after the reconstruction operation.

The trochanter may be fixed to the outer part of the shaft by a bone screw, but in most instances it is attached by sutures. One is passed

through the tissues at the upper margin of the trochanter, the other through the vastus muscle at the lower margin of the wound. These are crossed, the posterior end of the upper being tied to the anterior end of the lower and *vice versa*, in order to press the trochanter down against the femur as the limb is abducted.

The after-treatment is adapted to the patient. In some instances prolonged rest in bed for massage and muscle-training is indicated. In others early weight-bearing with the aid of crutches. The most important point in the after-care is to assure the range extension and abduction by daily methodical manual stretching until voluntary control is assured.

FIG. 905.—Shows the later effects of coxa vara or Legg's disease of early life. The patient at the age of thirty-two presented this distortion complicated by secondary arthritis deformans.

THE RECONSTRUCTION OPERATION FOR OTHER CONDITIONS.[1]

This operation is particularly serviceable for arthritis deformans. (Malum coxæ senile). In these cases there is, as a rule, persistent discomfort and usually flexion and adduction deformity. The ordinary operative procedure has been arthrodesis. This is unsatisfactory because it is difficult to induce actual bony anchylosis, consequently, although the discomfort may be relieved there is often a recurrence of the adduction deformity and thus apparent shortening of the limb. The aim of the reconstruction operation is to relieve pain, to check the progress of the disease and yet to preserve a fair range of motion by lessening the area of the destructive attrition of the expanded

[1] Whitman: Ann. Surg., November, 1924, and June, 1925.

and roughened surfaces of the articulation and transferring the new bearing surface of the femur from the outer to the inner part of the acetabulum.

FIG. 906.—Taken through the plaster spica illustrates the immediate effects of the reconstruction operation, the change in the relation of the trochanter to the ilium and the comparative symmetry of the new articulation being the more distinctive feature. (See Fig. 904.)

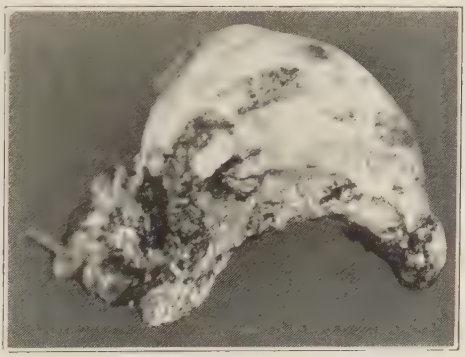

FIG. 907.—Arthritis deformans showing the bone removed in the reconstruction operation. The eroded cartilage and on the left a mass of granulation tissue is shown.

The operation is conducted as described. The trochanter is first removed; the capsule is opened and the head is dislocated by adducting the limb and rotating it outward. The head is resected. The extremity of the neck is then shaped with a file to a smooth rounded extremity. The after-treatment is the same in character that has been described.

The same type of operation may be employed for anchylosis, the acetabulum being reformed by the Doyen instrument, and for various other forms of disorganization of the hip-joint, of the type in which the contact of the trochanter with the side of the pelvis limits abduction.

FIG. 908.—Roentgen-ray taken ten months after the operation, showing the extremity of the neck and the transplanted trochanter. The reconstruction operation is of service for a variety of other conditions. One of which is illustrated in Fig. 905, showing deformity and arthritis secondary to coxa vara of childhood. The result of the operation is shown in Fig. 906.

CENTRAL FRACTURE OF THE ACETABULUM WITH PENETRATION OF THE FEMORAL HEAD.[1]

This injury is usually the result of a fall upon the trochanter or lateral compression of the pelvis.

The signs aside from those of the local injury are flattening of the trochanteric region, slight shortening of the limb and limited movement, particularly rotation, which is entirely restricted.

[1] Whitman: Annals of Surgery, January, 1920.

The diagnosis is rarely made at the time of the injury and the final result is usually persistent flexion and adduction of the limb. If one has the opportunity for immediate treatment the displacement may be reduced by manipulation similar to that for fracture of the neck of

FIG. 909

FIG. 910

FIG. 911

FIG. 909.—Contact of the trochanter and pelvis at the limit of normal abduction.
FIG. 910.—Contact of the trochanter and pelvis in central luxation restricting abduction.
FIG. 911.—Reduction of the displacement by the abduction method.

FIG. 912.—Central fracture of the acetabulum with penetration of the head of the femur showing contact of the trochanter and acetabular rim limiting abduction.

the femur, although in this instance the trochanter already apposed to the rim of the acetabulum serves as a fulcrum, so that by manual traction combined with abduction of the limb to the full degree the head may be withdrawn from the pelvis. In such cases it may be possible to replace the base of the acetabulum by pressure from within

through the vagina or rectum. The limb is then fixed in abduction until repair is complete. In cases of long standing the indication is to correct the adduction deformity by osteotomy at the base of the trochanter.

As has been stated, many of the fractures in orthopaedic practice are seen long after the injury and represent either deformity or functional disability resulting from ineffective primary treatment.

FIG. 913.—After reduction by the abduction method. Taken through the plaster spica.

Of these the more common forms are lateral distortions of the foot from fracture of the tarsus.

Valgus or varus from fracture at the ankle.

Equinus because of failure to support the foot properly in fractures of the limb.

Backward bowing after fracture of the leg bones.

Lateral distortions at the knee.

Outward bowing after fracture at the upper third of the femur because of inefficient protection.

BOSTON CITY HOSPITAL

Non-union, malunion or flexion and adduction of the limb after fracture at the hip.

In the upper extremity, deformity and disability at the wrist from Colles' fracture or from fracture or displacement of the carpal bones.

Lateral deformity of the forearm.

Fixed pronation of the forearm.

Cubitus varus or valgus.

Limitation of flexion at the elbow.

Non-union of the humerus sometimes induced by excessive traction.

Limited motion especially in abduction at the shoulder-joint and finally.

FIG. 914.—Typical Pott's fracture, showing fracture of the malleoli and lateral displacement of the foot. (See Fig. 915.)



FIG. 915.—Typical Pott's fracture showing backward displacement of the foot. (See Fig. 914.)

Fracture of the spine, commonly of the compression type, usually unrecognized at the time of the injury resulting in posterior deformity and persistent disability.

The most common and disabling of these injuries are those about the ankle and foot. In a total of 515 cases the fracture was of the oscalcis in 62 per cent.; of the astragalus in 14.1 per cent.; of the navicular in 85 per cent.; of the cuneiform bones—first, 5.2 per cent.; second, 2.9 per cent.; third, 2 per cent., and of the cuboid. In 50 per cent. of the cases the fracture was of a single bone.[1] Fractures involving the subastragaloid joint often cause disability of the flat-foot type. In some instances irregular projections of bone may be removed or lateral deformity may be corrected by osteotomy or otherwise. If lateral

[1] Müller: Archiv. f. Orth. u. unfalls Chir., 1927, vol. **27**.

movements of the foot cause persistent discomfort an operation for inducing ankylosis of the subastragaloid and mediotarsal joints, as described elsewhere, may be indicated. Usually the application of an efficient arch support to distribute the strain will relieve much of the discomfort.

In cases of fracture of the astragalus with irregularity of the bearing surface, the bone should be removed in the manner described elsewhere. In all instances the foot should be displaced backward sufficiently to restore symmetry.

Fractures about the ankle often result in varus or valgus deformity, which, as in Pott's fracture, is sometimes combined with equinus. Formerly one was usually content to simply correct the more obvious deformity by an osteotomy of the leg bones, but it is of advantage if possible to restore the normal relation of the bearing surfaces of the joint by dividing the bones at the seat of fracture which usually involves one or both malleoli. If equinus is present a subcutaneous division of the tendo Achillis is indicated.

A plaster splint is applied and as soon as practicable the patient is encouraged to bear weight upon the foot now fixed by an efficient support in normal relation to the leg. When consolidation is complete a protective brace is applied and supplementary exercises and manipulations are begun with the aim of restoring the range of motion.

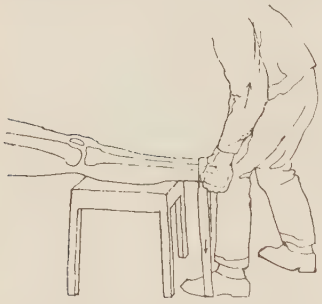

Fig. 916.—Reduction of posterior displacement of the foot in Pott's fracture. (See Fig. 915.) (Jones and Lovett.)

Fig. 917.—Pott's fracture, showing position of pads to restore curve of fibula and balance of ankle. (Jones and Lovett.)

One of the lessons taught by experience in the war, which applies equally well to industrial surgery, is the importance of the prompt application of splints for injuries of the bones and joints to relieve pain; to protect the part from further injury and to lessen the spread of infection.

Immediate alignment of the broken bones by preventing muscular spasm and contraction makes subsequent treatment comparatively simple, and as the majority of injuries of this class are of the lower extremity the Thomas knee brace is by far the most effective of the splints provided for field service. The ring assures resistance and the bars projecting beyond the foot provide for traction and lateral support. This brace has been described in Chapter IX. In field use it cannot

be as accurately adjusted as under more favorable conditions, since it must be large enough for the average man and is applied to either limb. It is constructed of Bessemer steel, copper-coated wire five-sixteenths inch in diameter. The inside bar is 47 inches in length, the outside 52. The ring, furnished in two sizes, 25 and 28 inches in circumference, inside measurement, is covered with ordinary garden hose three-fourths inch inside measurement.

Stretcher bearers were drilled methodically in the application of this brace as described by Osgood.

The Thomas[1] outfit consists of a stretcher on trestles; three blankets; a primus stove; Thomas splint, largest size, reversible stirrup; suspension bar; three flannel bandages (six yards); four triangular bandages; dressings; safety-pins; Gooch coaptation splints, 10 to 6 and 8 to 6 inches.

The personnel consists of an operator and one or two assistants. The indications for use are:

For all fractures of the femur except when extensive wounds of the upper part of the thigh or buttock prevent the application of the ring.

For fractures involving the knee-joint and upper part of the tibia.

For certain extensive wounds of the thigh.

Details of the Drill.—I. *Warning.*—On the word "one," the stretcher, placed on trestles with the stove beneath, is prepared as follows: The first blanket is folded lengthwise into three; two folds lie on the stretcher, one hangs over the side. The second blanket is arranged in the same way, one fold hanging over the other side of the stretcher.

The patient is now placed on the prepared stretcher and lies on four folds of the blanket, the two folds hanging down form a hot-air chamber. The third blanket is placed across the patient's chest, while the splint is being applied.

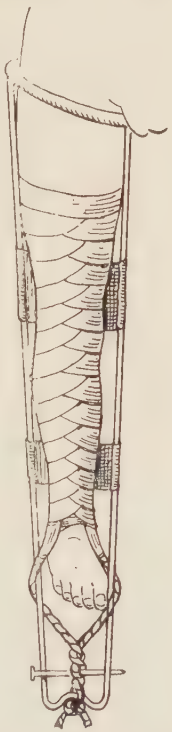

FIG. 918.—The Thomas knee brace, showing the twister which regulates the traction.[2]

II. *Extension.*—On the word "two," the No. 1 assistant stands at the foot of the stretcher facing the patient and opposite the injured limb. Grasping the heel of the boot with his right hand and the toe with his left, keeping the arms straight, he exerts a steady pull, thereby producing the necessary extension.

The No. 2 assistant stands by the injured part and supports the fracture above and below.

[1] Figs. 918 to 940 are from the Manual of Military Orthopaedic Surgery.

[2] Osgood: Jour. Am. Med Assn., August 31, 1917.

III. *Clove-hitch.*—On the word "three," to form the clove-hitch, the operator takes a length of 9 feet of flannel bandage. Holding it in the left hand by its midpoint, he grasps the center of the left half with his right hand, palm to the right, and makes a loop which is carried up and passes behind the left hand, thus forming a clove-hitch with a diameter of 10 inches. This is applied over the boot, with the short end on the outer side; the long end is carried under the instep, up and through the loop around the ankle. The two extension bands thus produced are ready to be attached to the splint later on.

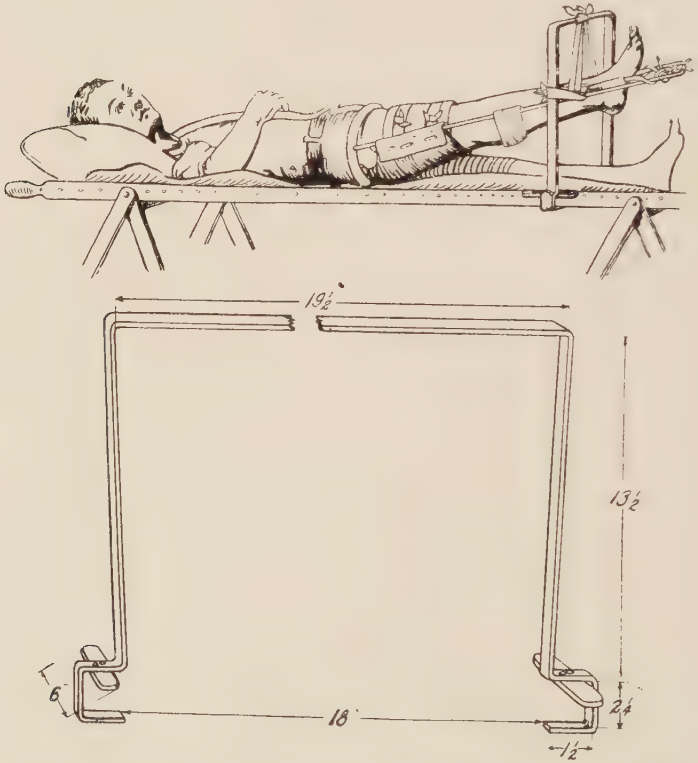

FIG. 919.—The Thomas brace with support for elevation of the limb attached to stretcher; a modification of the British type. Working drawing on page 1001.

IV. *Splint.*—On the word "four," the operator threads on the splint, No. 1 assistant removing the reapplying upper and lower hands alternately to allow the ring to be passed over the foot. The splint should be pushed up under the buttock as far as possible, care being taken to keep the notched transverse bar horizontal. No. 2 assistant, as before, steadies the thigh.

V. *Fixation of Leg.*—On the word "five": 1. The extension bands of the clove-hitch are tied around the notched bar at the end of the splint as follows: The outer band is passed over and under the bar, and

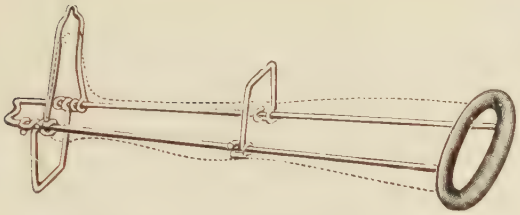

FIG. 920.—Thomas's knee splint with detachable wire foot-piece, brace support and reinforcing attachment in place.

FIG. 921.—Wire foot-piece.

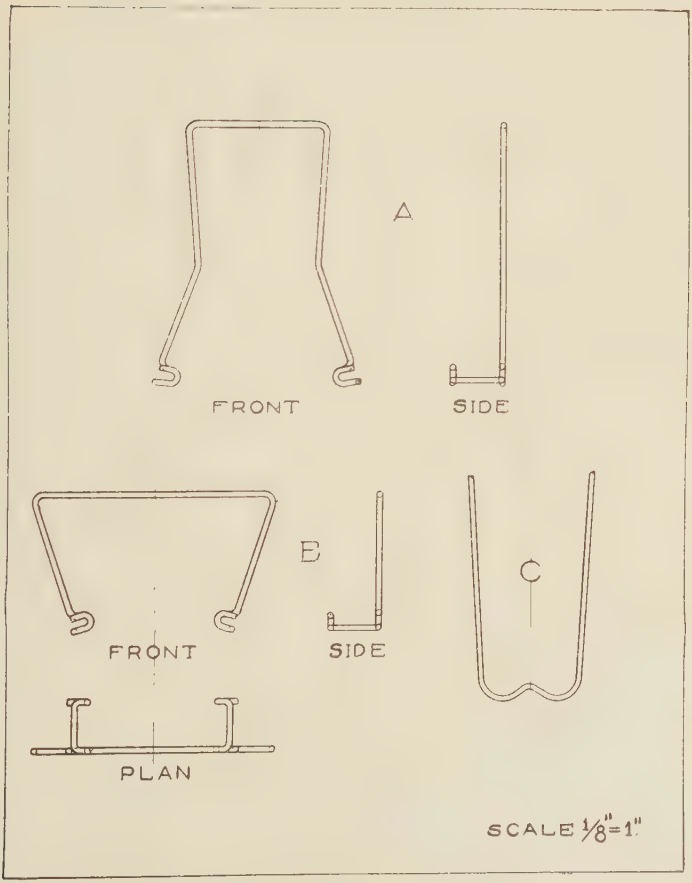

FIG. 922.—*A*, foot-piece for Thomas' knee splint; *B*, reinforcing, attachment and brace support for same; *C*, detail of lower end of Thomas' splint.

then around the notch drawn taut and held over to the opposite side. The inner band is passed under and over the bar, then also around the notch where it crosses the first band and prevents its slipping. The two are finally tied off by a half bow.

2. The middle flannel sling is tied behind the knee, which is held partly bent by No. 2 assistant.

3 and 4. The slings behind the ankle and the calf are tied, so that the leg now rests in a shallow trough, with its center on a level with the long bars of the splint.

5. To prevent the leg rising off the splint, the center of a narrow fold bandage is placed across the leg, just below the knee, the ends are carried down between the leg and the splint, brought up outside the bars, and then tied off in front of the leg. The lower limb is now firmly fixed in a position of extension, and it may be moved freely without causing pain to the patient or damage to the injured part.

VI. *Dressing Wound of Thigh.*—On the word "six," the wound is exposed by cutting away the overlaying portion of trousers on the front or back of the thigh, and the dressings are then applied.

VII. *Gooch Splints and Bandages.*—On the word "seven," the Gooch or coaptation splints are applied. The short piece is placed behind, and secured by tying the remaining two slings. The long piece is placed on the front of the thigh, care being taken to avoid pressure on the knee-cap. The whole is now retained in position by the two narrow fold bandages carried around the thigh outside the bars of the splint.

VIII. *Stirrup and Figure-of-eight.*—On the word "eight," the stirrup is sprung into the splint above the ankle, its foot toward the stretcher. A bandage is then applied to form an additional sling and by a figure-of-eight turn to prevent lateral movement of the foot.

IX. *Spanish Windlass.*—On the word "nine," the extension bands are tightened, and a small piece of wood or a nail is introduced to increase the tension by twisting up as required.

X. *Pad in the Ring.*—On the word "ten," a pad is placed inside the ring on the outer side of the thigh to act as a wedge and prevent undue movement.

XI. *Suspension Bar.*—On the word "eleven," the suspension bar is fitted to the stretcher with the "feet" away from the rackets. The splint is slung up three fingers breadths from the horizontal part of the suspension bar. To clamp down the side movements, lateral tapes are tied to the uprights, and if necessary an additional band may be passed from the splint around one handle of the stretcher.

XII. *Hot-water Bottles and Blankets.*—On the word "twelve," hot-water bottles are applied. The third blanket is folded lengthwise and placed over the patient. The hanging folds of the first and second blankets are brought up over this so that the patient is covered by four folds of blanket above and below.

There are several modifications of the Thomas brace in common

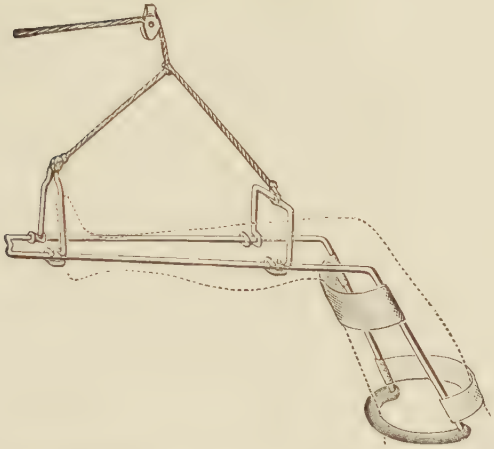

FIG. 923.—The modified Thomas knee brace used as a suspension appliance for fractures of the lower leg.

FIG. 924.—Blake's modification with adjustable foot piece.

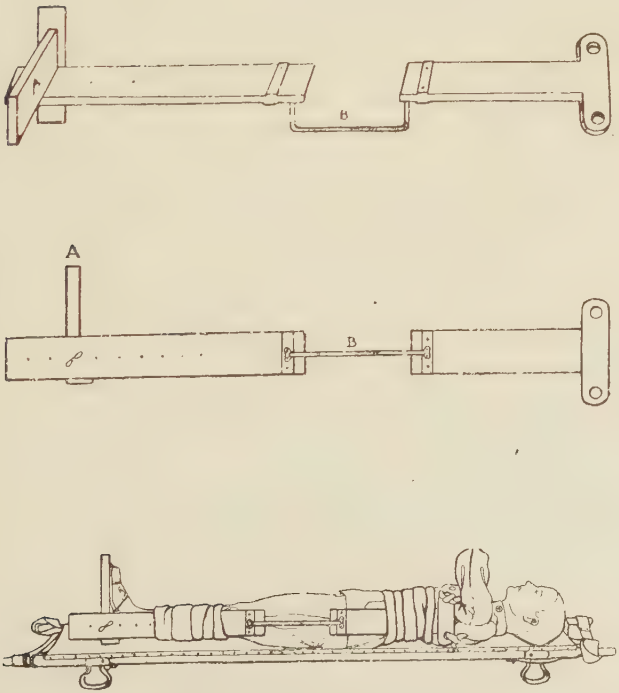

FIG. 925.—Long Liston splint with iron bridge interruption for fracture of the pelvis or extensive wounds in this region.

use. The anterior half of the ring is removed and replaced by a strap. This allows access to the groin. (Blake, Keller.) (Fig. 924.) The same type of brace bent at the knee will serve as a Hodgen suspension splint (Fig. 925). The uprights are joined to the ring by loops,

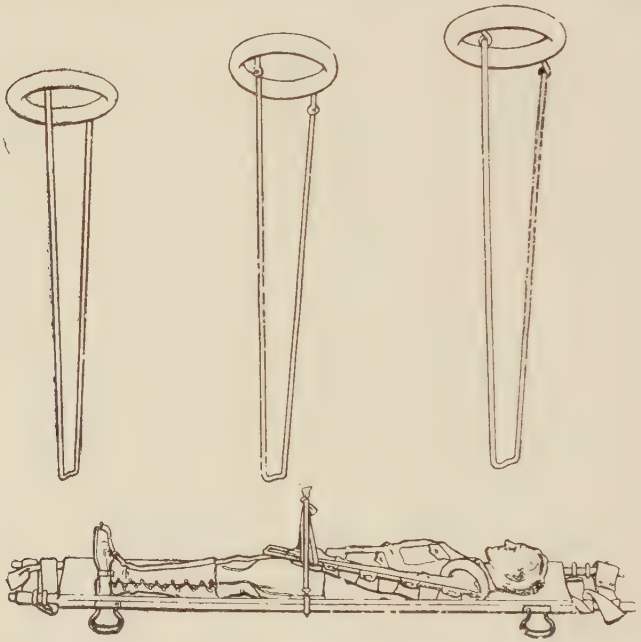

Fig. 926.—Murray's modification of the Thomas splint for transport. (Murray.)

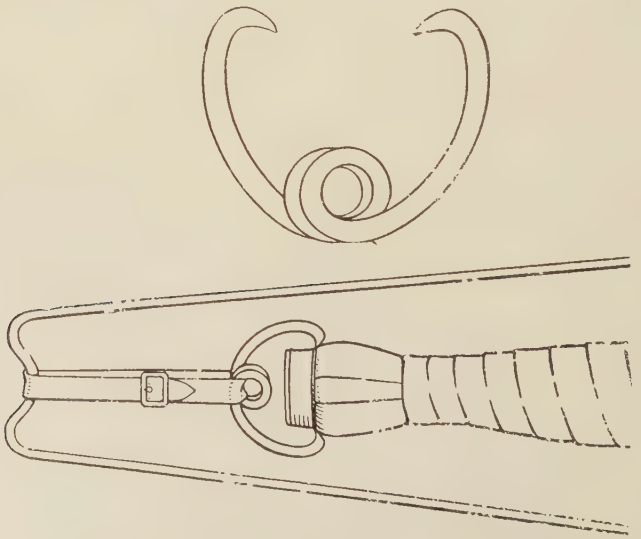

Fig. 927.—Spring clip for immediate application on the field. (Tapson.)

MEDICAL LIBRARY BOSTON CITY HOSPITAL

so that when used for fractures of the upper extremity, the arm may be placed by the side. (Murray.) (Fig. 926.)

For fractures of the pelvis or similar injuries the Liston side splint is used. This consists of two light boards for the limb and thorax, joined by a steel bracket at the hip, and provided with an upright foot support (Fig. 925).

The Cabot posterior wire brace with foot support with side splints is used for injuries of the knees, wounds of muscles, or for fractures at the ankle or leg without displacement (Fig. 930).

It may be noted again that the purpose of the immediate application of apparatus on the field is to assure rest for the injured part of which the basis is coaptation of the fragments. If this is attained the after-treatment is usually simple because the difficulty of adjustment is caused in most instances by muscular spasm, due to the irritation of displaced fragments and by the resistance of the swollen and infiltrated tissues.

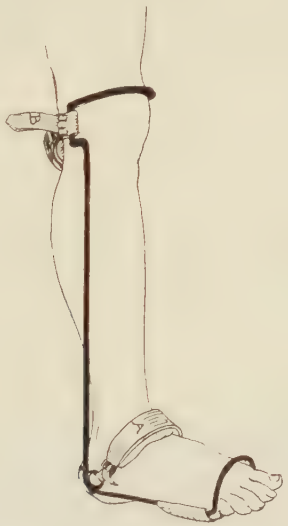

FIG. 928.—Line drawing of wire splint to correct foot-drop. (Osgood.)

All fractures with displacement should be immediately and completely reduced under anesthesia.

Fractures of the shafts of the bones often require traction for a time to assure the alignment. In other situations traction may be unnecessary; at the hip-joint, for example, when treated by the abduction method. At the shoulder-joint also the same method may be employed. Fractures of the elbow except of the olecranon should be treated by full flexion with the forearm supinated. At the wrist, if the deformity is completely reduced the character of the support is of comparatively slight importance. At the ankle-joint, success depends on the reduction of deformity. The foot should be drawn forward to its normal relation with the leg and fixed at a right angle and in slight inversion. The

tendo Achillis should be divided if it resists reposition. Fractures of the foot should be molded as far as possible into proper relation. For the treatment of injuries of this class, plaster of Paris has a great advantage over prepared splints. In fact the treatment of the majority of uncomplicated fractures plaster splints in their various forms in the hands of those accustomed to their use will answer every purpose.

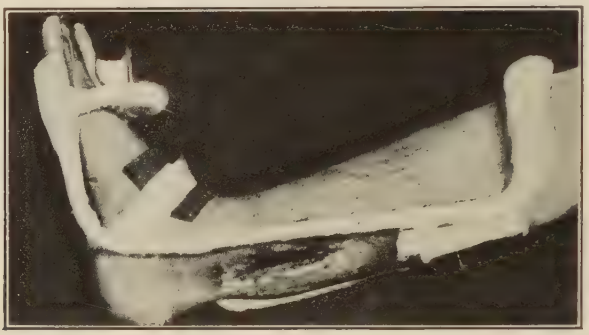

FIG. 929.—Wire foot-drop splint applied. (Osgood.)

A very satisfactory routine treatment for all fractures of the thigh, especially in children, is preliminary application of traction plasters to the limb up to the seat of fracture. When these have become firmly adherent the patient is anesthetized and the deformity is reduced by manipulation and manual traction. While traction is still exerted a spica plaster is applied, fixing the limb in moderate abduction and extension. Immediate traction by weight and pulley is applied and maintained until union is complete.

The appliance is shown in Fig. 334.



FIG. 930.—Padding the Cabot posterior wire splint: *1*, with sheet-wadding; *2*, with a cotton roller around the wire, and *3*, around both wires, to form a back to the splint. (Scudder.)

In the treatment of certain fractures of the lower extremity, especially of the femur near the knee, the Hodgen appliance is of service because it permits suspension and traction in the flexed attitude, both

at the hip and knee, which relaxes muscular tension. The weight of the patient's body, reinforced if necessary by elevating the foot of the bed, furnishes resistance. The flexed leg and the adjustment of the brace by adhesive plaster assure a firm hold on the limb, and traction

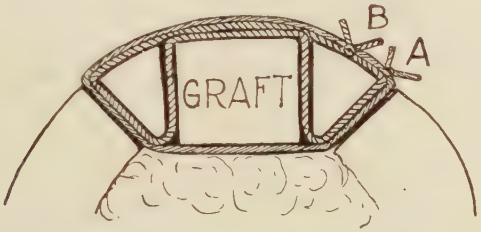

FIG. 931.—Diagram of the cross-section of a graft inlaid in a long bone, illustrating the manner of its fixation by kangaroo-tendon sutures passed through drill holes at either side of the gutter. Note that one suture passes through the drill holes and loops up over the graft and is tied; also note that a second suture passes under the graft and through the same drill holes, thus preventing the graft from falling into the medullary cavity. The gutter and graft in this instance are formed entirely by the twin saws. (Albee.)

is exerted by a weight usually of about 50 pounds, pulling in a direction forward and upward, so that the force is equally divided between the suspension and traction.

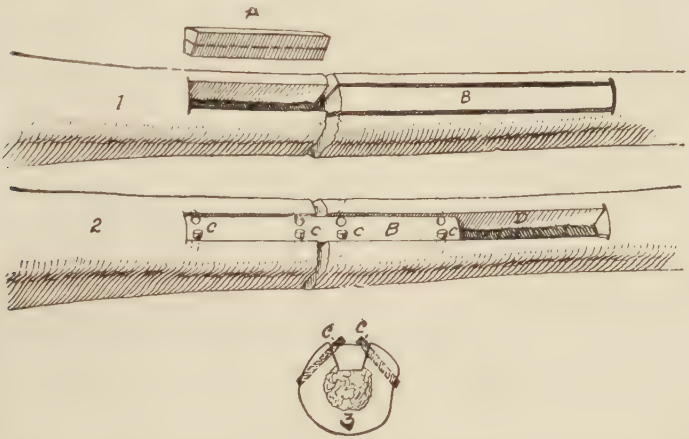

FIG. 932.—Illustrates the Albee method of making use of the bone graft with wedge cross-section removed from the fractured fragments or from some other bone, as the tibia, in the treatment of fresh as well as ununited fractures of long bones. The smaller drawing (3) illustrates the graft dowel pegs in position holding the graft in place, and also shows the shape of the graft and gutter-bed on cross-section. *c*, dowel grafts in place. (Albee.)

Suspension splints of this type are usually employed in the treatment of compound fractures of the upper as well as of the lower extremity. They have the great advantage that the wounds may be dressed and the position of the patient changed, without disturbing the injured part (Fig. 868).

It must be borne in mind that the primary object of treatment is to appose the fragments, and that its permanent attainment should be verified from time to time by measurement and whenever possible by roentgen-ray examination. Furthermore, that the final purpose of treatment is the restoration of function, and that protection and supervision are essential until it is assured.

As a rule, secondary operations are not undertaken to make limbs longer if joint motion is free—if the union is firm and if the alignment is satisfactory.

Deformity that embarrasses the movement of a joint or that causes faulty weight-bearing should be corrected.

Ununited fractures complicated by suppuration should not be operated on until long after the wound is closed, preferably after an interval of six months.



FIG. 933.—Massive autogenous graft applied to femur and held in place by six beef-bone screws. This graft gives abundant contact of endosteum to endosteum (Henderson).

The operation of choice is the inlay bone graft. The fragments are exposed and the fibrous covering of the ends removed. They are then brought into alignment and held in position, preferably by traction apparatus.

With an electric saw, carrying two parallel blades set at a distance varying with the size of the bone, a segment is removed, extending about two inches into each fragment, and to normal bone, opening the medullary cavity. A section of bone of equal size with its periosteum is then removed, usually from the tibia of the sound side. This is placed in the trough and is fixed in place by strong sutures of chromicized gut passed through holes bored in the sides of the groove over and in some instances under the graft as well, or when the bone is small passed around it.

The sliding graft is employed in comparatively recent cases, in which the nutrition of the bone seems fairly good. In some instances the inlay may be made slightly wedge-shaped to prevent it from sinking into the medullary cavity. A shallow cut is made with the twin saws and the section completed with a single saw inclined slightly inward.

The essentials of success in bone grafting are freedom from infection, secure fixation of the graft in contact, at the extremities at least, with healthy bone. Repair is usually slow, and protection should be assured until it is complete.

A practicable alternative to the inlay is a splint graft applied laterally to the fragment from which the cortex has been removed to provide a flat surface. The splint graft is usually fixed in place by bone screws, but in cases on children in which the bone is fragile, loops of chromicized catgut may be used instead (Fig. 933). Osteoperiosteal grafts may have the advantage of ease of application, but the outcome is less certain.

Another operation is called bone-splitting (Kleinschmidt[1]). The fibrous tissue having been removed from the fragment, the two extremities are split longitudinally, so that a wide area of freshened bone may be apposed.

Delayed Union.—In cases of delayed union repair may be stimulated by massage, by passive motion, by passive congestion and the like, or by the direct injection of blood at the site of the fracture. The most effective stimulation, however, for fracture of the lower extremity is weight-bearing under the protection of a splint that supports the bones in normal relation.

DISLOCATION OF THE CERVICAL VERTEBRÆ.

Subluxation or actual dislocation of the cervical vertebræ is not uncommon and may be induced by slight violence, by chiropractic manipulation for example.

In unilateral displacements there is distortion of the torticollis type: in bilateral cases the symptoms may be less apparent. The diagnosis is usually made by roentgen examination. The displacement may involve any of the cervical vertebræ.

Langworthy[2] has reported 30 cases, 13 unilateral and 17 bilateral. In this latter group the cord was involved in 8 cases and death followed in 5. In all the others the displacement was reduced by the Walton method, which he describes as follows:

The Method of Reduction.—"Walton's method aims to replace the articular facets that have slid apart. To dislocate, the facet of a cervical vertebra slides upward on the facet of the vertebra next below, and catches on the top of the lower facet or slips over into the intervertebral notch in front of the lower facet. The patient having been anesthetized is drawn to the edge of the table. To reduce a left side dislocation, the head is first bent toward the right shoulder to disengage the facets; that is, to lift the upper facet out of the intervertebral notch of the lower. The head is then rotated to the left to throw the upper facet back, and down to fit on the lower facet. The movements are reversed for the right side. One side at a time is reduced, a separate manipulation for each side being carried out in the bilateral cases. I use the edge of my hand as a fulcrum on the opposite side of the neck from the lesion when bending the head laterally to disengage the facets.

[1] Ztschr. f. Chir., April 24, 1926.
[2] Jour. Am. Med. Assn., January 11, 1930.

In some of the older lesions great force in this part of the manipulation is required, and the edge of the hand on the opposite side of the neck aids in lifting the displaced facet and prevents a lateral pushing of the whole head and neck toward the shoulder which is not effective. It is important to throw the head back into hyperextension and to keep it there, as soon as the dislocation is reduced, in order to prevent redislocation. A plaster case is applied in the position of hyperextension, including the head, neck and chest.

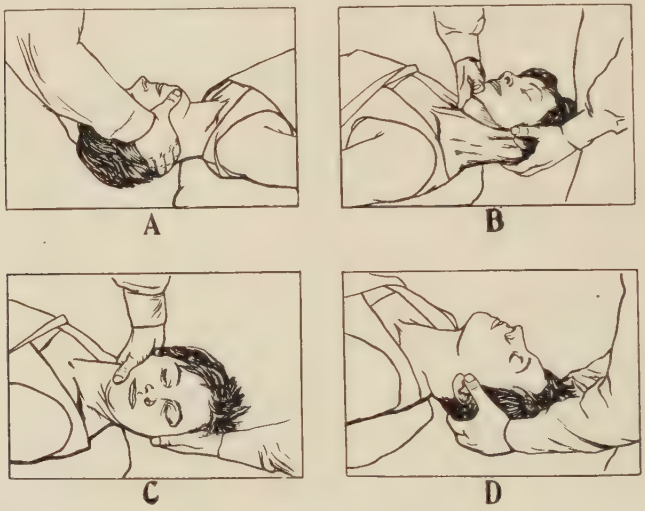

FIG. 934.—Steps in the manipulation as done to reduce a left-sided dislocation between cervical vertebræ: *A*, the side of the hand used as a fulcrum, over which the head is bent to the right as in B^0 *C*, head rotated to the left to complete the reduction; *D*, head hyperextended to prevent redislocation. (Langworthy, *Jour. Am. Med. Assn.*)

"In many cases the reduction is easy. In the other cases, considerable force must be applied quickly. In the bilateral cases a roentgenogram is made after each attempt. The first attempt is made with little force. If not successful, more force is used. As many as four attempts have been necessary, the last made with great force, before securing reduction. This force must be applied in a definite way. No violent pulling or twisting on the head should be done. Force, if necessary, is applied for an instant to raise the facet and then throw it back. For the left side, for instance, the head is bent easily to the right as far as it will go; then, with the edge of the right hand strongly against the right side of the neck, quick force is applied to bend the head still farther to the right, and at the point of maximum application of force, before relaxing the stretch on the left side of the neck, the head is rotated quickly to the left. The object is to lift the upper facet for an instant and to throw it back on the lower facet at the moment when it is raised. I have used practically my full strength in this maneuver without harm."

AMPUTATIONS AND ARTIFICIAL LIMBS.

The adjustment of artificial limbs in military hospitals is under the supervision of the orthopaedic division and, consequently, the preparation of stumps for their new function.

The Preparation of Stumps for Artificial Limbs.—The characteristics of a satisfactory stump are:[1]

1. A good covering for the bone.
2. Sound healing.
3. Painlessness.
4. Freedom of movement.

The skin should not be adherent to the bone, and the scar should not be exposed to pressure. If the stump is of a lower extremity the muscles should have firm attachment to the bone in order to assure control.

It is desirable that the stump should permit complete or partial weight-bearing, the percentage varying according to the site of the amputation, as illustrated by a report of 534 recent cases.[2]

Upper third of the thigh	2	out of 22	9 per cent.
Middle third of the thigh	75	out of 235	32 "
Lower third of the thigh	63	out of 81	77 "
Through knee-joint	5	out of 6	83 "
Upper third of leg	42	out of 74	56 "
Middle third of leg	64	out of 98	65 "
Lower third of leg	6	out of 15	43 "
Syme's amputation	12	out of 15	86 "

An average of 50 per cent. weight-bearing stumps.

It is generally admitted that the aperiosteal amputation, *i. e.*, the removal of both periosteum and endosteum from the lower extremity of the bone, prevents excrescences that sometimes cause discomfort. Nerves should be drawn down, divided and the sheath closed over the ends to avoid painful neuromata.

Little's conclusions as to the site of election for amputation, are that exarticulation at the hip or amputation through the neck of the femur is preferable to short stumps, which often become distorted and at best are not long enough to control the artificial limb.

Of other amputations of the thigh the longer the stump the better. End weight-bearing is of great advantage and a posterior scar is desirable. Amputations through the knee-joint are seldom satisfactory, because the stump cannot be adjusted to the joint of the artificial limb. The point of election below the knee is the junction of the middle and lower thirds of the leg.

The Symes amputation assures the best end-bearing stump if care is taken to remove the plantar nerves from the flap.

Amputations through the mediotarsal joint are not usually satisfactory because the unapposed action of the calf muscle induces equinus deformity and subjects the scar to pressure. It would seem, however,

[1] E. Muirhead Little: Am. Jour. Orthop. Surg., April, 1918.
[2] British Med. Jour., October 27, 1917.

that by implanting the anterior muscles in the bones, and if necessary lengthening the tendo Achillis, this might be avoided if the after-care were efficient.

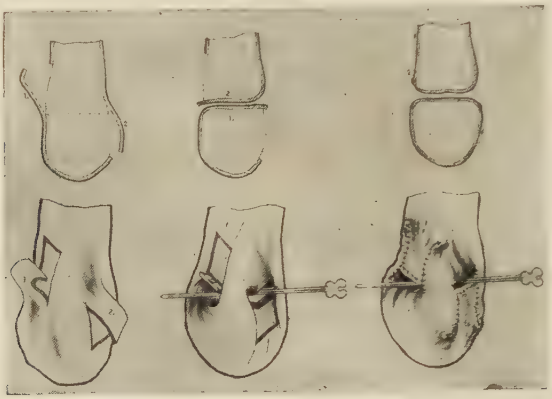

Fig. 935.—Diagram showing steps in operation in making skin tunnel. (Arana and Du Yalla.)

Vanghetti's Amputation.—The most interesting experiment in amputation and one that may be of practical advantage in the upper extremity is the preservation of the independent action of the muscles,

Fig. 936 —Double knob (flexor, extensor). Belt to move pulley of the prosthesis. (Putti.)

by freeing the muscular substance from the bone and enclosing it in skin flaps—the kineplastic amputation suggested by Vanghetti.[1] By his method the extensor and flexor muscles were joined over the

[1] Annals of Surgery, April, 1918.

end of the stump and the skin flaps sewed about them, forming a loop which could be drawn forward or back, and thus serve as a motive force for an artificial hand. This has been modified by Sauerbruch by passing a tube of skin through the stump as illustrated. Another variation is the formation of knobs of muscle covered with skin to which straps may be applied (Figs. 936 and 943).

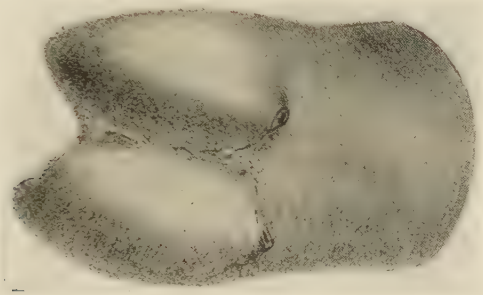

FIG. 937.—A double motor—one at extensor, one at flexor side (Sauerbruch.)

It is the general impression that these separate or club motors containing two or more tendons, if possible with a bony attachment, are superior to the pulley motor. The flexor motor is always stronger than that on the extensor side.



FIG. 938.—Single motor on the flexor side—tube passed inside, with strings for exercises (traction). (Sauerbruch.)

At the present time the tendency is to make the motors longer and to cover them with flaps from the abdomen.

Sauerbruch and Stadler[1] have reported on 1500 operations of this type.

Later a tunnel may be constructed as in the diagram.

The conditions that most often delay the application of an artificial limb are:

1. Sinus.
2. Painful nerves or sensitiveness due to inflammation of the bone.

[1] München. med. Wchnschr., April 9. 1920.

3. Unsound scars.
4. Contracture at the adjoining joint.

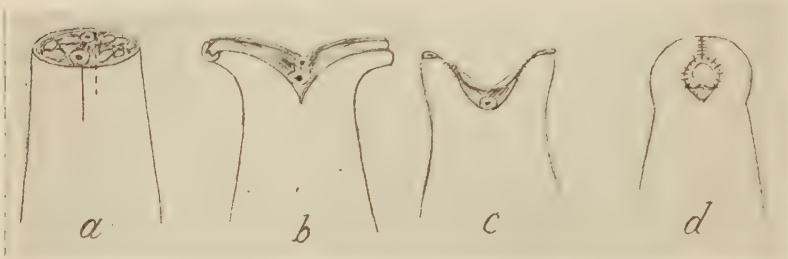

Fig. 939.—Pieri's suggestion for a primary kineplastic amputation. *a*, surgical preparation as for a Celsus stump—two-side incision; *b*, two flaps formed—bones sawed: *c*, sutures of flap to form two knobs; *d*, a motor loop is formed.

The principles of treatment are self-evident. As a rule, further shortening of the stump by reamputation is to be avoided if possible.

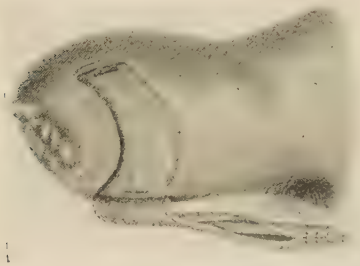

Fig. 940.—Muscular loop. Shows how to form a tube of skin for the exterior attachment. (Sauerbruch.)

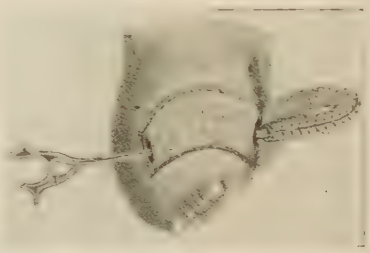

Fig. 941.—Cutaneous tube passed in a tunnel made in the motor. (Sauerbruch.)

Early functional use of the stump of a lower extremity is desirable, and as soon as the wound is closed the patient should attempt graduated

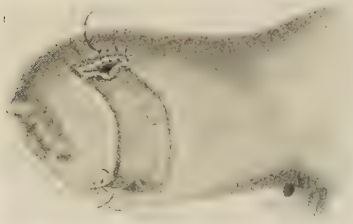

Fig. 942.—Further step in forming the exterior attachment. (Sauerbruch.)

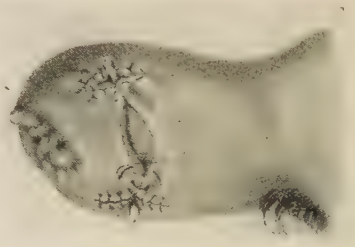

Fig. 943.—Repair of the skin. Rubber tube passed in the tunnel (Sauerbruch.)

weight-bearing and movements to prevent contractions. Often within a few weeks the patient may use the limb in locomotion. A "broomstick" of the proper length is fitted to a board the size of the end of

the stump, which is included in a plaster bucket, the junction being strengthened by wire or metal bands. The upper part of the plaster bucket should be adjusted beneath the tuberosity of the ischium, so that if practicable, weight may be borne in part here and in part by the stump resting on a cushion of cotton. The attachment is made by bands over the shoulder as for the Thomas splint, which if fitted with an adjustable bucket may be used for the same purpose.

As the stump changes in shape under functional use, it is of advantage when the amputation is below the knee to fit a temporary artificial limb similar to that to be eventually worn, except for the supporting bucket, which may be constructed of bone glue and plaster on a very thin plaster shell that has been accurately molded about the tuberosity of the tibia.

This preparation is composed of 400 parts of bone glue dissolved in one-half liter of water heated over a water-bath. When boiling, 400 grams of alabaster plaster of Paris in the form of a thin plaster cream are added slowly, the mixture being constantly stirred and at a temperature of 100° C. Starch bandages are saturated with the mixture, and are then wound about the plaster shell and the steel uprights of the limb. This may be changed from time to time until the stump becomes stable.

In Canada, artificial limbs of types that have proved to be most serviceable are furnished by the Government. The services of mechanics who wear such appliances being utilized for their manufacture, repair, and replacement. For this purpose numerous stations have been established throughout the Dominion.

The essentials of an artificial limb are comfort and security. It should be first applied in an unfinished condition, to be finally adjusted when the patient has learned to use it properly and when the stump has become stable.

In amputations of the thigh, the weight should be supported by the tuberosity of the ischium, and by pressure on the gluteal and adductor muscles, a stump capable of end weight-bearing being of great advantage in lessening friction and pressure. The adjustment of the bearing part of the bucket corresponds to the Thomas ring, that beneath the central surface of the tuberosity being the lowest part. The bucket should fit the stump closely to assure control.

The joint at the knee must be behind the axis of the limb, in order to prevent flexion under weight-bearing. The leg section is placed in a relation of slight valgus to that of the thigh, making the support more secure.

For amputation below the knee the chief support is the tuberosity of the tibia, to which the limb should be accurately adjusted, the leather socket being provided with lacing behind if necessary to accommodate the bulge of the calf.

The average weight of artificial limbs should be according to Little: hip, 9 pounds; thigh and pelvic band, $6\frac{3}{4}$ pounds; thigh, $5\frac{1}{4}$ pounds; below knee, $4\frac{3}{4}$ pounds.

Artificial limbs for the upper extremity are, as compared with those for the lower, of slight utility. They are most useful when arranged with hooks or other implements for special purposes, but a natural appearance and practical service cannot often be combined.

INJURY TO NERVES.

Injuries to peripheral nerves complicate a large proportion of gunshot wounds of the extremities. A test, therefore, of muscular function should be made in such cases, since efficient splinting to relax tension and to prevent deformity has an important influence on repair.

The more direct and immediate physical effects of the injuries of individual nerves are as follows:[1]

Circumflex.—Paralysis of deltoid and teres minor. A certain range of abduction of the arm by means of the trapezius and supraspinatus persists.

Musculospiral.—Loss of extension at the wrist and of the proximal phalanges of the thumb and fingers. The distal phalanges may be extended by the action of the interosseii and lumbricales. Supination of the forearm is weakened. Sensory disturbance is slight or absent.

Musculocutaneous.—Weakening of power of flexion at the elbow.

Ulnar.—Slight weakness of flexion of fingers. Inability to extend the fourth and fifth fingers. The fingers cannot be separated owing to paralysis of the dorsal interosseii. Anesthesia of the fourth and adjoining half of the fifth finger. Atrophy of the interossei, of the palmar thumb muscles and contraction of the fourth and fifth fingers are later symptoms.

Median.—Diminished power of flexion of fingers and thumb. Anesthesia of the palmar surface of the thumb, ring, index and half of the fourth fingers. If the injury is above the elbow the pronators of the forearm are paralyzed.

Sciatic.[2]—Unless the injury is high up the hamstring muscles are simply weakened. Paralysis below the knee is complete and there is anesthesia of the foot, except of the area on the inner side supplied by the internal saphenous.

External Popliteal.—Complete paralysis of the anterior and external leg muscles. Anesthesia of the dorsum of the foot and toes.

Musculocutaneous.—Paralysis of peroneii. Anesthesia except of adjoining surfaces of great and second toes.

Anterior Tibial.—Paralysis of dorsal flexion of the toes and anesthesia of adjoining surfaces of first and second toes.

The anterior crural supplies the psoas, the sartorius and the quadriceps extensor muscles. The others are supplied by the obturator internus. Injury of the anterior crural if high up would cause paralysis

[1] Leo Mayer: Orthopaedic Treatment of Gunshot Injuries.

[2] The hamstring muscles are partly supplied by a branch from the sacral plexus entering the muscles just below the tuberosity of the ischium.

of the anterior thigh group and anesthesia of the lower part of the front of the thigh and inner side of the leg.

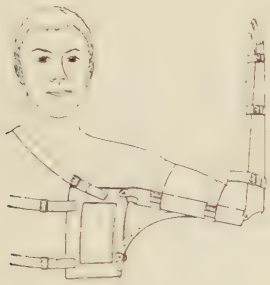

FIG. 944

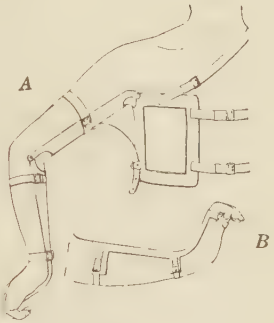

FIG. 945

FIG. 944.—Adjustable abduction splint with adjustable forearm piece for paralysis of the fifth and sixth cervical nerves. The arm is held in abduction and *external rotation* with the hand in supination. By altering the pin and lever to the arm piece, the arm can be held in any desired angle of abduction. Forearm piece may also be adjusted by screw lock to various degrees of flexion. The splint is made of aluminum and lined with felt.

FIG. 945.—Splint for total or partial paralysis of the musculospiral. *A* (above). Adjustable aluminum abduction splint with forearm piece to maintain the wrist in dorsiflexion. Arm held in abduction with the wrist dorsiflexed. *B* (below). Small dorsal skeleton splint (similar to Jones' splint only dorsally placed) to prevent wrist drop. Consists of a narrow dorsal piece and annular portion extending across the proximal phalanges of *all five* fingers. By being dorsally placed greater freedom is given to the palm. Note angle of elevation of the wrist.

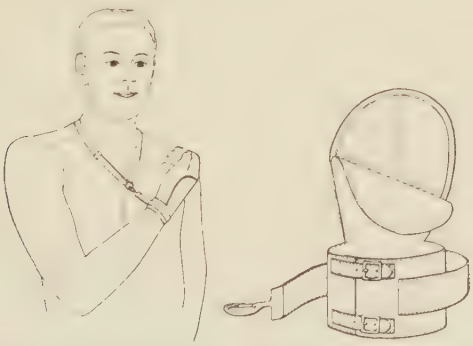

FIG. 946.—Wrist strap for paralysis of the musculocutaneous. *A* (at left). Arm held in semiflexion and drawn across to the opposite shoulder. Hand is held in supination. Metal dorsal extension piece supports the hand and prevents it from falling into dependent position. The small strap about the wrist is attached only to the volar surface on the *radial side* and passes *under* the wrist, thus assisting in maintaining supination. To illustrate wrist strap and metal extension. Leather is ripped and turned back, showing metal piece which extends from wrist across dorsum of hand. Note line of attachment of small wrist strap and that it passes *under and behind* the wrist. (Stookey.)

Injury of the obturator if high up would paralyze the adductors.

These nerves are of less surgical interest than those previously described.

Relative Frequency of Nerve Injury.—In 1000 consecutive cases analyzed by Burrows and Carter the ulnar nerve was involved in 327; the median nerve in 242; the musculospiral nerve in 204; the sciatic nerve in 121.

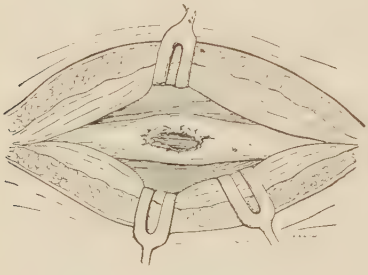

FIG. 947

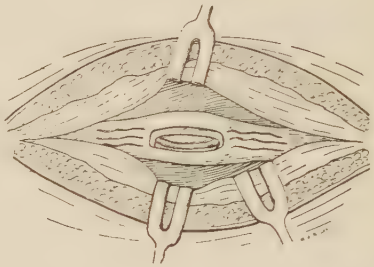

FIG. 948

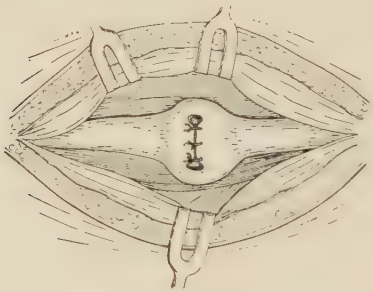

FIG. 949

FIGS. 947, 948 and 949.—Perforation of sciatic. Demonstrates method of suturing after excision of scar tissue. Line of excision should be sharp, avoiding as far as possible normal funiculi. Plain catgut sutures are passed through and through and tied after all are in place. (Stookey.)

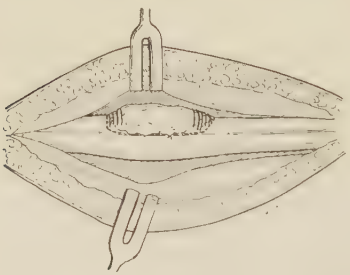

FIG. 950

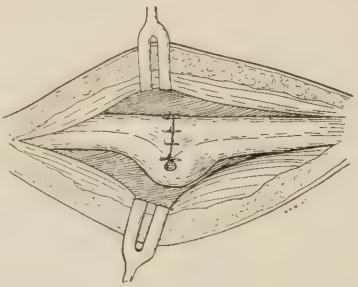

FIG. 951

FIGS. 950 and 951.—Partial injury to sciatic, peroneal portion involved. Nerve ends first mobilized. Series of multiple incisions with line of excision sharply made. Sutured with plain catgut without tension.

Surgery of Peripheral Nerve Injuries.—A very large proportion of the patients with peripheral nerve injuries present deformities that

might have been prevented by efficient support. The causes of deformity and the means by which it may be prevented have been described in Chapter XVII, with particular reference to the lower limbs. This supplemental discussion applies to the protective treatment of paralysis of the upper extremity.

The support should remove tension on the injured nerve and paralyzed muscles. It should be sufficiently comprehensive to prevent indirect as well as direct deformity. The attitude of election should be maintained constantly. The muscles should not be compressed, and care should be taken that pressure is not made on anesthetic areas.

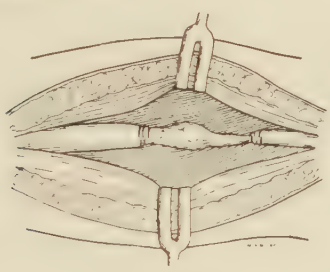

FIG. 952

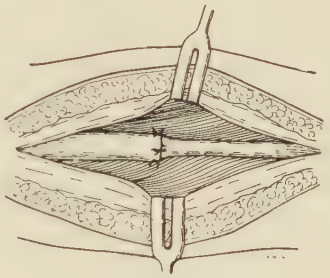

FIG. 953

FIGS. 952 and 953.—Nerve caught in scar and callus. Distal extremity very much smaller; usually the amount of connective tissue, in the late cases, is increased. Small longitudinal slit is made in distal stump to permit epineural approximation and prevent ingrowth of scar. (Stookey.)

For injury of the brachial plexus, particularly of the upper cords: The upper arm should be abducted to about 60 degrees and rotated outward. The forearm should be supinated and the wrist somewhat dorsiflexed. The apparatus used by Stookey, constructed of aluminum and with adjustable joints, illustrates the principle (Fig. 944).

For injury of the ulnar nerve above the elbow: The splint should hold the wrist in slight dorsiflexion, tilted toward the ulnar side, with the fingers slightly flexed and the thumb slightly adducted.

For median paralysis the attitude is the same except that the hand should be tilted somewhat toward the radial side.

For injury of the ulnar low down a short splint to hold the wrist in slight dorsiflexion, with the thumb adducted, is alone required; for musculospiral paralysis the wrist must be supported in dorsiflexion and the thumb and fingers in extension-flexion at the finger-joints being permitted at intervals.

The purpose of the splints is to prevent claw-hand, due to paralysis of the intrinsic muscles and the unapposed action of the extensors.

Langworthy[1] uses thin plaster splints molded about the dorsum of the forearm and hand to the extremities of the fingers, with a separate enclosure for the thumb. The splint is held in place by a single band above the wrist.

[1] Am. Jour. Orthop. Surg., November, 1918.

In connection with the support, gentle massage and the application of galvanic electricity or the faradic form, if the muscles respond, are of service in preserving nutrition and preventing retraction of the muscles. The finger-joints should be moved at regular intervals through the normal range of motion, in order to prevent the restriction that is induced by atrophy of the joint strictures.

It is estimated that from 40 to 60 per cent. of nerve injuries recover spontaneously, consequently immediate operation is rarely indicated except for extreme pain or advancing paralysis. Surgical intervention is not justifiable while there are evidences of progressive improvement, such as lessening of the area of anesthesia and return of deep sensibility. One of the most important signs of recovery according to Stookey,[1] is formication, a sign elicited by gentle pressure on the nerve trunk, inducing a peculiar creeping sensation in the periphery. Under ordinary conditions a delay of about four months is indicated, and as the nerve injury is often complicated by a suppurating tract no time is lost, since a clean wound is essential to success. Deformities and contractions should be overcome as a preliminary measure.

Sir Harold Stiles[2] has had an extensive experience with this class of injuries. The practical points which he emphasizes are that the operations on nerves are usually tedious, therefore the surgeon should be seated. Three assistants are desirable: one to hold the limb, one to swab and the other to retract the tissues.

A tourniquet is not advisable because the vessels serve as guides to the nerves and because of the subsequent oozing. No salt solution is used, as the best lotion is the patient's blood.

The knife should be very sharp; the dissection should be clean. It should err rather in being too extensive than too limited, and the nerve should always be exposed both above and below the lesion.

During dissection the limb should be flexed sufficiently to remove tension and to permit free retraction.

The dissection should be carried wide of the nerve and the muscles as well as the nerve should be freed from cicatricial tissue.

Repair of tendons must often be combined with the operation. When the dissection is complete and the wound dry, the direct operation on the nerve is begun, care being taken to preserve its branches. If the lesion is complete the bulbous or cicatricial extremities should be cut away with a sharp knife, until the nerve bundles are exposed throughout the entire area. If the nerve has not been completely divided, all cicatricial tissue should be removed from the sheath. It should then be carefully palpated for induration or for cicatricial or gliomatous formation in its substance. The excitability of the nerve should then be tested by the faradic current, and as this requires exposure, the entire limb should be sterilized. If the response is good, it is advisable to incise the affected portion longitudinally in one or two

[1] Surg., Gynec. and Obst., October, 1918.
[2] Am. Jour. Orthop. Surg., June, 1918.

BOSTON CITY HOSPITAL

places, but if feeble, an exsection should be made, provided the extremities can be easily apposed, although no fast rule can be made.

For suturing the finest linen thread is used. One through-and-through suture is placed for approximation, and the remainder are perineural sufficient in number to prevent the protrusion of the nerve fibers.

Accurate apposition is essential. No artificial covering is used, the best bed for the nerve being the fatty cellular tissue or muscle.

Drainage is not usually necessary.

The limb should be fixed by efficient splints in a position to relax all tension.

Repair of nerves that have been divided proceeds from above downward. The neuraxes penetrate the nerve trunk at a rate estimated at one inch a month. Thus return of function is much slower and more doubtful after division of the brachial plexus or the upper part of the sciatic than of injury nearer the distal extremity of a nerve.

During the period of recovery, the vasomotor function first improves then deep sensation to pressure and joint motion, the discriminating sensation. Voluntary motion returns first in the upper and last in the lower muscles supplied by the injured nerves.

Operations on Individual Nerves.—In dealing with injuries of the individual nerves, Stiles does not attempt to do more than touch upon a few points in the anatomy and technic of the operations, which may possibly prove helpful to those orthopaedic surgeons who have not yet had much opportunity for the treatment of these injuries, and in their interest his experience is presented in his own words:

Brachial Plexus: Supraclavicular Portion.—1. Injuries of the brachial plexus above the clavicle are more frequently found to involve the upper nerves, or the outer part of the plexus; wounds of the eighth cervical and first thoracic nerves are generally fatal from involvement of the subclavian vessels.

2. In operation on the plexus, free access is essential; hence an L-shaped incision is preferable to a single oblique incision. The vertical limb runs along the posterior border of the sternomastoid muscle as high as the junction of its upper and middle thirds. The horizontal limb should lie just *below* the clavicle.

3. The posterior belly of the omohyoid and the posterior border of the scalenus anticus are the chief guides to the plexus, behind which is the scalenus medius muscle.

4. The fifth cervical nerve appears from behind the scalenus anticus above the transverse process of the corresponding vertebra and therefore well *above* the carotid tubercle.

5. The suprascapular nerve is a useful guide to the upper primary cord (formed by the junction of the fifth and sixth nerves).

6. In freeing the plexus posteriorly care must be taken not to injure the roots of the long thoracic nerve, as they pierce the scalenus medius.

7. The subclavian vessels and the pleura must not be injured in

exposing the lower primary cord (formed by the junction of the eighth cervical and the greater part of the first thoracic nerves).

8. When the cord formed by the fifth and sixth nerves is alone involved, exsection followed by end-to-end suturing may be accomplished if the plexus be freed well down behind the clavicle; the bone itself need not, as a rule, be divided.

9. When end-to-end suturing is not possible, the distal stump should be united to a notch made in the seventh nerve.

10. The distal stump of the suprascapular nerve should be sought for and, if possible, reunited to the plexus.

11. In fixing the dressing the bandage should be applied so as to approximate the head and shoulder on the affected side.

12. In shrapnel wounds of the neck the plexus may be extensively involved in scar tissue without being itself seriously damaged. Very satisfactory results may be obtained in such cases by freely dissecting away all cicatricial tissue.

Brachial Plexus: Infraclavicular Portion.—1. Injuries to this part of the plexus are usually the result of bullet wounds through the shoulder below the outer half of the clavicle. It is remarkable how often the axillary vessels escape.

2. To expose the plexus in the upper part of the axilla the incision is made from a little external to the middle of the clavicle downward into the axilla at right angles to its anterior fold.

3. Divide the pectoralis major and free the pectoralis minor.

4. It is generally necessary to divide the pectoralis minor, and, after examination of the lesion, it may be deemed advisable to divide the clavicle; for this purpose a short transverse incision should be made *above* that bone.

5. Instead of dividing the clavicle, it is sometimes sufficient to partly detach from it the adjacent origins of the pectoralis major and deltoid muscles.

6. Before attacking the nerves it is advisable, in the first place, to expose, free and retract inward the axillary vein. The accidental wounding of this vein high up in the axilla may complicate the rest of the operation.

7. Having thoroughly freed the vein, the cords of the plexus and its branches are systematically examined and the lesion dealt with according to its nature.

Nerves in the Lower Axilla and Upper Half of the Arm.—1. The exact incision will depend on the level of the lesion, and it may be necessary to divide some of the lower fibers of the pectoralis major muscle.

2. Remember that, with the limb abducted, the lower part of the axillary vein and the upper part of the brachial vein are encountered immediately beneath the deep fascia.

3. In exposing the nerves take the median as the guide. It can usually be palpated through the thin skin as a well-defined tense cord. Lateral to it is the musculocutaneous.

4. To expose the musculospiral nerve in the upper part of the upper

arm retract the median nerve along with the main vessels backward and medially and then dissect more deeply between them and the coracobrachialis muscle. The nerve rests on the insertion of the latis-

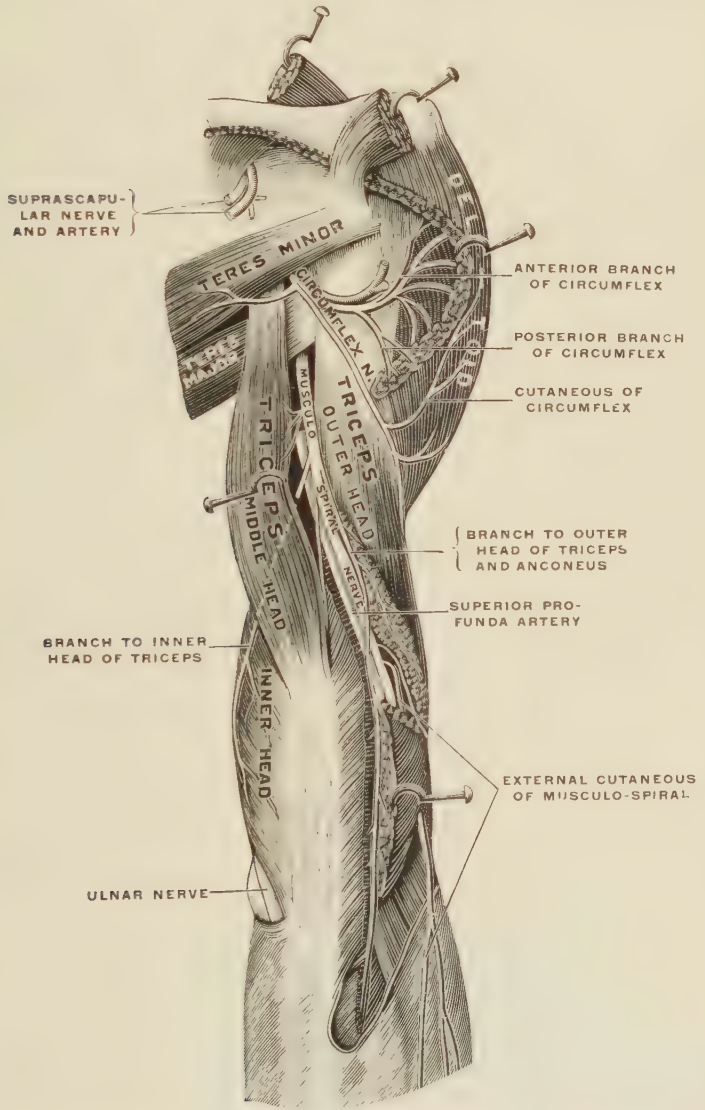

FIG. 954.—Musculospiral and circumflex nerves of right side. (Gerrish after Testut.)

simus dorsi; below this it may be followed into the upper part of the musculospiral groove, which it enters by passing lateral to the upper attenuated origin of the inner head of the triceps. By dividing this origin close to the bone, the nerve may be followed into the groove.

The superior profunda vessels and several branches of the musculospiral will be seen lying between the nerve itself and the median nerve and main vessels of the limb which have been retracted inward.

5. To expose the ulnar nerve the main vessels along with the median nerve are retracted forward and laterally; the nerve (ulnar) lies almost immediately behind and parallel to the basilic vein.

6. Combined lesions of the median and ulnar nerves are not infrequently met with in the upper arm, the result of a bullet traversing the limb from before backward.

Nerves in the Lower Half of the Upper Arm.—1. The median, except for an occasional anastomosis with the musculocutaneous, gives off no branches in the upper arm; hence end-to-end union may be effected after exsection of two inches of the nerve. In tracing the nerve distally it must be remembered that the branch to the pronator teres is given off at the level of the internal condyle.

2. When the ends cannot be approximated, nerve-grafting is preferable to either flap operation or nerve anastomosis. The internal cutaneous, before it divides, is a convenient nerve to use for the graft.

3. In the lower third of the upper arm the ulnar nerve lies a little behind the internal intermuscular septum. Not infrequently it is embedded in the substance of the inner head of the triceps, and in such cases the septum must not be mistaken for the nerve. Sometimes the nerve lies more in the substance of the septum.

4. In freeing the nerve, care should be taken to preserve the inferior profunda vessels which run along its sheath, and the slender branch of the musculospiral nerve which goes to the inner head of the triceps; this nerve lies just anterior to the ulnar between it and the intermuscular septum.

5. At the bend of the elbow the nerve is covered by a strong layer of fascia and, in freeing it, there is pretty free bleeding from the vascular anastomosis.

Ulnar and Median Nerves in the Forearm.—1. The ulnar in the upper half of the forearm lies deeply. There is no septum to serve as a guide to the nerve. The flexor carpi ulnaris muscle must, therefore, be split along the *line of the nerve*, which is from the back of the internal epicondyle to the outer side of the pisiform bone.

2. In freeing the nerve, its branches to the upper part of the flexor profundus and flexor carpi ulnaris muscles will be divided.

3. In the lower half of the forearm the mistake is often made of searching for the nerve beneath the tendon of the flexor carpi ulnaris, instead of directing the knife toward the medial border of the flexor sublimis digitorum, to which it is bound down by a thin layer of fascia. It will be observed that the nerve is very closely related to the ulnar artery and its venæ comites. In exposing the nerve, its dorsal cutaneous branch should be preserved if possible.

4. In dealing with the lesions of the ulnar nerve we must keep before us the fact that it is the main source of supply to the intrinsic muscles of the hand, and that after resecting a portion of the nerve, every

endeavor must be made to obtain an end-to-end approximation of the stumps. That is the principle I have gone upon in dealing with all nerve exsections, because it has always seemed to me that direct end-to-end approximation is much more likely to restore function than nerve-grafting, nerve-anastomosis, or a flap operation.

5. Fortunately the stumps of the ulnar can be approximated after exsection of a larger segment than is the case with the median, the reason being that, while the median takes the shortest possible route from its origin to its termination, the ulnar has two angular bends upon it—a lesser one at the middle of the upper arm, where it pierces the internal intermuscular septum, and a more pronounced one where it winds over the back of the internal epicondyle. By transposing the nerve so as to do away with these bends, while at the same time placing the nerve parallel to the median beneath the mass of muscles arising from the internal condyle and putting the limb up with the elbow flexed, a direct end-to-end union of the stumps may be obtained after resection of as much as three inches of the nerve. By transposing the nerve in this way, we sacrifice the branches which go to the flexor carpi ulnaris and the inner half of the flexor profundus muscles. This, however, is a comparatively small price to pay for restoring the function of the intrinsic muscles of the hand.

6. After resecting say two inches of the ulnar in the upper arm, the distal portion of the nerve is freed down to about the middle of the forearm. The skin and subcutaneous tissue are now reflected off the inner side of the front of the elbow so as to expose the outer border of the pronator radii teres, which is then freed by dividing the general envelope of deep fascia, after which a tunnel is made beneath it, and all the flexor muscles arising from the internal condyle, except the flexor carpi ulnaris. A pair of dressing forceps is then passed from above downward beneath the muscles, the stump of the distal portion of the nerve is seized and pulled upward through the tunnel, and thence into the upper arm, where the ends are sutured. Here there is a little point in the technic which is worthy of mention, namely, that the bulbous ends of the nerve should not be completely removed before this is done, otherwise, in grasping the stump, nerve fibers are liable to be bruised at the point of suture.

7. If a portion of the ulnar nerve is resected anywhere at or below the middle of the forearm, the nerve on the proximal side of the lesion is freed from below upward so far as, or even higher than, the middle of the upper arm, so as to straighten out the first kink. The proximal portion is then pulled from above downward through the tunnel made beneath the muscles already mentioned.

8. If, on the other hand, the resected portion of the nerve is opposite the elbow, the muscles arising from the internal condyle are divided obliquely from above downward and inward; the sutured portion of the nerve is then dropped into the floor of the gutter and the divided muscles resutured over it.

9. Injuries to the median nerve in the upper part of the forearm

may be too extensive to admit of end-to-end union of the stumps. In such cases tendon transplantation must be resorted to with the object

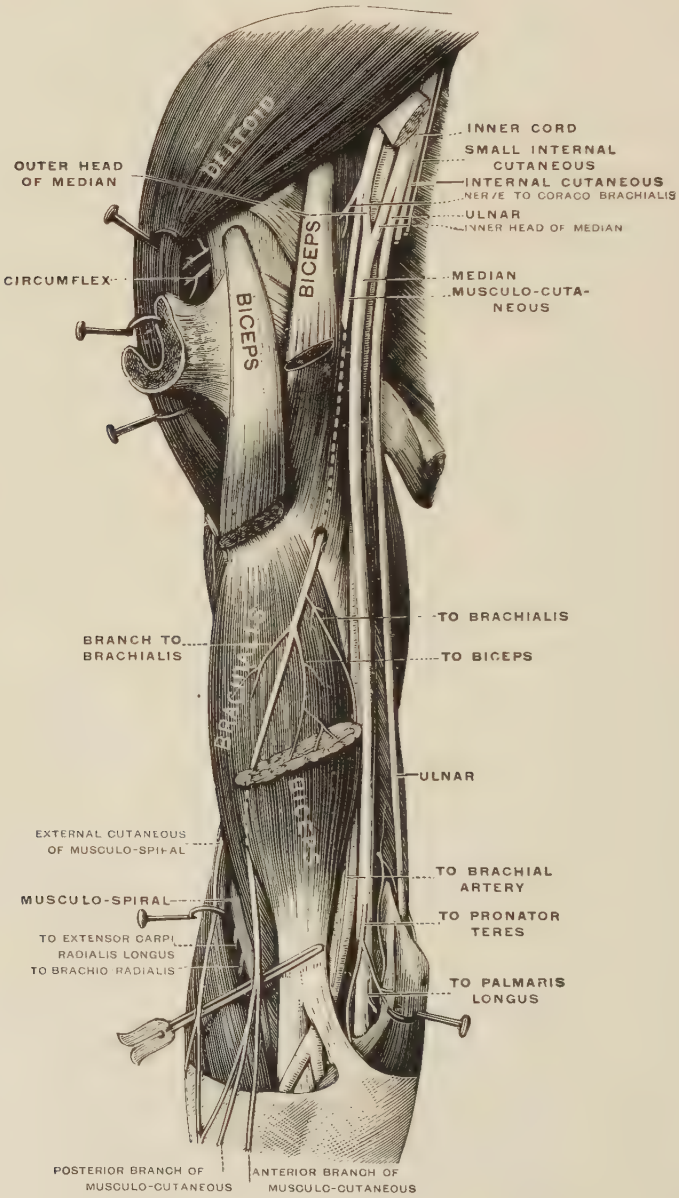

FIG. 955.—Deep nerves of the front of the right arm. (Gerrish after Testut.)

of obtaining flexion of the thumb and of the two outer fingers. The extensor carpi radialis longior is divided at its insertion and planted

into the flexor longus pollicis; the two outer tendons of the flexor profundus digitorum are divided a little above the wrist and sutured to its

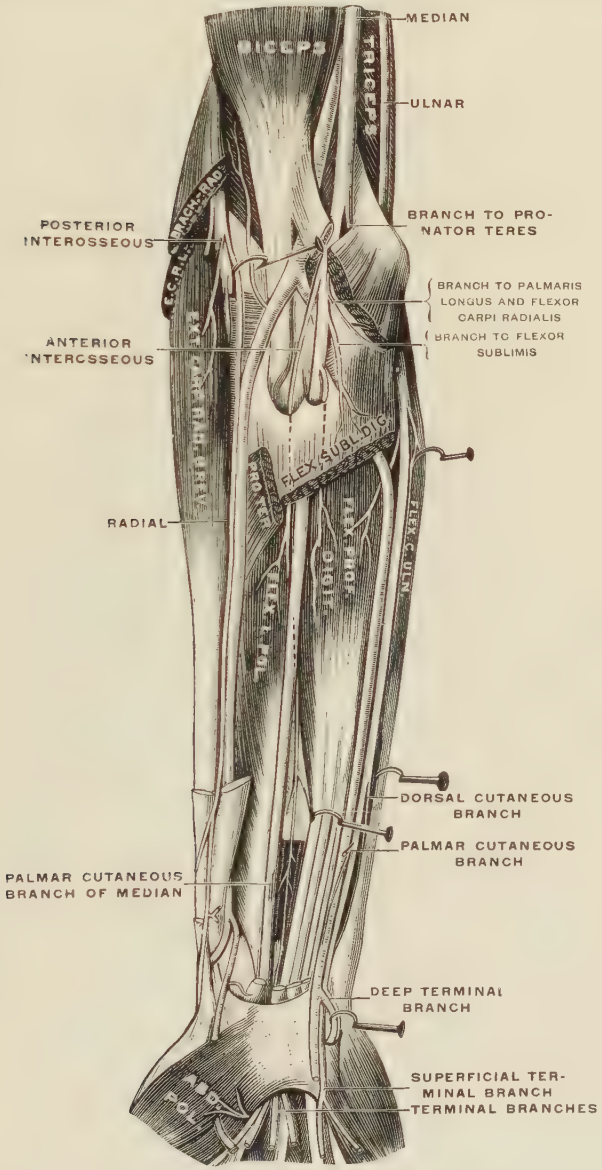

FIG. 956.—Deep nerves of the front of the right forearm. (Gerrish after Testut.)

two inner tendons. The flexor carpi ulnaris is divided close to the pisiform bone and united to the tendons of the flexor sublimis digitorum.

10. Extensive injuries of the median nerve in the middle of the forearm presents a difficult problem, because extensive freeing of the nerve on the proximal side of the lesion entails the division of its motor

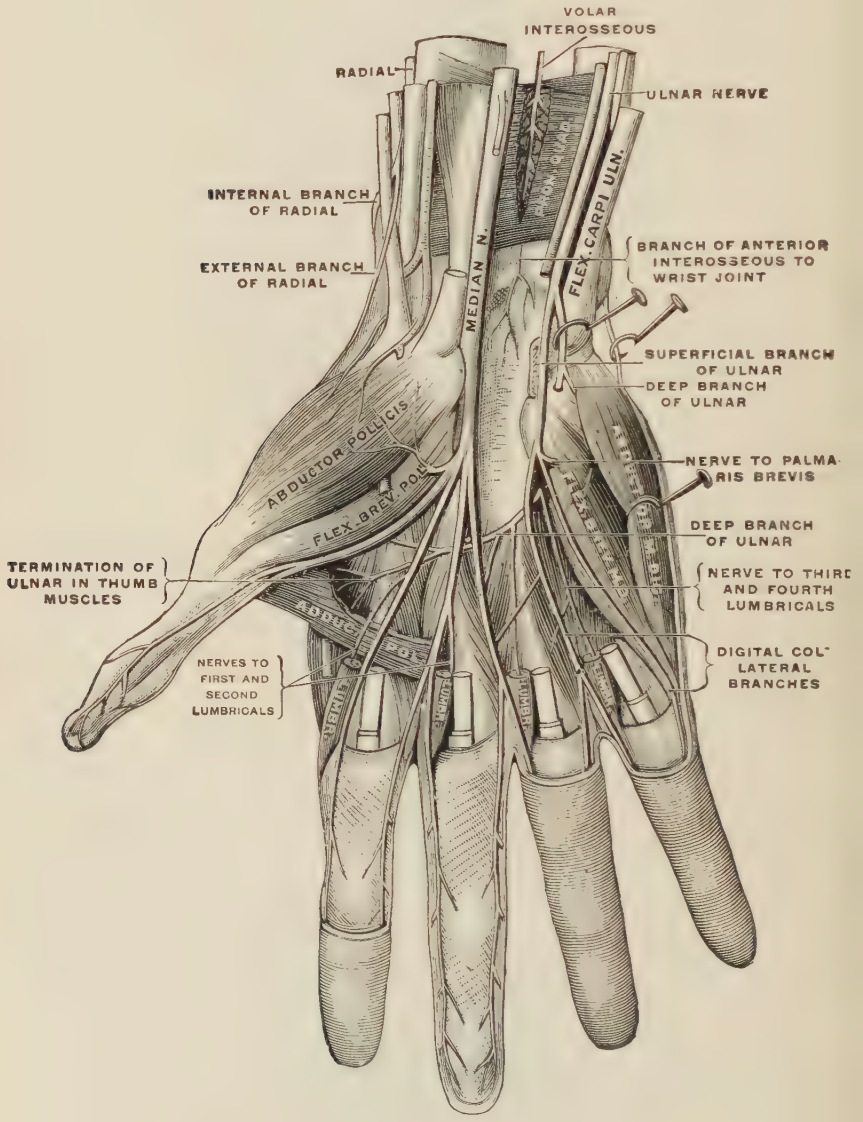

FIG. 957.—Deep palmar nerves. (Gerrish after Testut.)

branches to the long flexor of the thumb, to the whole of the flexor sublimis digitorum and to the most important part of the flexor profundus. As a rule, therefore, no attempt should be made to unite the stumps if

MEDICAL LIBRARY
OF THE
BOSTON CITY HOSPITAL

it is evident that by so doing paralysis of the above-mentioned muscles will result.

11. The median nerve in the lower half of the forearm may be approached by one of two routes, and the choice will depend very much

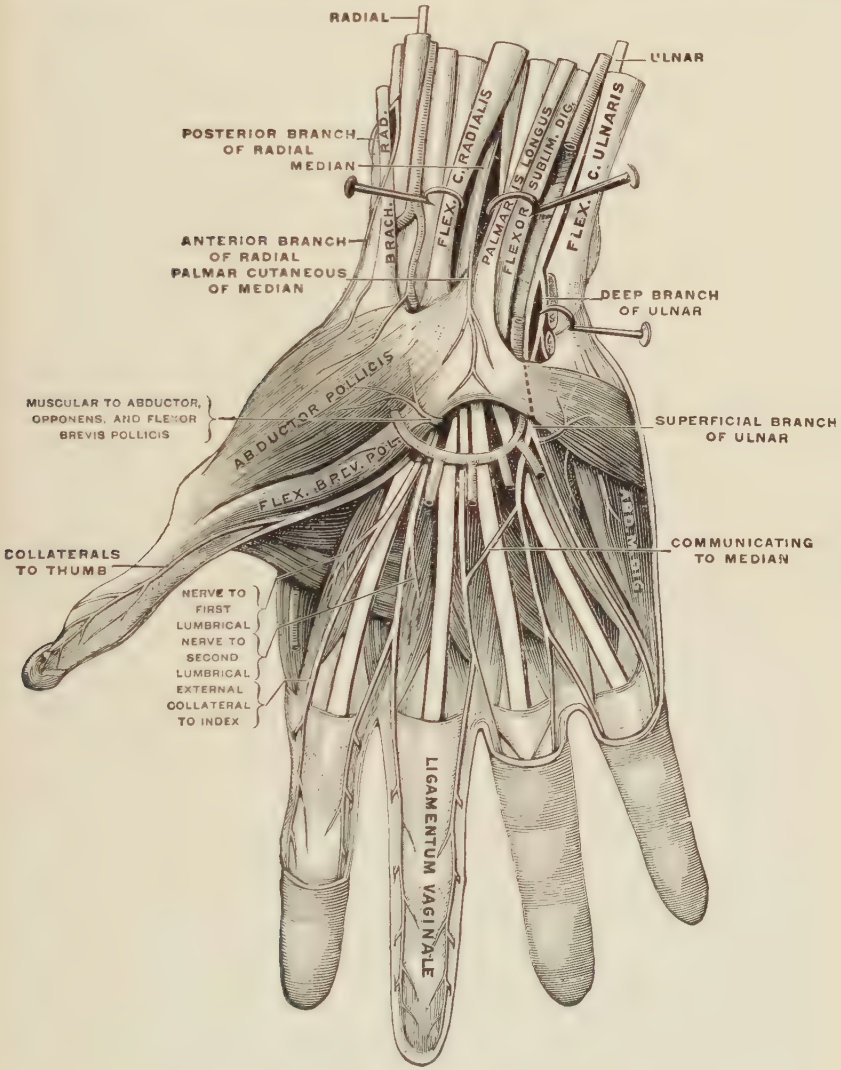

FIG. 958.—Superficial palmar nerves. (Gerrish after Testut.)

on the position of the scar of the original wound. The direct method is to make an incision parallel and a little external to the tendon of the flexor carpi radialis and then to divide the fibers of the flexor sublimis digitorum. The nerve clings to the deep surface of this muscle. The

other method is to make the incision along the ulnar border of the flexor sublimis digitorum, the muscle itself being retracted, and at the same time rotated outward so as to expose its deep surface. In this method of approach care must be taken to avoid injuring the ulnar vessels and nerve.

12. When both the median and the ulnar nerves have been too extensively injured in the lower part of the forearm to admit of end-to-end suturing, *all* the intrinsic muscles of the hand are paralyzed. If the long flexor of the thumb and the flexor of the index-finger are acting. the patient is, nevertheless, unable to oppose and adduct the thumb, To enable him to do so, Captain W. I. Baldwin removes the cartilages of the carpometacarpal joint of the thumb and anchyloses it to the carpus with the metacarpal bone brought forward and inward as well as rotated inward. By contracting the long flexor of the thumb and the flexors of the index-finger these two digits can be brought into apposition. Captain Baldwin is of opinion that even when the ulnar nerve is *not* involved the same operation is still advantageous, as it adds to the usefulness of the thumb by compensating for the paralysis of its abductor and opponens muscles.

13. With regard to extensive injuries of the median and ulnar nerves in the forearm, it is hardly necessary to point out that such lesions are often combined with more or less destruction of muscles and tendons, resulting in the formation of firm adhesions, dense cicatricial tissue, and frequently, also, aggravated digital contractures. In such cases it is important to make free dissections so as to remove all the cicatricial tissue which is interfering with the action of the muscles; and it will often be found necessary to follow this up by various reparative procedures, including tendon lengthening and tendon transplantations, all planned with the object of restoring, so far as possible, the function of the muscles. From what I have observed, it would appear that many of this kind have been "turned down," which could be greatly benefited by such operative procedures.

14. If the contraction of the digits is the result of nerve injury pure and simple a determined attempt should, of course, be made to straighten the fingers before operating on the nerve; but, should the contracture resist the treatment or should it recur, the nerve should be explored, as one not infrequently finds that the contracture is brought about reflexly by a partial or irritative nerve lesion. In some cases the contracture of the digits is merely an adaptive shortening of the muscles, resulting from persistence of the flexed position in which the patient held the fingers immediately after the injury. This form of contracture is more easily overcome.

Musculospiral Nerve in the Lower Half of the Upper Arm.—1. This nerve should first be explored, as it pierces the external intermuscular septum. Its two dorsal cutaneous branches to the forearm, along with the branch to the superior profunda artery, serve as useful guides to the nerve. To follow the nerve proximal to the above point, fibers of the triceps muscle must be divided, and care should be taken to pre-

serve, as far as possible, the motor branches of that muscle. Below, where the nerve pierces the septum, one must be on the lookout for the branches to the brachialis anticus, the supinator longus, and the extensor carpi radialis longior muscles.

2. Experience has shown that the ultimate results are much better after suture of the musculospiral than after suture of the median or ulnar nerves. This, according to Babinski, is because we are in the habit of measuring the degree of recovery in terms of motion, so that, according to this estimate, the recovery is in proportion to the preponderance of the motor over the sensory fibers. This explanation seems to have a very sound anatomical as well as physiological basis. Granted, then, that the prognosis after suture of the musculospiral nerve is very favorable, it must at the same time be remembered that, owing to the close relation of this nerve to the humerus, it is often so extensively injured that an end-to-end suture is impossible. Fortunately, however, it is just in cases of this kind that tendon transplantation gives such excellent results. Jones's procedure is to transplant: (1) the pronator radii teres muscle into the extensor carpi radialis longior and brevior muscles, (2) the flexor carpi ulnaris into the tendons of the three inner fingers, and (3) the flexor carpi radialis into those of the thumb and index finger.

3. An alternative plan, provided the palmaris longus be present, is: (1) to transplant it into the extensor ossis metacarpi pollicis and the extensor brevis pollicis muscles; (2) to insert the flexor carpi radialis into the long extensors, including that of the thumb, and (3) to transplant the pronator radii teres into the two radial extensors of the wrist, as above mentioned.

4. While time does not permit me to describe the details of these operations, I should like to emphasize the fact that the results are most satisfactory, especially if the after-treatment is carefully carried out and if the patient is encouraged in the coördination and reëducation of the transplanted muscles. It will be found that patients after this operation have a firm grip, that they can completely extend the fingers and thumb, and that they can learn to write without difficulty.

I have time only for a very few words with reference to injuries to nerves of the lower extremities.

Great Sciatic and Popliteal Nerves.—1. To expose the gluteal portion of the great sciatic nerve a T-shaped incision should be made, the upper limb parallel to the fibers of the gluteus maximus muscle, the lower limb vertically downward over the line of the nerve. By this means good access is obtained, and the nerve may be followed well up into the great sciatic notch, after freeing and retracting upward the pyriformis muscle. In one patient who had a permanent limitation of movement at the knee, I was obliged to remove so much of the gluteal portion of the nerve that it became necessary to remove a portion of the femur before the nerve stumps could be brought together. Sir Robert Jones, who was present at the operation, advised the removal of a good large wedge just below the great trochanter in order that, by obtaining union

in the abducted position, the shortening would be compensated for. The femur has united, but sufficient time has not elapsed since the operation to enable me to speak of the ultimate result.

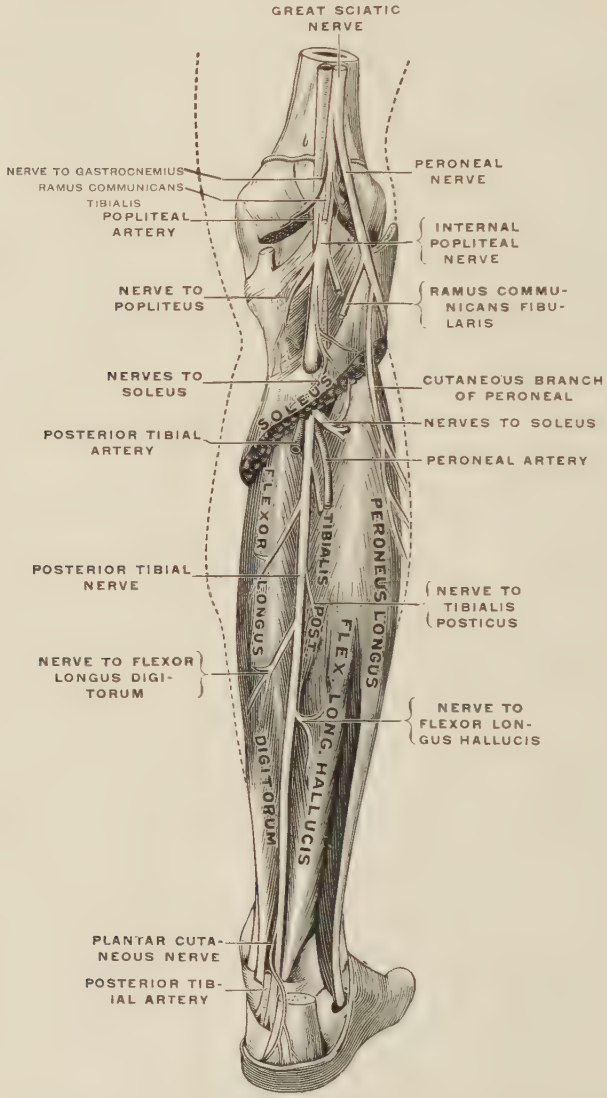

FIG. 959.—Deep nerves of the back of the leg. (Gerrish after Testut.)

2. To expose the nerve at the junction of the thigh and buttock, the *outer* border of the long head of the biceps is first exposed and the

muscle is then retracted *inward*. To reach the nerve in the middle of the thigh, this muscle is retracted *outward* after freeing the *inner* border. The nerve is here overlapped by the large fleshy belly of the semimembranosus muscle.

3. It not infrequently happens that only about half of the sciatic nerve has been badly injured. When this is the case, the damaged portion having been exsected, the main trunk should be split upward and downward sufficiently to allow the stumps of the injured half to be sutured without tension. When the uninjured half—which has been left intact—has been dropped back into its bed, it will be found to be loose and tortuous. The large size of the nerve lends itself admirably to this method of treatment, the advantages of which are obvious.

4. Internal popliteal lesions are less frequently met with than external popliteal lesions, partly because the internal nerve is less exposed, and partly because an injury to it is more likely to be combined with injury also to the popliteal vessels, with the result that the condition is either fatal or calls for amputation. In the case in which a false aneurysm is produced, it is wonderful how often the internal popliteal nerve is merely stretched and pushed aside. The pain, however, is generally very severe, but it subsides rapidly after the aneurysm has been dealt with.

5. Injuries of the *upper* part of the external popliteal nerve can generally be dealt with satisfactorily by adopting the principle already referred to in speaking of the sciatic nerve, namely, to follow the external popliteal up to the sciatic trunk and then to split the latter into its two divisions as high up as necessary.

6. Lesions of the external popliteal low down and of its subdivisions are, for anatomical reasons, often impossible to repair. In these circumstances the patient will require guidance as to whether he should be content with a drop-foot boot or whether he should have an operation done which will maintain the foot at right angles without artificial aid.

The results of operative treatment under favorable conditions (according to the Report of the Twenty-seventh French Congress of Surgeons) are very satisfactory:

Of 338 cases reported by Delagnière, 236 were of resection, with 88 per cent. of success; 113 were of neurolysis or nerve liberation, with good results only in cases of actual compression. Of 9 cases of nerve grafting only one-third were successful. Wiart has reported 86 cases of operation on the musculospiral nerve, most of which were of long-standing, complicated by previous suppuration. Of 25 resections success was obtained in 20 per cent. and improvement in an equal number. In 31 cases neurolysis was performed; 33 per cent. of these were successful and 25 per cent. were improved.

According to Platt and Bristow,[1] the end-results after complete

[1] Brit. Jour. Surg., January, 1924.

division and end-to-end suturing are usually imperfect, and in 20 per cent. failure is complete. The prognosis is most favorable for the musculospiral nerve. In 50 per cent. of the cases complete function is restored. The results are most unsatisfactory for the ulnar and median. Complete recovery of power in the intrinsic muscles of the hand never occurs. The prognosis is also poor for operation on the sciatic nerve.

TRICK MOVEMENTS.

Under this title, Wood Jones has called attention to the fact that it is sometimes possible for patients to carry out movements that might be mistaken for evidence of restoration of normal power. Thus, after complete division of the median and ulnar nerves the wrist may be flexed by the action of the extensor ossis metacarpi pollicis. After complete division of the musculospiral in the axilla the elbow may be flexed by the pronator radii teres and flexors of the fingers. After complete division of the median and ulnar nerves the fingers may be flexed by dorsiflexion of the wrist, thus bringing tension on the paralyzed flexor tendons. After complete division of the median nerve the thumb may be adducted by action of the extensor ossis metacarpi pollicis, supplied by the musculospiral and adductor pollicis supplied by the ulnar.

TENDON TRANSPLANTATION FOR PARALYSIS OF THE MEDIAN NERVE.

In cases of irreparable injury to the median nerve, tendon transplantation for the purpose of obtaining flexion of the thumb and two outer fingers may be indicated.

The extensor carpi radialis, an extensor of the wrist, is divided at its insertion at the back of the base of the first metacarpal bone and is attached to the tendon of the flexor longus hallucis, the flexor of the last phalanx of the thumb. The two outer tendons of the flexor profundus digitorum, the flexors of the distal phalanges are divided just above the wrist and are sutured to the two inner tendons, supplied by the ulnar nerve. The flexor carpi ulnaris is then divided at its insertion to the pisiform bone and is sutured to the tendons of the flexor sublimis digitorum, the flexor of the second phalanges supplied entirely by the median nerve.

Tendon transplantation for irremediable paralysis of the musculospiral nerve.

Transplant the pronator radii teres from its insertion at the middle of the outer surface of the radius to the extensor carpi radialis longior and brevior muscles, which are inserted at the bases of the first, second and metacarpal bones.

Transplant the tendon of the flexor carpi ulnaris from its insertion at the pisiform bone into the extensor tendons of the three smaller fingers, and the flexor carpi radialis into those of the thumb and first fingers.

An alternative plan is to transplant the palmar longus to the extensor ossis metacarpi pollicis, the abductor of the thumb, and to the extensor brevis pollicis.

Insert the flexor carpi radialis into the long extensors of the fingers and thumb and the pronator radii teres into the two radial extensors of the wrist as described above.

Naughton Dunn[1] describes the details of the operations as follows:

1. Incision about 8 inches in length following a line from the external condyle to the styloid process. This overlies the septum between the radial extensors and the extensor communis digitorum over middle of the radius. Free completely the insertion of the pronator radii teres. When these are separated the oblique insertion of the pronator radii teres is exposed.

2. Incision on the front of the wrist on the radial side and divide the tendons of the flexor carpi radialis and palmaris longus as low as possible.

3. Incision middle of front of forearm. Pull the tendons of the flexor carpi radialis and palmaris longus through this.

4. U-shaped incision, base upward over dorsum of wrist exposing all the extensor tendons.

5. Make a tunnel from 3 through the subcutaneous tissue to the radial side of the dorsum of the wrist.

6. Make an incision 3 inches long on flexor aspect of the wrist, over the flexor carpi ulnaris. Divide it at its insertion and pass it to the ulnar side of the dorsum of the wrist.



FIG. 960.—Superficial muscles of front of right forearm. (Gerrish after Testut.)

7. Suture incisions, 1, 2, 3 and 6.

8. Embed the pronator radii teres in the tendinous portion of the radial extensor and suture with thirty-day chromicized catgut.

[1] Am. Jour. Orthop. Surg., April, 1918.



FIG. 961.—Muscles in radial region of right forearm, and deep muscles in its dorsum. (Gerrish after Testut.)

9. Pass the flexor carpi radialis obliquely through the extensor ossis metacarpi pollicis and extensor brevis pollicis, and embed it in the common extensor of the fingers.

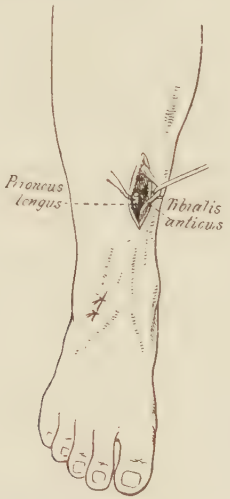

FIG. 962.—Tendon of tibialis anticus being drawn taut, the foot being kept at right angles; tendon is then cut and passed through a tunnel in the tibia. The tendon of the peroneus longus is shown drawn up through the same opening. (Jones.)

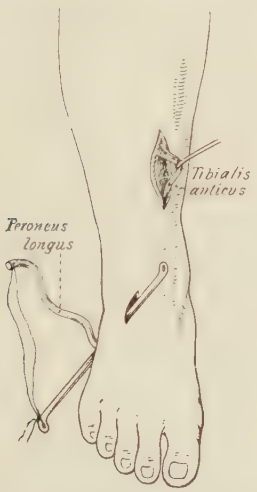

FIG. 963.—Tendon of peroneus longus about to be drawn through the incision opposite the annular ligament under which it has to pass. (Jones.)

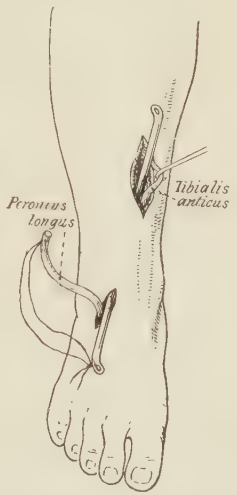

FIG. 964.—Tendon of peroneus longus about to be drawn under the annular ligament to be inserted in the tibia. (Jones.)

10. Embed the palmaris longus in the extensor longus pollicis.
11. Embed the flexor carpi ulnaris in the extensor carpi ulnaris.
12. Close the wound.

In suturing the tendons dorsiflexion of the wrist, extension of the fingers and abduction of the thumb should be maintained, and at the completion of the operation the tension should be sufficient as to almost maintain them in the required position without support. The corrected position should be assured by a splint for three months, but electrical stimulation of the muscles by a mild faradic current should be begun at the end of three weeks.

In some instances of more general paralysis from irremediable injury of the median and ulnar nerves the patient may retain the power to flex the thumb and index finger, and yet be unable to appose them. To restore this power, Baldwin removes the cartilage from the carpometacarpal joint of the thumb and induces anchylosis with the metacarpal bone, forward, inward and rotated inward, so that the flexors of the thumb and finger may appose them.

The operations to increase the stability of the lower extremity after paralysis have been described at length in Chapters XVII and XXIII.

For complete paralysis below the knee or for paralysis of the calf muscle, astragalectomy and backward displacement of the foot is the most effective procedure. For paralysis of the anterior muscles, Jones advises implantation of the tendons of the tibialis anticus and of the peroneus longus in the tibia. The peroneus longus is divided above the ankle, drawn forward through an opening in the skin on the outer border of the foot, then passed upward, over or under the anterior ligament and is inserted with the tibialis anticus in a hole bored in the crest of the tibia, at a tension sufficient to hold the foot in the desired position. The immediate effect of such operations is often more satisfactory than the final result.

ATTITUDES OF ELECTION.

Deformity is an almost inevitable result of the more severe types of disease that directly or indirectly involve the locomotor apparatus, the more constant factors in its causation being the force of gravity, muscular contraction and the postures assumed in accommodation to weakness and discomfort.

There is a standard position for each joint which best adapts the limb for functional usefulness when motion is lost or seriously impaired. This attitude should be assured as long as the tendency to deformity persists and it should be restored as soon as possible if it has been lost.

At the shoulder the position of election is 50 to 60 degrees of abduction with slight forward flexion of the arm. If, as is in untreated cases, the limb is apposed to the side of the trunk, the patient is obliged to raise the shoulder when attempting a lateral movement, but if it is fixed in abduction the muscles attached to the scapula assure a controlled range of motion in the secondary joint between it and the thorax.

At the elbow the forearm should be flexed nearly to a right angle and about three-fourths supinated.

The wrist should always be supported in dorsiflexion, as only in this attitude is the grasp of the hand effective.

At the hip the position of election is abduction of about 15 degrees, full extension, and slight outward rotation.

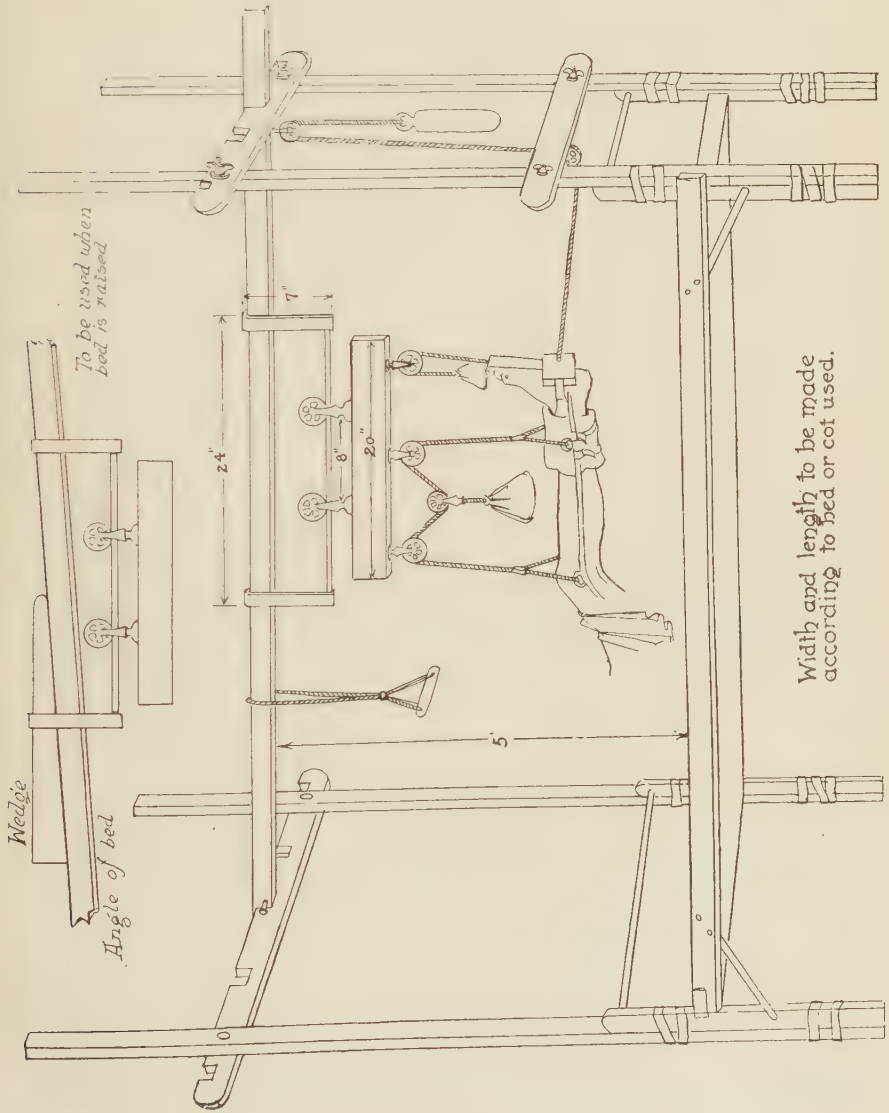

FIG. 965.—Portable suspension frame. (Lyle.)

At the knee full extension.

At the ankle the foot should be supported at a right angle to the leg and slightly inverted, in order that weight may be supported directly on the heel and upon the outer or strong side of the foot.

It is often stated that a position of moderate flexion both at the hip and knee is more useful than complete extension. Admitting that this

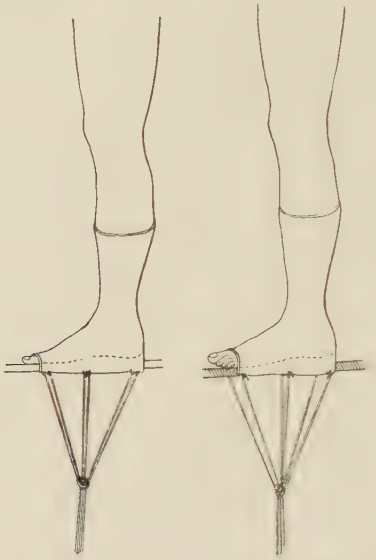

FIG. 966.—Stocking extension. An excellent traction may be obtained by a lightweight army sock. The lower leg, ankle, and foot, with the exception of the toes and the plantar surface, are painted with glue (Sinclair's adhesive: glue, 50 parts; water, 50 parts; glycerin, 2 parts; calcium chloride, 2 parts; thymol, 1 part) and the sock slipped on. The toe of the sock is cut off and a piece of light splint wood or the ladder splint material, cut the length of the foot, is inserted between the sole and the sock. Traction may then be made on this by means of pieces of bandage or cord passed through the sock and around the wood or the rods of the ladder splinting.[1]

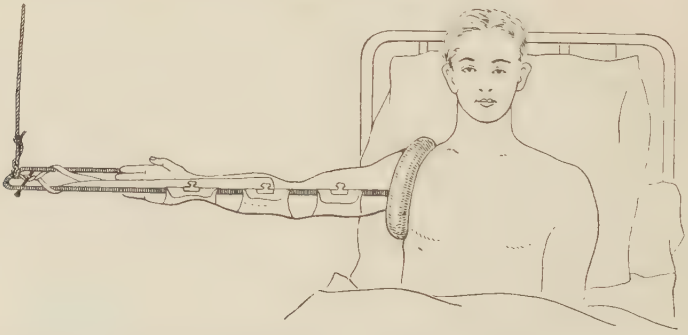

FIG. 967.—The Thomas brace used in suspension when the shoulder is so injured as to make the application of the extension arm splint impossible or undesirable. The regular Thomas knee splint may be applied over the uninjured shoulder (for shoulder and arm injuries).

is a debatable point, one would still support these joints in extension during treatment because bony anchylosis is unusual, and in stiffened

[1] Figs. 966 to 970 are from the Manual of Military Orthopaedic Surgery.

joints there is a strong tendency toward flexion after the subsidence of the disease, one of the factors being the sitting position.

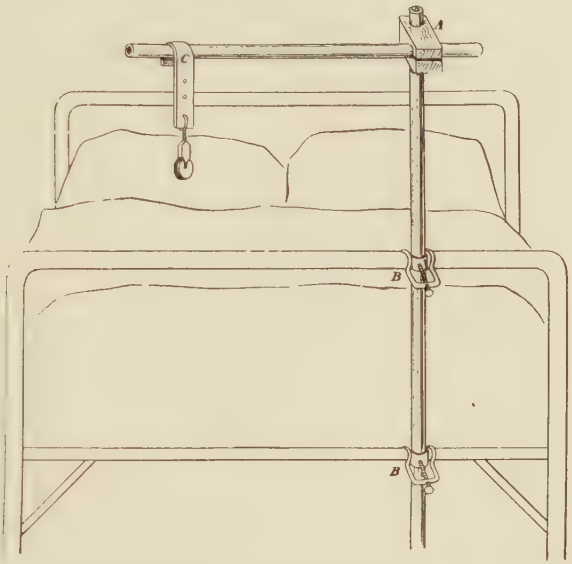

FIG. 968.—A traction attachment made from the Maddox unit clamps and iron pipe.

These positions of election may be assured in most instances by efficient splinting, but if muscular spasm is extreme, as in cases of joint disease of the lower extremity, continuous and sufficient traction in addition to the direct support is often required.

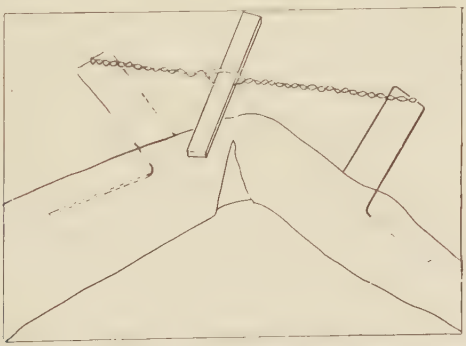

FIG. 969.—Method for correcting joint deformity by means of plaster dressing and improvised loops of heavy wire. (Freiberg.)

Fixation of a joint whose surfaces are involved in active disease is indicated to relieve the friction and pressure that increase its destructive effects. In such cases movement favors eventual anchylosis, while

fixation may preserve a certain range of motion, as is often observed in the final results of tuberculous disease.

Fixation of a normal joint induces degenerative changes in the synovial membrane, restriction of the area of articular cartilage, atrophy of the ligaments, muscles and bones. This degeneration and consequent restriction of motion are proportionate to the duration and

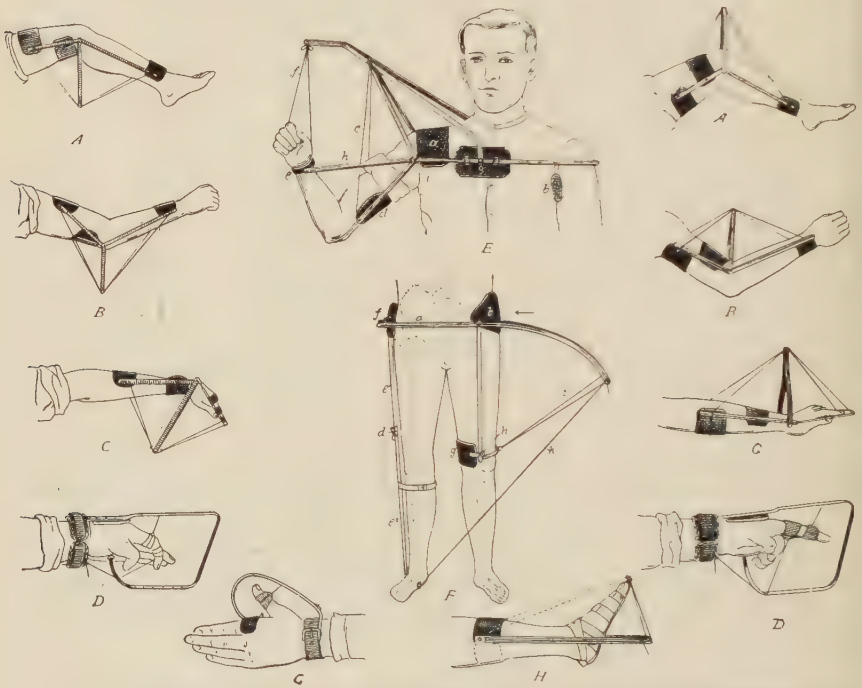

FIG. 970.—Schede splints for the after-treatment of injuries in the neighborhood of joints. By simply changing the position of the intermediate bar the splints can be used to produce either extension or flexion. The traction is exerted by means of a stout cord which the patient himself easily learns to adjust. (Mayer.)

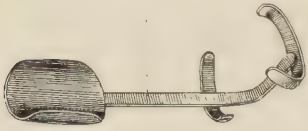

FIG. 971.—A simple brace to support the hand in dorsal flexion. (Jones.)

FIG. 972.—The support applied.[1]

degree of inactivity, modified somewhat by the quality of the individual. When function is resumed, regeneration proceeds rapidly in some and more slowly in other patients. Persistent stiffness is favored by age, by the so-called rheumatic tendency and by personal predisposition. Of this the stiff knee after the treatment of fracture at the hip and the stiff fingers after Colles's fracture are familiar examples.

[1] Figs. 973 to 981 are from the Manual of Military Orthopaedic Surgery.

It is often necessary to restrain movements in other joints in order to splint effectively that disabled by injury or disease. This restraint should not be prolonged, especially in the type of cases in which stiffness is to be feared. Thus, for example, in Colles's fracture the fingers should be exercised at regular intervals; so also in the treatment of paralysis, due to injury of the nerves, care should be taken to move the joints at intervals to prevent stiffness due to accommodation to a fixed position.

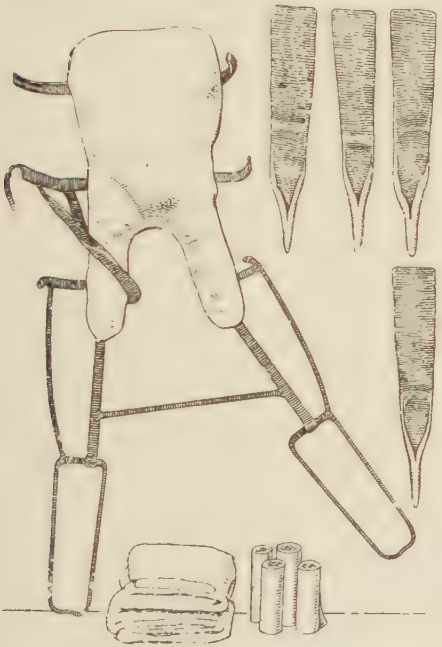

FIG. 973.—The Thomas-Jones abduction hip splint frame, showing the traction straps and bandages and the thick cushion on which the patient lies. The abduction treatment of fracture of the neck of the femur may be applied by this apparatus.

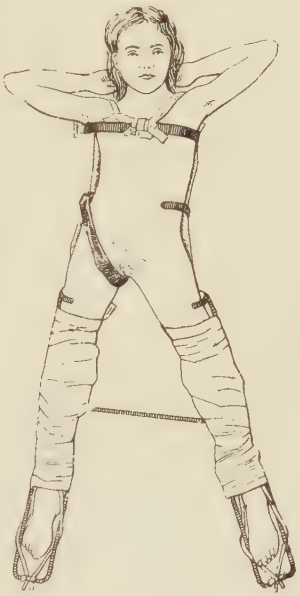

FIG. 974.—The frame applied.

Prolonged and complete fixation after injury, particularly when blood is effused within a joint, should be avoided. In cases of this type, massage should be employed from the first, together with both active and passive movements, carefully regulated by the tolerance of the individual and by the local effects.

In the treatment of the milder forms of joint infection, early regulated movement is usually desirable. In this connection attention may be called to a recent demonstration that the synovial membrane has a very decided power of resistance to infection, its secretion usually remaining sterile for twenty-four hours after penetration by an infected foreign body.

For bullet wounds of the knee and other injuries of a like character

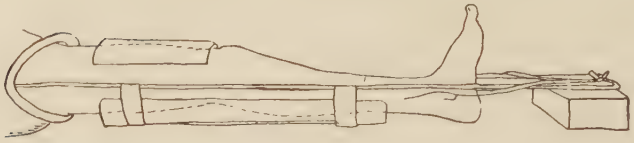

Fig. 975.—Diagram showing Thomas' knee-splint as used for fractures of the femur below the small trochanter, about the knee or upper part of the leg. Arthritis of knee, compound fracture of patella, etc. The gutter-splint behind is slung from the side bars. To avoid confusion, only the lower end of the extension plaster is shown; also all bandages and padding are omitted. The anterior splint is such as would be used for fracture of the shaft of the femur. The blocks supporting the end of the splint keep the heel off the bed and protects the heel.



Fig. 976.—The Thomas caliper knee brace.

Fig. 977.—Caliper leg brace for lateral deformity of foot.

Fig. 978.—The shoe and strap.

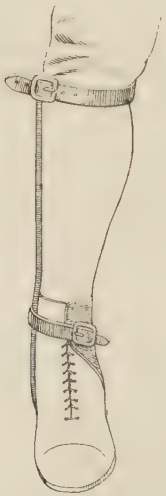

Fig. 979.—Caliper foot brace for lateral deformity applied.

Fig. 980.—Rectangular foot splint.

MEDICAL LIBRARY
OF THE
BOSTON CITY

the most approved treatment is to expose the joint completely, usually by a U-shaped incision about the patella, dividing its tendon.

The blood clots are washed away with ether, the foreign body together with loose fragments of bone or cartilage are removed, and cavities in the bone thoroughly curetted. The margins of the wounds in the synovial membranes of entrance and exit of the bullet are excised and sutured. Injured and infected tissue is cut away from the superficial wounds, the openings are closed without drainage, and a splint is applied. Early active and passive motion within the limit of pain is encouraged.

A series of cases reported by Depage[1] illustrate the comparative results of treatment:

	Mortality, per cent.	Suppuration, per cent.	Motion retained, per cent.
The first by irrigation and drainage	13	68	24
The second by the Carrel system	0	28	46
The third by the method described	0	4	86

If preventive treatment has been ineffective and deformity is present, it must be overcome, as a preliminary measure, by methods adapted to its character, as described elsewhere.

As a rule, immediate correction under anesthesia in suitable cases is the method of choice. It must be employed with caution in cases of long standing, in which the bones are atrophied, in order to avoid fracture. In such instances preliminary division of contracted parts and correction in two or more sittings may be advisable.

Gradual correction and fixation are often effective—a metal splint is adjusted to the deformity and is straightened slightly at intervals. This is the method of choice for deformities of the smaller joints, as illustrated by Jones's treatment of ischemic contraction, page 551.

The same principle may be utilized by applying a circular plaster splint to the limb, cutting it through on the flexed side and straightening it gradually by the insertion of wedges. A thick pad of felt should be placed over the patella and thigh where the pressure is concentrated. This method may be most efficiently applied by the Billroth splint, Fig. 394 (also Fig. 968).

Elastic tension is often effective if the coöperation of the patient in the adjustment of the apparatus is available. The principle is illustrated by the appliances of Schede (Fig. 969).

Operations on deformed limbs complicated by stiffened and disabled joints are performed primarily to restore symmetry, and particularly the attitude best adapted for function. When restriction of motion, due to adhesions within and contractions without the joint, is overcome a serviceable range of motion is often restored.

Operations for the restoration of motion in actually anchylosed and painless joints are rarely indicated in the lower extremity, because weight-bearing is far more important than motion.

[1] Judd: Surg., Gynec. and Obst., February, 1918.

At the ankle-joint when fixation is accompanied by deformity, or if weight-bearing causes discomfort, the removal of the astragalus may restore motion as well as symmetry. If both hip-joints are fixed, and especially if the limbs are distorted, an operation for the restoration of motion in one is indicated. At the knee-joint motion is usually attained at the expense of comfort and security.

In the upper extremity the conditions are different because the joints are not subjected to the strain of weight-bearing. Operations are, however, rarely indicated at the shoulder-joint because of the mobility of the scapula.

At the wrist-joint the operation would be indicated for complete anchylosis attended by deformity, because one might hope by a removal of one of the rows of carpal bones to restore a certain range of mobility as well as the proper attitude.

The operation is most often indicated at the elbow-joint because even limited motion about the attitude of election is of service. (See Arthroplasty.

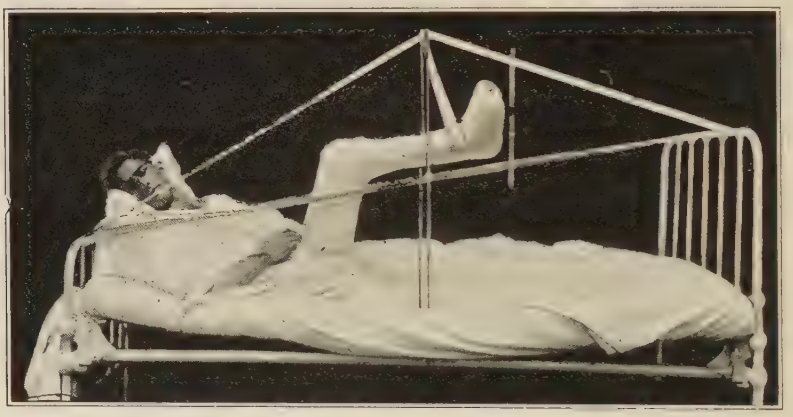

FIG. 981.—The Thomas knee brace utilized as a support for suspension. The astragalus has been removed for tuberculosis of the ankle.

RECONSTRUCTIVE TREATMENT.

It is self-evident that the basis of reconstruction is efficient treatment of the primary injury, disease or disability. The term is here restricted to the final adaptation of the disabled member to the function for which it may be capable.

This introduces the subject of effective after-treatment by what is called physiotherapy. The treatment of disabled soldiers and the rapidly enlarging field of industrial surgery have brought this subject into such prominence in recent years that a complete physiotherapeutic department in charge of a competent director may be considered an essential part of the equipment of a modern hospital. For even apart from its direct physical influence this treatment has the great advan-

tage of retaining the patient under observation and control during the critical period of convalescence.

The primary purpose of physiotherapy is to restore circulation, and thus to hasten the absorption of effused products, the result of injury or disease, to build up atrophied structures and to restore motion in stiffened joints.

The following description of the physical characteristics and action of the various agents employed is extracted in great part from a paper by Kovacs.[1]

Thermic Agents.—Radiant Light and Heat.—The action of the ordinary radiant light and heat from incandescent bulbs of varying candle power is based on the combined action of heat, light and chemical rays. It causes vasodilatation, free perspiration and increased local metabolic changes in the superficial tissues. It is indicated in all cases of traumatism, myalgia, myositis and in some forms of arthritis when deep penetration is not desired. It aids in the repair of wounds and in the combating of superficial infections, and it relieves pain by lessening nervous sensibility and relaxing vascular spasm. It is used as a preparation for massage, sinusoidal interrupted galvanism and static wave treatment, since it lowers the resistance of the skin to the passage of the electric current. To make this modality effective and safe, parabolic reflectors casting parallel rays should be used, and the radiance must be at a tolerable distance from the patient's skin. In cases in which there are scar lesions combined with peripheral nerve injuries, because of the disturbed sensation and lack of normal collateral circulation, very unpleasant and slowly healing burns easily develop. In such cases at least one-third more than the ordinary distance should be used.

Superheated Air.—The physiological action of local application of this form of heat therapy is local perspiration, superficial hyperemia and, later, venous stasis. The apparatus is, however, cumbersome and its method has been supplanted by the radiant light and heat applicators and of modern diathermia.

Whirlpool Baths.—These are a very effective combination of local heat and gentle massage. The limb is submerged for half an hour or more in a bath, the water at a temperature of from 100° to 110° F., being constantly agitated by its own pressure or by compressed air. The whirlpool bath has a marked effect on the local circulation. Cold, clammy, sensitive extremities following peripheral nerve injuries become warm, red and painless after its application; indolent ulcers, osteomyelitis of terminal phalanges, painful and adherent scars are favorably influenced. The whirpool bath is very useful as the first treatment for a fractured limb after the removal of the splint, since it cleanses the skin and relieves pain, swelling and stiffness.

Contrast Baths.—Contrast baths consist of immersing a part first in hot water, at a temperature of 120° F., then in iced water for from

[1] Jour. Am. Med. Assn., July 12, 1924.

twenty to thirty seconds, repeating for seven minutes. They produce an intense local vasomotor reaction, and are indicated for toughening stumps, in cases of chilblains and in other conditions resulting from sluggish circulation.

Diathermy.—This is the most effective form of heat application to the deep structures. Heat conveyed by radiation penetrates only a very short distance and heats only the skin directly; it is spread further by conduction, and is impeded by the circulating blood. An electric current of extremely rapid alternations (1,000,000 oscillations each second) does not stimulate excitable tissues or produce chemical (electrolytic) changes, but the heat penetrates (hence the name diathermy) all tissues traversed by it. When a current passes along a conductor, heat is developed, the amount and degree depending on the resistance of the conductor and the intensity of the current. A current generated by the diathermy machine when properly applied causes no other sensation than that of heat. The more dense the tissue, the greater the resistance; therefore, bone is particularly affected. By varying the size and position of the electrodes one can vary the location of the greatest intensity of heat at will.

The therapeutic action of diathermy is to induce deep hyperemia in the parts treated; this, in turn, disintegrates exudates, promotes absorption, relieves pain and attenuates or kills bacteria. Diathermy is, accordingly, indicated in a very wide range of traumatic and inflammatory conditions. The pain, exudates and adhesions in traumatic rheumatic and gonorrheal types of arthritis are influenced most favorably; even in some very severe cases of arthritis, in which no improvement of function can be hoped for, the sedative action of diathermy is of value. Sprains, strains of joints, traumatic and ordinary myositis in both acute and chronic varieties respond favorably. Diathermy is indicated in the treatment of fractures for the relief of pain and the absorption of an excess of callus. In some instances it is best to follow diathermy by a mechanical agent in order to utilize its tissue-relaxing, softening effects to best advantage. Diathermy is also indicated in bone infections, combined with ultra-violet radiation. It is an effective sedative in later stages of true neuritis.

Mechanical Agents.—Massage.—This has the advantage of requiring only a pair of skilled hands for its application, and it is therefore available for fractures and other injuries at the bedside. It improves the circulation, hastens absorption and thus prevents stiffness and pain. It is most effective when preceded by a thermal agent and followed by active or passive movements. In the treatment of deformities and weak, but not paralyzed, muscles, it may be combined with corrective exercises. Experimental evidence indicates that massage is but of slight benefit in preventing the atrophy of paralyzed muscles and only the lightest form of massage is indicated because, owing to the atrophy of the paralyzed muscle, pressure may be transmitted to the bloodvessels, causing paralytic dilatation. Heavy massage may be employed in chronic, more painful, cases.

Mechanical Vibration.—This applies deep massage and percussion. It is less tiring to the operator, and is also more easily regulated. It has been found useful in many forms of chronic myositis, in sacro-iliac and sacro-lumbar strain and other forms of backache. Its application should be preceded by a thermal agent.

Manipulation: Active and Passive Exercises.—These are of service in increasing the range of action in stiffened joints and developing muscle power, and are indicated for sprains, fractures, chronic inflammatory conditions, paralysis and deformities. As to mechanical treatment by apparatus, the present tendency is to use apparatus of very simple construction; ordinary weight and pulley exercises have replaced all the elaborate machinery of the Zander type. All exercises of this character are more effective after preliminary preparation by heat, massage or other mechanical agents.

Static Wave Current.—This produces a very fine continuous, painless, molecular massage. In its physics it represents a current of great force but of very little volume; a soft metal plate covers the part to be treated, and at each discharge of the machine across the spark gap there will be a contraction of all contractile tissues beneath the electrode. The static wave is indicated whenever tissue drainage and relief of stasis is desired, as after recent injury, when it acts to pump out the extravasated fluid before it becomes organized. If the exudate has become organized a previous softening by a thermal agent is necessary. In chronic non-infectious inflammatory conditions it will relieve local congestion and pain.

Static sparks produce a sudden and powerful contraction of local tissues with a subsequent reduction of pressure and relief of pain. Sparks are produced by approaching a patient sitting on a charged static platform with a grounded electrode. Deep-seated congestions, muscular spasm and peri-arthritic changes beyond the reach of massage are often influenced favorably by this method.

The static brush discharge is a refinement of the coarse spark, which is nebulized. It has been found useful in stimulating local blood supply and in relieving local induration and for pain after injury or the result of gout and neuritis. The patient has a feeling of a stream of hot sand being directed at him.

Faradic Current.—This is obtained by the transformation of a constant or direct current by an induction coil into a current imparting stimuli of about one-thousandth of a second duration. Acting through the nerve endings, it produces active contraction in normal muscles. Its effects are similar to those of voluntary movements, namely, to increase the circulation and to strengthen the muscles. It is indicated when active exercises are not practicable, as in cases of weak and flabby, but not paralyzed, muscles. In contrast to the original faradic current, the modern Bristow coil enables one to obtain these contractions painlessly, with alternate periods of rest, resembling a surging effect. The faradic current is most important as a diagnostic test in the case of suspected nerve lesions.

Galvanic (Constant or Direct) Current.—This causes muscular contractions only when its flow is suddenly started or cut off. Normal muscle responds quickly, but if conduction is impaired as the result of injury or diseases of the nerve or if the anterior horn cells are damaged, the contraction is slow and sluggish. This together with the lack of faradic response is called the "reaction of degeneration." Muscles under those conditions do not contract voluntarily or reflexly tend to revert to the non-contractile connective-tissue type. The purpose of treatment by the interrupted or sinusoidal galvanic current is to preserve the contractile function until the normal reactions have been restored in part.

Sinusoidal Current.—This is an alternating current with a gradual rise and fall in strength. The alternations can be made slow or rapid and their curves varied, any number of combinations and muscle contractions of varying character thus being obtained. Straight galvanic sinusoidal current is the most pleasant and effective means of imitating the normal motor nerve impulse.

Chemical Agents.—Ionization.—The tissue-softening effect of the negative pole of the straight galvanic current is used for the loosening of excessive or adherent scar tissue. Prolonged application of this current, when combined with thermal and mechanical agents, is often effective. Ionic medication of joints by this means, once in favor, has been practically abandoned, because the results, which were found to be due mainly to the nutritional effect of galvanism, may be more readily attained by diathermy.

Ultra-violet Rays.—Actinic or ultra-violet rays are the rays beyond the violet part of the visible spectrum. They seem to exert a powerful action on living structure, and in moderate doses are nourishing, tissue-stimulating and pain-relieving; in stronger application they are bactericidal and tissue-destroying. Sunlight in mountain regions contains an abundance of ultra-violet rays, but the dust and moisture in a city atmosphere absorb most of the latter, so that for constant use one must depend on artificial sources of supply. The quartz-mercury burner is the most effective of these; a low-tension electric current heats and vaporizes mercury in a fuzed quartz container. The radiations of this "air-cooled" lamp are used for general systemic treatment in rickets, in joint, bone and glandular tuberculosis, osteomyelitis, usually when given in conjunction with local ultra-violet treatment. That tanning of the skin is a necessary part of the ultra-violet treatment seems questionable. Local treatment alone is used for mild stimulation, and sterilization in chronic ulcers. For intensive local action in cavities or sinuses the water-cooled ultra-violet burners are used, thus making various degrees of local application possible.

Functional use regulated to the point of tolerance as indicated by fatigue or discomfort is of the first importance. If a lower extremity is involved, weight-bearing under proper protection should be encouraged, since it stimulates the circulation and builds up the tissue of the bones.

Voluntary exercise of the muscles is the most effective means of

restoring control and increasing the range of motion in stiffened joints. For such exercise, machines, if adapted to the particular case and used under supervision, are often helpful. Passive movements so often employed with the aim of increasing the range of motion, if they cause persistent discomfort, are the most effective means of limiting it. The same is true of forced movements in the later treatment of fractures involving joints. The attitude may be changed from time to time to prevent adaptive changes in the muscles and tissues, even if it causes temporary discomfort, but forcible movement in various directions, often repeated, injures the tissues and prolongs the period of disability.

Forcible movement under anesthesia throughout the normal range to overcome restriction due to adhesions or adaptive contractions, often causes less after-pain than limited passive movements which simply pull upon but do not overcome the resistance of the restraining tissues.

The treatment of the patient is of equal importance with that of the local disability. Jones has emphasized this point by calling attention to the great advantage of useful occupation as a training for mind and body over hospital routine:

"By the time a soldier has passed through various phases of recovery from septic wounds in several different hospitals, and is finally transferred to an orthopaedic center for treatment to correct deformity and restore the use of injured joints and muscles, his spirit is often broken. The shock of injury, frequently in itself severe, followed in succession by a long period of suppuration and then by a wearisome convalescence, during which he receives treatment by massage or electricity, or by monotonous movement with mechanical apparatus of the Zander type, too often leaves him discontented with hospital life, its monotonous round of routine, and its long periods of idleness.

"In the orthopaedic center he finds his fellow-patients busily engaged in employments in which they are doing something, and it is not many days before he asks for a 'job.'

"In the military orthopaedic hospital at Shepherd's Bush alone, out of 800 patients, about 500 are employed at some regular work, which fosters habits of diligence and self-respect and converts indolent and often discontented patients into happy men, who soon begin to feel that they are becoming useful members of society and not mere derelicts.

"Thus, when the preliminary stages of operative and surgical treatment are over, there is a steady gradation through massage and exercise to productive work, which is commenced as soon as the man can really begin to use his limbs at all. If his former trade or employment is a suitable one, he is put to use tools he understands, otherwise some occupation suitable for his disability, and curative in its character, is found for him.

"Men with stiff ankles are set to drive a treadle lathe or fretsaw. If put on a treadle-exercising machine the monotony soon wearies the mind, but if the mind is engaged not on the monotony of the foot-

work, but on the interest of the work turned out, neither mind nor body becomes tired.

"Men with defective elbows and shoulders find exercise and mental diversion in the carpenter's and blacksmith's shops. If their hands and fingers are stiff, working with a big swab to clean windows or with a paint brush is a more interesting occupation than gripping spring dumb-bells. Those of us who have any imagination cannot fail to realize the difference in atmosphere and *morale* in hospitals where the patients have nothing to do but smoke, play cards, or be entertained, from that found in those where for part of the day they have regular, useful and productive work.

"Massage and exercise is no longer a mere routine: it all fits in and leads up to the idea of fitness—fitness to work and earn a living and serve the State in an economic sense, even if not to return to the regiment and fight once more in the ranks of the army."

MEDICAL LIBRARY
OF THE
BOSTON CITY HOSPITAL

INDEX.

A

Abbott treatment of lateral curvature of spine, 212
Abduction treatment for fracture of the neck of the femur, 629, 956
Abductor paralysis, Dickson's operation for, 700
Abnormalities of ribs, 243
Abnormality of clavicle, 245
Abscess, Brodie's, 294
  diagnosis of, from tuberculous disease of spine, 55
  pelvic, diagnosis of, from tuberculous disease of spine, 42
    in tuberculous disease of spine, 40
  perinephritic, diagnosis of, from tuberculous disease of spine, 42
  in sacro-iliac disease, 137
  in tuberculous disease of bones, 264
    of hip-joint, 396
    of joints, 265
    of knee-joint, 453
    of spine, 26, 47
Absence of patella, 481
  of ribs, 244
Acetabulum in congenital dislocation at hip-joint, 579
Achillobursitis, 816
  anterior, 816
  etiology of, 816
  pain in, 817
  pathology of, 817
  posterior, 819
  symptoms of, 817
  treatment of, 817
Achillodynia, 816
Acquired cerebral paralysis of childhood, 711
    deformities in, 715
    disability in, 715
    loss of growth in, 916
  displacement of patella, 481
  genu recurvatum, 477
  luxation of clavicle, 248
  talipes, 848, 901
    calcaneovalgus, 930
      arthrodesis in, 945
      tendon implantation in, 944
        transplantation in, 932
    calcaneovarus, 930
      arthrodesis in, 945
Acquired talipes calcaneovarus, tendon implantation in, 944
        transplantation in, 932
    calcaneus, 918
      arthrodesis in, 923
      astragalectomy and backward displacement in, 924
      deformity in, development of, 918
      Judson brace in, 920
      silk ligaments in, 923
      symptoms of, 919
      tendon fixation in, 923
        transplantation in, 923
      treatment of, 919
        operative, 921
      Whitman's operation in, 924
      Willett's operation for, 922
    deformity in, development of, 901
    diagnosis of, from congenital, 902
    equinovalgus, 912
      loop operation in, 913
    equinovarus, 910
    equinus, 903
      astragalectomy and backward displacement in, 910
      deformity in, correction of, 905
        tonic effect of, 907
      silk ligaments in, 908
      tendon displacement in, 909
        implantation in, 908
      treatment of, 905
        operative, 908
    etiology of, 901
    valgus, simple, 917
  torticollis, 733, 738
    varieties of, 738
Acromegaly, 576
Acromio-clavicular articulation, displacement of, 248
  joint, arthritis of, 249
Acroparesthesia, 822
Actinomycosis of spine, 117
Acute anterior poliomyelitis, 662. *See* Poliomyelitis, acute anterior.
Albee's method of bone-grafting, 1007
Ambulatory supports in treatment of tuberculous disease of spine, 65

Amputation in treatment of tuberculosis of hip-joint, 405
of knee-joint, 456
Vanghetti's, 1012
Amputations, ratings for, 956
Amyotonia congenita, 723
diagnosis of, from acute anterior poliomyelitis, 668
Anchylosis of ankle-joint, treatment of, 316
of hip-joint, treatment of, 316
of joints, 312
arthroplasty in, 316
etiology of, 312
forcible correction in, 314
operative exploration in, 315
passive motion in, 314
pathology of, 212
prevention of, 212
treatment of, 212
of knee-joint, treatment of, 316
Angioneurotic edema of foot, 822
Angle of femoral neck, 616
Ankle-joint, anchylosis of, treatment of, 316
arthritis deformans of, diagnosis of, from tuberculosis, 492
infectious arthritis of, diagnosis of, from tuberculosis, 492
injury of, 499
range of motion at, 777
sprain of, 499
adhesive plaster strapping in, 500
chronic, 501
treatment of, 501
diagnosis of, from tuberculosis, 492
etiology of, 499
pain in, 499
stockinette bandage in, 499
symptoms of, 499
treatment of, 499
tuberculous disease of, 488
age in, 490
deformity in, 491
reduction of, 493
diagnosis of, 492
from arthritis deformans, 492
from flat-foot, 492
from infectious arthritis, 492
from rheumatism, 492
from sprains, 492
etiology of, 489
limp in, 491
pathology of, 488
prognosis of, 494
situation of, 489
stiffness in, 491
symptoms of, 490
Thomas' brace in, 493
treatment of, 493
Ankles, swelling about, 504
Anterior achillobursitis, 795
Anterior bow-legs, 659
congenital dislocation at hip-joint, 586
curvature of tibia, 659
displacement of tibia, 478
metatarsal arch, depression of, 808
weakness of, 808
metatarsalgia, 808
gout and, 813
heredity in, 813
influence of shoe in causing disability and pain, 812
rheumatism and, 813
poliomyelitis, 662. *See* Poliomyelitis, acute anterior.
Appendicitis, diagnosis of, from tuberculosis of spine, 42
Aran-Duchenne type of paralysis, 724
Arborescent synovial tuberculosis of joints, 266
Arches of foot, 756
Arm, muscles of, paralysis of, in acute anterior poliomyelitis, treatment of, 685
nerves of, surgery of, 1022
Arthrectomy in treatment of tuberculous disease of knee-joint, 453
Arthritis, 283
atrophic, 300
etiology of, 303
treatment of, 303
deformans, 295
of ankle-joint, diagnosis of, from tuberculosis, 492
of great toe, 828
of hip-joint, 424
diagnosis of, from tuberculosis, 352
reconstruction operation for, 992
of knee-joint, diagnosis of, from tuberculosis, 444
typhoid vaccine in, 306
degenerative, 295
etiology of, 298
pain in, 299
pathology of, 296
symptoms of, 299
treatment of, 300
diagnosis of, from tuberculous disease of spine, 55
gonococcal, 283
of hip-joint, 420
diagnosis of, from tuberculosis, 352
in infancy, 286
purulent, 285
serofibrinous, 284
serous, 284
symptoms of, 284
treatment of, 285
hypertrophic, 296
etiology of, 298
pain in, 299
pathology of, 296
symptoms of, 299

Arthritis, hypertrophic, treatment of, 300
in infancy, 287
etiology of, 287
prognosis of, 288
sex in, 288
symptoms of, 288
treatment of, 289
infectious, of ankle-joint, diagnosis of, from tuberculosis, 492
diseases and, 286
prognosis of, 286
treatment of, 287
of hip-joint, 419
diagnosis of, from congenital dislocation, 587
from tuberculosis, 352
symptoms of, 419
treatment of, 419
of knee-joint, diagnosis of, from tuberculosis, 443
of acromio-clavicular joint, 249
of spine, 120
treatment of, 120
proliferating, 295, 300
etiology of, 303
treatment of, 303
puerperal, 286
rheumatoid, 295
scarlatinal, 286
subacute, of hip-joint, 420
tuberculous, 289
typhoid fever and, 286
Arthrodesis in acquired talipes calcaneo-valgus, 945
calcaneovarus, 945
calcaneus, 923
equinus, 909
in acute anterior poliomyelitis, 706
in paralytic talipes, 923
in tuberculous disease of hip-joint, 396
extra-articular, 408
Arthropathy, tabetic, 309
diagnosis of, 311
pathology of, 309
symptoms of, 311
treatment of, 311
Arthroplasty in anchylosis of joints, 316
Campbell's operation, 317
MacAusland's operation, 317
Arthrotomy in congenital dislocation at hip-joint, 612
Artificial limb, 1011
preparation of stumps for, 1011
Aspiration in treatment of paralysis complicating Pott's disease, 105
Astragalectomy in acquired talipes calcaneus, 924
equinus, 910
in neglected talipes, 887
in paralytic talipes, 924
Astragalo-navicular joint, tuberculous disease of, 492
Asymmetrical development of body, 249
Ataxia, hereditary, 726
Atlo-axoid articulation, range of motion at, 51
Atrophic arthritis, 300
Atrophy in coxa vara, 620
in tuberculous disease of elbow-joint, 511
of hip-joint, 341
of shoulder-joint, 508
of wrist-joint, 516
myelopathic, 724
of bone, 255
peroneal, 726
progressive muscular, 723
Attitudes of election, 1038

B

Back knee, 477. *See* Genu recurvatum.
pain in, 132
treatment of, 134
round, 233
hollow, 233
strain of, diagnosis of, from tuberculous disease of spine, 40
Backward displacement of foot in acquired talipes calcaneus, 924
equinus, 910
in paralytic talipes, 924
Baker's knee, 638
Baldwin's tables of ideal weights, 257
Balkan frame, 973
Banjo splint, 972
"Baseball finger," 548
treatment of, 548
Bassie operation in anterior poliomyelitis, 708
Beck's preparation in tuberculous disease of bones, 274
Bennett's operation for fixation of knee-joint, 315
Bent back, 729
Bier's hyperemia in tuberculous disease of joints, 276
treatment of tuberculous disease of knee-joint, 452
Bifurcation operation, 610
Bilateral congenital dislocation at hip-joint, 589
coxa vara, 621
disease of hip, 393
Billroth splint, 1045
in treatment of tuberculous disease of knee-joint, 446
Boas table of weight, height and circumference of chest in childhood, 256
Body, asymmetrical development of, 249
weight, percentage of principal tissues and organs in, 257
Bone-grafts, 1007
Albee's method, 1007
Bones, atrophy of, 255
carcinoma of, 324

Bones, carpal, fracture of, 522
hypertrophy of, 256
malignant disease of, 324
metartarsal, fracture of, 837
multiple myeloma of, 568
of foot, supernumerary, 838
of hand, supernumerary, 524
of lower extremity, deformities of, 636
etiology of, 636
statistics of, 636
sarcoma of, 384
tarsal, fracture of, 502
roentgen-rays in, 502
treatment of, 502
tuberculous disease of, 258
abscess in, 264
age in, 262
Beck's preparation in, 274
diagnosis of, 270
roentgen-rays in, 271
drugs in, 273
dry caries in, 267
etiology of, 258
heliotherapy in, 271
iodoform filling in, 274
latent, 258
mode of infection in, 258
pathology of, 263
predisposition to, 258, 260
prognosis of, 269
repair in, 269
roentgen-rays in, 275
septic infection in, 268
sex in, 262
side affected in, 262
sunlight in, 271
treatment of, 271
mechanical, 273
operative, 273
tuberculin in, 273
tumors of, 324
Bow-legs, 636, 654
anterior, 659
osteotomy in, 660
symptoms of, 660
treatment of, 660
braces in, 657
Knight, 657
Napier, 657
deformity in, etiology of, 636
onset of, 636
outgrowth of, 639
predisposition to, 637
diagnosis of, from congenital dislocation of hip, 588
gait in, 656
measurements in, 656
osteoclasis in, 658
osteotomy in, 658
symptoms of, 656
treatment of, 656
expectant, 656
operative, 658
Brace, caliper, in treatment of tuberculosis of knee-joint, 450
Brace, Judson, in treatment of acquired talipes calcaneus, 920
of acute anterior poliomyelitis, 681
of paralytic talipes, 920
of tuberculosis of hip, 362
Taylor's club-foot, 868
in treatment of tuberculosis of hip, 362, 390, 391
of spine, 81
Thomas' caliper, in treatment of acute anterior poliomyelitis, 691
knock-knee, in treatment of acute anterior poliomyelitis, 691
in treatment of genu valgum, 649
of knock-knee, 650
of tuberculosis of ankle-joint, 493
of knee-joint, 448, 449
in treatment of bow-legs, 657
of genu varum, 657
of infantile talipes, 864
of weak foot, 790
Braces in orthopaedic surgery, 999–1005, 1039–1046
Brachial plexus, obstetrical injury to, repair of, 532
operations on, 1021
Bradford bed frame in treatment of tuberculous disease of spine, 59
brace in treatment of tuberculous disease of hip-joint, 363
frame, 972
Bradford-Goldthwait genuclast, for flexion deformity at knee, 448
Brain, decompression of, in treatment of cerebral paralysis of childhood, 722
Brodie's abscess, 294
Bryant's triangle, 620
Bunion, 834
Bursa, superficial pretibial, enlargement of, 475
Bursæ, diseases of, diagnosis of, from tuberculosis of hip-joint, 353
in popliteal region, 475
Bursitis, 474
of hip-joint, gluteal, 421
treatment of, 422
iliopsoas, 422
treatment of, 422
of shoulder-joint, chronic, 521
prepatellar, 474
treatment of, 475
pretibial, 475
symptoms of, 475
treatment of, 475
retrocalcaneo, 816

C

Cabot posterior wire splint, 975
Caliper brace in treatment of tuberculous disease of knee-joint, 450

Calipers, Adams type, 973
Calot jacket in treatment of tuberculous disease of spine, 72
Calot's fluid in treatment of tuberculous disease of joints, 274
Campbell brace in displacement of semilunar cartilage, 313
operation for acquired talipes equinous, 909
of arthroplasty, in ankylosis of joints, 317
Camptocormia, 729
Caput quadratum in rhachitis, 555
Carcinoma of bone, 324
of femur, 422
of spine, 114
Caries sicca, 267
Carpal bones, fracture of, 522
Cartilaginous exostoses, multiple, 566
Cerebral paralysis of childhood, 711
acquired, 711
after birth, 712
deformities in, 714
disability in, 715
during labor, 712
intra-uterine, 711
loss of growth in, 716
congenital, 711
deformities in, 714
mentality in, 714
weakness in, 712
decompression of brain in, 722
diagnosis of, from acute anterior poliomyelitis, 668
distribution of, 711
etiology of, 711
muscle transplantation in, 717
pathology of, 711
prognosis of, 722
symptoms of, 712
treatment of, 716
of hemiplegia, 716
of paraplegia, 718
operative, 718
Cerebrospinal meningitis, diagnosis of, from tuberculous disease of spine, 56
Cervical opisthotonos, 754
diagnosis of, from tuberculous disease of spine, 54
ribs, 243
vertebræ, dislocation of, reduction of, 1009
Charcot-Marie-tooth type of paralysis, 703–724
Charcot's disease of joints, 309
diagnosis of, 311
from tuberculosis, 444
pathology of, 309
symptoms of, 311
treatment of, 311
Chest in childhood, table of circumference of, 256
deformities of, 245
Chest, deformities of, minor, 247
flat, 245
treatment of, 245
funnel, 247
keel-shaped, 246
pigeon, 246
Childhood, fracture of neck of femur in, 628
Chondrodystrophia, 560
etiology of, 561
pathology of, 561
prognosis of, 562
treatment of, 564
Chondromalacia of patella, 477
Clark's report of syphilis of joints, 282
Clavicle, abnormality of, 245
luxation of, acquired, 248
treatment of, 248
subluxation of, 248
treatment of, 248
Club-hand, 544
etiology of, 544
treatment of, 545
Club-foot brace, Taylor, 868
congenital, 848
anatomy of, 855
etiology of, 849
symptoms of, 858
treatment of, 858
neglected, treatment of, 870
Coccygodynia, 147
treatment of, 147
Colles' fracture, plaster splint for, 971
Combined sclerosis, subacute, 727
Congenital absence of fibula, talipes equinovalgus and, 896
of tibia, talipes equinovarus and, 899
varus and, 899
anterior curvature of tibia, 661
cerebral paralysis of childhood, 711
club-foot, 848
contraction of fingers, 546
of knee, 486
deficiency of femur, 900
deformities at elbow, 540
at wrist, 544
dislocation at hip-joint, 577
acetabulum in, 579
anterior, 586
arthrotomy in, 612
bilateral, 585
diagnosis of, from tuberculosis of spine, 41
capsule in, 579
diagnosis of, 587
from bow-legs, 588
from coxa vara, 587
from infectious arthritis, 587
epiphysitis, 587
from progressive muscular dystrophy, 588
from tuberculosis, 353

Congenital dislocation at hip-joint, diagnosis of, from tuberculous disease of spine, 41
femur in, 580
in infancy, treatment of, 598
in older subjects, treatment of, 606
ligamentum teres in, 579
limp in, 582
Lorenz operation for, 588, 589
reduction in, 590
in two sittings, 592
in young subjects, 594
traction in, 592
muscles in, 580
open operation with enlargement of acetabulum in, 605
osteotomy in, 612
pain in, 585
pathology of, 578
pelvis in, 580
sailor gait in, 585
supracotyloid, 587
treatment of, 588
osteoplastic buttress in, 609
palliative, 613
review of, 611
variations in, 599
unilateral, 582
waddle in, 585
of knee, 486
of shoulder, 525
displacement of patella, 481
of phalanges of fingers, 547
of radius, 540
of ulna, 540
distortions of hand, 544
edema of feet, 900
elevation of scapula, 240
exostoses of foot, 837
genu recurvatum, 478
deformities of, absence of patella, 479
dislocation of hip, 479
valgus, 479
varus, 479
hallux valgus, 834
varus, 829
hammer-toe, 834
hypertrophy of feet, 900
lateral curvature of the spine, 165
pronation of forearm, 541
subluxation of hip, 613
syphilis of joints, 279
talipes, 848
calcaneovalgus, 896
calcaneovarus, 896
calcaneus, 894
cavus, 896
equinovalgus, 896
Congenital talipes, equinovarus, 855
equinus, 894
valgocavus, 896
valgus, 895
varus, 893
torticollis, 733
hematoma of sternomastoid and, 736
Constricting bands of feet, 900
Contracted foot, 803
Steindler's operation for, 806
Contraction of fingers, congenital, 546
of knee, congenital, 486
Convex stretcher frame in treatment of tuberculous disease of spine, 59
Corsets in treatment of tuberculous disease of spine, 79–81
Coxa valga, 635
vara, 614
atrophy in, 620
awkwardness in, 620
bilateral, 621
deformity in, 620
diagnosis of, 622
from congenital dislocation of hip, 587, 624
from hip disease, 622
from tuberculous disease of hip-joint, 353
discomfort in, 620
epiphyseal, 629
etiology of, 615
forcible abduction in, 624
limitation of motion in, 620
limp in, 620
mechanical effects of, 617
osteotomy for, 625
pathology of, 615
physical effects of, 620
shortening in, 620
symptoms of, 617
traumatic, 628
diagnosis of, from tuberculous disease of hip-joint, 353
treatment of, 624
unilateral, 621
Craniotabes in rachitis, 555
Cretinism, 562
Crucial ligaments, rupture of, 471
Cubitus valgus, 541
in rhachitis, 556
varus, 541
in rhachitis, 556
Cuneiform osteotomy in treatment of coxa vara, 626
of genu valgum, 652
of neglected talipes, 867
Cysts in popliteal region, 475
of femur, 422
of semilunar cartilages, 470

D

Decompression of brain in treatment of cerebral paralysis of childhood, 722

Deformities, acquired, in cerebral paralysis in childhood, 715
at wrist, congenital, 544
hysterical, 727
in acute anterior poliomyelitis, 675
in congenital cerebral paralysis of childhood, 714
in rhachitis, 554
of bones of lower extremity, 636
of chest, 245
minor, 247
of elbow, congenital, 540
of foot, 756, 846
compound, 847
of knee-joint, 461
of upper extremity, 525, 675
Deformity, functional, pathogenesis of, 250
Wolff's law of, 250
in acquired talipes, development of, 901, 918
in acute anterior poliomyelitis, 672, 675
in coxa vara, 619
in paralytic talipes, 918
in tuberculous disease of ankle-joint, 491
of elbow-joint, 511
of legs, weak foot in childhood and, 782
Degenerative arthritis, 296
Delbet's plaster splint, 977
Depression of anterior metatarsal arch, 808
of neck of femur, 614
Deviation in lateral curvature of spine, 150
of spine in tuberculosis, 47
Diaphyseal aclasis, 566
Dickson's operation for abductor paralysis, 700
Diphtheritic paralysis, diagnosis of, from acute anterior poliomyelitis, 668
from tuberculous disease of spine, 55
torticollis and, 754
Disabilities of foot, 756
Dislocation at hip-joint, congenital, 577
acetabulum in, 579
anterior, 586
arthrotomy in, 612
bilateral, 585
capsule in, 579
diagnosis of, 587
from bow-legs, 588
from coxa vara, 587
from infectious arthritis, 587
epiphysitis, 587
from progressive muscular dystrophy, 588
from tuberculous disease of spine, 41
etiology of, 580
Dislocation at hip-joint, congenital, femur in, 580
genu recurvatum and, 479
in infancy, treatment of, 598
in older subjects, treatment of, 606
ligamentum teres in, 579
limp in, 582
Lorenz operation for, 588, 589
reduction in, 590
in two sittings, 592
in young subjects, 594
traction in, 592
muscles in, 580
open operation with enlargement of acetabulum in, 605
osteotomy in, 612
pain in, 585
pathology of, 578
pelvis in, 580
prognosis of, 597
sailor gait in, 585
supracotyloid, 587
symptoms of, 582
treatment of, 588
osteoplastic buttress in, 609
palliative, 613
variations in, 599
unilateral, 582
waddle in, 585
of cervical vertebræ, reduction of, 1009
of knee, congenital, 486
of shoulder, congenital, 525
recurrent, 534
Nicola's operation for, 539
treatment of, 535
spontaneous, of hip-joint, 420
treatment of, 421
Displacement of acromio-clavicular articulation, 248
of patella, 481
of peroneal tendons, 841
of phalanges of fingers, 547
of radius, congenital, 540
of semilunar cartilage, 464
Campbell brace in, 467
pain in, 464
treatment of, 466
of tibia, anterior, 581
of ulna, congenital, 540
Distortions in acute anterior poliomyelitis, compensatory, 678
of fingers, 546
of hands, congenital, 544
of limbs in tuberculous disease of hip-joint, 335
Döllinger on retardation of growth in tuberculous disease of hip-joint, 344
Dorsified foot, 847

Drop-finger, 548
Dry caries in tuberculosis of bones, 267
of joints, 267
Dunn's operation for deformities of foot, 946
Dupuytren's contraction, 549
etiology of, 549
pathology of, 549
symptoms of, 550
treatment of, 550
Dysbasia angiosclerotica, 823
Dyschondroplasia, 565
roentgen-rays in, 565
Dystonia lenticularis, 723
musculorum deformans, 723
Dystrophy, muscular, 724
diagnosis of, from tuberculous disease of spine, 41

E

Edema, angioneurotic, of foot, 822
of feet, congenital, 900
Elbow, deformities of, congenital, 540
tennis, 521
Elbow-joint, tuberculous disease of, 510
age in, 510
atrophy in, 511
deformity in, 511
reduction of, 512
occurrence of, 510
pain in, 511
pathology of, 510
prognosis of, 513
sensitiveness in, 511
stiffness in, 511
swelling in, 511
symptoms of, 511
treatment of, 512
Electrical test in acute anterior poliomyelitis, 670
Elongation of ligament of patella, 485
Empyema, diagnosis of, from tuberculous disease of spine, 48
Enlargement of superficial pretibial bursa, 475
Epicondylitis, 521
Epiphyseal coxa vara, 629
fracture, diagnosis of, from tuberculosis of hip-joint, 353
Epiphyses at hip, 616
at knee, 435
at shoulder, 506
proportional growth from each, 257
Epiphysitis at hip-joint, acute, 419
diagnosis of, from tuberculous disease of hip-joint, 351
infectious, diagnosis of, from congenital dislocation, 587
of adolescents, 47
vertebral, 234
of adolescence, diagnosis of, from Pott's disease, 47
Equinus, postural, 803
Erythromelalgia, 822
Everted foot, 847
Excision in treatment of tuberculous disease of elbow-joint, 513
of knee-joint, 455
Exercise in treatment of genu valgum, 648
of knock-knee, 648
of weak foot, 786
Exostoses of foot, 837
congenital, 837
multiple cartilaginous, 566
Extended foot, 847
External semilunar cartilages, cysts of, 470
Extra-articular arthrodesis in tuberculous disease of hip-joint, 418
disease of hip-joint, 45
tuberculous disease of knee-joint and, 452
fusion, Haas' method of, 409

F

Fatty tissues of knee-joint, hyperplasia of, 474
Feet, congenital edema of, 900
hypertrophy of, 900
constricting bands of, 900
Femur, carcinoma of, 422
congenital deficiency of, 900
dislocation at hip-joint, 580
cysts of, 422
treatment of, 423
neck of, depression of, 614
fracture of, 629
abduction treatment of, 956
diagnosis of, from tuberculous disease of hip-joint, 353
in childhood, 628
simple, 628
diagnosis of, 628
treatment of, 629
sarcoma of, 422
Fibula, congenital absence of, etiology of, 897
talipes equinovalgus and, 896
treatment of, 898
Finger, baseball, 548
treatment of, 548
hammer, 547
jerking, 547
mallet, 548
treatment of, 548
snapping, 547
trigger, 547
etiology of, 547
treatment of, 548
Fingers, contraction of, congenital, 546
treatment of, 547
distortions of, 547
phalanges of, congenital displacement of, 547
webbed, 547

BOSTON 1061

Fingers, webbed, etiology of, 547
treatment of, 547
Finney and Hughson's operation for spasmodic torticollis, 749
Flat back, 234
chest, 245
foot, 767
diagnosis of, from tuberculous disease of ankle-joint, 492
Flexed and everted foot, 847
and inverted foot, 847
Foerster's operation for cerebral paralysis of childhood, 719
Foot, acroparesthesia of, 822
angioneurotic edema of, 822
arches of, 756
anterior metatarsal, 758
internal, 758
longitudinal, 756
transverse, 756
as a mechanism, 767
as a passive support, 759
bones of, supernumerary, 838
contracted, 803
etiology of, 803
Steindler's operation for, 806
symptoms of, 804
treatment of, 806
deformities of, 756, 846
compound, 847
Dunn's operation for, 946
paralytic, review of operative procedures for relief of, 916
disabilities of, 756
dorsiflexed, 847
erythromelalgia of, 822
everted, 847
exostoses of, 837
congenital, 837
subungual, 837
treatment of, 837
extended, 847
and everted, 847
and inverted, 847
flat, 767
flexed and everted, 847
and inverted, 847
functions of, 756
hollow, 803. *See* Foot, contracted.
in activity, 759
inverted, 847
movements of, 760
muscles of, function of, 766
plantar flexed, 847
postures of, improper, 760
pronated, 767
Raynaud's disease of, 822
splay, 767
splints in orthopaedic surgery, 1044
vasomotor trophic neuroses of, 822
weak, 767
in childhood, 781
deformity of legs and, 782
general weakness and, 783
irregular forms of, 782
Foot, weak, in childhood, symptoms of, in-toeing, 781
out-toeing, 781
outgrown joints, 782
weak ankles, 782
diagnosis of, 775
attitudes in, 775
bearing surface of, 776
contour in, 776
distribution of weight and strain in, 775
range of motion in, 777
etiology of, 772
limitation of motion in, 779
muscular spasm in, 779
pathology of, 773
review of, 774
rigid, 792
adjuncts in, 798
manipulation in, 795
Miller's operation in, 801
overcorrection in, forcible, 793
functional use in, 794
plaster strapping in, 799
treatment of, 792
Thomas', 798
varieties of, 797
symptoms of, 773
treatment of, 784
attitudes in, 786
brace in, 790
construction of, 788
exercises in, 786
operative, 801
plaster cast in, 788
shoe in, 785
raising inner border of, 785
support in, 787
types of, 780
varieties of, 779
Foot-drop, splint for, 1005, 1006
Forearm nerves, surgery of, 1024
pronation of, congenital, 540
treatment of, 541
Fracture at shoulder, treatment of, 986
delayed union of, 1009
epiphyseal, diagnosis of, from tuberculosis of hip-joint, 353
of metatarsal bones, 837
of neck of femur, 629
abduction treatment of, 978
in childhood, 628
diagnosis of, from tuberculous disease of hip-joint, 353
simple, 628
ununited, reconstruction operation for. *See* Chapter XXIV.
of carpal bones, 522
of tarsal bones, 502
orthopaedic surgery of, 959
ratings for, 956
treatment of, outline of, 959

Fracture, treatment of, outline of, compound fractures, 968
diagnosis, 960
examination, 960
first aid, 959
operative, 961
Fragilita generalisata, 570
ossium, 568
treatment of, 568
Friedreich's disease, 726
Functional pathogenesis of deformity, 250
Wolff's law of, 250
Functions of foot, 756
Funnel chest, 247

G

Gaenslen's operation for injury of sacro-iliac articulation, 145
Gait in bow-legs, 656
in genu valgum, 645
varum, 656
in knock-knee, 645
Ganglion, 548
Ganglionectomy, sympathetic, 825
Genu recurvatum, acquired, 477
etiology of, 477
symptoms of, 478
treatment of, 478
congenital, 478
deformities of, absence of patella, 479
dislocation of hip, 479
valgus, 479
varus, 479
etiology of, 479
treatment of, 480
traumatic, treatment of, 478
tuberculous disease of hip-joint and, 416
valgum, 636, 642
accommodative attitude in, 644
adolescent, 643
attitude of rest in, 638
braces in, 649
changed relation of femur and tibia in, 643
deformity in, outgrowth of, 639
predisposition to, 637
secondary, 644
etiology of, 636
exercise in, 648
gait in, 645
manipulation in, 648
measurements in, 647
onset of, 636
osteoclasis in, 653
osteotomy in, 652
pathology of, 647
posture in, 648
symptoms of, 642
treatment of, 647
expectant, 647
operative, 652
Genu valgum, unilateral, 645
with genu varum and general rhachitic distortions, 646
Wolff's treatment of, 654
varum, 636, 654
braces in, 657
deformity in, outgrowth of, 639
predisposition to, 637
etiology of, 636
gait in, 656
measurements in, 656
onset of, 636
osteoclasis in, 658
osteotomy in, 658
symptoms of, 656
treatment of, 656
expectant, 656
operative, 658
Gluteal bursitis, 421
treatment of, 422
Gluteus medius muscle, paralysis of, transplantation of tensor vaginæ femoris for, 695
Gonococcal arthritis, 283
in infancy, 286
of hip-joint, 420
diagnosis of, from tuberculosis, 352
purulent, 285
serofibrinous, 284
serous, 284
rheumatism, 283
of spine, 120
Gooch splints and bandages, 1002
Gout, 306
anterior metatarsalgia and, 813
Grattan's osteoclast, 653
"Growing pains," diagnosis of, from tuberculous disease of hip-joint, 351

H

Haas' method of extra-articular fusion, 409
Hallux flexus, 826
rigidus, 826
etiology of, 826
treatment of, 827
valgus, 831
etiology of, 831
pathology of, 832
shoes and, 831
symptoms of, 832
treatment of, 832
operative, 833
varus, 829
treatment of, 829
Hammer-finger, 547
toe, 834
congenital, 835
Hamstring muscles, transplantation of, 694
Hand, bones of, accessory, 524
brace, 1042
congenital distortions of, 544

Harrison's groove in rhachitis, 556
Heberden's nodes, 300
Heel, painful, 820
treatment of, 821
Height in childhood, table of, 256
Heliotherapy in treatment of tuberculous disease of bones, 271
Hemarthrosis, 308
of knee-joint, diagnosis of, from tuberculosis, 443
Hemiplegia in cerebral paralysis of childhood, treatment of, 716
Hemophilia, 307
treatment of, 308
Hemorrhage into joints, 308
Hemorrhagic osteomyelitis, 294
Hereditary ataxia, 726
Hernia, diagnosis of, from tuberculous disease of spine, 43
High shoe in treatment of tuberculous disease of hip-joint, 361
Hip, arthritis deformans of, diagnosis of, from tuberculosis, 352
disease, 327. *See* Tuberculous disease of hip-joint.
dislocation of, congenital, diagnosis of, from tuberculous disease of spine, 41
genu recurvatum and, 479
high, in lateral curvature of spine, 153
hysterical, 730
muscles of, paralysis of, in acute poliomyelitis, treatment of, 684
snapping, 614
splint, Taylor's, 390
convalescent, 393
Thomas-Jones, 1043
subluxation of, congenital, 613
Hip-joint, anchylosis of, treatment of, 316
arthritis of, acute infectious, 419
diagnosis of, from congenital dislocation, 587
symptoms of, 419
treatment of, 419
deformans of, 424
disease of, bilateral, 393
treatment of, 394
double, 393
with tuberculosis of spine, 395
dislocation at, congenital, 577
acetabulum in, 579
anterior, 586
arthrotomy in, 612
bilateral, 585
capsule in, 579
diagnosis of, 587
from bow-legs, 588
from coxa vara, 587
from infectious arthritis, 587
epiphysitis, 587
from progressive muscular dystrophy,588
from tuberculosis, 353
Hip-joint, dislocation at, congenital, diagnosis of, from tuberculous disease of spine, 588
etiology of, 580
femur in, 580
in infancy, treatment of, 598
in older subjects, treatment of, 606
ligamentum teres in, 579
limp in, 582
Lorenz operation for, 588
reduction in, 590
in two sittings, 592
in young subjects, 594
traction in, 592
muscles in, 580
open operation with enlargement of acetabulum in, 605
osteotomy in, 612
pain in, 585
pathology of, 578
pelvis in, 580
prognosis of, 597
sailor gait in, 585
supracotyloid, 587
symptoms of, 582
treatment of, 588
osteoplastic buttress in, 609
palliative, 613
review of, 611
variations in, 599
unilateral, 582
waddle in, 585
epiphysitis at, acute, 419
infectious, diagnosis of, from congenital dislocation, 587
symptoms of, 419
treatment of, 419
extra-articular disease of, 421
gluteal bursitis of, 421
treatment of, 422
gonorrheal arthritis of, 420
diagnosis of, from tuberculosis, 352
iliopsoas bursitis of, 422
treatment of, 422
infectious arthritis of, diagnosis of, from tuberculosis, 351
malignant disease about, 422
non-tuberculous affections of, 418
osteitis fibrosa of, 423
osteo-arthritis of, 424
pain in, 425
symptoms of, 425
treatment of, 426
range of motion at, Fig. 286, 327
spontaneous dislocation of, 420
treatment of, 421
subacute arthritis of, 420

Hip-joint, traumatisms at, 418
treatment of, 418
tuberculous disease of, 327
abscess in, 396
significance of, 399
treatment of, 400
actual lengthening in, 346
shortening in, 343
age in, 331
apparent lengthening in, 336
shortening in, 337
atrophy in, 341
causing equinus, 416
genu recurvatum, 416
knock-knee, 416
lateral curvature, 416
laxity of ligaments, 416
changes in contour of hip in, 342
debility in, 346
deformity in, correction of, 406
diagnosis of, 351
from anterior poliomyelitis, 351
from arthritis deformans of hip, 352
from congenital dislocation of hip, 353
from coxa vara, 353
from disease of bursæ, 353
from epiphyseal fracture, 353
from epiphysitis, 351
from extra-articular disease, 352
from fracture of neck of femur in children, 353
from gonococcal arthritis, 352
from "growing pains," 351
from hysterical joint, 352
from infectious arthritis, 351
from local injury, 351
irritation, 350
from pelvic disease, 352
from Perthes' disease, 351
from chronic polyarthritis, 352
from rheumatism, 351
from sacro-iliac disease,352
from scurvy, 351
from synovitis, 351
from traumatic coxa vara, 353
from tuberculous disease of spine, 352
roentgen-rays in, 353
distortion of limb in, 333
estimation of, 348
of atrophy in, 350
Kingsley's method, 349
etiology of, 331
examination in, method of, 346
physical, 347
fever in, 346
Hip-joint, tuberculous disease of, frequency of, 331
in adults, 396
in infancy, 396
König's statistics of, 339
limp in, 333
local signs of, 350
measurements in, 347
muscular spasm in, 333
night cry in, 332
pain in, 332
pathology of, 327
physical signs in, 333
prognosis of, 411
reduction of deformity in, by traction brace, 363
by weight and pulley, 364
retardation of growth in, 344
Döllinger on, 344
Taylor on, 345
sex in, 331
side affected in, 332
sinuses in, treatment of, 400
stiffness in, 333
symptoms of, 332
general, 346
treatment of, 356
amputation in, 406
arthrodesis in, 396
extra-articular, 408
Bradford brace in, 363
during stage of recovery, 390
functional results of, 413
high shoe in, 361
Judson brace in, 362
Lorenz spica in, 383
mechanical, 357
review of, 388
splinting, 357
stilting, 357
traction, 357
operative, excision, 402
exploratory, 401
perineal bands in, 361
plaster supports in, 378
application of, 381
Taylor hip brace in, 362
Thomas', 374
application of, 361
efficiency of, 369
modification of, 378
traction hip splint in, 358
Hoke's multiple osteotomy, 890
Hollow foot, 803. *See* Foot, contracted.
round back, 233
Horizontal fixation in treatment of tuberculous disease of spine, 58
Housemaid's knee, 474
Hunger osteomalacia, 571
Hypermobility of joints, 614
Hyperplasia of knee-joint, 474
of fatty tissue within joint, 474
Hypertrophic arthritis, 296

Hypertrophic osteo-arthropathy, secondary, 575
Hypertrophy of bone, 256
of feet, congenital, 900
Hysterical joint affections and deformities, 727
diagnosis of, from tuberculosis, 353
hip, 730
knee-joint, diagnosis of, from tuberculosis, 444
scoliosis, 729
spine, 729
talipes, 731

I

Idiopathic osteopsathyrosis, 568
Iliopsoas bursitis, 422
treatment of, 422
Infantile scorbutus, 560
talipes, treatment of, 860
Infectious arthritis of ankle-joint, diagnosis of, from tuberculosis, 492
of hip-joint, diagnosis of, from congenital dislocation, 587
from tuberculosis, 351
of knee-joint, diagnosis of, from tuberculosis, 443
diseases, arthritis and, 286
epiphysitis of hip-joint, diagnosis of, from congenital dislocation, 587
Inflammation of subdeltoid bursa in periarthritis of shoulder, 517
Ingrown toe-nail, 836
In-knee, 642
Intermittent limp, 823
Intervertebral disks, 31
Inverted foot, 847
Ischemic paralysis and contraction, 550
pain in, 550
swelling in, 550
symptoms of, 550
treatment of, 551

J

Jaw, snapping, 247
Jerking fingers, 547
Joint affections, hysterical, 727
diagnosis of, from tuberculosis, 353
disease, diagnosis of, from acute anterior poliomyelitis, 668
Joints, anchylosis of, 312
arthroplasty in, 316
etiology of, 312
forcible correction in, 314
operative exploration in, 315
passive motion in, 314
pathology of, 312
prevention of, 312
treatment of, 312
Joints, Charcot's disease of, 309
diagnosis of, 311
from tuberculosis, 444
pathology of, 309
symptoms of, 311
treatment of, 311
diseases of, diagnosis of, from acute anterior poliomyelitis, 667, 668
hemorrhage into, 308
hypermobility of, 614
neurotic, 731
etiology of, 731
symptoms of, 732
treatment of, 732
non-tuberculous disease of, 279
syphilis of, 279
congenital, 279
hereditary, 280
treatment of, 283
tuberculous disease of, 258
abscess in, 264
active congestion in, 276
age in, 262
arborescent synovial, 266
Bier's hyperemia in, 276
Calot's fluids in, 274
diagnosis of, 270
roentgen-rays in, 271
distribution of, 261
drugs in, 273
dry caries in, 267
etiology of, 258
latent, 258
mode of infection in, 258
pathology of, 263
perforation in, 265
predisposition to, 258, 260
prognosis of, 269
repair in, 269
rice bodies in, 267
septic infection in, 268
sex in, 262
side affected in, 262
sunlight in, 271
treatment of, 271
mechanical, 273
operative, 273
roentgen-rays in, 275
Jones' humerus traction splint, 970
Judson brace in treatment of acquired talipes calcaneus, 920
of acute anterior poliomyelitis, 681
of infantile talipes, 864
of paralytic talipes, 920
of tuberculous disease of hip-joint, 361
perineal crutch, 391
Jury-mast in treatment of tuberculous disease of spine, 69

K

Keel-shaped chest, 246
Kienbock's disease, 522

Kingsley's method of estimation flexion in tuberculous disease of hip-joint, 350
Knee, back, 477. *See* Genu recurvatum.
baker's, 638
contraction of, congenital, 486
treatment of, 487
dislocation of, congenital, 486
housemaid's, 474
ligaments of, rupture of, 471
snapping, 486
treatment of, 486
Knee-joint, anchylosis of, treatment of, 315
arthritis deformans of, diagnosis of, from tuberculosis, 444
deformities of, 461
hemarthrosis of, diagnosis of, from tuberculosis, 443
hyperplasia of fatty tissues of, 474
within joint, 474
symptoms of, 474
treatment of, 474
hysterical, diagnosis of, from tuberculosis, 444
in childhood, injury of, 461
muscular cramp of, 461
infectious arthritis of, diagnosis of from tuberculosis, 443
internal derangement of, 464
loose bodies in, 468
non-tuberculous affections of, 461
"quiet effusion" at, 463
range of motion at, Fig. 387, 435
rheumatism of, diagnosis of, from tuberculosis, 443
sarcoma of, diagnosis of, from tuberculosis, 444
synovitis of, 461
acute, 461
chronic, 462
diagnosis of, from tuberculosis, 443
incidental, 462
painless, 463
purulent, Willems' method of draining, 287
recurrent, 462
syphilis of, diagnosis of, from tuberculosis, 444
tuberculous disease of, 435
abscess in, 453
actual lengthening in, 442
shortening in, 442
age in, 438
amputation in, 456
arthrectomy in, 453
Billroth splint in, 446, 447
caliper brace in, 450
causes of death in, 459
complications of, 452
deformities in, secondary, 440
deformity in, reduction of, 445
diagnosis of, 443
from arthritis deformans, 444
from Charcot's disease, 444
Knee-joint, tuberculous disease of, diagnosis of, from hemarthrosis, 443
from hysterical joint, 444
from infectious arthritis, 443
from injury of knee, 443
from rheumatism, 443
from sarcoma, 444
from synovitis, 443
from syphilis, 444
distortions in, 439
etiology of, 437
excision in, 455
extra-articular disease and, 452
forcible correction by reverse leverage in, 445
knock-knee and, 440
limitation of motion in, 439
limp in, 438
mortality in, 458
occurrence of, 437
pain in, 438
passive congestion in, 452
pathology of, 435
plaster splint in, 445
prognosis of deformity in, 457
rotation of tibia upon femur and, 440
subluxation of tibia and, 440
symptoms of, 438
synovial, 453
Thomas brace in, 448
traction in, 446
treatment of, 444
accessory, 451
Bier's, 452
during convalescence, 452
mechanical, 448
operative, 453
roentgen-rays in, 451
Knight brace in treatment of genu varum, 657
Knock-knee, 636, 642
adolescent, 643
attitude in, accommodative, 644
of rest in, 638
braces in, 649
changed relation of femur and tibia in, 643
deformity in, outgrowth of, 639
predisposition to, 637
secondary, 644
exercise in, 638
gait in, 645
manipulation in, 648
measurements in, 647
onset of, 636
osteoclasis in, 653
osteotomy in, 652
pathology of, 647
posture in, 648
symptoms of, 642
treatment of, 647
expectant, 647
operative, 652

Knock-knee, tuberculous disease of hip-joint and, 416
knee-joint and, 440
unilateral, 645
with bow-legs and general rhachitic distortions, 646
Wolff's treatment of, 654
Köhler's disease, 497
of head of metatarsal bone, 498, 837
König's statistics of tuberculous disease of hip-joint, 339
Krogius's operation for slipping patella, 483
Kümmel's disease, 118
Kyphosis, 234
in rhachitis, 556
of adolescents, 127
postural, 235
symptoms of, 235
treatment of, 237

L

Laminectomy in treatment of tuberculous disease of spine, 105
Landmarks of spine, 31
"Late rickets," 559
Lateral curvature of spine, 146. *See* Spine, lateral curvature of.
ligaments of knee, rupture of, 471
Leg, muscles of, paralysis of, in acute anterior poliomyelitis, treatment of, 680
nerves of, surgery of, 1031
Legg-Perthes' disease, 429
Legs, deformity of, weak foot in childhood and, 782
Leontiasis ossea, 575
Leriche's operation, 824
Ligaments of knee, rupture of, 471
of patella, elongation of, 485
Ligamentum teres in congenital dislocation at hip-joint, 579
Limbs, artificial, 986
Limp in congenital dislocation at hip-joint, 582
in coxa vara, 621
in tuberculous disease of ankle-joint, 491
of hip-joint, 333
of knee-joint, 438
intermittent, 823
Liston splint, 1005
Loeffler's operation for outward rotation of limb in acute anterior poliomyelitis, 706
Long plaster cock-up splint, 971
Loop operation in acquired talipes equinovalgus, 912
Loose bodies in knee-joint, 468
Lordosis, 238
treatment of, 240
tuberculosis of hip-joint and, 416
Lorenz apparatus in treatment of tuberculous disease of spine, 58
Lorenz operation for congenital dislocation of hip, 589
spica in treatment of tuberculous disease of hip-joint, 383
Lumbago, 134
diagnosis of, from tuberculous disease of spine, 40
Lund swathe, 971
Luxation of clavicle, acquired, 248
treatment of, 248

M

MacAusland's operation of arthroplasty in ankylosis of joints, 321–323
Malformation of pectoral muscles, 245
of vertebræ, 242
Malignant disease about hip-joint, 422
of bone, 324
of spine, 114
Malleotomy in neglected talipes, 881
Mallet finger, 548
Marmorknochen, 570
Measurements, table of, 347
Meningitis, cerebrospinal, diagnosis of, from tuberculous disease of spine, 59
Metatarsal arch, anterior, depression of, 808
weakness of, 808
bone, head of, Köhler's disease of, 498, 837
bones, fracture of, 837
Metatarsalgia, anterior, 808
etiology of, 809
foot-plate in, 814
influence of shoe in causing disability and pain, 812
pathology of, 809
plaster splint in, 815
treatment of, 813
Metatarsus varus, 831
Michaelis' triangle, 175
Miller's operation for rigid weak foot, 801
Milray's disease, 900
Mollities ossium, 570
Motion at joints, range of, ankle and foot, 777
hip, Fig. 286, 327
knee, Fig. 387, 435
shoulder, Fig. 434, 506
spine, alto-axoid articulation, 51
Morbus coxæ, 327. *See* Tuberculous disease of hip-joint.
Morton's neuralgia, 808
Multiple cartilaginous exostoses, 566
myeloma of bone, 568
neuritis, 726
diagnosis of, from acute anterior poliomyelitis, 668
Murray's modification of Thomas' splint, 1004
Muscle-building exercises in lateral curvature of spine, 202
Muscles in congenital dislocation at hip-joint, 580

Muscles of arm, paralysis of, in acute anterior poliomyelitis, treatment of, 685
of foot, function of, 764
of hip, paralysis of, in acute anterior poliomyelitis, treatment of, 684
of leg, paralysis of, in acute anterior poliomyelitis, treatment of, 680
of thigh, paralysis of, in acute anterior poliomyelitis, treatment of, 681
pectoral, malformation of, 245
Muscular atrophy, progressive, 723
cramp of knee-joint in childhood, 461
dystrophy, 724
diagnosis of, from tuberculous disease of spine, 41
paralysis, pseudohypertrophic, 724
spasm in tuberculous disease of hip-joint, 333
of spine, 46
in weak foot, 779
Myelitis, transverse, diagnosis of, from acute anterior poliomyelitis, 668
Myeloma of bone, multiple, 568
Myelopathic atrophy, 724
paralysis, 724
Myopathic paralysis, 724
Myositis ossificans, 324

N

Napier brace in treatment of genu varum, 657
Neck, deformities of, in acute anterior poliomyelitis, 675
of femur, depression of, 614
snapping, 247
Nélaton's line, relation of, 617
Nerve grafting in treatment of acute anterior poliomyelitis, 709
Nerves in lower axilla, surgery of, 1022
half of upper arm, surgery of, 1024
in upper half of arm, surgery of, 1022
injury of, surgery of, 1016
of leg, surgery of, 1031
palmar, surgery of, 1028, 1029
peripheral, ratings for, 958
surgery of, 1018
Nervous system, diseases of, 662
Neuralgia, Morton's, 808
etiology of, 809
influence of shoe in causing disability and pain, 812
pathology of, 809
treatment of, 813
plantar, 821
treatment of, 822
Neuritis, 727
multiple, 726
diagnosis of, from acute anterior poliomyelitis, 668
Neuritis of spine, 136
Neuroses, vasomotor trophic, of foot, 822
Neurotic joints, 731
spine, 728
Nicola's operation for recurrent dislocation of shoulder, 539
Night cry in tuberculous disease of hip-joint, 332
of spine, 25
Non-tuberculous affections of hip-joint, 418
of knee-joint, 461
of spine, 114
disease of joints, 279

O

Ober's operation for club-foot, 881
Obstetrical injury to brachial plexus, repair of, 532
paralysis, 525
deformity in, reduction of, 528
diagnosis of, from acute anterior poliomyelitis, 669
treatment of, 526
Ocular torticollis, 755
Opisthotonos, cervical, 754
Orr treatment of osteomyelitis, 292
Os calcis, stripping of, 806
Osgood-Schlatter disease, 476
Osteitis, chronic sclerosing, 293
deformans, 572
localized, 574
of spine, 129
treatment of, 575
fibrosa, 423, 566
diagnosis of, roentgen-rays in, 566
Osteo-arthritis, 295
of hip-joint, 424
of spine, 120, 125
Osteo-arthropathy, secondary hypertrophic, 575
Osteochondritis deformans coxæ juvenilis, 429
dissecans, 468
diagnosis of, 468
etiology of, 468
roentgen-rays in, 468, 469
symptoms of, 468
treatment of, 468
ischiopubica, 434
syphilitic, 279
Osteochondromatosis, 469
Osteoclasis in treatment of bow-legs, 658
of genu valgum, 653
varum, 658
of knock-knee, 653
of neglected talipes, 879, 880
Osteoclast, Grattan's, 653
Osteogenesis imperfecta, 568
Osteomalacia, 570
hunger, 571
in childhood, 570
treatment of, 571

BOSTON CITY

Osteomalacia, local, 571
senile, 571
Osteomyelitis, acute, 289
of spine, 116
prognosis of, 292
symptoms of, 290
treatment of, 290
chronic, 292
treatment of, 292
hemorrhagic, 294
treatment of, Orr, 292
Osteoplastic buttress in congenital dislocation of hip, 609
Osteopsathyrosis, idiopathic, 568
Osteosclerosis fragilis generalisata, 570
Osteotomy for coxa vara, 625, 626
Hoke's multiple, 890
in congenital dislocation at hip-joint, 612
in treatment of acute anterior poliomyelitis, 709
of genu valgum, 652
varum, 658
of knock-knee, 652
of neglected talipes, 887–890
Overlapping toes, 836

P

Pain in achillobursitis, 817
in back, 132
in congenital dislocation at hip-joint, 585
in degenerative arthritis, 299
in displacement of semilunar cartilage, 464
in hypertrophic arthritis, 299
in hysterical hip, 730
in ischemic paralysis and contraction, 550
in neurotic spine, 728
in painful heel, 820
in periarthritis of shoulder, 517
in plantar neuralgia, 821
in sacro-iliac disease, 136
in sprain of ankle-joint, 599
of wrist-joint, 522
in tuberculous disease of elbow-joint, 511
of hip-joint, 332
of knee-joint, 438
of shoulder-joint, 508
of spine, 25, 35, 45, 48
of wrist-joint, 516
Painful great toe, 826
in older subjects, 827
heel, 820
treatment of, 821
shoulder, 517
warts, 816
Palmar nerves, surgery of, 1028, 1029
Paralysis, abductor, Dickson's operation for, 700
Aran-Duchenne type of, 724
Charcot-Marie-tooth type of, 724
Paralysis, diphtheritic, diagnosis of, from acute anterior poliomyelitis, 668
from tuberculous diseases of spine, 55
torticollis and, 754
in acute anterior poliomyelitis, 644
effect of, 671
in tuberculous disease of spine, 26
myelopathic 724
myopathic, 724
obstetrical, 525
deformity in, reduction of, 528
diagnosis of, from acute anterior poliomyelitis, 669
treatment of, 526
of childhood, cerebral, 711
acquired, 711
congenital, 711
diagnosis of, from acute anterior poliomyelitis, 668
distribution of, 711
etiology of, 711
pathology of, 711
prognosis of, 722
symptoms of, 712
treatment of, 716
of muscles of arm in acute anterior poliomyelitis, treatment of, 685
of hip in acute anterior poliomyelitis, treatment of, 684
of leg in acute anterior poliomyelitis, treatment of, 680
of thigh in acute anterior poliomyelitis, treatment of, 681
of upper arm, operation for, 708
pseudohypertrophic muscular, 724
diagnosis of, 725
treatment of, 726
spastic, 711. *See* Cerebral paralysis of childhood.
spinal, 723
Paralytic deformities, review of operative procedures for relief of, 947
elevation of scapula, 242
scoliosis in acute anterior poliomyelitis, treatment of, 685
talipes, 918
arthrodesis in, 923
astragalectomy and backward displacement in, 924
deformity in, development of, 918
etiology of, 918
Judson brace in, 920
silk ligaments in, 923
symptoms of, 919
tendon fixation in, 923
transplantation in, 923
treatment of, 919
operative, 921
Whitman's operation for, 924
Willett's operation for, 922
torticollis, 754
Paraplegia, ataxic, 726

Paraplegia in cerebral paralysis of childhood, treatment of, 718
Pott's, 99
diagnosis of, from acute anterior poliomyelitis, 668
primary spastic spinal, diagnosis of, from tuberculosis, 56
spastic spinal, diagnosis of, from acute anterior poliomyelitis, 668
Patella, absence of, 481
treatment of, 481
biparta, 481
chondromalacia of, 477
displacements of, 481
ligament, elongation of, 485
etiology of, 485
symptoms of, 486
treatment of, 486
rudimentary, 481
treatment of, 481
slipping, 482
etiology of, 482
symptoms of, 483
treatment of, 483
Krogius's operation for, 483
Pectoral muscles, malformation of, 245
Pectus carinatum, 246
excavatum, 247
Pelvis, abscess of, diagnosis of, from tuberculosis of spine, 42
in tuberculosis of spine, 40
diseases of, diagnosis of, from tuberculous disease of hip-joint, 352
in congenital dislocation at hip-joint, 580
inclination of, 31
Periarterial sympathectomy, 824
Periarthritis of shoulder, 517
inflammation of subdeltoid bursa in, 519
pain in, 517
symptoms of, 517
treatment of, 519
Perineal band in tuberculous disease of hip-joint, 361
crutch, Judson's, 392
Perinephritic abscess, diagnosis of, from tuberculous disease of spine, 42
Peripheral nerve injuries, surgery of, 1018
ratings, 958
Peroneal atrophy, 726
tendons, displacement of, 841
treatment of, 841
Perthes' disease, 429
diagnosis of, from tuberculous disease of hip-joint, 351
Pes planus, 780
Phalanges of fingers, congenital displacement of, 547
Phelps' bed in treatment of tuberculous disease of spine, 58
operation in treatment of neglected talipes, 885
Pigeon breast in rhachitis, 555
chest, 246
Pigeon chest in tuberculosis of spine, 45
toe, 829
Plantalgia, 821
Plantar flexed foot, 847
neuralgia, 821
treatment of, 822
Plaster bandages in treatment of infantile talipes, 861
cast in treatment of weak foot, 788
cock-up splint, 971
jacket in treatment of tuberculous disease of spine, 66
splint in treatment of tuberculous disease of knee-joint, 445
strapping in treatment of rigid weak foot, 799
of sprain of ankle-joint, 500
supports in treatment of tuberculous disease of hip-joint, 378
Pleurisy, diagnosis of, from tuberculous disease of spine, 48
Pneumonia, diagnosis of, from tuberculous disease of spine, 48
Poliomyelitis, acute anterior, 662
age in, 663
arthrodesis in, 706
deformities in, 675
cause of, 672, 674
reduction of, 687
diagnosis of, 667
from amyotonia congentia, 669
from diphtheritic paralysis, 668
from joint diseases, 668
from multiple neuritis, 668
from obstetrical paralysis, 669
from paralysis of cerebral origin in childhood, 668
from Pott's paraplegia, 668
from pseudoparalysis, 669
from rheumatism, 668
from spastic spinal paraplegia, 668
from transverse myelitis, 668
from tuberculous disease of hip-joint, 351
from weakness, 669
distortions in, compensatory, 678
electrical test in, 670
muscle and tendon transplantation in, 692
training in, 685
muscular action and gravity in, 672
nerve grafting in, 709
osteotomy in, 709

Poliomyelitis, acute anterior, paralysis in, distribution of, 664
effect of, 671
of deltoid muscle in, transplantation of trapezius for, 692
of hip in, treatment of, 684
of leg in, treatment of, 680
of muscles of arm in, treatment of, 685
of thigh in, treatment of, 681
paralytic scoliosis in, treatment of, 685
posture in, 673
prognosis of, 669
retardation of growth in, 676
season in, 663
silk ligaments in, 706
subluxation in, 675
symptoms of, 665
Thomas caliper brace in, 691
knock-knee brace in, 691
transplantation of hamstring muscles in, 694
of trapezius in, 692
treatment of, 678
operative, 687
review of, 709
Polyarthritis, chronic, diagnosis of, from tuberculosis of hip-joint, 352
Still's, 303
Popliteal region, bursæ in, 475
cysts in, 475
Posterior achillobursitis, 819
Postural equinus, 803
kyphosis, 235
Posture in acute anterior poliomyelitis, 673
Pot belly in rhachitis, 556
Pott's disease, 17. *See* Tuberculous disease of spine.
paraplegia, 99
diagnosis of, from acute anterior poliomyelitis, 668
Prepatellar bursitis, 474
treatment of, 475
Pretibial bursa, superficial enlargement of, 475
bursitis, 475
symptoms of, 475
treatment of, 475
Progressive muscular atrophy, 723
Proliferative arthritis, 295
Pronated foot, 767
Pronation of forearm, congenital, 540
treatment of, 541
Pseudo-arthrosis, 661
Pseudohypertrophic muscular paralysis, 724
Pseudoparalysis, diagnosis of, from acute anterior poliomyelitis, 669
in rhachitis, 557
Psoas contraction in tuberculous disease of spine, 35
Psychical torticollis, 755
Puerperal arthritis, 286

Q

"Quiet effusion" at knee-joint, 463

R

Radius, displacement of, congenital, 540
subluxation of, 543
Rainbow frame, 975
Range of motion at atlo-axoid joints, 51
at foot, 760
at hip, 327
at knee, 435
Raynaud's disease, 822
Reconstruction operation, 981
for arthritis deformans, 992
Reconstructive treatment, 1046
baths in, 1047
chemical agents in, 1048
diathermy in, 1048
electricity in, 1051
exercise in, 1049
forcible movement under anesthesia, 1051
heat in, 1048
ionization in, 1050
lights in, 1047
massage in, 1048
mechanical agents in, 1048
vibration in, 1049
passive movements in, 1051
productive work in, 1051
superheated air in, 1047
thermic agents in, 1047
ultra-violet rays in, 1050
voluntary exercise in, 1050
weight-bearing in, 1050
Recurrent dislocation of shoulder, 534
synovitis of knee-joint, 462
Renal rickets, 559
Respiration in tuberculous disease of spine, 46
Retardation of growth in acute anterior poliomyelitis, 676
Retrocalcaneobursitis, 816
Rhachitic kyphosis, 129
lateral curvature of spine, 166
rosary in rhachitis, 554
spine, 128
attitude in, 129
natural cure of, 129
treatment of, 128
torticollis, 754
Rhachitis, 553
acute, diagnosis of, from tuberculous disease of spine, 43

Rhachitis, age of onset in, 553
attitude in, 557
caput quadratum in, 555
craniotabes in, 555
cubitus valgus in, 556
varus in, 556
deformities in, 554
distortions of lower limb, 661
"double joints" in, 554
etiology of, 553
Harrison's groove in, 556
kyphosis in, 556
pathology of, 553
pigeon breast in, 555
pot belly in, 556
prognosis of, 558
pseudoparalysis in, 557
rhachitic rosary in, 554
scoliosis in, 556
symptoms of, 554
treatment of, 558
"Rheumatism," 307
anterior metatarsalgia and, 813
diagnosis of, from acute anterior poliomyelitis, 668
from tuberculosis of ankle-joint, 492
of hip-joint, 351
of knee-joint, 443
gonococcal, 283
tuberculous, 268
Rheumatoid arthritis, 295
of spine, 124
Ribs, abnormalities of, 243
absence of, 244
cervical, 243
Rice bodies in tuberculous disease of joints, 267
Rickets, 553. *See* Rhachitis.
late, 559
scurvy, 560. *See* Infantile scorbutus.
Rigid weak foot, 792
adjuncts in, 798
manipulation in, 795
Miller's operation in, 801
overcorrection in, forcible, 793
functional use in, 794
plaster strapping in, 799
Thomas', 798
treatment of, 742
varieties of, 797
Roentgen-rays in diagnosis of osteitis fibrosa, 566
of tuberculous disease of bones, 271
of joints, 271
in dyschondroplasia, 565
in fracture of tarsal bones, 502
in osteochondritis dessecans, 468
in sprain of wrist-joint, chronic, 522
in treatment of tuberculous disease of bones, 275
of joints, 275
Rollier's sunlight treatment, 271
Rotary lateral curvature, 148
Rotation in lateral curvature of spine, 150
Round back, 233
hollow, 233
shoulders, 235
diagnosis of, from tuberculous disease of spine, 47
Rudimentary patella, 481
Rupture of ligaments of knee, 471
of spinal ligaments, 118
of tendo Achillis, 820
Rydygier incision for excision of hip in tuberculosis, 402, 403

S

Sacro-iliac articulation, injury or weakness of, 139
Gaenslen's operation for, 145
disease, 137
abscess in, 137
diagnosis of, 137
pain in, 137
prognosis of, 137
symptoms of, 137
treatment of, 137
Sarcoma of bone, 324
of femur, 422
of knee-joint, diagnosis of, from tuberculosis, 444
Scapula, congenital elevation of, 240
etiology of, 241
treatment of, 241
paralytic elevation of, 242
Scapular crepitus, 248
Scapulohumeral periarthritis, 517
Scarlatina arthritis, 286
Schede splints, 1042
Schlatter's disease, 476
Schultze pelvic support for plaster spica in treatment of tuberculous disease of hip-joint, 382
Sciatic scoliosis, 135
Sciatica, deformity secondary to, 135
treatment of, 135
diagnosis of, from tuberculous disease of spine, 40
Sclerosing osteitis, chronic, 294
Sclerosis, combined subacute, 727
Scoliosis, 148. *See* Spine, lateral curvature of.
hysterical, 729
in rhachitis, 556
paralytic, in acute anterior poliomyelitis, treatment of, 685
sciatic, 135
Scorbutus, 308
infantile, 560
pathology of, 560
symptoms of, 560
treatment of, 560
Scurvy, diagnosis of, from tuberculosis of hip-joint, 351
of spine, 43

Scurvy rickets, 560
Secondary hypertrophic osteoarthropathy, 575
Self-correction exercises in lateral curvature of spine, 195
Semilunar cartilages, cysts of, 470
displacement of, 464
Campbell brace in, Fig. 268, 313, 467
pain in, 464
treatment of, 466
external, cysts of, 470
Senile osteomalacia, 571
Septic infection in tuberculous disease of bones, 268
of joints, 268
Sesamoid bones, injury to, 828
Shenton's line, 620
Shoe, high, in treatment of tuberculous disease of hip-joint, 351
in treatment of weak foot, 785
Shoes, 841
flat sole, 844
for normal feet, 842
for shoemaker's feet, 842
hallux valgus and, 832
rocker sole, 844
Shoulder, dislocation of, congenital, 525
recurrent, 534
treatment of, 535
Nicola's operation for, 539
fracture at, treatment of, 986
high, in lateral curvature of spine, 153
painful, 517
periarthritis of, 517
inflammation of subdeltoid bursa in, 519
pain in, 517
symptoms of, 517
treatment of, 519
snapping, 520
stiff, 517
Shoulder-joint, bursitis of, chronic, 521
range of motion at, Fig. 434, 506
tuberculous disease of, 506
age in, 508
atrophy in, 508
pain in, 508
pathology of, 506
prognosis of, 510
restriction of motion in, 508
sensitiveness in, 508
symptoms of, 508
treatment of, 508
Shoulders, round, 235
Silk ligaments in treatment of acute anterior poliomyelitis, 706
of paralytic talipes, 923
of talipes calcaneus, 923
equinus, 908
Sinuses in tuberculous disease of hip-joint, 400
Slipping patella, 482
Smith-Peterson operation for injury of sacro-iliac articulation, 143
Snapping, finger, 547
hip, 614
jaw, 247
knee, 486
neck, 247
shoulder, 520
thumb, 548
Socks, 845
Spanish windlass, 1002
Spasm, muscular, in tuberculous disease of spine, 46
Spasmodic torticollis, 738, 746
Spastic paralysis, 711
diagnosis of, from tuberculous disease of spine, 55
spinal paralysis, 723
diagnosis of, from acute anterior poliomyelitis, 668
paraplegia, diagnosis of, from tuberculosis, 56
Spina bifida, talipes and, 900
ventosa, 517
Spinal cord, length of, 31
ligaments, rupture of, 118
paralysis, spastic, 723
diagnosis of, from acute anterior poliomyelitis, 668
paraplegia, spastic, primary, diagnosis of, from tuberculosis, 56
Spine, actinomycosis of, 117
arthritis of, 120
treatment of, 120
articulations of, infectious diseases of, 119
carcinoma of, 114
diagnosis of, 115
contour of, variations in, 233
coverings of, infectious diseases of, 119
deformities of, anterior-posterior, 234
deviation of, in tuberculosis, 47
divisions of, 29
fracture of, 117
hysterical, 729
symptoms of, 729
injury of, treatment of, 118
kyphosis of, 129
landmarks of, 31
lateral curvature of, 148
age in, 160
changes in anterior-posterior contour in, 152
compensatory deformity and, 161
congenital, 165
definition of, 148
deformity elsewhere and, 161
prevention of, 177
varieties of, 170
description of, 148
deviation in, 150
diagnosis of, 173

Spine, lateral curvature of, disease within thoracic walls and, 163
etiology of, 158
exercises in, body-inclination to left, 196
chest pressing with right hand, 198
head bending backward, 195
horizontal bar pull-ups, 205
left hip twisting backward, 198
leg hopping, 208
standing, pelvis, tilting, 205
neck firm, 195
oblique stride, standing, 199
muscle building, 202
opposite bend standing, trunk, raising, resisted, 202
sitting, backward bending of trunk, 205
standing, head bending backward, resisted, 202
prone lying, diving, 205
head and shoulder raising, the seal, 202
leg raising, 205
respiratory, half-reclining-arm extensions and flexions, resisted, 208
right neck firm, 198
self-correction, 195
trunk bending forward, 199
hereditary influence in, 168
high hip in, 153
shoe in, 232
shoulder in, 153
incidental, 165
occupation and, 165, 166
paralysis and, 162
pathology of, 153
prognosis of, 175
relative frequency of, 158
rhachitic, 166
treatment of, 178
rotation in, 150
sex in, 159
symptoms of, 172
treatment of, 178
Abbott, 212
corrective, combined with support, 208
duration of, 232
general, 232
operative, 226
posture in, 180
principles of, 178
removal of superincumbent weight in, 231
self-suspension in, 231
Spine, lateral curvature of, treatment of, supplemental, 231
support during recumbency in, 232
Volkmann seat in, 231
tuberculous disease of hip-joint and, 416
malignant disease of, 114
neurotic, 728
pain in, 728
sensitiveness in, 728
symptoms of, 728
treatment of, 729
non-tuberculous affections of, 114
osteitis deformans of, 129
osteo-arthritis of, 120, 125
osteomyelitis of, acute, 116
symptoms of, 116
treatment of, 117
range of motion at, 51
rhachitic, 118
attitude in, 129
natural cure of, 129
rheumatism of, gonococcal, 120
rheumatoid arthritis of, 124
rotary-lateral curvature of, diagnosis of, from tuberculosis, 48
surgery of, 950
syphilis of, 114
tabetic deformity of, 129
tuberculous disease of, 17
abscess in, 26, 94
course and peculiarities of, in different regions, 95
treatment of, 96
age at onset, 25
attitude in, change of, 25
awkwardness in, 25
case record in, 56
complications of, 94
contour of spine in, 26
deformity in, 17, 26
bone, 26
compensatory, 26
later effects of, 112
muscular, 26
secondary, 113
diagnosis of, from cerebrospinal meningitis, 36
from cervical opisthotonos, 54
from congenital dislocation of hip-joint, 587
from diphtheritic paralysis, 55
from primary spastic spinal paraplegia, 56
from pseudohypertrophic muscular dystrophy, 55
from spastic paralysis, 55
from tuberculous disease of hip-joint, 352
from vertebral epiphysitis of adolescence, 47
general, 55

Spine, tuberculous disease of, diagnosis of, roentgen-ray photography in, 56
etiology of, 20
examination in, regional, 34
flexibility of spine in, 28
frequency of, 20
impairment of function in, 25
in lower cervical region, 52
region, 34
attitude in, 34
diagnosis of, 40
from acute rhachitis, 43
from appendicitis, 42
from bilateral congenital dislocation of hip, 41
from hernia, 43
from hip disease, 41
from lumbago, 40
from muscular dystrophies, 41
from pelvic abscess, 42
from perinephritic abscess, 42
from sacro-iliac disease, 41
from sciatica, 40
from scurvy, 43
from spondylitis deformans, 41
from spondylolisthesis, 41
from strain of back, 40
lateral inclination of body in, 36
lordosis in, 34
pain in, 35
peculiarities of, in infancy, 43
pelvic abscess in, 40
psoas contraction in, 35
stiffness in, 37
stooping in, 37
symptoms of, 48
treatment of, 92
weakness in, 37
in middle and upper dorsal region, treatment of, 92
in occipito-axoid region, 25
treatment of, 93
in thoracic region, 44
abscess in, 47
attitudes in, 44
deviation of spine in, 47
diagnosis of, 47
from empyema, 48
from pleurisy, 48
from pneumonia, 48
from rotary-lateral curvature, 48
from round shoulders, 47
muscular spasm in, 46
pain in, 45
Spine, tuberculous disease of, in thoracic region, pigeon chest in, 45
respiration in, 46
symptoms of, 48
in upper dorsal and middle cervical region, treatment of, 93
region, 49
attitude in, 50
diagnosis of, 52
from abscess, 55
from arthritis, 55
from cervical opisthotonos, 54
from injury, 54
from torticollis, 53
pain in, 49
stiff neck in, 49
symptoms of, 49
summary of, 55
loss of mobility in, 25
night cry in, 25
paralysis in, 26, 99
duration of, 102
frequency of, 101
laminectomy in, 105
liability to, in different regions, 101
local, 107
prognosis of, 104
symptoms of, 102
time of onset of, 102
treatment of, 104
pathology of, 18
physical signs of, 32
prognosis of, 23
rational signs of, 31
recurrence of, 112
sex in, 22
situation of, 22
stiffness in, 25
symptoms of, 24
complicating, 26
general, 28
secondary, 26
treatment of, 57
ambulatory supports in, 66
Bradford bed frame in, 59
Calot jacket in, 72
application of, 75, 78
comparison of the two forms of ambulatory support in, 88
convex stretcher frame in, 59
corset in, other than plaster of Paris, 81
duration of, 111
horizontal fixation in, 58
jury-mast in, 69
Lorenz apparatus in, 58
mechanical, 57
operative, 107
Phelps bed in, 58
plaster corset in, 79

Spine, tuberculous disease of, treatment of, plaster jacket in, 66
principles of, in their practical application, 89
by recumbency, indications for, 89
Taylor back brace in, 81
Thomas collar in, 89
weak foot and, 113
weakness in, 25
tumors of, 114
typhoid, 119
diagnosis of, 119
treatment of, 119
Splay-foot, 767
Splints, Billroth, in treatment of tuberculous, disease of knee-joint, 446
in orthopaedic surgery, 969–977, 998–1014, 1042–1044
in treatment of infantile talipes, 863
plaster, in treatment of tuberculous disease of knee-joint, 445
Taylor's hip, 390
convalescent, 390
Spondylitis deformans, 120
diagnosis of, from tuberculous disease of spine, 41
pain in, 123
pathology of, 120
symptoms of, 123
treatment of, 126
types of, 124
superficialis, 18
traumatic, 118, 122
symptoms of, 118
treatment of, 118
Spondylolisthesis, 129
diagnosis of, from tuberculous diseases of spine, 41
etiology of, 131
treatment of, 131
Spontaneous dislocation of hip-joint, 420
Sprain of ankle-joint, 499
adhesive-plaster strapping in, 500
chronic, 501
diagnosis of, from tuberculosis, 492
pain in, 499
stockinette bandage in, 499
of wrist-joint, 522
chronic, 522
roentgen-rays in, 522
pain in, 522
Sprengel's deformity, 240
etiology of, 241
treatment of, 241
Steindler's operation in acute anterior poliomyelitis, 708
for contracted foot, 806
Stiff shoulder, 517
Stiffness in tuberculous disease of ankle-joint, 491
of elbow-joint, 511
of hip-joint, 333
of spine, 37
Stiffness of vertebral column, 120
Still's disease, 303
Stockinette bandage in treatment of sprain of ankle-joint, 499
Stocking extension, 1040
Strain of back, diagnosis of, from tuberculous disease of spine, 40
of tendo-Achillis, 820
Stretcher bearer's drill, 999–1002
Stripping of os calcis, 806
Stumps, preparation of, for artificial limbs, 1011
Subacute arthritis of hip-joint, 420
combined sclerosis, 727
Subastragaloid joint, tuberculosis of, 491
Subcutaneous tenotomy in treatment of neglected talipes, 882
Subluxation of clavicle, 248
of hip, congenital, 613
of radius, 543
of tibia and tuberculous disease of knee-joint, 440
of wrist, 542
Subungual exostoses of foot, 837
Supernumerary bones of foot, 838
Supracotyloid congenital dislocation at hip-joint, 587
Suspension frame, portable, 1039
Swelling about ankles, 504
Sympathetic ganglionectomy, 825
Synovial tuberculosis of knee-joint, 453
Synovitis of knee-joint, 461
acute, 461
chronic, 462
diagnosis of, from tuberculosis, 443
incidental, 462
painless, 463
recurrent, 462
Syphilis of joints, 279
congenital, 280
hereditary, 280
occurrence of, 281
Clark's report on, 282
of knee-joint, diagnosis of, from tuberculosis, 444
of spine, 114
Syphilitic osteochondritis, 279

T

Tabetic arthropathy, 309
diagnosis of, 311
distribution of, 310
pathology of, 309
symptoms of, 311
treatment of, 311
deformity of spine, 129
Table of age of incipience in tuberculous disease of elbow-joint, 510
of shoulder-joint, 508
of wrist-joint, 516
for estimating degree of flexion in tuberculous disease of hip-joint, 350

Table for estimating of lateral distortion in tuberculous disease of hip-joint, 348
of circumference of chest in childhood, 256
of frequency of acquired talipes, 854
of congenital talipes, 854
of height in childhood, 256
of length of bones in tuberculous disease of hip-joint, 345
of measurements, 345
of strength of muscles of foot, 765
of weight, height and circumference of chest in childhood, 256
Talipes, 846
acquired, 848, 901
deformity in, development of, 901
diagnosis of, from congenital, 902
etiology of, 901
frequency of, table of, 854
arcuatus, 803
calcaneovalgus, 847
acquired, 930
arthrodesis in, 945
tendon implantation in, 944
transplantation in, 932
treatment of, 931
congenital, 896
calcaneovarus, 847
acquired, 930
arthrodesis in, 945
tendon implantation in, 944
transplantation in, 932
treatment of, 931
congenital, 896
calcaneus, 847
acquired, 918
arthrodesis in, 923
astragalectomy and backward displacement in, 924
deformity in, development of, 918
etiology of, 918
Judson brace in, 920
silk ligaments in, 923
symptoms of, 919
tendon fixation in, 923
transplantation in, 923
treatment of, 919
operative, 921
Whitman's operation for, 924
Willett's operation for, 922
congenital, 895
cavus, 803
congenital, 896
congenital, 848
etiology of, 849
frequency of, table of, 853
equinocavus, congenital, 896
equinovalgus, 847, 896
acquired, 912
loop operation in, 912
Talipes, equinovalgus, congenital, absence of fibula and, 896
etiology of, 897
treatment of, 898
equinovarus, 847
acquired, 910
treatment of, 910
anatomy of, 855
congenital, 855
absence of tibia and, 899
treatment of, review of, 891
infantile, treatment of, 860
symptoms of, 858
treatment of, 858
equinus, 847
acquired, 903
arthrodesis in, 909
astragalectomy and backward displacement in, 910
Campbell operation for, 909
deformity in, correction of, 905
etiology of, 904
silk ligaments in, 908
symptoms of, 904
tendon displacement in, 909
implantation in, 908
treatment of, 905
operative, 908
congenital, 894
etiology of, 848
hysterical, 731
treatment of, 731
infantile, treatment of, 860
braces in, 863
first stage of, 860
Judson brace in, 864
manipulation in, 861
mechanical, 861
methodical manual correction in, 868
plaster bandage in, 861
rectification of deformity in, 860
restoration of function, 866
retention in, 867
second stage of, 866
splints in, 863
supervision in, 870
support in, 866
Taylor brace in, 868
tenotomy in, 865
third stage of, 870
neglected, treatment of, 870
age as influencing, 870
astragalectomy and, 887
division of tendo-Achillis in, 883
forcible manual correction in, 872
importance of functional use in, 876
Judson brace in, 891
malleotomy in, 881

Talipes, neglected, treatment of, open incision, method of, 884, 885
osteoclast in, 880
osteotomy in, 889, 890
Phelps' operation in, 885
rapid correction of deformity in, 871
secondary deformities in, 882
simple mechanical rectification of deformity in walking children and in later years, 890
subcutaneous tenotomy in, 882
Thomas' method of, 879
Wolff's method of, 878
wrenches in, 879
paralytic, 918
arthrodesis in, 923
astraglectomy and backward displacement in, 924
deformity in, development of, 918
etiology of, 918
Judson brace in, 920
silk ligaments in, 923
symptoms of, 919
tendon fixation in, 923
transplantation in, 923
treatment of, 912
operative, 921
Whitman's operation for, 924
Willett's operation for, 922
plantaris, 803
spina bifida and, 910
valgocavus, congenital, 896
valgus, 847
acquired simple, 917
congenital, 895
varieties of, 847
varus, 847
congenital, 893
absence of tibia and, 899
Tarsal bones, fracture of, 502
roentgen-rays in, 502
treatment of, 502
Tarsus, tuberculosis of, 496
treatment of, 497
Taylor back brace in treatment of tuberculous disease of spine, 81
club-foot brace, 868
convalescent hip splint, 393
hip brace in treatment of tuberculous disease of hip-joint, 362
hip splint, 390
on retardation of growth in tuberculous disease of hip-joint, 345
Tendinitis ossificans, 820
Tendo Achillis, division of, in neglected talipes, 883
rupture of, 820
treatment of, 820
strain of, 820
Tendon displacement in treatment of acquired talipes equinus, 909
fixation in treatment of acquired talipes calcaneus, 923
of paralytic talipes, 923
implantation in acquired talipes calcaneovarus, 944
in talipes equinus, 908
sheaths, tumors of, 504
transplantation, 1034–1038
in acquired talipes calcaneovalgus, 941
in paralytic talipes, 923
in talipes calcaneovalgus, 932
calcaneovarus, 932
calcaneus, 923
Tendons, peroneal, displacement of, 841
treatment of, 841
Tennis elbow, 521
Tenosynovitis, 502
of wrist-joint, 523
acute, 523
chronic, 523
treatment of, 504
tuberculous, 504
Tenotomy, subcutaneous, in treatment of neglected talipes, 882
in treatment of infantile talipes, 865
Tensor vaginæ femoris muscle, transplantation of, for paralysis of gluteus medius, 698
Thigh, muscles of, paralysis of, in acute anterior poliomyelitis, treatment of, 681
Thomas' brace in treatment of genu valgum, 650
of knock-knee, 650
of tuberculous disease of ankle-joint, 493
of knee-joint, 448, 449, 450
caliper brace in treatment of acute anterior poliomyelitis, 691
splint, 974
collar in treatment of tuberculosis of spine, 89
knee-splint, 1001
knock-knee brace in treatment of acute anterior poliomyelitis, 691
method of treatment of neglected talipes, 879
outfit for field service, 999–1004
personnel of, 999
splint, modification of, 1003, 1004
theory in arthritis deformans, 306
traction arm splint, 969
leg splint, 973
treatment of rigid weak foot, 798
of tuberculous disease of hip-joint, 373
modification of, 378
Thomas-Jones abduction hip splint, 1043
Thrombo-angiitis obliterans, 823
Thumb, snapping, 339
Tibia, anterior curvature of, 659
congenital, 661

Tibia, congenital absence of, talipes equinovarus and, 899
varus and, 899
displacement of, anterior, 478
subluxation of, tuberculous diseases of knee-joint and, 440
Tibial tubercle, injury of, 476
Toe, great, painful, 826
in older subjects, 827
hammer, 834
congenital, 835
symptoms of, 835
treatment of, 835
nail, ingrown, 836
pigeon, 829
Toes, overlapping, 836
treatment of, 836
Torticollis, 733
acquired, 733, 738
acute, 733, 738
etiology of, 738
spastic, 739
symptoms of, 740
treatment of, 745
chronic, 733
treatment of, 742
congenital, 733
etiology of, 736
hematoma of sternomastoid and, 736
pathology of, 738
deformity in, overcorrection of, 744
diagnosis of, 741
from arthritis, 742
from tuberculous diseases of spine, 52, 741
diphtheritic paralysis and, 754
hematoma in, treatment of, 743
irregular forms of, 738
mechanical, 738
ocular, 755
paralytic, 754
posterior, 740
psychical, 755
rhachitic, 754
simple, 738
spasmodic, 738, 746
etiology of, 747
Finney and Hughson's operation for, 749
pathology of, 747
prognosis of, 747
treatment of, 747
treatment of, 742, 745
Traction in tuberculous diseases of knee-joint, 445, 446
of hip-joint, 357, 358, 359, 361
Transplantation of muscles in treatment of paralysis of acute anterior poliomyelitis, 692–698
of tendon, 1034, 1038
Transverse myelitis, diagnosis of, from acute anterior poliomyelitis, 668
Traumatic coxa vara, 628
Traumatic genu recurvatum, treatment of, 478
spondylitis, 118, 122
Traumatisms at hip-joint, 418
Treatment of abscess in tuberculous disease of hip-joint, 399
of spine, 96
of absence of patella, 481
of achillobursitis, 817
of acquired genu recurvatum, 478
luxation of clavicle, 248
talipes calcaneovalgus, 930
calcaneovarus, 930
calcaneus, 919
equinovarus, 910
equinus, 905
of acute anterior poliomyelitis, 678
infectious arthritis of hip-joint, 419
synovitis of knee-joint, 461
of anchylosis of ankle-joint, 316
of hip-joint, 316
of knee-joint, 316
of anterior metatarsalgia, 813
of arthritis in infancy, 289
of suboccipital region of spine, 120
of atrophic arthritis, 300
of baseball-finger, 548
of bilateral disease of hip, 394
of bow-legs, 656
of cerebral paralysis of childhood, 716
of Charcot's disease of joints, 311
of chondrodystrophia, 564
of chronic sprain of ankle-joint, 501
of club-hand, 545
of coccygodynia, 147
of congenital club-foot, 858
contraction of fingers, 547
of knee, 486
dislocation at hip-joint, 588
in infancy, 598
in older subjects, 606
elevation of scapula, 241
genu recurvatum, 480
pronation of forearm, 541
of contracted foot, 806
of coxa vara, 624
of cysts of femur, 423
of deformity secondary to sciatica, 135
of degenerative arthritis, 300
of displacement of peroneal tendons, 841
of semilunar cartilage, 466
of Dupuytren's contraction, 550
of elongation of ligaments of patella, 486
of epiphyseal fracture of neck of femur, 629
of epiphysitis at hip-joint, 419
of exostoses of foot, 837
of flat chest, 245
of fracture of metatarsal bones, 837

Treatment of fracture of neck of femur, 629, 978
of tarsal bones, 502
of fragilitas ossium, 568
of genu valgum, 647
varum, 656
of gluteal bursitis of hip-joint, 422
of gonococcal arthritis, 285
rheumatism of spine, 120
of hallux rigidus, 827
valgus, 832
varus, 829
of hammer-toe, 835
of hemophilia, 308
of hyperplasia of knee-joint, 474
of hypertrophic arthritis, 300
of hysterical talipes, 731
of iliopsoas bursitis of hip-joint, 422
of infantile scorbutus, 560
talipes, 860
of injury of spine, 118
of ischemic paralysis and contraction, 551
of kyphosis, 237
of lateral curvature of spine, 178
of lordosis, 240
of mallet-finger, 548
of Morton's neuralgia, 813
of neglected club-foot, 870
of neurotic joints, 732
spine, 729
of obstetrical paralysis, 526
of osteitis deformans, 575
of osteo-arthritis of hip-joint, 426
of osteochondritis deformans juvenilis, 433
dissecans, 469
of osteomalacia in childhood, 571
of osteomyelitis, 290
of overlapping toes, 836
of pain in back, 134
of painful heel, 821
of paralysis of muscles of arm in acute anterior poliomyelitis, 685
of hip in acute anterior poliomyelitis, 684
of leg in acute anterior poliomyelitis, 680
of thigh in acute anterior poliomyelitis, 681
in tuberculous disease of spine, 104
of paralytic scoliosis in acute anterior poliomyelitis, 685
talipes, 919
of periarthritis of shoulder, 519
of pigeon chest, 246
of plantar neuralgia, 822
of prepatellar bursitis, 475
of pretibial bursitis, 475
of proliferating arthritis, 303
of pseudohypertrophic muscular paralysis, 726
of recurrent dislocation of shoulder, 535
Treatment of rhachitic spine, 128
of rhachitis, 558
of rigid weak foot, 792
of rudimentary patella, 481
of sacro-iliac disease, 137
of sinuses in tuberculous disease of hip-joint, 400
of slipping patella, 483
of snapping knee, 486
of spina ventosa, 517
of spondylitis deformans, 126
of spondylolisthesis, 131
of spontaneous dislocation of hip-joint, 421
of sprain of ankle-joint, 498
of wrist-joint, 522
of Sprengel's deformity, 241
of subluxation of clavicle, 248
of wrist, 543
of syphilis of joints, 283
of tabetic arthropathy, 311
of talipes equinovarus, 858
of tenosynovitis, 504
of torticollis, 742
of traumatic genu recurvatum, 478
spondylitis, 118
of traumatisms at hip-joint, 418
of trigger-finger, 548
of tuberculous disease of ankle-joint, 493
of bones, 271
of elbow-joint, 512
of hip-joint, 356
of joints, 271
of knee-joint, 444
of shoulder-joint, 508
of spine, 57
of tarsus, 497
of wrist-joint, 516
of "typhoid spine," 119
of weak foot, 784
of webbed fingers, 547
Trench foot, 822
treatment of, 823
Triangle, Bryant's, 620
of Michaelis, 175
Trick movements, 1034
Trigger-finger, 547
etiology of, 547
treatment of, 548
Trunk, deformities of, in acute anterior poliomyelitis, 675
Tubercle, tibial, injury of, 476
Tuberculin in treatment of tuberculous disease of bones, 273
Tuberculous arthritis, 289
disease of ankle-joint, 488
age in, 490
deformity in, 491
reduction of, 493
diagnosis of, 492
from arthritis deformans, 492
from flat-foot, 492
from infectious arthritis, 492

Tuberculous disease of ankle-joint, diagnosis of, from rheumatism, 492
from sprains, 492
etiology of, 489
limp in, 491
pathology of, 488
prognosis of, 494
stiffness in, 491
symptoms of, 480
Thomas' brace in, 493
treatment of, 493
of astragalonavicular joint, 492
of bones, 258
abscess in, 264
age in, 262
diagnosis of, 270
roentgen-ray in, 271
distribution of, 261
dry caries in, 267
etiology of, 258
latent, 258
mode of infection in, 258
pathology of, 263
predisposition to, 258, 260
prognosis of, 269
repair in, 269
septic infection in, 268
sex in, 262
side affected in, 262
treatment of, 271
Beck's, 274
drugs in, 273
mechanical, 273
operative, 273
roentgen-rays in, 275
sunlight in, 271
tuberculin in, 273
of elbow-joint, 510
age in, 510
atrophy in, 511
deformity in, 511
reduction of, 512
occurrence of, 510
pain in, 511
pathology of, 510
prognosis of, 513
sensitiveness in, 511
stiffness in, 511
swelling in, 511
symptoms of, 511
treatment of, 512
operative, 513
of hip-joint, 327
abscess in, 396
actual lengthening in, 346
shortening in, 343
age in, 331
apparent lengthening in, 335
shortening in, 336
atrophy in, 341
causing equinus, 416
genu recurvatum, 416
knock-knee, 416
lateral curvature, 416
laxity of ligaments, 416
Tuberculous disease of hip-joint, causing lordosis, 416
changes in contour of hip in, 341
debility in, 346
deformity in, correction of, 406
diagnosis of, 350
from anterior poliomyelitis, 351
from arthritis deformans of hip, 352
from congenital dislocation of hip, 353
from coxa vara, 353
from disease of bursæ, 353
from epiphyseal fracture, 353
from epiphysitis, 351
from extra-articular disease, 352
from fracture of neck of femur in childhood, 353
from gonococcal arthritis, 352
from growing pains, 351
from hysterical joint, 353
from infectious arthritis, 351
from Legg-Perthes' disease, 351
from local injury, 351
irritation, 350
from pelvic disease, 352
from chronic polyarthritis, 352
from rheumatism, 351
from sacro-iliac disease,352
from scurvy, 351
from synovitis, 351
from traumatic coxa vara, 353
from tuberculous disease of spine, 352
roentgen-rays in, 353
distortion of limb in, 333
estimation of, 348
etiology of, 331
examination in, 346
fever in, 346
frequency of, 331
history in, 346
in adults, 396
in infancy, 395
König's statistics of, 339
limp in, 333
local signs of, 350
measurements in, 347
mortality in, 411
muscular spasm in, 333
night cry in, 332
pain in, 332
pathology of, 327
physical signs in, 333
prognosis of, 411
reduction of deformity in, 363
retardation of growth in, 344
sex in, 331

Tuberculous disease of hip-joint, side affected in, 332
sinuses in, treatment of, 400
stiffness in, 333
symptoms of, 332
general, 346
treatment of, 356
amputation in, 405
Bradford brace in, 363
during stage of recovery, 390
functional results of, 413
high shoe in, 361
Judson brace in, 362
lateral traction in, 368
Lorenz spica in, 363
mechanical, 357
review of, 388
operative, excision, 402
perineal bands in, 361
plaster supports in, 378
Taylor hip brace in, 362
Thomas', 374
modification of, 378
traction hip splint in, 358
plasters in, 358
of joints, 258
abscess in, 264
active congestion in, 276
age in, 262
arborescent synovial, 266
Bier's hyperemia in, 276
Calot's fluid in, 274
diagnosis of, 270
roentgen-rays in, 271
distribution of, 261
dry caries in, 267
etiology of, 258
latent, 258
mode of infection in, 258
passive congestion in, 276
pathology of, 263
perforation in, 265
predisposition to, 258, 260
prognosis of, 269
repair in, 269
rice bodies in, 267
septic infection in, 268
sex in, 262
side affected in, 262
sunlight in, 271
treatment of, 271
mechanical, 273
operative, 273
roentgen-rays in, 275
of knee-joint, 435
abscess in, 453
actual lengthening in, 442
shortening in, 442
age in, 438
amputation in, 456
arthrectomy in, 453
Bier's treatment in, 452
Billroth splint in, 446
caliper brace in, 450
complications of, 452
Tuberculous disease of knee-joint, deformities in, secondary, 440
deformity in, reduction of, 445
diagnosis of, 443
from arthritis deformans, 444
from Charcot's disease, 444
from hemarthrosis, 443
from hysterical joint, 444
from infectious arthritis, 443
from injury of knee, 443
from rheumatism, 443
from sarcoma, 444
from synovitis, 443
from syphilis, 444
distortions in, 489
etiology of, 437
excision in, 455
extra-articular disease and, 452
forcible correction by reverse leverage in, 445
knock-knee and, 440
limitation of motion in, 439
limp in, 438
mortality in, 458
occurrence of, 437
pain in, 438
passive congestion in, 452
pathology of, 435
plaster splint in, 445
prognosis of, 457
rotation of tibia upon femur and, 440
subluxation of tibia and, 440
symptoms of, 438
synovial, 453
Thomas brace in, 448
traction in, 446
treatment of, 444
accessory, 451
during convalescence, 452
functional results of, 458
operative, 453
roentgen-rays in, 451
of shoulder-joint, 506
age in, 508
atrophy in, 508
pain in, 508
pathology of, 506
prognosis of, 510
restriction of motion in, 508
sensitiveness in, 508
symptoms of, 508
treatment of, 508
of spine, 17
abscess in, 26, 94
course and peculiarities of, in different regions, 95
treatment of, 96
age at onset of, 21
attitude in, change of, 25
awkwardness in, 25
complications of, 94
contour of spine in, 26
deformity in, 17, 26

Tuberculous disease of spine, deformity in, bone, 26
compensatory, 26
later effects of, 112
muscular, 26
secondary, 113
diagnosis of, from cerebrospinal meningitis, 56
from congenital dislocation of hip-joint, 587
from diphtheritic paralysis, 55
from primary spastic spinal paraplegia, 56
from pseudohypertrophic muscular dystrophy, 55
from spastic paralysis, 55
from tuberculous disease of hip-joint, 352
general, 55
roentgen-ray photography in, 56
etiology of, 20
examination in, regional, 34
flexibility of spine in, 28
frequency of, 20
history in, 32
impairment of function in, 25
in lower cervical region, 52
region, 34
attitude in, 34
diagnosis of, 40
from acute rhachitis, 43
from appendicitis, 42
from congenital dislocation of hip, 41
from hernia, 43
from hip disease, 42
from lumbago, 40
from muscular dystrophies, 41
from pelvic abscess, 42
from perinephritic abscess, 42
from sacro-iliac disease, 41
from sciatica, 40
from scurvy, 43
from spondylitis deformans, 41
from spondylolisthesis, 41
from strain of back, 40
lateral inclination of body in, 36
lordosis in, 34
pain in, 37
peculiarities of, in infancy, 43
pelvic abscess in, 40
psoas contraction in, 35
stiffness in, 37
stooping in, 37
symptoms of, 44
treatment of, 92
Tuberculous disease of spine, in lower region, weakness in, 37
in middle and upper dorsal region, treatment of, 92
in occipito-axoid region, treatment of, 93
in thoracic region, 44
abscess in, 47
attitudes in, 44
cough in, 47
deviation of spine in, 47
diagnosis of, 47
from empyema, 48
from pleurisy, 48
from pneumonia, 48
from rotary-lateral curvature, 48
from "round shoulders," 47
muscular spasm in, 47
pain in, 45
pigeon chest in, 45
respiration in, 46
symptoms of, summary of, 48
in upper dorsal and middle cervical region, treatment of, 93
region, 49
attitude in, 50
diagnosis of, 52
from abscess, 55
from arthritis, 55
from cervical opisthotonos, 54
from injury, 54
from torticollis, 53
pain in, 49
stiff neck in, 49
symptoms of, 49
loss of mobility in, 25
"night cry" in, 25
pain in, 25
paralysis in, 26, 99
duration of, 102
laminectomy in, 105
liability to, in different regions, 101
local, 107
prognosis of, 104
symptoms of, 102
time of onset of, 102
treatment of, 104
pathology of, 18
physical signs of, 32
prognosis of, 23
rational signs of, 31
recurrence of, 112
sex in, 22
situation of, 22
stiffness in, 25
symptoms of, 24
complicating, 26
general, 28
secondary, 26
treatment of, 57

Tuberculous disease of spine, treatment of, ambulatory supports in, 66
Bradford bed frame in, 59
by recumbency, indication for, 89
Calot jacket in, 72, 75
comparison of the two forms of ambulatory support in, 88
convex stretcher frame in, 59
corsets in, other than plaster of Paris, 81
duration of, 111
horizontal fixation in, 58
jury-mast in, 69
Lorenz apparatus in, 58
mechanical, 57
operative, 107
Phelps bed in, 58
plaster corset in, 79
jacket in, 66
Taylor back brace in, 81
Thomas collar in, 89
weak foot and, 113
weakness in, 25
of subastragaloid joint, 492
of tarsus, 496
treatment of, 497
of wrist-joint, 513
age in, 516
atrophy in, 516
limitation of motion in, 516
pain in, 516
prognosis of, 516
sensitiveness in, 516
swelling in, 516
symptoms of, 516
treatment of, 516
rheumatism, 268
tenosynovitis, 504
Tumor albus, 435
Tumors of bone, 324
of spine, 114
of tendon sheaths, 504
Typhoid fever, arthritis and, 286
spine, 119
vaccine in arthritis deformans, 306

U

Ulna, displacement of, congenital, 540
Unilateral congenital dislocation at hip-joint, 582
coxa vara, 621
genu valgum, 645
knock-knee, 645
Upper extremity, deformities of, 525
in acute anterior poliomyelitis, 675

V

Valgus deformities, congenital genu recurvatum and, 479
Vanghetti's amputation, 1012
Varicose veins, injection treatment of, 825
Verrall's operation for injury of sacro-iliac articulation, 147
Varus deformities, congenital genu recurvatum and, 479
Vasomotor trophic neuroses of foot, 822
Vertebræ, deficiency of, 242
malformation of, 242
Vertebral column, stiffness of, 120
epiphysitis, 234
of adolescence, diagnosis of, from Pott's disease, 47
Volkmann seat in lateral curvature of spine, 231

W

Waddle in congenital dislocation at hip-joint, 585
Walton's method of reduction of dislocation of cervical vertebræ, 1009
Warts, painful, 816
Weak foot, 767
diagnosis of, 775
attitudes in, 775
bearing surface of, 776
contour in, 776
distribution of weight and strain in, 775
range of motion of, 777
etiology of, 772
in childhood, 781
deformity of legs and, 782
general weakness and, 783
irregular forms of, 782
symptoms of, in-toeing, 781
out-toeing, 781
outgrown joints, 782
weak ankles, 782
limitation of motion in, 779
muscular spasm in, 779
pathology of, 773
review of, 784
rigid, 792
manipulation in, 795
overcorrection in, 793
plaster strapping, 799
treatment of, 792
adjuncts in, 798
Thomas', 798
varieties of, 797
symptoms of, 773
treatment of, 784
attitudes in, 786
brace in, 790
construction of, 788
exercise in, 786
operative, 800
plaster cast in, 788
shoe in, 785
support in, 787
types of, 780
Weakness of anterior metatarsal arch, 808
in tuberculous disease of spine, 37

MEDICAL LIBRARY BOSTON CITY HOSPITAL

Webbed fingers, 547
Webb's treatment of ingrown toe-nail, 836
Weight in childhood, table of, 256
of muscular substance of long muscles of lower extremity of adult, 932
White swelling, 435
Whitman's abduction treatment for fracture of neck of femur, 978
in adult life, 978
in childhood, 978
in epiphyseal fracture, 978
brace for paralytic calcaneus. *See* Calcaneus.
for flat foot, Fig. 688, 790
loop operation for paralytic valgus, 912
method of correcting flexion deformity at knee by reverse leverage, 441
operation in acquired talipes calcaneus, 924
for paralytic talipes, 924
reconstruction operation, 987
for arthritis deformans of hip, 992
Willems' method of draining purulent synovitis of knee-joint, 287
Willett's operation for acquired talipes calcaneus, 922
Willett's operation, paralytic talipes, 922
Wolff's law of functional pathogenesis of deformity, 250
treatment of genu valgum, 654
of knock-knee, 654
of neglected talipes, 878
Wrenches in treatment of neglected talipes, 879
Wrist, congenital deformities at, 544
subluxation of, 542
etiology of, 543
treatment of, 543
Wrist-joint, sprain of, 522
chronic, 522
pain in, 522
treatment of, 522
tenosynovitis of, 523
acute, 523
chronic, 523
tuberculous disease of, 513
atrophy in, 516
limitation of motion in, 516
prognosis of, 516
symptoms of, 516
treatment of, 516
Wry-neck, 733. *See* Torticollis.

X

X-RAYS. *See* Roentgen-rays.

18.P.78.
A treatise on orthopaedic surge1930
Countway Library AIY7354
3 2044 045 144 896

18.P.78.
A treatise on orthopaedic surge1930
Countway Library AIY7354
3 2044 045 144 896